


# World Journal of *Gastroenterology*

*World J Gastroenterol* 2022 July 14; 28(26): 3008-3281



## REVIEW

- 3008** Advances in the imaging of gastroenteropancreatic neuroendocrine neoplasms  
*Ramachandran A, Madhusudhan KS*
- 3027** Tumor microenvironment involvement in colorectal cancer progression *via* Wnt/ $\beta$ -catenin pathway: Providing understanding of the complex mechanisms of chemoresistance  
*Novoa Díaz MB, Martín MJ, Gentili C*
- 3047** Role of baicalin as a potential therapeutic agent in hepatobiliary and gastrointestinal disorders: A review  
*Ganguly R, Gupta A, Pandey AK*

## MINIREVIEWS

- 3063** Alterations of autophagic and innate immune responses by the Crohn's disease-associated ATG16L1 mutation  
*Okai N, Watanabe T, Minaga K, Kamata K, Honjo H, Kudo M*
- 3071** Anabolic androgenic steroid-induced liver injury: An update  
*Petrovic A, Vukadin S, Sikora R, Bojanic K, Smolic R, Plavec D, Wu GY, Smolic M*
- 3081** Epidemiological and clinical aspects of hepatitis B virus infection in Italy over the last 50 years  
*Sagnelli C, Sica A, Creta M, Calogero A, Ciccozzi M, Sagnelli E*
- 3092** Shared decision-making in the management of patients with inflammatory bowel disease  
*Song K, Wu D*
- 3101** Clinical implications and mechanism of histopathological growth pattern in colorectal cancer liver metastases  
*Kong BT, Fan QS, Wang XM, Zhang Q, Zhang GL*
- 3116** Role of gadoteric acid-enhanced liver magnetic resonance imaging in the evaluation of hepatocellular carcinoma after locoregional treatment  
*Gatti M, Maino C, Darvizeh F, Serafini A, Tricarico E, Guarneri A, Inchingolo R, Ippolito D, Ricardi U, Fonio P, Faletti R*

## ORIGINAL ARTICLE

## Basic Study

- 3132** Neutrophil extracellular traps participate in the development of cancer-associated thrombosis in patients with gastric cancer  
*Li JC, Zou XM, Yang SF, Jin JQ, Zhu L, Li CJ, Yang H, Zhang AG, Zhao TQ, Chen CY*
- 3150** Activation of natural killer T cells contributes to Th1 bias in the murine liver after 14 d of ethinylestradiol exposure  
*Zou MZ, Kong WC, Cai H, Xing MT, Yu ZX, Chen X, Zhang LY, Wang XZ*

- 3164** *Bifidobacterium infantis* regulates the programmed cell death 1 pathway and immune response in mice with inflammatory bowel disease

Zhou LY, Xie Y, Li Y

- 3177** Involvement of Met receptor pathway in aggressive behavior of colorectal cancer cells induced by parathyroid hormone-related peptide

Novoa Díaz MB, Carriere P, Gigola G, Zwenger AO, Calvo N, Gentili C

- 3201** Intracellular alpha-fetoprotein mitigates hepatocyte apoptosis and necroptosis by inhibiting endoplasmic reticulum stress

Chen YF, Liu SY, Cheng QJ, Wang YJ, Chen S, Zhou YY, Liu X, Jiang ZG, Zhong WW, He YH

### Retrospective Cohort Study

- 3218** Divergent trajectories of lean *vs* obese non-alcoholic steatohepatitis patients from listing to post-transplant: A retrospective cohort study

Qazi-Arisar FA, Uchila R, Chen C, Yang C, Chen SY, Karnam RS, Azhie A, Xu W, Galvin Z, Selzner N, Lilly L, Bhat M

### Retrospective Study

- 3232** Tumor-feeding artery diameter reduction is associated with improved short-term effect of hepatic arterial infusion chemotherapy plus lenvatinib treatment

Wu DD, He XF, Tian C, Peng P, Chen CL, Liu XH, Pang HJ

### Observational Study

- 3243** Impact of sodium glucose cotransporter-2 inhibitors on liver steatosis/fibrosis/inflammation and redox balance in non-alcoholic fatty liver disease

Bellanti F, Lo Buglio A, Dobrakowski M, Kasperczyk A, Kasperczyk S, Aich P, Singh SP, Serviddio G, Vendemiale G

## SYSTEMATIC REVIEWS

- 3258** Endoscopic techniques for diagnosis and treatment of gastro-entero-pancreatic neuroendocrine neoplasms: Where we are

Rossi RE, Elvevi A, Gallo C, Palermo A, Invernizzi P, Massironi S

## LETTER TO THE EDITOR

- 3274** Intestinal inflammation and the microbiota: Beyond diversity

Alberca GGF, Cardoso NSS, Solis-Castro RL, Nakano V, Alberca RW

- 3279** Intestinal virome: An important research direction for alcoholic and nonalcoholic liver diseases

Li Y, Liu WC, Chang B

**ABOUT COVER**

Editorial Board Member of *World Journal of Gastroenterology*, Koichi Suda, MD, PhD, FACS, Professor and Head, Divisions of GI and HPB Surgery, Department of Surgery, Fujita Health University, Rm C908, 1-98 Dengakugakubo, Kutsukake, Toyoake, Aichi 470-1192, Japan. ko-suda@fujita-hu.ac.jp

**AIMS AND SCOPE**

The primary aim of *World Journal of Gastroenterology* (WJG, *World J Gastroenterol*) is to provide scholars and readers from various fields of gastroenterology and hepatology with a platform to publish high-quality basic and clinical research articles and communicate their research findings online. WJG mainly publishes articles reporting research results and findings obtained in the field of gastroenterology and hepatology and covering a wide range of topics including gastroenterology, hepatology, gastrointestinal endoscopy, gastrointestinal surgery, gastrointestinal oncology, and pediatric gastroenterology.

**INDEXING/ABSTRACTING**

The WJG is now abstracted and indexed in Science Citation Index Expanded (SCIE, also known as SciSearch®), Current Contents/Clinical Medicine, Journal Citation Reports, Index Medicus, MEDLINE, PubMed, PubMed Central, Scopus, Reference Citation Analysis, China National Knowledge Infrastructure, China Science and Technology Journal Database, and Superstar Journals Database. The 2022 edition of Journal Citation Reports® cites the 2021 impact factor (IF) for WJG as 5.374; IF without journal self cites: 5.187; 5-year IF: 5.715; Journal Citation Indicator: 0.84; Ranking: 31 among 93 journals in gastroenterology and hepatology; and Quartile category: Q2. The WJG's CiteScore for 2021 is 8.1 and Scopus CiteScore rank 2021: Gastroenterology is 18/149.

**RESPONSIBLE EDITORS FOR THIS ISSUE**

Production Editor: Hua-Ge Yu; Production Department Director: Xu Guo; Editorial Office Director: Jia-Ru Fan.

**NAME OF JOURNAL**

*World Journal of Gastroenterology*

**ISSN**

ISSN 1007-9327 (print) ISSN 2219-2840 (online)

**LAUNCH DATE**

October 1, 1995

**FREQUENCY**

Weekly

**EDITORS-IN-CHIEF**

Andrzej S Tarnawski

**EDITORIAL BOARD MEMBERS**

<http://www.wjgnet.com/1007-9327/editorialboard.htm>

**PUBLICATION DATE**

July 14, 2022

**COPYRIGHT**

© 2022 Baishideng Publishing Group Inc

**INSTRUCTIONS TO AUTHORS**

<https://www.wjgnet.com/bpg/gerinfo/204>

**GUIDELINES FOR ETHICS DOCUMENTS**

<https://www.wjgnet.com/bpg/GerInfo/287>

**GUIDELINES FOR NON-NATIVE SPEAKERS OF ENGLISH**

<https://www.wjgnet.com/bpg/gerinfo/240>

**PUBLICATION ETHICS**

<https://www.wjgnet.com/bpg/GerInfo/288>

**PUBLICATION MISCONDUCT**

<https://www.wjgnet.com/bpg/gerinfo/208>

**ARTICLE PROCESSING CHARGE**

<https://www.wjgnet.com/bpg/gerinfo/242>

**STEPS FOR SUBMITTING MANUSCRIPTS**

<https://www.wjgnet.com/bpg/GerInfo/239>

**ONLINE SUBMISSION**

<https://www.f6publishing.com>



## Retrospective Study

# Tumor-feeding artery diameter reduction is associated with improved short-term effect of hepatic arterial infusion chemotherapy plus lenvatinib treatment

De-Di Wu, Xiao-Feng He, Chen Tian, Peng Peng, Chuan-Li Chen, Xue-Han Liu, Hua-Jin Pang

**Specialty type:** Gastroenterology and hepatology

**Provenance and peer review:**

Unsolicited article; Externally peer reviewed.

**Peer-review model:** Single blind

**Peer-review report's scientific quality classification**

Grade A (Excellent): 0  
Grade B (Very good): B  
Grade C (Good): C  
Grade D (Fair): 0  
Grade E (Poor): 0

**P-Reviewer:** Dilek ON, Turkey; Tsoulfas G, Greece

**Received:** January 22, 2022

**Peer-review started:** January 22, 2022

**First decision:** March 8, 2022

**Revised:** March 17, 2022

**Accepted:** June 18, 2022

**Article in press:** June 18, 2022

**Published online:** July 14, 2022



**De-Di Wu, Xiao-Feng He, Chen Tian, Peng Peng, Hua-Jin Pang,** Division of Vascular and Interventional Radiology, Department of General Surgery, Nanfang Hospital, Southern Medical University, Guangzhou 510515, Guangdong Province, China

**Chuan-Li Chen,** Medical Imaging Center, Nanfang Hospital, Southern Medical University, Guangzhou 510515, Guangdong Province, China

**Xue-Han Liu,** Department of Statistics, Huazhong University of Science and Technology, Wuhan 430000, Hubei Province, China

**Corresponding author:** Hua-Jin Pang, PhD, Associate Chief Physician, Associate Professor, Division of Vascular and Interventional Radiology, Department of General Surgery, Nanfang Hospital, Southern Medical University, No. 1838 North Baiyun Avenue, Guangzhou 510515, Guangdong Province, China. [nfyphj@163.com](mailto:nfyphj@163.com)

## Abstract

### BACKGROUND

Recently, hepatic arterial infusion chemotherapy (HAIC) plus lenvatinib has been frequently used to treat unresectable hepatocellular carcinoma (uHCC) in China. In the clinic, the hepatic arteries of some patients shrink significantly during this treatment, leading to improved short-term efficacy.

### AIM

To investigate the relationship between the shrinkage of hepatic arteries and the short-term effect of HAIC plus lenvatinib treatment.

### METHODS

Sixty-seven participants with uHCC were enrolled in this retrospective study. The patients received HAIC every 3 wk, followed by oral lenvatinib after the first HAIC course. Hepatic artery diameters were measured on CT before treatment and after 1 and 2 mo of treatment. Meanwhile, the changes in tumor capillaries were also examined on pathological specimens before and after 1 mo of treatment. The antitumor response after 1, 3, and 6 mo of treatment was assessed using the modified Response Evaluation Criteria in Solid Tumors (mRECIST). The relationship between the changes in vessel diameters and the short-term effect of the combination treatment was evaluated by receiver-operating characteristic and



logistic regression analyses.

## RESULTS

The hepatic artery diameters were all significantly decreased after 1 and 2 mo of treatment ( $P < 0.001$ ), but there was no difference in the vessel diameters between 1 and 2 mo ( $P > 0.05$ ). The microvessel density in the tumor lesions decreased significantly after 1 mo of combination treatment ( $P < 0.001$ ). According to mRECIST, 46, 41, and 24 patients had complete or partial responses after 1, 3, and 6 mo of treatment, respectively, whereas 21, 21, and 32 patients had a stable or progressive disease at these times, respectively. Shrinkage of the tumor-feeding artery was significantly associated with the tumor response after 1, 3, and 6 mo of treatment ( $P < 0.001$ ,  $P = 0.004$ , and  $P = 0.023$ , respectively); however, changes in other hepatic arteries were not significantly associated with the tumor response. Furthermore, shrinkage of the tumor-feeding artery was an independent factor for treatment efficacy ( $P = 0.001$ ,  $P = 0.001$ , and  $P = 0.002$  and 1, 3, and 6 mo, respectively).

## CONCLUSION

The hepatic arteries shrank rapidly after treatment with HAIC plus lenvatinib, and shrinkage of the tumor-feeding artery diameter was closely related to improved short-term efficacy.

**Key Words:** Hepatocellular carcinoma; Hepatic arterial infusion chemotherapy; Lenvatinib; Short-term effect; Hepatic artery; Vessel diameter

©The Author(s) 2022. Published by Baishideng Publishing Group Inc. All rights reserved.

**Core Tip:** In this study, it was observed for the first time that the hepatic arteries shrank rapidly after hepatic arterial infusion chemotherapy plus lenvatinib therapy, and the close relationship between shrinkage of the tumor-feeding artery and improved short-term effect in patients with unresectable hepatocellular carcinoma was also confirmed. These findings would be of great significance to physicians for evaluating the effectiveness of this combination therapy earlier in the course of treatment and altering the treatment plan as needed.

**Citation:** Wu DD, He XF, Tian C, Peng P, Chen CL, Liu XH, Pang HJ. Tumor-feeding artery diameter reduction is associated with improved short-term effect of hepatic arterial infusion chemotherapy plus lenvatinib treatment. *World J Gastroenterol* 2022; 28(26): 3232-3242

**URL:** <https://www.wjgnet.com/1007-9327/full/v28/i26/3232.htm>

**DOI:** <https://dx.doi.org/10.3748/wjg.v28.i26.3232>

## INTRODUCTION

Hepatocellular carcinoma (HCC) is one of the most common malignant tumors, with 850000 new cases reported per year worldwide[1,2]. In total, 70%-80% of patients with HCC in China are ineligible for surgical resection at the time of onset[3]. Recently, hepatic arterial infusion chemotherapy (HAIC) has been increasingly used to treat patients with unresectable HCC (uHCC) in Asian countries[4,5]. HAIC is recommended as a major treatment option in patients with intermediate and advanced HCC by current Japanese and Chinese guidelines[6].

Lenvatinib is an oral multi-target tyrosine kinase inhibitor (TKI) with antiangiogenic effects. Previous studies demonstrated the survival benefit of lenvatinib plus HAIC *vs* lenvatinib alone in patients with advanced HCC[7]. This combination therapy often requires 6-8 cycles, and early assessment of the antitumor response appears essential for both patients and physicians[8].

Recently, a clinical study demonstrated that the diameters of hepatic arteries are significantly reduced after TKI therapy[9]. Since the early imaging response is often associated with survival benefits, it should be clarified whether the changes in hepatic vessel diameters are related to the efficacy of HAIC combined with lenvatinib. As a result, we conducted a retrospective study of patients with uHCC treated with HAIC plus lenvatinib. The aim of this study was to: (1) Explore the changes in hepatic arteries after combination treatment; and (2) Determine the relationship between the hepatic artery changes and early therapeutic effects.

## MATERIALS AND METHODS

### Patient eligibility

This was a single-center, retrospective analysis of data from 67 patients with uHCC treated at our institution from January 2019 to October 2020. Approval for the study was obtained from the local ethics committee on human research. The HCC diagnosis was based on the findings of pathological, imaging, and clinical assessments using the European Association for the Study of the Liver criteria[10]. Eligible patients were those aged 18 years or older with uHCC (including patients with large/multifocal HCC and/or with vascular invasion and extrahepatic spread) who received HAIC plus lenvatinib as an initial treatment. Patients who underwent transcatheter arterial chemoembolization or received other TKIs before combination therapy were excluded. Enrolled patients who discontinued treatment during the follow-up period were also excluded.

### Treatments

HAIC was repeated at an interval of 3 wk in enrolled patients in our hospital. A catheter was initially advanced into the celiac or superior mesenteric artery for digital subtraction angiography from the femoral artery; then, a microcatheter was left in the tumor-feeding artery (TFA) for subsequent treatment.

The patients received the following regimen for HAIC through the indwelling microcatheter connected to an artery infusion pump in the ward: oxaliplatin 85 mg/m<sup>2</sup> administered intraarterially for 2 h, leucovorin 400 mg/m<sup>2</sup> administered intraarterially for 1 h, and 5FU 400 mg/m<sup>2</sup> intra-arterial bolus injection on day 1, followed by 5FU 2400 mg/m<sup>2</sup> continuous arterial infusion for 46 h. Three days after the first HAIC course, patients began to take lenvatinib (Eisai, Tokyo, Japan) orally at the recommended doses of 12 mg/day for patients weighing ≥ 60 kg and 8 mg/day for patients weighing < 60 kg[11]. Dose adjustment or termination of lenvatinib therapy was allowed when drug-related adverse events (AEs) occurred. Discontinuation of the combination treatment was also allowed for potentially fatal AEs, clinical tumor progression, or the need for conversion therapy.

### Evaluations and measurement

Therapeutic responses after 1, 3, and 6 mo of combination treatment were assessed according to the modified Response Evaluation Criteria in Solid Tumors using CT (Philips Brilliance iCT; Philips Medical Systems, Best, the Netherlands) images. Treatment responders were defined as patients with a complete response (CR) or partial response (PR). Non-responders were defined as patients with stable disease (SD) or progressive disease (PD). AEs were assessed using the Common Terminology Criteria for Adverse Events (CTCAE) version 5.0[12].

Epigastric enhanced CT Digital Imaging and Communication of Medicine (DICOM) data were collected before treatment and after 1 and 2 mo of treatment and introduced into an image post-processing workstation (Philips IntelliSpace Portal; Koninklijke Philips N.V., Eindhoven, the Netherlands) for three-dimensional reconstruction. On the image post-processing workstation, multiplanar reconstruction images centered on the contrast-enhanced hepatic arteries and the centerline (CLL) of the blood vessels were generated by the software to straighten the curved arteries. The trunk or the thickest branch of the TFA was selected as the object of measurement. The CLL was adjusted manually to measure the largest diameter of the arteries. The diameters of the opening of the common hepatic artery (CHA), proper hepatic artery (PHA), left hepatic artery (LHA), right hepatic artery (RHA), and TFA were further measured by manually drawing the region of interest (Figure 1)[13]. The change in vessel diameters was defined and calculated using the following formula:  $\Delta_{\text{artery}} = (D_{\text{post}} - D_{\text{pre}}) / D_{\text{pre}}$  ( $\Delta_{\text{artery}}$ : The rate of change in the diameter of CHA, PHA, LHA, RHA, or TFA;  $D_{\text{pre}}$ : The vessel diameter before combination treatment;  $D_{\text{post}}$ : The vessel diameter after combination treatment).

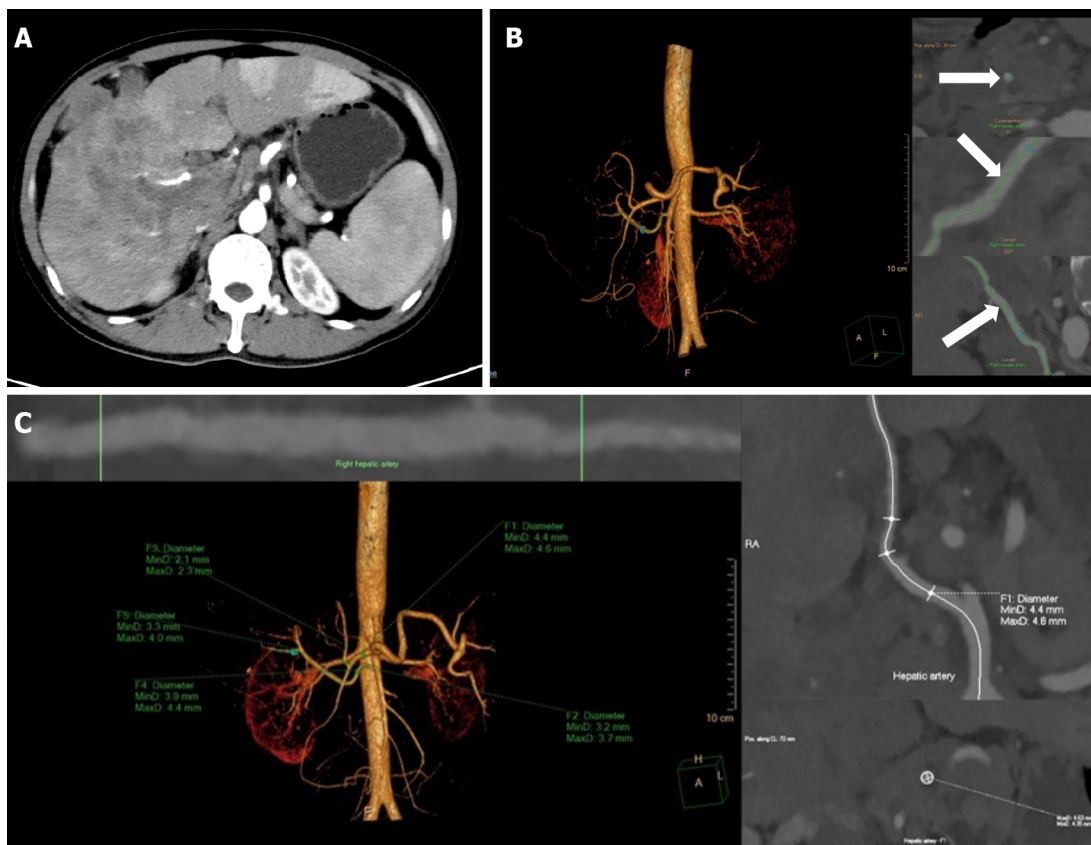
Both the measurement of artery diameters and the evaluation of therapeutic efficacy were individually conducted by two physicians with experience in gastroenterological diagnostics, and differences were resolved by a more experienced physician.

### Immunohistochemistry

Tumor angiogenesis was evaluated by measuring microvessel density (MVD) after staining using an anti-CD34 antibody. Punch biopsy samples were obtained from tumor lesions before and 1 mo after the start of HAIC plus lenvatinib therapy. The tumor samples were fixed in 10% formalin and embedded in paraffin. After routine laboratory procedures, immunohistochemistry was performed to detect the expression of CD34 (endothelial cell marker) through the avidin-biotin-peroxidase complex[14,15]. MVD was measured at × 100 magnification in five regions of interest using a light microscope. All endothelial cells, including individual cells and grouped cells, were counted as a single vessel if they were separated from the surrounding tumor and other connective tissues[16].

### Statistical analysis

Statistical analyses were performed using IBM SPSS Statistics 26.0. The measurement data were presented as the mean ± SD, and  $P < 0.05$  indicated statistical significance. Considering the loss to



DOI: 10.3748/wjg.v28.i26.3232 Copyright ©The Author(s) 2022.

**Figure 1 Reconstruction and measurement of the hepatic arteries.** A: The thickest branch of tumor-feeding arteries generated from the right hepatic artery; B: Three-dimensional reconstruction of hepatic arteries in an image post-processing workstation and the adjustment of center line (arrows) on multiple layers; C: The hepatic artery diameters are measured automatically by drawing the region of interest. F1-5, the opening of the common hepatic artery, the proper hepatic artery, the left hepatic artery, the right hepatic artery and the tumor-feeding artery.

follow-up, the changes in the artery diameters were compared using the mixed linear model for repeated measured data, and follow-up pairwise comparison was conducted among the three periods. The independent-samples *t*-test was used to analyze the changes in MVD. Receiver-operating characteristic (ROC) analysis was used to evaluate the changes in the diameter of all hepatic arteries to differentiate between responders and non-responders and identify the cutoff values. The cutoff was calculated for any factors that were statistically significant in the ROC analysis, which were candidates for univariate and multivariable logistic regression analyses with baseline data.

## RESULTS

### Participant characteristics

During the study period, patients meeting the inclusion criteria were followed up for 6 mo after the start of the combination treatment. The study population was predominantly male (59/67, 88.1%), and most of the enrolled patients were infected with hepatitis B virus (53/67, 79.1%). In total, 45 (67.2%) patients were estimated to have Child-Pugh stage A liver function, and 22 (32.8%) patients were categorized as Child-Pugh stage B. Portal vein tumor thrombosis was diagnosed in 44 (65.7%) patients, hepatic vein tumor thrombus in 17 (25.4%) patients, and extrahepatic spread occurred in 13 (19.4%) patients. The characteristics of the patients are summarized in Table 1.

### Treatment-related AEs

There were no treatment-related deaths in our study. According to CTCAE, grade 1-2 events were observed in 37 patients (55.2%) and grade 3 events in 2 (3.0%) patients, whereas no grade  $\geq 4$  AEs occurred. The most common grade 1-2 events were abdominal pain (17/67, 25.4%), fever (8/67, 11.9%), and transient nausea and vomiting (8/67, 11.9%). The grade 3 events were liver dysfunction and decreased leukocyte counts, both of which normalized after treatment.



**Table 1** The baseline characteristics of patients

Characteristics	n (%)
Age	
≤ 60	52 (77.6)
> 60	15 (22.4)
Gender	
Male	59 (88.1)
Female	8 (11.9)
ECOG PS	
0	52 (77.6)
1	15 (22.4)
HBsAg	
Positive	53 (79.1)
Negative	14 (20.9)
Child-Pugh Class	
Class A	45 (67.2)
Class B	22 (32.8)
Tumor size, cm	
≤ 10	43 (64.2)
> 10	24 (35.8)
No. of intrahepatic tumors	
≤ 3	32 (47.8)
> 3	35 (52.2)
Baseline AFP level, ng/mL	
≤ 400	29 (43.3)
> 400	38 (56.7)
PVTT	
Absent	23 (34.3)
Present	44 (65.7)
HVTT	
Absent	50 (74.6)
Present	17 (25.4)
Metastasis	
Absent	54 (80.6)
Present	13 (19.4)

ECOG PS: Eastern Cooperative Oncology Group performance status; HBsAg: Hepatitis B surface antigen; AFP: Alfa-fetoprotein; PVTT: Portal vein tumor thrombus; HVTT: Hepatic vein tumor thrombus.

### Efficacy

Five patients missed the 3-mo imaging evaluation, and 11 patients missed the 6-mo evaluation because of loss to follow-up. In total, 46, 41, and 24 patients were classified as responders (CR + PR) after 1, 3, and 6 mo of treatment, respectively, whereas the numbers of non-responders (SD + PD) at these time points were 21, 21, and 32, respectively. The overall response rates (ORR) in this study at 1, 3, and 6 mo were 68.7%, 66.1%, and 42.9%, respectively. Eight patients received downstaging therapy within 1 year after treatment, of which six patients underwent hepatectomy and the other two patients underwent radiofrequency ablation.

### Artery diameters

Vessel diameters were measured in all patients before treatment and after 1 mo of treatment, whereas six patients missed the 2-month measurement. After 1 and 2 mo of treatment, all vessel diameters had gradually decreased compared with the baseline ( $P < 0.001$ ), but the difference in vessel diameters between 1 and 2 mo was not significant ( $P > 0.05$ , Figure 2). According to the ROC analysis, the change in the TFA diameter was significantly different between the responders and non-responders at 1, 3, and 6 mo ( $P < 0.001$ ,  $P = 0.004$ , and  $P = 0.023$ , respectively), and the corresponding cutoff values were -0.169, -0.169, and -0.264, respectively. Meanwhile, there were no significant differences in the diameters of other hepatic arteries between the groups (Table 2). Considering the unclear clinical meaning of continuous changes in vessel diameters, the change in the TFA diameter was classified as reduced or unchanged based on the cutoff values.

The results of the univariate and multivariable logistic regression analyses of tumor response are listed in Table 3. According to the multivariable analysis, the change in the TFA diameter was an independent factor for the efficacy of HAIC plus lenvatinib after 1 [odds ratio (OR) = 0.12; 95% confidence interval (CI): 0.03-0.43;  $P = 0.001$ ], 3 (OR = 0.06; 95%CI: 0.01-0.29;  $P = 0.001$ ), and 6 mo (OR = 0.14; 95%CI: 0.04-0.47;  $P = 0.002$ ) of treatment. Other independent factors included the alpha-fetoprotein level (OR = 0.17; 95%CI: 0.04-0.73;  $P = 0.018$ ) at 1 mo and tumor size (OR = 7.65; 95%CI: 1.36-42.88;  $P = 0.021$ ) at 3 mo.

### MVD

The MVD of tumor lesions after the administration of lenvatinib was robustly smaller than that before treatment, suggesting that angiogenesis was strongly suppressed by lenvatinib ( $P < 0.001$ , Figure 3).

## DISCUSSION

In the present study, significant shrinkage of hepatic arteries was observed in patients with uHCC after 1 mo of HAIC plus lenvatinib therapy for the first time. We also confirmed that the morphological change in the TFA was closely related to the tumor response after 1, 3, and 6 mo of combination treatment, and this change was an independent factor for improved short-term therapeutic efficacy. These findings would be of great significance to physicians for evaluating the effectiveness of this combination therapy earlier in the course of treatment and altering the treatment plan as needed.

Hepatic arteries were shown to be markedly thin following TKI treatment, and Chen *et al*[17] attributed these morphological changes to the anti-angiogenic effect of targeted drugs. Notably, lenvatinib more effectively suppresses angiogenesis and inhibits tumor growth than sorafenib by targeting both vascular endothelial growth factor (VEGF) and fibroblast growth factor[18,19]. In our study, shrinkage of hepatic vessels was observed early after the start of HAIC plus lenvatinib therapy, and the powerful antiangiogenic effect of lenvatinib was proven by the decrease in the MVD of the tumor lesions. Meanwhile, anti-VEGF therapies can reverse vessel abnormalities and improve the tumor microenvironment[20]. The decline in local tumor perfusion secondary to the decrease in tumor capillaries and the “normalization hypothesis” may be the main reasons for the conspicuous reduction of hepatic arteries with the combination regimen.

The efficiency of HAIC combined with lenvatinib for intermediate and advanced HCC has been confirmed in previous studies[21,22]. In this study, the ORR reached 68.7%, 66.1%, and 42.9% at 1, 3, and 6 mo, and conversion therapy was achieved in eight patients, which further verified the effectiveness of the combination therapy. Thus, it was necessary to explore the mechanism of action of this combination therapy. A reduction in hepatic artery diameters was observed in most patients in the present study. Kuorda *et al*[23] also reported that local tumor perfusion declined significantly after oral lenvatinib administration. These findings illustrated that lenvatinib reduces the tumor blood supply after combination therapy. Meanwhile, HAIC has the advantage of achieving high local concentrations in the tumor during arterial infusion[24]. According to the pharmacokinetic characteristics of the intra-arterial infusion[25], a decrease in tumor blood flow can increase the dose of the drug in the target organ, thus enhancing the antitumor effect of HAIC. Furthermore, the normalization and improved functionality of tumor vessels including reduced hypoxia, reduced vascular leakage, and improved vascular permeability can improve the delivery of local chemotherapeutic drugs in tumors[26,27]. The increased drug accumulation in the target organ often results in improved therapeutic efficacy. Since the combined therapy could improve the therapeutic effect, it may also expand the scope of HAIC, which is limited to patients with HCC and multinodule lesions or vascular invasion.

In clinical practice, HAIC often requires 6-8 courses. Moreover, repetitive and inefficient treatment is harmful to patients with uHCC. Therefore, early evaluation of the treatment response is of great significance. In this study, we found that the reduction in the TFA diameter after combination therapy was an independent factor for improved therapeutic efficacy within 6 mo. The morphological change in the TFA is easy to observe during HAIC, and it can help in estimating the early therapeutic effect. Since an improved short-term effect often results in a good prognosis, the observation on thinning of the TFA is significant and more practical for patients with uHCC who are receiving HAIC plus lenvatinib.

**Table 2 Receiver-operating characteristic analysis for antitumor response**

$\Delta$ artery	1 mo			3 mo			6 mo		
	Responder	Non-responder	P value	Responder	Non-responder	P value	Responder	Non-responder	P value
CHA	-(0.17 ± 0.17)	-(0.14 ± 0.18)	0.25	-(0.15 ± 0.16)	-(0.18 ± 0.19)	1.00	-(0.18 ± 0.16)	-(0.15 ± 0.18)	0.51
PHA	-(0.21 ± 0.14)	-(0.13 ± 0.25)	0.15	-(0.20 ± 0.15)	-(0.16 ± 0.20)	0.35	-(0.16 ± 0.16)	-(0.22 ± 0.17)	0.30
LHA	-(0.27 ± 0.17)	-(0.21 ± 0.28)	0.59	(0.28 ± 0.18)	(0.20 ± 0.27)	0.43	-(0.22 ± 0.24)	-(0.30 ± 0.17)	0.18
RHA	-(0.22 ± 0.17)	-(0.16 ± 0.23)	0.26	-(0.20 ± 0.19)	-(0.22 ± 0.20)	0.58	-(0.16 ± 0.23)	-(0.24 ± 0.17)	0.44
TFA	-(0.33 ± 0.20)	-(0.16 ± 0.19)	< 0.001	-(0.32 ± 0.19)	-(0.18 ± 0.22)	0.004	-(0.36 ± 0.16)	-(0.25 ± 0.23)	0.023

$\Delta$  artery: The rate of change in vessel diameters of hepatic arteries; CHA: Common hepatic artery; PHA: Proper hepatic artery; LHA: Left hepatic artery; RHA: Right hepatic artery; TFA: Tumor-feeding artery.

**Table 3 Univariate and multivariate logistic regression analysis for efficacy of treatment with hepatic arterial infusion chemotherapy plus lenvatinib**

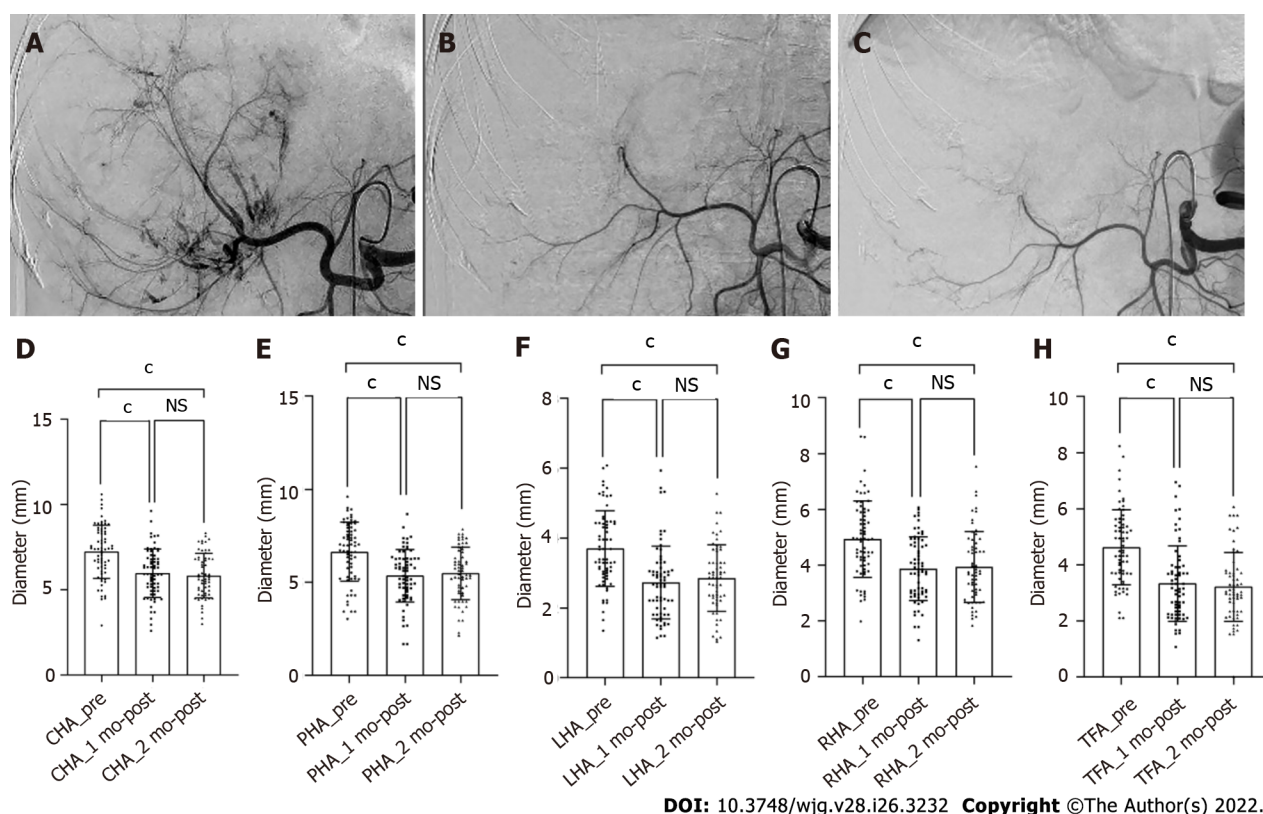
	1 mo			3 mo			6 mo		
	Univariate	Multivariate		Univariate	Multivariate		Univariate	Multivariate	
	P1 value	P2 value	OR (95%CI)	P1 value	P2 value	OR (95%CI)	P1 value	P2 value	OR (95%CI)
TFA (reduced/basically unchanged)	< 0.001	0.001	0.12 (0.03-0.43)	< 0.001	0.001	0.06 (0.01-0.29)	0.002	0.002	0.14 (0.04-0.47)
Sex (male/female)	0.680	-	-	0.349	-	-	0.892	-	-
Age ( $\leq 60$ / $> 60$ )	0.850	-	-	0.868	-	-	0.573	-	-
ECOG (0/1)	0.412	-	-	0.147	-	-	0.365	-	-
HBsAg (positive/negative)	0.122	-	-	0.113	-	-	0.784	-	-
AFP, ng/mL ( $\leq 400$ / $> 400$ )	0.003	0.018	0.17 (0.04-0.73)	0.089	0.546	-	0.040	0.122	-
Child-Pugh (A/B)	0.384	-	-	0.897	-	-	0.869	-	-
Tumor size, cm ( $\leq 10$ / $> 10$ )	0.166	-	-	0.053	0.021	7.65 (1.36-42.88)	0.625	-	-
Tumor number ( $\leq 3$ / $> 3$ )	0.609	-	-	0.533	-	-	0.280	-	-
PVTT (absent/present)	0.220	-	-	0.169	-	-	0.577	-	-
HVTT (absent/present)	0.842	-	-	0.455	-	-	1.000	-	-
Metastasis (absent/present)	0.960	-	-	0.694	-	-	0.615	-	-

Any factors that were statistically significant at  $P < 0.10$  in the univariate logistic regression analysis were candidates for entry into the multivariate logistic regression analysis. TFA: The tumor-feeding artery; ECOG PS: Eastern Cooperative Oncology Group performance status; HBsAg: Hepatitis B surface antigen; AFP: Alfa-fetoprotein; PVTT: Portal vein tumor thrombus; HVTT: Hepatic vein tumor thrombus; OR: Odds ratio; CI: Confidence interval.

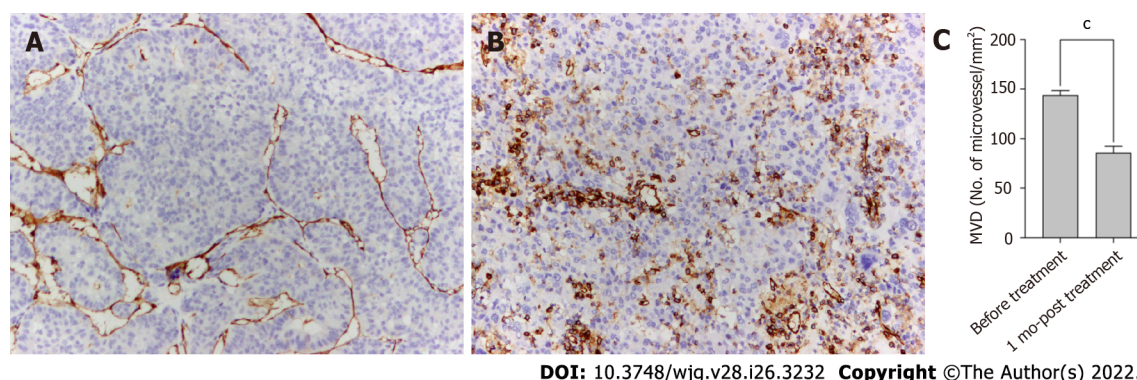
The present study had some limitations. This was a single-center retrospective study, and the sample size was small.

## CONCLUSION

In conclusion, lenvatinib can reduce the diameters of hepatic arteries and thus enhance the effect of HAIC. Shrinkage of the TFA after HAIC plus lenvatinib therapy was linked to improved short-term outcomes in patients with uHCC.



**Figure 2** Shrinkage of the hepatic artery diameters in patient with unresectable hepatocellular carcinoma after treatment with hepatic arterial infusion chemotherapy plus lenvatinib. A-C: Digital subtraction angiography performed before treatment (A), after 1 (B) and 2 (C) mo of treatment; D-H: Bars represent the vessel diameters before treatment, at 1 and 2 mo after treatment. *P*-values are calculated using the mixed linear model for repeated measured data. <sup>c</sup>*P* < 0.001. NS: Not significant (*P* > 0.05); CHA: Common hepatic artery; PHA: Proper hepatic artery; LHA: Left hepatic artery; RHA: Right hepatic artery; TFA: Tumor-feeding artery.



**Figure 3** Anti-angiogenic activities of lenvatinib in tumor lesions. A and B: The microvessels in the tumor lesion collected before (A) and after 1 mo (B) of treatment with lenvatinib are stained with anti-CD34 antibody ( $\times 100$ ); C: Bars represent the microvessel density that decreased sharply after administration of lenvatinib. Data are presented as means  $\pm$  SD. <sup>c</sup>*P* < 0.001 vs before treatment. MVD: Micro-vessel density.

## ARTICLE HIGHLIGHTS

### Research background

Combination of hepatic arterial infusion chemotherapy (HAIC) and lenvatinib has been frequently used to treat unresectable hepatocellular carcinoma (uHCC) in China.

### Research motivation

Shrinkage of hepatic arteries after the combination therapy is a common phenomenon and may early reflect the antitumor response, the relationship between which needs further exploration.

### Research objectives

To investigate the relationship between hepatic artery diameters reduction and the short-term efficacy of HAIC plus lenvatinib.

### Research methods

Sixty-seven patients with uHCC receiving HAIC plus lenvatinib were analyzed retrospectively. The modified Response Evaluation Criteria in Solid Tumors was used to assess the antitumor response after 1, 3, and 6 mo of treatment. The measurement of hepatic artery diameters before treatment and after 1 and 2 mo of treatment were conducted in a computed tomography image post-processing workstation. Meanwhile, the changes in tumor capillaries were also examined on pathological specimens before and after 1 mo of treatment.

### Research results

All the hepatic artery diameters and the microvessel density in the tumor lesions were significantly decreased after the combination treatment (all  $P < 0.001$ ). Shrinkage of the tumor-feeding artery (TFA) was significantly associated with the antitumor response after 1, 3, and 6 mo of treatment ( $P < 0.001$ ,  $P = 0.004$ , and  $P = 0.023$ , respectively) and an independent factor for treatment efficacy ( $P = 0.001$ ,  $P = 0.001$ , and  $P = 0.002$  and 1, 3, and 6 mo, respectively).

### Research conclusions

The retrospective study demonstrated that the shrinkage of the TFA diameter was closely related to improved short-term efficacy of treatment with HAIC plus lenvatinib for the first time.

### Research perspectives

We believe the findings in this paper will be of interest to the researchers in uHCC. Further, prospective randomized multicenter trials are needed to confirm the relationship between the morphological change in TFA and the early therapeutic effect of uHCC treatment.

---

## ACKNOWLEDGEMENTS

---

All authors are grateful to Dr. Fan XY for assisting with the reconstruction of the CT images.

---

## FOOTNOTES

---

**Author contributions:** Wu DD and Pang HJ designed this study; Wu DD, Tian C, and Chen CL performed the reconstruction and measurement; Wu DD, Liu XH, and Pang HJ analyzed the data; Peng P collected the clinical data; Wu DD wrote the paper; He XF and Pang HJ made critical revisions to the paper; all authors approved the publication of the paper.

**Institutional review board statement:** The research was conducted in accordance with the 1975 Declaration of Helsinki and approved by the medical ethics committee of Nanfang Hospital, Southern Medical University.

**Informed consent statement:** The requirement for informed consent was waived owing to the retrospective nature of the study.

**Conflict-of-interest statement:** There was no conflict of interest to disclose.

**Data sharing statement:** No additional data are available.

**Open-Access:** This article is an open-access article that was selected by an in-house editor and fully peer-reviewed by external reviewers. It is distributed in accordance with the Creative Commons Attribution NonCommercial (CC BY-NC 4.0) license, which permits others to distribute, remix, adapt, build upon this work non-commercially, and license their derivative works on different terms, provided the original work is properly cited and the use is non-commercial. See: <https://creativecommons.org/licenses/by-nc/4.0/>

**Country/Territory of origin:** China

**ORCID number:** De-Di Wu 0000-0001-8409-9770; Xiao-Feng He 0000-0001-8255-1874; Chen Tian 0000-0003-4260-290X; Peng Peng 0000-0001-9864-0580; Chuan-Li Chen 0000-0001-7610-5966; Xue-Han Liu 0000-0002-8966-7172; Hua-Jin Pang 0000-0001-7367-5701.

**S-Editor:** Yan JP

**L-Editor:** A



P-Editor: Yan JP

## REFERENCES

- 1 Torre LA, Bray F, Siegel RL, Ferlay J, Lortet-Tieulent J, Jemal A. Global cancer statistics, 2012. *CA Cancer J Clin* 2015; **65**: 87-108 [PMID: 25651787 DOI: 10.3322/caac.21262]
- 2 Llovet JM, Zucman-Rossi J, Pikarsky E, Sangro B, Schwartz M, Sherman M, Gores G. Hepatocellular carcinoma. *Nat Rev Dis Primers* 2016; **2**: 16018 [PMID: 27158749 DOI: 10.1038/nrdp.2016.18]
- 3 European Association for the Study of the Liver. Corrigendum to "EASL Clinical Practice Guidelines: Management of hepatocellular carcinoma" [J Hepatol 69 (2018) 182-236]. *J Hepatol* 2019; **70**: 817 [PMID: 30739718 DOI: 10.1016/j.jhep.2019.01.020]
- 4 Kudo M, Trevisani F, Abou-Alfa GK, Rimassa L. Hepatocellular Carcinoma: Therapeutic Guidelines and Medical Treatment. *Liver Cancer* 2016; **6**: 16-26 [PMID: 27995084 DOI: 10.1159/000449343]
- 5 Ikeda M, Morizane C, Ueno M, Okusaka T, Ishii H, Furuse J. Chemotherapy for hepatocellular carcinoma: current status and future perspectives. *Jpn J Clin Oncol* 2018; **48**: 103-114 [PMID: 29253194 DOI: 10.1093/jcco/hyx180]
- 6 Kudo M, Matsui O, Izumi N, Iijima H, Kadoya M, Imai Y, Okusaka T, Miyayama S, Tsuchiya K, Ueshima K, Hiraoka A, Ikeda M, Ogasawara S, Yamashita T, Minami T, Yamakado K; Liver Cancer Study Group of Japan. JSH Consensus-Based Clinical Practice Guidelines for the Management of Hepatocellular Carcinoma: 2014 Update by the Liver Cancer Study Group of Japan. *Liver Cancer* 2014; **3**: 458-468 [PMID: 26280007 DOI: 10.1159/000343875]
- 7 He MK, Liang RB, Zhao Y, Xu YJ, Chen HW, Zhou YM, Lai ZC, Xu L, Wei W, Zhang YJ, Chen MS, Guo RP, Li QJ, Shi M. Lenvatinib, toripalimab, plus hepatic arterial infusion chemotherapy versus lenvatinib alone for advanced hepatocellular carcinoma. *Ther Adv Med Oncol* 2021; **13**: 17588359211002720 [PMID: 33854567 DOI: 10.1177/17588359211002720]
- 8 Obi S, Sato S, Kawai T. Current Status of Hepatic Arterial Infusion Chemotherapy. *Liver Cancer* 2015; **4**: 188-199 [PMID: 26674592 DOI: 10.1159/000367746]
- 9 Matsuda N, Imai N, Kuzuya T, Yamamoto K, Ito T, Ishizu Y, Honda T, Ishigami M, Fujishiro M. Progression After Molecular Targeted Agents: Hepatic Arterial Changes and Transarterial Chemoembolization in Hepatocellular Carcinoma. *In Vivo* 2021; **35**: 1185-1189 [PMID: 33622919 DOI: 10.21873/in vivo.12367]
- 10 Jiang H, Liu X, Chen J, Wei Y, Lee JM, Cao L, Wu Y, Duan T, Li X, Ma L, Song B. Man or machine? *Cancer Imaging* 2019; **19**: 84 [PMID: 31806050 DOI: 10.1186/s40644-019-0266-9]
- 11 Okusaka T, Ikeda K, Kudo M, Finn R, Qin S, Han KH, Cheng AL, Piscaglia F, Kobayashi M, Sung M, Chen M, Wyrwicz L, Yoon JH, Ren Z, Mody K, Dutcus C, Tamai T, Ren M, Hayato S, Kumada H. Safety and efficacy of lenvatinib by starting dose based on body weight in patients with unresectable hepatocellular carcinoma in REFLECT. *J Gastroenterol* 2021; **56**: 570-580 [PMID: 33948712 DOI: 10.1007/s00535-021-01785-0]
- 12 Freites-Martinez A, Santana N, Arias-Santiago S, Viera A. Using the Common Terminology Criteria for Adverse Events (CTCAE - Version 5.0) to Evaluate the Severity of Adverse Events of Anticancer Therapies. *Actas Dermosifiliogr (Engl Ed)* 2021; **112**: 90-92 [PMID: 32891586 DOI: 10.1016/j.ad.2019.05.009]
- 13 Pang H, Chen Y, He X, Tan X, Wang J, Yao Q, Liu X. Twelve-Month Computed Tomography Follow-Up after Thoracic Endovascular Repair for Acute Complicated Aortic Dissection. *Ann Vasc Surg* 2021; **71**: 444-450 [PMID: 32891743 DOI: 10.1016/j.avsg.2020.08.125]
- 14 Matsuki M, Adachi Y, Ozawa Y, Kimura T, Hoshi T, Okamoto K, Tohyama O, Mitsuhashi K, Yamaguchi A, Matsui J, Funahashi Y. Targeting of tumor growth and angiogenesis underlies the enhanced antitumor activity of lenvatinib in combination with everolimus. *Cancer Sci* 2017; **108**: 763-771 [PMID: 28107584 DOI: 10.1111/cas.13169]
- 15 Matsuki M, Hoshi T, Yamamoto Y, Ikemori-Kawada M, Minoshima Y, Funahashi Y, Matsui J. Lenvatinib inhibits angiogenesis and tumor fibroblast growth factor signaling pathways in human hepatocellular carcinoma models. *Cancer Med* 2018; **7**: 2641-2653 [PMID: 29733511 DOI: 10.1002/cam4.1517]
- 16 Mohamed A, Chenna A, Abdelatah M, Sanjay J, Mohammad MK, Saber I, Kauh J, Elhammali B, Kaseb A. Microvessel density analysis in patients with viral hepatitis-related hepatocellular carcinoma. *J Gastrointest Cancer* 2015; **46**: 104-108 [PMID: 25645584 DOI: 10.1007/s12029-015-9684-5]
- 17 Chen L, Zheng Y, Zhang H, Pan H, Liu Q, Zhou X, Wei W, Liu Y, Zhen M, Wang J, Zhou J, Zhao Y. Comparative analysis of tumor-associated vascular changes following TACE alone or in combination with sorafenib treatment in HCC: A retrospective study. *Oncol Lett* 2018; **16**: 3690-3698 [PMID: 30127979 DOI: 10.3892/ol.2018.9055]
- 18 Yamamoto Y, Matsui J, Matsushima T, Obaishi H, Miyazaki K, Nakamura K, Tohyama O, Semba T, Yamaguchi A, Hoshi SS, Mimura F, Haneda T, Fukuda Y, Kamata JI, Takahashi K, Matsukura M, Wakabayashi T, Asada M, Nomoto KI, Watanabe T, Dezso Z, Yoshimatsu K, Funahashi Y, Tsuruoka A. Lenvatinib, an angiogenesis inhibitor targeting VEGFR/FGFR, shows broad antitumor activity in human tumor xenograft models associated with microvessel density and pericyte coverage. *Vasc Cell* 2014; **6**: 18 [PMID: 25197551 DOI: 10.1186/2045-824X-6-18]
- 19 Perera S, Kelly D, O'Kane GM. Non-immunotherapy options for the first-line management of hepatocellular carcinoma: exploring the evolving role of sorafenib and lenvatinib in advanced disease. *Curr Oncol* 2020; **27**: S165-S172 [PMID: 33343210 DOI: 10.3747/co.27.7159]
- 20 Liu K, Zhang X, Xu W, Chen J, Yu J, Gamble JR, McCaughan GW. Targeting the vasculature in hepatocellular carcinoma treatment: Starving vs normalizing blood supply. *Clin Transl Gastroenterol* 2017; **8**: e98 [PMID: 28617447 DOI: 10.1038/ctg.2017.28]
- 21 Shimose S, Iwamoto H, Tanaka M, Niizeki T, Shirono T, Noda Y, Kamachi N, Okamura S, Nakano M, Suga H, Yamaguchi T, Kawaguchi T, Kuromatsu R, Noguchi K, Koga H, Torimura T. Alternating Lenvatinib and Trans-Arterial Therapy Prolongs Overall Survival in Patients with Inter-Mediate Stage HepatoCellular Carcinoma: A Propensity Score Matching Study. *Cancers (Basel)* 2021; **13** [PMID: 33466496 DOI: 10.3390/cancers13010160]

- 22 **Mai QC**, Mo ZQ, Shi F, Chen XM. Lenvatinib plus hepatic arterial infusion of modified FOLFOX regime in patients with advanced hepatocellular carcinoma. *J Clin Oncol* 2020; **38** [DOI: [10.1200/jco.2020.38.15\\_suppl.e16603](https://doi.org/10.1200/jco.2020.38.15_suppl.e16603)]
- 23 **Kuorda H**, Abe T, Fujiwara Y, Okamoto T, Yonezawa M, Sato H, Endo K, Oikawa T, Sawara K, Takikawa Y. Change in arterial tumor perfusion is an early biomarker of lenvatinib efficacy in patients with unresectable hepatocellular carcinoma. *World J Gastroenterol* 2019; **25**: 2365-2372 [PMID: [31148907](https://pubmed.ncbi.nlm.nih.gov/31148907/) DOI: [10.3748/wjg.v25.i19.2365](https://doi.org/10.3748/wjg.v25.i19.2365)]
- 24 **Kondo Y**, Fukuda R. [Cutting Edge of Hepatic Artery Infusion Chemotherapy for Hepatocellular Carcinoma]. *Gan To Kagaku Ryoho* 2020; **47**: 1-5 [PMID: [32381852](https://pubmed.ncbi.nlm.nih.gov/32381852/)]
- 25 **Chen HS**, Gross JF. Intra-arterial infusion of anticancer drugs: theoretic aspects of drug delivery and review of responses. *Cancer Treat Rep* 1980; **64**: 31-40 [PMID: [6155210](https://pubmed.ncbi.nlm.nih.gov/6155210/) DOI: [10.1016/0304-3835\(80\)90154-8](https://doi.org/10.1016/0304-3835(80)90154-8)]
- 26 **Jain RK**. Normalizing tumor vasculature with anti-angiogenic therapy: a new paradigm for combination therapy. *Nat Med* 2001; **7**: 987-989 [PMID: [11533692](https://pubmed.ncbi.nlm.nih.gov/11533692/) DOI: [10.1038/nm0901-987](https://doi.org/10.1038/nm0901-987)]
- 27 **Willett CG**, Boucher Y, di Tomaso E, Duda DG, Munn LL, Tong RT, Chung DC, Sahani DV, Kalva SP, Kozin SV, Mino M, Cohen KS, Scadden DT, Hartford AC, Fischman AJ, Clark JW, Ryan DP, Zhu AX, Blaszkowsky LS, Chen HX, Shellito PC, Lauwers GY, Jain RK. Direct evidence that the VEGF-specific antibody bevacizumab has antivascular effects in human rectal cancer. *Nat Med* 2004; **10**: 145-147 [PMID: [14745444](https://pubmed.ncbi.nlm.nih.gov/14745444/) DOI: [10.1038/nm988](https://doi.org/10.1038/nm988)]



Published by **Baishideng Publishing Group Inc**  
7041 Koll Center Parkway, Suite 160, Pleasanton, CA 94566, USA

**Telephone:** +1-925-3991568

**E-mail:** [bpgoffice@wjgnet.com](mailto:bpgoffice@wjgnet.com)

**Help Desk:** <https://www.f6publishing.com/helpdesk>

<https://www.wjgnet.com>

