

World Journal of *Gastroenterology*

World J Gastroenterol 2022 September 14; 28(34): 4929-5092



REVIEW

- 4929** Therapeutic strategies for post-transplant recurrence of hepatocellular carcinoma
Sposito C, Citterio D, Viridis M, Battiston C, Droz Dit Busset M, Flores M, Mazzaferro V

MINIREVIEWS

- 4943** Diagnosis, treatment, and current concepts in the endoscopic management of gastroenteropancreatic neuroendocrine neoplasms
Iabichino G, Di Leo M, Arena M, Rubis Passoni GG, Morandi E, Turpini F, Viaggi P, Luigiano C, De Luca L
- 4959** Efficacy of cytapheresis in patients with ulcerative colitis showing insufficient or lost response to biologic therapy
Iizuka M, Etou T, Sagara S

ORIGINAL ARTICLE

Basic Study

- 4973** Long noncoding RNA ZNF1-AS1 promotes the invasion and proliferation of gastric cancer cells by regulating LIN28 and CAPRIN1
Zhuo ZL, Xian HP, Sun YJ, Long Y, Liu C, Liang B, Zhao XT
- 4993** Oxidized low-density lipoprotein stimulates CD206 positive macrophages upregulating CD44 and CD133 expression in colorectal cancer with high-fat diet
Zheng SM, Chen H, Sha WH, Chen XF, Yin JB, Zhu XB, Zheng ZW, Ma J
- 5007** Ji-Chuan decoction ameliorates slow transit constipation *via* regulation of intestinal glial cell apoptosis
Wang XM, Lv LX, Qin YS, Zhang YZ, Yang N, Wu S, Xia XW, Yang H, Xu H, Liu Y, Ding WJ

Retrospective Cohort Study

- 5023** Pregnancy and fetal outcomes of chronic hepatitis C mothers with viremia in China
Pan CQ, Zhu BS, Xu JP, Li JX, Sun LJ, Tian HX, Zhang XH, Li SW, Dai EH

Retrospective Study

- 5036** Trends in hospitalization for alcoholic hepatitis from 2011 to 2017: A USA nationwide study
Wakil A, Mohamed M, Tafesh Z, Niazi M, Olivo R, Xia W, Greenberg P, Pyrsopoulos N
- 5047** Analysis of invasiveness and tumor-associated macrophages infiltration in solid pseudopapillary tumors of pancreas
Yang J, Tan CL, Long D, Liang Y, Zhou L, Liu XB, Chen YH

Observational Study

- 5058** Impact of adalimumab on disease burden in moderate-to-severe ulcerative colitis patients: The one-year, real-world UCanADA study

Bessissow T, Nguyen GC, Tarabain O, Peyrin-Biroulet L, Foucault N, McHugh K, Ruel J

CASE REPORT

- 5076** Gastrointestinal tumors in transplantation: Two case reports and review of literature

Stammler R, Anglicheau D, Landi B, Meatchi T, Ragot E, Thervet E, Lazareth H

- 5086** Spontaneous expulsion of a duodenal lipoma after endoscopic biopsy: A case report

Chen ZH, Lv LH, Pan WS, Zhu YM

ABOUT COVER

Editorial Board Member of *World Journal of Gastroenterology*, Abhinav Vasudevan, BMed, MPH, FRACP, PhD, Staff Physician and Medical Lead in Inflammatory Bowel Diseases, Department of Gastroenterology and Hepatology, Eastern Health, Box Hill 3128, Australia

AIMS AND SCOPE

The primary aim of *World Journal of Gastroenterology* (WJG, *World J Gastroenterol*) is to provide scholars and readers from various fields of gastroenterology and hepatology with a platform to publish high-quality basic and clinical research articles and communicate their research findings online. WJG mainly publishes articles reporting research results and findings obtained in the field of gastroenterology and hepatology and covering a wide range of topics including gastroenterology, hepatology, gastrointestinal endoscopy, gastrointestinal surgery, gastrointestinal oncology, and pediatric gastroenterology.

INDEXING/ABSTRACTING

The WJG is now abstracted and indexed in Science Citation Index Expanded (SCIE, also known as SciSearch®), Current Contents/Clinical Medicine, Journal Citation Reports, Index Medicus, MEDLINE, PubMed, PubMed Central, Scopus, Reference Citation Analysis, China National Knowledge Infrastructure, China Science and Technology Journal Database, and Superstar Journals Database. The 2022 edition of Journal Citation Reports® cites the 2021 impact factor (IF) for WJG as 5.374; IF without journal self cites: 5.187; 5-year IF: 5.715; Journal Citation Indicator: 0.84; Ranking: 31 among 93 journals in gastroenterology and hepatology; and Quartile category: Q2. The WJG's CiteScore for 2021 is 8.1 and Scopus CiteScore rank 2021: Gastroenterology is 18/149.

RESPONSIBLE EDITORS FOR THIS ISSUE

Production Editor: Hua-Ge Yu; Production Department Director: Xu Guo; Editorial Office Director: Jia-Ru Fan.

NAME OF JOURNAL

World Journal of Gastroenterology

ISSN

ISSN 1007-9327 (print) ISSN 2219-2840 (online)

LAUNCH DATE

October 1, 1995

FREQUENCY

Weekly

EDITORS-IN-CHIEF

Andrzej S Tarnawski

EDITORIAL BOARD MEMBERS

<http://www.wjgnet.com/1007-9327/editorialboard.htm>

PUBLICATION DATE

September 14, 2022

COPYRIGHT

© 2022 Baishideng Publishing Group Inc

INSTRUCTIONS TO AUTHORS

<https://www.wjgnet.com/bpg/gerinfo/204>

GUIDELINES FOR ETHICS DOCUMENTS

<https://www.wjgnet.com/bpg/GerInfo/287>

GUIDELINES FOR NON-NATIVE SPEAKERS OF ENGLISH

<https://www.wjgnet.com/bpg/gerinfo/240>

PUBLICATION ETHICS

<https://www.wjgnet.com/bpg/GerInfo/288>

PUBLICATION MISCONDUCT

<https://www.wjgnet.com/bpg/gerinfo/208>

ARTICLE PROCESSING CHARGE

<https://www.wjgnet.com/bpg/gerinfo/242>

STEPS FOR SUBMITTING MANUSCRIPTS

<https://www.wjgnet.com/bpg/GerInfo/239>

ONLINE SUBMISSION

<https://www.f6publishing.com>



Therapeutic strategies for post-transplant recurrence of hepatocellular carcinoma

Carlo Sposito, Davide Citterio, Matteo Virdis, Carlo Battiston, Michele Droz Dit Busset, Maria Flores, Vincenzo Mazzaferro

Specialty type: Gastroenterology and hepatology

Provenance and peer review:

Invited article; Externally peer reviewed.

Peer-review model: Single blind

Peer-review report's scientific quality classification

Grade A (Excellent): A, A

Grade B (Very good): 0

Grade C (Good): 0

Grade D (Fair): 0

Grade E (Poor): 0

P-Reviewer: Chang A, Thailand; Kim IH, South Korea

Received: January 27, 2022

Peer-review started: January 27, 2022

First decision: February 24, 2022

Revised: March 5, 2022

Accepted: July 26, 2022

Article in press: July 26, 2022

Published online: September 14, 2022



Carlo Sposito, Davide Citterio, Matteo Virdis, Carlo Battiston, Michele Droz Dit Busset, Maria Flores, Vincenzo Mazzaferro, HPB Surgery, Hepatology and Liver Transplantation, Fondazione IRCCS Istituto Nazionale Tumori di Milano, Milan 20133, Italy

Carlo Sposito, Vincenzo Mazzaferro, Department of Oncology and Hemato-Oncology, University of Milan, Milan 20100, Italy

Corresponding author: Carlo Sposito, MD, Associate Professor, Surgeon, HPB Surgery, Hepatology and Liver Transplantation, Fondazione IRCCS Istituto Nazionale Tumori di Milano, Via Venezian 1, Milan 20133, Italy. carlo.sposito@istitutotumori.mi.it

Abstract

Despite stringent selection criteria, hepatocellular carcinoma recurrence after liver transplantation (LT) still occurs in up to 20% of cases, mostly within the first 2–3 years. No adjuvant treatments to prevent such an occurrence have been developed so far. However, a balanced use of immunosuppression with minimal dose of calcineurin inhibitors and possible addition of mammalian target of rapamycin inhibitors is strongly advisable. Moreover, several pre- and post-transplant predictors of recurrence have been identified and may help determine the frequency and duration of post-transplant follow-up. When recurrence occurs, the outcomes are poor with a median survival of 12 mo according to most retrospective studies. The factor that most impacts survival after recurrence is timing (within 1–2 years from LT according to different authors). Several therapeutic options may be chosen in case of recurrence, according to timing and disease presentation. Surgical treatment seems to provide a survival benefit, especially in case of late recurrence, while the benefit of locoregional treatments has been suggested only in small retrospective studies. When systemic treatment is indicated, sorafenib has been proved safe and effective, while only few data are available for lenvatinib and regorafenib in second line. The use of immune checkpoint inhibitors is controversial in this setting, given the safety warnings for the risk of acute rejection.

Key Words: Liver transplantation; Hepatocellular carcinoma; Immunosuppression; Recurrence; Surgical treatment; Locoregional treatment; Systemic treatment

©The Author(s) 2022. Published by Baishideng Publishing Group Inc. All rights reserved.

Core tip: Hepatocellular carcinoma (HCC) is becoming the most common indication for liver transplantation (LT). The problem of tumor recurrence after LT, that occurs in up to 20% of cases, is becoming of increasing interest. We reviewed of the available literature on HCC recurrence after LT. The best preventive measures still rely on pretransplant selection criteria, since no dedicated follow-up guidelines exist and no post-LT adjuvant treatments are available. When recurrence occurs, the prognosis is poor. However, aggressive surgical treatment, particularly in the case of late recurrence, may provide a significant survival benefit.

Citation: Sposito C, Citterio D, Viridis M, Battiston C, Droz Dit Busset M, Flores M, Mazzaferro V. Therapeutic strategies for post-transplant recurrence of hepatocellular carcinoma. *World J Gastroenterol* 2022; 28(34): 4929-4942

URL: <https://www.wjgnet.com/1007-9327/full/v28/i34/4929.htm>

DOI: <https://dx.doi.org/10.3748/wjg.v28.i34.4929>

INTRODUCTION

Hepatocellular carcinoma (HCC) is the most common liver cancer and the fourth leading cause of cancer-related mortality[1,2]. From the time of its initial developments in the early 1960s, liver transplantation (LT) appeared as the ideal cure for HCC on liver cirrhosis because of the perspective to cure at the same time both the tumor and the underlying liver disease. However, the first experiences were disappointing with many authors reporting 5-year survival < 40%, mainly because of recurrences of the primary tumor[3-6]. A retrospective review of these discouraging results progressively led to the observation that survival of patients was directly related to the stage of HCC at the time of LT. This was the basis on which a prospective study was conducted in Milan applying *a priori* restrictive criteria for the selection of HCC candidates for LT (namely a single nodule ≤ 5 cm or two or three nodules ≤ 3 cm, each with no macrovascular invasion at pretransplant imaging). The seminal paper published in 1996 demonstrated that LT under such criteria achieved better long-term results than any other therapy, with outcomes similar to LT for nononcological indications[7]. The so called Milan criteria (MC) were subsequently validated by many other groups reporting 5-year survival rates of ≥ 70%, and became the benchmark for selecting patients with HCC for LT. Pooled recurrence rates have been reported to be around 8% for patients within MC *versus* 28% for patients beyond these criteria, according to a recent meta-analysis[8]. Thus, HCC recurs in a proportion of recipients who are within MC, while LT may provide cure for some patients who are beyond these criteria. When recurrence occurs, survival is poor and post-LT HCC recurrence is the factor that most affects long-term outcomes in this setting. Considering that HCC represents the most common indication for LT in the USA, and that since the introduction of direct antiviral agents against hepatitis C virus the proportion of patients undergoing LT for HCC is increasing worldwide[9,10], the problem of tumor recurrence will probably affect a growing number of patients. However, to date, treatment of HCC recurrence following LT is largely understudied and dedicated guidelines are lacking. The aim of this paper is to provide a review of the current evidence on therapeutic strategies for patients with HCC recurrence after LT.

PREVENTION OF POST-LT HCC RECURRENCE

Tumor recurrence may be linked to remaining (previously undetected) extrahepatic HCC at the time of LT, or result from the post-LT engraftment of circulating HCC clones[11]. It is extrahepatic in 50%-60% of cases, with lung, bones and adrenal glands being the most frequently affected sites[12]. Timing of HCC recurrence is variable, but in most cases it occurs within 3 years after LT. Early recurrence (< 1 year after LT) is associated with a significantly worse prognosis, while later recurrence might result in better outcomes and even in cure in selected cases[13].

Prevention of recurrence through selection criteria

Considering that the risk of post-LT recurrence is strictly related to pretransplant HCC stage and treatment, recurrence is firstly prevented by the application of pre-LT selection criteria able to identify patients at higher risk. Proposals for expansion of MC have been initially developed using tumor morphology, namely size and number of nodules. In fact, these factors have been demonstrated as surrogate markers of microvascular invasion (MVI) and/or poor tumor differentiation, which are the principal determinants of biological aggressiveness and therefore of the risk of post-LT recurrence[14]. Expanded criteria increased the acceptable size and number of HCC nodules with respect to MC, but the considerable heterogeneity coupled with differences in accuracy of liver imaging techniques

probably represent the greatest limitation of criteria based only on morphology.

To overcome these limits, criteria incorporating serum markers as surrogates of biological tumor features such as α -fetoprotein (AFP) have been proposed. In particular, by combining the morphological characteristics of the tumor and AFP values it was possible to develop selection criteria for LT definitively exceeding MC, while even decreasing the risk of post-LT recurrence[15,16]. A strategy combining tumor burden with the assessment of response to pre-LT locoregional treatment (LRT) as a marker of favorable tumor biology has gained broader acceptance[17]. For patients beyond MC, a common strategy is to downstage patients by means of LRT or surgical therapy. In fact, patients successfully downstaged within accepted criteria share the same prognosis as patients within the criteria *ab initio* and so far[18], response to therapies appears as one of the best surrogates of favorable tumor biology and thus an optimal selection tool for candidates for LT[17,19,20]. Patients progressing in the pre-LT period despite LRT have significantly worse post-LT outcomes with respect to patients with stable or responding disease. Finally, tumor differentiation, MVI, presence of circulating cancer cells and genomic markers have also been suggested as selection criteria for LT, but these assessments require biopsy, which might induce tumor seeding. Furthermore, it is well known that tumors are heterogeneous and show areas of varying degrees of differentiation and genomic features.

Post-LT surveillance

Considering that post-LT recurrence is mostly asymptomatic, and that early detection of recurrence may have a positive impact on long-term outcomes, post-LT surveillance has an important role in this setting. However, no guidelines from the major Hepato-bilio-pancreatic societies are available and surveillance protocols are mostly center-specific, often with a high heterogeneity between centers as recently reported[21]. Few retrospective studies on post-LT surveillance have been published to date, and several questions regarding frequency, duration, and imaging modality for a cost-effective surveillance remain open.

For imaging modality, cross-sectional imaging of the abdomen [with either multiphase computed tomography (CT) or magnetic resonance imaging] and noncontrast lung CT scan allow detection of the most frequent sites of recurrent HCC[21,22]. Cross-sectional imaging of the brain, bone scintigraphy or positron emission tomography-CT are indicated only in case of clinical suspicion and not on a regular basis, while it seems reasonable to check for AFP levels at each surveillance visit even if no data is available to support this indication.

Given that the majority of recurrences occur within the first 3 years after LT, there is general agreement to indicate surveillance imaging and visits more frequently in this time frame (*i.e.*, every 4–6 mo) and yearly thereafter[22]. Some authors suggest interrupting surveillance after 5 years. However, recurrences (either *de novo* tumors or true recurrences) have been repeatedly reported up to 10–15 years after LT[23]; considering that late HCC relapse is associated with a better prognosis with respect to earlier events and that it is sometimes curable, it seems reasonable to prolong yearly surveillance for at least ten years.

Ideally, frequency and duration of surveillance would be based on the assessed risk of post-LT HCC recurrence. Several proposals have been made in this sense, and the RETREAT score[24] (that includes AFP at LT, presence of MVI and sum of maximum size + number of vital nodules) is the most recent and promising predictor in terms of discriminative power and validation on a large scale registry. However, no prospective validation is available to date, and the cost-effectiveness of a surveillance program based on the risk of recurrence has yet to be demonstrated.

The impact of surveillance programs on post-recurrence survival has been scarcely studied. A recent multicenter study on 232 patients who experienced HCC recurrence found that increasing number of post-LT surveillance scans (with cut-off at three surveillance scans within the first 2 years) was associated with improved survival and possibility of undergoing potentially curative treatments[25].

Role of immunosuppression

Improvements in the management of immunosuppression reduced rejection episodes favoring long-term graft survival; calcineurin inhibitors (CNIs) tacrolimus and cyclosporine played a fundamental role in this improvement. However, several studies demonstrated that CNI exposure is associated with an increased risk of tumor recurrence with a dose-dependent effect[26]. It is likely that the immunosuppression induced by CNIs prevents the immune system from detecting and destroying circulating or dormant HCC cells and therefore, dosage of CNIs should be maintained with the aim of balancing this risk without increasing the risk of rejection episodes.

Mammalian target of rapamycin inhibitors (mTORis) sirolimus and everolimus are another class of immunosuppressants targeting some HCC pathways, which showed antiangiogenic and antiproliferative effects in experimental models[27]. Data from retrospective studies and meta-analyses suggest that, compared to CNIs, the use of mTORis reduces the risk of post-LT HCC recurrence and increases long-term survival. In the most recent meta-analysis including 23 comparative studies [17 observational and 6 randomized controlled trials (RCTs)] with 6495 patients, recurrence-free survival (RFS) was significantly increased with mTORi-based therapy at 1 and 3 years with a nonsignificant increase at 5 years[28]. Overall survival (OS) was also significantly improved, as well as recurrence rate being lower in the mTORi arm without differences based on the type of mTORi. However, only one RCT that

compared post-LT immunosuppression containing mTORi (sirolimus) *versus* not containing mTORi [29]. In this international RCT of 525 patients there appeared to be an advantage in the sirolimus group regarding RFS in the first 3–5 years. However, this benefit was subsequently lost with further follow-up and the trial failed to meet the primary endpoint of demonstrating a significant reduction of recurrences in the mTORi-containing immunosuppression group.

Adjuvant treatments after LT

Several attempts had been performed with chemotherapy as an adjuvant treatment to prevent HCC recurrence after LT[30,31]. HCC is a chemoresistant tumor; therefore, cytotoxic systemic therapies have failed to provide any consistent benefit in this setting and have been abandoned in the last decade[32]. Sorafenib, an oral multikinase inhibitor that shows significant improvement in survival of patients with advanced HCC, has been tested in small studies in the setting of adjuvant treatment for HCC after LT. Despite some initial signs of efficacy, with one phase I study showing a significant reduction in the risk of HCC recurrence with a maximum tolerable dose of sorafenib 200 mg twice daily[33], other single-center case series failed to confirm these data and to date no RCTs are available. Lenvatinib, a more recent targeted therapy for advanced HCC, has not been prospectively tested in the adjuvant setting; a small retrospective case series confirmed an acceptable drug safety and patient tolerance but did not show any significant reduction in terms of HCC recurrence[34]. Immune checkpoints inhibitors (ICIs) have emerged as a treatment option for advanced-stage HCC. No studies are available on ICIs as post-LT adjuvant treatment. A recent systematic review and pooled analysis reviewed 14 patients receiving ICIs for recurrent disease after LT for HCC: 11 of them (78.6%) died, and graft rejection was the cause of death in five cases (45.4%). The high rejection rate raises the question of safety of ICIs in transplanted patients, even in the setting of overt recurrence[35]. Thus, to date, no anticancer treatments can be recommended to prevent HCC recurrence after LT, and it is unlikely that they will become available in the near future.

TREATMENT OF POST-LT HCC RECURRENCE

Literature concerning the efficacy of each treatment modality is scarce, with the many limitations related to the small number of patients included, the frequent use of combined treatment and the different patterns of recurrence, all acting as confounding factors. In the majority of cases (50%–60%) recurrence is extrahepatic and affects the following sites: lungs (40%–60%), bones (25%–30%), adrenal glands (10%), lymph nodes (10%) and peritoneum (10%)[12]. Liver-only recurrence occurs in 15%–40% of patients, while combined liver and extrahepatic recurrence accounts for 30%–40% of cases. The therapeutic options clearly depend on location, multifocality and clinical presentation of recurrence (Figure 1).

Surgery

Liver resection is safe and provides a survival benefit in case of intrahepatic oligorecurrence[36,37], with a median survival of 28–65 mo observed for patients receiving surgery, compared to 5–15 mo in those receiving systemic treatment only[38–41]. Surgical treatment is feasible in 25%–50% of cases with higher morbidity rate (60%–80%) with respect to primary liver resections[42–44], mainly because of the risk of infections in the context of immunosuppression.

Sapisochin *et al*[39] retrospectively analyzed 121 patients with HCC recurrence after LT, finding that not being amenable to resection or ablation was an independent predictor of poor prognosis [hazard ratio (HR) = 4.7, 95% confidence interval (CI): 2.7–8.3]. An Italian multicenter study analyzed 21 patients with recurrence and reported a significantly better 4-year survival rate in patients treated with surgical resection for intra- and extrahepatic recurrence compared to those with unresectable disease (57% *vs* 14%, $P = 0.02$)[45]. In another series of 106 patients, treatment for recurrent HCC most commonly included chemotherapy (73.5%), surgical resection (23.3%), external beam radiation (13.6%), and ablation (3.9%), with the majority of patients receiving nonsurgical therapies (59.2%). The highest survival rates at 3 years were observed in patients receiving surgical therapy alone (60%), followed by patients receiving both surgical and nonsurgical therapy (37%), patients receiving only nonsurgical therapy (11%), and patients receiving no treatment (0%)[40]. Time from LT to recurrence is one of the most important prognostic factors, and patients with late recurrence show more favorable 5-year outcomes survival with resection compared to those of patients who recur earlier[46].

Surgery may enhance long-term survival also in patients with pulmonary recurrences amenable to resection, with 5-year survival rates ranging from 34% to 44% in those undergoing metastasectomy[47–52]. A benefit from surgical treatment is also reported for other sites of recurrence in smaller case series, including vertebrae[53], adrenal glands[54,55], lymph nodes[56], peritoneum[57] and pharynx[58]. In patients with multiple recurrences, some benefits have also been gained from repeated resections, probably reflecting less aggressive tumor biology[41].

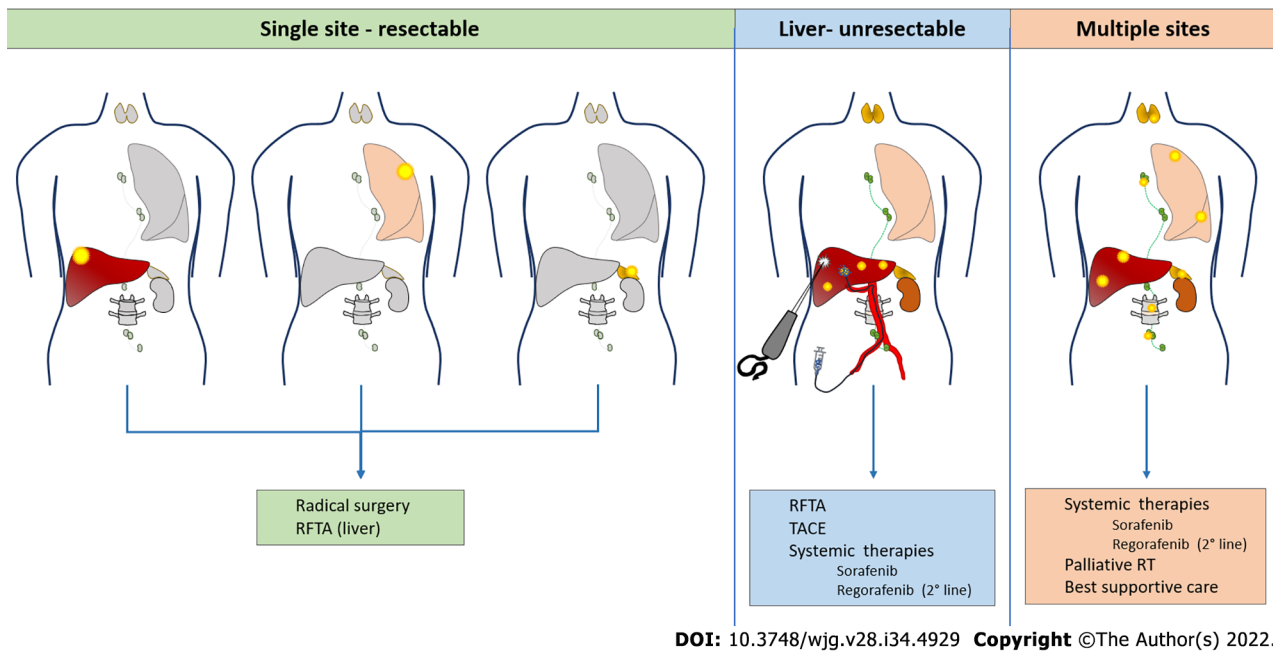


Figure 1 Hepatocellular carcinoma recurrence after liver transplantation: Treatment possibilities according to disease presentation. RT: Radiotherapy; RFTA: Radiofrequency thermal ablation; TACE: Transarterial chemoembolization.

Locoregional therapies

Radiofrequency ablation (RFA) for liver recurrences may be proposed with a curative intent for small lesions, with the advantages of a percutaneous approach. In a retrospective single-center series, Huang *et al*[44] compared 15 patients with post-LT HCC recurrence treated surgically with 11 patients treated with RFA. This study demonstrated similar 5-year OS (35% for surgery *vs* 28% for RFA) but a tendency to a worse 5-year disease-free survival in the RFA group (16% *vs* 0%). Another study evaluating safety and efficacy of microwave ablation on a series of 11 patients found this technique safe and tolerable, with a 15.8% rate of local tumor progression after treatment and 15.3% survival at 2 years[59].

Multifocal intrahepatic recurrences may be amenable to transarterial chemoembolization (TACE). The largest series collected 28 patients treated by conventional TACE[60]. There were no significant post-treatment complications and the targeted tumor reduced in size by $\geq 25\%$ in 19 patients (67.9%). However, intrahepatic recurrence or extrahepatic metastases occurred in 26 patients (92.9%) within 6 mo. The 3- and 5-year survival rates following TACE were 6% and 0%, respectively, with a mean survival time of 9 mo. A single-center retrospective investigation compared 14 patients treated with TACE with 14 matched controls who did not receive TACE but chemotherapy, radiotherapy or supportive care. Eight of the 14 patients treated with TACE (57%) showed partial tumor response and had a significantly longer survival compared to those who did not[61].

Systemic therapies

The effectiveness of systemic therapies for HCC recurrence following LT is largely unstudied because these patients have been routinely excluded from clinical trials. Sorafenib has been increasingly administered for treatment of post LT recurrences, and some data have been collected in the literature regarding its safety and efficacy in this setting. In a case-control study from Sposito *et al*[62], sorafenib provided improved median survival after HCC recurrence untreatable by surgery or LRT with respect to best supportive care (10.6 *vs* 2.2 mo). A meta-analysis published 2 years later reported a pooled 1-year survival of 36% (range 18%–90%)[63]. The main limitation of sorafenib in transplanted patients is toxicity, often leading to dose reduction, as reported by several studies[62,64]. Close monitoring is warranted for these patients, particularly in case of immunosuppression with mTORis, since this association may lead to severe adverse events[65–70]. Regorafenib may be proposed as a second-line treatment in case of progression under sorafenib[71]. In a recent multicenter study, second line treatment with regorafenib after sorafenib discontinuation provided a median survival of 13.1 mo compared with 5.5 mo with best supportive care in post-LT HCC relapse[72]. Recently approved tyrosine kinase inhibitors (lenvatinib[73] and cabozantinib[74]) and monoclonal antibodies (ramucirumab[75]) will soon be introduced in clinical practice also for the treatment of post-LT recurrence, giving us the opportunity to collect data about their efficacy and toxicity in this setting[76]. Currently, immunotherapy is changing the landscape of systemic therapies for HCC[77–79], but its safety after LT represents a point of concern, since ICIs may cause allograft rejection and other serious adverse events[80–85].

FACTORS IMPACTING SURVIVAL AFTER HCC RECURRENCE

Studies evaluating the outcome of patients with post-LT HCC recurrence mostly consist of small and heterogeneous series burdened by significant biases in terms of transplant criteria, availability of different treatments and patients' selection to curative and palliative options[86]. Survival of post-LT HCC recurrence is dismal and significantly worse than relapse after resection (median OS around 12 mo *vs* nearly 2 years in transplanted and resected patients, respectively), and immunosuppression is a potential driver of such a difference[87,88]. A number of factors have an impact on survival, and there is a small subset of patients with more favorable prognosis in whom curative treatments may be undertaken. Table 1 summarizes the results of studies evaluating the prognostic factors and outcome of treatment for HCC relapse after LT.

Time to recurrence and primary tumor features

Several studies showed that time from LT to recurrence has a primary role on outcomes, with early relapse being associated with poor prognosis either when defined as occurring within 6 mo[89-93], 1 year[39,94,95] or 2 years[96]. Many factors related to the primary tumor biology and aggressiveness affect time to recurrence and/or post-relapse survival: size (with cutoffs > 30 or > 50 mm)[45,97], staging outside MC[45], bilobar spread[97], absence of peritumoral capsule[45], poorly differentiated tumors[91,94,95], total tumor volume[92], presence of micro- or macrovascular invasion and pre-LT lymphocyte to neutrophil ratio[39,40,91,92]. The use of mTORi in the post-LT setting seems to be related to better post-recurrence outcomes, as shown both in eastern and western series[93,95]. Moreover, a history of graft rejection has also been associated with improved outcomes, possibly due to more active anticancer immunity[92].

It has been suggested that the observed difference in outcomes between early and late recurrences lies in different underlying biological mechanisms. However, this does not turn into a difference in the site of recurrence. In fact, occurrence of extrahepatic, combined intra- and extrahepatic or intrahepatic relapses do not seem to be different in early *versus* late recurrences[97]. While early relapses may be due to undetected extrahepatic metastases or circulating HCC clones implanting in a target organ during or soon after LT, late recurrences are possibly related to a second hit leading to late engrafting of HCC cells remaining latent during the initial post-LT period. In the latter, immunosuppression may also play a role[23]. As for intrahepatic late relapses, a further mechanism to be considered is *de novo* occurrence of HCC, usually arising in the context of chronic liver disease or cirrhosis due to recurrence of primary hepatitis, ischemic biliary injury or chronic rejection, several years after LT[98]. In such instances, results are expected to parallel those of nontransplant recipients with localized HCC, in which surgery or LRTs are effective in controlling the disease.

Pattern, features and resectability of recurrence

Aside from primary disease features, other studies have focused on the pattern of recurrence as a relevant prognostic factor for post-recurrence survival. As expected, limited disease spread with localized nodules (oligorecurrence), either hepatic or extrahepatic, has been associated to better outcomes than disseminated multifocal recurrence in several series[36-38,41,45,90]. In addition, a different prognostic impact of hepatic *versus* extrahepatic localization has been repeatedly reported. Hong *et al* showed that liver involvement as the first recurrence site was associated with worse survival, with fewer patients amenable to resection among intrahepatic rather than extrahepatic localizations[93]. A monocentric French series on 70 HCC recurrences also identified intrahepatic location as an unfavorable prognostic factor, which was confirmed in a Latin American series on 105 post-LT recurrences showing a lower probability of treatment in patients with hepatic relapses[41,94]. It may be speculated that this is related to the biological mechanism underlying tumor relapse, with recurrences due to undetected metastases at the time of LT more likely to occur at extrahepatic sites and associated with decreased burden as compared to circulating HCC clones, biologically more aggressive tumors, and being more likely to implant in the new liver. Of note, peritoneal and bone localizations were also reported as a poor prognostic factors[37,91,95]. Nevertheless, evidence deriving from several studies shows that the best outcomes are observed in patients with unifocal, often extrahepatic disease, easily amenable to surgical resection[36-38,41,45]. In the large series by Sapisochin *et al*[39] cited above, not being amenable to curative-intent treatment (resection or ablation) was an independent indicator of poor survival, together with AFP ≥ 100 ng/mL at the time of relapse. In another single-center study from the USA by Bodzin *et al*[40] on 106 recurrences, a prominent prognostic role of recurrence-related factors (AFP at relapse, > 3 nodules, maximum size of recurrence and bone spread) rather than primary disease features was shown. By combining such factors, a risk score model was built, with accurate stratification of recurrent patients into low-risk (median survival of 70.6 mo), medium-risk (12.2 mo) and high-risk (3.4 mo) subgroups.

Due to selection bias of surgical patients towards later recurrences, more favorable localizations, less aggressive disease and better performance status, the independent prognostic role of either recurrence pattern or resectability is questionable. The limited disease spread may make patients more likely to undergo surgical excision on the one hand, or simply reflect a different tumor biology, etiology, and

Table 1 Studies evaluating the prognostic factors and outcome of treatment for hepatocellular carcinoma relapse after liver transplantation

Ref.	No. of patients	Type of study	Site of recurrence	Treatment	mTTR	mOS	Negative outcome predictors
Sapisochin <i>et al</i> [39], 2015	121 (15.5%)	Retrospective multicenter	18.4% liver, 47.4% extrahepatic, 34.2% liver + extra	31.4% surgery/ablation, 42.1% palliative, 26.4% BSC	14 mo	12.2 mo (1 yr 54%; 3 yr 19%; 5 yr 14%)	No curative treatment. RFS < 1 yr. AFP > 100 ng/mL
Ho <i>et al</i> [96], 2020	349 (16.4%)	National registry	≥ 38.1% liver, ≥ 20.3% extrahepatic/(liver + extra)	4.6% surgery, 6.3% ablation, 32.1% RT, 27.2% TACE, 20.3% Sorafenib, 20.3% BSC	17.8 mo	11.2 mo (1 yr 57%; 3 yr 24.7%; 4 yr 19%)	LT era > 2008 (due to listing of downstaged patients). No curative treatment. Sorafenib/RT
Hong <i>et al</i> [93], 2019	92 (17.3%) (LDLT)	Retrospective multicenter	37% liver, 34.8% lung, 28.3% bone, 16.3% lymph nodes	38% surgery, 51.1% TACE, 38% RT, 45.7% Sorafenib	11.3 mo	11.7 mo (1 yr 59.5%; 3 yr 23%; 5 yr 11.9%)	TTR < 6 mo. No curative treatment. Multiorgan involvement. Explant tumor size > 5 cm. mTORi (late)
Toso <i>et al</i> [92], 2013	30 (12.8%)	Retrospective multicenter	46.6% liver, 43.3% lung, 23.3% bone, 13.3% other	20% surgery, 10% TACE/RF/PEI, 70% CT/BSC	14.2 mo	33 mo	Graft rejection 0-6 mo. TTR
Bodzin <i>et al</i> [40], 2017	106 (12.4%)	Retrospective multicenter	37.8% liver, 55.7% lung, 25.5% bone, 3.8% brain	23.3% surgery, 3.9% RFA, 13.6% RT, 73.5% CT, 17% BSC	15.8 mo	10.6 mo	MELD at LT > 23. TTR. > 3 recurrent nodules. Size of recurrence. Bone recurrence. AFP at recurrence. Donor Na. Pre-LT NLR
Fernandez-Sevilla <i>et al</i> [41], 2017	70 (14.2%)	Retrospective single center	2.8% liver, 72.9% extrahepatic, 24.3% liver + extra	31.4% surgery, 8.6% TACE, 28.6% Sorafenib	17 mo	19 mo (1 yr 65%; 3 yr 26%; 5 yr 5%)	AFP > 100 ng/mL. Intrahepatic. Multifocal. No surgical treatment
Maccali <i>et al</i> [94], 2021	105 (16.6%)	Retrospective multicenter	23.8% liver, 21% liver + extra, 55.2% extrahepatic	9.5% surgery, 2.9% TACE, 4.8% RT, 44.8% CT/Sorafenib	13 mo	6.2 mo	RFS < 1 yr. No surgical, loco-regional or systemic treatment
Ekpanyapong <i>et al</i> [95], 2020	96 (13.5%)	Retrospective single center	21.9% liver, 78.1% extrahepatic/(liver + extra)	27.1% surgery. 5.2% RFA. 1% TACE. 10.4% RT. 39.6% Sorafenib. 16.7% BSC	17.1 mo	10.1 mo (1 yr 48%; 3 yr 16%)	AFP > 1000 ng/mL. Poorly differentiated HCC. Bilirubin ≥ 1.2 mg/dL and albumin < 3.5 mg/dL at recurrence. Peritoneal disease
Regalia <i>et al</i> [45], 1998	21 (15.9%)	Retrospective multicenter	19% liver, 19% lung, 14% bone, 38% multiple sites	33.3% surgery, 19% CT, 14.3% RT/CT-RT, 23.8% BSC	7.8 mo	1 yr 62%; 3 yr 29%; 4 yr 23%	Related to early recurrence: Explant tumor size > 3 cm; outside Milan Criteria; absence of capsule
Kornberg <i>et al</i> [38], 2010	16 (26.7%)	Retrospective single center	25% liver, 25% bone, 31.2% lung, 6.2% brain, 6.2% peritoneum, 6.2% adrenal gland	43.7% surgery, 18.7% RT, 6.2% TACE, 6.2% Sorafenib, 31.2% BSC	23 mo	10.5 mo	No surgical treatment. Early recurrence (< 24 mo)
Alshahrani <i>et al</i> [57], 2018	232 (15.6%)	Retrospective single center	31% liver, 57.8% extrahepatic, 13.4% multiple sites	-	-	1 yr 60.2%; 3 yr 28.3%; 5 yr 20.5%; 10 yr 7%	Early recurrence
Taketomi <i>et al</i> [100], 2010	17 (16.8%) (LDLT)	Retrospective single center	-	53% surgery, 47% other	12.9 mo	1 yr 76.5%; 3 yr 51.3%; 5 yr 34.2%	No surgical treatment. Early recurrence
Roh <i>et al</i> [90], 2014	63 (13.8%)	Retrospective single center	22% liver, 16% lung, 52% multiple sites, 10% other	6% surgery, 38% local treatment, 16% systemic treatment, 33% combined treatment, 13% BSC	12.9 mo	12.2 mo	Bone involvement. Early recurrence (< 6 mo). Multi-organ
Valdivieso <i>et al</i> [36], 2010	23 (12.6%)	Retrospective single center	8.7% liver, 21.7% liver + extra, 69.5% extrahepatic	47.8% surgery, 17.4% systemic treatment, 34.8% BSC	23.4 mo	R0 33.2 mo, other 11.9 mo	R0 surgical treatment
Mehta <i>et al</i> [101], 2020	84 (11.6%)	Retrospective multicenter	26.2% liver, 48.8% extrahepatic, 25% multiple sites	-	13 mo	-	-
Sharma <i>et al</i>	17 (18%)	Retrospective	35.3% liver, 64.7%	-	25.2	-	-

[102], 2012		single center	multiple sites		mo		
Shin <i>et al</i> [91], 2010	28 (20.3%) (LDLT)	Retrospective single center	50% liver, 25% extrahepatic, 25% multiple sites	Liver: TACE. Extrahepatic: Systemic therapy/RT	7.9 mo	11.7 mo (1 yr 52.8%; 3 yr 15.8%)	Major vascular invasion. Poorly differentiated HCC. No surgical treatment. Bone metastases
Schlitt <i>et al</i> [103], 1999	39 (56.5%)	Retrospective single center	23.1% liver, 38.5 liver + extra, 38.5% extrahepatic	38.4% surgery, 41% BSC, 12.8% systemic treatment, 2.5% TACE, 5.1% RT	14.5 mo	8 mo (non-surgical treatment)	-
Escartin <i>et al</i> [104], 2007	28 (15.2%)	Retrospective single center	14.3% liver, 46.4% extrahepatic, 39.3% multiple sites	-	-	7 mo	-
Cescon <i>et al</i> [105], 2010	34 (12%)	Retrospective single center	8.8% liver, 20.6% extrahepatic, 70.6% multiple sites	100% systemic treatment (in combination with: 5.9% surgery, 3% RT, 3% RFA, 3% IA CT)	12 mo	-	-
Roayaie <i>et al</i> [37], 2004	57 (18.3%)	Retrospective single center	15.8 % liver, 52.6% extrahepatic, 31.6% multiple sites	31.6% surgery, 5.2% TACE, 26.3% systemic treatment, 7% RT, 29.8% BSC	12.2 mo	8.7 mo	Bone metastases. No surgical treatment. Early recurrence

RFS: Relapse free survival; OS: Overall survival; RT: Radiotherapy; BSC: Best supportive care; IA CT: Intra-arterial chemotherapy. RFA: Radiofrequency ablation; LT: Liver transplant; mTTR: Median time to recurrence; mOS: Median overall survival; TACE: Transarterial chemoembolization; HCC: Hepatocellular carcinoma; PEI: Percutaneous ethanol injection; LDLT: Living donor liver transplantation.

stage of recurrence on the other hand, as compared to more advanced cases of multifocal recurrence. Even when radical resection cannot be undertaken, it is widely accepted that any kind of treatment of recurrence has a positive prognostic impact. In the multicenter Latin American study, propensity score matching was used to evaluate the adjusted treatment effect considering selection bias. Patients treated with both sorafenib and surgery/TACE had better survival compared to the best supportive care regardless of time to recurrence[95]. Although randomized data are unlikely to be available in this context and retrospective comparisons are impaired by intrinsic differences between single site/oligometastatic and disseminated recurrence, surgical treatment remains an independent predictor of improved outcome following post-LT recurrence[37-39,41].

Serum markers

As for primary disease and post-LT outcome, AFP at recurrence as an indicator of disease spread, MVI and biological aggressiveness was frequently reported as a strong predictor of prognosis, with cutoffs varying from 100 to 1000 ng/mL[39-41,95]. The difference in survival for patients with high AFP was evident regardless of curative-intent treatment, confirming its value as a marker of unfavorable biological features, and its ability to guide the clinical management of patients affected by HCC recurrence. Finally, other biochemical markers at recurrence were associated with shorter survival: High bilirubin, possibly as a reflection of graft dysfunction, and low albumin, related to poor nutritional status as a general prognostic factor outlined in several series[96,99].

CONCLUSION

HCC recurrence after LT is still a dreadful event, occurring in up to 20% of cases. It might be prevented by stringent pretransplant selection criteria incorporating biological markers of aggressiveness (such as response to therapy, serum markers, histological factors) in addition to size and number of tumors. Several advances in this sense have been made in the last decade, allowing patients with HCC broader access to LT with more precise prediction of outcomes. In the post-LT period, surveillance should be driven by post-LT risk stratification, and the RETREAT score seems to be the best cost-effective approach. No adjuvant treatments after LT have been validated to prevent HCC recurrence; however, a balanced use of immunosuppression with minimal dose of CNIs and possibly the addition of mTORi is strongly advisable. Median post-recurrence survival is 12 mo: the interplay between time to recurrence (with a negative impact of earlier events) and the possibility of a radical treatment is the strongest determinant of survival.

FOOTNOTES

Author contributions: Sposito C wrote and revised the paper; Citterio D, Virdis M, Battiston C, Droz Dit Busset M and Flores M wrote the paper and the tables; Virdis M drew the figures; Flores M and Battiston C did literature research; Mazzaferro V have reviewed the paper for important intellectual content.

Conflict-of-interest statement: All the authors report no relevant conflicts of interest for this article.

Open-Access: This article is an open-access article that was selected by an in-house editor and fully peer-reviewed by external reviewers. It is distributed in accordance with the Creative Commons Attribution NonCommercial (CC BY-NC 4.0) license, which permits others to distribute, remix, adapt, build upon this work non-commercially, and license their derivative works on different terms, provided the original work is properly cited and the use is non-commercial. See: <https://creativecommons.org/licenses/by-nc/4.0/>

Country/Territory of origin: Italy

ORCID number: Carlo Sposito 0000-0002-2276-2669; Davide Citterio 0000-0002-0708-8733; Matteo Virdis 0000-0002-1944-2357; Carlo Battiston 0000-0001-6826-7893; Michele Droz Dit Busset 0000-0002-5967-6828; Maria Flores 0000-0001-7195-6251; Vincenzo Mazzaferro 0000-0002-4013-8085.

S-Editor: Wang JJ

L-Editor: Kerr C

P-Editor: Wang JJ

REFERENCES

- Villanueva A. Hepatocellular Carcinoma. *N Engl J Med* 2019; **380**: 1450-1462 [PMID: 30970190 DOI: 10.1056/NEJMra1713263]
- Bray F, Ferlay J, Soerjomataram I, Siegel RL, Torre LA, Jemal A. Global cancer statistics 2018: GLOBOCAN estimates of incidence and mortality worldwide for 36 cancers in 185 countries. *CA Cancer J Clin* 2018; **68**: 394-424 [PMID: 30207593 DOI: 10.3322/caac.21492]
- Iwatsuki S, Starzl TE, Sheahan DG, Yokoyama I, Demetris AJ, Todo S, Tzakis AG, Van Thiel DH, Carr B, Selby R, Madariaga J. Hepatic resection vs transplantation for hepatocellular carcinoma. *Ann Surg* 1991; **214**: 221-229 [DOI: 10.1097/0000658-199109000-00005]
- Yokoyama I, Carr B, Saito H, Iwatsuki S, Starzl TE. Accelerated growth rates of recurrent hepatocellular carcinoma after liver transplantation. *Cancer* 1991; **68**: 2095-2100 [PMID: 1655200 DOI: 10.1002/1097-0142(19911115)68:10<2095::aid-cnrcr2820681002>3.0.co;2-y]
- Bismuth H, Chiche L, Adam R, Castaing D, Diamond T, Dennison A. Liver resection versus transplantation for hepatocellular carcinoma in cirrhotic patients. *Ann Surg* 1993; **218**: 145-151 [PMID: 8393649 DOI: 10.1097/0000658-199308000-00005]
- Ringe B, Pichlmayr R, Wittekind C, Tusch G. Surgical treatment of hepatocellular carcinoma: experience with liver resection and transplantation in 198 patients. *World J Surg* 1991; **15**: 270-285 [PMID: 1851588 DOI: 10.1007/BF01659064]
- Mazzaferro V, Regalia E, Doci R, Andreola S, Pulvirenti A, Bozzetti F, Montalto F, Ammatuna M, Morabito A, Gennari L. Liver transplantation for the treatment of small hepatocellular carcinomas in patients with cirrhosis. *N Engl J Med* 1996; **334**: 693-699 [PMID: 8594428 DOI: 10.1056/NEJM199603143341104]
- Tan DJH, Wong C, Ng CH, Poh CW, Jain SR, Huang DQ, Muthiah MD. A Meta-Analysis on the Rate of Hepatocellular Carcinoma Recurrence after Liver Transplant and Associations to Etiology, Alpha-Fetoprotein, Income and Ethnicity. *J Clin Med* 2021; **10** [PMID: 33440759 DOI: 10.3390/jcm10020238]
- Yang JD, Larson JJ, Watt KD, Allen AM, Wiesner RH, Gores GJ, Roberts LR, Heimbach JA, Leise MD. Hepatocellular Carcinoma Is the Most Common Indication for Liver Transplantation and Placement on the Waitlist in the United States. *Clin Gastroenterol Hepatol* 2017; **15**: 767-775.e3 [PMID: 28013117 DOI: 10.1016/j.cgh.2016.11.034]
- Kwong AJ, Kim WR, Flemming JA. De Novo Hepatocellular Carcinoma Among Liver Transplant Registrants in the Direct Acting Antiviral Era. *Hepatology* 2018; **68**: 1288-1297 [PMID: 29672886 DOI: 10.1002/hep.30045]
- Toso C, Mentha G, Majno P. Liver transplantation for hepatocellular carcinoma: five steps to prevent recurrence. *Am J Transplant* 2011; **11**: 2031-2035 [PMID: 21831154 DOI: 10.1111/j.1600-6143.2011.03689.x]
- Sapisochin G, Bruix J. Liver transplantation for hepatocellular carcinoma: outcomes and novel surgical approaches. *Nat Rev Gastroenterol Hepatol* 2017; **14**: 203-217 [PMID: 28053342 DOI: 10.1038/nrgastro.2016.193]
- Goldaracena N, Mehta N, Scalera I, Sposito C, Atenafu EG, Yao FY, Muiesan P, Mazzaferro V, Sapisochin G. Multicenter validation of a score to predict prognosis after the development of HCC recurrence following liver transplantation. *HPB (Oxford)* 2019; **21**: 731-738 [PMID: 30391218 DOI: 10.1016/j.hpb.2018.10.005]
- Mazzaferro V, Llovet JM, Miceli R, Bhoori S, Schiavo M, Mariani L, Camerini T, Roayaie S, Schwartz ME, Grazi GL, Adam R, Neuhaus P, Salizzoni M, Bruix J, Forner A, De Carlis L, Cillo U, Burroughs AK, Troisi R, Rossi M, Gerunda GE, Lerut J, Belghiti J, Boin I, Gugenheim J, Rochling F, Van Hoek B, Majno P; Metroticket Investigator Study Group. Predicting survival after liver transplantation in patients with hepatocellular carcinoma beyond the Milan criteria: a retrospective, exploratory analysis. *Lancet Oncol* 2009; **10**: 35-43 [PMID: 19058754 DOI: 10.1016/S1470-2045(08)70284-5]

- 15 **Duvoux C**, Roudot-Thoraval F, Decaens T, Pessione F, Badran H, Piardi T, Francoz C, Compagnon P, Vanlemmens C, Dumortier J, Dharancy S, Gugenheim J, Bernard PH, Adam R, Radenne S, Muscari F, Conti F, Hardwigsen J, Pageaux GP, Chazouillères O, Salame E, Hilleret MN, Lebray P, Abergel A, Debette-Gratien M, Kluger MD, Mallat A, Azoulay D, Cherqui D; Liver Transplantation French Study Group. Liver transplantation for hepatocellular carcinoma: a model including α -fetoprotein improves the performance of Milan criteria. *Gastroenterology* 2012; **143**: 986-94.e3; quiz e14 [PMID: 22750200 DOI: 10.1053/j.gastro.2012.05.052]
- 16 **Mazzaferro V**, Sposito C, Zhou J, Pinna AD, De Carlis L, Fan J, Cescon M, Di Sandro S, Yi-Feng H, Lauterio A, Bongini M, Cucchetti A. Metroticket 2.0 Model for Analysis of Competing Risks of Death After Liver Transplantation for Hepatocellular Carcinoma. *Gastroenterology* 2018; **154**: 128-139 [PMID: 28989060 DOI: 10.1053/j.gastro.2017.09.025]
- 17 **Lai Q**, Avolio AW, Graziadei I, Otto G, Rossi M, Tisone G, Goffette P, Vogel W, Pitton MB, Lerut J; European Hepatocellular Cancer Liver Transplant Study Group. Alpha-fetoprotein and modified response evaluation criteria in solid tumors progression after locoregional therapy as predictors of hepatocellular cancer recurrence and death after transplantation. *Liver Transpl* 2013; **19**: 1108-1118 [PMID: 23873764 DOI: 10.1002/lt.23706]
- 18 **Yao FY**, Mehta N, Flemming J, Dodge J, Hameed B, Fix O, Hirose R, Fidelman N, Kerlan RK Jr, Roberts JP. Downstaging of hepatocellular cancer before liver transplant: long-term outcome compared to tumors within Milan criteria. *Hepatology* 2015; **61**: 1968-1977 [PMID: 25689978 DOI: 10.1002/hep.27752]
- 19 **Otto G**, Herber S, Heise M, Lohse AW, Mönch C, Bittinger F, Hoppe-Lotichius M, Schuchmann M, Victor A, Pitton M. Response to transarterial chemoembolization as a biological selection criterion for liver transplantation in hepatocellular carcinoma. *Liver Transpl* 2006; **12**: 1260-1267 [PMID: 16826556 DOI: 10.1002/Lt.20837]
- 20 **Millonig G**, Graziadei IW, Freund MC, Jaschke W, Stadlmann S, Ladurner R, Margreiter R, Vogel W. Response to preoperative chemoembolization correlates with outcome after liver transplantation in patients with hepatocellular carcinoma. *Liver Transpl* 2007; **13**: 272-279 [PMID: 17256758 DOI: 10.1002/Lt.21033]
- 21 **Aggarwal A**, Te HS, Verna EC, Desai AP. A National Survey of Hepatocellular Carcinoma Surveillance Practices Following Liver Transplantation. *Transplant Direct* 2021; **7**: e638 [PMID: 33324743 DOI: 10.1097/TXD.0000000000001086]
- 22 **Berenguer M**, Burra P, Ghobrial M, Hibi T, Metselaar H, Sapisochin G, Bhoori S, Kwan Man N, Mas V, Ohira M, Sangro B, van der Laan LJW. Posttransplant Management of Recipients Undergoing Liver Transplantation for Hepatocellular Carcinoma. Working Group Report From the ILTS Transplant Oncology Consensus Conference. *Transplantation* 2020; **104**: 1143-1149 [PMID: 32217940 DOI: 10.1097/TP.0000000000003196]
- 23 **Verna EC**, Patel YA, Aggarwal A, Desai AP, Frenette C, Pillai AA, Salgia R, Seetharam A, Sharma P, Sherman C, Tsoulfas G, Yao FY. Liver transplantation for hepatocellular carcinoma: Management after the transplant. *Am J Transplant* 2020; **20**: 333-347 [PMID: 31710773 DOI: 10.1111/ajt.15697]
- 24 **Mehta N**, Heimbach J, Harnois DM, Sapisochin G, Dodge JL, Lee D, Burns JM, Sanchez W, Greig PD, Grant DR, Roberts JP, Yao FY. Validation of a Risk Estimation of Tumor Recurrence After Transplant (RETREAT) Score for Hepatocellular Carcinoma Recurrence After Liver Transplant. *JAMA Oncol* 2017; **3**: 493-500 [PMID: 27838698 DOI: 10.1001/jamaoncol.2016.5116]
- 25 **Lee DD**, Sapisochin G, Mehta N, Gorgen A, Musto KR, Hajda H, Yao FY, Hodge DO, Carter RE, Harnois DM. Surveillance for HCC After Liver Transplantation: Increased Monitoring May Yield Aggressive Treatment Options and Improved Postrecurrence Survival. *Transplantation* 2020; **104**: 2105-2112 [PMID: 31972705 DOI: 10.1097/TP.0000000000003117]
- 26 **Rodríguez-Perálvarez M**, Tsochatzis E, Naveas MC, Pieri G, García-Caparrós C, O'Beirne J, Poyato-González A, Ferrín-Sánchez G, Montero-Álvarez JL, Patch D, Thorburn D, Briceño J, De la Mata M, Burroughs AK. Reduced exposure to calcineurin inhibitors early after liver transplantation prevents recurrence of hepatocellular carcinoma. *J Hepatol* 2013; **59**: 1193-1199 [PMID: 23867318 DOI: 10.1016/j.jhep.2013.07.012]
- 27 **Semela D**, Piguet AC, Kolev M, Schmitter K, Hlushchuk R, Djonov V, Stoupis C, Dufour JF. Vascular remodeling and antitumoral effects of mTOR inhibition in a rat model of hepatocellular carcinoma. *J Hepatol* 2007; **46**: 840-848 [PMID: 17321636 DOI: 10.1016/j.jhep.2006.11.021]
- 28 **Grigg SE**, Sarri GL, Gow PJ, Yeomans ND. Systematic review with meta-analysis: sirolimus- or everolimus-based immunosuppression following liver transplantation for hepatocellular carcinoma. *Aliment Pharmacol Ther* 2019; **49**: 1260-1273 [PMID: 30989721 DOI: 10.1111/apt.15253]
- 29 **Geissler EK**, Schnitzbauer AA, Zülke C, Lamby PE, Proneth A, Duvoux C, Burra P, Jauch KW, Rentsch M, Ganten TM, Schmidt J, Settmacher U, Heise M, Rossi G, Cillo U, Kneteman N, Adam R, van Hoek B, Bachellier P, Wolf P, Rostaing L, Bechstein WO, Rizell M, Powell J, Hidalgo E, Gugenheim J, Wolters H, Brockmann J, Roy A, Mutzbauer I, Schlitt A, Beckebaum S, Graeb C, Nadalin S, Valente U, Turrión VS, Jamieson N, Scholz T, Colledan M, Fändrich F, Becker T, Sönderdahl G, Chazouillères O, Mäkitalo H, Pageaux GP, Steininger R, Soliman T, de Jong KP, Pirenne J, Margreiter R, Pratschke J, Pinna AD, Hauss J, Schreiber S, Strasser S, Klempnauer J, Troisi RI, Bhoori S, Lerut J, Bilbao I, Klein CG, Königsrainer A, Mirza DF, Otto G, Mazzaferro V, Neuhaus P, Schlitt HJ. Sirolimus Use in Liver Transplant Recipients With Hepatocellular Carcinoma: A Randomized, Multicenter, Open-Label Phase 3 Trial. *Transplantation* 2016; **100**: 116-125 [PMID: 26555945 DOI: 10.1097/TP.0000000000000965]
- 30 **Olthoff KM**, Rosove MH, Shackleton CR, Imagawa DK, Farmer DG, Northcross P, Pakrasi AL, Martin P, Goldstein LI, Shaked A. Adjuvant chemotherapy improves survival after liver transplantation for hepatocellular carcinoma. *Ann Surg* 1995; **221**: 734-41; discussion 731 [PMID: 7794077 DOI: 10.1097/0000658-199506000-00012]
- 31 **Hsieh CB**, Chou SJ, Shih ML, Chu HC, Chu CH, Yu JC, Yao NS. Preliminary experience with gemcitabine and cisplatin adjuvant chemotherapy after liver transplantation for hepatocellular carcinoma. *Eur J Surg Oncol* 2008; **34**: 906-910 [PMID: 18166289 DOI: 10.1016/j.ejso.2007.11.014]
- 32 **Fujiki M**, Aucejo F, Kim R. Adjuvant treatment of hepatocellular carcinoma after orthotopic liver transplantation: do we really need this? *Clin Transplant* 2013; **27**: 169-177 [PMID: 23216662 DOI: 10.1111/ctr.12042]
- 33 **Siegel AB**, El-Khoueiry AB, Finn RS, Guthrie KA, Goyal A, Venook AP, Blanke CD, Verna EC, Dove L, Emond J, Kato T, Samstein B, Busuttil R, Remotti H, Coffey A, Brown RS Jr. Phase I trial of sorafenib following liver transplantation in

- patients with high-risk hepatocellular carcinoma. *Liver Cancer* 2015; **4**: 115-125 [PMID: [26020033](#) DOI: [10.1159/000367734](#)]
- 34 **Han B**, Ding H, Zhao S, Zhang Y, Wang J, Gu J. Potential Role of Adjuvant Lenvatinib in Improving Disease-Free Survival for Patients With High-Risk Hepatitis B Virus-Related Hepatocellular Carcinoma Following Liver Transplantation: A Retrospective, Case Control Study. *Front Oncol* 2020; **10**: 562103 [PMID: [33365268](#) DOI: [10.3389/fonc.2020.562103](#)]
 - 35 **Ziogas IA**, Evangelidou AP, Giannis D, Hayat MH, Mylonas KS, Tohme S, Geller DA, Elias N, Goyal L, Tsoulfas G. The Role of Immunotherapy in Hepatocellular Carcinoma: A Systematic Review and Pooled Analysis of 2,402 Patients. *Oncologist* 2021; **26**: e1036-e1049 [PMID: [33314549](#) DOI: [10.1002/onco.13638](#)]
 - 36 **Valdivieso A**, Bustamante J, Gastaca M, Uriarte JG, Ventoso A, Ruiz P, Fernandez JR, Pijoan I, Testillano M, Suarez MJ, Montejo M, Ortiz de Urbina J. Management of hepatocellular carcinoma recurrence after liver transplantation. *Transplant Proc* 2010; **42**: 660-662 [PMID: [20304217](#) DOI: [10.1016/j.transproceed.2010.02.014](#)]
 - 37 **Roayaie S**, Schwartz JD, Sung MW, Emre SH, Miller CM, Gondolesi GE, Krieger NR, Schwartz ME. Recurrence of hepatocellular carcinoma after liver transplant: patterns and prognosis. *Liver Transpl* 2004; **10**: 534-540 [PMID: [15048797](#) DOI: [10.1002/Lt.20128](#)]
 - 38 **Kornberg A**, Küpper B, Tannapfel A, Katenkamp K, Thrum K, Habrecht O, Wilberg J. Long-term survival after recurrent hepatocellular carcinoma in liver transplant patients: clinical patterns and outcome variables. *Eur J Surg Oncol* 2010; **36**: 275-280 [PMID: [19857941](#) DOI: [10.1016/j.ejso.2009.10.001](#)]
 - 39 **Sapisochin G**, Goldaracena N, Astete S, Laurence JM, Davidson D, Rafael E, Castells L, Sandroussi C, Bilbao I, Dopazo C, Grant DR, Lázaro JL, Caralt M, Ghanekar A, McGilvray ID, Lilly L, Cattral MS, Selzner M, Charco R, Greig PD. Benefit of Treating Hepatocellular Carcinoma Recurrence after Liver Transplantation and Analysis of Prognostic Factors for Survival in a Large Euro-American Series. *Ann Surg Oncol* 2015; **22**: 2286-2294 [PMID: [25472651](#) DOI: [10.1245/s10434-014-4273-6](#)]
 - 40 **Bodzin AS**, Lunsford KE, Markovic D, Harlander-Locke MP, Busuttil RW, Agopian VG. Predicting Mortality in Patients Developing Recurrent Hepatocellular Carcinoma After Liver Transplantation: Impact of Treatment Modality and Recurrence Characteristics. *Ann Surg* 2017; **266**: 118-125 [PMID: [27433914](#) DOI: [10.1097/SLA.0000000000001894](#)]
 - 41 **Fernandez-Sevilla E**, Allard MA, Selten J, Golse N, Vibert E, Sa Cunha A, Cherqui D, Castaing D, Adam R. Recurrence of hepatocellular carcinoma after liver transplantation: Is there a place for resection? *Liver Transpl* 2017; **23**: 440-447 [PMID: [28187493](#) DOI: [10.1002/lt.24742](#)]
 - 42 **Sommacale D**, Dondero F, Sauvanet A, Francoz C, Durand F, Farges O, Kianmanesh R, Belghiti J. Liver resection in transplanted patients: a single-center Western experience. *Transplant Proc* 2013; **45**: 2726-2728 [PMID: [24034033](#) DOI: [10.1016/j.transproceed.2013.07.032](#)]
 - 43 **Chok KSh**. Management of recurrent hepatocellular carcinoma after liver transplant. *World J Hepatol* 2015; **7**: 1142-1148 [PMID: [26052403](#) DOI: [10.4254/wjh.v7.i8.1142](#)]
 - 44 **Huang J**, Yan L, Wu H, Yang J, Liao M, Zeng Y. Is radiofrequency ablation applicable for recurrent hepatocellular carcinoma after liver transplantation? *J Surg Res* 2016; **200**: 122-130 [PMID: [26277218](#) DOI: [10.1016/j.jss.2015.07.033](#)]
 - 45 **Regalia E**, Fassati LR, Valente U, Pulvirenti A, Damilano I, Dardano G, Montalto F, Coppa J, Mazzaferro V. Pattern and management of recurrent hepatocellular carcinoma after liver transplantation. *J Hepatobiliary Pancreat Surg* 1998; **5**: 29-34 [PMID: [9683751](#) DOI: [10.1007/pl00009947](#)]
 - 46 **Chok KS**, Chan SC, Cheung TT, Chan AC, Fan ST, Lo CM. Late recurrence of hepatocellular carcinoma after liver transplantation. *World J Surg* 2011; **35**: 2058-2062 [PMID: [21597889](#) DOI: [10.1007/s00268-011-1146-z](#)]
 - 47 **Tomimaru Y**, Sasaki Y, Yamada T, Eguchi H, Takami K, Ohigashi H, Higashiyama M, Ishikawa O, Kodama K, Imaoka S. The significance of surgical resection for pulmonary metastasis from hepatocellular carcinoma. *Am J Surg* 2006; **192**: 46-51 [PMID: [16769274](#) DOI: [10.1016/j.amjsurg.2005.12.006](#)]
 - 48 **Jeong YH**, Hwang S, Lee GD, Choi SH, Kim HR, Kim YH, Park SI, Kim DK. Surgical Outcome of Pulmonary Metastasectomy for Hepatocellular Carcinoma Recurrence in Liver Transplant Patients. *Ann Transplant* 2021; **26**: e930383 [PMID: [33972494](#) DOI: [10.12659/AOT.930383](#)]
 - 49 **Bates MJ**, Farkas E, Taylor D, McFadden PM. Pulmonary resection of metastatic hepatocellular carcinoma after liver transplantation. *Ann Thorac Surg* 2008; **85**: 412-415 [PMID: [18222234](#) DOI: [10.1016/j.athoracsur.2007.10.065](#)]
 - 50 **Han KN**, Kim YT, Yoon JH, Suh KS, Song JY, Kang CH, Sung SW, Kim JH. Role of surgical resection for pulmonary metastasis of hepatocellular carcinoma. *Lung Cancer* 2010; **70**: 295-300 [PMID: [20353879](#) DOI: [10.1016/j.lungcan.2010.02.014](#)]
 - 51 **Finn RS**, Qin S, Ikeda M, Galle PR, Ducreux M, Kim TY, Kudo M, Breder V, Merle P, Kaseb AO, Li D, Verret W, Xu DZ, Hernandez S, Liu J, Huang C, Mulla S, Wang Y, Lim HY, Zhu AX, Cheng AL; IMbrave150 Investigators. Atezolizumab plus Bevacizumab in Unresectable Hepatocellular Carcinoma. *N Engl J Med* 2020; **382**: 1894-1905 [PMID: [32402160](#) DOI: [10.1056/NEJMoa1915745](#)]
 - 52 **Hwang S**, Kim YH, Kim DK, Ahn CS, Moon DB, Kim KH, Ha TY, Song GW, Jung DH, Kim HR, Park GC, Namgoong JM, Yoon SY, Jung SW, Park SI, Lee SG. Resection of pulmonary metastases from hepatocellular carcinoma following liver transplantation. *World J Surg* 2012; **36**: 1592-1602 [PMID: [22411088](#) DOI: [10.1007/s00268-012-1533-0](#)]
 - 53 **Hu JG**, Lu Y, Lin XJ. En Bloc lumpectomy of T12 vertebra for progressive hepatocellular carcinoma metastases following liver transplantation: A case report. *Medicine (Baltimore)* 2020; **99**: e18756 [PMID: [31914098](#) DOI: [10.1097/MD.00000000000018756](#)]
 - 54 **Abdel Wahab M**, Shehta A, Ibrahim EM, Eldesoky RT, Sultan AA, Zalata KR, Fathy O, Elshoubary M, Salah T, Yassen AM, Elmorshedi M, Monier A, Farouk A, Shiha U. Adrenalectomy for solitary recurrent hepatocellular carcinoma five years after living donor liver transplantation: A case report. *Int J Surg Case Rep* 2019; **54**: 23-27 [PMID: [30513494](#) DOI: [10.1016/j.ijscr.2018.11.062](#)]
 - 55 **Jalbani IK**, Nazim SM, Tariq MU, Abbas F. Adrenalectomy for solitary metastasis of Hepatocellular carcinoma post liver transplantation: Case report and literature review. *Pak J Med Sci* 2016; **32**: 1044-1046 [PMID: [27648064](#) DOI: [10.12669/pjms.324.10339](#)]

- 56 Ikegami T, Yoshizumi T, Kawasaki J, Nagatsu A, Uchiyama H, Harada N, Harimoto N, Itoh S, Motomura T, Soejima Y, Maehara Y. Surgical Resection for Lymph Node Metastasis After Liver Transplantation for Hepatocellular Carcinoma. *Anticancer Res* 2017; **37**: 891-895 [PMID: 28179348 DOI: 10.21873/anticancer.11395]
- 57 Alshahrani AA, Ha SM, Hwang S, Ahn CS, Kim KH, Moon DB, Ha TY, Song GW, Jung DH, Park GC, Cho HD, Kwon JH, Kang SH, Lee SG. Clinical Features and Surveillance of Very Late Hepatocellular Carcinoma Recurrence After Liver Transplantation. *Ann Transplant* 2018; **23**: 659-665 [PMID: 30237389 DOI: 10.12659/AOT.910598]
- 58 Tohyama T, Sakamoto K, Tamura K, Nakamura T, Watanabe J, Wakisaka H, Takada Y. Pharyngeal metastasis following living-donor liver transplantation for hepatocellular carcinoma: a case report and literature review. *World J Surg Oncol* 2020; **18**: 109 [PMID: 32466780 DOI: 10.1186/s12957-020-01873-0]
- 59 Zhai H, Liang P, Yu XL, Cheng Z, Han ZY, Liu F, Yu J. Microwave ablation in treating intrahepatic recurrence of hepatocellular carcinoma after liver transplantation: An analysis of 11 cases. *Int J Hyperthermia* 2015; **31**: 863-868 [PMID: 26608701 DOI: 10.3109/02656736.2015.1091953]
- 60 Ko HK, Ko GY, Yoon HK, Sung KB. Tumor response to transcatheter arterial chemoembolization in recurrent hepatocellular carcinoma after living donor liver transplantation. *Korean J Radiol* 2007; **8**: 320-327 [PMID: 17673843 DOI: 10.3348/kjr.2007.8.4.320]
- 61 Zhou B, Shan H, Zhu KS, Jiang ZB, Guan SH, Meng XC, Zeng XC. Chemoembolization with lobaplatin mixed with iodized oil for unresectable recurrent hepatocellular carcinoma after orthotopic liver transplantation. *J Vasc Interv Radiol* 2010; **21**: 333-338 [PMID: 20116286 DOI: 10.1016/j.jvir.2009.11.006]
- 62 Sposito C, Mariani L, Germini A, Flores Reyes M, Bongini M, Grossi G, Bhoori S, Mazzaferro V. Comparative efficacy of sorafenib versus best supportive care in recurrent hepatocellular carcinoma after liver transplantation: a case-control study. *J Hepatol* 2013; **59**: 59-66 [PMID: 23500153 DOI: 10.1016/j.jhep.2013.02.026]
- 63 Mancuso A, Mazzola A, Cabibbo G, Perricone G, Enea M, Galvano A, Zavaglia C, Belli L, Cammà C. Survival of patients treated with sorafenib for hepatocellular carcinoma recurrence after liver transplantation: a systematic review and meta-analysis. *Dig Liver Dis* 2015; **47**: 324-330 [PMID: 25641331 DOI: 10.1016/j.dld.2015.01.001]
- 64 Toso C, Mentha G, Majno P. Integrating sorafenib into an algorithm for the management of post-transplant hepatocellular carcinoma recurrence. *J Hepatol* 2013; **59**: 3-5 [PMID: 23567081 DOI: 10.1016/j.jhep.2013.03.029]
- 65 Invernizzi F, Iavarone M, Zavaglia C, Mazza S, Maggi U, Cesarini L, Antonelli B, Airolidi A, Manini MA, Sangiovanni A, Rossi G, Donato MF, Saverio Belli L, Lampertico P. Experience With Early Sorafenib Treatment With mTOR Inhibitors in Hepatocellular Carcinoma Recurring After Liver Transplantation. *Transplantation* 2020; **104**: 568-574 [PMID: 31517781 DOI: 10.1097/TP.0000000000002955]
- 66 Piguet AC, Saar B, Hlushchuk R, St-Pierre MV, McSheehy PM, Radojevic V, Afthinos M, Terracciano L, Djonov V, Dufour JF. Everolimus augments the effects of sorafenib in a syngeneic orthotopic model of hepatocellular carcinoma. *Mol Cancer Ther* 2011; **10**: 1007-1017 [PMID: 21487053 DOI: 10.1158/1535-7163.MCT-10-0666]
- 67 Herden U, Fischer L, Schäfer H, Nashan B, von Baehr V, Sterneck M. Sorafenib-induced severe acute hepatitis in a stable liver transplant recipient. *Transplantation* 2010; **90**: 98-99 [PMID: 20606568 DOI: 10.1097/TP.0b013e3181daac69]
- 68 Waidmann O, Hofmann WP, Zeuzem S, Trojan J. mTOR inhibitors and sorafenib for recurrent hepatocellular carcinoma after orthotopic liver transplantation. *J Hepatol* 2011; **54**: 396-398 [PMID: 21111506 DOI: 10.1016/j.jhep.2010.08.038]
- 69 De Simone P, Crocetti L, Pezzati D, Bargellini I, Ghinolfi D, Carrai P, Leonardi G, Della Pina C, Cioni D, Pollina L, Campani D, Bartolozzi C, Lencioni R, Filippini F. Efficacy and safety of combination therapy with everolimus and sorafenib for recurrence of hepatocellular carcinoma after liver transplantation. *Transplant Proc* 2014; **46**: 241-244 [PMID: 24507059 DOI: 10.1016/j.transproceed.2013.10.035]
- 70 Bhoori S, Toffanin S, Sposito C, Germini A, Pelleggrinelli A, Lampis A, Mazzaferro V. Personalized molecular targeted therapy in advanced, recurrent hepatocellular carcinoma after liver transplantation: a proof of principle. *J Hepatol* 2010; **52**: 771-775 [PMID: 20347502 DOI: 10.1016/j.jhep.2010.01.025]
- 71 Iavarone M, Invernizzi F, Czauderna C, Sanduzzi-Zamparelli M, Bhoori S, Amadeo G, Manini MA, López MF, Anders M, Pinter M, Rodríguez MJB, Cristóbal MR, Soteras GA, Piñero F, Villadsen GE, Weinmann A, Crespo G, Mazzaferro V, Regnault H, Giorgio M, González-Diéguez ML, Donato MF, Varela M, Wörns MA, Bruix J, Lampertico P, Reig M. Preliminary experience on safety of regorafenib after sorafenib failure in recurrent hepatocellular carcinoma after liver transplantation. *Am J Transplant* 2019; **19**: 3176-3184 [PMID: 31365177 DOI: 10.1111/ajt.15551]
- 72 Iavarone M, Invernizzi F, Ivanics T, Mazza S, Zavaglia C, Sanduzzi-Zamparelli M, Fraile-López M, Czauderna C, Di Costanzo G, Bhoori S, Pinter M, Manini MA, Amadeo G, Yunquera AF, Piñero F, Blanco Rodríguez MJ, Anders M, Aballay Soteras G, Villadsen GE, Yoon PD, Cesarini L, Díaz-González Á, González-Diéguez ML, Tortora R, Weinmann A, Mazzaferro V, Romero Cristóbal M, Crespo G, Regnault H, De Giorgio M, Varela M, Prince R, Scudeller L, Donato MF, Wörns MA, Bruix J, Sapisochin G, Lampertico P, Reig M. Regorafenib Efficacy After Sorafenib in Patients With Recurrent Hepatocellular Carcinoma After Liver Transplantation: A Retrospective Study. *Liver Transpl* 2021; **27**: 1767-1778 [PMID: 34388851 DOI: 10.1002/lt.26264]
- 73 Kudo M, Finn RS, Qin S, Han KH, Ikeda K, Piscaglia F, Baron A, Park JW, Han G, Jassem J, Blanc JF, Vogel A, Komov D, Evans TRJ, Lopez C, Dutcus C, Guo M, Saito K, Kraljevic S, Tamai T, Ren M, Cheng AL. Lenvatinib versus sorafenib in first-line treatment of patients with unresectable hepatocellular carcinoma: a randomised phase 3 non-inferiority trial. *Lancet* 2018; **391**: 1163-1173 [PMID: 29433850 DOI: 10.1016/S0140-6736(18)30207-1]
- 74 Abou-Alfa GK, Meyer T, Cheng AL, El-Khoueiry AB, Rimassa L, Ryoo BY, Cicin I, Merle P, Chen Y, Park JW, Blanc JF, Bolondi L, Klumpen HJ, Chan SL, Zagonel V, Pressiani T, Ryu MH, Venook AP, Hessel C, Borgman-Hagey AE, Schwab G, Kelley RK. Cabozantinib in Patients with Advanced and Progressing Hepatocellular Carcinoma. *N Engl J Med* 2018; **379**: 54-63 [PMID: 29972759 DOI: 10.1056/NEJMoa1717002]
- 75 Zhu AX, Kang YK, Yen CJ, Finn RS, Galle PR, Llovet JM, Assenat E, Brandi G, Pracht M, Lim HY, Rau KM, Motomura K, Ohno I, Merle P, Daniele B, Shin DB, Gerken G, Borg C, Hiriart JB, Okusaka T, Morimoto M, Hsu Y, Abada PB, Kudo M; REACH-2 study investigators. Ramucirumab after sorafenib in patients with advanced hepatocellular carcinoma and increased α -fetoprotein concentrations (REACH-2): a randomised, double-blind, placebo-controlled, phase

- 3 trial. *Lancet Oncol* 2019; **20**: 282-296 [PMID: 30665869 DOI: 10.1016/S1470-2045(18)30937-9]
- 76 **Limassa L**, Personeni N, Czauderna C, Foerster F, Galle P. Systemic treatment of HCC in special populations. *J Hepatol* 2021; **74**: 931-943 [PMID: 33248171 DOI: 10.1016/j.jhep.2020.11.026]
- 77 **El-Khoueiry AB**, Sangro B, Yau T, Crocenzi TS, Kudo M, Hsu C, Kim TY, Choo SP, Trojan J, Welling TH Rd, Meyer T, Kang YK, Yeo W, Chopra A, Anderson J, Dela Cruz C, Lang L, Neely J, Tang H, Dastani HB, Melero I. Nivolumab in patients with advanced hepatocellular carcinoma (CheckMate 040): an open-label, non-comparative, phase 1/2 dose escalation and expansion trial. *Lancet* 2017; **389**: 2492-2502 [PMID: 28434648 DOI: 10.1016/S0140-6736(17)31046-2]
- 78 **Finn RS**, Ryoo BY, Merle P, Kudo M, Bouattour M, Lim HY, Breder V, Edeline J, Chao Y, Ogasawara S, Yau T, Garrido M, Chan SL, Knox J, Daniele B, Ebbinghaus SW, Chen E, Siegel AB, Zhu AX, Cheng AL; KEYNOTE-240 investigators. Pembrolizumab As Second-Line Therapy in Patients With Advanced Hepatocellular Carcinoma in KEYNOTE-240: A Randomized, Double-Blind, Phase III Trial. *J Clin Oncol* 2020; **38**: 193-202 [PMID: 31790344 DOI: 10.1200/JCO.19.01307]
- 79 **Zhu AX**, Finn RS, Edeline J, Cattani S, Ogasawara S, Palmer D, Verslype C, Zagonel V, Fartoux L, Vogel A, Sarker D, Verset G, Chan SL, Knox J, Daniele B, Webber AL, Ebbinghaus SW, Ma J, Siegel AB, Cheng AL, Kudo M; KEYNOTE-224 investigators. Pembrolizumab in patients with advanced hepatocellular carcinoma previously treated with sorafenib (KEYNOTE-224): a non-randomised, open-label phase 2 trial. *Lancet Oncol* 2018; **19**: 940-952 [PMID: 29875066 DOI: 10.1016/S1470-2045(18)30351-6]
- 80 **Kittai AS**, Oldham H, Cetnar J, Taylor M. Immune Checkpoint Inhibitors in Organ Transplant Patients. *J Immunother* 2017; **40**: 277-281 [PMID: 28719552 DOI: 10.1097/CJI.0000000000000180]
- 81 **Friend BD**, Venick RS, McDiarmid SV, Zhou X, Naini B, Wang H, Farmer DG, Busuttil RW, Federman N. Fatal orthotopic liver transplant organ rejection induced by a checkpoint inhibitor in two patients with refractory, metastatic hepatocellular carcinoma. *Pediatr Blood Cancer* 2017; **64** [PMID: 28643391 DOI: 10.1002/pbc.26682]
- 82 **Biondani P**, De Martin E, Samuel D. Safety of an anti-PD-1 immune checkpoint inhibitor in a liver transplant recipient. *Ann Oncol* 2018; **29**: 286-287 [PMID: 29293878 DOI: 10.1093/annonc/mdx548]
- 83 **DeLeon TT**, Salomao MA, Aql BA, Sonbol MB, Yokoda RT, Ali AH, Moss AA, Mathur AK, Chascsa DM, Rakela J, Bryce AH, Borad MJ. Pilot evaluation of PD-1 inhibition in metastatic cancer patients with a history of liver transplantation: the Mayo Clinic experience. *J Gastrointest Oncol* 2018; **9**: 1054-1062 [PMID: 30603124 DOI: 10.21037/jgo.2018.07.05]
- 84 **Gassmann D**, Weiler S, Mertens JC, Reiner CS, Vrugt B, Nägeli M, Mangana J, Müllhaupt B, Jenni F, Misselwitz B. Liver Allograft Failure After Nivolumab Treatment-A Case Report With Systematic Literature Research. *Transplant Direct* 2018; **4**: e376 [PMID: 30255136 DOI: 10.1097/TXD.0000000000000814]
- 85 **Lipson EJ**, Bodell MA, Kraus ES, Sharfman WH. Successful administration of ipilimumab to two kidney transplantation patients with metastatic melanoma. *J Clin Oncol* 2014; **32**: e69-e71 [PMID: 24493726 DOI: 10.1200/JCO.2013.49.2314]
- 86 **de'Angelis N**, Landi F, Carra MC, Azoulay D. Managements of recurrent hepatocellular carcinoma after liver transplantation: A systematic review. *World J Gastroenterol* 2015; **21**: 11185-11198 [PMID: 26494973 DOI: 10.3748/wjg.v21.i39.11185]
- 87 **Pelizzaro F**, Gambato M, Gringeri E, Vitale A, Cillo U, Farinati F, Burra P, Russo FP. Management of Hepatocellular Carcinoma Recurrence after Liver Transplantation. *Cancers (Basel)* 2021; **13** [PMID: 34638365 DOI: 10.3390/cancers13194882]
- 88 **Shalaby S**, Burra P. De novo and recurrent malignancy. *Best Pract Res Clin Gastroenterol* 2020; **46-47**: 101680 [PMID: 33158464 DOI: 10.1016/j.bpg.2020.101680]
- 89 **Jeyarajah DR**, Doyle MBM, Espat NJ, Hansen PD, Iannitti DA, Kim J, Thambi-Pillai T, Visser BC. Role of yttrium-90 selective internal radiation therapy in the treatment of liver-dominant metastatic colorectal cancer: an evidence-based expert consensus algorithm. *J Gastrointest Oncol* 2020; **11**: 443-460 [PMID: 32399284 DOI: 10.21037/jgo.2020.01.09]
- 90 **Roh YN**, David Kwon CH, Song S, Shin M, Man Kim J, Kim S, Joh JW, Lee SK. The prognosis and treatment outcomes of patients with recurrent hepatocellular carcinoma after liver transplantation. *Clin Transplant* 2014; **28**: 141-148 [PMID: 24372624 DOI: 10.1111/ctr.12286]
- 91 **Shin WY**, Suh KS, Lee HW, Kim J, Kim T, Yi NJ, Lee KU. Prognostic factors affecting survival after recurrence in adult living donor liver transplantation for hepatocellular carcinoma. *Liver Transpl* 2010; **16**: 678-684 [PMID: 20440777 DOI: 10.1002/lt.22047]
- 92 **Toso C**, Cader S, Mentha-Dugerdil A, Meeberg G, Majno P, Morard I, Giostra E, Berney T, Morel P, Mentha G, Kneteman NM. Factors predicting survival after post-transplant hepatocellular carcinoma recurrence. *J Hepatobiliary Pancreat Sci* 2013; **20**: 342-347 [PMID: 22710887 DOI: 10.1007/s00534-012-0528-4]
- 93 **Hong SK**, Lee KW, Yoon KC, Kim HS, Ahn SW, Kim H, Lee JM, Cho JH, Yi NJ, Suh KS. Different prognostic factors and strategies for early and late recurrence after adult living donor liver transplantation for hepatocellular carcinoma. *Clin Transplant* 2019; **33**: e13703 [PMID: 31464006 DOI: 10.1111/ctr.13703]
- 94 **Maccali C**, Chagas AL, Boin I, Quiñonez E, Marciano S, Vilatobá M, Varón A, Anders M, Hoyos Duque S, Lima AS, Menendez J, Padilla-Machaca M, Poniachik J, Zapata R, Maraschio M, Chong Menéndez R, Muñoz L, Arufe D, Figueroa R, Soza A, Fauda M, Perales SR, Vergara Sandoval R, Bermudez C, Beltran O, Arenas Hoyos I, McCormack L, Mattera FJ, Gadano A, Parente García JH, Tani CM, Augusto Carneiro D'Albuquerque L, Carrilho FJ, Silva M, Piñero F. Recurrence of hepatocellular carcinoma after liver transplantation: Prognostic and predictive factors of survival in a Latin American cohort. *Liver Int* 2021; **41**: 851-862 [PMID: 33217193 DOI: 10.1111/liv.14736]
- 95 **Ekpanyapong S**, Philips N, Loza BL, Abt P, Furth EE, Tondon R, Khungar V, Olthoff K, Shaked A, Hoteit MA, Reddy KR. Predictors, Presentation, and Treatment Outcomes of Recurrent Hepatocellular Carcinoma After Liver Transplantation: A Large Single Center Experience. *J Clin Exp Hepatol* 2020; **10**: 304-315 [PMID: 32655233 DOI: 10.1016/j.jceh.2019.11.003]
- 96 **Ho CM**, Lee CH, Lee MC, Zhang JF, Chen CH, Wang JY, Hu RH, Lee PH. Survival After Treatable Hepatocellular Carcinoma Recurrence in Liver Recipients: A Nationwide Cohort Analysis. *Front Oncol* 2020; **10**: 616094 [PMID: 33598433 DOI: 10.3389/fonc.2020.616094]

- 97 **El-Domiaty N**, Saliba F, Vibert E, Karam V, Sobesky R, Ibrahim W, Pittau G, Ciacio O, Salloum C, Amer K, Saeed MA, Shawky JA, Sa Cunha A, Rosmorduc O, Cherqui D, Adam R, Samuel D. Early Versus Late Hepatocellular Carcinoma Recurrence After Transplantation: Predictive Factors, Patterns, and Long-term Outcome. *Transplantation* 2021; **105**: 1778-1790 [PMID: [32890134](#) DOI: [10.1097/TP.0000000000003434](#)]
- 98 **Au KP**, Chok KSH. Multidisciplinary approach for post-liver transplant recurrence of hepatocellular carcinoma: A proposed management algorithm. *World J Gastroenterol* 2018; **24**: 5081-5094 [PMID: [30568386](#) DOI: [10.3748/wjg.v24.i45.5081](#)]
- 99 **Nagai S**, Mangus RS, Kubal CA, Ekser B, Fridell JA, Klingler KR, Maluccio MA, Tector AJ. Prognosis after recurrence of hepatocellular carcinoma in liver transplantation: predictors for successful treatment and survival. *Clin Transplant* 2015; **29**: 1156-1163 [PMID: [26458066](#) DOI: [10.1111/ctr.12644](#)]
- 100 **Taketomi A**, Fukuhara T, Morita K, Kayashima H, Ninomiya M, Yamashita Y, Ikegami T, Uchiyama H, Yoshizumi T, Soejima Y, Shirabe K, Maehara Y. Improved results of a surgical resection for the recurrence of hepatocellular carcinoma after living donor liver transplantation. *Ann Surg Oncol* 2010; **17**: 2283-2289 [PMID: [20204531](#) DOI: [10.1245/s10434-010-0999-y](#)]
- 101 **Mehta N**, Bhangui P, Yao FY, Mazzaferro V, Toso C, Akamatsu N, Durand F, Ijzermans J, Polak W, Zheng S, Roberts JP, Sapisochin G, Hibi T, Kwan NM, Ghobrial M, Soin A. Liver Transplantation for Hepatocellular Carcinoma. Working Group Report from the ILTS Transplant Oncology Consensus Conference. *Transplantation* 2020; **104**: 1136-1142 [PMID: [32217938](#) DOI: [10.1097/TP.0000000000003174](#)]
- 102 **Sharma P**, Welch K, Hussain H, Pelletier SJ, Fontana RJ, Marrero J, Merion RM. Incidence and risk factors of hepatocellular carcinoma recurrence after liver transplantation in the MELD era. *Dig Dis Sci* 2012; **57**: 806-812 [PMID: [21953139](#) DOI: [10.1007/s10620-011-1910-9](#)]
- 103 **Schlitt HJ**, Neipp M, Weimann A, Oldhafer KJ, Schmoll E, Boeker K, Nashan B, Kubicka S, Maschek H, Tusch G, Raab R, Ringe B, Manns MP, Pichlmayr R. Recurrence patterns of hepatocellular and fibrolamellar carcinoma after liver transplantation. *J Clin Oncol* 1999; **17**: 324-331 [PMID: [10458250](#) DOI: [10.1200/JCO.1999.17.1.324](#)]
- 104 **Escarot A**, Sapisochin G, Bilbao I, Vilallonga R, Bueno J, Castells L, Dopazo C, Castro E, Caralt M, Balsells J. Recurrence of hepatocellular carcinoma after liver transplantation. *Transplant Proc* 2007; **39**: 2308-2310 [PMID: [17889173](#) DOI: [10.1016/j.transproceed.2007.06.042](#)]
- 105 **Cescon M**, Ravaioli M, Grazi GL, Ercolani G, Cucchetti A, Bertuzzo V, Vetrone G, Del Gaudio M, Vivarelli M, D'Errico-Grigioni A, Dazzi A, Di Gioia P, Lauro A, Pinna AD. Prognostic factors for tumor recurrence after a 12-year, single-center experience of liver transplantations in patients with hepatocellular carcinoma. *J Transplant* 2010; **2010** [PMID: [20862199](#) DOI: [10.1155/2010/904152](#)]



Published by **Baishideng Publishing Group Inc**
7041 Koll Center Parkway, Suite 160, Pleasanton, CA 94566, USA

Telephone: +1-925-3991568

E-mail: bpgoffice@wjgnet.com

Help Desk: <https://www.f6publishing.com/helpdesk>

<https://www.wjgnet.com>

