

World Journal of *Gastroenterology*

World J Gastroenterol 2022 September 14; 28(34): 4929-5092



REVIEW

- 4929** Therapeutic strategies for post-transplant recurrence of hepatocellular carcinoma
Sposito C, Citterio D, Viridis M, Battiston C, Droz Dit Busset M, Flores M, Mazzaferro V

MINIREVIEWS

- 4943** Diagnosis, treatment, and current concepts in the endoscopic management of gastroenteropancreatic neuroendocrine neoplasms
Iabichino G, Di Leo M, Arena M, Rubis Passoni GG, Morandi E, Turpini F, Viaggi P, Luigiano C, De Luca L
- 4959** Efficacy of cytapheresis in patients with ulcerative colitis showing insufficient or lost response to biologic therapy
Iizuka M, Etou T, Sagara S

ORIGINAL ARTICLE

Basic Study

- 4973** Long noncoding RNA ZNF1-AS1 promotes the invasion and proliferation of gastric cancer cells by regulating LIN28 and CAPRIN1
Zhuo ZL, Xian HP, Sun YJ, Long Y, Liu C, Liang B, Zhao XT
- 4993** Oxidized low-density lipoprotein stimulates CD206 positive macrophages upregulating CD44 and CD133 expression in colorectal cancer with high-fat diet
Zheng SM, Chen H, Sha WH, Chen XF, Yin JB, Zhu XB, Zheng ZW, Ma J
- 5007** Ji-Chuan decoction ameliorates slow transit constipation *via* regulation of intestinal glial cell apoptosis
Wang XM, Lv LX, Qin YS, Zhang YZ, Yang N, Wu S, Xia XW, Yang H, Xu H, Liu Y, Ding WJ

Retrospective Cohort Study

- 5023** Pregnancy and fetal outcomes of chronic hepatitis C mothers with viremia in China
Pan CQ, Zhu BS, Xu JP, Li JX, Sun LJ, Tian HX, Zhang XH, Li SW, Dai EH

Retrospective Study

- 5036** Trends in hospitalization for alcoholic hepatitis from 2011 to 2017: A USA nationwide study
Wakil A, Mohamed M, Tafesh Z, Niazi M, Olivo R, Xia W, Greenberg P, Pyrsopoulos N
- 5047** Analysis of invasiveness and tumor-associated macrophages infiltration in solid pseudopapillary tumors of pancreas
Yang J, Tan CL, Long D, Liang Y, Zhou L, Liu XB, Chen YH

Observational Study

- 5058** Impact of adalimumab on disease burden in moderate-to-severe ulcerative colitis patients: The one-year, real-world UCanADA study

Bessissow T, Nguyen GC, Tarabain O, Peyrin-Biroulet L, Foucault N, McHugh K, Ruel J

CASE REPORT

- 5076** Gastrointestinal tumors in transplantation: Two case reports and review of literature

Stammler R, Anglicheau D, Landi B, Meatchi T, Ragot E, Thervet E, Lazareth H

- 5086** Spontaneous expulsion of a duodenal lipoma after endoscopic biopsy: A case report

Chen ZH, Lv LH, Pan WS, Zhu YM

ABOUT COVER

Editorial Board Member of *World Journal of Gastroenterology*, Abhinav Vasudevan, BMed, MPH, FRACP, PhD, Staff Physician and Medical Lead in Inflammatory Bowel Diseases, Department of Gastroenterology and Hepatology, Eastern Health, Box Hill 3128, Australia

AIMS AND SCOPE

The primary aim of *World Journal of Gastroenterology* (WJG, *World J Gastroenterol*) is to provide scholars and readers from various fields of gastroenterology and hepatology with a platform to publish high-quality basic and clinical research articles and communicate their research findings online. WJG mainly publishes articles reporting research results and findings obtained in the field of gastroenterology and hepatology and covering a wide range of topics including gastroenterology, hepatology, gastrointestinal endoscopy, gastrointestinal surgery, gastrointestinal oncology, and pediatric gastroenterology.

INDEXING/ABSTRACTING

The WJG is now abstracted and indexed in Science Citation Index Expanded (SCIE, also known as SciSearch®), Current Contents/Clinical Medicine, Journal Citation Reports, Index Medicus, MEDLINE, PubMed, PubMed Central, Scopus, Reference Citation Analysis, China National Knowledge Infrastructure, China Science and Technology Journal Database, and Superstar Journals Database. The 2022 edition of Journal Citation Reports® cites the 2021 impact factor (IF) for WJG as 5.374; IF without journal self cites: 5.187; 5-year IF: 5.715; Journal Citation Indicator: 0.84; Ranking: 31 among 93 journals in gastroenterology and hepatology; and Quartile category: Q2. The WJG's CiteScore for 2021 is 8.1 and Scopus CiteScore rank 2021: Gastroenterology is 18/149.

RESPONSIBLE EDITORS FOR THIS ISSUE

Production Editor: Hua-Ge Yu; Production Department Director: Xu Guo; Editorial Office Director: Jia-Ru Fan.

NAME OF JOURNAL

World Journal of Gastroenterology

ISSN

ISSN 1007-9327 (print) ISSN 2219-2840 (online)

LAUNCH DATE

October 1, 1995

FREQUENCY

Weekly

EDITORS-IN-CHIEF

Andrzej S Tarnawski

EDITORIAL BOARD MEMBERS

<http://www.wjgnet.com/1007-9327/editorialboard.htm>

PUBLICATION DATE

September 14, 2022

COPYRIGHT

© 2022 Baishideng Publishing Group Inc

INSTRUCTIONS TO AUTHORS

<https://www.wjgnet.com/bpg/gerinfo/204>

GUIDELINES FOR ETHICS DOCUMENTS

<https://www.wjgnet.com/bpg/GerInfo/287>

GUIDELINES FOR NON-NATIVE SPEAKERS OF ENGLISH

<https://www.wjgnet.com/bpg/gerinfo/240>

PUBLICATION ETHICS

<https://www.wjgnet.com/bpg/GerInfo/288>

PUBLICATION MISCONDUCT

<https://www.wjgnet.com/bpg/gerinfo/208>

ARTICLE PROCESSING CHARGE

<https://www.wjgnet.com/bpg/gerinfo/242>

STEPS FOR SUBMITTING MANUSCRIPTS

<https://www.wjgnet.com/bpg/GerInfo/239>

ONLINE SUBMISSION

<https://www.f6publishing.com>



Spontaneous expulsion of a duodenal lipoma after endoscopic biopsy: A case report

Zhi-Hao Chen, Li-Hong Lv, Wen-Sheng Pan, Yi-Miao Zhu

Specialty type: Gastroenterology and hepatology

Provenance and peer review: Unsolicited article; Externally peer reviewed.

Peer-review model: Single blind

Peer-review report's scientific quality classification

Grade A (Excellent): 0
Grade B (Very good): B
Grade C (Good): C, C
Grade D (Fair): 0
Grade E (Poor): 0

P-Reviewer: Morozov S, Russia; Skok K, Austria

Received: March 3, 2022

Peer-review started: March 3, 2022

First decision: June 11, 2022

Revised: July 24, 2022

Accepted: August 21, 2022

Article in press: August 21, 2022

Published online: September 14, 2022



Zhi-Hao Chen, Wen-Sheng Pan, Yi-Miao Zhu, Department of Gastroenterology, Zhejiang Provincial People's Hospital, Hangzhou 310014, Zhejiang Province, China

Zhi-Hao Chen, Wen-Sheng Pan, Yi-Miao Zhu, Affiliated Hospital, People's Hospital of Hangzhou Medical College, Hangzhou 310014, Zhejiang Province, China

Li-Hong Lv, Department of Gastroenterology, Xianju County People's Hospital, Taizhou 317300, Zhejiang Province, China

Corresponding author: Yi-Miao Zhu, MM, Doctor, Department of Gastroenterology, Zhejiang Provincial People's Hospital, No. 158 Shangtang Road, Gongshu District, Hangzhou 310014, Zhejiang Province, China. zhuyimiao01@163.com

Abstract

BACKGROUND

Gastrointestinal (GI) lipomas are benign submucosal tumors of mature adipocytes that arise mainly in the colon and stomach, sometimes in the ileum and jejunum, and rarely in the duodenum. Patients with symptomatic lipomas require endoscopic or surgical treatment. Spontaneous expulsion of lipomas after biopsy is a rare condition that has limited case reports.

CASE SUMMARY

A 56-year-old man presented to our hospital with intermittent postprandial epigastric fullness. Esophagogastroduodenoscopy (EGD) revealed a 10-mm soft yellowish submucosal lesion with the "pillow sign," located in the second portion of duodenum. Endoscopic ultrasonography (EUS) using a 12-MHz catheter probe showed a hyperechoic, homogenous, and round solid lesion (OLYMPUS EUS EU-ME2, UM-DP12-25R, 12-MHz radial miniprobe, Olympus Corporation, Tokyo, Japan). Deep biopsy was performed using the bite-on-bite technique with forceps. Histological examination was compatible with submucosal lipoma. The lesion spontaneously expelled 12 d after the biopsy. Follow-up EUS performed after 2 mo confirmed this condition.

CONCLUSION

Deep biopsy could lead to spontaneous GI lipoma expulsion. This might be the first step in lipoma diagnosis and treatment.

Key Words: Lipoma; Duodenal neoplasms; Spontaneous expulsion; Endoscopic biopsy;

Adipose tissue; Case report

©The Author(s) 2022. Published by Baishideng Publishing Group Inc. All rights reserved.

Core Tip: Gastrointestinal lipomas are benign tumors consisting of mature adipocytes. Symptomatic patients may require endoscopic or surgical treatment. Here, we report a case of duodenal papillary lipoma, which was spontaneously expelled 12 d after a bite-on-bite deep biopsy with forceps. The spontaneous expulsion of the lipoma shows the possibility of performing a deep biopsy as a fenestration in the first step as a diagnostic and therapeutic procedure.

Citation: Chen ZH, Lv LH, Pan WS, Zhu YM. Spontaneous expulsion of a duodenal lipoma after endoscopic biopsy: A case report. *World J Gastroenterol* 2022; 28(34): 5086-5092

URL: <https://www.wjgnet.com/1007-9327/full/v28/i34/5086.htm>

DOI: <https://dx.doi.org/10.3748/wjg.v28.i34.5086>

INTRODUCTION

Gastrointestinal (GI) lipomas are benign submucosal tumors of mature adipocytes that are commonly found incidentally on endoscopy and imaging. They arise throughout the GI tract, mainly in the colon (65%-75%), followed by the ileum and jejunum (25%)[1]. The duodenum is a rare site of GI lipomas, with only 4% of lipomas affected, mostly in the second portion of the duodenum[1]. Lipomas are rarely symptomatic and have no malignant potential. However, they occasionally result in hemorrhage, abdominal pain, intestinal intussusception, or obstructive jaundice, which are related to the characteristics of the lipoma, such as its size and location[1,2]. Symptomatic duodenal lipomas require treatment. They can be excised endoscopically or surgically. This report presents a case of duodenal lipoma diagnosed by endoscopic ultrasonography (EUS) that was spontaneously expelled 12 d after a bite-on-bite deep biopsy with forceps.

CASE PRESENTATION

Chief complaints

A 56-year-old Chinese man presented to our gastroenterology department with intermittent postprandial epigastric fullness for half a year.

History of present illness

The patient had early satiety and mild reflux, especially after greasy meals, without abdominal pain, melena, fever, or jaundice. The symptoms were moderate and paroxysmal, which affected his appetite. No weight loss was reported during the past half a year. There was no history of abdominal surgery.

History of past illness

The patient's past medical history was non-contributory.

Personal and family history

The patient has none family history.

Physical examination

On physical examination, the patient's vital signs were stable with a 37.2 °C body temperature on admission. The subject's height was 170 cm and weight was 80 kg, with body mass index of 27.68 kg/m². No obvious abnormalities were observed upon pulmonary and cardiac examination. There was no tenderness, mass, unusual bowel sounds, or Murphy's sign upon abdominal examination. No jaundice or superficial lymphadenopathy was observed.

Laboratory examinations

The analyses of complete blood count, blood biochemistry, and serum tumor marker levels were within the normal range.

Imaging examinations

Esophagogastroduodenoscopy (EGD) revealed a 10-mm soft yellowish submucosal lesion with the “pillow sign,” located in the second portion of the duodenum, directly upon the duodenal papilla (Figures 1A and B). Contrast-enhanced computed tomography (CT) revealed a suspicious low-density lesion in the peripapillary region without enhancement (Figure 1C). Further EUS (OLYMPUS EUS EU-ME2, UM-DP12-25R, 12-MHz radial miniprobe, Olympus Corporation, Tokyo, Japan) revealed a hyperechoic, homogenous, round solid lesion arising from the submucosal layer, accompanied by echo attenuation (Figure 1D).

FINAL DIAGNOSIS

Deep biopsy was performed *via* the bite-on-bite technique using forceps (Micro-Tech Co. Ltd., Nanjing, China) (Figure 1E). Microscopic examination showed a small amount of roundish adipocytes in the submucosa layer, expressing S-100. Tiny lipid droplets were observed in cell cytoplasm. The glands of epithelium were neatly arranged on top. The small fragments of biopsy compatible with a submucosal lipoma. (Figures 1F-H). Based on the classic endoscopic signs, EUS characteristics and histology of the lesion, a diagnosis of duodenal lipoma was made. No bleeding, perforation, or any other complications were observed the patient.

TREATMENT

During endoscopy, the patient underwent neither resection nor hemostatic procedures after the biopsy. Prokinetics and proton pump inhibitor were prescribed to relieve the symptoms. Considering the size and location of the lipoma, we suggested that the patient remain under observation. However, the patient was extremely anxious about the lesion and insisted on its removal; thus, endoscopic resection and prophylactic pancreatic duct stenting were attempted.

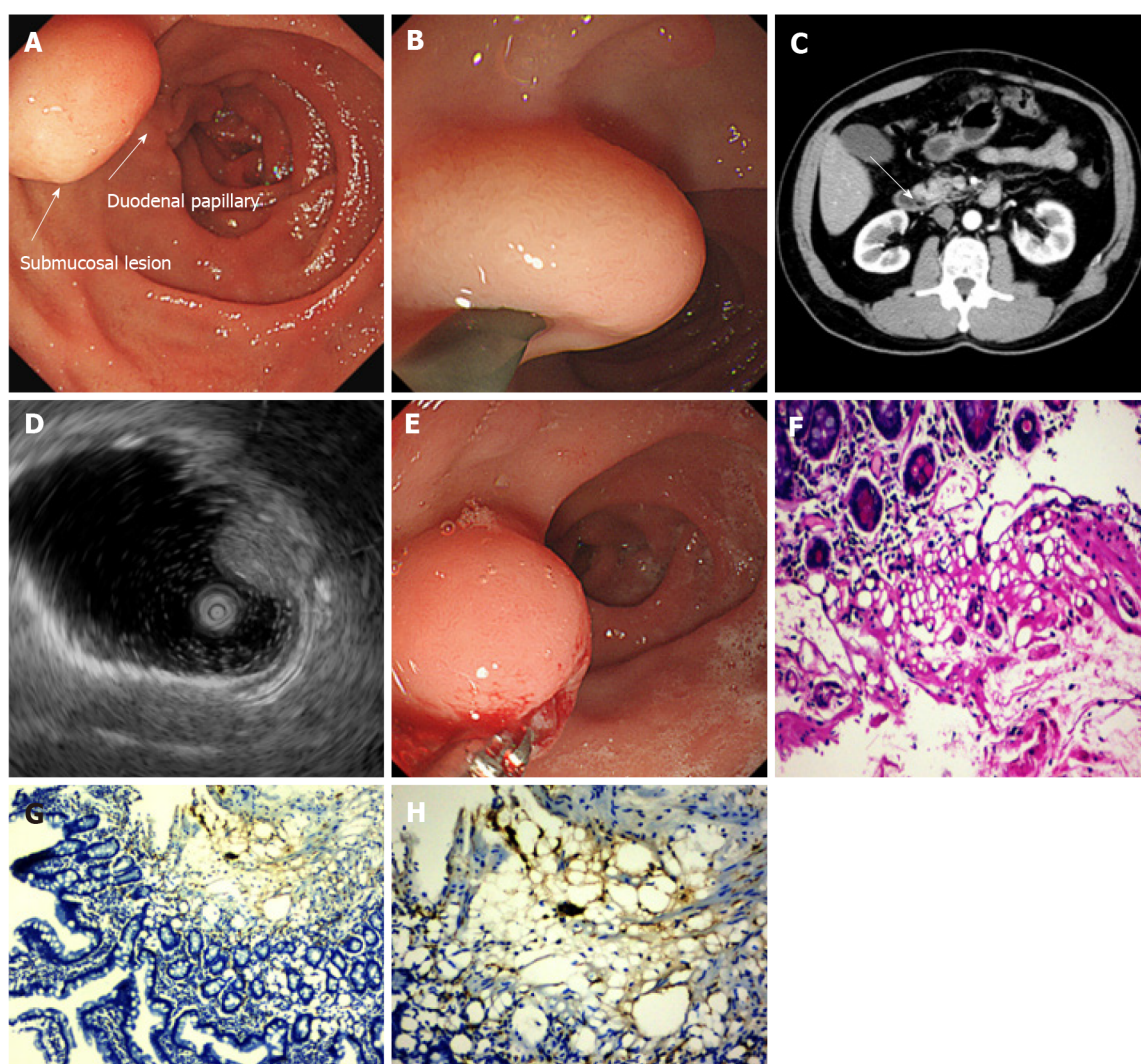
OUTCOME AND FOLLOW-UP

The patient reported milder symptoms and fewer episodes after prescription. However, he insisted on resection. On endoscopic resection, which was 12 d after the biopsy, the lipoma had disappeared, with only a red scar and inflammatory mucosa residue in situ of the lesion (Figures 2A and B). Two months after the first EUS, a follow-up EUS was performed, showing that macroscopically the site displayed signs of inflammation and scarring. And the former lesion no longer existed in the surrounding duodenal wall in EUS (Figures 2C-E). After endoscopy, mild symptoms occasionally occurred during the follow-up period, without medications.

DISCUSSION

Duodenal lipoma is a rare benign tumor of the GI tract accounting for 4% of GI lipomas, most of which occur in the second portion of the duodenum[1,2]. Duodenal lipoma can be symptomatic or asymptomatic, depending on the size and location. Moreover, 80% of symptomatic duodenal lipomas have a diameter of > 2 cm, mainly manifesting as intestinal obstruction, hemorrhage, and jaundice[2,3]. The tumor in our case was a submucosal lipoma, which accounts for > 90% of intestinal lipomas, with the others arising from the intermuscular tissue and subserosa[4]. Imaging of lipomas is well recognized. CT shows well-defined border tumors in a uniform low density with fat attenuation of -120 HU to -60 HU, while magnetic resonance imaging shows high-intensity lesion with on T1-weighted, iso-signal intensity on T2-weighted, and low intensity on fat-suppressed T2-weighted imaging[5,6]. The classic endoscopic signs as “pillow sign,” “tenting sign,” and “naked fat sign” indicate the possibility of lipomas. The typical EUS finding for submucosal lipomas is a homogeneous hyperechoic mass originating from the submucosal layer, with echo attenuation behind and/or inside the rear area[7]. In our case, the duodenal lipoma was present in the second portion of the duodenum, immediately upon the duodenal papilla, with classic imaging on EGD, CT, and EUS, with pathologically confirmation.

Symptomatic lipomas require treatment, including removal *via* endoscopy or surgical excision. There are four techniques for endoscopic excision: Dissection-based resection, endoscopic mucosal resection (EMR), loop-assisted resection, and unroofing[8] (Figure 3). Dissection-based resection defines as endoscopic procedure mainly using dissection-based techniques, such as ESD. Loop-assisted resection is the procedure performed with loop for haemostatic or removal reasons. Because of the poor conduction of electric current in the adipose tissue, endoscopists must apply a higher electrical output during

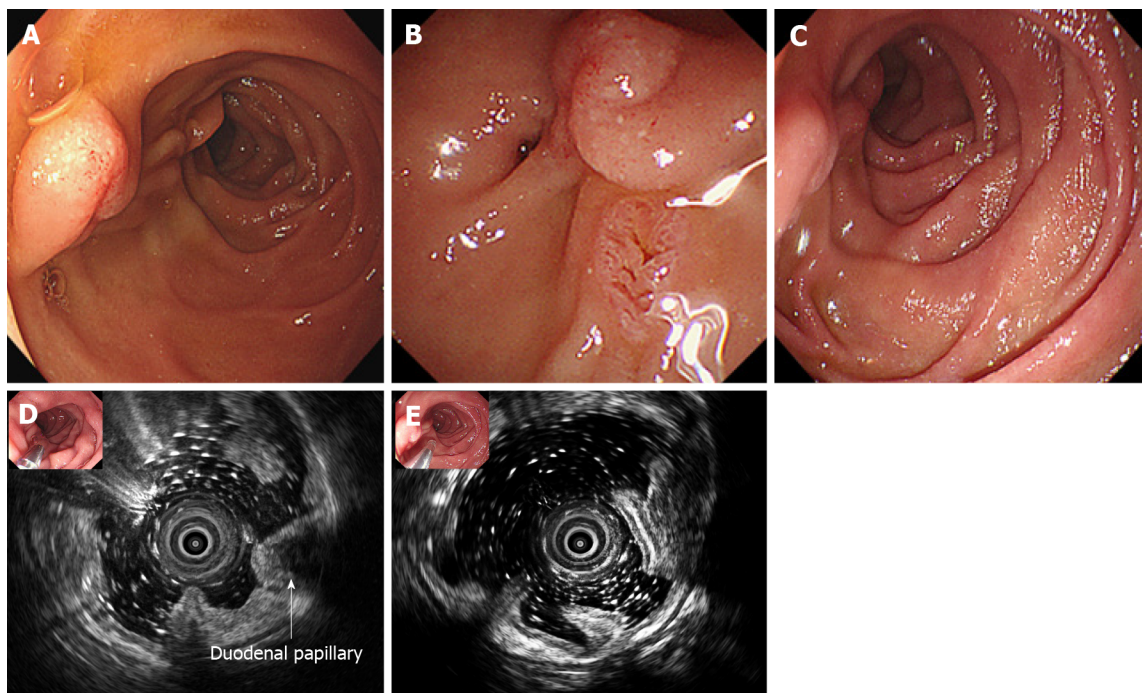


DOI: 10.3748/wjg.v28.i34.5086 Copyright ©The Author(s) 2022.

Figure 1 Imaging findings at the time of diagnosis. A and B: Esophagogastroduodenoscopy revealed a 10-mm soft yellowish submucosal lesion with the “pillow sign,” located in the second portion of duodenum, immediately upon the duodenal papillary; C: Abdominal contrast-enhanced computed tomography shows a suspicious low-density lesion in the peripapillary region without enhancement (white arrow); D: Endoscopic ultrasonography with a 12-MHz catheter probe showed a hyperechoic, homogenous, and round solid lesion with echo attenuation, arising from the submucosal layer; E: Deep biopsy *via* bite-on-bite technique with forceps was performed; F-H: Microscopic examination showed a small amount of roundish adipocyte in the submucosa layer, expressing S-100. Tiny lipid droplets were observed in cell cytoplasm. The glands of epithelium were neatly arranged on top (F: Hematoxylin and eosin staining, $\times 200$; G: Immunohistochemical S-100 stain, $\times 100$; H: IHC S-100 stain, $\times 200$).

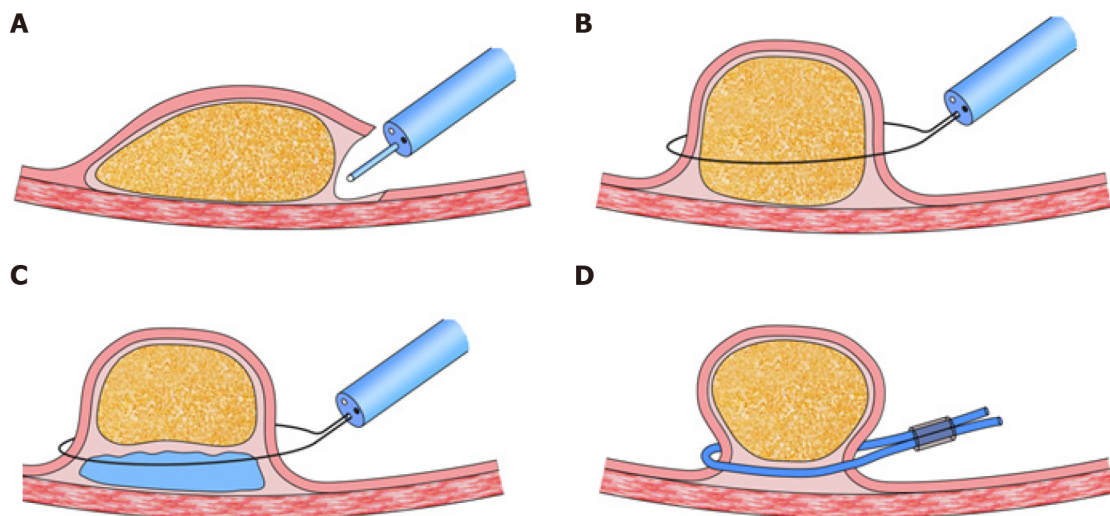
resection, which increases the possibility of complications, such as hemorrhage and perforation, especially for giant lipomas. The unroofing technique, which cuts off the upper half of the lesion, with the remaining adipose tissue extruded from the open surface, was first applied by Mimura *et al*[9]. Its efficacy and safety have been approved by several authors in case reports[10-14]. Bronswijk *et al*[8] collected 24 studies (77 lesions included) of endoscopic treatment for colon lipomas, and a systematic review indicated that endoscopic resolution rates were 60%, 100%, 93.6%, and 93.1% for unroofing, dissection-based resection, EMR, and loop-assisted resection, respectively. The former two techniques reported no adverse events, whereas the latter two showed complication rates of 12.9%-13.8%. Yamamoto *et al*[15] proposed a two-step hybrid technique that combined endoscopic unroofing with EMR for giant lipomas.

Spontaneous disappearance or expulsion of lipomas is an extremely rare manifestation that had limited case reports. There have been some cases of spontaneous expulsion per rectum of submucosal lipomas without any intervention. With a certain volume, these submucosal lipomas cause intussusception, which might lead to ischemia, necrosis, and breakage, and the lipomas were spontaneously expelled[4,16-20]. In our case, the lipoma was spontaneously expelled after deep biopsy *via* the bite-on-bite technique with forceps, which we suspected was the result of fat extravasation from the biopsy site as fenestration over time. There were a few cases of spontaneous expulsion after biopsy of GI lipoma[21-24]. Kurahara *et al*[21] first reported a gastric lipoma that was expelled after biopsy. Ishiyama *et al*[22] reported the expulsion of a colonic lipoma after biopsy. We speculated that, in these cases, three



DOI: 10.3748/wjg.v28.i34.5086 Copyright ©The Author(s) 2022.

Figure 2 Follow-up endoscopic view of the lesion. A and B: 12 d after the biopsy, the lipoma was spontaneously expelled, with red scar and inflammatory mucosa residue in situ of the lesion; C-E: Follow-up endoscopic ultrasonography after 2 mo revealed that the *in situ* mucosa was smooth, and the former lesion no longer existed in the surrounding duodenal wall or periduodenal papilla region.



DOI: 10.3748/wjg.v28.i34.5086 Copyright ©The Author(s) 2022.

Figure 3 Techniques for endoscopic excision of gastrointestinal lipomas[14]. A: Dissection-based resection technique; B: Unroofing technique; C: Endoscopic mucosal resection; D: Loop-assisted resection technique.

conditions need to be met for the lipoma to disappear: (1) The overlying mucosa and tumor capsule must be damaged by either acquired opening, such as unroofing and deep biopsy, or spontaneous opening, such as ischemia and ulceration; (2) The lipoma should arise from the submucosal layer; and (3) The extravasation rate, which depends on the tumor volume and size of the fenestration, should be faster than the mucosal healing rate. In this case, the special anatomical position might have facilitated pancreatic lipase and bile digestion of the lipoma to speed up the discharge process.

The treatment techniques and cases of spontaneous expulsion lipomas indicate that we might conduct a deep biopsy based on bite-on-bite techniques or more intense “tunneled biopsy” as fenestration routinely when a lipoma is diagnosed with typical EUS and EGD. Such biopsies could aid in further diagnosis in pathology and reduce the size or even remove the lesion as a treatment, particularly in cases where the lesion is relatively large or located in the small intestine[25]. A simple deep biopsy

during diagnosis might decrease the complications caused by the lesion itself or by the next step of endoscopic or surgical resection. Larger studies are necessary to make conclusion on the efficacy of fenestration on lipoma and algorithm of treatment.

CONCLUSION

In this case, we present the spontaneous expulsion of a duodenal lipoma 12 d after a bite-on-bite deep biopsy. Treatments for benign and slow-growing tumors include endoscopic dissection-based resection, EMR, loop-assisted resection, endoscopic unroofing, and surgical resection. The expulsion of lipoma after biopsy enlightens us the possibility of taking a deep biopsy as a fenestration in the first step as the diagnostic and therapeutic procedure.

ACKNOWLEDGEMENTS

Yi-Miao Zhu would extend her sincere gratitude to Yuan Chen for his careful review of the pathology, valuable suggestions, and inspiring advice of the case. Special thanks should go to her beloved husband for his continuous support and encouragement.

FOOTNOTES

Author contributions: Chen ZH, Lv LH, and Zhu YM assembled, analyzed, and interpreted the patient's data and case presentation; Zhu YM and Pan WS reviewed the literature; Chen ZH and Zhu YM prepared the original manuscript; Zhu YM edited and critically revised the manuscript; all authors contributed to writing the manuscript; and all authors read and approved the final manuscript.

Supported by the Medical Technology and Education of Zhejiang Province of China, No. Y202146136.

Informed consent statement: Written informed consent was obtained from the patient's guardian for the publication of this case report and any accompanying images.

Conflict-of-interest statement: All the authors report no relevant conflicts of interest for this article.

CARE Checklist (2016) statement: The authors read the CARE Checklist (2016), and the manuscript was prepared and revised according to the CARE checklist (2016).

Open-Access: This article is an open-access article that was selected by an in-house editor and fully peer-reviewed by external reviewers. It is distributed in accordance with the Creative Commons Attribution NonCommercial (CC BY-NC 4.0) license, which permits others to distribute, remix, adapt, build upon this work non-commercially, and license their derivative works on different terms, provided the original work is properly cited and the use is non-commercial. See: <https://creativecommons.org/licenses/by-nc/4.0/>

Country/Territory of origin: China

ORCID number: Wen-Sheng Pan 0000-0002-2347-1695; Yi-Miao Zhu 0000-0002-1745-4063.

S-Editor: Wang JJ

L-Editor: A

P-Editor: Wang JJ

REFERENCES

- 1 O'Riordan BG, Vilor M, Herrera L. Small bowel tumors: an overview. *Dig Dis* 1996; **14**: 245-257 [PMID: 8843980 DOI: 10.1159/000171556]
- 2 Pei MW, Hu MR, Chen WB, Qin C. Diagnosis and Treatment of Duodenal Lipoma: A Systematic Review and a Case Report. *J Clin Diagn Res* 2017; **11**: PE01-PE05 [PMID: 28892976 DOI: 10.7860/JCDR/2017/27748.10322]
- 3 Wilson JM, Melvin DB, Gray G, Thorbjarnarson B. Benign small bowel tumor. *Ann Surg* 1975; **181**: 247-250 [PMID: 1078626]
- 4 Kang B, Zhang Q, Shang D, Ni Q, Muhammad F, Hou L, Cui W. Resolution of intussusception after spontaneous expulsion of an ileal lipoma per rectum: a case report and literature review. *World J Surg Oncol* 2014; **12**: 143 [PMID: 24884620 DOI: 10.1186/1477-7819-12-143]
- 5 Genchellac H, Demir MK, Ozdemir H, Unlu E, Temizoz O. Computed tomographic and magnetic resonance imaging

- findings of asymptomatic intra-abdominal gastrointestinal system lipomas. *J Comput Assist Tomogr* 2008; **32**: 841-847 [PMID: 19204441 DOI: 10.1097/RCT.0b013e318159a4b5]
- 6 Kovač JD, Dunjić MK, Bjelović M, Banko B, Lilić G, Milenković R, Micev M, Maksimović R. Magnetic resonance imaging features of multiple duodenal lipomas: a rare cause of intestinal obstruction. *Jpn J Radiol* 2012; **30**: 676-679 [PMID: 22752443 DOI: 10.1007/s11604-012-0098-z]
 - 7 Chen HT, Xu GQ, Wang LJ, Chen YP, Li YM. Sonographic features of duodenal lipomas in eight clinicopathologically diagnosed patients. *World J Gastroenterol* 2011; **17**: 2855-2859 [PMID: 21734794 DOI: 10.3748/wjg.v17.i23.2855]
 - 8 Bronswijk M, Vandenbroucke AM, Bossuyt P. Endoscopic treatment of large symptomatic colon lipomas: A systematic review of efficacy and safety. *United European Gastroenterol J* 2020; **8**: 1147-1154 [PMID: 32746773 DOI: 10.1177/2050640620948661]
 - 9 Mimura T, Kuramoto S, Hashimoto M, Yamasaki K, Kobayashi K, Kobayashi M, Oohara T. Unroofing for lymphangioma of the large intestine: a new approach to endoscopic treatment. *Gastrointest Endosc* 1997; **46**: 259-263 [PMID: 9378215 DOI: 10.1016/s0016-5107(97)70097-x]
 - 10 Kim GW, Kwon CI, Song SH, Jin SM, Kim KH, Moon JH, Hong SP, Park PW. Endoscopic resection of giant colonic lipoma: case series with partial resection. *Clin Endosc* 2013; **46**: 586-590 [PMID: 24143327 DOI: 10.5946/ce.2013.46.5.586]
 - 11 Lee KJ, Kim GH, Park DY, Shin NR, Lee BE, Ryu DY, Kim DU, Song GA. Endoscopic resection of gastrointestinal lipomas: a single-center experience. *Surg Endosc* 2014; **28**: 185-192 [PMID: 23996333 DOI: 10.1007/s00464-013-3151-9]
 - 12 Shin EK, Kim KJ, Seo JA, Paek JH, Choi IS, Moon W, Park MI, Park SJ. [A case of giant colonic lipoma showing spontaneous resolution after endoscopic partial resection]. *Korean J Gastroenterol* 2007; **50**: 199-202 [PMID: 17885287]
 - 13 Soares JB, Gonçalves R, Rolanda C. Endoscopic resection of a large colonic lipoma by unroofing technique. *Endoscopy* 2011; **43** Suppl 2 UCTN: E407 [PMID: 22275025 DOI: 10.1055/s-0030-1256938]
 - 14 Sugimoto K, Sato K, Maekawa H, Sakurada M, Orita H, Ito T, Saita M, Ikota M, Yoshida Y, Yamano M. Unroofing technique for endoscopic resection of a large colonic lipoma. *Case Rep Gastroenterol* 2012; **6**: 557-562 [PMID: 22949897 DOI: 10.1159/000342350]
 - 15 Yamamoto K, Ikeya T, Shiratori Y. Endoscopic unroofing and mucosal resection for a large colonic lipoma with intussusception: an effective hybrid technique. *VideoGIE* 2021; **6**: 190-192 [PMID: 33898900 DOI: 10.1016/j.vgie.2020.11.018]
 - 16 Misra SP, Singh SK, Thorat VK, Gulati P, Malhotra V, Anand BS. Spontaneous expulsion per rectum of an ileal lipoma. *Postgrad Med J* 1988; **64**: 718-719 [PMID: 3251232 DOI: 10.1136/pgmj.64.755.718]
 - 17 Hamila F, Elghali MA, Bouriga R, Haj Khelifa MH, Fadhl H, Jarrar MS, Letaief R. Partial spontaneous anal expulsion of the right colon lipoma: An exceptional diagnostic circumstance. *Int J Surg Case Rep* 2017; **41**: 414-416 [PMID: 29546005 DOI: 10.1016/j.ijscr.2017.10.059]
 - 18 Robertson DA, Saweirs W, Low-Beer TS. Spontaneous expulsion of a large colonic tumour. *Br Med J (Clin Res Ed)* 1982; **285**: 1084 [PMID: 6812756 DOI: 10.1136/bmj.285.6348.1084]
 - 19 Zamboni WA, Fleisher H, Zander JD, Folse JR. Spontaneous expulsion of lipoma per rectum occurring with colonic intussusception. *Surgery* 1987; **101**: 104-107 [PMID: 3492056]
 - 20 Stebbings WS, Staunton MD. Spontaneous expulsion of a large submucosal colonic lipoma. *J R Soc Med* 1989; **82**: 624-625 [PMID: 2810300 DOI: 10.1177/014107688908201021]
 - 21 Kurahara K, Aoyagi K, Hizawa K, Yao T, Iida M, Fujishima M. Spontaneous disappearance of a gastric lipoma after endoscopic biopsy: report of an unusual case. *Endoscopy* 1999; **31**: S31 [PMID: 10376473]
 - 22 Ishiyama S, Tashiro Y, Nagayasu K, Niwa K, Ono S, Sugimoto K, Hata M, Kamiyama H, Komiyama H, Takahashi M, Yaginuma Y, Kojima Y, Goto M, Tanaka M, Sengoku H, Okuzawa A, Tomiki Y, Sakamoto K. Spontaneous disappearance of a giant colonic lipoma after endoscopic biopsy. *Endoscopy* 2011; **43** Suppl 2 UCTN: E16 [PMID: 21271519 DOI: 10.1055/s-0030-1255826]
 - 23 João M, Cunha I, Gravito-Soares E, Gravito-Soares M, Amaro P, Figueiredo P. An Atypical Presentation of a Colonic Lipoma: Avoiding Surgery with a Deeper Endoscopic Look. *GE Port J Gastroenterol* 2022; **29**: 45-50 [PMID: 35111963 DOI: 10.1159/000513967]
 - 24 Sidani SM, Tawil AN, Sidani MS. Extraction of a large self-amputated colonic lipoma: A case report. *Int J Surg* 2008; **6**: 409-411 [PMID: 18947813 DOI: 10.1016/j.ijssu.2006.05.003]
 - 25 Koutsoumpas A, Perera R, Melton A, Kuker J, Ghosh T, Braden B. Tunneled biopsy is an underutilised, simple, safe and efficient method for tissue acquisition from subepithelial tumours. *World J Clin Cases* 2021; **9**: 5822-5829 [PMID: 34368301 DOI: 10.12998/wjcc.v9.i21.5822]



Published by **Baishideng Publishing Group Inc**
7041 Koll Center Parkway, Suite 160, Pleasanton, CA 94566, USA

Telephone: +1-925-3991568

E-mail: bpgoffice@wjgnet.com

Help Desk: <https://www.f6publishing.com/helpdesk>

<https://www.wjgnet.com>

