

World Journal of *Gastroenterology*

World J Gastroenterol 2022 December 21; 28(47): 6619-6790



OPINION REVIEW

- 6619 How to avoid overtreatment of benign colorectal lesions: Rationale for an evidence-based management
Bustamante-Balén M

REVIEW

- 6632 Mucosal imaging in colon polyps: New advances and what the future may hold
Young EJ, Rajandran A, Philpott HL, Sathananthan D, Hoile SF, Singh R
- 6662 Acute liver injury in COVID-19 patients hospitalized in the intensive care unit: Narrative review
Polyzogopoulou E, Amoiridou P, Abraham TP, Ventoulis I
- 6689 Alterations of the gut microbiota in coronavirus disease 2019 and its therapeutic potential
Xiang H, Liu QP

MINIREVIEWS

- 6702 Microbiota in the stomach and application of probiotics to gastroduodenal diseases
Koga Y
- 6716 Liver injury in COVID-19: A minireview
Hu WS, Jiang FY, Shu W, Zhao R, Cao JM, Wang DP
- 6732 Obstructive and secretory complications of diverting ileostomy
Tsujinaka S, Suzuki H, Miura T, Sato Y, Shibata C
- 6743 Role of the combination of biologics and/or small molecules in the treatment of patients with inflammatory bowel disease
Balderramo D

ORIGINAL ARTICLE

Basic Study

- 6752 Interleukin-34 deficiency aggravates development of colitis and colitis-associated cancer in mice
Liu ZX, Chen WJ, Wang Y, Chen BQ, Liu YC, Cheng TC, Luo LL, Chen L, Ju LL, Liu Y, Li M, Feng N, Shao JG, Bian ZL
- 6769 Dickkopf-related protein 1/cytoskeleton-associated protein 4 signaling activation by *Helicobacter pylori*-induced activator protein-1 promotes gastric tumorigenesis via the PI3K/AKT/mTOR pathway
Luo M, Chen YJ, Xie Y, Wang QR, Xiang YN, Long NY, Yang WX, Zhao Y, Zhou JJ

LETTER TO THE EDITOR

- 6788** The potential role of the three-dimensional-bioprinting model in screening and developing drugs
Deng CL, Wu B

ABOUT COVER

Editorial Board of *World Journal of Gastroenterology*, Guy D Eslick, DrPH, PhD, FACE, Professor, NHMRC Centre for Research Excellence in Digestive Health, The Hunter Medical Research Institute (HMRI), The University of Newcastle, Newcastle 2300, NSW, Australia. guy.eslick@newcastle.edu.au

AIMS AND SCOPE

The primary aim of *World Journal of Gastroenterology* (WJG, *World J Gastroenterol*) is to provide scholars and readers from various fields of gastroenterology and hepatology with a platform to publish high-quality basic and clinical research articles and communicate their research findings online. WJG mainly publishes articles reporting research results and findings obtained in the field of gastroenterology and hepatology and covering a wide range of topics including gastroenterology, hepatology, gastrointestinal endoscopy, gastrointestinal surgery, gastrointestinal oncology, and pediatric gastroenterology.

INDEXING/ABSTRACTING

The WJG is now abstracted and indexed in Science Citation Index Expanded (SCIE, also known as SciSearch®), Current Contents/Clinical Medicine, Journal Citation Reports, Index Medicus, MEDLINE, PubMed, PubMed Central, Scopus, Reference Citation Analysis, China National Knowledge Infrastructure, China Science and Technology Journal Database, and Superstar Journals Database. The 2022 edition of Journal Citation Reports® cites the 2021 impact factor (IF) for WJG as 5.374; IF without journal self cites: 5.187; 5-year IF: 5.715; Journal Citation Indicator: 0.84; Ranking: 31 among 93 journals in gastroenterology and hepatology; and Quartile category: Q2. The WJG's CiteScore for 2021 is 8.1 and Scopus CiteScore rank 2021: Gastroenterology is 18/149.

RESPONSIBLE EDITORS FOR THIS ISSUE

Production Editor: Yi-Xuan Cai; **Production Department Director:** Xiang Li; **Editorial Office Director:** Jia-Ru Fan.

NAME OF JOURNAL

World Journal of Gastroenterology

ISSN

ISSN 1007-9327 (print) ISSN 2219-2840 (online)

LAUNCH DATE

October 1, 1995

FREQUENCY

Weekly

EDITORS-IN-CHIEF

Andrzej S Tarnawski

EDITORIAL BOARD MEMBERS

<http://www.wjgnet.com/1007-9327/editorialboard.htm>

PUBLICATION DATE

December 21, 2022

COPYRIGHT

© 2023 Baishideng Publishing Group Inc

INSTRUCTIONS TO AUTHORS

<https://www.wjgnet.com/bpg/gerinfo/204>

GUIDELINES FOR ETHICS DOCUMENTS

<https://www.wjgnet.com/bpg/GerInfo/287>

GUIDELINES FOR NON-NATIVE SPEAKERS OF ENGLISH

<https://www.wjgnet.com/bpg/gerinfo/240>

PUBLICATION ETHICS

<https://www.wjgnet.com/bpg/GerInfo/288>

PUBLICATION MISCONDUCT

<https://www.wjgnet.com/bpg/gerinfo/208>

ARTICLE PROCESSING CHARGE

<https://www.wjgnet.com/bpg/gerinfo/242>

STEPS FOR SUBMITTING MANUSCRIPTS

<https://www.wjgnet.com/bpg/GerInfo/239>

ONLINE SUBMISSION

<https://www.f6publishing.com>



Acute liver injury in COVID-19 patients hospitalized in the intensive care unit: Narrative review

Effie Polyzogopoulou, Pinelopi Amoiridou, Theodore P Abraham, Ioannis Ventoulis

Specialty type: Gastroenterology and hepatology

Provenance and peer review: Invited article; Externally peer reviewed.

Peer-review model: Single blind

Peer-review report's scientific quality classification

Grade A (Excellent): 0
Grade B (Very good): B
Grade C (Good): C, C, C
Grade D (Fair): D
Grade E (Poor): 0

P-Reviewer: Gong N, China; Karna ST, India; Meena DS, India; Wishahi M, Egypt

Received: September 13, 2022

Peer-review started: September 13, 2022

First decision: October 19, 2022

Revised: November 14, 2022

Accepted: December 5, 2022

Article in press: December 5, 2022

Published online: December 21, 2022



Effie Polyzogopoulou, Department of Emergency Medicine, Attikon University Hospital, National and Kapodistrian University of Athens Medical School, Athens 12462, Greece

Pinelopi Amoiridou, Department of Intensive Care, AHEPA University Hospital, Thessaloniki 54621, Greece

Theodore P Abraham, Hypertrophic Cardiomyopathy Center of Excellence, University of California, San Francisco, CA 94117, United States

Ioannis Ventoulis, Department of Occupational Therapy, University of Western Macedonia, Ptolemaida 50200, Greece

Corresponding author: Ioannis Ventoulis, MD, PhD, Assistant Professor, Department of Occupational Therapy, University of Western Macedonia, Keptse Area, Ptolemaida 50200, Greece. iventoulis@uowm.gr

Abstract

In recent years, humanity has been confronted with a global pandemic due to coronavirus disease 2019 (COVID-19), which has caused an unprecedented health and economic crisis worldwide. Apart from the respiratory symptoms, which are considered the principal manifestations of COVID-19, it has been recognized that COVID-19 constitutes a systemic inflammatory process affecting multiple organ systems. Across the spectrum of organ involvement in COVID-19, acute liver injury (ALI) has been gradually gaining increasing attention by the international scientific community. COVID-19 associated liver impairment can affect a considerable proportion of COVID-19 patients and seems to correlate with the severity of the disease course. Indeed, COVID-19 patients hospitalized in the intensive care unit (ICU) run a greater risk of developing ALI due to the severity of their clinical condition and in the context of multi-organ failure. The putative pathophysiological mechanisms of COVID-19 induced ALI in ICU patients remain poorly understood and appear to be multifactorial in nature. Several theories have been proposed to explain the occurrence of ALI in the ICU setting, such as hypoperfusion and ischemia due to hemodynamic instability, passive liver congestion as a result of congestive heart failure, ischemia-reperfusion injury, hypoxia due to respiratory failure, mechanical ventilation itself, sepsis and septic shock, cytokine storm, endotheliitis with concomitant coagulopathy, drug-induced liver injury, parenteral nutrition and direct cytopathic viral effect. It should be noted that no specific therapy for COVID-19 induced ALI exists. Therefore, the therapeutic approach lies in preventive measures and is exclusively

supportive once ALI ensues. The aim of the current review is to scrutinize the existing evidence on COVID-19 associated ALI in ICU patients, explore its clinical implications, shed light on the underlying pathophysiological mechanisms and propose potential therapeutic approaches. Ongoing research on the particular scientific field will further elucidate the pathophysiology behind ALI and address unresolved issues, in the hope of mitigating the tremendous health consequences imposed by COVID-19 on ICU patients.

Key Words: Liver injury; COVID-19; Intensive care; Pathophysiological mechanisms; Cytokine storm; Multi-organ failure

©The Author(s) 2022. Published by Baishideng Publishing Group Inc. All rights reserved.

Core Tip: In recent times, coronavirus disease 2019 (COVID-19) pandemic has substantially altered the hitherto existing medical landscape, causing tremendous perturbations among the global scientific community and imposing a disproportionate burden on healthcare systems worldwide. It soon became apparent that COVID-19 affects multiple organ systems, including the liver. Acute liver injury has been progressively identified as a common, yet often under-recognized, complication of COVID-19, especially in the intensive care unit (ICU) setting, resulting in higher mortality rates. This review attempts to elucidate the underlying pathophysiological mechanisms that contribute to the development of acute liver injury in ICU patients with COVID-19, summarize emergent data and propose therapeutic strategies.

Citation: Polyzogopoulou E, Amoiridou P, Abraham TP, Ventoulis I. Acute liver injury in COVID-19 patients hospitalized in the intensive care unit: Narrative review. *World J Gastroenterol* 2022; 28(47): 6662-6688

URL: <https://www.wjgnet.com/1007-9327/full/v28/i47/6662.htm>

DOI: <https://dx.doi.org/10.3748/wjg.v28.i47.6662>

INTRODUCTION

In recent years, humanity has been confronted with a global pandemic due to coronavirus disease 2019 (COVID-19), which has caused an unprecedented health and economic crisis worldwide. The initial isolation of the novel severe acute respiratory syndrome coronavirus-2 (SARS-CoV-2) and the subsequent first outbreak of COVID-19 in Wuhan, China, marked a grim milestone for mankind, substantially altering the existing scientific, social and economic landscape[1-3]. Since then, COVID-19 has rapidly spread throughout the world across all nations and ages and has resulted in the emergence of numerous mutant SARS-CoV-2 variants, triggering recurrent COVID-19 surges that continue to drive the ongoing pandemic[4-6]. Due to its dynamic and ever-changing epidemiological course, COVID-19 still remains an international public health emergency and accounts for considerable morbidity and mortality, inflicting an overwhelming death toll and a disproportionate burden on healthcare systems worldwide, thus raising major concerns among the global scientific community[7,8].

The clinical spectrum of COVID-19 is highly variable with a wide range of clinical manifestations. In most cases, the course of the disease is either asymptomatic or presents as a mild self-limited infection; however, in some patients, especially those with underlying comorbidities, COVID-19 evolves to a severe or even a critical life-threatening disease, culminating in the development of acute respiratory distress syndrome (ARDS) which requires intensive care support and may eventually progress to death [9,10]. Undoubtedly, SARS-CoV-2 infection demonstrates an inherent propensity for the respiratory system; hence, lung involvement is the predominant feature in patients hospitalized with COVID-19. Nonetheless, as the complete magnitude of COVID-19 sequelae continues to unravel, it has been realized that this new nosological entity constitutes a diverse, complex and multifaceted syndrome that extends beyond the respiratory system and affects multiple organs, including the liver[11,12]. Bearing this in mind, specific attention has been gradually drawn towards the pathogenesis of liver injury in the setting of COVID-19, since acute liver injury (ALI) has been progressively identified as a common, yet often under-recognized, complication of COVID-19. As a matter of fact, there have been numerous literature reports that a considerable proportion of COVID-19 patients develop liver injury characterized by abnormalities in liver chemistry levels. Notably, ALI seems to correlate with the severity of the disease course[13-16]. Indeed, COVID-19 patients hospitalized in the intensive care unit (ICU) run a greater risk of developing ALI, mainly due to the severity of their clinical condition and in the context of multi-organ failure, thus resulting in higher mortality rates[17-20].

Studies dealing with COVID-19 induced ALI in the ICU setting are rather limited. Accordingly, the present review aims to summarize relevant existing evidence regarding ALI in COVID-19 patients

hospitalized in the ICU and explore its clinical implications, while at the same time an attempt is made to elucidate the underlying pathophysiological mechanisms that contribute to the development of ALI in ICU patients, and to propose therapeutic approaches.

DEFINING ACUTE LIVER INJURY

A universal definition of ALI is still lacking. This poses significant challenges and oftentimes generates confusion among clinicians when referring to liver injury and trying to accurately interpret abnormal liver tests[21]. Based on the latest American College of Gastroenterology clinical guidelines for the evaluation of abnormal liver chemistries[22], markers of liver injury comprise routinely measured liver chemistries, namely aspartate transaminase (AST), alanine transaminase (ALT), alkaline phosphatase (ALP) and bilirubin, whereas markers of hepatocellular function include albumin, bilirubin and prothrombin time. Sometimes, elevation of gamma-glutamyl transferase (GGT) can be used as a supplement to confirm the hepatic origin of an elevated ALP level. According to the same guidelines [22], AST and/or ALT elevation is defined as borderline when values are less than 2-fold the upper limit of normal (ULN); mild when they are between 2 and 5 times the ULN; moderate when they are between 5 and 15 times the ULN; severe if they exceed 15 times the ULN; and massive in case they are above 10000 IU/L. Furthermore, in order to characterize the type of liver injury, the following categories have been proposed based on the proportion of elevated AST and ALT values as compared to ALP values: Hepatocellular injury (disproportionate elevation of AST/ALT), cholestatic injury (predominant elevation of ALP) and mixed pattern of injury (elevation of both AST/ALT and ALP levels). For this purpose, the R ratio has been used, which is derived from the formula $R = (\text{ALT value:ALT ULN})/(\text{ALP value:ALP ULN})$, whereby an R ratio > 5 indicates hepatocellular injury, an R value < 2 suggests cholestatic injury and an R value 2-5 is consistent with a mixed pattern of liver injury[22].

The lack of a uniform definition of ALI has led to the arbitrary use of different criteria for identifying ALI, which has resulted in great heterogeneity of reported research results. The adoption of diverse criteria by researchers, either for defining ALI or characterizing its pattern and severity, is also evident in the current literature regarding COVID-19 induced ALI. For instance, in a large retrospective United States cohort of COVID-19 patients, ALI was defined as any elevation of ALT and AST above normal and was subsequently classified, according to the degree of ALT elevation, as none/mild, moderate or severe when ALT values were less than 2-fold the ULN, between 2 and 5 times the ULN and more than 5-fold the ULN respectively[23]. On the other hand, Yip *et al*[24] defined ALI as an elevation of ALT and/or AST ≥ 2 times the ULN, with a concomitant increase of total bilirubin by more than 2-fold the ULN and/or international normalized ratio (INR) ≥ 1.7 [24], whereas Cai *et al*[25] defined liver injury either as an increase of ALT and/or AST ≥ 3 times the ULN or as a more than 2-fold increase of ALP, GGT and/or total bilirubin above the ULN[25]. Meanwhile, other researchers avoided the use of the term ALI and employed other general terminology instead, such as “liver test abnormalities” or “abnormal liver function tests”, to include any increase of at least one of AST, ALT, ALP, bilirubin and GGT above the ULN (as *per* local laboratory reference range standards) or even a reduction of albumin levels below normal cut-off values[26,27].

Based on the above, it is more than obvious that there is a wide discrepancy in the current COVID-19 literature with regard to ALI definition, thus rendering interpretation and comparison of results rather burdensome and obscure. On this account, it would be desirable for researchers to reach a consensus on a unifying definition in order to eliminate existing disparities.

EXISTING EVIDENCE

In the current COVID-19 literature there is a dearth of published clinical studies with an exclusive focus on COVID-19 induced ALI in ICU patients. Moreover, most of the available data on the topic are rather diverse owing to the lack of a uniform definition for liver injury, disparate thresholds applied for ALI, divergent study designs and different endpoints of each study.

The allegedly first study to explore the incidence, clinical characteristics and outcomes of ALI exclusively in ICU patients with COVID-19 was conducted in Germany and included 72 critically ill patients between March and July 2020[28]. The investigators used the term severe liver dysfunction and defined it as the occurrence of hypoxic liver injury (manifested by elevated aminotransferase levels > 20-fold the ULN in the setting of cardiac, circulatory or respiratory failure and after exclusion of other possible causes) and/or jaundice (total bilirubin ≥ 2 mg/dL). They found that 31% of the ICU patients developed severe liver dysfunction during their ICU stay approximately a week after ICU admission, predominantly in the form of cholestatic liver injury (45%) followed by equally contributing hepatocellular (27%) and mixed pattern injury (27%). Patients with severe liver dysfunction had a higher simplified acute physiology score II on admission, indicating a more severe clinical condition, as well as higher rates of viremia during their ICU stay. Severe liver dysfunction was associated with more severe respiratory failure, as manifested by more frequent development of ARDS and lower values of

Horowitz index, namely lower ratio of partial pressure of oxygen to fraction of inspired oxygen ($\text{PaO}_2/\text{FiO}_2$ ratio). Furthermore, patients with severe liver dysfunction were more likely to require mechanical ventilation (MV), circulatory support with vasopressors, renal replacement therapy and rescue therapy by means of veno-venous extracorporeal membrane oxygenation (ECMO). Accordingly, patients with severe liver dysfunction experienced higher mortality rates and, more importantly, severe liver dysfunction was found to be an independent predictor of mortality[28].

Along the same lines, Huang *et al*[29] conducted a retrospective study with the aim to investigate the prevalence of hypoxic hepatitis in 51 COVID-19 patients hospitalized in a Chinese ICU from December 2019 to March 2020[29]. They used the same definition of hypoxic hepatitis; that is, a massive but transient elevation of ALT levels > 20-fold the ULN in the setting of cardiac, circulatory or respiratory failure, after excluding other putative causes of ALI. Based on this terminology, hypoxic hepatitis was evident in 3 male patients, corresponding to 5.88% of all ICU patients, with peak ALT values being 1665, 1412 and 1140 U/L respectively. All 3 patients progressed to respiratory failure and eventually died due to multiple organ failure. When looking at the dynamic changes of liver enzymes, it was observed that ALT and AST elevations occurred at an earlier stage, while bilirubin levels increased sharply at a later stage when transaminase values had already started to show a downward trend after peaking in the third week. The authors came to the conclusion that hypoxic hepatitis was not an infrequent condition in ICU patients with severe COVID-19 and was accompanied by high mortality[29].

Meanwhile, Salik *et al*[30] conducted a study which included 533 COVID-19 patients admitted to the ICU with the aim to determine the impact of observed liver test abnormalities on mortality[30]. Liver injury was defined as ALT and/or AST levels above 3 times the ULN, and/or total bilirubin levels greater than 2-fold the ULN. Patients were divided into three groups: Group 1 consisted of patients with normal liver chemistries; Group 2 included patients with abnormal liver test values not falling into the category of liver injury; Group 3 comprised patients with liver injury. Any kind of liver test abnormality, reflected by groups 2 and 3, was observed in 52% of the total cohort and was more frequent in males. However, as *per* study's definition, only 8.6% of all ICU patients developed ALI, represented by group 3 alone. Paradoxically, the authors reported that patients with ALI and milder liver test abnormalities (groups 2 and 3) had shorter ICU lengths of stay compared with group 1, but this result is most likely attributed to the unacceptably high total mortality rates of patients belonging to these groups (71.4% and 78.3% for groups 2 and 3 respectively), which erroneously were not taken into account as confounding factors during the analysis. The authors concluded that liver test abnormalities were predictive of higher mortality, given that groups 2 and 3 experienced higher than expected 7-d, 28-d and total mortality rates[30].

A similar definition of ALI was employed by Arentz *et al*[31] who published the first case series of ICU patients with COVID-19 in the United States, dating back to February-March 2020[31]. A total of 21 patients were included. On ICU admission, abnormal liver tests were reported in 8 patients (38%) with one patient displaying very high levels of AST (4432 U/L) and ALT (1414 U/L). During the course of the disease, among patients who were mechanically ventilated, 3 (14.3%) developed ALI, defined as a more than 3-fold rise above the ULN in AST or ALT levels. No further details about ALI were provided by this study, since its focus was not on liver injury in the ICU, but rather its aim was to describe the clinical characteristics and outcomes in the initial ICU cases of COVID-19 patients in the United States [31].

Likewise, in a retrospective observational cohort study from France with 600 COVID-19 patients, 153 of whom required ICU hospitalization, it was reported that 9.8% of the ICU patients developed ALI, defined as AST levels higher than 3-fold the ULN[32]. ALI occurred more frequently in the ICU compared to common ward patients, as did most of the other extrapulmonary complications, like acute kidney injury, cardiovascular events and thromboembolic events. Data analysis demonstrated that factors associated with higher risk for ALI included age > 75 years, concomitant cancer, chronic cardiac disease, as well as higher levels of C-reactive protein (CRP), serum creatinine and hemoglobin[32].

Another retrospective observational study from China reported an 18.1% incidence of ALI in 83 ICU patients with COVID-19[33]. In this case, ALI was defined as an elevation of hepatic biomarkers more than 2-fold the ULN or as disproportionately elevated AST and ALT levels compared to ALP levels. However, the focus of this study was on acute gastrointestinal injury (defined as various grades of malfunction of the gastrointestinal tract) in critically ill patients with COVID-19 and not specifically on ALI; hence, no additional data on ALI were available. Nevertheless, since ALI could be considered one of the components of acute gastrointestinal injury, it could be assumed that the main study conclusions may also be applicable to ALI. The major findings of this study were that patients with worse grades of acute gastrointestinal injury had worse clinical severity features, while sequential organ failure assessment score, MV duration and white blood cell count arose as independent risk factors for the development of more severe acute gastrointestinal injury. What is more, these patients exhibited higher rates of both septic shock and 28-d in-hospital mortality[33].

In a case series examining the temporal evolution of blood liver tests in 20 consecutive ICU patients with COVID-19, liver injury was reported to be frequent, albeit transient and non-severe[34]. However, liver injury was ill-defined as any elevation of at least one liver test (AST, ALT, ALP, GGT, total bilirubin) above the ULN. Consequently, all 20 patients exhibited some form of liver injury during the first 10 d after ICU admission. Interestingly, only median levels of AST, ALT and GGT (but not bilirubin

or ALP) increased above the ULN, while only GGT showed pronounced elevations (≥ 3 -fold the ULN) with a peak on day 8 after ICU admission. Based on these findings, the researchers commented that late cholestasis was frequently observed[34].

In addition, Shousha *et al*[35] conducted a prospective cohort study in 547 Egyptian patients with COVID-19 in order to investigate the underlying prevalence and severity of liver and gastrointestinal disturbances, as well as their effect on disease outcomes[35]. Among patients who required ICU admission (122/547), 48.50% had elevated AST and 35.60% had elevated ALT. Elevated AST, but not ALT, levels were associated with increased mortality in univariate analysis. Moreover, patients admitted to the ICU displayed significantly higher hospital admission levels of fibrosis-4 index (FIB-4), which incorporates 4 variables (age, AST, ALT and platelet count) and is considered a predictive marker for significant liver fibrosis. Similarly high levels of FIB-4 were observed in severe COVID-19 cases and in non-survivors. In the multivariate analysis, FIB-4 score > 3.25 was a significant predictor of mortality. Unfortunately, no other specific ICU details could be extrapolated from this study, owing to the trial design and aim, which was not focused on ICU patients[35].

Based on the observation that black population in the United States had been disproportionately affected by COVID-19, Currier *et al*[36] investigated potential differences in outcomes between black and non-black patients with COVID-19 and elevated liver enzymes[36]. They included a total number of 8028 patients, out of whom 3937 patients had available liver test data for interpretation. The analysis demonstrated that 45% of both black and non-black patients exhibited elevations in their liver chemistries. Among black patients with liver test elevations, 46% were intubated compared to 34.8% of non-black patients with elevated liver enzymes. This study highlighted that black patients who had liver test abnormalities were more prone to ICU admission and intubation than non-black counterparts, who albeit run a significantly higher risk of death[36].

Besides, ALI has also been appreciated in the context of specific patient categories with a prior history of liver disease. In this perspective, a multicenter observational cohort study from the United States aimed to explore the prevalence and impact of COVID-19 induced ALI in liver transplant recipients of various races and ethnicities[37]. 112 adult liver transplant recipients with COVID-19 were included, 81 of whom required hospitalization. Among hospitalized patients, 30 (37%) were admitted to the ICU with the majority of them requiring MV and circulatory support with vasopressors. ICU patients were more likely to develop ALI, which was determined according to ALT values at the peak of COVID-19 and was defined as ALT levels greater than 2-fold the ULN. On multivariate analysis, use of vasopressors in the ICU was found to be an independent predictor of liver injury. Furthermore, ICU patients had a higher likelihood of having their immunosuppression therapy modified. However, reduction in immunosuppression was not associated either with ALI or with risk of mortality or graft rejection, in contrast to antibiotic administration which was related to increased risk for ALI. Overall, the presence of ALI independently predicted risk for ICU admission and mortality in liver transplant recipients with COVID-19[37].

Other than cohort studies, there have also been case reports regarding COVID-19 induced ALI in ICU patients. Of note, a case report from Italy highlighted a rare case of ALI progressing to acute liver failure and eventually death[38]. It involved 2 critically ill COVID-19 patients hospitalized in the ICU due to severe ARDS. The patients were treated with tocilizumab, as part of the anti-cytokine storm regimen, which however seemed to have aggravated the underlying COVID-19 immunosuppression, thus facilitating the development of opportunistic infections in the already immunocompromised patients. Indeed, a few days prior to their death, lab tests revealed Herpes simplex virus 1 viremia leading to fulminant hepatitis with dramatic increases in ALT, AST, bilirubin and INR levels and resulting in fatal outcomes for both patients[38].

Furthermore, one should bear in mind that within the spectrum of liver injury in COVID-19 patients lies the cholestatic pattern of liver injury, along with its late sequelae, such as the development of secondary sclerosing cholangitis in critically ill patients. In this regard, Bütikofer *et al*[39] described the incidence and severity of cholestatic liver injury in 34 ICU patients with COVID-19[39]. Cholestatic liver injury was termed mild if ALP and GGT levels were higher than 1.5-fold and 3-fold the ULN respectively, whereas it was considered severe in case the above abnormalities were accompanied by a concomitant elevation of total bilirubin levels more than 2-fold the ULN. The investigators reported that 59% of the ICU patients developed some degree of cholestasis (32% mild and 27% severe). Patients with severe cholestatic injury displayed a more complicated clinical course, required more intensified supportive treatment (in terms of vasopressor support, renal replacement therapy and ECMO) and had a more extended length of ICU stay. Moreover, 4 out of 9 patients with severe cholestatic injury developed secondary sclerosing cholangitis, eventually resulting in 2 deaths and 1 candidacy for liver transplantation. By the same token, irrespective of the degree of cholestasis, the vast majority of patients with pronounced elevations of ALT levels (> 10 -fold the ULN) developed untoward outcomes, progressing either to secondary sclerosing cholangitis or death[39].

From a similar perspective, on the grounds of a higher than expected incidence of cholangiopathies in critically ill patients with COVID-19, Wendel-Garcia *et al*[40] addressed the issue of drug-induced liver injury (DILI) in a prospective observational cohort of patients with COVID-19 associated ARDS[40]. They performed a post hoc analysis on 243 ICU patients who were on invasive MV, with the aim to investigate whether a causal relationship between the prolonged infusion of high-dose ketamine and the

occurrence of cholestatic liver injury existed. Acute cholestatic DILI was defined as ALP levels greater than 1.5-fold and GGT levels greater than 3-fold the ULN, whereas patients were deemed to have severe cholestatic liver injury in case a concurrent increase in bilirubin levels more than 2-fold the ULN was present. During their ICU stay, 114 patients developed cholestatic liver injury, 100 of whom had received long-term ketamine infusion, while severe cholestatic liver injury occurred in 33% of the latter. The analysis revealed a duration-effect and dose-effect relationship between ketamine infusion and bilirubin and ALP levels. In other words, prolonged duration of infusion and higher doses of ketamine were positively correlated with rising bilirubin and ALP levels. Interestingly, no such effect was observed with long-term infusion of propofol and sufentanil, even at high doses. The study clearly demonstrated an increased hazard of developing cholestatic liver injury in ICU patients who had received long-term ketamine infusion as a co-sedative agent; yet, no association between ketamine infusion and increased in-hospital mortality was depicted[40].

The aforementioned studies regarding the prevalence and clinical implications of COVID-19 induced ALI in ICU patients are summarized in [Table 1](#).

PATHOPHYSIOLOGY

The pathophysiology of ALI in COVID-19 patients hospitalized in the ICU has not been fully elucidated and still awaits to be unraveled, since the underlying mechanisms have not been sufficiently decoded and appear to be multifactorial in nature. So far, the scientific research conducted in the field has proposed several mechanisms that associate SARS-CoV-2 infection with ALI. These mechanisms may have direct or indirect impact on liver function. In fact, there seems to be a complex interplay among several distinct pathophysiological pathways implicated in the course of critically ill patients with COVID-19 ([Figure 1](#)). Presumably, these diverse pathophysiological mechanisms act in synergy and exert cumulative effects, since no single mechanism can completely explain the vast spectrum of liver involvement in ICU patients with COVID-19. It is worth noting that COVID-19 induced ALI can occur either in the context of an underlying liver disease, thus leading to decompensation of the preexisting state of equilibrium, or can manifest as a *de novo* nosological entity in “naïve” patients with no previous history of documented hepatic dysfunction[41-44].

Hypoperfusion

ICU patients represent a specific subgroup of patients with distinctive features. Hemodynamic instability is frequently encountered among patients hospitalized in the ICU setting, who therefore require administration of vasopressors or even inotropes, sometimes in particularly high doses. There are miscellaneous factors contributing to the observed hemodynamic instability of ICU patients, including hypovolemic, distributive, cardiogenic or obstructive shock, MV, sedation and drugs[45,46]. It is worth mentioning that in the COVID-19 era a specific cause leading to cardiogenic shock may be related to myocardial injury caused by SARS-CoV-2. Cardiovascular involvement in COVID-19 may manifest in the form of myocarditis and pericarditis, but also as arrhythmias, acute coronary syndromes and stress-induced cardiomyopathy. When severe, all of these cardiovascular manifestations may potentially lead to acute heart failure and shock, especially in vulnerable patients with pre-existing cardiovascular disease[47-49]. Regardless of the cause, hemodynamic instability results in decreased splanchnic blood flow, leading to inadequate blood supply to the liver and subsequent liver ischemia. The resultant decreased end-organ perfusion is exaggerated in cases of hypovolemia[50].

Moreover, in the setting of passive liver congestion due to right heart failure of various etiologies, the superimposed elevated hepatic venous pressures further impair hepatic circulation by reducing the gradient between portal and hepatic venous pressures, which primarily drives the flow within the portal venous system. On top of that, the liver autoregulatory mechanisms are disrupted and become maladaptive, while the hepatic arterial buffer system fails to sustain hepatic blood flow under conditions of low mesenteric perfusion and cannot compensate for the changes in liver blood supply caused by low blood pressure, thus placing the liver at risk for further ischemic injury[51,52].

It needs to be emphasized that, although vasopressors can have beneficial hemodynamic effects in terms of restoring and maintaining hemodynamic stability and supporting vital functions, they are not void of adverse effects, which can often be detrimental. Indeed, they can cause excessive vasoconstriction and hence impair tissue perfusion through reduction of blood flow in vasoconstricted vascular beds, while at the same time they may exert deleterious effects on cardiac, metabolic, microbiome and immune function[53-55].

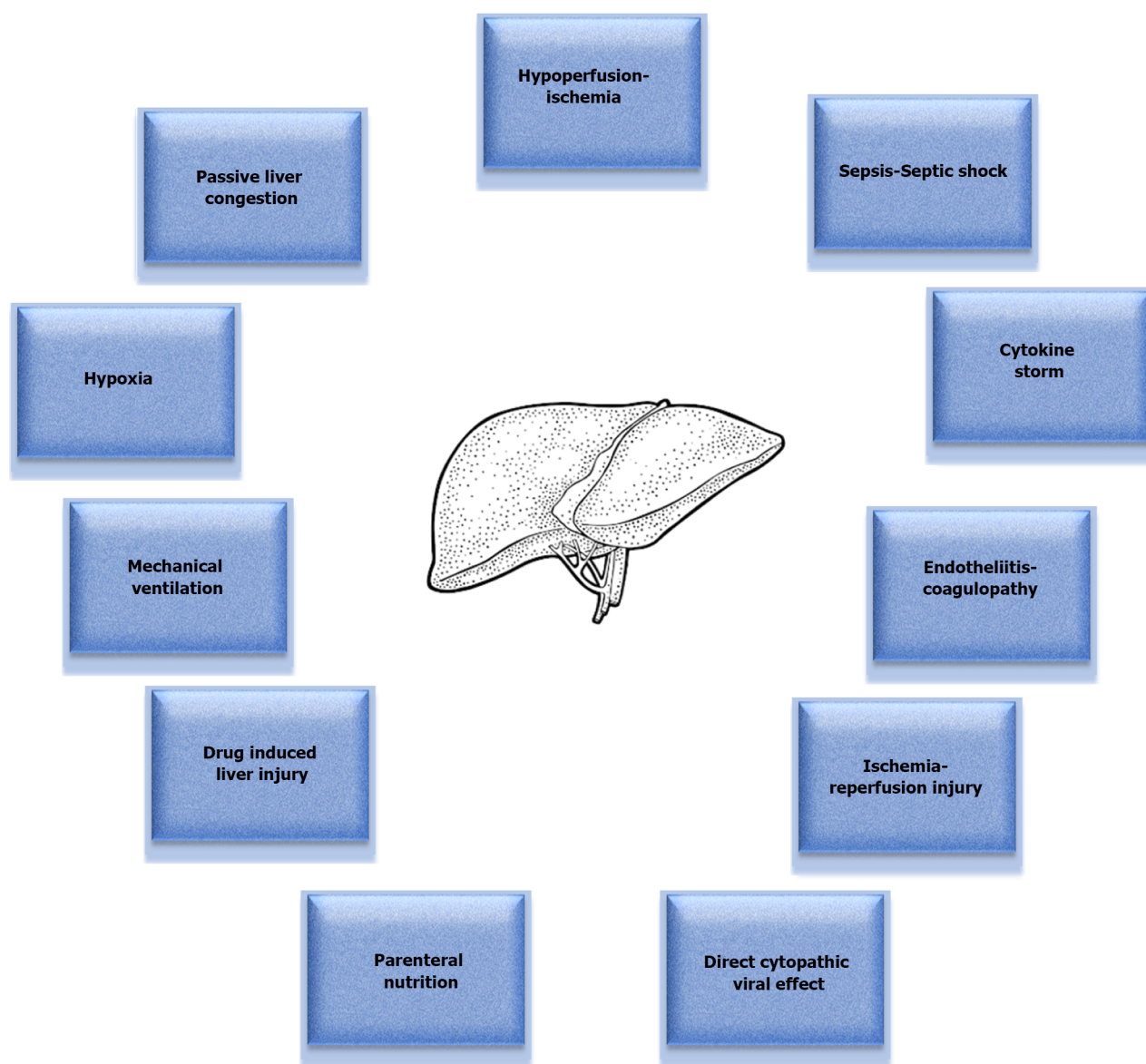
From a cellular standpoint, the sudden and profound reduction in systemic blood pressure, in conjunction with increased hepatic venous pressures, establish a low-flow state, which can result in the so-called hypoxic hepatocellular injury characterized by prominent centrilobular hepatocellular necrosis, since the central areas of the liver (commonly referred to as zone 3) are more susceptible to ischemic insults[51]. Mitochondrial damage and DNA fragmentation are the principal mechanisms implicated in the process of injury during hypoxic ALI, as evidenced by elevated plasma levels of glutamate dehydrogenase and cytochrome c oxidase mitochondrial DNA on the one hand and elevated

Table 1 Studies examining coronavirus disease 2019 induced acute liver injury in intensive care unit patients

Ref.	ALI definition	Number of ICU patients	ALI incidence	Major findings/outcomes
Roedl <i>et al</i> [28], 2021, Germany, Single-center, retrospective	↑ Transaminases > 20 × ULN or BIL ≥ 2 mg/dL	72	31%	ALI pts experienced higher mortality (83% for hepatocellular, 66% for mixed and 60% for cholestatic ALI), developed respiratory failure more frequently and had higher need for MV, ECMO, vasopressors and RRT
Huang <i>et al</i> [29], 2020, China, Single-center, retrospective	↑ALT > 20 × ULN	51	5.88%	ALI was not rare and was associated with high mortality due to MOF
Salik <i>et al</i> [30], 2021, Turkey, Single-center, retrospective	↑ALT/AST > 3 × ULN and/or ↑TBIL > 2 × ULN	533	8.6%	ALI pts had higher total, 7-d and 28-d mortality, as well as higher SOFA score. ALI was more frequent in males
Arentz <i>et al</i> [31], 2020, United States, Single-center, case series	ALT or AST levels > 3 × ULN	21	14.3%	67% mortality for the overall cohort, no mortality data for ALI pts. All ALI pts (3) were on MV. High rate of cardiomyopathy in the overall cohort
Martinot <i>et al</i> [32], 2021, France, Single-center, retrospective observational cohort	AST ≥ 3 × ULN	153	9.8%	Factors associated with higher risk for ALI: Age > 75, cancer, cardiac disease, higher levels of CRP, serum Cr and Hb
Sun <i>et al</i> [33], 2020, China, Single-center, retrospective observational	↑Serum levels of liver biomarkers (<i>e.g.</i> ALT) > 2 × ULN or disproportionate ↑ ALT/AST <i>vs</i> ALP	83	18.1%	The study focused on AGI, defined as various grades of malfunction of the GI tract, and not on ALI. Pts with worse AGI grades had higher 28-d mortality, higher incidence of septic shock and worse clinical variables
Cardoso <i>et al</i> [34], 2020, Portugal, Single-center, case series	Any elevation of at least one liver test (AST, ALT, ALP, GGT, TBIL) above ULN	20	100%	Liver injury was frequent, but transient and non-severe. Late cholestasis was mainly observed
Shousha <i>et al</i> [35], 2021, Egypt, Multi-center, prospective cohort	↑Transaminases > 3 × ULN	122 ICU pts. Overall cohort consisted of 547 pts	4.91% or 3.70% (based on AST or ALT levels respectively). Data represent overall (not ICU) pts cohort	FIB-4 on admission was significantly higher in pts admitted to the ICU, those with more severe COVID-19 and non-survivors. FIB-4 score > 3.25 and ICU admission were significant predictors of mortality
Currier <i>et al</i> [36], 2021, United States, Single-center, retrospective	ALT/AST > 60, ALP > 150, or BIL > 1.5	No data available for ICU pts. Overall cohort consisted of 8028 pts	45%. Data represent overall (not ICU) pts cohort	Black COVID-19 pts with liver test abnormalities were at greater risk for ICU admission and intubation compared to other races, but non-Black pts with liver test abnormalities were at increased risk of death
Rabiee <i>et al</i> [37], 2020, United States, Multi-center, observational cohort	ALT ≥ 2 × ULN (moderate: ALT 2-5 × ULN, severe: ALT > 5 × ULN)	30 ICU pts. Overall cohort consisted of 81 hospitalized LT recipients	34.6%. Data represent overall (not ICU) pts cohort	ALI was associated with higher risk for ICU admission and higher mortality. Hispanic ethnicity, metabolic syndrome, use of vasopressors, antibiotic use and younger age were independent risk factors for ALI. ICU pts were more likely to have their immunosuppression therapy modified
Roncati <i>et al</i> [38], 2022, Italy, Case report	N/A	2	100%	Fulminant herpetic hepatitis developed as a superimposed opportunistic infection due to tocilizumab-induced immunosuppression. Both pts died due to acute liver failure
Bütikofer <i>et al</i> [39], 2021, Switzerland, Single-center, retrospective cohort	Cholestatic ALI: ALP ≥ 1.5 × ULN and GGT ≥ 3 × ULN (termed severe if additionally TBIL ≥ 2 × ULN)	34	59% (27% severe)	Pts with severe ALI had higher mortality, significantly longer ICU stay with a more complicated course and required higher levels of support
Wendel-Garcia <i>et al</i> [40], 2022, Switzerland, Single-center, prospective observational cohort (post-hoc analysis)	Acute cholestatic liver injury: ALP > 1.5 × ULN and GGT > 3 × ULN (severe if additionally BIL > 2 × ULN)	243	47%	Pts who received ketamine had an increased risk of developing cholestatic liver injury than pts who didn't. Ketamine infusion demonstrated a dose-dependency and duration-dependency association with increasing BIL and ALP levels, but it was not associated with increased hospital mortality

AGI: Acute gastrointestinal injury; ALI: Acute liver injury; ALT: Alanine transaminase; ALP: Alkaline phosphatase; AST: Aspartate transaminase; BIL: Bilirubin; COVID-19: Coronavirus disease 2019; Cr: Creatinine; CRP: C-reactive protein; ECMO: Extracorporeal membrane oxygenation; FIB-4: Fibrosis-4 index; GI: Gastrointestinal; GGT: Gamma-glutamyl transferase; Hb: Hemoglobin; ICU: Intensive care unit; LT: Liver transplant; MOF: Multiple organ failure; MV: Mechanical ventilation; Pts: Patients; RRT: Renal replacement therapy; SOFA: Sequential organ failure assessment; TBIL: Total bilirubin; ULN: Upper limit of normal

Upper limit of normal.



DOI: 10.3748/wjg.v28.i47.6662 Copyright ©The Author(s) 2022.

Figure 1 Pathophysiological mechanisms implicated in the development of coronavirus disease 2019 acute liver injury in the intensive care unit setting. Figure 1 depicts the various pathophysiological mechanisms that come into play in the setting of coronavirus disease 2019 (COVID-19) infection, which eventually culminate in the development of acute liver injury (ALI) in intensive care unit (ICU) patients. Hypoperfusion and ischemia due to the frequently observed hemodynamic instability in the ICU patients play a major role in the process. Passive liver congestion as a result of congestive heart failure of various etiologies is another key determinant. The situation can be further aggravated by ischemia-reperfusion injury. Sepsis can also cause hepatic dysfunction, which is usually cholestatic in nature and reversible, but, when it progresses to septic shock, it results in multiple organ dysfunction syndrome and liver hypoperfusion, manifesting as shock liver. Besides, hypoxia due to respiratory failure and acute respiratory distress syndrome may also lead to ALI. Paradoxically, mechanical ventilation *per se* can exert deleterious effects on the liver through positive pressure ventilation, especially when accompanied by the application of high positive end-expiratory pressure and large tidal volumes. Furthermore, ALI can stem from the inflammatory cascade generated by the cytokine storm, while it can be further complicated by impaired microcirculation and thrombosis as a result of endotheliitis with concomitant coagulopathy. Drug-induced liver injury, as well as parenteral nutrition, must also not be overlooked as potential causative factors. Finally, liver injury could also be attributed to a direct cytopathic viral effect. There seems to be a complex interplay among these numerous underlying mechanisms, which may act either independently and cause COVID-19 induced ALI in the ICU setting, or more frequently synergistically and generate a relentless ALI vicious cycle.

circulating levels of nuclear DNA fragments on the other[56].

Even after restoring hemodynamic stability with the use of vasoactive drugs, it should be kept in mind that ischemia reperfusion injury may ensue, whereby reperfusion after prolonged ischemia can trigger a cascade of molecular mechanisms, paradoxically begetting further liver injury. This cascade of events involves the recruitment and activation of cellular mediators, the engagement of the complement

system, the generation of reactive oxygen species and the release of a wide variety of various cytokines, chemokines, adhesion molecules and other chemical mediators, which lead to microvascular alterations, acute inflammatory responses, derangements in microcirculation and increased hepatocellular apoptosis and necrosis[57].

Sepsis-Septic shock

In the ICU environment, sepsis represents a relentless plague with grave consequences for the critically ill patients, accounting for a significant proportion of the observed high morbidity and mortality rates. This becomes even more relevant for COVID-19 patients hospitalized in the ICU, given the fact that they require extended ICU stay with prolonged periods of invasive MV and vasopressor support, in the setting of a severely compromised immune system with a markedly dysregulated host response to infection. Sepsis may stem from multiple sources of infection and invariably results in organ dysfunction[58]. With regard to the liver, sepsis can cause hepatic dysfunction, which primarily manifests as sepsis-associated cholestatic dysfunction and to a lesser extent as hypoxic hepatitis. Sepsis, especially when caused by infections from gram-negative bacteria, increases intestinal permeability and results in endotoxin translocation from the intestinal lumen into the portal circulation. In the liver, endotoxins mount an inflammatory response through activation of Kupffer cells and macrophages, which results in secretion of proinflammatory cytokines[21,59]. This inflammatory reaction induces changes in the architecture and function of hepatocytes and cholangiocytes, leading to dysregulation of the liver metabolic signaling pathways, repression of the hepatobiliary transporter systems and decrease in canalicular contractility. All these result in bile acid retention with defective bile acid uptake, impaired bile production and secretion, inhibition of bile flow and formation of biliary sludge. The condition is further exacerbated by the impaired hepatic microcirculation due to sepsis-induced microvascular endothelial injury resulting in coagulopathy and microthrombi formation[21,60]. In the majority of critically ill patients, this type of cholestasis is reversible, but, in rare cases, destruction of the biliary epithelium due to ischemia and inflammation may cause irreversible biliary damage, progressing to secondary sclerosing cholangitis with formation of biliary casts and scarring of the bile ducts[60,61].

When sepsis culminates in septic shock, hemodynamic instability prevails, necessitating administration of vasopressors or inotropes[62]. Under these circumstances, the imminent end-organ hypoperfusion may eventually lead to shock liver in the context of multiple organ dysfunction syndrome. Indeed, the impaired hepatic perfusion leads to hypoxic hepatitis by causing direct hepatocellular injury. Despite the associated hyperdynamic state with increased cardiac output, septic shock is characterized by ongoing liver ischemia owing to impaired tissue oxygen extraction or, in other words, inability of hepatocytes to utilize oxygen. Once hepatocytes, especially those residing in the centrilobular regions of the liver, are deprived of oxygen, they start malfunctioning[21,63]. In fact, progressive tissue hypoxia promotes a catabolic state of anaerobic metabolism, suppresses mitochondrial energy production, compromises cellular membrane integrity due to loss of energy-dependent ion pumps and causes significant structural and functional abnormalities to hepatocytes[63]. The final result is direct hepatocellular damage, which is clinically described as hypoxic or ischemic liver injury and characterized by a massive, acute and transient rise in serum levels of aminotransferases[64].

Hypoxia

One of the cardinal features of COVID-19 critical illness is severe systemic hypoxia due to respiratory failure or ARDS[65]. Regardless of hemodynamic status, severe hypoxia *per se* can lead to ALI[66]. As a matter of fact, a pronounced and prolonged imbalance between oxygen supply and expenditure, secondary to profound hypoxia, can result in oxygen deprivation to the liver and thus trigger hypoxic hepatitis[64]. Hypoxia has long been implicated in the pathogenesis of liver diseases[67]. It has been shown that hypoxia induces alterations in gene expression by effectuating the activation of hypoxia-inducible factor 1 α and nuclear factor kappa B, which in turn stimulate angiogenesis, chronic inflammation and epithelial-mesenchymal transition. Accordingly, the activation of these transcriptional pathways promotes liver fibrosis and increases hepatic vascular resistance, thereby diminishing liver blood flow and further aggravating liver hypoxia[68].

In most ICU cases, hypoxia, the predominant characteristic of ARDS, mandates the use of invasive MV. During ARDS management, protective ventilation strategies are employed, which incorporate the use of low tidal volumes with permissive hypercapnia[69]. However, both hypoxia and hypercapnia have been known to induce pulmonary vasoconstriction, which in turn increases pulmonary vascular resistance and right ventricular afterload[70,71]. This may cause derangements in the subtle balance between the respiratory and cardiovascular system, eventually provoking cardiocirculatory instability, which sequentially establishes an even harsher hypoxic environment[71].

In view of the fact that severely hypoxemic patients require invasive MV, often with the application of high positive end-expiratory pressure (PEEP) levels, the strain imposed on the right ventricle by MV may elicit right ventricular failure and reduce venous return and right ventricular preload, thus further affecting hemodynamic stability[72,73]. These mechanical effects are aggravated in patients with ARDS or in mechanically ventilated patients with intrinsic PEEP due to dynamic hyperinflation. As a result, the clinical course of the patients may be complicated by acute cor pulmonale. Factors associated with a

higher risk for developing acute cor pulmonale include worse oxygenation, hypercapnia, high ventilator pressures and pneumonia-related ARDS[72].

MV

Owing to the fact that respiratory failure is the most frequent indication for ICU admission, the majority of ICU patients are mechanically ventilated. Although life-saving, MV may elicit untoward effects on the function of extrapulmonary organs, including the liver, *via* multiple interactions.

It has long been recognized that positive pressure ventilation can induce a decrease in cardiac output accompanied by a reduction in hepatic arterial blood flow, while high intrathoracic pressures can jointly incur increases in hepatic venous and inferior vena caval pressures. In parallel, liver compression by the descent of the diaphragm increases hepatic venous resistance and causes a rise in intravascular portal pressure. The constellation of these MV-triggered events can cause congestive hepatomegaly and induce hepatocellular dysfunction[74].

The aforementioned effects on liver hemodynamics can be further aggravated by the application of PEEP. Indeed, it is widely known from the literature that PEEP may increase the backpressure to liver venous outflow and cause an elevation in liver venous resistance, thus decreasing total venous return and resulting in hepatic blood pooling and liver congestion[75,76]. This decrease in venous return is further amplified in hypovolemic states[71]. Besides, in a study assessing risk factors for liver injury in critically ill patients, high levels of PEEP were found to promote hepatic dysfunction[77].

Furthermore, in a study by Schricker *et al*[78], it was found that PEEP affected liver metabolism by promoting hepatic gluconeogenesis and enhancing oxidative hepatic lipid utilization for energy coverage in the liver[78]. A parallel increase in the splanchnic oxygen extraction rate was reported in response to a decline in hepatic oxygen delivery caused by a PEEP-dependent decrease in cardiac output[78]. This mechanism has been corroborated by various human studies which have shown that increasing levels of PEEP reduced splanchnic blood flow, thereby jeopardizing oxygen delivery to the abdominal viscera; yet, splanchnic oxygen consumption was usually maintained through a compensatory increase in splanchnic oxygen extraction[79].

Moreover, the application of large tidal volumes during MV markedly increases pulmonary vascular resistance. In turn, the increased pulmonary vascular resistance may compromise the systolic performance of the right ventricle, since ejection will have to take place against an increased right ventricular afterload[71]. The ensuing right ventricular dysfunction will result in high right atrial pressures, which will then be transmitted backwards to the liver, causing hepatic congestion due to a retrograde increase in the pressures of the inferior vena cava and the hepatic veins[80].

Additionally, the use of high PEEP, high inspiratory pressures and high tidal volumes during MV may alter hepatosplanchnic perfusion by precipitating varying degrees of elevation in the intra-abdominal pressure[81-83]. As a matter of fact, MV, especially with high levels of PEEP, induces changes in pressure in the intra-abdominal compartment through transmission of increased intrathoracic pressures to the abdomen and downward displacement of the diaphragm. Should a sustained rise in intra-abdominal pressure occur, this can lead to an abdominal compartment-like syndrome, thus affecting abdominal venous return and causing a decline in cardiac output as a result of a marked decrease in right ventricular preload[84]. Concurrently, the resultant intra-abdominal hypertension may compromise liver perfusion and jeopardize the physiologic hepatic function by compressing the portal vein and causing intestinal congestion[85]. At the same time, the increased abdominal pressure is transmitted to the thoracic cavity, affecting lung volumes and respiratory mechanics and generating increases in peak inspiratory, plateau and mean airway pressures of the mechanically ventilated patients[86]. Accordingly, this may negatively affect cardiac and respiratory performance, potentially leading to cardiovascular collapse, which will further exacerbate the vicious cycle of poor tissue perfusion and organ dysfunction[84]. The clinical importance of this phenomenon may be further magnified by the presence of causal factors which predispose to additional elevations of intra-abdominal pressure, such as acidosis, coagulopathy, sepsis, MV, use of PEEP or presence of auto-PEEP, pneumonia, prone positioning, aggressive fluid resuscitation or increased severity scores[87].

Finally, MV *per se* can induce an early systemic inflammatory reaction, governed by an increased expression of soluble adhesive molecules and cytokines, along with a concomitant activation of the neurohumoral axis[88].

Collectively, it becomes evident from the above that MV may exert negative effects on liver function in terms of both mechanics and hemodynamics, as well as from a neurohumoral and metabolic perspective[89].

Cytokine storm

SARS-CoV-2 activates the host immune system at different levels and in varying degrees. In critically ill COVID-19 patients, the virus triggers an uncontrolled immune response, which results in a state of generalized overt inflammation. This overwhelming inflammatory reaction is termed cytokine storm and is heralded by the excessive production of proinflammatory cytokines on the grounds of a dysregulated immune system. During this chain of events, cytokines play a pivotal role in the inflammatory cascade triggered by SARS-CoV-2. Principal cytokines involved in the process include interleukin-6 (IL-6) and tumor necrosis factor-alpha (TNF- α). The excessive expression of proinflammatory cytokines,

chemokines and adhesion molecules attracts neutrophils, monocytes, macrophages and platelets, which further potentiate cytokine production. The resultant flooding of cytokines and chemokines poses a systemic stress on multiple organs, leading to tissue injury through activation of numerous signaling pathways. Ultimately, the severe systemic inflammatory response syndrome (SIRS) results in multi-organ failure. Of course, the liver is not spared throughout this process and sustains immune-mediated direct and indirect injury of varying magnitude[90-92].

It has been demonstrated that COVID-19 patients exhibit elevated levels of various inflammatory cytokines, such as IL-1 β , IL-2, IL-6, IL-10, TNF- α , interferon-gamma (IFN- γ), IFN- γ -inducible protein 10, granulocyte macrophage-colony stimulating factor and monocyte chemoattractant protein-1. What is more, some of these cytokines have been shown to correlate with the severity of COVID-19 disease course. Moreover, inflammatory infiltrates, indicative of immune-mediated injury, have been found to be present in numerous tissue samples of COVID-19 patients[93]. In addition, elevated levels of IL-6 and IL-10 and low counts of CD4+ T cells have been reported to be independent risk factors for development of ALI in COVID-19 patients[94]. All the above point towards the fact that an exaggerated immune-mediated response, generating an inflammatory cascade of events known as cytokine storm, plays a key role in the development of COVID-19 induced ALI.

Endotheliitis-coagulopathy

COVID-19 is considered a thrombotic disease which affects the vessel endothelium *via* inflammation and promotes endotheliitis, coagulopathy and thrombosis[95,96]. Indeed, endotheliitis seems to be the aftermath of the complex interplay between SARS-CoV-2 and the host immune response. SARS-CoV-2 initiates an inappropriate inflammatory response that triggers the overproduction of chemical mediators and mounts cell-mediated interactions with a subsequent burst of a cytokine storm. Activated immune cells bind to the adhesion molecules expressed on the surface of endothelial cells and generate an inflammatory state. The complex and sustained activation of cellular downstream signaling pathways mediated by pro-inflammatory cytokines drives SIRS, which affects the endothelium. The integrity of the endothelial barrier is compromised, thus promoting endothelial capillary leak and interstitial oedema. Normal endothelial function is also disrupted due to the production of free radicals, the reduction of nitric oxide (NO) levels and the decrease of the endothelial NO synthase activity. Through impairment of endothelial function, NO dysregulation and increased oxidative stress lead to maldistribution of microvascular blood flow, eventually resulting in abnormal vascular tone, attenuated endothelium-dependent vasodilation, compromised tissue oxygen delivery and tissue hypoxia[97,98]. In addition, dysfunctional endothelial cells may create a procoagulant milieu, by triggering fibrin formation as well as platelet adhesion and aggregation. These derangements alter local hemorheological conditions and promote microcirculatory stasis, microthrombi formation and capillary plugging. The generalized hypercoagulable state leads to maldistribution of tissue perfusion and microcirculatory ischemia, further aggravating tissue hypoxia[97]. The reduced peripheral perfusion due to the aforementioned endothelial dysfunction affects multiple systems and may result in multi-organ failure. The liver is not left intact throughout this process and subsequently ALI emerges[98,99].

DILI

ICU patients present several unique characteristics which render them much more susceptible to the development of DILI, compared to common ward patients. First of all, ICU patients typically have multiple co-morbidities and require treatment with numerous pharmacologic agents. Oftentimes, complex drug-combination strategies are employed in an attempt to cope with infections due to multi-drug resistant microorganisms[100]. However, polypharmacy exposes them to the risk of many potential drug-drug interactions[101]. Second, their ICU stay is usually prolonged, thus mandating long-course treatment[102]. Furthermore, due to their underlying critical condition, drug pharmacokinetics are substantially modified and are therefore unpredictable, increasing DILI risk[103]. Additionally, when considering the co-existence of other causes of liver injury that are almost invariably present in ICU patients with COVID-19, it becomes evident that the risk of DILI is further accentuated.

A variety of drugs used in the ICU for the treatment of COVID-19 patients could potentially lead to liver injury. Acetaminophen is a drug widely used in the ICU with well-documented hepatotoxic properties, which may confer liver injury even at lower than maximum daily recommended doses[104]. Besides, ICU patients with COVID-19, especially those with ARDS and on invasive MV, are particularly prone to bacterial infections and other opportunistic super-infections and are therefore treated with several antibiotics and antifungals. However, many of the antibiotics prescribed in the ICU carry an inherent risk of DILI, such as penicillins, cephalosporins, fluoroquinolones, macrolides and tetracyclines [105,106]. The same holds true for antifungal agents with triazoles demonstrating the highest potential for hepatotoxicity[106,107].

Furthermore, antiviral drugs used in the treatment of COVID-19 have been implicated in the development of ALI. The effect of antiviral treatment on liver function was studied in critically ill patients with COVID-19 in a retrospective cohort study and it was concluded that the overall use of antivirals was associated with increased risk of ALI[108]. Remdesivir is the sole antiviral drug currently approved for COVID-19 treatment, although its use and benefits are still under debate[109]. Early reports from studies examining compassionate use of remdesivir indicated that hepatotoxicity was

among one of the most frequent adverse events observed during remdesivir treatment. It manifested as an increase in transaminase levels, which resulted in discontinuation of the drug in some cases[110, 111]. A randomized, double-blind, placebo-controlled multicenter trial from China also reported increases in aminotransferase or bilirubin levels with remdesivir, sometimes leading to premature discontinuation of therapy[112]. However, the authors concluded that, overall, remdesivir was adequately tolerated and the serious adverse events tended to be lower in the remdesivir group than in the placebo group[112]. According to a systematic review and meta-analysis, the use of remdesivir frequently resulted in elevated transaminases with the incidence of DILI being 15.2% among COVID-19 patients receiving remdesivir[113]. Remdesivir was also found to confer an increased risk of ALI in a study analyzing data derived from Vigibase, a pharmacovigilance global database system available from the World Health Organization[114]. Indeed, the most frequently reported adverse effects related to remdesivir were increased liver enzymes, mainly transaminases and to a lesser extent bilirubin. Of note, most cases were deemed serious by virtue of requiring hospitalization or resulting in prolonged hospital stay[114]. Other studies have also shown that remdesivir can cause hepatocellular injury, but it seems that in most cases ALI is mild, asymptomatic and not clinically apparent; it is not associated with jaundice and does not progress to severe liver damage or failure, while it is characterized by low discontinuation rates and reversibility after discontinuation[115-119]. Nevertheless, remdesivir's use in the ICU is strictly limited in patients with severe COVID-19 who are not on MV[120].

Apart from antiviral drugs, immunomodulatory therapies have been put forward as therapeutic options for COVID-19. Tocilizumab, which is an anti-IL-6 receptor monoclonal antibody, is among the most utilized ones. It has been used in patients with respiratory deterioration and high oxygen requirements and has been associated with a reduction in mortality and need for intubation, when combined with corticosteroid use and administered early in the disease course[121-123]. However, its use has been associated with the development of a hepatocellular pattern of DILI, characterized by a mild to moderate elevation of transaminases in most cases[124-126]. The observed hepatotoxicity has been reported to be dose-dependent and generally transient[119]. Moreover, owing to the fact that tocilizumab induces immunosuppression, it should be used with caution, since it can increase the risk of infectious complications and may cause reactivation of hepatitis B virus (HBV) in patients with latent infections[127,128]. Thus, clinicians should always keep in mind that tocilizumab-induced ALI could also potentially arise from HBV reactivation[14].

Furthermore, low molecular weight heparins are among the most frequently used regimens in the ICU. Heparin-induced hepatotoxicity has been described in the literature, but is generally mild, transient and self-limited and does not warrant discontinuation of heparin therapy, which is an essential component of COVID-19 treatment[118,119,129-131]. Likewise, the use of systemic corticosteroids, which are routinely recommended in mechanically ventilated patients with COVID-19 and ARDS, has been rarely associated with DILI[119,120,132]. Moreover, amiodarone, which is frequently used in the ICU setting as an antiarrhythmic drug to terminate supraventricular and ventricular tachyarrhythmias, is well-known for its hepatotoxic effects and could thus contribute to the development of DILI[133].

Lastly, the use of anesthetic drugs deserves specific mention, since COVID-19 pandemic has posed unique challenges to intensivists with regard to sedative strategies. Oftentimes, achieving satisfactory and deep sedation in invasively mechanically ventilated patients has been proven problematic, since an inordinate resistance to standard sedative regimens has been typically observed. In order to overcome this impediment, ICU physicians have been compelled to resort to alternative methods of sedation[134]. As a result, ketamine has been increasingly used as a second-line anesthetic agent for long-term sedation, in combination with the standard course of sedative and analgesic treatment. However, there have been several reports associating the prolonged infusion of ketamine in high doses with cases of hepatotoxicity[40,135-138]. The resulting ALI manifests in the form of cholestatic liver injury, which may further progress to the development of secondary sclerosing cholangitis. In general, ketamine infusion requires prolonged period of administration and high total cumulative doses in order to exert its cholangiotoxic effect[40,135]. The postulated mechanism through which ketamine induces or exacerbates cholestatic liver injury includes bile stasis, which promotes the precipitation of the water-insoluble norketamine (the main active metabolite of ketamine) within the biliary tree, ultimately resulting in biliary tract dysfunction and leading to biliary strictures, biliary obstruction, cholangitis or even secondary biliary cirrhosis[40,136]. In brief, the blockade of the N-methyl-D-aspartate (NMDA) receptors in smooth muscle cells by ketamine favours bile stasis and bile duct dilation, while the ketamine-induced contraction of the sphincter of Oddi increases flow resistance within the biliary tree, thus further aggravating bile accumulation. Meanwhile, bile stasis is additionally exacerbated by gall bladder dyskinesia, which is caused by the ketamine-mediated blockade of NMDA receptors in the dorsal motor nucleus of the vagal nerve[40]. These phenomena collectively establish the ideal predisposing conditions for the precipitation of norketamine and the resultant biliary tract injury. Notably, the biliary system sustains multiple assaults, since the aforementioned sequential events act in concert with other COVID-19 related direct and indirect insults to the biliary tract, such as hypoxia, ischemia, hypoperfusion, hemodynamic instability, MV, SIRS or the virus SARS-CoV-2 itself[135,139,140].

Parenteral nutrition

Parenteral nutrition is often initiated in ICU patients in order to cover their metabolic demands in case of intolerance or contraindications to enteral feeding or whenever caloric targets are not met by enteral nutrition alone[141]. However, it has been demonstrated that ICU patients receiving total parenteral nutrition run a significantly greater risk of developing ALI than those receiving enteral nutrition[142]. Indeed, parenteral nutrition has been associated with liver injury, resulting in elevations of all liver enzymes, namely transaminases, ALP, GGT and bilirubin. Since parenteral nutrition by-passes the gut and results in decreased luminal content, it eliminates the hepatoprotective gut-derived signals, alters the enterohepatic circulation of bile acids and disrupts the normal crosstalk between the gut and the liver. Through various complex signaling pathways, parenteral nutrition causes cholestasis, steatosis, altered glucose and fat metabolism and hepatic fibrosis. Moreover, it interrupts gut mucosal integrity, causes derangements in the gut microbiota, promotes bacterial translocation and induces gut inflammation as well as increased cytokine release, all of which may contribute to further liver injury[143,144].

In addition, the lack of enteral feeding suppresses the secretion of cholecystokinin, gastrin and peptide YY. This leads to reduced intestinal motility, attenuated gallbladder contraction and decreased stimulation of bile flow, thus establishing the ideal environment for bacterial overgrowth, bile stasis, biliary sludging and subsequent bile duct obstruction. These conditions render the hepatocytes more susceptible to both direct and indirect toxic effects[144,145].

Besides, parenteral nutrition *per se* can be hepatotoxic through its components, mainly soy-derived phytosterols, manganese, aluminium and copper. Soybean oil-based lipid emulsions contain predominantly ω -6 polyunsaturated fatty acids which possess proinflammatory properties and lead to Kupffer cell activation, while phytosterols impede bile acid transport to the liver by antagonizing bile nuclear receptors. Furthermore, lipid emulsion infusion may be rarely complicated by fat overload syndrome with deleterious effects to the liver and other systemic organs[144,145].

Another potential risk of parenteral nutrition is energetic overfeeding, which increases the hazard for hepatobiliary complications[146]. Similarly, the strategy of combining parenteral with enteral nutrition, that may sometimes be employed to optimize nutritional intake in ICU patients, carries the risk of overfeeding, which predisposes to hepatic steatosis and hepatitis[141,145].

On the other side of the spectrum lies underfeeding of ICU patients, which may be related to various factors, such as feeding intolerance, hemodynamic instability, underestimation of caloric needs, frequent feeding interruptions due to diagnostic procedures or therapeutic interventions[147]. Underfeeding may contribute to a decrease in serum albumin concentration, which is a frequent underlying finding in ICU patients. Albumin levels reflect the liver's synthetic function and hypoalbuminaemia is associated with worse outcomes in critically ill patients[148].

Direct cytopathic viral effect

It has been postulated that ALI may be caused by direct viral invasion, infection and damage of hepatocytes. On this account, SARS-CoV-2 may exert direct cytopathic effects on hepatic cells, by causing lysis or promoting apoptosis and necrosis[18]. This hypothesis has been supported after identifying typical ultrastructural features and histopathological lesions of viral infection in postmortem liver biopsies of 2 cases with elevated transaminases[149]. However, the low expression level of angiotensin converting enzyme 2 (ACE2) receptors on the surface of hepatocytes, as opposed to the enriched ACE2 expression in cholangiocytes, could not support the theory of SARS-CoV-2 hepatotropism; instead, it rather implied that cholangiocytes could be targeted by SARS-CoV-2 or that alternative receptors on hepatocytes other than ACE2 could serve as the cell entry points of the virus[150]. Subsequent research revealed the presence of three SARS-CoV-2 interacting host receptors in different parts of the liver tissue, namely ACE2, transmembrane serine protease 2 and paired basic amino acid cleaving enzyme (FURIN), thus endorsing the possibility that SARS-CoV-2 may actually cause direct cytopathic injury to hepatocytes[151]. To date, the direct cytopathic viral effect has not been firmly established yet, whereas in the ICU setting this proposed mechanism does not seem to play a prominent role in the observed ALI.

It needs to be emphasized that, although there are several viruses displaying some form of hepatotropism, there may be considerable heterogeneity among them. This could be due to the fact that the immune responses mounted by the host against the virus may differ significantly depending on whether the virus is cytopathic or not, as well as on which immune evasion mechanisms are adopted by the virus, in conjunction with other factors, like impaired immunity or high viral load[92]. Furthermore, the pattern of the observed changes in transaminases during SARS-CoV-2 infection differs from the liver injury pattern of other epidemic viruses, which result in a much steeper curve of aminotransferase elevations owing to massive parenchymal necrosis[18].

Given that the mechanisms of COVID-19 induced ALI still remain largely unclear, our current understanding is limited with regard to the exact pathophysiology behind the liver injury caused by SARS-CoV-2 and how this differs or resembles the effects of other hepatotropic viruses. Even more so, data regarding the potential discrepancies in the hepatotropism of the different SARS-CoV-2 strains are lacking; hence, it would be intriguing for researchers to investigate the possible different effects that are exerted by different strains of SARS-CoV-2 on the liver and identify any associated variations in the

pathophysiology and clinical course of ALI.

LIVER HISTOPATHOLOGY IN COVID-19: IS THERE A LINK WITH PATHOPHYSIOLOGICAL MECHANISMS IN ALI?

It could be assumed that the underlying pathophysiological mechanism of ALI might be postulated based on the findings of pathological studies. However, such studies are generally inconclusive, since a firm and indisputable cause of liver injury cannot be safely deduced from histopathological reports.

As a matter of fact, histopathological findings from postmortem liver biopsy specimens have shown moderate microvesicular steatosis and mild lobular and portal activity[152]. These findings could be compatible either with direct SARS-CoV-2 infection of the liver or with DILI, but they are not conclusive in terms of supporting a definite cause of liver injury. Besides, the concomitant finding of overactivated T cells in the peripheral blood, with increased expression of proinflammatory markers and high concentration of cytotoxic granules, most likely points towards an immune-mediated injury rather than a direct cytopathic effect[152]. In another liver biopsy, the findings of mild vesicular steatosis and watery degeneration in some hepatocytes were attributed to ischemia and hypoxia, while the investigators also reported the presence of a few inflammatory cells in the hepatic sinuses, namely neutrophils, plasma cells and Kupffer cells[25].

Postmortem liver tissue biopsies from two COVID-19 cases with elevated transaminases have actually shown typical lesions of viral infection, suggestive of a direct cytopathic effect of SARS-CoV-2 on liver cells[149]. In particular, ultrastructural examination *via* transmission electron microscopy revealed that typical SARS-CoV-2 particles with corona-like spike structures were abundantly present in the cytoplasm of hepatocytes, indicating that the virus can both enter and replicate in hepatocytes. These infected hepatocytes showed cytopathic features, such as marked mitochondria swelling, endoplasmic reticulum dilation, decrease of glycogen granules and damage of the cell membrane. Histologically, plenty apoptotic hepatocytes were observed, as well as binuclear or a few multinuclear syncytial hepatocytes. Other findings included moderate microvesicular and mild macrovesicular steatosis, moderate focal lobular inflammation and mild portal inflammation with predominantly lymphocytic infiltrates[149].

Besides, in post-mortem needle core biopsies from livers, centrilobular sinusoidal dilation, mild lobular lymphocytic infiltration and patchy hepatic necrosis were mainly observed[153]. Sinusoidal dilation is a rather frequent non-specific finding observed in liver biopsies of terminally ill hospitalized patients and is often attributed to reduced venous outflow in the hepatic veins as a result of passive liver congestion in the setting of congestive heart failure[13].

Finally, an Italian study of 48 postmortem liver biopsies reported histopathological findings suggestive of diffuse vascular alterations characterized by marked derangement of the intrahepatic vasculature and varying degrees of occlusive thrombosis[154]. Specifically, there was an increase in the number of portal vein branches, coupled with severe luminal dilation and wall fibrosis. This proliferative process was accompanied by partial or complete luminal thrombosis of portal and sinusoidal vessels, portal vein endotheliitis and portal vein wall fibrosclerosis. Steatosis was also observed in more than half of the specimens, while SARS-CoV-2 was detected in most of the samples either within blood clots or in the cytoplasm of endothelial cells[154].

PREDISPOSING FACTORS FOR ALI

COVID-19 severity has been reported to be one of the main risk factors for the development of ALI in COVID-19 patients[155]. Indeed, in a systematic review and meta-analysis it was found that increasing levels of COVID-19 severity were associated with a higher risk of developing ALI and more pronounced gastrointestinal symptoms[156]. ICU patients are more prone to developing liver impairment. This was evidenced by a meta-analysis which reported that biomarkers of liver function were significantly elevated in patients with severe and fatal forms of COVID-19 and could potentially portend a progression towards multiple organ failure, when combined with other hematologic, biochemical and immunological biomarkers[157]. Besides, higher incidence of ALI has been observed in patients with more extensive pulmonary lesions on computed tomography (CT) imaging reflected by higher CT scores, which in turn correlate with COVID-19 clinical severity[158,159].

Furthermore, pre-existing liver disease has been recognized as a predisposing factor for ALI, especially in critically ill patients with COVID-19, given the fact that patients with pre-existing liver disease, particularly those with cirrhosis, run a greater risk of hospitalization and mortality[160]. Metabolic-associated fatty liver disease has been shown to be an independent predictor for the development of mild and moderate ALI[161]. Likewise, in another patient series, metabolic-associated fatty liver disease, together with high body mass index, prevailed in the majority of patients with persistent liver injury[162]. However, it still remains controversial whether metabolic-associated fatty

liver disease is also a marker of disease severity, progression and mortality[161,162]. Shao *et al*[163] reported that the presence of fatty liver disease was associated with a higher risk of ALI in COVID-19 patients, while the presence of cirrhosis incurred an increased risk of disease progression[163]. Along the same lines, in another single-center retrospective study from Shanghai, low liver CT density, suggestive of fatty infiltration and steatosis, was shown to be a risk factor of liver injury, together with COVID-19 severity, male sex and medications, such as lopinavir/ritonavir, glucocorticoids and thymopeptides[164].

In their multicenter study involving 112 liver transplant recipients, Rabiee *et al*[37] found that ALI was associated with a higher risk for ICU admission and higher mortality in COVID-19 liver transplant recipients[37]. Interestingly, when compared to a matched control group of non-transplant patients with chronic liver disease, the incidence of ALI was higher in patients with chronic liver disease (47.5%) than in liver transplant recipients (34.6%). On multivariate analysis, younger age, metabolic syndrome, Hispanic ethnicity, administration of vasopressors and antibiotic use emerged as independent risk factors for ALI. On the other hand, non-Hispanic white liver transplant recipients had a lower risk of ALI. With regard to immunosuppressants, reducing tacrolimus or withholding mycophenolate did not increase the risk of ALI, while acute cellular rejection occurred in only one patient of the cohort. Overall, it was concluded that reduction in immunosuppression therapy was not associated with ALI or risk of mortality, thus immunosuppression can be safely modified if deemed necessary[37].

Several prediction models have been proposed in order to estimate the risk of liver injury. For instance, it has been reported that a prediction model incorporating plateletcrit, retinol-binding protein and carbon dioxide combining power could sufficiently predict the occurrence of ALI in patients with moderate COVID-19 in a timely manner[165]. Another risk scoring system was proposed by Shao *et al* [163] with the intention to predict ALI risk, which included three variables upon admission, namely ALT, CRP and lactate dehydrogenase[163]. In the same study, the authors noted that male patients were more likely to develop ALI. Interestingly, the presence of hypertension was found to convey an increased risk of ALI only for patients without any prior liver disease, but not for patients suffering from pre-existing chronic liver disease[163].

In a prospective cohort study, male sex, older age, diabetes mellitus and lymphopenia emerged as independent risk factors that could predict liver dysfunction among COVID-19 patients[166]. Other investigators concluded that male sex, along with high D-dimers and high neutrophil percentage, were the most important risk factors that could predict the development of ALI in COVID-19 patients[167]. Similarly, it was demonstrated that male sex and CPR were independently associated with liver injury [168], while another study found that male sex, high levels of serum CRP and a high neutrophil to lymphocyte ratio were potential risk factors for ALI[169]. A subsequent systematic review and meta-analysis corroborated the above findings by confirming that male sex and low lymphocyte count were associated with ALI occurrence[170].

Male sex has almost invariably been associated with the risk of liver injury and the severity of the disease[166-170]. The observed discrepancy between the genders may be related to genetic and hormonal factors, which result in lower viral load levels, milder grades of inflammation and better immune responses in women than men[171].

Finally, metabolic syndrome, which is a constellation of hypertension, hyperglycemia, dyslipidemia and obesity, has also been proposed as a predisposing factor for ALI[172]. In a recent retrospective cohort study, being overweight was a risk factor for liver injury, whereas obesity was associated with severe liver injury[173].

THERAPEUTIC STRATEGY

It should be emphasized that no specific therapy for COVID-19 induced ALI exists. Therefore, the therapeutic approach initially lies in prevention and is exclusively supportive once ALI ensues.

In the ICU setting, the main pillar of the overall ALI therapeutic strategy for critically ill COVID-19 patients consists of preventive measures. First and foremost, a detailed medical history should be obtained. This should include a comprehensive review of the medical background for concomitant liver diseases, other underlying comorbidities, use of drugs in the near past that are known to induce ALI, or exposure to alcohol, herbs and chemicals[22]. Next, high level of clinical vigilance is warranted. ICU physicians should perform meticulous clinical examination on a regular daily basis, or even at repeated intervals throughout the day if deemed necessary, in order to check for and recognize early signs and symptoms of impending organ dysfunction. In parallel, COVID-19 patients should have regular lab tests performed to closely monitor liver enzymes and promptly identify any potential liver test abnormalities.

Among the precautionary measures to avoid ALI, prompt restoration of central hemodynamics is of paramount importance, since it will allow the hemodynamic stabilization of the patient in due time and prevent liver ischemia. In patients with hemodynamic instability, fluid resuscitation constitutes the mainstay of treatment in the attempt to restore hypovolemia. In general, a conservative over a liberal fluid strategy is advocated in critically ill COVID-19 patients with shock, provided that hypovolemia

has been addressed. Caution should be exercised so as to avoid volume overload, especially in patients with cardiac dysfunction. In order to achieve optimal loading conditions, a multimodal approach should be adopted, whereby fluid resuscitation should be guided by physical examination, follow-up of vital signs, lactate levels, dynamic parameters and point-of-care ultrasonography[120]. It has been proposed that a systematic approach incorporating focused echocardiography, lung scanning and abdominal ultrasound may facilitate the bedside evaluation of cardiac function, volume status and fluid responsiveness, while at the same time it can aid in the differential diagnosis of an undifferentiated shock, as well as in the detection of biliary or hepatic sepsis, intraabdominal fluid collection and other acute pathologies[174-176].

When hemodynamic stability is not achieved after fluid resuscitation, the administration of vasopressors is indicated. Norepinephrine should be the first-line vasopressor, while vasopressin is recommended as a second-line agent if hemodynamic status does not improve. In case of persistent hypoperfusion despite adequate fluid loading and use of vasopressors, initiation of intravenous inotropes, preferably dobutamine, is advised, particularly if there is evidence of cardiac dysfunction. Excessively high doses of vasopressors and inotropes should be avoided. Titration of vasoactive agents should generally target a mean arterial pressure of 60-65 mmHg. The ultimate goal is to achieve and maintain adequate end-organ perfusion by restoring arterial pressure and optimizing cardiac output [120].

Furthermore, increased awareness is warranted for the early identification and management of sepsis. Immediate control of the source of sepsis is crucial, along with the optimization of the patient's hemodynamic profile. Prompt and appropriate antibiotic therapy is the cornerstone in the management of patients with sepsis. In case of suspected infection, ICU physicians should start early antibiotic treatment, initially with an empiric broad spectrum antibiotic and subsequently modify antimicrobial therapy according to culture results and susceptibilities, by de-escalating or changing to a narrow spectrum antimicrobial which targets the specific pathogen[177]. The appropriate antibiotic regimen should be selected with caution, as several common antibiotic agents may carry a high risk for ALI or other adverse events. Moreover, the clinicians should be aware of drug-drug interactions and be alert for potential hepatotoxicity reactions[178]. In any case, judicious antibiotic stewardship is highly recommended.

Besides, the importance of using pharmacologic thromboprophylaxis in critically ill patients cannot be overemphasized. As a matter of fact, thromboprophylaxis is strongly recommended in the recently published surviving sepsis campaign guidelines on the management of adults with COVID-19 in the ICU[120].

Hypoxia should be consistently addressed and corrected by administering the minimum amount of supplemental oxygen that will achieve a target of peripheral oxygen saturation (SpO₂) between 92% and 96%. Regarding patients who are on invasive MV, specific attention ought to be paid to the implementation of lung-protective ventilation strategies. Low tidal volumes (4-8 mL/Kg of predicted body weight) should be applied, coupled with a target of plateau pressure < 30 cm H₂O and a driving pressure < 14 cm H₂O[120]. It should be emphasized that the volume- and pressure- limited ventilation strategy may lead to hypercapnia. Despite the fact that the strategy of permissive hypercapnia is frequently adopted in the ICU, clinicians should bear in mind that hypercapnia, combined with persistent hypoxia which is frequently observed in ARDS patients with COVID-19, may cause profound pulmonary arterial vasoconstriction, increase right ventricular afterload and jeopardize hemodynamic status with grave consequences for the liver[69,177]. It should also be noted that oftentimes ventilatory management needs to be individualized, given that different patient profiles exist with diverse lung mechanics and discrepant responses to a certain ventilatory strategy[179]. In these cases, the ventilatory approach will need to diverge from the conventional form of ventilation in ARDS. Along these lines, although a higher over a lower PEEP strategy is generally recommended in ARDS, clinicians should avoid using very high PEEP, since this could compromise right ventricular function and adversely affect liver function. Thus, close monitoring is advised so that impending cardiopulmonary deterioration is promptly recognized[179]. Furthermore, appropriate ventilator settings should be meticulously adjusted in order to minimize or prevent auto-PEEP, which can further aggravate right ventricular performance[72]. Prone positioning for 12-16 h *per* day is also recommended as a measure to improve hypoxia[120]. In cases of severe hypoxia with persistent patient-ventilator dyssynchrony or persistently elevated plateau pressures, neuromuscular blocking agents should be employed either as intermittent boluses or continuous infusions, as needed[120]. Finally, after other options have failed to enhance oxygenation, it is reasonable to apply rescue strategies. Alveolar recruitment maneuvers could be used with caution and under close monitoring for barotrauma and cardiovascular collapse, while a trial of an inhaled pulmonary vasodilator might also be attempted[120]. In cases of refractory ARDS with or without hemodynamic shock, veno-venous ECMO might be considered as a last resort to improve oxygenation and restore hemodynamic stability[120,179]. It is also considered prudent to monitor intra-abdominal pressure for potential persistent MV-related increases and address accordingly[86].

Besides, specific attention should be paid to sedation practices used in the ICU setting. If possible, administration of multiple sedative agents should be avoided in order to decrease potential risk of side-effects and drug-drug interactions. Moreover, sedatives should be titrated to the lowest effective doses and should not be administered for prolonged duration[134]. Daily sedation intervals should be applied

when appropriate[180]. Regarding ketamine, a strategy of withholding use of this agent is generally advised due to its reported adverse effects. If used, ketamine should be administered at the lowest possible doses and for brief time periods[135,136].

Nutritional status should be regularly assessed and early enteral nutrition should be initiated[181]. Parenteral nutrition should be refrained and used only in cases where enteral nutrition is not possible or contraindicated[181,182]. Caution should be exercised in order to avoid under- or over-feeding. Any nutrient deficiencies should be replaced[181]. Glycemic control should be optimized. Provided that it does not cause hypoglycemic episodes, early and intensive intravenous insulin therapy is encouraged in the ICU setting, since it reduces the risk of cholestatic liver dysfunction and the formation of biliary sludge[183,184].

In the event of ALI occurrence, every effort should be focused on restraining its progression and thus minimizing any ALI-associated consequences. Once ALI arises, it is important to seek and recognize the underlying etiology and address the responsible precipitating factor in a timely fashion. Currently, there are no specific therapies that mitigate or reverse COVID-19 induced ALI. Nevertheless, prompt diagnosis of ALI and initiation of supportive treatment is crucial. In cases of mild or moderate ALI, general supportive measures with close monitoring of liver chemistries should suffice and, in most cases, ALI will eventually subside[185].

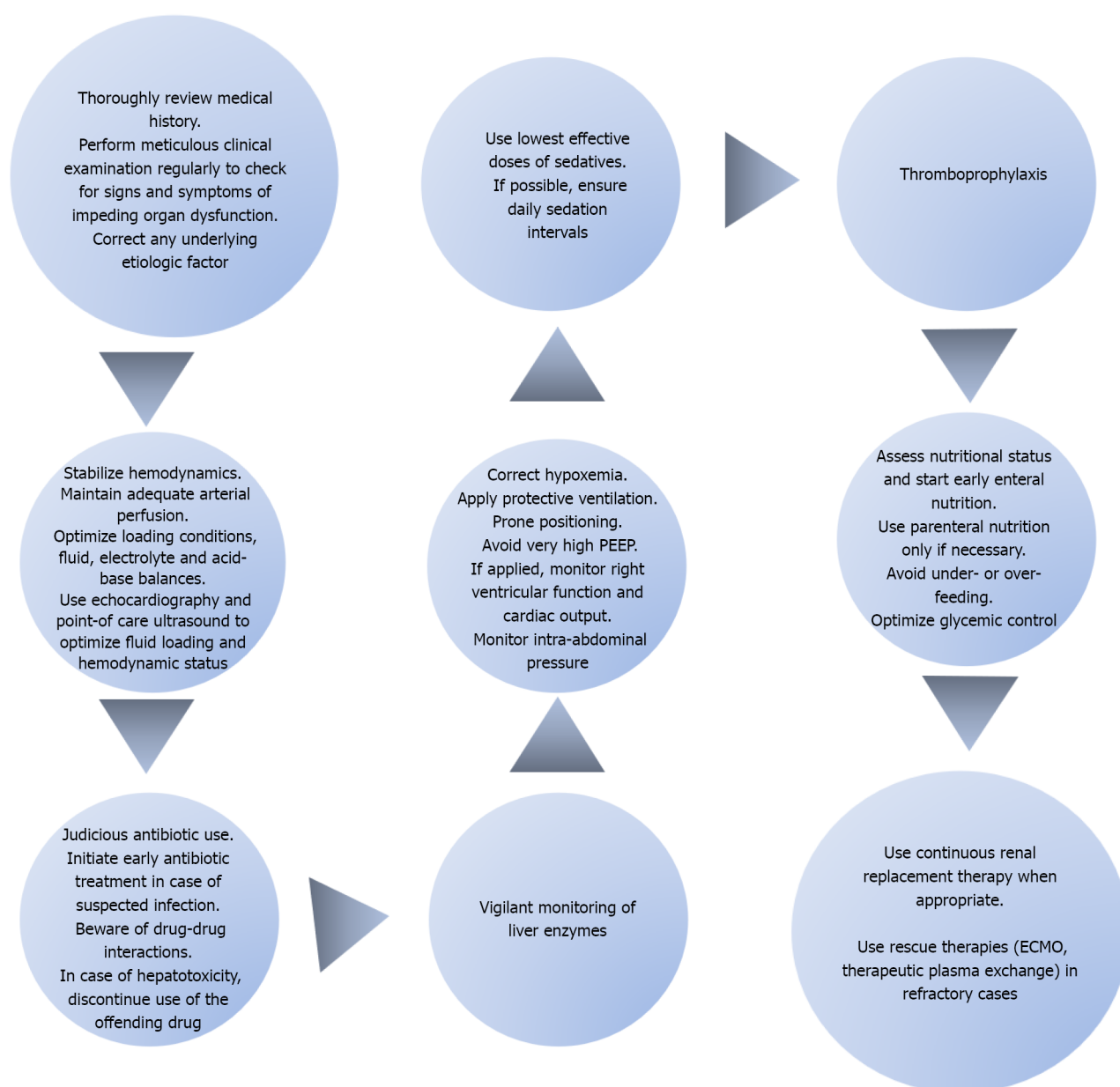
Infrequently, cases of severe ALI may occur. In such a scenario, supportive treatment should aim at preserving liver perfusion and microcirculation, by optimizing circulatory and respiratory conditions, relieving liver congestion, restoring electrolyte and acid-base balances and eliminating any underlying precipitating factor. If DILI is suspected, the administration of the causative pharmacologic agent should be discontinued[178]. Time of withdrawal of the culprit hepatotoxic factor is of major importance; hence, high level of clinical awareness is advised along with vigilant monitoring of liver enzymes[185]. With regard to acetaminophen toxicity, therapy with N-acetylcysteine should be promptly instituted by administering either an intravenous or an oral acetylcysteine regimen[186].

During the COVID-19 pandemic, the notion of continuous renal replacement therapy as a blood purification method to combat cytokine storm has been revived. In COVID-19 clinical practice, continuous renal replacement therapy can be used for septic patients with volume overload, patients with severe metabolic acidosis and those with electrolyte disturbances or progressive azotemia. Apart from its well-established indications, it has been proposed that continuous renal replacement therapy might have a potential role in critical COVID-19 cases with an excessive cytokine storm by removing cytokines and other inflammatory mediators[187,188]. Therapeutic plasma exchange has also been put forward as a promising adjunctive rescue therapy in the battle of COVID-19 critical illness, which could mitigate cytokine storm effects and thus reverse end-organ failure[189,190]. Finally, ECMO has been used as a salvage therapy for both respiratory and circulatory support[191].

Figure 2 depicts the steps of the therapeutic approach that should be consistently followed and addressed by ICU physicians both for the prevention and treatment of COVID-19 induced ALI.

CONCLUSION

Despite the conflicting estimates of its prevalence, ALI represents a common and often under-recognized complication of COVID-19 in ICU patients that deserves more clinical attention, considering the fact that it is intertwined with significant clinical ramifications and poor patient outcomes. COVID-19 induced ALI may present with varying degrees of clinical severity. Increased clinical vigilance is therefore advised, since it can easily be overlooked. In the ICU setting, several pathophysiological mechanisms may be implicated in the development of COVID-19 induced ALI. These may act either independently or more frequently synergistically. In the latter case, the effect exerted on the liver is cumulative, thus increasing the severity of ALI. Therefore, it is of utmost importance for ICU clinicians to ensure that they consistently comply with certain predefined bundles of preventive and therapeutic measures in order to alleviate the burden of COVID-19 associated ALI in ICU patients. Ongoing research on the particular scientific field will further elucidate the pathophysiology behind ALI and address unresolved issues, in the hope of mitigating the tremendous health consequences imposed by COVID-19 on ICU patients.



DOI: 10.3748/wjg.v28.i47.6662 Copyright ©The Author(s) 2022.

Figure 2 Steps of the intensive care unit therapeutic approach in patients with coronavirus disease 2019 induced acute liver injury. The intensive care unit (ICU) therapeutic approach for coronavirus disease 2019 patients with acute liver injury (ALI) lies in preventive measures and is exclusively supportive once ALI ensues. After obtaining a detailed medical history, a thorough physical examination should be performed on a regular basis. Upon recognition of any signs of impending liver dysfunction, the possible etiologic factor should be systematically sought and appropriately addressed. Hemodynamic stabilization of the patient is of paramount importance. The goal is to maintain adequate arterial perfusion in order to prevent liver ischemia. The use of echocardiography and point-of-care ultrasonography will help determine the hemodynamic status and optimize loading conditions. It is important to constantly maintain fluid, electrolyte and acid-base balances. Furthermore, early identification and management of sepsis cannot be overemphasized. Prompt initiation of appropriate antibiotic therapy is the mainstay of sepsis management. Antibiotics should be used judiciously with an increased level of awareness for possible drug-drug interactions. In case of hepatotoxicity, the administration of the responsible pharmacologic agent should be discontinued. Close monitoring of liver enzymes is advised at all times. Furthermore, hypoxia should be consistently addressed and corrected. In mechanically ventilated patients, a lung-protective ventilation strategy should be implemented with the use of low tidal volumes coupled with a target of plateau pressure < 30 cm H₂O. The application of very high positive end-expiratory pressure should be avoided because it could compromise right ventricular performance and precipitate passive liver congestion. Moreover, prone positioning is recommended in order to improve hypoxia. Intra-abdominal pressure should also be monitored so as to prevent any potential increases related to mechanical ventilation which could jeopardize liver function. Additionally, optimal sedation strategies should be applied with the lowest effective doses and daily sedation intervals. Thromboprophylaxis is strongly recommended as a preventive measure in all ICU patients. Besides that, nutritional status should be regularly assessed and efforts should focus on initiating early enteral feeding while avoiding parenteral nutrition. Under- or over-feeding should be avoided and glycemic control should be optimized. Finally, renal replacement therapy can be used whenever indicated. In refractory cases, rescue therapies may be employed with the use of extracorporeal membrane oxygenation and therapeutic plasma exchange in an attempt to provide circulatory and respiratory support and reverse end-organ failure. PEEP: Positive end-expiratory pressure; ECMO: Extracorporeal membrane oxygenation.

FOOTNOTES

Author contributions: Ventoulis I conceived and designed the study; Amoiridou P and Polyzogopoulou E contributed to the data acquisition, analysis and interpretation, drafted the manuscript with input from Abraham TP and Ventoulis I; Polyzogopoulou E contributed to the final layout of the table and figures; Abraham TP performed language editing of the manuscript; Abraham TP and Ventoulis I performed editing and critical revision of the manuscript; Polyzogopoulou E, Amoiridou P, Abraham TP and Ventoulis I approved the final version of the article.

Conflict-of-interest statement: All the authors report no relevant conflicts of interest for this article.

Open-Access: This article is an open-access article that was selected by an in-house editor and fully peer-reviewed by external reviewers. It is distributed in accordance with the Creative Commons Attribution NonCommercial (CC BY-NC 4.0) license, which permits others to distribute, remix, adapt, build upon this work non-commercially, and license their derivative works on different terms, provided the original work is properly cited and the use is non-commercial. See: <https://creativecommons.org/licenses/by-nc/4.0/>

Country/Territory of origin: Greece

ORCID number: Effie Polyzogopoulou 0000-0001-7585-1203; Pinelopi Amoiridou 0000-0001-9264-8215; Theodore P Abraham 0000-0003-3411-1334; Ioannis Ventoulis 0000-0002-7572-4527.

S-Editor: Fan JR

L-Editor: A

P-Editor: Fan JR

REFERENCES

- Zhu N, Zhang D, Wang W, Li X, Yang B, Song J, Zhao X, Huang B, Shi W, Lu R, Niu P, Zhan F, Ma X, Wang D, Xu W, Wu G, Gao GF, Tan W; China Novel Coronavirus Investigating and Research Team. A Novel Coronavirus from Patients with Pneumonia in China, 2019. *N Engl J Med* 2020; **382**: 727-733 [PMID: 31978945 DOI: 10.1056/NEJMoa2001017]
- Khalifa SAM, Swilam MM, El-Wahed AAA, Du M, El-Seedi HHR, Kai G, Masry SHD, Abdel-Daim MM, Zou X, Halabi MF, Alsharif SM, El-Seedi HR. Beyond the Pandemic: COVID-19 Pandemic Changed the Face of Life. *Int J Environ Res Public Health* 2021; **18** [PMID: 34070448 DOI: 10.3390/ijerph18115645]
- Fairman KA. Pandemics, policy, and the power of paradigm: will COVID-19 lead to a new scientific revolution? *Ann Epidemiol* 2022; **69**: 17-23 [PMID: 35231588 DOI: 10.1016/j.annepidem.2022.02.005]
- Mallah SI, Ghorab OK, Al-Salmi S, Abdellatif OS, Tharmaratnam T, Iskandar MA, Sefen JAN, Sidhu P, Atallah B, El-Lababidi R, Al-Qahtani M. COVID-19: breaking down a global health crisis. *Ann Clin Microbiol Antimicrob* 2021; **20**: 35 [PMID: 34006330 DOI: 10.1186/s12941-021-00438-7]
- Otto SP, Day T, Arino J, Colijn C, Dushoff J, Li M, Mechai S, Van Domselaar G, Wu J, Earn DJD, Ogden NH. The origins and potential future of SARS-CoV-2 variants of concern in the evolving COVID-19 pandemic. *Curr Biol* 2021; **31**: R918-R929 [PMID: 34314723 DOI: 10.1016/j.cub.2021.06.049]
- Chavda VP, Patel AB, Vaghasiya DD. SARS-CoV-2 variants and vulnerability at the global level. *J Med Virol* 2022; **94**: 2986-3005 [PMID: 35277864 DOI: 10.1002/jmv.27717]
- Peramo-Álvarez FP, López-Zúñiga MÁ, López-Ruz MÁ. Medical sequels of COVID-19. *Med Clin (Engl Ed)* 2021; **157**: 388-394 [PMID: 34632064 DOI: 10.1016/j.medcle.2021.04.008]
- COVID-19 Excess Mortality Collaborators. Estimating excess mortality due to the COVID-19 pandemic: a systematic analysis of COVID-19-related mortality, 2020-21. *Lancet* 2022; **399**: 1513-1536 [PMID: 35279232 DOI: 10.1016/S0140-6736(21)02796-3]
- Zaman MS, Sizemore RC. Diverse Manifestations of COVID-19: Some Suggested Mechanisms. *Int J Environ Res Public Health* 2021; **18** [PMID: 34574709 DOI: 10.3390/ijerph18189785]
- Long B, Carius BM, Chavez S, Liang SY, Brady WJ, Koyfman A, Gottlieb M. Clinical update on COVID-19 for the emergency clinician: Presentation and evaluation. *Am J Emerg Med* 2022; **54**: 46-57 [PMID: 35121478 DOI: 10.1016/j.ajem.2022.01.028]
- Rosen HR, O'Connell C, Nadim MK, DeClerck B, Sheibani S, DePasquale E, Sanossian N, Blodgett E, Angell T. Extrapulmonary manifestations of severe acute respiratory syndrome coronavirus-2 infection. *J Med Virol* 2021; **93**: 2645-2653 [PMID: 33090515 DOI: 10.1002/jmv.26595]
- Cho J, Lee J, Sia CH, Koo CS, Tan BY, Hong W, Choi E, Goh X, Chai L, Chandran NS, Chua HR, Chan BP, Muthiah M, Low TT, Yap ES, Lahiri M. Extrapulmonary manifestations and complications of severe acute respiratory syndrome coronavirus 2 infection: a systematic review. *Singapore Med J* 2021 [PMID: 34544216 DOI: 10.11622/smedj.2021100]
- Li Y, Xiao SY. Hepatic involvement in COVID-19 patients: Pathology, pathogenesis, and clinical implications. *J Med Virol* 2020; **92**: 1491-1494 [PMID: 32369204 DOI: 10.1002/jmv.25973]
- Saviano A, Wrensch F, Ghany MG, Baumert TF. Liver Disease and Coronavirus Disease 2019: From Pathogenesis to Clinical Care. *Hepatology* 2021; **74**: 1088-1100 [PMID: 33332624 DOI: 10.1002/hep.31684]
- Huang YK, Li YJ, Li B, Wang P, Wang QH. Dysregulated liver function in SARS-CoV-2 infection: Current understanding and perspectives. *World J Gastroenterol* 2021; **27**: 4358-4370 [PMID: 34366609 DOI: 10.3748/wjg.v27.i27.4358]
- Wu ZH, Yang DL. A meta-analysis of the impact of COVID-19 on liver dysfunction. *Eur J Med Res* 2020; **25**: 54 [PMID: 33332624 DOI: 10.1002/hep.31684]

- 33148326 DOI: [10.1186/s40001-020-00454-x](https://doi.org/10.1186/s40001-020-00454-x)]
- 17 **Omar AS**, Kaddoura R, Orabi B, Hanoura S. Impact of COVID-19 pandemic on liver, liver diseases, and liver transplantation programs in intensive care units. *World J Hepatol* 2021; **13**: 1215-1233 [PMID: [34786163](https://pubmed.ncbi.nlm.nih.gov/34786163/) DOI: [10.4254/wjh.v13.i10.1215](https://doi.org/10.4254/wjh.v13.i10.1215)]
 - 18 **Cichoż-Lach H**, Michalak A. Liver injury in the era of COVID-19. *World J Gastroenterol* 2021; **27**: 377-390 [PMID: [33584070](https://pubmed.ncbi.nlm.nih.gov/33584070/) DOI: [10.3748/wjg.v27.i5.377](https://doi.org/10.3748/wjg.v27.i5.377)]
 - 19 **Yang RX**, Zheng RD, Fan JG. Etiology and management of liver injury in patients with COVID-19. *World J Gastroenterol* 2020; **26**: 4753-4762 [PMID: [32921955](https://pubmed.ncbi.nlm.nih.gov/32921955/) DOI: [10.3748/wjg.v26.i32.4753](https://doi.org/10.3748/wjg.v26.i32.4753)]
 - 20 **Tian D**, Ye Q. Hepatic complications of COVID-19 and its treatment. *J Med Virol* 2020; **92**: 1818-1824 [PMID: [32437004](https://pubmed.ncbi.nlm.nih.gov/32437004/) DOI: [10.1002/jmv.26036](https://doi.org/10.1002/jmv.26036)]
 - 21 **Lescot T**, Karvellas C, Beaussier M, Magder S. Acquired liver injury in the intensive care unit. *Anesthesiology* 2012; **117**: 898-904 [PMID: [22854981](https://pubmed.ncbi.nlm.nih.gov/22854981/) DOI: [10.1097/ALN.0b013e318266c6df](https://doi.org/10.1097/ALN.0b013e318266c6df)]
 - 22 **Kwo PY**, Cohen SM, Lim JK. ACG Clinical Guideline: Evaluation of Abnormal Liver Chemistries. *Am J Gastroenterol* 2017; **112**: 18-35 [PMID: [27995906](https://pubmed.ncbi.nlm.nih.gov/27995906/) DOI: [10.1038/ajg.2016.517](https://doi.org/10.1038/ajg.2016.517)]
 - 23 **Phipps MM**, Barraza LH, LaSota ED, Sobieszczyk ME, Pereira MR, Zheng EX, Fox AN, Zucker J, Verna EC. Acute Liver Injury in COVID-19: Prevalence and Association with Clinical Outcomes in a Large U.S. Cohort. *Hepatology* 2020; **72**: 807-817 [PMID: [32473607](https://pubmed.ncbi.nlm.nih.gov/32473607/) DOI: [10.1002/hep.31404](https://doi.org/10.1002/hep.31404)]
 - 24 **Yip TC**, Lui GC, Wong VW, Chow VC, Ho TH, Li TC, Tse YK, Hui DS, Chan HL, Wong GL. Liver injury is independently associated with adverse clinical outcomes in patients with COVID-19. *Gut* 2021; **70**: 733-742 [PMID: [32641471](https://pubmed.ncbi.nlm.nih.gov/32641471/) DOI: [10.1136/gutjnl-2020-321726](https://doi.org/10.1136/gutjnl-2020-321726)]
 - 25 **Cai Q**, Huang D, Yu H, Zhu Z, Xia Z, Su Y, Li Z, Zhou G, Gou J, Qu J, Sun Y, Liu Y, He Q, Chen J, Liu L, Xu L. COVID-19: Abnormal liver function tests. *J Hepatol* 2020; **73**: 566-574 [PMID: [32298767](https://pubmed.ncbi.nlm.nih.gov/32298767/) DOI: [10.1016/j.jhep.2020.04.006](https://doi.org/10.1016/j.jhep.2020.04.006)]
 - 26 **Hundt MA**, Deng Y, Ciarleglio MM, Nathanson MH, Lim JK. Abnormal Liver Tests in COVID-19: A Retrospective Observational Cohort Study of 1,827 Patients in a Major U.S. Hospital Network. *Hepatology* 2020; **72**: 1169-1176 [PMID: [32725890](https://pubmed.ncbi.nlm.nih.gov/32725890/) DOI: [10.1002/hep.31487](https://doi.org/10.1002/hep.31487)]
 - 27 **Piano S**, Dalbeni A, Vettore E, Benfaremo D, Mattioli M, Gambino CG, Framba V, Cerruti L, Mantovani A, Martini A, Luchetti MM, Serra R, Cattelan A, Vettor R, Angeli P; COVID-LIVER study group. Abnormal liver function tests predict transfer to intensive care unit and death in COVID-19. *Liver Int* 2020; **40**: 2394-2406 [PMID: [32526083](https://pubmed.ncbi.nlm.nih.gov/32526083/) DOI: [10.1111/liv.14565](https://doi.org/10.1111/liv.14565)]
 - 28 **Roedl K**, Jarczak D, Drolz A, Wichmann D, Boenisch O, de Heer G, Burdelski C, Frings D, Sensen B, Nierhaus A, Lütgehetmann M, Kluge S, Fuhrmann V. Severe liver dysfunction complicating course of COVID-19 in the critically ill: multifactorial cause or direct viral effect? *Ann Intensive Care* 2021; **11**: 44 [PMID: [33721137](https://pubmed.ncbi.nlm.nih.gov/33721137/) DOI: [10.1186/s13613-021-00835-3](https://doi.org/10.1186/s13613-021-00835-3)]
 - 29 **Huang H**, Li H, Chen S, Zhou X, Dai X, Wu J, Zhang J, Shao L, Yan R, Wang M, Wang J, Tu Y, Ge M. Prevalence and Characteristics of Hypoxic Hepatitis in COVID-19 Patients in the Intensive Care Unit: A First Retrospective Study. *Front Med (Lausanne)* 2020; **7**: 607206 [PMID: [33681238](https://pubmed.ncbi.nlm.nih.gov/33681238/) DOI: [10.3389/fmed.2020.607206](https://doi.org/10.3389/fmed.2020.607206)]
 - 30 **Salik F**, Uzundere O, Bıçak M, Akelma H, Akgündüz M, Korhan Z, Kandemir D, Kaçar CK. Liver function as a predictor of mortality in COVID-19: A retrospective study. *Ann Hepatol* 2021; **26**: 100553 [PMID: [34624543](https://pubmed.ncbi.nlm.nih.gov/34624543/) DOI: [10.1016/j.ahep.2021.100553](https://doi.org/10.1016/j.ahep.2021.100553)]
 - 31 **Arentz M**, Yim E, Klaff L, Lokhandwala S, Riedo FX, Chong M, Lee M. Characteristics and Outcomes of 21 Critically Ill Patients With COVID-19 in Washington State. *JAMA* 2020; **323**: 1612-1614 [PMID: [32191259](https://pubmed.ncbi.nlm.nih.gov/32191259/) DOI: [10.1001/jama.2020.4326](https://doi.org/10.1001/jama.2020.4326)]
 - 32 **Martinot M**, Eyriey M, Gravier S, Bonijoly T, Kayser D, Ion C, Mohseni-Zadeh M, Camara S, Dubois J, Haerrel E, Drouaine J, Kaiser J, Ongagna JC, Schieber-Pachart A, Kempf C; Centre Alsace COVID-19 Study Group. Predictors of mortality, ICU hospitalization, and extrapulmonary complications in COVID-19 patients. *Infect Dis Now* 2021; **51**: 518-525 [PMID: [34242842](https://pubmed.ncbi.nlm.nih.gov/34242842/) DOI: [10.1016/j.idnow.2021.07.002](https://doi.org/10.1016/j.idnow.2021.07.002)]
 - 33 **Sun JK**, Liu Y, Zou L, Zhang WH, Li JJ, Wang Y, Kan XH, Chen JD, Shi QK, Yuan ST. Acute gastrointestinal injury in critically ill patients with COVID-19 in Wuhan, China. *World J Gastroenterol* 2020; **26**: 6087-6097 [PMID: [33132657](https://pubmed.ncbi.nlm.nih.gov/33132657/) DOI: [10.3748/wjg.v26.i39.6087](https://doi.org/10.3748/wjg.v26.i39.6087)]
 - 34 **Cardoso FS**, Pereira R, Germano N. Liver injury in critically ill patients with COVID-19: a case series. *Crit Care* 2020; **24**: 190 [PMID: [32366282](https://pubmed.ncbi.nlm.nih.gov/32366282/) DOI: [10.1186/s13054-020-02924-4](https://doi.org/10.1186/s13054-020-02924-4)]
 - 35 **Shousha HI**, Afify S, Maher R, Asem N, Fouad E, Mostafa EF, Medhat MA, Abdalazeem A, Elmorsy H, Aziz MM, Mohammed RS, Ibrahim M, Elgarem H, Omran D, Hassany M, Elsayed B, Abdelaziz AY, El Kassas M. Hepatic and gastrointestinal disturbances in Egyptian patients infected with coronavirus disease 2019: A multicentre cohort study. *World J Gastroenterol* 2021; **27**: 6951-6966 [PMID: [34790017](https://pubmed.ncbi.nlm.nih.gov/34790017/) DOI: [10.3748/wjg.v27.i40.6951](https://doi.org/10.3748/wjg.v27.i40.6951)]
 - 36 **Currier E**, Dabaja M, Syed-Mohammed Jafri SM. Elevated liver enzymes in black COVID-19 patients linked to higher rates of ICU admittance and intubation compared to non-black patients. *Hepatology* 2021; **74** Suppl 1: 316A
 - 37 **Rabiee A**, Sadowski B, Adeniji N, Perumalswami PV, Nguyen V, Moghe A, Latt NL, Kumar S, Aloman C, Catana AM, Bloom PP, Chavin KD, Carr RM, Dunn W, Chen VL, Aby ES, Debes JD, Dhanasekaran R; COLD Consortium. Liver Injury in Liver Transplant Recipients With Coronavirus Disease 2019 (COVID-19): U.S. Multicenter Experience. *Hepatology* 2020; **72**: 1900-1911 [PMID: [32964510](https://pubmed.ncbi.nlm.nih.gov/32964510/) DOI: [10.1002/hep.31574](https://doi.org/10.1002/hep.31574)]
 - 38 **Roncati L**, Manenti A, Fabbiani L, Malagoli C, Nasillo V, Lusenti B, Lupi M, Zanelli G, Salviato T, Costantini M, Trenti T, Maiorana A. HSV1 viremia with fulminant hepatitis as opportunistic sequela in severe COVID-19. *Ann Hematol* 2022; **101**: 229-231 [PMID: [33458783](https://pubmed.ncbi.nlm.nih.gov/33458783/) DOI: [10.1007/s00277-021-04417-y](https://doi.org/10.1007/s00277-021-04417-y)]
 - 39 **Bütikofer S**, Lenggenhager D, Wendel Garcia PD, Maggio EM, Haberecker M, Reiner CS, Brüllmann G, Buehler PK, Gubler C, Müllhaupt B, Jüngst C, Morell B. Secondary sclerosing cholangitis as cause of persistent jaundice in patients with severe COVID-19. *Liver Int* 2021; **41**: 2404-2417 [PMID: [34018314](https://pubmed.ncbi.nlm.nih.gov/34018314/) DOI: [10.1111/liv.14971](https://doi.org/10.1111/liv.14971)]
 - 40 **Wendel-Garcia PD**, Erlebach R, Hofmaenner DA, Camen G, Schuepbach RA, Jüngst C, Müllhaupt B, Bartussek J,

- Buehler PK, Andermatt R, David S. Long-term ketamine infusion-induced cholestatic liver injury in COVID-19-associated acute respiratory distress syndrome. *Crit Care* 2022; **26**: 148 [PMID: [35606831](#) DOI: [10.1186/s13054-022-04019-8](#)]
- 41 Nardo AD, Schneeweiss-Gleixner M, Bakail M, Dixon ED, Lax SF, Trauner M. Pathophysiological mechanisms of liver injury in COVID-19. *Liver Int* 2021; **41**: 20-32 [PMID: [33190346](#) DOI: [10.1111/liv.14730](#)]
- 42 Bertolini A, van de Peppel IP, Bodewes FAJA, Moshage H, Fantin A, Farinati F, Fiorotto R, Jonker JW, Strazzabosco M, Verkade HJ, Peserico G. Abnormal Liver Function Tests in Patients With COVID-19: Relevance and Potential Pathogenesis. *Hepatology* 2020; **72**: 1864-1872 [PMID: [32702162](#) DOI: [10.1002/hep.31480](#)]
- 43 Jothamani D, Venugopal R, Abedin MF, Kaliamoorthy I, Rela M. COVID-19 and the liver. *J Hepatol* 2020; **73**: 1231-1240 [PMID: [32553666](#) DOI: [10.1016/j.jhep.2020.06.006](#)]
- 44 Garrido I, Liberal R, Macedo G. Review article: COVID-19 and liver disease-what we know on 1st May 2020. *Aliment Pharmacol Ther* 2020; **52**: 267-275 [PMID: [32402090](#) DOI: [10.1111/apt.15813](#)]
- 45 Schenk J, van der Ven WH, Schuurmans J, Roerhorst S, Cherpanath TGV, Lagrand WK, Thorat P, Elbers PWG, Tuinman PR, Scheeren TWL, Bakker J, Geerts BF, Veelo DP, Paulus F, Vlaar APJ; Cardiovascular Dynamics Section of the ESICM. Definition and incidence of hypotension in intensive care unit patients, an international survey of the European Society of Intensive Care Medicine. *J Crit Care* 2021; **65**: 142-148 [PMID: [34148010](#) DOI: [10.1016/j.jcrc.2021.05.023](#)]
- 46 van der Ven WH, Schuurmans J, Schenk J, Roerhorst S, Cherpanath TGV, Lagrand WK, Thorat P, Elbers PWG, Tuinman PR, Scheeren TWL, Bakker J, Geerts BF, Veelo DP, Paulus F, Vlaar APJ; Cardiovascular Dynamics Section of the ESICM. Monitoring, management, and outcome of hypotension in Intensive Care Unit patients, an international survey of the European Society of Intensive Care Medicine. *J Crit Care* 2022; **67**: 118-125 [PMID: [34749051](#) DOI: [10.1016/j.jcrc.2021.10.008](#)]
- 47 Salabei JK, Asnake ZT, Ismail ZH, Charles K, Stanger GT, Abdullahi AH, Abraham AT, Okonoboh P. COVID-19 and the cardiovascular system: an update. *Am J Med Sci* 2022; **364**: 139-147 [PMID: [35151635](#) DOI: [10.1016/j.amjms.2022.01.022](#)]
- 48 Crudo VL, Ahmed AI, Cowan EL, Shah DJ, Al-Mallah MH, Malahfji M. Acute and Subclinical Myocardial Injury in COVID-19. *Methodist Debaque Cardiovasc J* 2021; **17**: 22-30 [PMID: [34992721](#) DOI: [10.14797/mdevj.1038](#)]
- 49 Siripanthong B, Nazarian S, Muser D, Deo R, Santangeli P, Khanji MY, Cooper LT Jr, Chahal CAA. Recognizing COVID-19-related myocarditis: The possible pathophysiology and proposed guideline for diagnosis and management. *Heart Rhythm* 2020; **17**: 1463-1471 [PMID: [32387246](#) DOI: [10.1016/j.hrthm.2020.05.001](#)]
- 50 Harjola VP, Mullens W, Banaszewski M, Bauersachs J, Brunner-La Rocca HP, Chioncel O, Collins SP, Doehner W, Filippatos GS, Flammer AJ, Fuhrmann V, Lainscak M, Lassus J, Legrand M, Masip J, Mueller C, Papp Z, Parissis J, Platz E, Rudiger A, Ruschitzka F, Schäfer A, Seferovic PM, Skouri H, Yilmaz MB, Mebazaa A. Organ dysfunction, injury and failure in acute heart failure: from pathophysiology to diagnosis and management. A review on behalf of the Acute Heart Failure Committee of the Heart Failure Association (HFA) of the European Society of Cardiology (ESC). *Eur J Heart Fail* 2017; **19**: 821-836 [PMID: [28560717](#) DOI: [10.1002/ehf.872](#)]
- 51 Lightsey JM, Rockey DC. Current concepts in ischemic hepatitis. *Curr Opin Gastroenterol* 2017; **33**: 158-163 [PMID: [28346236](#) DOI: [10.1097/MOG.0000000000000355](#)]
- 52 Jakob SM, Tenhunen JJ, Laitinen S, Heino A, Alhava E, Takala J. Effects of systemic arterial hypoperfusion on splanchnic hemodynamics and hepatic arterial buffer response in pigs. *Am J Physiol Gastrointest Liver Physiol* 2001; **280**: G819-G827 [PMID: [11292589](#) DOI: [10.1152/ajpgi.2001.280.5.G819](#)]
- 53 Russell JA, Gordon AC, Williams MD, Boyd JH, Walley KR, Kissoon N. Vasopressor Therapy in the Intensive Care Unit. *Semin Respir Crit Care Med* 2021; **42**: 59-77 [PMID: [32820475](#) DOI: [10.1055/s-0040-1710320](#)]
- 54 Lamontagne F, Marshall JC, Adhikari NKJ. Permissive hypotension during shock resuscitation: equipoise in all patients? *Intensive Care Med* 2018; **44**: 87-90 [PMID: [28551721](#) DOI: [10.1007/s00134-017-4849-2](#)]
- 55 Lamontagne F, Richards-Belle A, Thomas K, Harrison DA, Sadique MZ, Grieve RD, Camsooksai J, Darnell R, Gordon AC, Henry D, Hudson N, Mason AJ, Saul M, Whitman C, Young JD, Rowan KM, Mouncey PR; 65 trial investigators. Effect of Reduced Exposure to Vasopressors on 90-Day Mortality in Older Critically Ill Patients With Vasodilatory Hypotension: A Randomized Clinical Trial. *JAMA* 2020; **323**: 938-949 [PMID: [32049269](#) DOI: [10.1001/jama.2020.0930](#)]
- 56 Weemhoff JL, Woolbright BL, Jenkins RE, McGill MR, Sharpe MR, Olson JC, Antoine DJ, Curry SC, Jaeschke H. Plasma biomarkers to study mechanisms of liver injury in patients with hypoxic hepatitis. *Liver Int* 2017; **37**: 377-384 [PMID: [27429052](#) DOI: [10.1111/liv.13202](#)]
- 57 Datta G, Fuller BJ, Davidson BR. Molecular mechanisms of liver ischemia reperfusion injury: insights from transgenic knockout models. *World J Gastroenterol* 2013; **19**: 1683-1698 [PMID: [23555157](#) DOI: [10.3748/wjg.v19.i11.1683](#)]
- 58 Cecconi M, Evans L, Levy M, Rhodes A. Sepsis and septic shock. *Lancet* 2018; **392**: 75-87 [PMID: [29937192](#) DOI: [10.1016/S0140-6736\(18\)30696-2](#)]
- 59 Geier A, Fickert P, Trauner M. Mechanisms of disease: mechanisms and clinical implications of cholestasis in sepsis. *Nat Clin Pract Gastroenterol Hepatol* 2006; **3**: 574-585 [PMID: [17008927](#) DOI: [10.1038/ncpgasthep.0602](#)]
- 60 Horvatits T, Drolz A, Trauner M, Fuhrmann V. Liver Injury and Failure in Critical Illness. *Hepatology* 2019; **70**: 2204-2215 [PMID: [31215660](#) DOI: [10.1002/hep.30824](#)]
- 61 Gudnason HO, Björnsson ES. Secondary sclerosing cholangitis in critically ill patients: current perspectives. *Clin Exp Gastroenterol* 2017; **10**: 105-111 [PMID: [28694703](#) DOI: [10.2147/CEG.S115518](#)]
- 62 Stratton L, Berlin DA, Arbo JE. Vasopressors and Inotropes in Sepsis. *Emerg Med Clin North Am* 2017; **35**: 75-91 [PMID: [27908339](#) DOI: [10.1016/j.emc.2016.09.005](#)]
- 63 Gorecki G, Cochior D, Moldovan C, Rusu E. Molecular mechanisms in septic shock (Review). *Exp Ther Med* 2021; **22**: 1161 [PMID: [34504606](#) DOI: [10.3892/etm.2021.10595](#)]
- 64 Waseem N, Chen PH. Hypoxic Hepatitis: A Review and Clinical Update. *J Clin Transl Hepatol* 2016; **4**: 263-268 [PMID: [27777895](#) DOI: [10.14218/JCTH.2016.00022](#)]
- 65 Meyer NJ, Gattinoni L, Calfee CS. Acute respiratory distress syndrome. *Lancet* 2021; **398**: 622-637 [PMID: [34217425](#)]

- DOI: [10.1016/S0140-6736\(21\)00439-6](https://doi.org/10.1016/S0140-6736(21)00439-6)
- 66 **Henrion J**, Minette P, Colin L, Schapira M, Delannoy A, Heller FR. Hypoxic hepatitis caused by acute exacerbation of chronic respiratory failure: a case-controlled, hemodynamic study of 17 consecutive cases. *Hepatology* 1999; **29**: 427-433 [PMID: [9918919](https://pubmed.ncbi.nlm.nih.gov/9918919/) DOI: [10.1002/hep.510290202](https://doi.org/10.1002/hep.510290202)]
 - 67 **Kietzmann T**, Dimova EY, Flügel D, Scharf JG. Oxygen: modulator of physiological and pathophysiological processes in the liver. *Z Gastroenterol* 2006; **44**: 67-76 [PMID: [16397842](https://pubmed.ncbi.nlm.nih.gov/16397842/) DOI: [10.1055/s-2005-858987](https://doi.org/10.1055/s-2005-858987)]
 - 68 **Cai J**, Hu M, Chen Z, Ling Z. The roles and mechanisms of hypoxia in liver fibrosis. *J Transl Med* 2021; **19**: 186 [PMID: [33933107](https://pubmed.ncbi.nlm.nih.gov/33933107/) DOI: [10.1186/s12967-021-02854-x](https://doi.org/10.1186/s12967-021-02854-x)]
 - 69 **Young M**, DiSilvio B, Rao S, Velliyattikuzhi S, Balaan M. Mechanical Ventilation in ARDS. *Crit Care Nurs Q* 2019; **42**: 392-399 [PMID: [31449149](https://pubmed.ncbi.nlm.nih.gov/31449149/) DOI: [10.1097/CNQ.0000000000000279](https://doi.org/10.1097/CNQ.0000000000000279)]
 - 70 **Sylvester JT**, Shimoda LA, Aaronson PI, Ward JP. Hypoxic pulmonary vasoconstriction. *Physiol Rev* 2012; **92**: 367-520 [PMID: [22298659](https://pubmed.ncbi.nlm.nih.gov/22298659/) DOI: [10.1152/physrev.00041.2010](https://doi.org/10.1152/physrev.00041.2010)]
 - 71 **Mahmood SS**, Pinsky MR. Heart-lung interactions during mechanical ventilation: the basics. *Ann Transl Med* 2018; **6**: 349 [PMID: [30370276](https://pubmed.ncbi.nlm.nih.gov/30370276/) DOI: [10.21037/atm.2018.04.29](https://doi.org/10.21037/atm.2018.04.29)]
 - 72 **Grübler MR**, Wigger O, Berger D, Blöchliger S. Basic concepts of heart-lung interactions during mechanical ventilation. *Swiss Med Wkly* 2017; **147**: w14491 [PMID: [28944931](https://pubmed.ncbi.nlm.nih.gov/28944931/) DOI: [10.4414/smww.2017.14491](https://doi.org/10.4414/smww.2017.14491)]
 - 73 **Kondili E**, Makris D, Georgopoulos D, Rovina N, Kotanidou A, Koutsoukou A. COVID-19 ARDS: Points to Be Considered in Mechanical Ventilation and Weaning. *J Pers Med* 2021; **11** [PMID: [34834461](https://pubmed.ncbi.nlm.nih.gov/34834461/) DOI: [10.3390/jpm11111109](https://doi.org/10.3390/jpm11111109)]
 - 74 **Richard C**, Berdeaux A, Delion F, Riou B, Rimaillho A, Giudicelli JF, Auzépy P. Effect of mechanical ventilation on hepatic drug pharmacokinetics. *Chest* 1986; **90**: 837-841 [PMID: [3780330](https://pubmed.ncbi.nlm.nih.gov/3780330/) DOI: [10.1378/chest.90.6.837](https://doi.org/10.1378/chest.90.6.837)]
 - 75 **Brienza N**, Revelly JP, Ayuse T, Robotham JL. Effects of PEEP on liver arterial and venous blood flows. *Am J Respir Crit Care Med* 1995; **152**: 504-510 [PMID: [7633699](https://pubmed.ncbi.nlm.nih.gov/7633699/) DOI: [10.1164/ajrcm.152.2.7633699](https://doi.org/10.1164/ajrcm.152.2.7633699)]
 - 76 **Fujita Y**. Effects of PEEP on splanchnic hemodynamics and blood volume. *Acta Anaesthesiol Scand* 1993; **37**: 427-431 [PMID: [8322573](https://pubmed.ncbi.nlm.nih.gov/8322573/) DOI: [10.1111/j.1399-6576.1993.tb03742.x](https://doi.org/10.1111/j.1399-6576.1993.tb03742.x)]
 - 77 **Brienza N**, Dalfino L, Cinnella G, Diele C, Bruno F, Fiore T. Jaundice in critical illness: promoting factors of a concealed reality. *Intensive Care Med* 2006; **32**: 267-274 [PMID: [16450099](https://pubmed.ncbi.nlm.nih.gov/16450099/) DOI: [10.1007/s00134-005-0023-3](https://doi.org/10.1007/s00134-005-0023-3)]
 - 78 **Schricker T**, Kugler B, Schywalsky M, Braun G, Träger K, Georgieff M. Effects of PEEP ventilation on liver metabolism. *Infusionsther Transfusionsmed* 1995; **22**: 168-174 [PMID: [7640511](https://pubmed.ncbi.nlm.nih.gov/7640511/) DOI: [10.1159/000223118](https://doi.org/10.1159/000223118)]
 - 79 **Putensen C**, Wrigge H, Hering R. The effects of mechanical ventilation on the gut and abdomen. *Curr Opin Crit Care* 2006; **12**: 160-165 [PMID: [16543794](https://pubmed.ncbi.nlm.nih.gov/16543794/) DOI: [10.1097/01.ccx.0000216585.54502.eb](https://doi.org/10.1097/01.ccx.0000216585.54502.eb)]
 - 80 **Fortea JI**, Puente Á, Cuadrado A, Huelin P, Pellón R, González Sánchez FJ, Mayorga M, Cagigal ML, García Carrera I, Cobreros M, Crespo J, Fábrega E. Congestive Hepatopathy. *Int J Mol Sci* 2020; **21** [PMID: [33321947](https://pubmed.ncbi.nlm.nih.gov/33321947/) DOI: [10.3390/ijms21249420](https://doi.org/10.3390/ijms21249420)]
 - 81 **Jakob SM**. The effects of mechanical ventilation on hepato-splanchnic perfusion. *Curr Opin Crit Care* 2010; **16**: 165-168 [PMID: [20134320](https://pubmed.ncbi.nlm.nih.gov/20134320/) DOI: [10.1097/MCC.0b013e3283374b1c](https://doi.org/10.1097/MCC.0b013e3283374b1c)]
 - 82 **Puiac C**, Szederjesi J, Lazar A, Almasy E, Rad P, Puscasiu L. Influence of Ventilation Parameters on Intraabdominal Pressure. *J Crit Care Med (Targu Mures)* 2016; **2**: 80-84 [PMID: [29967842](https://pubmed.ncbi.nlm.nih.gov/29967842/) DOI: [10.1515/jccm-2016-0016](https://doi.org/10.1515/jccm-2016-0016)]
 - 83 **Rafiei MR**, Aghadavoudi O, Shekarchi B, Sajjadi SS, Masoudifar M. Can selection of mechanical ventilation mode prevent increased intra-abdominal pressure in patients admitted to the intensive care unit? *Int J Prev Med* 2013; **4**: 552-556 [PMID: [23930166](https://pubmed.ncbi.nlm.nih.gov/23930166/)]
 - 84 **Dagar G**, Taneja A, Nanchal RS. Abdominal Circulatory Interactions. *Crit Care Clin* 2016; **32**: 265-277 [PMID: [27016167](https://pubmed.ncbi.nlm.nih.gov/27016167/) DOI: [10.1016/j.ccc.2015.12.005](https://doi.org/10.1016/j.ccc.2015.12.005)]
 - 85 **Lewis M**, Benjamin ER, Demetriades D. Intra-abdominal hypertension and abdominal compartment syndrome. *Curr Probl Surg* 2021; **58**: 100971 [PMID: [34836571](https://pubmed.ncbi.nlm.nih.gov/34836571/) DOI: [10.1016/j.cpsurg.2021.100971](https://doi.org/10.1016/j.cpsurg.2021.100971)]
 - 86 **Regli A**, Pelosi P, Malbrain MLNG. Ventilation in patients with intra-abdominal hypertension: what every critical care physician needs to know. *Ann Intensive Care* 2019; **9**: 52 [PMID: [31025221](https://pubmed.ncbi.nlm.nih.gov/31025221/) DOI: [10.1186/s13613-019-0522-y](https://doi.org/10.1186/s13613-019-0522-y)]
 - 87 **Kirkpatrick AW**, Roberts DJ, De Waele J, Jaeschke R, Malbrain ML, De Keulenaer B, Duchesne J, Bjorck M, Leppaniemi A, Ejike JC, Sugrue M, Cheatham M, Ivatury R, Ball CG, Reintam Blaser A, Regli A, Balogh ZJ, D'Amours S, Debergh D, Kaplan M, Kimball E, Olvera C; Pediatric Guidelines Sub-Committee for the World Society of the Abdominal Compartment Syndrome. Intra-abdominal hypertension and the abdominal compartment syndrome: updated consensus definitions and clinical practice guidelines from the World Society of the Abdominal Compartment Syndrome. *Intensive Care Med* 2013; **39**: 1190-1206 [PMID: [23673399](https://pubmed.ncbi.nlm.nih.gov/23673399/) DOI: [10.1007/s00134-013-2906-z](https://doi.org/10.1007/s00134-013-2906-z)]
 - 88 **Kobr J**, Fremuth J, Pizingerová K, Fikrllová S, Jehlicka P, Honomichl P, Sasek L, Racek J, Topolcan O. Total body response to mechanical ventilation of healthy lungs: an experimental study in piglets. *Physiol Res* 2010; **59**: 545-552 [PMID: [19929141](https://pubmed.ncbi.nlm.nih.gov/19929141/) DOI: [10.33549/physiolres.931752](https://doi.org/10.33549/physiolres.931752)]
 - 89 **Silva PL**, Ball L, Rocco PRM, Pelosi P. Physiological and Pathophysiological Consequences of Mechanical Ventilation. *Semin Respir Crit Care Med* 2022; **43**: 321-334 [PMID: [35439832](https://pubmed.ncbi.nlm.nih.gov/35439832/) DOI: [10.1055/s-0042-1744447](https://doi.org/10.1055/s-0042-1744447)]
 - 90 **Jiang Y**, Rubin L, Peng T, Liu L, Xing X, Lazarovici P, Zheng W. Cytokine storm in COVID-19: from viral infection to immune responses, diagnosis and therapy. *Int J Biol Sci* 2022; **18**: 459-472 [PMID: [35002503](https://pubmed.ncbi.nlm.nih.gov/35002503/) DOI: [10.7150/ijbs.59272](https://doi.org/10.7150/ijbs.59272)]
 - 91 **Hu B**, Huang S, Yin L. The cytokine storm and COVID-19. *J Med Virol* 2021; **93**: 250-256 [PMID: [32592501](https://pubmed.ncbi.nlm.nih.gov/32592501/) DOI: [10.1002/jmv.26232](https://doi.org/10.1002/jmv.26232)]
 - 92 **Maggi E**, Canonica GW, Moretta L. COVID-19: Unanswered questions on immune response and pathogenesis. *J Allergy Clin Immunol* 2020; **146**: 18-22 [PMID: [32389590](https://pubmed.ncbi.nlm.nih.gov/32389590/) DOI: [10.1016/j.jaci.2020.05.001](https://doi.org/10.1016/j.jaci.2020.05.001)]
 - 93 **Zanza C**, Romenskaya T, Manetti AC, Franceschi F, La Russa R, Bertozzi G, Maiese A, Savioli G, Volonnino G, Longhitano Y. Cytokine Storm in COVID-19: Immunopathogenesis and Therapy. *Medicina (Kaunas)* 2022; **58** [PMID: [35208467](https://pubmed.ncbi.nlm.nih.gov/35208467/) DOI: [10.3390/medicina58020144](https://doi.org/10.3390/medicina58020144)]
 - 94 **Zhan K**, Liao S, Li J, Bai Y, Lv L, Yu K, Qiu L, Li C, Yuan G, Zhang A, Mei Z. Risk factors in patients with COVID-19 developing severe liver injury during hospitalisation. *Gut* 2021; **70**: 628-629 [PMID: [32571973](https://pubmed.ncbi.nlm.nih.gov/32571973/) DOI: [10.1136/gut-2020-004396](https://doi.org/10.1136/gut-2020-004396)]

- 10.1136/gutjnl-2020-321913]
- 95 **Gómez-Mesa JE**, Galindo-Coral S, Montes MC, Muñoz Martín AJ. Thrombosis and Coagulopathy in COVID-19. *Curr Probl Cardiol* 2021; **46**: 100742 [PMID: 33243440 DOI: 10.1016/j.cpcardiol.2020.100742]
 - 96 **Iba T**, Connors JM, Levy JH. The coagulopathy, endotheliopathy, and vasculitis of COVID-19. *Inflamm Res* 2020; **69**: 1181-1189 [PMID: 32918567 DOI: 10.1007/s00011-020-01401-6]
 - 97 **Martini R**. The compelling arguments for the need of microvascular investigation in COVID-19 critical patients. *Clin Hemorheol Microcirc* 2020; **75**: 27-34 [PMID: 32568186 DOI: 10.3233/CH-200895]
 - 98 **Otifi HM**, Adiga BK. Endothelial Dysfunction in Covid-19 Infection. *Am J Med Sci* 2022; **363**: 281-287 [PMID: 35093394 DOI: 10.1016/j.amjms.2021.12.010]
 - 99 **Cai Y**, Ye LP, Song YQ, Mao XL, Wang L, Jiang YZ, Que WT, Li SW. Liver injury in COVID-19: Detection, pathogenesis, and treatment. *World J Gastroenterol* 2021; **27**: 3022-3036 [PMID: 34168405 DOI: 10.3748/wjg.v27.i22.3022]
 - 100 **Trevino SE**, Kollef MH. Management of Infections with Drug-Resistant Organisms in Critical Care: An Ongoing Battle. *Clin Chest Med* 2015; **36**: 531-541 [PMID: 26304289 DOI: 10.1016/j.ccm.2015.05.007]
 - 101 **Fitzmaurice MG**, Wong A, Akerberg H, Avramovska S, Smithburger PL, Buckley MS, Kane-Gill SL. Evaluation of Potential Drug-Drug Interactions in Adults in the Intensive Care Unit: A Systematic Review and Meta-Analysis. *Drug Saf* 2019; **42**: 1035-1044 [PMID: 31098917 DOI: 10.1007/s40264-019-00829-y]
 - 102 **Kane-Gill SL**, Kirisci L, Verrico MM, Rothschild JM. Analysis of risk factors for adverse drug events in critically ill patients*. *Crit Care Med* 2012; **40**: 823-828 [PMID: 22036859 DOI: 10.1097/CCM.0b013e318236f473]
 - 103 **Smith BS**, Yogaratnam D, Levasseur-Franklin KE, Forni A, Fong J. Introduction to drug pharmacokinetics in the critically ill patient. *Chest* 2012; **141**: 1327-1336 [PMID: 22553267 DOI: 10.1378/chest.11-1396]
 - 104 **Yoon E**, Babar A, Choudhary M, Kutner M, Pyrsopoulos N. Acetaminophen-Induced Hepatotoxicity: a Comprehensive Update. *J Clin Transl Hepatol* 2016; **4**: 131-142 [PMID: 27350943 DOI: 10.14218/JCTH.2015.00052]
 - 105 **Björnsson ES**. Drug-induced liver injury due to antibiotics. *Scand J Gastroenterol* 2017; **52**: 617-623 [PMID: 28276834 DOI: 10.1080/00365521.2017.1291719]
 - 106 **Brown SJ**, Desmond PV. Hepatotoxicity of antimicrobial agents. *Semin Liver Dis* 2002; **22**: 157-167 [PMID: 12016547 DOI: 10.1055/s-2002-30103]
 - 107 **Kyriakidis I**, Tragiannidis A, Munchen S, Groll AH. Clinical hepatotoxicity associated with antifungal agents. *Expert Opin Drug Saf* 2017; **16**: 149-165 [PMID: 27927037 DOI: 10.1080/14740338.2017.1270264]
 - 108 **Ruan X**, Lu X, Wang K, Zhang B, Wang J, Li Y, Xu Z, Yan F. Liver injury after antiviral treatment of critically ill patients with COVID-19: a single-centered retrospective cohort study. *Ann Palliat Med* 2021; **10**: 2429-2438 [PMID: 33440980 DOI: 10.21037/apm-20-1581]
 - 109 **Lee TC**, Murthy S, Del Corpo O, Senécal J, Butler-Laporte G, Sohani ZN, Brophy JM, McDonald EG. Remdesivir for the treatment of COVID-19: a systematic review and meta-analysis. *Clin Microbiol Infect* 2022; **28**: 1203-1210 [PMID: 35598856 DOI: 10.1016/j.cmi.2022.04.018]
 - 110 **Antinori S**, Cossu MV, Ridolfo AL, Rech R, Bonazzetti C, Pagani G, Gubertini G, Coen M, Magni C, Castelli A, Borghi B, Colombo R, Giorgi R, Angeli E, Mileto D, Milazzo L, Vimercati S, Pellicciotta M, Corbellino M, Torre A, Rusconi S, Oreni L, Gismondo MR, Giacomelli A, Meroni L, Rizzardini G, Galli M. Compassionate remdesivir treatment of severe Covid-19 pneumonia in intensive care unit (ICU) and Non-ICU patients: Clinical outcome and differences in post-treatment hospitalisation status. *Pharmacol Res* 2020; **158**: 104899 [PMID: 32407959 DOI: 10.1016/j.phrs.2020.104899]
 - 111 **Grein J**, Ohmagari N, Shin D, Diaz G, Asperges E, Castagna A, Feldt T, Green G, Green ML, Lescure FX, Nicastri E, Oda R, Yo K, Quiros-Roldan E, Studemeister A, Redinski J, Ahmed S, Burnett J, Chelliah D, Chen D, Chihara S, Cohen SH, Cunningham J, D'Arminio Monforte A, Ismail S, Kato H, Lapadula G, L'Her E, Maeno T, Majumder S, Massari M, Mora-Rillo M, Mutoh Y, Nguyen D, Verweij E, Zoufaly A, Osinusi AO, DeZure A, Zhao Y, Zhong L, Chokkalingam A, Elboudwarej E, Telep L, Timbs L, Henne I, Sellers S, Cao H, Tan SK, Winterbourne L, Desai P, Mera R, Gaggari A, Myers RP, Brainard DM, Childs R, Flanigan T. Compassionate Use of Remdesivir for Patients with Severe Covid-19. *N Engl J Med* 2020; **382**: 2327-2336 [PMID: 32275812 DOI: 10.1056/NEJMoa2007016]
 - 112 **Wang Y**, Zhang D, Du G, Du R, Zhao J, Jin Y, Fu S, Gao L, Cheng Z, Lu Q, Hu Y, Luo G, Wang K, Lu Y, Li H, Wang S, Ruan S, Yang C, Mei C, Wang Y, Ding D, Wu F, Tang X, Ye X, Ye Y, Liu B, Yang J, Yin W, Wang A, Fan G, Zhou F, Liu Z, Gu X, Xu J, Shang L, Zhang Y, Cao L, Guo T, Wan Y, Qin H, Jiang Y, Jaki T, Hayden FG, Horby PW, Cao B, Wang C. Remdesivir in adults with severe COVID-19: a randomised, double-blind, placebo-controlled, multicentre trial. *Lancet* 2020; **395**: 1569-1578 [PMID: 32423584 DOI: 10.1016/S0140-6736(20)31022-9]
 - 113 **Kulkarni AV**, Kumar P, Tevethia HV, Premkumar M, Arab JP, Candia R, Talukdar R, Sharma M, Qi X, Rao PN, Reddy DN. Systematic review with meta-analysis: liver manifestations and outcomes in COVID-19. *Aliment Pharmacol Ther* 2020; **52**: 584-599 [PMID: 32638436 DOI: 10.1111/apt.15916]
 - 114 **Montastruc F**, Thuriot S, Durrieu G. Hepatic Disorders With the Use of Remdesivir for Coronavirus 2019. *Clin Gastroenterol Hepatol* 2020; **18**: 2835-2836 [PMID: 32721580 DOI: 10.1016/j.cgh.2020.07.050]
 - 115 **Zampino R**, Mele F, Florio LL, Bertolino L, Andini R, Galdo M, De Rosa R, Corcione A, Durante-Mangoni E. Liver injury in remdesivir-treated COVID-19 patients. *Hepatol Int* 2020; **14**: 881-883 [PMID: 32725454 DOI: 10.1007/s12072-020-10077-3]
 - 116 **Aleem A**, Mahadevaiah G, Shariff N, Kothadia JP. Hepatic manifestations of COVID-19 and effect of remdesivir on liver function in patients with COVID-19 illness. *Proc (Bayl Univ Med Cent)* 2021; **34**: 473-477 [PMID: 34219928 DOI: 10.1080/08998280.2021.1885289]
 - 117 **Angamo MT**, Mohammed MA, Peterson GM. Efficacy and safety of remdesivir in hospitalised COVID-19 patients: a systematic review and meta-analysis. *Infection* 2022; **50**: 27-41 [PMID: 34331674 DOI: 10.1007/s15010-021-01671-0]
 - 118 **Ortiz GX**, Lenhart G, Becker MW, Schwambach KH, Tovo CV, Blatt CR. Drug-induced liver injury and COVID-19: A review for clinical practice. *World J Hepatol* 2021; **13**: 1143-1153 [PMID: 34630881 DOI: 10.4254/wjh.v13.i9.1143]
 - 119 **Gabrielli M**, Franza L, Esperide A, Gasparrini I, Gasbarrini A, Franceschi F, On Behalf Of Gemelli Against Covid. Liver

- Injury in Patients Hospitalized for COVID-19: Possible Role of Therapy. *Vaccines (Basel)* 2022; **10** [PMID: 35214651 DOI: 10.3390/vaccines10020192]
- 120 **Alhazzani W**, Evans L, Alshamsi F, Möller MH, Ostermann M, Prescott HC, Arabi YM, Loeb M, Ng Gong M, Fan E, Oczkowski S, Levy MM, Derde L, Dziera A, Du B, Machado F, Wunsch H, Crowther M, Cecconi M, Koh Y, Burry L, Chertow DS, Szczeklik W, Belley-Cote E, Greco M, Bala M, Zarychanski R, Kesecioglu J, McGeer A, Mermel L, Mammen MJ, Nainan Myatra S, Arrington A, Kleinpell R, Citerio G, Lewis K, Bridges E, Memish ZA, Hammond N, Hayden FG, Alshahrani M, Al Duhailib Z, Martin GS, Kaplan LJ, Coopersmith CM, Antonelli M, Rhodes A. Surviving Sepsis Campaign Guidelines on the Management of Adults With Coronavirus Disease 2019 (COVID-19) in the ICU: First Update. *Crit Care Med* 2021; **49**: e219-e234 [PMID: 33555780 DOI: 10.1097/CCM.0000000000004899]
 - 121 **Kyriakopoulos C**, Ntritsos G, Gogali A, Milionis H, Evangelou E, Kostikas K. Tocilizumab administration for the treatment of hospitalized patients with COVID-19: A systematic review and meta-analysis. *Respirology* 2021; **26**: 1027-1040 [PMID: 34605114 DOI: 10.1111/resp.14152]
 - 122 **Abidi E**, El Nekidy WS, Alefishat E, Rahman N, Petroianu GA, El-Lababidi R, Mallat J. Tocilizumab and COVID-19: Timing of Administration and Efficacy. *Front Pharmacol* 2022; **13**: 825749 [PMID: 35250575 DOI: 10.3389/fphar.2022.825749]
 - 123 **Capra R**, De Rossi N, Mattioli F, Romanelli G, Scarpazza C, Sormani MP, Cossi S. Impact of low dose tocilizumab on mortality rate in patients with COVID-19 related pneumonia. *Eur J Intern Med* 2020; **76**: 31-35 [PMID: 32405160 DOI: 10.1016/j.ejim.2020.05.009]
 - 124 **Campochiaro C**, Della-Torre E, Cavalli G, De Luca G, Ripa M, Boffini N, Tomelleri A, Baldissera E, Rovere-Querini P, Ruggeri A, Monti G, De Cobelli F, Zangrillo A, Tresoldi M, Castagna A, Dagna L; TOCI-RAF Study Group. Efficacy and safety of tocilizumab in severe COVID-19 patients: a single-centre retrospective cohort study. *Eur J Intern Med* 2020; **76**: 43-49 [PMID: 32482597 DOI: 10.1016/j.ejim.2020.05.021]
 - 125 **Mazzitelli M**, Arrighi E, Serapide F, Pelle MC, Tassone B, Lionello R, Marrazzo G, Laganà D, Costanzo FS, Matera G, Trecarichi EM, Torti C. Use of subcutaneous tocilizumab in patients with COVID-19 pneumonia. *J Med Virol* 2021; **93**: 32-34 [PMID: 32410234 DOI: 10.1002/jmv.26016]
 - 126 **Salvarani C**, Dolci G, Massari M, Merlo DF, Cavuto S, Savoldi L, Bruzzi P, Boni F, Braglia L, Turrà C, Ballerini PF, Sciascia R, Zammarchi L, Para O, Scotton PG, Inojosa WO, Ravagnani V, Salerno ND, Sainaghi PP, Brignone A, Codeluppi M, Teopompi E, Milesi M, Bertomoro P, Claudio N, Salio M, Falcone M, Cenderello G, Donghi L, Del Bono V, Colombelli PL, Angheben A, Passaro A, Secondo G, Pascale R, Piazza I, Facciolo N, Costantini M; RCT-TCZ-COVID-19 Study Group. Effect of Tocilizumab vs Standard Care on Clinical Worsening in Patients Hospitalized With COVID-19 Pneumonia: A Randomized Clinical Trial. *JAMA Intern Med* 2021; **181**: 24-31 [PMID: 33080005 DOI: 10.1001/jamainternmed.2020.6615]
 - 127 **Jain S**, Sharma SK. Rational use of tocilizumab in COVID-19. *Ann Rheum Dis* 2022; **81**: e213 [PMID: 32737106 DOI: 10.1136/annrheumdis-2020-218519]
 - 128 **Charan J**, Dutta S, Kaur R, Bhardwaj P, Sharma P, Ambwani S, Jahan I, Abubakar AR, Islam S, Hardcastle TC, Rahman NAA, Lugova H, Haque M. Tocilizumab in COVID-19: a study of adverse drug events reported in the WHO database. *Expert Opin Drug Saf* 2021; **20**: 1125-1136 [PMID: 34162299 DOI: 10.1080/14740338.2021.1946513]
 - 129 **Yang X**, Li N, Guo T, Guan X, Tan J, Gao X, Wu Y, Jia L, Gu M, Hua L, Liu H. Comparison of the Effects of Low-Molecular-Weight Heparin and Fondaparinux on Liver Function in Patients With Pulmonary Embolism. *J Clin Pharmacol* 2020; **60**: 1671-1678 [PMID: 32639644 DOI: 10.1002/jcph.1686]
 - 130 **Hahn KJ**, Morales SJ, Lewis JH. Enoxaparin-Induced Liver Injury: Case Report and Review of the Literature and FDA Adverse Event Reporting System (FAERS). *Drug Saf Case Rep* 2015; **2**: 17 [PMID: 27747729 DOI: 10.1007/s40800-015-0018-0]
 - 131 **Carlson MK**, Gleason PP, Sen S. Elevation of hepatic transaminases after enoxaparin use: case report and review of unfractionated and low-molecular-weight heparin-induced hepatotoxicity. *Pharmacotherapy* 2001; **21**: 108-113 [PMID: 11191729 DOI: 10.1592/phco.21.1.108.34436]
 - 132 **Sato K**, Yamazaki Y, Uraoka T. Strategy for the control of drug-induced liver injury due to investigational treatments/drugs for COVID-19. *World J Gastroenterol* 2021; **27**: 8370-8373 [PMID: 35068875 DOI: 10.3748/wjg.v27.i48.8370]
 - 133 **Babatin M**, Lee SS, Pollak PT. Amiodarone hepatotoxicity. *Curr Vasc Pharmacol* 2008; **6**: 228-236 [PMID: 18673162 DOI: 10.2174/157016108784912019]
 - 134 **Karamchandani K**, Dalal R, Patel J, Modgil P, Quintili A. Challenges in Sedation Management in Critically Ill Patients with COVID-19: a Brief Review. *Curr Anesthesiol Rep* 2021; **11**: 107-115 [PMID: 33654458 DOI: 10.1007/s40140-021-00440-x]
 - 135 **de Tymowski C**, Dépret F, Dudoignon E, Legrand M, Mallet V; Keta-Cov Research Group. Ketamine-induced cholangiopathy in ARDS patients. *Intensive Care Med* 2021; **47**: 1173-1174 [PMID: 34313797 DOI: 10.1007/s00134-021-06482-3]
 - 136 **Keta-Cov research group**. Intravenous ketamine and progressive cholangiopathy in COVID-19 patients. *J Hepatol* 2021; **74**: 1243-1244 [PMID: 33617925 DOI: 10.1016/j.jhep.2021.02.007]
 - 137 **Mallet V**; Keta-Cov research group. Reply to: "Progressive cholangiopathy in COVID-19 patients: Other possible diagnoses than ketamine-induced cholangiopathy should be considered". *J Hepatol* 2021; **75**: 990-992 [PMID: 34174378 DOI: 10.1016/j.jhep.2021.06.024]
 - 138 **Knooihuizen SAI**, Aday A, Lee WM. Ketamine-Induced Sclerosing Cholangitis (KISC) in a Critically Ill Patient With COVID-19. *Hepatology* 2021; **74**: 519-521 [PMID: 33226658 DOI: 10.1002/hep.31650]
 - 139 **Meersseman P**, Blondeel J, De Vlieger G, van der Merwe S, Monbaliu D; Collaborators Leuven Liver Transplant program. Secondary sclerosing cholangitis: an emerging complication in critically ill COVID-19 patients. *Intensive Care Med* 2021; **47**: 1037-1040 [PMID: 34185115 DOI: 10.1007/s00134-021-06445-8]
 - 140 **Deltenre P**, Moreno C, Trépo E. Progressive cholangiopathy in COVID-19 patients: Other possible diagnoses than ketamine-induced cholangiopathy should be considered. *J Hepatol* 2021; **75**: 989-990 [PMID: 33753153 DOI: 10.1016/j.jhep.2021.06.024]

- 10.1016/j.jhep.2021.02.036]
- 141 **Casaer MP**, Mesotten D, Hermans G, Wouters PJ, Schetz M, Meyfroidt G, Van Cromphaut S, Ingels C, Meersseman P, Muller J, Vlasselaers D, Debaveye Y, Desmet L, Dubois J, Van Assche A, Vanderheyden S, Wilmer A, Van den Berghe G. Early versus late parenteral nutrition in critically ill adults. *N Engl J Med* 2011; **365**: 506-517 [PMID: [21714640](#) DOI: [10.1056/NEJMoa1102662](#)]
 - 142 **Grau T**, Bonet A, Rubio M, Mateo D, Farré M, Acosta JA, Blesa A, Montejó JC, de Lorenzo AG, Mesejo A; Working Group on Nutrition and Metabolism of the Spanish Society of Critical Care. Liver dysfunction associated with artificial nutrition in critically ill patients. *Crit Care* 2007; **11**: R10 [PMID: [17254321](#) DOI: [10.1186/cc5670](#)]
 - 143 **Madnawat H**, Welu AL, Gilbert EJ, Taylor DB, Jain S, Manithody C, Blomenkamp K, Jain AK. Mechanisms of Parenteral Nutrition-Associated Liver and Gut Injury. *Nutr Clin Pract* 2020; **35**: 63-71 [PMID: [31872510](#) DOI: [10.1002/ncp.10461](#)]
 - 144 **Meyerson C**, Naini BV. Something old, something new: liver injury associated with total parenteral nutrition therapy and immune checkpoint inhibitors. *Hum Pathol* 2020; **96**: 39-47 [PMID: [31669893](#) DOI: [10.1016/j.humpath.2019.10.007](#)]
 - 145 **Żalikowska-Gardocka M**, Przybyłkowski A. Review of parenteral nutrition-associated liver disease. *Clin Exp Hepatol* 2020; **6**: 65-73 [PMID: [32728621](#) DOI: [10.5114/ceh.2019.95528](#)]
 - 146 **Grau T**, Bonet A. Caloric intake and liver dysfunction in critically ill patients. *Curr Opin Clin Nutr Metab Care* 2009; **12**: 175-179 [PMID: [19202389](#) DOI: [10.1097/MCO.0b013e3283252f9e](#)]
 - 147 **Salciute-Simene E**, Stasiunaitis R, Ambrasas E, Tutkus J, Milkevicius I, Sostakaite G, Klimasauskas A, Kekstas G. Impact of enteral nutrition interruptions on underfeeding in intensive care unit. *Clin Nutr* 2021; **40**: 1310-1317 [PMID: [32896448](#) DOI: [10.1016/j.clnu.2020.08.014](#)]
 - 148 **Vincent JL**. Relevance of albumin in modern critical care medicine. *Best Pract Res Clin Anaesthesiol* 2009; **23**: 183-191 [PMID: [19653438](#) DOI: [10.1016/j.bpa.2008.11.004](#)]
 - 149 **Wang Y**, Liu S, Liu H, Li W, Lin F, Jiang L, Li X, Xu P, Zhang L, Zhao L, Cao Y, Kang J, Yang J, Li L, Liu X, Li Y, Nie R, Mu J, Lu F, Zhao S, Lu J, Zhao J. SARS-CoV-2 infection of the liver directly contributes to hepatic impairment in patients with COVID-19. *J Hepatol* 2020; **73**: 807-816 [PMID: [32437830](#) DOI: [10.1016/j.jhep.2020.05.002](#)]
 - 150 **Chai X**, Hu L, Zhang Y, Han W, Lu Z, Ke A, Zhou J, Shi G, Fang N, Fan J, Cai J, Lan F. Specific ACE2 expression in cholangiocytes may cause liver damage after 2019-nCoV infection. 2020 Preprint. Available from: bioRxiv:931766v1 [DOI: [10.1101/2020.02.03.931766](#)]
 - 151 **Pirola CJ**, Sookoian S. SARS-CoV-2 virus and liver expression of host receptors: Putative mechanisms of liver involvement in COVID-19. *Liver Int* 2020; **40**: 2038-2040 [PMID: [32352224](#) DOI: [10.1111/liv.14500](#)]
 - 152 **Xu Z**, Shi L, Wang Y, Zhang J, Huang L, Zhang C, Liu S, Zhao P, Liu H, Zhu L, Tai Y, Bai C, Gao T, Song J, Xia P, Dong J, Zhao J, Wang FS. Pathological findings of COVID-19 associated with acute respiratory distress syndrome. *Lancet Respir Med* 2020; **8**: 420-422 [PMID: [32085846](#) DOI: [10.1016/S2213-2600\(20\)30076-X](#)]
 - 153 **Tian S**, Xiong Y, Liu H, Niu L, Guo J, Liao M, Xiao SY. Pathological study of the 2019 novel coronavirus disease (COVID-19) through postmortem core biopsies. *Mod Pathol* 2020; **33**: 1007-1014 [PMID: [32291399](#) DOI: [10.1038/s41379-020-0536-x](#)]
 - 154 **Sonzogni A**, Previtali G, Seghezzi M, Grazia Alessio M, Gianatti A, Licini L, Morotti D, Zerbi P, Carsana L, Rossi R, Lauri E, Pellegrinelli A, Nebuloni M. Liver histopathology in severe COVID 19 respiratory failure is suggestive of vascular alterations. *Liver Int* 2020; **40**: 2110-2116 [PMID: [32654359](#) DOI: [10.1111/liv.14601](#)]
 - 155 **Zhang C**, Shi L, Wang FS. Liver injury in COVID-19: management and challenges. *Lancet Gastroenterol Hepatol* 2020; **5**: 428-430 [PMID: [32145190](#) DOI: [10.1016/S2468-1253\(20\)30057-1](#)]
 - 156 **Mao R**, Qiu Y, He JS, Tan JY, Li XH, Liang J, Shen J, Zhu LR, Chen Y, Iacucci M, Ng SC, Ghosh S, Chen MH. Manifestations and prognosis of gastrointestinal and liver involvement in patients with COVID-19: a systematic review and meta-analysis. *Lancet Gastroenterol Hepatol* 2020; **5**: 667-678 [PMID: [32405603](#) DOI: [10.1016/S2468-1253\(20\)30126-6](#)]
 - 157 **Henry BM**, de Oliveira MHS, Benoit S, Plebani M, Lippi G. Hematologic, biochemical and immune biomarker abnormalities associated with severe illness and mortality in coronavirus disease 2019 (COVID-19): a meta-analysis. *Clin Chem Lab Med* 2020; **58**: 1021-1028 [PMID: [32286245](#) DOI: [10.1515/cclm-2020-0369](#)]
 - 158 **Xie H**, Zhao J, Lian N, Lin S, Xie Q, Zhuo H. Clinical characteristics of non-ICU hospitalized patients with coronavirus disease 2019 and liver injury: A retrospective study. *Liver Int* 2020; **40**: 1321-1326 [PMID: [32239591](#) DOI: [10.1111/liv.14449](#)]
 - 159 **Lei P**, Zhang L, Han P, Zheng C, Tong Q, Shang H, Yang F, Hu Y, Li X, Song Y. Liver injury in patients with COVID-19: clinical profiles, CT findings, the correlation of the severity with liver injury. *Hepatol Int* 2020; **14**: 733-742 [PMID: [32886333](#) DOI: [10.1007/s12072-020-10087-1](#)]
 - 160 **Singh S**, Khan A. Clinical Characteristics and Outcomes of Coronavirus Disease 2019 Among Patients With Preexisting Liver Disease in the United States: A Multicenter Research Network Study. *Gastroenterology* 2020; **159**: 768-771.e3 [PMID: [32376408](#) DOI: [10.1053/j.gastro.2020.04.064](#)]
 - 161 **Mushtaq K**, Khan MU, Iqbal F, Alsoub DH, Chaudhry HS, Ata F, Iqbal P, Elfert K, Balaraju G, Almaslamani M, Al-Ejji K, AlKaabi S, Kamel YM. NAFLD is a predictor of liver injury in COVID-19 hospitalized patients but not of mortality, disease severity on the presentation or progression - The debate continues. *J Hepatol* 2021; **74**: 482-484 [PMID: [33223215](#) DOI: [10.1016/j.jhep.2020.09.006](#)]
 - 162 **Ji D**, Qin E, Xu J, Zhang D, Cheng G, Wang Y, Lau G. Non-alcoholic fatty liver diseases in patients with COVID-19: A retrospective study. *J Hepatol* 2020; **73**: 451-453 [PMID: [32278005](#) DOI: [10.1016/j.jhep.2020.03.044](#)]
 - 163 **Shao J**, Liang Y, Li Y, Ding R, Zhu M, You W, Wang Z, Huang B, Wu M, Zhang T, Li K, Wu W, Wu L, Wang Q, Xia X, Wang S, Lu L. Implications of liver injury in risk-stratification and management of patients with COVID-19. *Hepatol Int* 2021; **15**: 202-212 [PMID: [33548030](#) DOI: [10.1007/s12072-020-10123-0](#)]
 - 164 **Guo H**, Zhang Z, Zhang Y, Liu Y, Wang J, Qian Z, Zou Y, Lu H. Analysis of liver injury factors in 332 patients with COVID-19 in Shanghai, China. *Aging (Albany NY)* 2020; **12**: 18844-18852 [PMID: [33001040](#) DOI: [10.18632/aging.103860](#)]

- 165 **Wang Y**, Gao D, Li X, Xu P, Zhou Q, Yin J, Xu J. Early changes in laboratory tests predict liver function damage in patients with moderate coronavirus disease 2019: a retrospective multicenter study. *BMC Gastroenterol* 2022; **22**: 113 [PMID: 35264110 DOI: 10.1186/s12876-022-02188-y]
- 166 **Fu L**, Fei J, Xu S, Xiang HX, Xiang Y, Hu B, Li MD, Liu FF, Li Y, Li XY, Zhao H, Xu DX. Liver Dysfunction and Its Association with the Risk of Death in COVID-19 Patients: A Prospective Cohort Study. *J Clin Transl Hepatol* 2020; **8**: 246-254 [PMID: 33083246 DOI: 10.14218/JCTH.2020.00043]
- 167 **Zhang H**, Liao YS, Gong J, Liu J, Zhang H. Clinical characteristics and risk factors for liver injury in COVID-19 patients in Wuhan. *World J Gastroenterol* 2020; **26**: 4694-4702 [PMID: 32884226 DOI: 10.3748/wjg.v26.i31.4694]
- 168 **Shen JX**, Zhuang ZH, Zhang QX, Huang JF, Chen GP, Fang YY, Cheng AG. Risk Factors and Prognosis in Patients with COVID-19 and Liver Injury: A Retrospective Analysis. *J Multidiscip Healthc* 2021; **14**: 629-637 [PMID: 33731999 DOI: 10.2147/JMDH.S293378]
- 169 **Wang M**, Yan W, Qi W, Wu D, Zhu L, Li W, Wang X, Ma K, Ni M, Xu D, Wang H, Chen G, Yu H, Ding H, Xing M, Han M, Luo X, Chen T, Guo W, Xi D, Ning Q. Clinical characteristics and risk factors of liver injury in COVID-19: a retrospective cohort study from Wuhan, China. *Hepatol Int* 2020; **14**: 723-732 [PMID: 33026573 DOI: 10.1007/s12072-020-10075-5]
- 170 **Harapan H**, Fajar JK, Supriono S, Soegiarto G, Wulandari L, Seratin F, Prayudi NG, Dewi DP, Monica Elsin MT, Atamou L, Wiranata S, Aprianto DP, Friska E, Sari Firdaus DF, Alaidin M, Wardhani FA, Husnah M, Hidayati NW, Hendriyanti Y, Wardani K, Evatta A, Manugan RA, Pradipto W, Rahmawati A, Tamara F, Mahendra AI, Nainu F, Santoso B, Irawan Primasatya CA, Tjionganata N, Budiman HA. The prevalence, predictors and outcomes of acute liver injury among patients with COVID-19: A systematic review and meta-analysis. *Rev Med Virol* 2022; **32**: e2304 [PMID: 34643006 DOI: 10.1002/rmv.2304]
- 171 **Conti P**, Younes A. Coronavirus COV-19/SARS-CoV-2 affects women less than men: clinical response to viral infection. *J Biol Regul Homeost Agents* 2020; **34**: 339-343 [PMID: 32253888 DOI: 10.23812/Editorial-Conti-3]
- 172 **Li R**, Tang Y, Liang M, Ding J. Liver injury in COVID-19 patients with metabolic syndrome-a narrative review. *Ann Palliat Med* 2021; **10**: 8264-8270 [PMID: 34353107 DOI: 10.21037/apm-21-1398]
- 173 **Krishnan A**, Prichett L, Tao X, Alqahtani SA, Hamilton JP, Mezey E, Strauss AT, Kim A, Potter JJ, Chen PH, Woreta TA. Abnormal liver chemistries as a predictor of COVID-19 severity and clinical outcomes in hospitalized patients. *World J Gastroenterol* 2022; **28**: 570-587 [PMID: 35316959 DOI: 10.3748/wjg.v28.i5.570]
- 174 **Premkumar M**, Kajal K, Kulkarni AV, Gupta A, Divyaveer S. Point-of-Care Echocardiography and Hemodynamic Monitoring in Cirrhosis and Acute-on-Chronic Liver Failure in the COVID-19 Era. *J Intensive Care Med* 2021; **36**: 511-523 [PMID: 33438491 DOI: 10.1177/0885066620988281]
- 175 **Simon R**, Petrișor C, Bodolea C, Csipak G, Oancea C, Golea A. A.B.C. approach proposal for POCUS in COVID-19 critically ill patients. *Med Ultrason* 2021; **23**: 94-102 [PMID: 33245734 DOI: 10.11152/mu-2733]
- 176 **Ady J**, Fong Y. Imaging for infection: from visualization of inflammation to visualization of microbes. *Surg Infect (Larchmt)* 2014; **15**: 700-707 [PMID: 25402672 DOI: 10.1089/sur.2014.029]
- 177 **Evans L**, Rhodes A, Alhazzani W, Antonelli M, Coopersmith CM, French C, Machado FR, McIntyre L, Ostermann M, Prescott HC, Schorr C, Simpson S, Wiersinga WJ, Alshamsi F, Angus DC, Arabi Y, Azevedo L, Beale R, Beilman G, Belley-Cote E, Burry L, Cecconi M, Centofanti J, Coz Yataco A, De Waele J, Dellinger RP, Doi K, Du B, Estenssoro E, Ferrer R, Gomersall C, Hodgson C, Möller MH, Iwashyna T, Jacob S, Kleinpell R, Klompas M, Koh Y, Kumar A, Kwizera A, Lobo S, Masur H, McGloughlin S, Mehta S, Mehta Y, Mer M, Nunnally M, Oczkowski S, Osborn T, Papanthanasoglou E, Perner A, Puskarich M, Roberts J, Schweickert W, Seckel M, Sevransky J, Sprung CL, Welte T, Zimmerman J, Levy M. Surviving sepsis campaign: international guidelines for management of sepsis and septic shock 2021. *Intensive Care Med* 2021; **47**: 1181-1247 [PMID: 34599691 DOI: 10.1007/s00134-021-06506-y]
- 178 **Tajiri K**, Shimizu Y. Practical guidelines for diagnosis and early management of drug-induced liver injury. *World J Gastroenterol* 2008; **14**: 6774-6785 [PMID: 19058303 DOI: 10.3748/wjg.14.6774]
- 179 **Hajjar LA**, Costa IBSDS, Rizk SI, Biselli B, Gomes BR, Bittar CS, de Oliveira GQ, de Almeida JP, de Oliveira Bello MV, Garzillo C, Leme AC, Elena M, Val F, de Almeida Lopes M, Lacerda MVG, Ramires JAF, Kalil Filho R, Teboul JL, Landoni G. Intensive care management of patients with COVID-19: a practical approach. *Ann Intensive Care* 2021; **11**: 36 [PMID: 33604873 DOI: 10.1186/s13613-021-00820-w]
- 180 **Devlin JW**, Skrobik Y, Gélinas C, Needham DM, Slooter AJC, Pandharipande PP, Watson PL, Weinhouse GL, Nunnally ME, Rochweg B, Balas MC, van den Boogaard M, Bosma KJ, Brummel NE, Chanques G, Denehy L, Drouot X, Fraser GL, Harris JE, Joffe AM, Kho ME, Kress JP, Lanphere JA, McKinley S, Neufeld KJ, Pisani MA, Payen JF, Pun BT, Puntillo KA, Riker RR, Robinson BRH, Shehabi Y, Szumita PM, Winkelman C, Centofanti JE, Price C, Nikayin S, Misak CJ, Flood PD, Kiedrowski K, Alhazzani W. Clinical Practice Guidelines for the Prevention and Management of Pain, Agitation/Sedation, Delirium, Immobility, and Sleep Disruption in Adult Patients in the ICU. *Crit Care Med* 2018; **46**: e825-e873 [PMID: 30113379 DOI: 10.1097/CCM.0000000000003299]
- 181 **Barazzoni R**, Bischoff SC, Breda J, Wickramasinghe K, Krznaric Z, Nitzan D, Pirlich M, Singer P; endorsed by the ESPEN Council. ESPEN expert statements and practical guidance for nutritional management of individuals with SARS-CoV-2 infection. *Clin Nutr* 2020; **39**: 1631-1638 [PMID: 32305181 DOI: 10.1016/j.clnu.2020.03.022]
- 182 **Vanwijngaerden YM**, Langouche L, Brunner R, Debaveye Y, Gielen M, Casaer M, Liddle C, Coulter S, Wouters PJ, Wilmer A, Van den Berghe G, Mesotten D. Withholding parenteral nutrition during critical illness increases plasma bilirubin but lowers the incidence of biliary sludge. *Hepatology* 2014; **60**: 202-210 [PMID: 24213952 DOI: 10.1002/hep.26928]
- 183 **Bornstein SR**, Rubino F, Khunti K, Mingrone G, Hopkins D, Birkenfeld AL, Boehm B, Amiel S, Holt RI, Skyler JS, DeVries JH, Renard E, Eckel RH, Zimmet P, Alberti KG, Vidal J, Geloneze B, Chan JC, Ji L, Ludwig B. Practical recommendations for the management of diabetes in patients with COVID-19. *Lancet Diabetes Endocrinol* 2020; **8**: 546-550 [PMID: 32334646 DOI: 10.1016/S2213-8587(20)30152-2]
- 184 **Mesotten D**, Wauters J, Van den Berghe G, Wouters PJ, Milants I, Wilmer A. The effect of strict blood glucose control on biliary sludge and cholestasis in critically ill patients. *J Clin Endocrinol Metab* 2009; **94**: 2345-2352 [PMID: 19366849]

- DOI: [10.1210/jc.2008-2579](https://doi.org/10.1210/jc.2008-2579)]
- 185 **Fix OK**, Hameed B, Fontana RJ, Kwok RM, McGuire BM, Mulligan DC, Pratt DS, Russo MW, Schilsky ML, Verna EC, Loomba R, Cohen DE, Bezerra JA, Reddy KR, Chung RT. Clinical Best Practice Advice for Hepatology and Liver Transplant Providers During the COVID-19 Pandemic: AASLD Expert Panel Consensus Statement. *Hepatology* 2020; **72**: 287-304 [PMID: [32298473](https://pubmed.ncbi.nlm.nih.gov/32298473/) DOI: [10.1002/hep.31281](https://doi.org/10.1002/hep.31281)]
 - 186 **Williamson K**, Wahl MS, Mycyk MB. Direct comparison of 20-hour IV, 36-hour oral, and 72-hour oral acetylcysteine for treatment of acute acetaminophen poisoning. *Am J Ther* 2013; **20**: 37-40 [PMID: [23299230](https://pubmed.ncbi.nlm.nih.gov/23299230/) DOI: [10.1097/MJT.0b013e318250f829](https://doi.org/10.1097/MJT.0b013e318250f829)]
 - 187 **Davenport A**, Honore PM. Continuous renal replacement therapy under special conditions like sepsis, burn, cardiac failure, neurotrauma, and liver failure. *Semin Dial* 2021; **34**: 457-471 [PMID: [34448261](https://pubmed.ncbi.nlm.nih.gov/34448261/) DOI: [10.1111/sdi.13002](https://doi.org/10.1111/sdi.13002)]
 - 188 **Katagiri D**. For safe and adequate blood purification therapy in severe COVID-19 – what we have learned so far. *Glob Health Med* 2022; **4**: 94-100 [PMID: [35586758](https://pubmed.ncbi.nlm.nih.gov/35586758/) DOI: [10.35772/ghm.2022.01004](https://doi.org/10.35772/ghm.2022.01004)]
 - 189 **Memish ZA**, Faqih F, Alharthy A, Alqahtani SA, Karakitsos D. Plasma exchange in the treatment of complex COVID-19-related critical illness: controversies and perspectives. *Int J Antimicrob Agents* 2021; **57**: 106273 [PMID: [33370568](https://pubmed.ncbi.nlm.nih.gov/33370568/) DOI: [10.1016/j.ijantimicag.2020.106273](https://doi.org/10.1016/j.ijantimicag.2020.106273)]
 - 190 **Fernandez J**, Gratacos-Ginès J, Olivas P, Costa M, Nieto S, Mateo D, Sánchez MB, Aguilar F, Bassegoda O, Ruiz P, Caballol B, Pocurull A, Llach J, Mustieles MJ, Cid J, Reverter E, Toapanta ND, Hernández-Tejero M, Martínez JA, Claria J, Fernández C, Mensa J, Arroyo V, Castro P, Lozano M; Covid Clinic Critical Care (CCCC) Group. Plasma Exchange: An Effective Rescue Therapy in Critically Ill Patients With Coronavirus Disease 2019 Infection. *Crit Care Med* 2020; **48**: e1350-e1355 [PMID: [32833695](https://pubmed.ncbi.nlm.nih.gov/32833695/) DOI: [10.1097/CCM.0000000000004613](https://doi.org/10.1097/CCM.0000000000004613)]
 - 191 **Zhou Z**, Kuang H, Ma Y, Zhang L. Application of extracorporeal therapies in critically ill COVID-19 patients. *J Zhejiang Univ Sci B* 2021; **22**: 701-717 [PMID: [34514751](https://pubmed.ncbi.nlm.nih.gov/34514751/) DOI: [10.1631/jzus.B2100344](https://doi.org/10.1631/jzus.B2100344)]



Published by **Baishideng Publishing Group Inc**
7041 Koll Center Parkway, Suite 160, Pleasanton, CA 94566, USA

Telephone: +1-925-3991568

E-mail: bpgoffice@wjgnet.com

Help Desk: <https://www.f6publishing.com/helpdesk>

<https://www.wjgnet.com>

