

World Journal of *Gastroenterology*

World J Gastroenterol 2022 December 28; 28(48): 6791-6961



REVIEW

- 6791** COVID-19 vaccination and liver disease
Ozaka S, Kobayashi T, Mizukami K, Murakami K
- 6811** Mechanism and potential treatments for gastrointestinal dysfunction in patients with COVID-19
Yao Y, Liu ZJ, Zhang YK, Sun HJ
- 6827** Clinical diagnosis and management of pancreatic cancer: Markers, molecular mechanisms, and treatment options
Zhang CY, Liu S, Yang M
- 6846** Bile acids and microbes in metabolic disease
Sah DK, Arjunan A, Park SY, Jung YD

MINIREVIEWS

- 6867** Recent advances in the management of autoimmune pancreatitis in the era of artificial intelligence
Mack S, Flattet Y, Bichard P, Frossard JL
- 6875** Molecular mechanisms implicated in SARS-CoV-2 liver tropism
Quarleri J, Delpino MV
- 6888** Current status of novel biologics and small molecule drugs in the individualized treatment of inflammatory bowel disease
Xu YH, Zhu WM, Guo Z
- 6900** Confusion and prospects for carcinogenesis of gastric adenoma and dysplasia: What is the correct answer currently?
Kinami S, Yamada S, Takamura H
- 6909** Nuclear factor erythroid 2-related factor 2-mediated signaling and metabolic associated fatty liver disease
Bukke VN, Moola A, Serviddio G, Vendemiale G, Bellanti F
- 6922** Current and future perspectives on acute-on-chronic liver failure: Challenges of transplantation, machine perfusion, and beyond
Della Guardia B, Boteon APCS, Matielo CEL, Felga G, Boteon YL

ORIGINAL ARTICLE

Basic Study

- 6935** Bladder-colon chronic cross-sensitization involves neuro-glial pathways in male mice
Atmani K, Wuestenberghs F, Baron M, Bouleté I, Guérin C, Bahloul W, Vaudry D, do Rego JC, Cornu JN, Leroi AM, Coëffier M, Meleine M, Gourcerol G

Retrospective Study

- 6950** Clinical features and long-term outcomes of patients with colonic oligopolyposis of unknown etiology

Feldman D, Rodgers-Fouche L, Hicks S, Chung DC

ABOUT COVER

Editorial Board of *World Journal of Gastroenterology*, Xi-Dai Long, MD, PhD, Professor, Department of Pathology, the Affiliated Hospital of Youjiang Medical University for Nationalities, BOSE 533000, Guangxi, China.
sjtulongxd@263.net

AIMS AND SCOPE

The primary aim of *World Journal of Gastroenterology* (WJG, *World J Gastroenterol*) is to provide scholars and readers from various fields of gastroenterology and hepatology with a platform to publish high-quality basic and clinical research articles and communicate their research findings online. WJG mainly publishes articles reporting research results and findings obtained in the field of gastroenterology and hepatology and covering a wide range of topics including gastroenterology, hepatology, gastrointestinal endoscopy, gastrointestinal surgery, gastrointestinal oncology, and pediatric gastroenterology.

INDEXING/ABSTRACTING

The WJG is now abstracted and indexed in Science Citation Index Expanded (SCIE, also known as SciSearch®), Current Contents/Clinical Medicine, Journal Citation Reports, Index Medicus, MEDLINE, PubMed, PubMed Central, Scopus, Reference Citation Analysis, China National Knowledge Infrastructure, China Science and Technology Journal Database, and Superstar Journals Database. The 2022 edition of Journal Citation Reports® cites the 2021 impact factor (IF) for WJG as 5.374; IF without journal self cites: 5.187; 5-year IF: 5.715; Journal Citation Indicator: 0.84; Ranking: 31 among 93 journals in gastroenterology and hepatology; and Quartile category: Q2. The WJG's CiteScore for 2021 is 8.1 and Scopus CiteScore rank 2021: Gastroenterology is 18/149.

RESPONSIBLE EDITORS FOR THIS ISSUE

Production Editor: *Yu-Xi Chen*; Production Department Director: *Xu Guo*; Editorial Office Director: *Jia-Ru Fan*.

NAME OF JOURNAL

World Journal of Gastroenterology

ISSN

ISSN 1007-9327 (print) ISSN 2219-2840 (online)

LAUNCH DATE

October 1, 1995

FREQUENCY

Weekly

EDITORS-IN-CHIEF

Andrzej S Tarnawski

EDITORIAL BOARD MEMBERS

<http://www.wjgnet.com/1007-9327/editorialboard.htm>

PUBLICATION DATE

December 28, 2022

COPYRIGHT

© 2022 Baishideng Publishing Group Inc

INSTRUCTIONS TO AUTHORS

<https://www.wjgnet.com/bpg/gerinfo/204>

GUIDELINES FOR ETHICS DOCUMENTS

<https://www.wjgnet.com/bpg/GerInfo/287>

GUIDELINES FOR NON-NATIVE SPEAKERS OF ENGLISH

<https://www.wjgnet.com/bpg/gerinfo/240>

PUBLICATION ETHICS

<https://www.wjgnet.com/bpg/GerInfo/288>

PUBLICATION MISCONDUCT

<https://www.wjgnet.com/bpg/gerinfo/208>

ARTICLE PROCESSING CHARGE

<https://www.wjgnet.com/bpg/gerinfo/242>

STEPS FOR SUBMITTING MANUSCRIPTS

<https://www.wjgnet.com/bpg/GerInfo/239>

ONLINE SUBMISSION

<https://www.f6publishing.com>



Confusion and prospects for carcinogenesis of gastric adenoma and dysplasia: What is the correct answer currently?

Shinichi Kinami, Sohsuke Yamada, Hiroyuki Takamura

Specialty type: Gastroenterology and hepatology

Provenance and peer review: Invited article; Externally peer reviewed.

Peer-review model: Single blind

Peer-review report's scientific quality classification

Grade A (Excellent): 0
Grade B (Very good): B, B
Grade C (Good): 0
Grade D (Fair): 0
Grade E (Poor): 0

P-Reviewer: Noh CK, South Korea; Vieth M, Germany

Received: September 15, 2022

Peer-review started: September 15, 2022

First decision: October 30, 2022

Revised: November 7, 2022

Accepted: December 5, 2022

Article in press: December 5, 2022

Published online: December 28, 2022



Shinichi Kinami, Department of Surgical Oncology, Kanazawa Medical University, Kahoku-gun 920-0293, Ishikawa, Japan

Sohsuke Yamada, Department of Clinical Pathology, Kanazawa Medical University, Uchinada 920-0293, Ishikawa, Japan

Hiroyuki Takamura, Department of Surgical Oncology, Kanazawa Medical University, Kahoku-gun 920-0293, Ishikawa, Japan

Corresponding author: Shinichi Kinami, MD, PhD, Professor, Department of Surgical Oncology, Kanazawa Medical University, 1-1 Daigaku, Uchinada-machi, Kahoku-gun 920-0293, Ishikawa, Japan. kinami@kanazawa-med.ac.jp

Abstract

There are differences in the diagnoses of superficial gastric lesions between Japan and other countries. In Japan, superficial gastric lesions are classified as adenoma or cancer. Conversely, outside Japan, the same lesion is classified as low-grade dysplasia (LGD), high-grade dysplasia, or invasive neoplasia. Gastric carcinogenesis occurs mostly *de novo*, and the adenoma-carcinoma sequence does not appear to be the main pathway of carcinogenesis. Superficial gastric tumors can be roughly divided into the APC mutation type and the TP53 mutation type, which are mutually exclusive. APC-type tumors have low malignancy and develop into LGD, whereas TP53-type tumors have high malignancy and are considered cancerous even if small. For lesions diagnosed as category 3 or 4 in the Vienna classification, it is desirable to perform complete *en bloc* resection by endoscopic submucosal dissection followed by staging. If there is lymphovascular or submucosal invasion after mucosal resection, additional surgical treatment of gastrectomy with lymph node dissection is required. In such cases, function-preserving curative gastrectomy guided by sentinel lymph node biopsy may be a good alternative.

Key Words: Gastric adenoma; Low-grade dysplasia; High-grade dysplasia; Intramucosal carcinoma; Submucosal carcinoma; Endoscopic submucosal dissection

©The Author(s) 2022. Published by Baishideng Publishing Group Inc. All rights reserved.

Core Tip: Gastric carcinogenesis occurs mostly *de novo*. Superficial gastric tumors can be roughly divided into the *APC* mutation type and the *TP53* mutation type, which are mutually exclusive. *APC*-type tumors have low malignancy and develop into low-grade dysplasia, whereas *TP53*-type tumors have high malignancy and are considered cancerous even if they are small. For lesions diagnosed as category 3 or 4 in the Vienna classification system, endoscopic submucosal dissection and staging should be performed. If the tumor is diagnosed with lymphovascular or submucosal invasion, additional surgical treatment of gastrectomy with lymph node dissection is required.

Citation: Kinami S, Yamada S, Takamura H. Confusion and prospects for carcinogenesis of gastric adenoma and dysplasia: What is the correct answer currently? *World J Gastroenterol* 2022; 28(48): 6900-6908

URL: <https://www.wjgnet.com/1007-9327/full/v28/i48/6900.htm>

DOI: <https://dx.doi.org/10.3748/wjg.v28.i48.6900>

INTRODUCTION

Gastric cancer is one of the most common cancers worldwide. However, the incidence of gastric cancer declined in many Western countries during the 20th century. Japan was one of the countries with a high incidence of gastric cancer, but the incidence is also decreasing. This fact proves that *Helicobacter pylori* (*H. pylori*) infection is deeply involved in the development of gastric cancer[1]. In Japan, the water supply and sewerage systems were completed in the 1960s, and the *H. pylori* infection rate has decreased among the generations born subsequently[2,3]. Most patients with gastric cancer in Japan are elderly, and the incidence of gastric cancer among age groups with low *H. pylori* infection rates is low. Besides *H. pylori*, many factors are known to be involved in gastric carcinogenesis. These include salt intake, smoking, exposure to N-nitroso compounds, and Epstein-Barr virus infection[4-7]. However, the molecular mechanisms leading to gastric carcinogenesis are not well understood.

In contrast, the molecular mechanism leading to colorectal cancer has been clarified to some extent. Colorectal cancer is one of the most common cancers worldwide. Many colorectal cancers are thought to develop from adenomas and serrated polyps through the adenoma-carcinoma sequence. The molecular mechanism of colorectal carcinogenesis has long been a subject of interest and has been well-studied, with genetic and epigenetic changes in oncogenes and tumor suppressor genes identified in considerable detail.

There are various reasons for this difference in the understanding of the molecular mechanisms between gastric carcinogenesis and colorectal carcinogenesis. The most important is that gastric carcinogenesis is often of the *de novo* type and does not necessarily follow the adenoma-carcinoma sequence, making it difficult to examine the genetic changes from benign lesions to carcinoma in a sequential manner. Another reason is that the diagnostic criteria for gastric adenomas are vague and differ between countries in the East and West.

In this article, we describe the issues surrounding gastric adenomas, the molecular mechanisms of carcinogenesis that have been identified to date, and future perspectives.

DIAGNOSTIC CRITERIA FOR GASTRIC ADENOMA

It has long been known that some benign superficial gastric lesions are difficult to distinguish from adenocarcinoma. They are conventionally called atypical epithelial lesions or Ila-subtype[8,9]. These cases were organized and given the diagnostic name "gastric adenoma[10]" approximately during the time the World Health Organization (WHO) histological classification of gastric cancer was established in the 1970s. In Japan, superficial gastric lesions are classified into adenoma and cancer and a treatment policy is adopted: The cancer is resected, small adenomas are followed up, and large adenomas are regarded as early gastric cancer (EGC) and treated by mucosal resection. In Japan, gastric adenomas are classified mainly according to glandular structure, with occasional reference to immunohistochemical mucin staining. Recently, foveolar-type gastric adenomas with a raspberry-like appearance in *H. pylori*-negative cases have become a contentious issue[11,12]. Conversely, outside Japan, dysplasia is used to describe lesions that are difficult to distinguish from benign to malignant. Dysplasia is defined as a histologically probable neoplastic lesion without evidence of invasive growth within the specimen. Intraepithelial neoplasia is a synonymous condition. Dysplasia is classified into low-grade dysplasia (LGD) and high-grade dysplasia (HGD) according to the degree of cellular atypia[13]. Gastric adenoma exists outside Japan but mainly refers to a protruding tumor.

Therefore, there are differences in the diagnoses of superficial gastric lesions between Japan and other countries. Table 1 also shows the classification of gastric lesions according to the WHO classification, Vienna classification proposed at the worldwide pathologists' consensus meeting[14], and revised

Table 1 The classifications of gastric adenoma of the Japanese Gastric Cancer Association and gastric superficial lesions of the WHO classification and the Vienna classification

Classification	Code	Diagnosis	Subtype	Subtype 2
JGCA[16]		Gastric adenoma	Intestinal type	
			Gastric type	Pyloric gland type
				Foveolar type
WHO 2019[13]	8148/0	Glandular intraepithelial neoplasia, low grade		
	8148/2	Glandular intraepithelial neoplasia, high grade		
	8213/0	Serrated dysplasia, low grade		
	8213/2	Serrated dysplasia, high grade	Intestinal-type dysplasia	
			Foveolar-type (gastric type) dysplasia	
			Gastric pit/crypt dysplasia	
	8144/0	Intestinal-type adenoma, low grade		
	8114/2	Intestinal-type adenoma, low grade	Sporadic intestinal-type gastric adenoma	
			Syndromic intestinal-type gastric adenoma	
	8210/0	Adenomatous polyp, low-grade dysplasia		
	8210/2	Adenomatous polyp, high-grade dysplasia		
Vienna[14]	3	Non-invasive low-grade neoplasia	Low-grade adenoma/dysplasia	
	4	Non-invasive high-grade neoplasia		
	4.1		High-grade adenoma/dysplasia	
	4.2		Non-invasive carcinoma (carcinoma <i>in situ</i>)	
	4.3		Suspicion of invasive carcinoma	
	5	Invasive neoplasia		
	5.1		Intramucosal carcinoma	
	5.2		Submucosal carcinoma or beyond	
Revised Vienna[15]	3	Mucosal low-grade neoplasia	Low-grade adenoma/dysplasia	
	4	Mucosal high-grade neoplasia		
	4.1		High-grade adenoma/dysplasia	
	4.2		Non-invasive carcinoma (carcinoma <i>in situ</i>)	
	4.3		Suspicious for invasive carcinoma	
	4.4		Intramucosal carcinoma	
	5	Submucosal invasion by carcinoma		

JGCA: Japanese Gastric Cancer Association.

Vienna classification[15]. **Figure 1** shows the relationship between the diagnosis of gastric lesions and the Japanese classification of gastric carcinoma[16], WHO classification, and Vienna classification. The diagnosis of adenomas in Japan is probably the most limited. It is difficult to determine the correct classification system because they all have advantages and disadvantages, and there are also differences in the frequency of encountering lesions and treatment strategies. In Japan, where the prevalence of gastric cancer is high, clinicians perform numerous endoscopic screenings. They often find EGCs, and targeted biopsy is frequently used for definitive diagnosis. Pathologists and clinicians must determine benign or malignant lesions from biopsies and determine cancer based on cellular and structural atypia. As the presence or absence of submucosal invasion is not required under the Japanese classification,

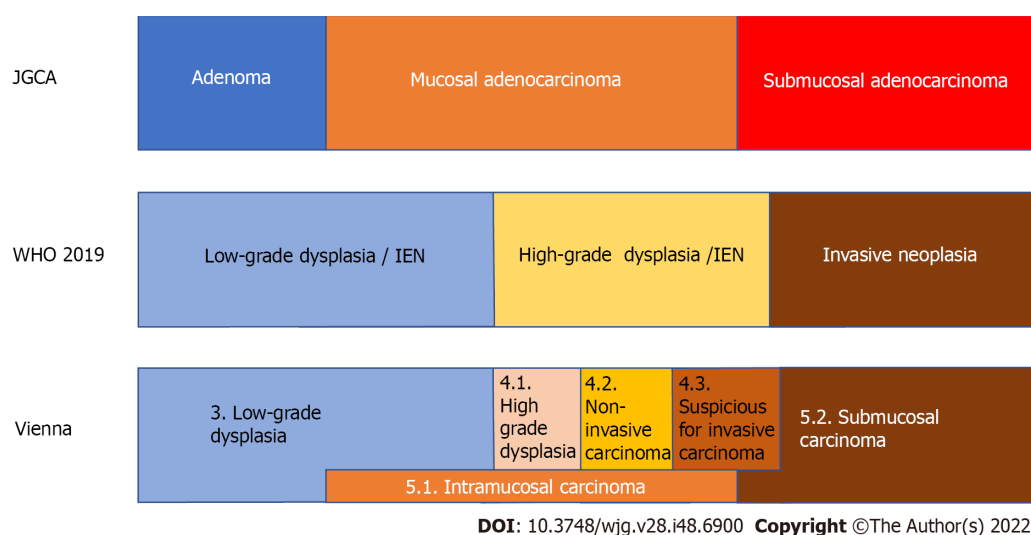


Figure 1 The relationship of the diagnosis of superficial gastric lesions between the Japanese classification of gastric carcinoma by the Japanese Gastric Cancer Association, the WHO classification, and the Vienna classification. In Japan, gastric cancer is diagnosed based on cellular and structural atypia. On the other hand, outside Japan, dysplasia is used to describe lesions that are histologically probable neoplastic lesions without evidence of invasive growth. Intraepithelial neoplasia is a synonymous condition. Therefore, all mucosal and some submucosal cancers diagnosed by the Japanese Gastric Cancer Association criteria are diagnosed as dysplasia outside Japan. The original Vienna classification is the answer to this discrepancy by setting non-invasive carcinoma and intramucosal carcinoma. IEN: Intraepithelial neoplasia; JGCA: Japanese Gastric Cancer Association.

cancer can be diagnosed without performing complete resection and determining the presence or absence of submucosal invasion. However, intramucosal carcinoma is also considered a cancer, although this is not accepted by some pathologists in Western countries. Conversely, according to criteria other than those of the Japanese Gastric Cancer Association (JGCA), it is difficult to obtain tissue from the submucosal layer with endoscopic biopsy; therefore, pathological judgment using biopsy material can only be performed in dysplasia, making it difficult to diagnose cancer using biopsy. Pathologists cannot determine gastric cancer without complete resection of the lesion, and intramucosal cancer is not defined as cancer. Although intramucosal carcinoma has a good prognosis and rarely metastasizes, lymph node metastasis still occurs in 2% of cases[17]; if left untreated, it can progress to submucosal and advanced cancer[18]. Therefore, intramucosal cancer should still be considered life-threatening. In Japan, adenomas are regarded as “benign lesions”; therefore, even among Japanese pathologists, it is difficult to distinguish high-grade intestinal-type adenomas and foveolar-type adenomas from cancer, and discrepancies in diagnosis sometimes occur.

DOES GASTRIC ADENOMA BECOME CANCER?

Many colorectal cancers are thought to develop from adenomas and serrated polyps. Do gastric adenomas become cancers, similar to colorectal cancer?

Some gastric lesions might be cancerous after mucosal resection, even if the preoperative diagnosis is adenoma using targeted biopsy. The frequency of such cases varies in the literature; however, there are reports of a reasonably high rate; therefore, caution should be exercised[19]. It is sometimes difficult to distinguish between high-grade intestinal-type adenomas and very well-differentiated tubular adenocarcinomas, and sampling errors may occur in targeted biopsies[19]. In contrast, adenocarcinoma in adenoma, unlike colorectal cancer, is rarely observed in low-grade intestinal-type adenoma, and it is rare for low-grade adenoma of Vienna classification category 3 to become malignant[20]. In addition, gastric minute carcinomas without adenomatous components are common. Gastric carcinogenesis is mostly *de novo*, and the adenoma-carcinoma sequence does not appear to be the main pathway of carcinogenesis.

The Cancer Genome Atlas system classifies gastric cancer into four categories based on molecular biological characteristics[21]. A summary of this classification system is presented in Table 2. The molecular biological features revealed here help in the consideration of treatment strategies for advanced gastric cancer; however, this system does not provide insight into genetic alterations in the early stages of carcinogenesis.

The pathway for the accumulation of gene mutations leading to gastric carcinogenesis is not as clear as that in colorectal cancer. This may be mainly due to the lack of a clear adenoma-carcinoma sequence in the stomach and the discrepancy in the diagnostic criteria for gastric adenoma and intramucosal carcinoma between countries in the East and West.

Table 2 Brief summary of The Cancer Genome Atlas classification

Type	Chromosomal instability	EBV	Microsatellite instability	Genomically stable
Percentage	50%	9%	21%	20%
Profile of patients		Male prevalence	Elderly age	Younger age
Location	GEJ, cardia	Corpus or fundus	Antrum	Distal location
Lauren type	Intestinal		Intestinal	Poorly cohesive
Other pathological feature	DNA aneuploidy	Carcinoma with lymphoid stroma		
Prognosis			Favorable	Worst
Genetic features	<i>TP53</i> mutation	Extensive DNA promoter methylation	<i>MLH1</i> promoter hypermethylation	Low copy number alterations and mutational burden
	Amplification of <i>TKR</i>	<i>CDKN2A</i> promoter hypermethylation	High mutational burden	<i>ARID1</i> , <i>RHOA</i> , <i>CDH1</i> mutations
		<i>PIK3CA</i> , <i>ARID1A</i> , <i>BCOR</i> mutations		<i>CLDN18-ARHGAP26</i> fusion in 15%

TCGA: The Cancer Genome Atlas; EBV: Epstein-Barr virus; GEJ: Esophagogastric junction.

GENETIC MUTATION AND CANCERIZATION OF GASTRIC ADENOMA AND DYSPLASIA

Recent advances in genetic analysis have provided insights into gene mutations in adenomas and dysplasia, and the pathway to carcinogenesis in adenomas and dysplasia is becoming more clear.

Fassan *et al*[22] investigated the mutational status of HGD and EGC using high-throughput mutation profiling. Mutations in *APC*, *ATM*, *FGFR3*, *PIK3CA*, *RB1*, *STK11*, and *TP53* were confirmed in both HGD and EGC. Lim *et al*[23] examined the mutation profiles of LGD using whole-exome sequencing and confirmed that *APC* mutations occur in LGD. Lee *et al*[24] examined *APC* mutations in adenomas, dysplasias, and adenocarcinomas. They found that *APC* mutations play an essential role in the pathogenesis of adenoma and dysplasia but have a limited role in the progression to adenocarcinoma. Rokutan *et al*[25] investigated the mutational status of LGD, HGD, and intramucosal carcinoma using targeted deep DNA sequencing. They found that *APC* mutations and *TP53* mutations were highly prevalent in these lesions and were the initial mutations in the tumors. *TP53* mutations were also found in microscopic intramucosal carcinomas of 1 mm and 3 mm. *APC* mutations were found in all the LGDs examined. In contrast, no *TP53* mutations were detected in the LGD group. *APC* mutations and *TP53* mutations are frequently observed in patients with HGD, but they are mutually exclusive.

Based on these results, superficial gastric tumors can be roughly divided into the *APC* mutation type and the *TP53* mutation type. *APC*-type tumors have low malignancy and develop into LGD, whereas *TP53*-type tumors have high malignancy and are judged as cancerous even if they are small[25]. It is still unclear whether *APC*-type LGD progresses into HGD or whether *APC*-type HGD progresses into cancer. In contrast, it is reasonable to treat *TP53*-type HGD as cancer. This finding is illustrated in Figure 2; it also shows the translation of this to the JGCA criteria. Many Japanese gastric cancer specialists believe that all mucosal cancers progress from submucosal to advanced. However, some mucosal cancers may not progress to submucosal cancer, although they may progress laterally.

HOW SHOULD GASTRIC TUMORS BE TREATED?

Superficial gastric tumors are often observed in *H. pylori*-positive stomachs under numerous gastroscopies. There is still no consensus regarding the treatment of these tumors.

In Japan, EGC is often detected, and endoscopic submucosal dissection (ESD) is frequently performed; therefore, most superficial gastric tumors, including gastric adenomas, are resected by ESD [19]. The treatment policy is the same in China and South Korea, where there are many *H. pylori*-positive individuals. In contrast, in Western countries, the treatment of dysplasia is not always standardized due to the small number of *H. pylori*-positive patients, low number of gastroscopies performed, and lack of widespread use of ESD. In the Vienna classification[14,15], a target biopsy diagnosis is set from category 1 to 5, with category 1 being negative for neoplasia and should undergo no treatment, category 2 is indefinite for neoplasia and should undergo repeat biopsy, and category 5 is indicated for surgical resection. The problem is the treatment of categories 3 and 4. The revised Vienna classification[15] recommends endoscopic resection or follow-up for category 3 and endoscopic or surgical local resection

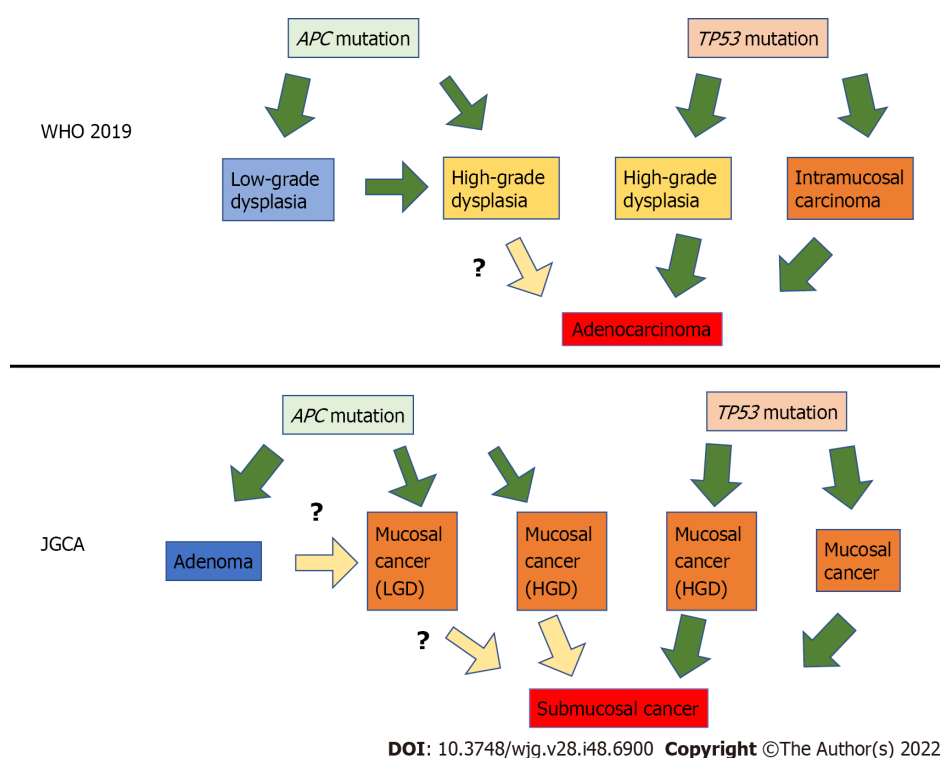
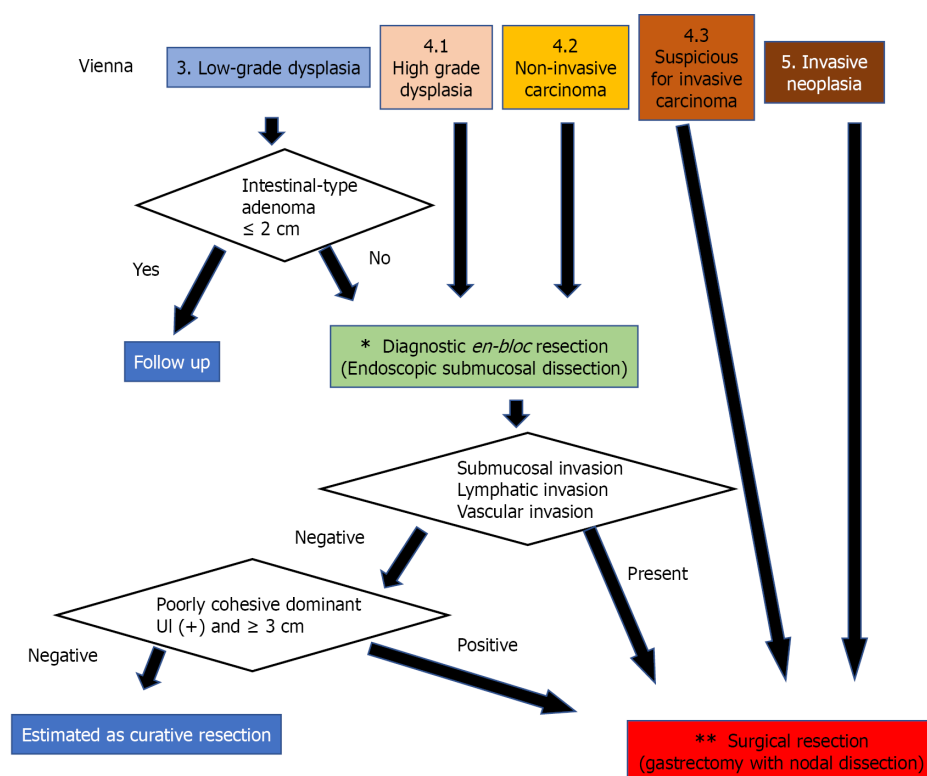


Figure 2 The diagram assuming the relationship between gene mutations and gastric carcinogenesis. Superficial gastric tumors can be roughly divided into two types by specific gene mutations: The *APC* mutation type and the *TP53* mutation type. *APC*-type tumors have low malignancy and develop into low-grade dysplasia, whereas *TP53*-type tumors have high malignancy and are considered cancerous even if small. JGCA: Japanese Gastric Cancer Association; HGD: High-grade dysplasia; LGD: Low-grade dysplasia.

for category 4. The 2012 MAPS guideline[26] states that “patients with endoscopically visible HGD or carcinoma should undergo staging and adequate management”. According to this, category 3 should be followed up, and category 4 should undergo excision. In contrast, the 2019 MAPS II guideline[27] states that “patients with an endoscopically visible lesion harboring LGD, HGD, or carcinoma should undergo staging and treatment”. Due to the uncertainty of biopsy diagnosis[28,29], it is assumed that LGD would be upgraded to HGD or adenocarcinoma after resection. Therefore, treatment is also required for LGD [27], and category 3 is targeted for diagnostic treatment. However, staging and treatment methods have not been described. Considering the invasiveness of surgical resection, it is desirable to perform complete *en bloc* resection by ESD first[30] and then perform staging. Subsequent treatment should follow the Japanese Gastric Cancer Treatment Guidelines[31]. If the tumor is a well to moderately differentiated mucosal cancer with no lymphovascular invasion, treatment is completed, and if lymphovascular invasion or submucosal invasion is found, additional surgical treatment of gastrectomy with lymph node dissection is required.

Conversely, do we need ESD for all category 3 cases? Endoscopic resection of colorectal adenomas reduces the incidence of colorectal cancer, which provides evidence that the adenoma-carcinoma sequence is an essential pathway for colorectal carcinogenesis. In contrast, low-grade intestinal adenomas, which are rarely associated with adenocarcinomas, are unlikely to become cancerous even if left untreated. Upgrading to HGD or adenocarcinoma has been reported to be less than 10% after follow-up for adenoma and LGD[20,32], and the possibility of regression with *H. pylori* eradication therapy has also been reported[32]. For these reasons, category 3 adenomas can be safely treated with observation; if the adenoma meets the intestinal type in the JGCA criteria and is less than 2 cm in size, resection may not be necessary. However, a case of gastric-type adenoma that was adenocarcinoma in adenoma with submucosal invasion has been reported[33], and follow-up of gastric-type adenoma may not always be safe. In addition, the safety of observing LGDs that fall into mucosal cancer in the JGCA criteria is not guaranteed. In the future, further understanding of the relationship between genetic mutations in LGD and the natural history of lesions will provide profiles for safe follow-up of category 3 Lesions. Category 3 patients with *APC* mutations may be observed. However, at this time, category 3 adenomas, other than intestinal-type adenomas, seem to have no choice but to undergo complete diagnostic resection with ESD.

The results are summarized in Figure 3. Since category 3 and 4 Lesions are highly likely to be mucosal adenocarcinomas according to the JGCA criteria, complete *en bloc* resection of the mucosal layer is desirable even for diagnostic purposes, and ESD is appropriate. However, ESD is a complicated procedure. Surgical mucosal resection and laparoscopic intragastric surgery may also be acceptable in



DOI: 10.3748/wjg.v28.i48.6900 Copyright ©The Author(s) 2022.

Figure 3 The strategy for diagnosis, staging, and treatment of gastric dysplasia and cancer according to the Vienna classification. Since category 3 and 4 Lesions are highly likely to be mucosal adenocarcinomas according to the Japanese Gastric Cancer Association (JGCA) criteria, complete *en bloc* resection of the mucosal layer is desirable for diagnosis and initial treatment. However, a small part of category 3, such as a small intestinal-type adenoma judged by the JGCA criteria, can be followed up. In contrast, category 5 corresponds to submucosal adenocarcinoma according to the JGCA criteria; therefore, curative surgery is necessary. Category 4.3 was also treated surgically. The asterisk (*): For *en bloc* mucosal resection, endoscopic submucosal dissection is appropriate; however, laparoscopic intragastric surgery may also be acceptable in cases where there is no skilled endoscopist. The two asterisks (**): Gastrectomy with lymph node dissection up to D1+ is recommended for surgical treatment. However, since the possibility of lymph node metastasis is only 15%-20% even for such lesions, function-preserving curative gastrectomy guided by sentinel lymph node biopsy can be performed by a specialist.

cases where there is no skilled endoscopist[34]. In contrast, category 5 corresponds to submucosal adenocarcinoma in the JGCA criteria; therefore, gastrectomy with lymph node dissection is necessary [17,30]. Category 4.3. also has a high possibility of developing similar lesions; thus, surgery should be performed from the beginning. In addition, since the possibility of lymph node metastasis is only 15%-20% even for such lesions, not only gastrectomy with nodal dissection up to D1+ but also function-preserving curative gastrectomy guided by sentinel lymph node biopsy may be a good indication[17].

CONCLUSION

Gastric carcinogenesis occurs mostly *de novo*, and the adenoma-carcinoma sequence does not appear to be the main pathway of carcinogenesis. Superficial gastric tumors can be roughly divided into the *APC* mutation type and the *TP53* mutation type, which are mutually exclusive. For lesions diagnosed as category 3 or 4 in the Vienna classification, it is desirable to perform ESD for accurate diagnosis and staging. If there is lymphovascular or submucosal invasion, additional surgical treatment of gastrectomy with lymph node dissection is required.

FOOTNOTES

Author contributions: Kinami S was responsible for the scientific conception of the study and writing of the manuscript; Yamada S and Takamura H contributed to the drafting, editing, and critical revision of the manuscript; all authors approved the final version of the manuscript.

Conflict-of-interest statement: The authors declare no conflict of interest related to the publication of this study.

Open-Access: This article is an open-access article that was selected by an in-house editor and fully peer-reviewed by external reviewers. It is distributed in accordance with the Creative Commons Attribution NonCommercial (CC BY-NC 4.0) license, which permits others to distribute, remix, adapt, build upon this work non-commercially, and license their derivative works on different terms, provided the original work is properly cited and the use is non-commercial. See: <https://creativecommons.org/licenses/by-nc/4.0/>

Country/Territory of origin: Japan

ORCID number: Shinichi Kinami 0000-0001-9867-3120; Sohsuke Yamada 0000-0003-2662-0024; Hiroyuki Takamura 0000-0001-9351-1309.

S-Editor: Chen YL

L-Editor: A

P-Editor: Chen YL

REFERENCES

- 1 Uemura N, Okamoto S, Yamamoto S, Matsumura N, Yamaguchi S, Yamakido M, Taniyama K, Sasaki N, Schlemper RJ. Helicobacter pylori infection and the development of gastric cancer. *N Engl J Med* 2001; **345**: 784-789 [PMID: 11556297 DOI: 10.1056/NEJMoa001999]
- 2 Ueda J, Goshō M, Inui Y, Matsuda T, Sakakibara M, Mabe K, Nakajima S, Shimoyama T, Yasuda M, Kawai T, Murakami K, Kamada T, Mizuno M, Kikuchi S, Lin Y, Kato M. Prevalence of Helicobacter pylori infection by birth year and geographic area in Japan. *Helicobacter* 2014; **19**: 105-110 [PMID: 24506211 DOI: 10.1111/hel.12110]
- 3 Kamada T, Haruma K, Ito M, Inoue K, Manabe N, Matsumoto H, Kusunoki H, Hata J, Yoshihara M, Sumii K, Akiyama T, Tanaka S, Shiotani A, Graham DY. Time Trends in Helicobacter pylori Infection and Atrophic Gastritis Over 40 Years in Japan. *Helicobacter* 2015; **20**: 192-198 [PMID: 25581708 DOI: 10.1111/hel.12193]
- 4 Maddineni G, Xie JJ, Brahmbhatt B, Mutha P. Diet and carcinogenesis of gastric cancer. *Curr Opin Gastroenterol* 2022; **38**: 588-591 [PMID: 36165035 DOI: 10.1097/MOG.0000000000000875]
- 5 Bornschein J, Malfertheiner P. Gastric carcinogenesis. *Langenbecks Arch Surg* 2011; **396**: 729-742 [PMID: 21611816 DOI: 10.1007/s00423-011-0810-y]
- 6 Mirvish SS. Role of N-nitroso compounds (NOC) and N-nitrosation in etiology of gastric, esophageal, nasopharyngeal and bladder cancer and contribution to cancer of known exposures to NOC. *Cancer Lett* 1995; **93**: 17-48 [PMID: 7600541 DOI: 10.1016/0304-3835(95)03786-V]
- 7 Yang J, Liu Z, Zeng B, Hu G, Gan R. Epstein-Barr virus-associated gastric cancer: A distinct subtype. *Cancer Lett* 2020; **495**: 191-199 [PMID: 32979463 DOI: 10.1016/j.canlet.2020.09.019]
- 8 Nakamura K, Sugano H, Takagi K, Fuchigami A. Histopathological study on early carcinoma of the stomach: criteria for diagnosis of atypical epithelium. *Gan* 1966; **57**: 613-620 [PMID: 5973413]
- 9 Sugano H, Nakamura K, Takagi K. An atypical epithelium of the stomach. *Gann Monogr* 1971; **11**: 257-269
- 10 Nakamura K, Takagi K. Some considerations on lesion of atypical epithelium of the stomach. *Stomach and Intestine (Jpn)* 1975; **10**: 1455-1463
- 11 Shibagaki K, Mishiro T, Fukuyama C, Takahashi Y, Itawaki A, Nonomura S, Yamashita N, Kotani S, Mikami H, Izumi D, Kawashima K, Ishimura N, Nagase M, Araki A, Ishikawa N, Maruyama R, Kushima R, Ishihara S. Sporadic foveolar-type gastric adenoma with a raspberry-like appearance in Helicobacter pylori-naïve patients. *Virchows Arch* 2021; **479**: 687-695 [PMID: 34043063 DOI: 10.1007/s00428-021-03124-3]
- 12 Bertz S, Angeloni M, Drgac J, Falkeis C, Lang-Schwarz C, Sterlacci W, Veits L, Hartmann A, Vieth M. Helicobacter Infection and Gastric Adenoma. *Microorganisms* 2021; **9** [PMID: 33466325 DOI: 10.3390/microorganisms9010108]
- 13 WHO Classification of Tumours Editorial Board. WHO classification of tumours of the digestive system. 5th ed. Lyon: IARC Press, 2019 [DOI: 10.1111/his.13975]
- 14 Schlemper RJ, Riddell RH, Kato Y, Borchard F, Cooper HS, Dawsey SM, Dixon MF, Fenoglio-Preiser CM, Fléjou JF, Geboes K, Hattori T, Hirota T, Itabashi M, Iwafuchi M, Iwashita A, Kim YI, Kirchner T, Klimpfinger M, Koike M, Lauwers GY, Lewin KJ, Oberhuber G, Offner F, Price AB, Rubio CA, Shimizu M, Shimoda T, Sipponen P, Solcia E, Stolte M, Watanabe H, Yamabe H. The Vienna classification of gastrointestinal epithelial neoplasia. *Gut* 2000; **47**: 251-255 [PMID: 10896917 DOI: 10.1136/gut.47.2.251]
- 15 Dixon MF. Gastrointestinal epithelial neoplasia: Vienna revisited. *Gut* 2002; **51**: 130-131 [PMID: 12077106 DOI: 10.1136/gut.51.1.130]
- 16 Japanese Gastric Cancer Association. Japanese classification of gastric carcinoma. 15th ed. Tokyo: Kanehara Shuppan, 2018 [DOI: 10.1007/pl00011681]
- 17 Kinami S, Nakamura N, Tomita Y, Miyata T, Fujita H, Ueda N, Kosaka T. Precision surgical approach with lymph-node dissection in early gastric cancer. *World J Gastroenterol* 2019; **25**: 1640-1652 [PMID: 31011251 DOI: 10.3748/wjg.v25.i14.1640]
- 18 Tsukuma H, Oshima A, Narahara H, Morii T. Natural history of early gastric cancer: a non-concurrent, long term, follow up study. *Gut* 2000; **47**: 618-621 [PMID: 11034575 DOI: 10.1136/gut.47.5.618]
- 19 Kato M. Diagnosis and therapies for gastric non-invasive neoplasia. *World J Gastroenterol* 2015; **21**: 12513-12518 [PMID: 26640329 DOI: 10.3748/wjg.v21.i44.12513]
- 20 Yamada H, Ikegami M, Shimoda T, Takagi N, Maruyama M. Long-term follow-up study of gastric adenoma/dysplasia.

- Endoscopy* 2004; **36**: 390-396 [PMID: [15100945](#) DOI: [10.1055/s-2004-814330](#)]
- 21 **Cancer Genome Atlas Research Network.** Comprehensive molecular characterization of gastric adenocarcinoma. *Nature* 2014; **513**: 202-209 [PMID: [25079317](#) DOI: [10.1038/nature13480](#)]
 - 22 **Fassan M**, Simbolo M, Bria E, Mafficini A, Pilotto S, Capelli P, Bencivenga M, Pecori S, Luchini C, Neves D, Turri G, Vicentini C, Montagna L, Tomezzoli A, Tortora G, Chilosi M, De Manzoni G, Scarpa A. High-throughput mutation profiling identifies novel molecular dysregulation in high-grade intraepithelial neoplasia and early gastric cancers. *Gastric Cancer* 2014; **17**: 442-449 [PMID: [24272205](#) DOI: [10.1007/s10120-013-0315-1](#)]
 - 23 **Lim CH**, Cho YK, Kim SW, Choi MG, Rhee JK, Chung YJ, Lee SH, Kim TM. The chronological sequence of somatic mutations in early gastric carcinogenesis inferred from multiregion sequencing of gastric adenomas. *Oncotarget* 2016; **7**: 39758-39767 [PMID: [27175599](#) DOI: [10.18632/oncotarget.9250](#)]
 - 24 **Lee JH**, Abraham SC, Kim HS, Nam JH, Choi C, Lee MC, Park CS, Juhng SW, Rashid A, Hamilton SR, Wu TT. Inverse relationship between APC gene mutation in gastric adenomas and development of adenocarcinoma. *Am J Pathol* 2002; **161**: 611-618 [PMID: [12163385](#) DOI: [10.1016/S0002-9440\(10\)64216-2](#)]
 - 25 **Rokutan H**, Abe H, Nakamura H, Ushiku T, Arakawa E, Hosoda F, Yachida S, Tsuji Y, Fujishiro M, Koike K, Totoki Y, Fukayama M, Shibata T. Initial and crucial genetic events in intestinal-type gastric intramucosal neoplasia. *J Pathol* 2019; **247**: 494-504 [PMID: [30474112](#) DOI: [10.1002/path.5208](#)]
 - 26 **Dinis-Ribeiro M**, Areia M, de Vries AC, Marcos-Pinto R, Monteiro-Soares M, O'Connor A, Pereira C, Pimentel-Nunes P, Correia R, Ensari A, Dumonceau JM, Machado JC, Macedo G, Malfertheiner P, Matysiak-Budnik T, Megraud F, Miki K, O'Morain C, Peek RM, Ponchon T, Ristimaki A, Rembacken B, Carneiro F, Kuipers EJ; European Society of Gastrointestinal Endoscopy; European Helicobacter Study Group; European Society of Pathology; Sociedade Portuguesa de Endoscopia Digestiva. Management of precancerous conditions and lesions in the stomach (MAPS): guideline from the European Society of Gastrointestinal Endoscopy (ESGE), European Helicobacter Study Group (EHSG), European Society of Pathology (ESP), and the Sociedade Portuguesa de Endoscopia Digestiva (SPED). *Endoscopy* 2012; **44**: 74-94 [PMID: [22198778](#) DOI: [10.1055/s-0031-1291491](#)]
 - 27 **Pimentel-Nunes P**, Libânio D, Marcos-Pinto R, Areia M, Leja M, Esposito G, Garrido M, Kikuste I, Megraud F, Matysiak-Budnik T, Annibale B, Dumonceau JM, Barros R, Fléjou JF, Carneiro F, van Hooft JE, Kuipers EJ, Dinis-Ribeiro M. Management of epithelial precancerous conditions and lesions in the stomach (MAPS II): European Society of Gastrointestinal Endoscopy (ESGE), European Helicobacter and Microbiota Study Group (EHMSG), European Society of Pathology (ESP), and Sociedade Portuguesa de Endoscopia Digestiva (SPED) guideline update 2019. *Endoscopy* 2019; **51**: 365-388 [PMID: [30841008](#) DOI: [10.1055/a-0859-1883](#)]
 - 28 **Lim H**, Jung HY, Park YS, Na HK, Ahn JY, Choi JY, Lee JH, Kim MY, Choi KS, Kim DH, Choi KD, Song HJ, Lee GH, Kim JH. Discrepancy between endoscopic forceps biopsy and endoscopic resection in gastric epithelial neoplasia. *Surg Endosc* 2014; **28**: 1256-1262 [PMID: [24310738](#) DOI: [10.1007/s00464-013-3316-6](#)]
 - 29 **Zhao G**, Xue M, Hu Y, Lai S, Chen S, Wang L. How Commonly Is the Diagnosis of Gastric Low Grade Dysplasia Upgraded following Endoscopic Resection? *PLoS One* 2015; **10**: e0132699 [PMID: [26182344](#) DOI: [10.1371/journal.pone.0132699](#)]
 - 30 **Ono H**. Early gastric cancer: diagnosis, pathology, treatment techniques and treatment outcomes. *Eur J Gastroenterol Hepatol* 2006; **18**: 863-866 [PMID: [16825902](#) DOI: [10.1097/00042737-200608000-00009](#)]
 - 31 **Japanese Gastric Cancer Association.** Japanese gastric cancer treatment guidelines 2018 (5th edition). *Gastric Cancer* 2021; **24**: 1-21 [PMID: [32060757](#) DOI: [10.1007/s10120-020-01042-y](#)]
 - 32 **Suzuki S**, Gotoda T, Suzuki H, Kono S, Iwatsuka K, Kusano C, Oda I, Sekine S, Moriyasu F. Morphologic and Histologic Changes in Gastric Adenomas After Helicobacter pylori Eradication: A Long-Term Prospective Analysis. *Helicobacter* 2015; **20**: 431-437 [PMID: [25704290](#) DOI: [10.1111/hel.12218](#)]
 - 33 **Hirata I**, Kinugasa H, Miyahara K, Higashi R, Kunihiro M, Morito T, Ichimura K, Tanaka T, Nakagawa M. [Gastric type adenoma with submucosal invasive carcinoma: a case study]. *Nihon Shokakibyo Gakkai Zasshi* 2018; **115**: 283-289 [PMID: [29526980](#) DOI: [10.11405/nisshoshi.115.283](#)]
 - 34 **Ohashi S**. Laparoscopic intraluminal (intragastic) surgery for early gastric cancer. A new concept in laparoscopic surgery. *Surg Endosc* 1995; **9**: 169-171 [PMID: [7597587](#) DOI: [10.1007/BF00191960](#)]



Published by **Baishideng Publishing Group Inc**
7041 Koll Center Parkway, Suite 160, Pleasanton, CA 94566, USA

Telephone: +1-925-3991568

E-mail: bpgoffice@wjgnet.com

Help Desk: <https://www.f6publishing.com/helpdesk>

<https://www.wjgnet.com>

