

World Journal of *Gastroenterology*

World J Gastroenterol 2022 February 21; 28(7): 693-774



Contents

Weekly Volume 28 Number 7 February 21, 2022

EDITORIAL

- 693** Early gastric cancer: A challenge in Western countries
Chiarello MM, Fico V, Pepe G, Tropeano G, Adams NJ, Altieri G, Brisinda G

MINIREVIEWS

- 704** Will the collaboration of surgery and external radiotherapy open new avenues for hepatocellular carcinoma with portal vein thrombosis?
Choe JW, Lee HY, Rim CH

ORIGINAL ARTICLE

Retrospective Study

- 715** Clinical online nomogram for predicting prognosis in recurrent hepatolithiasis after biliary surgery: A multicenter, retrospective study
Pu T, Chen JM, Li ZH, Jiang D, Guo Q, Li AQ, Cai M, Chen ZX, Xie K, Zhao YJ, Wang C, Hou H, Lu Z, Geng XP, Liu FB

Observational Study

- 732** Effect of *Bifidobacterium longum* 35624 on disease severity and quality of life in patients with irritable bowel syndrome
Sabaté JM, Iglicki F

SYSTEMATIC REVIEWS

- 745** Stereotactic radiotherapy and the potential role of magnetic resonance-guided adaptive techniques for pancreatic cancer
Ermongkonchai T, Khor R, Muralidharan V, Tebbutt N, Lim K, Kutaiba N, Ng SP

CASE REPORT

- 755** Crohn's disease-related 'gastrocnemius myalgia syndrome' successfully treated with infliximab: A case report
Catherine J, Kadhim H, Lambot F, Liefferinckx C, Meurant V, Otero Sanchez L

LETTER TO THE EDITOR

- 763** Gallbladder biliary lithotripsy: A new rationale applied to old treatment
Dioscoridi L, Mutignani M
- 766** Gastrointestinal microbiome and *Helicobacter pylori*: Eradicate, leave it as it is, or take a personalized benefit-risk approach?
Sitkin S, Lazebnik L, Avalueva E, Kononova S, Vakhtov T

ABOUT COVER

Editorial Board Member of *World Journal of Gastroenterology*, Madhusudana Girija Sanal, MBBS, PhD, Academic Fellow, Assistant Professor, Department of Molecular and Cellular Medicine, Institute of Liver and Biliary Sciences, New Delhi 110070, Delhi, India. sanalmg@gmail.com

AIMS AND SCOPE

The primary aim of *World Journal of Gastroenterology* (WJG, *World J Gastroenterol*) is to provide scholars and readers from various fields of gastroenterology and hepatology with a platform to publish high-quality basic and clinical research articles and communicate their research findings online. WJG mainly publishes articles reporting research results and findings obtained in the field of gastroenterology and hepatology and covering a wide range of topics including gastroenterology, hepatology, gastrointestinal endoscopy, gastrointestinal surgery, gastrointestinal oncology, and pediatric gastroenterology.

INDEXING/ABSTRACTING

The WJG is now indexed in Current Contents®/Clinical Medicine, Science Citation Index Expanded (also known as SciSearch®), Journal Citation Reports®, Index Medicus, MEDLINE, PubMed, PubMed Central, and Scopus. The 2021 edition of Journal Citation Report® cites the 2020 impact factor (IF) for WJG as 5.742; Journal Citation Indicator: 0.79; IF without journal self cites: 5.590; 5-year IF: 5.044; Ranking: 28 among 92 journals in gastroenterology and hepatology; and Quartile category: Q2. The WJG's CiteScore for 2020 is 6.9 and Scopus CiteScore rank 2020: Gastroenterology is 19/136.

RESPONSIBLE EDITORS FOR THIS ISSUE

Production Editor: Lin-YuTong Wang; Production Department Director: Xiang Li; Editorial Office Director: Ze-Mao Gong.

NAME OF JOURNAL

World Journal of Gastroenterology

ISSN

ISSN 1007-9327 (print) ISSN 2219-2840 (online)

LAUNCH DATE

October 1, 1995

FREQUENCY

Weekly

EDITORS-IN-CHIEF

Andrzej S Tarnawski

EDITORIAL BOARD MEMBERS

<http://www.wjgnet.com/1007-9327/editorialboard.htm>

PUBLICATION DATE

February 21, 2022

COPYRIGHT

© 2022 Baishideng Publishing Group Inc

INSTRUCTIONS TO AUTHORS

<https://www.wjgnet.com/bpg/gerinfo/204>

GUIDELINES FOR ETHICS DOCUMENTS

<https://www.wjgnet.com/bpg/GerInfo/287>

GUIDELINES FOR NON-NATIVE SPEAKERS OF ENGLISH

<https://www.wjgnet.com/bpg/gerinfo/240>

PUBLICATION ETHICS

<https://www.wjgnet.com/bpg/GerInfo/288>

PUBLICATION MISCONDUCT

<https://www.wjgnet.com/bpg/gerinfo/208>

ARTICLE PROCESSING CHARGE

<https://www.wjgnet.com/bpg/gerinfo/242>

STEPS FOR SUBMITTING MANUSCRIPTS

<https://www.wjgnet.com/bpg/GerInfo/239>

ONLINE SUBMISSION

<https://www.f6publishing.com>



Will the collaboration of surgery and external radiotherapy open new avenues for hepatocellular carcinoma with portal vein thrombosis?

Jung Wan Choe, Hye Yoon Lee, Chai Hong Rim

Specialty type: Gastroenterology and hepatology

Provenance and peer review: Unsolicited article; Externally peer reviewed.

Peer-review model: Single blind

Peer-review report's scientific quality classification

Grade A (Excellent): A, A

Grade B (Very good): B

Grade C (Good): C

Grade D (Fair): 0

Grade E (Poor): 0

P-Reviewer: Cao X, Cheng JY, Granito A, He YQ

Received: October 28, 2021

Peer-review started: October 28, 2021

First decision: December 12, 2021

Revised: December 17, 2021

Accepted: January 19, 2022

Article in press: January 19, 2022

Published online: February 21, 2022



Jung Wan Choe, Department of Internal Medicine, Korea University Ansan Hospital, Ansan 15355, South Korea

Hye Yoon Lee, Department of Surgery, Korea University Ansan Hospital, Ansan 15355, South Korea

Chai Hong Rim, Department of Radiation Oncology, Korea University Ansan Hospital, Ansan 15355, South Korea

Corresponding author: Chai Hong Rim, MD, PhD, Assistant Professor, Department of Radiation Oncology, Korea University Ansan Hospital, 123 Jeokgeum-ro, Danwon-gu, Ansan 15355, South Korea. crusion3@naver.com

Abstract

Portal invasion of hepatocellular carcinoma (HCC) occurs in 12.5%-40% of patients diagnosed with cancer and yields poor clinical outcomes. Since it is a common cause of inoperability, sorafenib was regarded as the standard treatment for HCC in the Barcelona Clinic of Liver Cancer guidelines. However, the median survival of the Asian population was only approximately 6 mo, and the tumor response rate was less than moderate (< 5%). Various locoregional modalities were performed, including external beam radiotherapy (EBRT), transarterial chemoembolization, hepatic arterial infusion chemotherapy, and surgery, alone or in combination. Among them, EBRT is a noninvasive method and can safely treat tumors involving the major vessels. Palliative EBRT has been commonly performed, especially in East Asian countries, where locally invasive HCC is highly prevalent. Although surgery is not commonly indicated, pioneering studies have demonstrated encouraging results in recent decades. Furthermore, the combination of neo- or adjuvant EBRT and surgery has been recently used and has significantly improved the outcomes of HCC patients, as reported in a few randomized studies. Regarding systemic modality, a combination of novel immunotherapy and vascular endothelial growth factor inhibitor showed results superior to that of sorafenib as a first-line agent. Future clinical trials investigating the combined use of these novel agents, surgery, and EBRT are expected to improve the prognosis of HCC with portal invasion.

Key Words: Surgery; Hepatocellular carcinoma; Radiotherapy; Systemic treatment

©The Author(s) 2022. Published by Baishideng Publishing Group Inc. All rights reserved.

Core Tip: The prognosis of hepatocellular carcinoma with portal vein involvement is poor, and there had been few available local modalities. However, with the development of radiotherapy techniques, the 1-year survival rate has been reported to be close to 45%-50% after palliation. Recently, a surgical approach has also been attempted showing encouraging results. Furthermore, the combination of surgery and radiation therapy showed effective results in studies including randomized studies. The combination of these two modalities are expected to increase efficacy of treating hepatocellular carcinoma with portal invasion.

Citation: Choe JW, Lee HY, Rim CH. Will the collaboration of surgery and external radiotherapy open new avenues for hepatocellular carcinoma with portal vein thrombosis? *World J Gastroenterol* 2022; 28(7): 704-714

URL: <https://www.wjgnet.com/1007-9327/full/v28/i7/704.htm>

DOI: <https://dx.doi.org/10.3748/wjg.v28.i7.704>

INTRODUCTION

Portal invasion of hepatocellular carcinoma (HCC) is a known clinical factor associated with poor prognosis. Portal vein invasion might cause portal hypertension, which can lead to decreased liver function and enlarge the gastrointestinal varices[1]. In addition, portal tumor thrombosis acts as a tumor deposit that can induce intra- and extrahepatic metastases[2,3]. Without active treatment, the survival period of HCC patients with portal invasion is usually less than 4 mo[4-6]. Portal invasion occurs in 12.5%-40% of all HCC patients in the clinical setting[7-11]. According to the 16th National Survey for Primary Liver Cancer conducted in Japan, portal involvement was found in 16% (808/5130) of patients who underwent hepatic resection[12]. In our previous study using data from the Nationwide Liver Cancer Registry, 2553 of 10743 patients (approximately 10% randomly extracted patient records from all administrative districts of South Korea), or about a quarter, had portal vein involvement at the time of diagnosis[13].

To date, there is no standard treatment for HCC with portal invasion; hence, various systemic and locoregional modalities have been used. Since portal invasion is a component of the Barcelona Clinic of Liver Cancer (BCLC) stage C, the European Association for the Study of the Liver (EASL)[14] and American Association for the Study of Liver Diseases (AASLD) guidelines[15], which were published in 2018, support the use of sorafenib for the treatment of HCC with this stage. Although sorafenib was the only modality that achieved an overall survival (OS) benefit, as reported in a phase 3 randomized study conducted within a period of 15 years, the tumor response rate was not satisfactory (less than 5%), and the median OS was only 6 mo after treatment as shown in an Asian population study[16]. In addition, it should not be overlooked that approximately 95% of the enrolled patients were in Child-Pugh class A in this study, even though a significant portion of the HCC patients with PVT have a liver function of Child-Pugh class B or C[17]; data on the use of sorafenib in these patients is limited. A randomized phase 3 trial was done comparing sorafenib *vs* best supportive care alone in Child-Pugh class B patients, and the results are expected to provide further guidance[18]. A recent study investigated the use of regorafenib for the HCC patients who have failed to improve on sorafenib; the median OS of 10.6 mo was achieved in patients who received regorafenib, which was better than the OS of 7.8 mo for those receiving the placebo[19]. Although several studies on the expansion of indications for systemic and rescue therapies are in progress, satisfactory results have not yet been obtained.

Therefore, various locoregional modalities have been used to improve the patient outcomes. Despite that the AASLD guidelines endorsed treatment recommendations of BCLC system previously[20], in its updated version in 2018, it is mentioned that systemic therapy for HCC with macrovascular invasion is recommended but not over locoregional treatments[15]. The preferred option of locoregional modality was not suggested, although recent studies regarding transarterial chemoembolization (TACE), external beam radiotherapy (EBRT), and hepatic arterial infusion chemotherapy (HAIC) were referenced, because evidence is limited to suggest relative superiority among those modalities.

The application of locoregional treatment for HCC with portal invasion varies regionally, and treatment strategies also differ between Eastern and Western countries[21]. In Asian countries, hepatitis B virus-related HCCs comprise the majority of diagnosed diseases. These diseases are mainly caused by insertional mutagenesis of viral oncoproteins and tend to progress rapidly and invasively, whereas liver function can be relatively preserved. In Western countries, the common causes of HCC include alcohol consumption or fatty liver of other causes. These diseases are associated with somatic alterations and chromosomal instability accumulated due to cirrhosis progression; they tend to be less progressive and have higher differentiation, but the liver function is commonly damaged due to persistent cirrhosis[22]. Therefore, the active locoregional treatments including TACE, surgery, EBRT, and HAIC are more rigorously attempted in Asia than in Western countries[21]. For instance, the surgical approach is

preferentially recommended for portal invasion cases that do not invade the main branch, as indicated in the recent Chinese expert consensus guidelines[23], although the vast majority of international guidelines did not suggest surgery as the preferred option for those cases[24,25]. Based on the Korean Liver Cancer Study Group guidelines, the combination of TACE and EBRT was suggested as the best option for HCC patients without extrahepatic metastases but with major vessel invasion[26].

Various locoregional modalities have been used independently or in combination to treat HCC with portal invasion. In particular, despite the fact that surgery is not generally recommended for portal invasive cases, recent studies have achieved favorable oncologic results by reducing the extent of tumors through EBRT and surgery. In this review, we aimed to discuss the role of locoregional modalities in the treatment of HCC with portal invasion, focusing on the recent results of surgery and EBRT as individual treatments and as a combination therapy.

PALLIATING PORTAL INVASION WITH EXTERNAL RADIOTHERAPY

In the early 1990s, before the generalization of a planning system using computed tomography, EBRT was known to have a limited role in HCC. EBRT had been “technically radioresistant” during the era of two-dimensional radiotherapy, of which the treatment was planned and performed under plain radiographic guidance. Since EBRT relies on bony and organ shadows available on plain films, radiation therapy inevitably encompasses a significant portion of the normal liver. Due to the possibility of hepatic radiotoxicity, only doses lower than 30 Gy could be administered, which is not sufficient to control the tumor[24,27].

Although the risk of radiation-induced liver disease steeply increased after delivering 30 Gy of irradiation to the entire liver, CT-based planning has enabled the safe delivery of high doses of over 50 Gy. The application of a more updated technology, such as intensity-modulated radiotherapy (a special type of EBRT that increases the conformality of the radiation target by actively modulating the dose intensity, portal shape, and beam movements), enabled the irradiation of advanced intrahepatic tumors while saving the necessary portion of the normal liver (Figure 1). Furthermore, despite the fact that tumor vascular invasion makes the application of local modalities difficult, EBRT is feasible because the major blood vessels can withstand more than approximately 100 Gy (in conventional fraction) and the target dose can be delivered regardless of the location of tumor[28]. Indeed, the HCC cells are radiosensitive and highly proliferative tumor cells with an alpha/beta ratio of approximately 15, which is similar to that of head and neck cancer (a radiosensitive cancer commonly treated with chemotherapy or radiotherapy)[29,30]. Previous studies using radiation therapy for locally advanced HCCs, which recruited patients from the 90s to the 2000s, have shown that HCC responds well to high doses of radiation. In a previous study including 158 unresectable HCC patients (about 50% of patients had portal invasion), Park *et al*[31] reported that the tumor response rates in patients who received irradiation doses of < 40 Gy, 40-50 Gy, or > 50 Gy increased to 29.2%, 68.6%, and 77.1%, respectively. Similarly, our previous study reported that as a result of prescribing a median total EBRT dose of 61.2 Gy, a high tumor response rate of 62.2% was reported in 45 HCC patients with portal vein thrombosis (PVT)[32].

Various studies have reported the use of EBRT in HCC patients with portal invasion in recent decades. In order to integrate the data from several studies, we performed a meta-analysis of 26 studies and 2,111 HCC patients treated with EBRT[33]. The pooled 1- and 2-year OS rates were 43.8% [95% confidence interval (CI): 37.6%-50.2%] and 22.3% (17.7%-27.6%) in patients who underwent three-dimensional conformal radiotherapy (3DCRT), and 48.5% (39.4%-57.8%) and 26.8% (19.0%-36.3%) in patients who underwent stereotactic body radiotherapy (SBRT). The pooled tumor response rates were 51.5% (95%CI: 45.7%-57.0%) and 70.7% (95%CI: 63.7%-76.8%) in patients who underwent 3DCRT and SBRT, respectively. Severe gastrointestinal or hepatic complications rarely occurred and were either not reported in most studies or were documented in less than 5%-10% of treated patients. Various locoregional modalities have been applied for the treatment of unresectable HCCs, and TACE is the most common modality performed in combination with EBRT. Huo *et al*[34] reported that the combination of TACE and RT had higher survival benefit [odds ratio (OR): 1.36, 95%CI: 1.19-1.54 for 1-year OS] and complete response rate (OR: 2.73, 95%CI: 1.95-3.81) than TACE alone for unresectable HCCs. They also pointed out that the benefits of OS progressively increased (ORs: 1.55, 1.91, 3.01, and 3.98 for 2-, 3-, 4-, and 5-year OS, respectively). In a recent randomized trial, Yoon *et al*[35] reported that the combination of TACE and EBRT improved the OS (median: 55 wk *vs* 43 wk, $P = 0.04$) and progression-free survival (median: 31 wk *vs* 11.7 wk, $P < 0.001$) of HCC patients with major vascular invasion compared with sorafenib. Recently, our team performed a study using nationwide data from all administrative districts of South Korea[13]. Strict propensity matching was performed, and data of 444 HCC patients with portal invasion (222 who underwent local treatment including EBRT and 222 who did not undergo active oncologic treatment) were analyzed. Local treatment, including radiotherapy, had significant benefits on the OS (median: 8 mo *vs* 2 mo, $P < 0.001$) and cancer-specific survival. Table 1 summarizes the key results of the cited studies.

Table 1 Summary of key studies according to the treatment method

Ref.	Study type	Number of patients	Main outcomes
Radiotherapy studies			
Rim <i>et al</i> [33], 2018	Meta-analysis of observational studies	2111 with PVT	Pooled 1- and 2-yr OS: 43.8% and 22.3%, respectively (3DCRT) Pooled 1- and 2-year OS: 48.5% and 26.8%, respectively (SBRT) Grade 3 complications less than 5% to 10%
Huo <i>et al</i> [34], 2015	Comparative meta-analysis	2577 underwent TACE or RTx	TACE and RT had OS benefit compared with TACE alone ORs: 1.55, 1.91, 3.01, and 3.98 for 2-, 3-, 4-, and 5-yr OS rates, respectively
Yoon <i>et al</i> [35], 2018	Randomized trial	90 with major vascular invasion	TACE and RT had survival benefit compared with sorafenib Median OS 55 wk <i>vs</i> 43 wk, $P = 0.004$ Median PFS 31 wk <i>vs</i> 11.7 wk, $P < 0.001$
Lee <i>et al</i> [13], 2021	Observational study using national database	444 propensity-matched patients with PVT	Local treatment including RTx had survival benefit compared with no oncologic treatment Median OS: 8 mo <i>vs</i> 2 mo, $P < 0.001$ Median CSS: 8 mo <i>vs</i> 2 mo, $P < 0.001$ OS and CSS benefit persist in the CPC A and CPC B subgroups
Surgery studies			
Kokudo <i>et al</i> [41], 2016	Observational study using national database	2116 propensity-matched patients with PVT	Surgery had benefit compared with non-surgery Median OS: 2.45 yr <i>vs</i> 1.57 yr, $P < 0.001$ Surgery benefit was not observed in the Vp4 subgroup ($P = 0.242$)
Wang <i>et al</i> [42], 2016	Retrospective study	1580 with PVT underwent (1) surgery, (2) TACE, (3) TACE with sorafenib, or (4) TACE with RTx	Median OS: Cheng's type I: 15.9 <i>vs</i> 9.28 <i>vs</i> 12.0 <i>vs</i> 12.2 ($P < 0.001$) Cheng's type II: 12.5 <i>vs</i> 4.9 <i>vs</i> 8.9 <i>vs</i> 10.6 ($P < 0.001$) Cheng's type III: 6.0 <i>vs</i> 4.0 <i>vs</i> 7.0 <i>vs</i> 8.9 ($P = 0.001$)
Shi <i>et al</i> [43], 2010	Retrospective study	406 with PVT underwent surgery	Surgery showed better outcomes in Cheng's type I and type II (1-yr OS: 52% and 38%, respectively) PVT than type III and IV (1-yr OS: 25% and 18%, respectively)
Chen <i>et al</i> [44], 2006	Retrospective study	438 with PVT underwent surgery	Surgery yielded satisfactory results in Cheng's type I and II PVT (1- and 2-yr OS: 58.7% and 39.9%, respectively), not in types III and IV (1- and 2-yr OS: 39.5% and 20.4%, respectively)
Combined surgery and radiotherapy			
Chong <i>et al</i> [46], 2018	Retrospective study	26 underwent surgery following CCRT <i>vs</i> 18 underwent surgery alone	Surgery following CCRT had benefit on surgery alone Median DSS: 62 wk <i>vs</i> 15 wk, $P = 0.006$ Median DFS: 32 wk <i>vs</i> 3 wk, $P = 0.002$
Sun <i>et al</i> [47], 2019	Randomized trial	26 underwent surgery with adjuvant IMRT <i>vs</i> 26 surgery alone	Adjuvant IMRT significantly improved clinical outcomes Median OS: 18.9 mo <i>vs</i> 10.8 mo, $P = 0.005$ Median DFS: 9.1 mo <i>vs</i> 4.1 mo, $P = 0.001$
Wei <i>et al</i> [49], 2019	Randomized trial	82 neoadjuvant RT <i>vs</i> 82 surgery alone	1- and 2-yr OS: 75.2% and 27.4%, respectively (neoadjuvant RT) 1- and 2-yr OS: 43.2% and 9.4%, respectively (control) RT benefited Cheng's type I and II PVT as well as type III PVT
Li <i>et al</i> [50], 2016	Comparative study	45 neoadjuvant RT <i>vs</i> 50 surgery alone	Neoadjuvant RT decreased the rates of HCC recurrence [49% <i>vs</i> 88.7%, respectively ($P < 0.001$)] and increased overall survival [1-yr OS: 69% <i>vs</i> 35.6%, respectively ($P < 0.01$)]

PVT: Portal vein thrombosis; OS: Overall survival; 3DCRT: 3-dimensional conformal radiotherapy; SBRT: Stereotactic body radiotherapy; TACE: Transarterial chemoembolization; RTx: Radiotherapy; PFS: Progression-free survival; CSS: Cause-specific survival; CPC: Child-Pugh class; CCRT:

Concurrent chemoradiotherapy; DSS: Disease-specific survival; IMRT: Intensity-modulated radiotherapy.

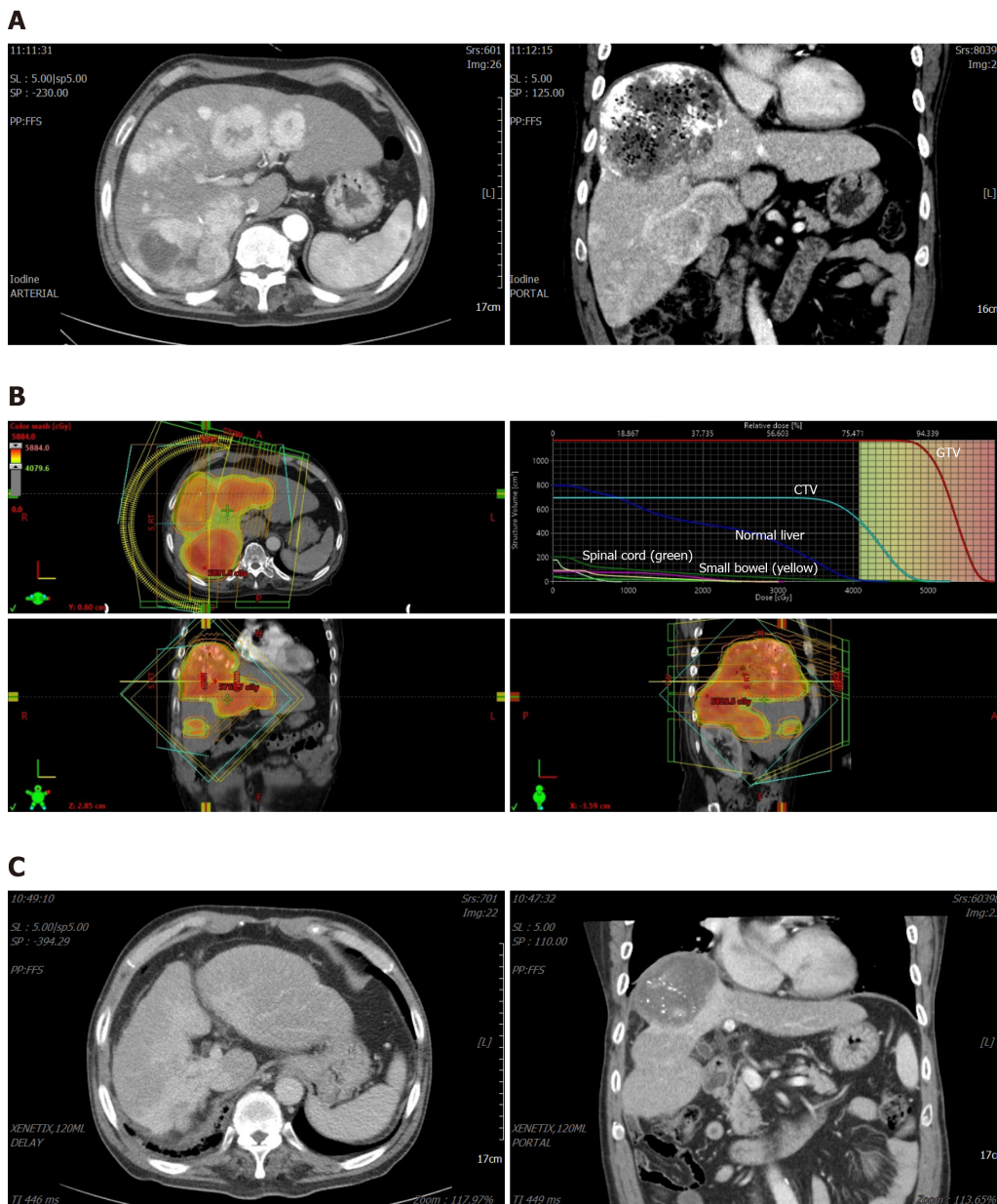


Figure 1 A case of a locally advanced hepatocellular carcinoma with portal thrombosis treated with radiotherapy. A: Multiple tumors noted in right lobe and segment 4, with a large tumor in segment 8, and involving right portal vein thrombosis; B: A dose-distribution of external radiotherapy plan. We prescribed 53 Gy/20F to gross tumor volume (red color wash in upper-left figure) with at least 42 Gy/20F were delivered to clinical target volume (green color wash in upper-left figure). Quantitative dose-histogram for specific organs is generated (upper-right figure). We planned to save at least 70% of normal liver to be irradiated less than 30 Gy; C: One year after radiotherapy and three times of transarterial chemoembolization, tumors were remised without active enhancing lesions. Liver function was maintained at Child-Pugh score A. GTV: Gross tumor volume; CTV: Clinical target volume.

In addition, particle therapy (*e.g.*, proton or heavy ion therapy) can provide additional benefits compared to conventional EBRT, which uses X-rays in treating locally advanced HCC. Particle therapy is most similar to conventional EBRT in terms of the overall principle of causing cancer cell death. However, dose escalation and complication reduction could be achieved based on the physical characteristic called Bragg peak (*e.g.*, the phenomenon that energy deposits almost disappear after radiation passes through the body and progresses to a certain depth)[36]. Sanford *et al*[37] reported the benefit of proton therapy as compared to conventional EBRT for 133 unresectable HCC patients based on survival (median OS: 31 mo *vs* 14 mo, HR = 0.47, $P = 0.008$) and liver toxicities (odds ratio: 0.26, $P = 0.03$). Cheng *et al*[38] also reported the benefit of proton therapy as compared to conventional EBRT based on survival (HR 0.56, $P = 0.032$) and radiation-induced liver disease (11.8% *vs* 36.4%, $P = 0.004$), using a propensity-matched cohort. The current hurdle for using particle therapy is its accessibility; currently,

there are about 110 particle therapy centers in operation worldwide, but most of them are in major developed countries such as the US, Japan, and Germany[39]. The financial burden of treatment due to the high cost of equipment is also a problem to be resolved. However, the efficiency of EBRT could be greatly improved once these difficulties are gradually resolved.

In summary, EBRT can be used for the treatment of HCC by delivering a high dose of radiation and has technical advances. It is an effective palliative modality for HCC with portal invasion and is commonly performed along with TACE.

SURGICAL RESECTION OF HCC WITH PORTAL INVASION

Previously, surgery was not commonly performed in HCC patients with portal invasion because of the short life expectancy and therapeutic risks. Neither the EASL nor the AASLD guidelines suggest the performance of surgical resection as treatment for HCC with portal invasion[14,15]. However, East Asian countries, including China and Japan, have recently been actively performing surgery for portal invasion[40].

Kokudo *et al*[41] performed a key study to evaluate the efficacy of surgical resection in HCC patients with portal invasion using the nationwide data from Japan. Among 6474 HCC patients with PVT, approximately 2100 patients with Child-Pugh A liver function were matched using propensity scores (liver resection group vs. non-liver resection group). The liver resection group showed significantly longer survival (median: 2.45 years vs 1.57 years, $P < 0.001$). However, the OS benefit was not significant in the subgroup with Vp4 PVT ($P = 0.242$). Figure 2 shows an illustration of the two common classifications of PVT. Furthermore, R2 resection was performed in 60.5% of patients, and the 90-day mortality was 8.2% in the Vp4 PVT group. The authors recommended liver resection as the first-line of treatment for HCC with PVT in the first-order branch. Another large series conducted by four Chinese centers[42] which included 1572 HCC patients with PVT, reported similar results. The median survival times of the surgical group were 15.9 and 12.5 mo for PVT of type I and II in Cheng's classification, which were much better than those of their nonsurgical counterparts. However, for patients with Cheng's type III PVT, the TACE and RT group showed higher survival rate than the surgery group (8.9 mo vs 6.0 mo). Therefore, authors suggested that surgery should be considered for type I and II PVT, but TACE and RT should be recommended for type III PVT (PVT in the main trunk or contralateral branches). Other series from East Asian countries reported the feasibility of surgical resection in HCC patients with branch thrombosis, but this modality may lead to poor outcomes and increase the surgical risks in those with main PVT[43,44].

Based on the above studies, consensus guidelines in East Asia recommend the use of surgery for the treatment of HCC with portal invasion. The recent treatment guidelines of the Japan Society of Hepatology[45] suggested four possible options for HCC with major vessel invasion: three locoregional modalities including TACE, surgical resection, hepatic arterial infusion chemotherapy, and molecular-targeted therapy. They stated that it is difficult to provide a universal ranking for the four modalities; therefore, the four modalities are recommended in parallel. On the contrary, the Chinese Expert guidelines for HCC with PVT recommend surgical resection as a preferred option for patients with Child-Pugh A, PVT type I and II based on Cheng's classification (branch PVT), and good performance. Type III PVT cases are recommended to undergo surgery after downstaging *via* EBRT or TACE[23].

In summary, surgical treatment is being actively performed for HCC with PVT, especially in East Asia. Although surgical resection is a considerable modality for HCC with branch PVT (types I and II based on Cheng's classification; Vp1-3 based on the Japanese classification), this modality can lead to poor outcomes and increase the risk for perioperative complications when used in patients with main PVT. Table 1 summarizes the key studies related to this topic.

PROMISING RESULTS OF SURGERY AND RADIOTHERAPY AS COMBINATION TREATMENT

In cancer treatment, the application of radiotherapy before and after surgical treatment to lower the recurrence and survival rates is a widely used method. Previously, patients with HCC with portal invasion were deemed to have a dismal prognosis; therefore, active treatment combining surgery and EBRT has not been widely accepted. However, several researchers have recently reported promising outcomes of neo- or adjuvant EBRT.

The multidisciplinary team of Yonsei University[46] reported their experience of trimodality treatment for HCC with portal invasion, which is neoadjuvant CCRT (HAIC plus EBRT) yielding downstaging and surgical resection. Patients who underwent trimodality treatment had a median disease-specific survival of 62 mo, while those who underwent resection alone had a median disease-specific survival of only 15 mo ($P = 0.006$). Sun *et al*[47] from the Eastern Hepatobiliary Surgery Hospital performed a randomized study to investigate the benefit of adjuvant IMRT in HCC patients with PVT

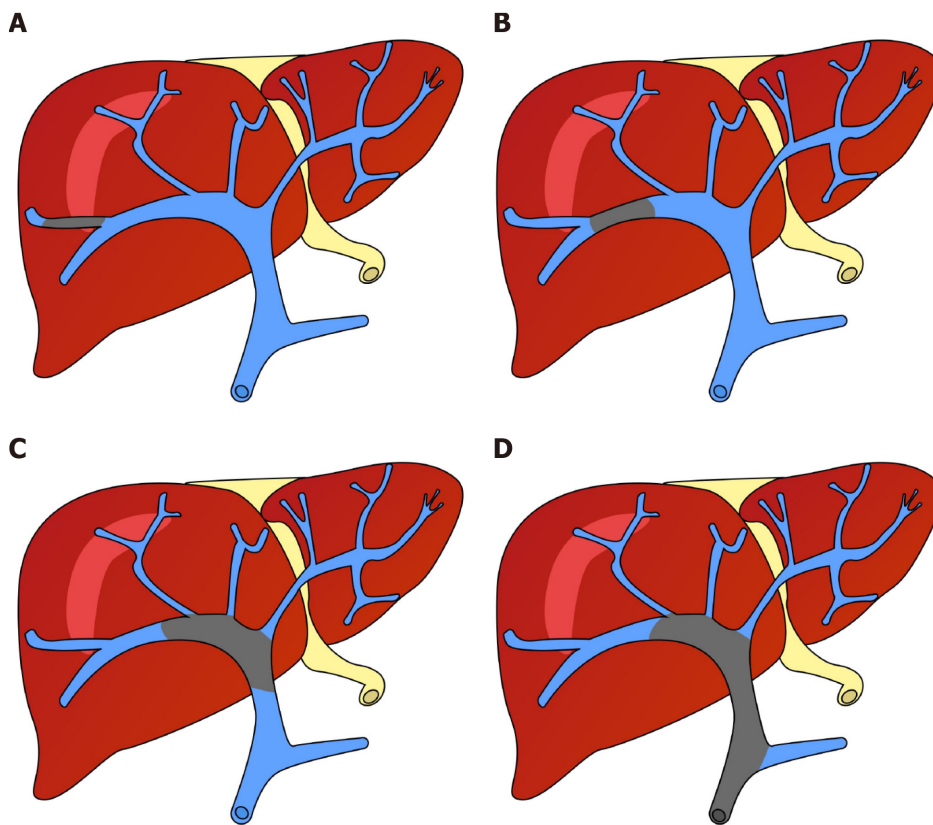


Figure 2 Illustration of two systems categorizing portal vein thrombus. A: Invasion of the second-order branch of the portal vein: VP2 in the liver cancer study group of Japan (e.g., Vp1 denotes the invasion distal to the second-order branch) and Cheng's classification type I; B: Invasion of the first-order branch: VP3 and Cheng's type II; C: Invasion of the main branch and/or bilateral first-order branches: VP4 and Cheng's type III; D: Invasion of the superior mesenteric vein: Cheng's type IV.

(adjuvant RT *vs* surgery alone). The adjuvant radiotherapy group showed significantly higher disease-free survival (DFS) (median: 9.1 mo *vs* 4.1 mo, $P = 0.001$) and OS (median: 18.9 vs. 10.8 mo, $P = 0.001$). The most common complications after RT were fatigue or anorexia, and grade 3 gastrointestinal complications occurred in 2 of 26 patients (7.7%). Grade 4 or higher adverse effects have not been reported. Although OS difference was significant in subgroup analyses among patients with Cheng's type I or II PVT (median 20.7 mo *vs* 11.7 mo, $P = 0.008$), due to the limited number of patients (only 6 and 7 patients had Cheng's type III or IV PVT, respectively, in both arms), the difference was not considered significant in the subgroup with PVT at main branch or trunk. Soin *et al* [48] reported encouraging results that comparable survival was achieved in HCC patients with PVT after down-staging, including SBRT, and liver transplantation, to those without PVT who underwent transplantation (5-year OS 57% *vs* 65%, $P = 0.06$).

Wei *et al* [49] performed a cornerstone study related to this topic, randomizing 164 patients into the neoadjuvant EBRT and surgery group and surgery groups. The 1- and 2-year OS rates in the neoadjuvant arm were 75.2% and 27.4%, whereas those in the surgery arm were 43.1% and 9.4%, respectively ($P < 0.001$). EBRT improved the OS and DFS of patients with type II PVT ($P = 0.01$ and $P = 0.016$, respectively) and those with type III PVT ($P < 0.001$ and $P = 0.002$, respectively), according to Cheng's classification. No significant difference was observed in the perioperative complications between the two groups, although a few more grade 3 or 4 complications were reported after RT (two cases of abdominal hemorrhage in the neoadjuvant EBRT arm and none in the surgery arm). In a previous non-randomized comparative study on HCC with main PVT (type III based on Cheng's classification), Li *et al* [50] investigated the benefit of neoadjuvant radiotherapy. The 1- and 2-year OS rates in the neoadjuvant group were 69% and 20.4%, whereas those in the surgery group were 35.6% and 0%, respectively ($P < 0.01$). The recurrence rates were 49% and 88.7% at 6 mo in the neoadjuvant and surgery groups, respectively ($P < 0.001$).

In summary, recent studies demonstrated that combining neo- or adjuvant EBRT and surgery could further improve the oncologic outcomes of HCC patients with portal invasion, possibly those with main PVT. Table 1 presents a list of related studies.

FUTURE PERSPECTIVE AND SUMMARY

Until the 2000s, there were limited practical treatment methods for HCC with portal invasion. Since the mid-2000s, sorafenib, the first effective systemic agent for unresectable HCC, has been established. In recent decades, aside from TACE, which is the most commonly used locoregional modality, other methods including EBRT, TARE, HAIC, and surgery have also been attempted. Furthermore, the use of a novel systemic modality (atezolizumab-bevacizumab)[51] that surpassed sorafenib in terms of survival and tumor responses, which had been established as a standard systemic agent for 15 years, was reported in 2020. Atezolizumab-bevacizumab is a combination of anti PD-L1 (an immune checkpoint inhibitor) and anti-vascular endothelial growth factor (VEGF) (a tumor microenvironment-modulating agent). As the anti-VEGF therapy reverses the VEGF-mediated immune suppression and increases the T-cell infiltration in tumors, the efficacy of anti PD-L1 could be enhanced[51]. Radiation therapy also enhances the performance of tumor antigen presentation and T-cell infiltration in the tumors[52]. In addition, radiation itself induces the sensitization of tumor cells to immune-mediated cell death by upregulating FAS expression. Therefore, the combination of immune checkpoint inhibitors and radiation therapy could be a promising treatment for HCC due to its synergistic effect. In addition, advances in understanding tumor immunity have resulted in new emerging immunotherapies. For example, CD4+ CD25+ regulatory T cells have a well-established immunosuppressive role in the HCC microenvironment and express various chemokine receptors and surface molecules such as PD-1, CTLA4 and others[53]. They can potentially be direct or indirect targets for newly emerging immune checkpoint inhibitor immunotherapy. Future clinical studies investigating the efficacy and feasibility of novel immunotherapy in combination with EBRT are necessary.

CONCLUSION

Although HCC with portal invasion is considered to have a limited benefit from surgery, pioneering researchers have obtained promising outcomes, and recent studies have demonstrated that the addition of EBRT can further increase the treatment efficiency. If effective novel systemic agents, surgery, and EBRT are used in an appropriate combination, the prognosis of HCC with portal invasion can be significantly improved. In other words, we believe that the most potent anticancer modalities known to date, the tripartite collaboration of chemotherapy, surgery, and radiotherapy, commonly used in the treatment of other solid cancers, will be used as a new standard treatment for HCC with portal invasion in the near future. However, clinical trials are warranted to evaluate the efficacy of such collaborations.

FOOTNOTES

Author contributions: Rim CH contributed to conceptualization; Lee HY supervised the study; Choe JW and Rim CH wrote the original draft; Choe JW, Lee HY and Rim CH reviewed and edited the manuscript; All authors have read and agreed to the published version of the manuscript.

Supported by the National Research Fund of Korea, No. NRF-2021R1I1A2047475.

Conflict-of-interest statement: The authors declare that they have no conflicts of interest.

Open-Access: This article is an open-access article that was selected by an in-house editor and fully peer-reviewed by external reviewers. It is distributed in accordance with the Creative Commons Attribution NonCommercial (CC BY-NC 4.0) license, which permits others to distribute, remix, adapt, build upon this work non-commercially, and license their derivative works on different terms, provided the original work is properly cited and the use is non-commercial. See: <https://creativecommons.org/licenses/by-nc/4.0/>

Country/Territory of origin: South Korea

ORCID number: Jung Wan Choe 0000-0003-0634-5141; Hye Yoon Lee 0000-0001-9077-1412; Chai Hong Rim 0000-0001-7431-4588.

S-Editor: Gong ZM

L-Editor: A

P-Editor: Gong ZM

REFERENCES

- 1 **Fimognari FL**, Violi F. Portal vein thrombosis in liver cirrhosis. *Intern Emerg Med* 2008; **3**: 213-218 [PMID: 18274708 DOI: 10.1007/s11739-008-0128-0]
- 2 **Addario L**, Tritto G, Cavaglia E, Amodio F, Giannelli E, Di Costanzo GG. Preserved liver function, portal thrombosis and absence of oesophageal varices are risk factors for metastasis of hepatocellular carcinoma. *Dig Liver Dis* 2011; **43**: 319-324 [PMID: 20952262 DOI: 10.1016/j.dld.2010.09.003]
- 3 **Toyosaka A**, Okamoto E, Mitsunobu M, Oriyama T, Nakao N, Miura K. Pathologic and radiographic studies of intrahepatic metastasis in hepatocellular carcinoma; the role of efferent vessels. *HPB Surg* 1996; **10**: 97-103; discussion 103 [PMID: 9184864 DOI: 10.1155/1996/75210]
- 4 **Llovet JM**, Bustamante J, Castells A, Vilana R, Ayuso Mdel C, Sala M, Brú C, Rodés J, Bruix J. Natural history of untreated nonsurgical hepatocellular carcinoma: rationale for the design and evaluation of therapeutic trials. *Hepatology* 1999; **29**: 62-67 [PMID: 9862851 DOI: 10.1002/hep.510290145]
- 5 **Yeung YP**, Lo CM, Liu CL, Wong BC, Fan ST, Wong J. Natural history of untreated nonsurgical hepatocellular carcinoma. *Am J Gastroenterol* 2005; **100**: 1995-2004 [PMID: 16128944 DOI: 10.1111/j.1572-0241.2005.00229.x]
- 6 **Zeeneeldin AA**, Salem SE, Darwish AD, El-Gammal MM, Hussein MM, Saadeldin M. Untreated hepatocellular carcinoma in Egypt: outcome and prognostic factors. *J Hepatocell Carcinoma* 2015; **2**: 3-9 [PMID: 27508189 DOI: 10.2147/JHC.S73828]
- 7 **Calvet X**, Bruix J, Ginés P, Bru C, Solé M, Vilana R, Rodés J. Prognostic factors of hepatocellular carcinoma in the west: a multivariate analysis in 206 patients. *Hepatology* 1990; **12**: 753-760 [PMID: 2170267 DOI: 10.1002/hep.1840120422]
- 8 **Fuster J**, García-Valdecasas JC, Grande L, Tabet J, Bruix J, Anglada T, Taurá P, Lacy AM, González X, Vilana R, Bru C, Solé M, Visa J. Hepatocellular carcinoma and cirrhosis. Results of surgical treatment in a European series. *Ann Surg* 1996; **223**: 297-302 [PMID: 8604911 DOI: 10.1097/00000658-199603000-00011]
- 9 **Ikai I**, Arii S, Kojiro M, Ichida T, Makuuchi M, Matsuyama Y, Nakanuma Y, Okita K, Omata M, Takayasu K, Yamaoka Y. Reevaluation of prognostic factors for survival after liver resection in patients with hepatocellular carcinoma in a Japanese nationwide survey. *Cancer* 2004; **101**: 796-802 [PMID: 15305412 DOI: 10.1002/encr.20426]
- 10 **Portolani N**, Coniglio A, Ghidoni S, Giovanelli M, Benetti A, Tiberio GA, Giulini SM. Early and late recurrence after liver resection for hepatocellular carcinoma: prognostic and therapeutic implications. *Ann Surg* 2006; **243**: 229-235 [PMID: 16432356 DOI: 10.1097/01.sla.0000197706.21803.a1]
- 11 **Stuart KE**, Anand AJ, Jenkins RL. Hepatocellular carcinoma in the United States. Prognostic features, treatment outcome, and survival. *Cancer* 1996; **77**: 2217-2222 [PMID: 8635087 DOI: 10.1002/(sici)1097-0142(19960601)77:11<2217::Aid-cnrc6>3.0.Co;2-m]
- 12 **Yamaoka Y**, Ikai I, Arii S, Ichida T, Okita K, Omata M. Report of 16th national survey for primary liver cancer. *Kanzo* 2005; **46**: 234-254 [DOI: 10.2957/kanzo.46.234]
- 13 **Lee HA**, Park S, Seo YS, Yoon WS, Rim CH; On Behalf Of The Korean Liver Cancer Study Group. Benefits of Local Treatment Including External Radiotherapy for Hepatocellular Carcinoma with Portal Invasion. *Biology (Basel)* 2021; **10** [PMID: 33919745 DOI: 10.3390/biology10040326]
- 14 **European Association for the Study of the Liver**. EASL Clinical Practice Guidelines: Management of hepatocellular carcinoma. *J Hepatol* 2018; **69**: 182-236 [PMID: 29628281 DOI: 10.1016/j.jhep.2018.03.019]
- 15 **Heimbach JK**, Kulik LM, Finn RS, Sirlin CB, Abecassis MM, Roberts LR, Zhu AX, Murad MH, Marrero JA. AASLD guidelines for the treatment of hepatocellular carcinoma. *Hepatology* 2018; **67**: 358-380 [PMID: 28130846 DOI: 10.1002/hep.29086]
- 16 **Cheng AL**, Kang YK, Chen Z, Tsao CJ, Qin S, Kim JS, Luo R, Feng J, Ye S, Yang TS, Xu J, Sun Y, Liang H, Liu J, Wang J, Tak WY, Pan H, Burock K, Zou J, Voliotis D, Guan Z. Efficacy and safety of sorafenib in patients in the Asia-Pacific region with advanced hepatocellular carcinoma: a phase III randomised, double-blind, placebo-controlled trial. *Lancet Oncol* 2009; **10**: 25-34 [PMID: 19095497 DOI: 10.1016/S1470-2045(08)70285-7]
- 17 **Amitrano L**, Guardascione MA, Brancaccio V, Margaglione M, Manguso F, Iannaccone L, Grandone E, Balzano A. Risk factors and clinical presentation of portal vein thrombosis in patients with liver cirrhosis. *J Hepatol* 2004; **40**: 736-741 [PMID: 15094219 DOI: 10.1016/j.jhep.2004.01.001]
- 18 **Granito A**, Bolondi L. Non-transplant therapies for patients with hepatocellular carcinoma and Child-Pugh-Turcotte class B cirrhosis. *Lancet Oncol* 2017; **18**: e101-e112 [PMID: 28214411 DOI: 10.1016/S1470-2045(16)30569-1]
- 19 **Granito A**, Forgione A, Marinelli S, Renzulli M, Ielasi L, Sansone V, Benevento F, Piscaglia F, Tovoli F. Experience with regorafenib in the treatment of hepatocellular carcinoma. *Therap Adv Gastroenterol* 2021; **14**: 17562848211016959 [PMID: 34104211 DOI: 10.1177/17562848211016959]
- 20 **Bruix J**, Sherman M; American Association for the Study of Liver Diseases. Management of hepatocellular carcinoma: an update. *Hepatology* 2011; **53**: 1020-1022 [PMID: 21374666 DOI: 10.1002/hep.24199]
- 21 **Lu J**, Zhang XP, Zhong BY, Lau WY, Madoff DC, Davidson JC, Qi X, Cheng SQ, Teng GJ. Management of patients with hepatocellular carcinoma and portal vein tumour thrombosis: comparing east and west. *Lancet Gastroenterol Hepatol* 2019; **4**: 721-730 [PMID: 31387735 DOI: 10.1016/S2468-1253(19)30178-5]
- 22 **Zucman-Rossi J**, Villanueva A, Nault JC, Llovet JM. Genetic Landscape and Biomarkers of Hepatocellular Carcinoma. *Gastroenterology* 2015; **149**: 1226-1239.e4 [PMID: 26099527 DOI: 10.1053/j.gastro.2015.05.061]
- 23 **Cheng S**, Chen M, Cai J, Sun J, Guo R, Bi X, Lau WY, Wu M. Chinese Expert Consensus on Multidisciplinary Diagnosis and Treatment of Hepatocellular Carcinoma with Portal Vein Tumor Thrombus (2018 Edition). *Liver Cancer* 2020; **9**: 28-40 [PMID: 32071907 DOI: 10.1159/000503685]
- 24 **Rim CH**. Differences in radiotherapy application according to regional disease characteristics of hepatocellular carcinoma. *J Liver Cancer* 2021; **21**: 113-123 [DOI: 10.17998/jlc.2021.05.26]
- 25 **Rim CH**, Cheng J, Huang WY, Kimura T, Lee V, Zeng ZC, Seong J. An evaluation of hepatocellular carcinoma practice guidelines from a radiation oncology perspective. *Radiother Oncol* 2020; **148**: 73-81 [PMID: 32335365 DOI: 10.1016/j.radonc.2020.03.027]

- 26 **Korean Liver Cancer Association (KLCA)**; National Cancer Center (NCC), Goyang, Korea. 2018 Korean Liver Cancer Association-National Cancer Center Korea Practice Guidelines for the Management of Hepatocellular Carcinoma. *Korean J Radiol* 2019; **20**: 1042-1113 [PMID: 31270974 DOI: 10.3348/kjr.2019.0140]
- 27 **Rim CH**, Yim HJ, Park S, Seong J. Recent clinical applications of external beam radiotherapy for hepatocellular carcinoma according to guidelines, major trials and meta-analyses. *J Med Imaging Radiat Oncol* 2019; **63**: 812-821 [PMID: 31482683 DOI: 10.1111/1754-9485.12948]
- 28 **Rim CH**, Yoon WS. Leaflet manual of external beam radiation therapy for hepatocellular carcinoma: a review of the indications, evidences, and clinical trials. *Onco Targets Ther* 2018; **11**: 2865-2874 [PMID: 29844684 DOI: 10.2147/OTT.S164651]
- 29 **Hennequin C**, Quero L, Rivera S. [Radiosensitivity of hepatocellular carcinoma]. *Cancer Radiother* 2011; **15**: 39-42 [PMID: 21237689 DOI: 10.1016/j.canrad.2010.11.004]
- 30 **van Leeuwen CM**, Oei AL, Crezee J, Bel A, Franken NAP, Stalpers LJA, Kok HP. The alfa and beta of tumours: a review of parameters of the linear-quadratic model, derived from clinical radiotherapy studies. *Radiat Oncol* 2018; **13**: 96 [PMID: 29769103 DOI: 10.1186/s13014-018-1040-z]
- 31 **Park HC**, Seong J, Han KH, Chon CY, Moon YM, Suh CO. Dose-response relationship in local radiotherapy for hepatocellular carcinoma. *Int J Radiat Oncol Biol Phys* 2002; **54**: 150-155 [PMID: 12182985 DOI: 10.1016/s0360-3016(02)02864-x]
- 32 **Rim CH**, Yang DS, Park YJ, Yoon WS, Lee JA, Kim CY. Effectiveness of high-dose three-dimensional conformal radiotherapy in hepatocellular carcinoma with portal vein thrombosis. *Jpn J Clin Oncol* 2012; **42**: 721-729 [PMID: 22689916 DOI: 10.1093/jjco/hys082]
- 33 **Rim CH**, Kim CY, Yang DS, Yoon WS. Comparison of radiation therapy modalities for hepatocellular carcinoma with portal vein thrombosis: A meta-analysis and systematic review. *Radiother Oncol* 2018; **129**: 112-122 [PMID: 29233562 DOI: 10.1016/j.radonc.2017.11.013]
- 34 **Huo YR**, Eslick GD. Transcatheter Arterial Chemoembolization Plus Radiotherapy Compared With Chemoembolization Alone for Hepatocellular Carcinoma: A Systematic Review and Meta-analysis. *JAMA Oncol* 2015; **1**: 756-765 [PMID: 26182200 DOI: 10.1001/jamaoncol.2015.2189]
- 35 **Yoon SM**, Ryoo BY, Lee SJ, Kim JH, Shin JH, An JH, Lee HC, Lim YS. Efficacy and Safety of Transarterial Chemoembolization Plus External Beam Radiotherapy vs Sorafenib in Hepatocellular Carcinoma With Macroscopic Vascular Invasion: A Randomized Clinical Trial. *JAMA Oncol* 2018; **4**: 661-669 [PMID: 29543938 DOI: 10.1001/jamaoncol.2017.5847]
- 36 **Mizumoto M**, Oshiro Y, Okumura T, Fukumitsu N, Numajiri H, Ohnishi K, Aihara T, Ishikawa H, Tsuboi K, Sakurai H. Proton Beam Therapy for Hepatocellular Carcinoma: A Review of the University of Tsukuba Experience. *Int J Part Ther* 2016; **2**: 570-578 [PMID: 31772968 DOI: 10.14338/IJPT-15-00035.2]
- 37 **Sanford NN**, Pursley J, Noe B, Yeap BY, Goyal L, Clark JW, Allen JN, Blaszkowsky LS, Ryan DP, Ferrone CR, Tanabe KK, Qadan M, Crane CH, Koay EJ, Eyler C, DeLaney TF, Zhu AX, Wo JY, Grassberger C, Hong TS. Protons versus Photons for Unresectable Hepatocellular Carcinoma: Liver Decompensation and Overall Survival. *Int J Radiat Oncol Biol Phys* 2019; **105**: 64-72 [PMID: 30684667 DOI: 10.1016/j.ijrobp.2019.01.076]
- 38 **Cheng JY**, Liu CM, Wang YM, Hsu HC, Huang EY, Huang TT, Lee CH, Hung SP, Huang BS. Proton versus photon radiotherapy for primary hepatocellular carcinoma: a propensity-matched analysis. *Radiat Oncol* 2020; **15**: 159 [PMID: 32605627 DOI: 10.1186/s13014-020-01605-4]
- 39 **PTCOG**. Particle therapy co-operative group. [Accessed December 13, 2021] Available from: <https://www.ptcog.ch/index.php/facilities-in-operation>
- 40 **Peng SY**, Wang XA, Huang CY, Li JT, Hong DF, Wang YF, Xu B. Better surgical treatment method for hepatocellular carcinoma with portal vein tumor thrombus. *World J Gastroenterol* 2018; **24**: 4527-4535 [PMID: 30386102 DOI: 10.3748/wjg.v24.i40.4527]
- 41 **Kokudo T**, Hasegawa K, Matsuyama Y, Takayama T, Izumi N, Kadoya M, Kudo M, Ku Y, Sakamoto M, Nakashima O, Kaneko S, Kokudo N; Liver Cancer Study Group of Japan. Survival benefit of liver resection for hepatocellular carcinoma associated with portal vein invasion. *J Hepatol* 2016; **65**: 938-943 [PMID: 27266618 DOI: 10.1016/j.jhep.2016.05.044]
- 42 **Wang K**, Guo WX, Chen MS, Mao YL, Sun BC, Shi J, Zhang YJ, Meng Y, Yang YF, Cong WM, Wu MC, Lau WY, Cheng SQ. Multimodality Treatment for Hepatocellular Carcinoma With Portal Vein Tumor Thrombus: A Large-Scale, Multicenter, Propensity Matching Score Analysis. *Medicine (Baltimore)* 2016; **95**: e3015 [PMID: 26986115 DOI: 10.1097/MD.0000000000003015]
- 43 **Shi J**, Lai EC, Li N, Guo WX, Xue J, Lau WY, Wu MC, Cheng SQ. Surgical treatment of hepatocellular carcinoma with portal vein tumor thrombus. *Ann Surg Oncol* 2010; **17**: 2073-2080 [PMID: 20131013 DOI: 10.1245/s10434-010-0940-4]
- 44 **Chen XP**, Qiu FZ, Wu ZD, Zhang ZW, Huang ZY, Chen YF, Zhang BX, He SQ, Zhang WG. Effects of location and extension of portal vein tumor thrombus on long-term outcomes of surgical treatment for hepatocellular carcinoma. *Ann Surg Oncol* 2006; **13**: 940-946 [PMID: 16788755 DOI: 10.1245/ASO.2006.08.007]
- 45 **Kokudo N**, Takemura N, Hasegawa K, Takayama T, Kubo S, Shimada M, Nagano H, Hatano E, Izumi N, Kaneko S, Kudo M, Iijima H, Genda T, Tateishi R, Torimura T, Igaki H, Kobayashi S, Sakurai H, Murakami T, Watadani T, Matsuyama Y. Clinical practice guidelines for hepatocellular carcinoma: The Japan Society of Hepatology 2017 (4th JSH-HCC guidelines) 2019 update. *Hepatol Res* 2019; **49**: 1109-1113 [PMID: 31336394 DOI: 10.1111/hepr.13411]
- 46 **Chong JU**, Choi GH, Han DH, Kim KS, Seong J, Han KH, Choi JS. Downstaging with Localized Concurrent Chemoradiotherapy Can Identify Optimal Surgical Candidates in Hepatocellular Carcinoma with Portal Vein Tumor Thrombus. *Ann Surg Oncol* 2018; **25**: 3308-3315 [PMID: 30083834 DOI: 10.1245/s10434-018-6653-9]
- 47 **Sun J**, Yang L, Shi J, Liu C, Zhang X, Chai Z, Lau WY, Meng Y, Cheng SQ. Postoperative adjuvant IMRT for patients with HCC and portal vein tumor thrombus: An open-label randomized controlled trial. *Radiother Oncol* 2019; **140**: 20-25 [PMID: 31176205 DOI: 10.1016/j.radonc.2019.05.006]
- 48 **Soin AS**, Bhargui P, Kataria T, Baijal SS, Piplani T, Gautam D, Choudhary NS, Thiagarajan S, Rastogi A, Saraf N, Saigal S. Experience With LDLT in Patients With Hepatocellular Carcinoma and Portal Vein Tumor Thrombosis

- Postdownstaging. *Transplantation* 2020; **104**: 2334-2345 [PMID: [32032291](#) DOI: [10.1097/TP.0000000000003162](#)]
- 49 **Wei X**, Jiang Y, Zhang X, Feng S, Zhou B, Ye X, Xing H, Xu Y, Shi J, Guo W, Zhou D, Zhang H, Sun H, Huang C, Lu C, Zheng Y, Meng Y, Huang B, Cong W, Lau WY, Cheng S. Neoadjuvant Three-Dimensional Conformal Radiotherapy for Resectable Hepatocellular Carcinoma With Portal Vein Tumor Thrombus: A Randomized, Open-Label, Multicenter Controlled Study. *J Clin Oncol* 2019; **37**: 2141-2151 [PMID: [31283409](#) DOI: [10.1200/JCO.18.02184](#)]
- 50 **Li N**, Feng S, Xue J, Wei XB, Shi J, Guo WX, Lau WY, Wu MC, Cheng SQ, Meng Y. Hepatocellular carcinoma with main portal vein tumor thrombus: a comparative study comparing hepatectomy with or without neoadjuvant radiotherapy. *HPB (Oxford)* 2016; **18**: 549-556 [PMID: [27317960](#) DOI: [10.1016/j.hpb.2016.04.003](#)]
- 51 **Finn RS**, Qin S, Ikeda M, Galle PR, Ducreux M, Kim TY, Kudo M, Breder V, Merle P, Kaseb AO, Li D, Verret W, Xu DZ, Hernandez S, Liu J, Huang C, Mulla S, Wang Y, Lim HY, Zhu AX, Cheng AL; IMbrave150 Investigators. Atezolizumab plus Bevacizumab in Unresectable Hepatocellular Carcinoma. *N Engl J Med* 2020; **382**: 1894-1905 [PMID: [32402160](#) DOI: [10.1056/NEJMoa1915745](#)]
- 52 **Lee BM**, Seong J. Radiotherapy as an immune checkpoint blockade combination strategy for hepatocellular carcinoma. *World J Gastroenterol* 2021; **27**: 919-927 [PMID: [33776363](#) DOI: [10.3748/wjg.v27.i10.919](#)]
- 53 **Granito A**, Muratori L, Lalanne C, Quarneri C, Ferri S, Guidi M, Lenzi M, Muratori P. Hepatocellular carcinoma in viral and autoimmune liver diseases: Role of CD4+ CD25+ Foxp3+ regulatory T cells in the immune microenvironment. *World J Gastroenterol* 2021; **27**: 2994-3009 [PMID: [34168403](#) DOI: [10.3748/wjg.v27.i22.2994](#)]



Published by **Baishideng Publishing Group Inc**
7041 Koll Center Parkway, Suite 160, Pleasanton, CA 94566, USA

Telephone: +1-925-3991568

E-mail: bpgoffice@wjgnet.com

Help Desk: <https://www.f6publishing.com/helpdesk>

<https://www.wjgnet.com>

