

World Journal of *Gastroenterology*

World J Gastroenterol 2022 February 21; 28(7): 693-774



Contents

Weekly Volume 28 Number 7 February 21, 2022

EDITORIAL

- 693** Early gastric cancer: A challenge in Western countries
Chiarello MM, Fico V, Pepe G, Tropeano G, Adams NJ, Altieri G, Brisinda G

MINIREVIEWS

- 704** Will the collaboration of surgery and external radiotherapy open new avenues for hepatocellular carcinoma with portal vein thrombosis?
Choe JW, Lee HY, Rim CH

ORIGINAL ARTICLE

Retrospective Study

- 715** Clinical online nomogram for predicting prognosis in recurrent hepatolithiasis after biliary surgery: A multicenter, retrospective study
Pu T, Chen JM, Li ZH, Jiang D, Guo Q, Li AQ, Cai M, Chen ZX, Xie K, Zhao YJ, Wang C, Hou H, Lu Z, Geng XP, Liu FB

Observational Study

- 732** Effect of *Bifidobacterium longum* 35624 on disease severity and quality of life in patients with irritable bowel syndrome
Sabaté JM, Iglicki F

SYSTEMATIC REVIEWS

- 745** Stereotactic radiotherapy and the potential role of magnetic resonance-guided adaptive techniques for pancreatic cancer
Ermongkonchai T, Khor R, Muralidharan V, Tebbutt N, Lim K, Kutaiba N, Ng SP

CASE REPORT

- 755** Crohn's disease-related 'gastrocnemius myalgia syndrome' successfully treated with infliximab: A case report
Catherine J, Kadhim H, Lambot F, Liefferinckx C, Meurant V, Otero Sanchez L

LETTER TO THE EDITOR

- 763** Gallbladder biliary lithotripsy: A new rationale applied to old treatment
Dioscoridi L, Mutignani M
- 766** Gastrointestinal microbiome and *Helicobacter pylori*: Eradicate, leave it as it is, or take a personalized benefit-risk approach?
Sitkin S, Lazebnik L, Avalueva E, Kononova S, Vakhtov T

ABOUT COVER

Editorial Board Member of *World Journal of Gastroenterology*, Madhusudana Girija Sanal, MBBS, PhD, Academic Fellow, Assistant Professor, Department of Molecular and Cellular Medicine, Institute of Liver and Biliary Sciences, New Delhi 110070, Delhi, India. sanalmg@gmail.com

AIMS AND SCOPE

The primary aim of *World Journal of Gastroenterology* (WJG, *World J Gastroenterol*) is to provide scholars and readers from various fields of gastroenterology and hepatology with a platform to publish high-quality basic and clinical research articles and communicate their research findings online. WJG mainly publishes articles reporting research results and findings obtained in the field of gastroenterology and hepatology and covering a wide range of topics including gastroenterology, hepatology, gastrointestinal endoscopy, gastrointestinal surgery, gastrointestinal oncology, and pediatric gastroenterology.

INDEXING/ABSTRACTING

The WJG is now indexed in Current Contents®/Clinical Medicine, Science Citation Index Expanded (also known as SciSearch®), Journal Citation Reports®, Index Medicus, MEDLINE, PubMed, PubMed Central, and Scopus. The 2021 edition of Journal Citation Report® cites the 2020 impact factor (IF) for WJG as 5.742; Journal Citation Indicator: 0.79; IF without journal self cites: 5.590; 5-year IF: 5.044; Ranking: 28 among 92 journals in gastroenterology and hepatology; and Quartile category: Q2. The WJG's CiteScore for 2020 is 6.9 and Scopus CiteScore rank 2020: Gastroenterology is 19/136.

RESPONSIBLE EDITORS FOR THIS ISSUE

Production Editor: Lin-YuTong Wang; Production Department Director: Xiang Li; Editorial Office Director: Ze-Mao Gong.

NAME OF JOURNAL

World Journal of Gastroenterology

ISSN

ISSN 1007-9327 (print) ISSN 2219-2840 (online)

LAUNCH DATE

October 1, 1995

FREQUENCY

Weekly

EDITORS-IN-CHIEF

Andrzej S Tarnawski

EDITORIAL BOARD MEMBERS

<http://www.wjgnet.com/1007-9327/editorialboard.htm>

PUBLICATION DATE

February 21, 2022

COPYRIGHT

© 2022 Baishideng Publishing Group Inc

INSTRUCTIONS TO AUTHORS

<https://www.wjgnet.com/bpg/gerinfo/204>

GUIDELINES FOR ETHICS DOCUMENTS

<https://www.wjgnet.com/bpg/GerInfo/287>

GUIDELINES FOR NON-NATIVE SPEAKERS OF ENGLISH

<https://www.wjgnet.com/bpg/gerinfo/240>

PUBLICATION ETHICS

<https://www.wjgnet.com/bpg/GerInfo/288>

PUBLICATION MISCONDUCT

<https://www.wjgnet.com/bpg/gerinfo/208>

ARTICLE PROCESSING CHARGE

<https://www.wjgnet.com/bpg/gerinfo/242>

STEPS FOR SUBMITTING MANUSCRIPTS

<https://www.wjgnet.com/bpg/GerInfo/239>

ONLINE SUBMISSION

<https://www.f6publishing.com>



Crohn's disease-related 'gastrocnemius myalgia syndrome' successfully treated with infliximab: A case report

Julien Catherine, Hazim Kadhim, Frédéric Lambot, Claire Liefverinckx, Virginie Meurant, Lukas Otero Sanchez

Specialty type: Gastroenterology and hepatology

Provenance and peer review: Unsolicited article; Externally peer reviewed.

Peer-review model: Single blind

Peer-review report's scientific quality classification

Grade A (Excellent): A, A

Grade B (Very good): 0

Grade C (Good): 0

Grade D (Fair): 0

Grade E (Poor): 0

P-Reviewer: Dhali A, Homan M

Received: September 30, 2021

Peer-review started: September 30, 2021

First decision: December 4, 2021

Revised: December 13, 2021

Accepted: January 19, 2022

Article in press: January 19, 2022

Published online: February 21, 2022



Julien Catherine, Institute for Medical Immunology, Université Libre de Bruxelles, Gosselies 6041, Belgium

Julien Catherine, Department of Internal Medicine, C.U.B. Hôpital Erasme, Brussels 1070, Belgium

Hazim Kadhim, NeuroMyopathology Unit (Anatomic Pathology Service) and Reference Center for Neuromuscular Pathology, CHU Brugmann, Université Libre de Bruxelles, Brussels 1020, Belgium

Frédéric Lambot, Department of Internal Medicine, Centre Hospitalier Universitaire Tivoli, La Louvière 7100, Belgium

Claire Liefverinckx, Lukas Otero Sanchez, Department of Gastroenterology, Hepatopancreatology and Digestive Oncology, C.U.B. Hôpital Erasme, Brussels 1070, Belgium

Claire Liefverinckx, Lukas Otero Sanchez, Laboratory of Experimental Gastroenterology, Université Libre de Bruxelles, Brussels 1070, Belgium

Virginie Meurant, Department of Emergency Medicine, Centre Hospitalier Universitaire Tivoli, La Louvière 7100, Belgium

Corresponding author: Julien Catherine, MD, Medical Assistant, Research Fellow, Institute for Medical Immunology, Université Libre de Bruxelles, Rue Adrienne Boland 8, Gosselies 6041, Belgium. julien.catherine@ulb.be

Abstract

BACKGROUND

Extra-intestinal manifestations in inflammatory bowel diseases (IBD) are frequent and involve virtually all organs. Conversely, the clinical characteristics and course of inflammatory myopathies in IBD remain poorly described and mostly related to orbital myositis. Moreover, alternative therapeutic strategies in non-responder patients to corticosteroid therapy must still be clarified.

CASE SUMMARY

A 33-year-old woman with a history of unclassified colitis presented with acute bilateral calf pain. On admission, her clinical and biological examinations were non-specific. However, magnetic resonance imaging showed bilateral inflammatory changes in gastrocnemius muscles suggestive of myositis. Muscle biopsy confirmed the diagnosis of myositis and demonstrated an inflammatory infiltrate

mainly located in the perimysial compartment including lympho-plasmocytic cells with the formation of several granulomatous structures while the endomysium was relatively spared. The combined clinical, biological and histomyopathological findings were concordant with the diagnosis of ‘gastrocnemius myalgia syndrome’ (GMS), a rare disorder associated with Crohn’s disease (CD). Ileocolonoscopy confirmed CD diagnosis and systemic corticosteroids (CS) therapy was started, resulting in a rapid clinical improvement. During CS tapering, however, she experienced a relapse of GMS together with a severe active ileocolitis. Infliximab was started and allowed a sustained remission of both conditions at the latest follow-up (20 mo).

CONCLUSION

The GMS represent a rare CD-associated inflammatory myopathy for which anti-tumour necrosis factor- α therapy might be considered as an effective therapeutic option.

Key Words: Crohn’s disease; Extra-intestinal manifestation; Gastrocnemius myalgia syndrome; Granulomatous myositis; Anti-tumour necrosis factor- α therapy; Case report

©The Author(s) 2022. Published by Baishideng Publishing Group Inc. All rights reserved.

Core Tip: Inflammatory myopathies are scarce in the setting of inflammatory bowel diseases (IBD) and could be wrongly attributed to IBD-related osteoarticular manifestations or to medications’ side effects. This case describes a very atypical presentation of myositis restricted to the legs called the ‘gastrocnemius myalgia syndrome’, an entity only described during Crohn’s disease. Its restricted location to the legs as well as normal creatine kinase levels in serum reflecting a predominant interstitial immune reaction are key characteristics in reported cases. Although corticosteroids are often used as first-line therapy, cortico-dependence is not rare and anti-tumour necrosis factor- α agents might represent an effective therapeutic option.

Citation: Catherine J, Kadhim H, Lambot F, Liefferinckx C, Meurant V, Otero Sanchez L. Crohn’s disease-related ‘gastrocnemius myalgia syndrome’ successfully treated with infliximab: A case report. *World J Gastroenterol* 2022; 28(7): 755-762

URL: <https://www.wjgnet.com/1007-9327/full/v28/i7/755.htm>

DOI: <https://dx.doi.org/10.3748/wjg.v28.i7.755>

INTRODUCTION

The multi-system nature of inflammatory bowel diseases (IBD) is widely known. The extraintestinal manifestations (EIMs) of IBD are diverse and deferred from IBD diagnosis in a quarter of the cases. It has been estimated that 6% to 47% of patients with IBD experience at least one EIM[1]. The most frequently reported EIMs include peripheral and/or axial arthropathy, cutaneous lesions, ophthalmological immune-inflammatory manifestations and hepatobiliary affections[2]. However, EIMs can involve almost any organ or tissue, and some rare manifestations, such as specific muscular involvement can also occur and might even herald an hidden IBD[3].

The occurrence of muscular involvement in IBD is scarce, and mostly related to orbital myositis, a subtype of orbital pseudotumor principally reported during Crohn’s disease (CD)[4,5]. Myositis affecting the limbs is a much rarer entity, and is mostly localized in the lower extremities, involving the gastrocnemius muscles, a clinical entity designated as “gastrocnemius myalgia syndrome” (GMS)[3]. To date, very little is known about the full spectrum of myositis occurring during the course of IBD.

We hereby report the first CD-associated GMS in a Belgian patient that turned out to be “granulomatous myositis”, an exceptionally rare subtype. In addition, we performed a literature review by searching EMBASE, MEDLINE, Scopus, and the Cochrane Library databases for studies published between January 1, 1970, and July 7, 2021, using the following keywords or MeSH terms: ‘Inflammatory Bowel Diseases’, ‘Crohn’s Disease’, ‘Ulcerative colitis’, ‘Myositis’, ‘Gastrocnemius myalgia syndrome’ and ‘Granulomatous Myositis’. Finally, we discuss the role of anti-tumour necrosis factor (TNF)- α therapy in this specific context.

CASE PRESENTATION

Chief complaints

A 33-year-old woman presented at the emergency department with a 5-d history of isolated tenderness in both calves leading to walking difficulties.

History of present illness

She denied any traumatism but reported a colitis relapse 30 d before her admission which resolved with a short-course of modified-release beclomethasone therapy.

History of past illness

The patient had a history of allergic asthma, *Helicobacter pylori* gastritis and unclassified colitis. Previous investigations performed during colitis flares did not discriminate a specific IBD pattern concluding in an unclassified colitis. The patient was not taking any chronic medication. Her familial history was not contributive.

Physical examination

Clinical findings on admission included bilateral swelling of both calves which were warm and painful to palpation. Motricity and sensitive perception were preserved. Examination of other muscles, joints and the spine was unremarkable and her abdomen was soft and non-tender.

Laboratory examinations

Initial laboratory investigations showed a C-reactive protein level at 106.6 mg/L (normal range, 0.4-12 mg/L) with mild neutrophilic leukocytosis (8770/mm³, normal range 1900-8000/mm³). Creatinine kinase (CK), aspartate aminotransferase, lactate dehydrogenase and D-dimer serum levels were within reference values. Hemocultures were negative as well as antinuclear, antineutrophil cytoplasmic and anti-*saccharomyces cerevisiae* antibodies.

Imaging examinations

Ultrasonography of lower limbs revealed a bilateral 5-millimeter-thick edema surrounding gastrocnemius muscles in the absence of vascular abnormality while a magnetic resonance imaging showed marked inflammation of muscles and their fascia in both legs, suggested by a high signal on T2-weighted images and a strong gadolinium enhancement on fat-suppressed T1-weighted images (Figure 1).

Muscular biopsy

A muscular biopsy of the right gastrocnemius revealed a remarkable inflammatory reaction that particularly involved the perimysial compartment. The infiltrate mainly comprised dense lymphoplasmocytic cells with the formation of several granulomatous structures wherein several histiocytes, sometimes multinucleated, were observed (Figure 2A, C and D). Endomysial inflammatory infiltrate was however less remarkable and rather discrete and focal. There was besides a very mild and discrete perivascular affinity for the inflammatory infiltrate but there was no frank/convincing vasculitis in the examined sections (Figure 2B). A few muscle fibers showed suspected myofibrillary disintegration. Immunohistochemical analyses showed an outstanding cohort of CD3 positive cells (with a slight predominance of CD8⁺ over CD4⁺ cells) (Figure 2C and D). Electron microscopy was generally unremarkable and showed rare lipofuscin deposits. Moreover, rare mastocytes were observed.

FINAL DIAGNOSIS

This histomyopathological affection in this clinical context was concordant with the GMS, a rare disorder classically associated with CD[6]. Moreover, a new ileocolonoscopy was performed during the hospital stay and revealed endoscopic pattern in favor of CD diagnosis, despite the absence of intestinal granuloma on histopathologic examination.

TREATMENT

Considering these results, the patient was started on a prednisone equivalent dose of 1 mg/kg, resulting in a rapid clinical and biochemical remission.

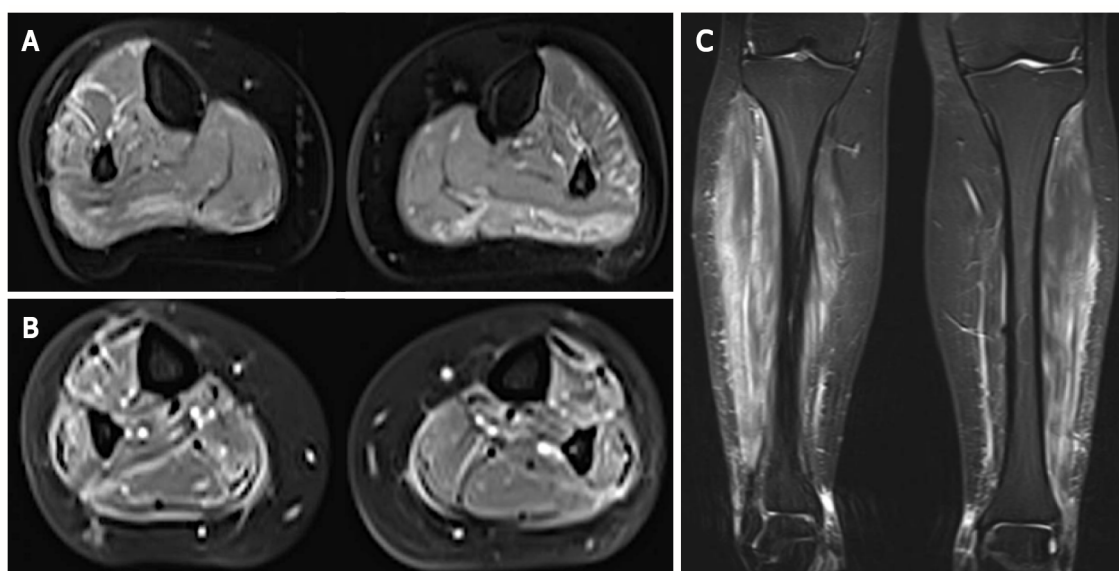


Figure 1 Magnetic resonance imaging of the calves in axial and frontal views. A and C: Demonstration of high signal on T2-weighted images in muscles from posterior and lateral compartments of the legs as well as in their surrounding fascia; B: This finding was accentuated on gadolinium-enhanced fat-suppressed T1-weighted images, suggestive of myositis and fasciitis.

OUTCOME AND FOLLOW-UP

Two months later, the patient experienced intestinal symptoms associated with a recurrence of pain in both legs during corticosteroids (CS) tapering. The ileocolonoscopy performed at that time showed a very severe ileocolitis [CD Endoscopic Index of Severity (CDEIS) scored at 31] with no histopathologic evidence of granuloma for which intravenous methylprednisolone (1 mg/kg for 5 d) and infliximab (5 mg/kg at week 0, 1 and 4) therapies were started to target both muscular and intestinal disease leading to clinical remission of both ileocolitis- and myositis-related symptoms. Oral corticotherapy was then prescribed and slowly tapered while infliximab was continued (5 mg/kg, every 8 wk). Twenty months later, both ileocolitis and myositis were quiescent.

DISCUSSION

Inflammatory myopathies (IM) occurring in the setting of IBD are considered as rare EIMs and have been roughly described in the literature to date[6]. We report the first CD-associated GMS in a Belgian patient that besides turned out to be “granulomatous”. This represents a very exceptional subtype as there has been only two such reported cases. To the best of our knowledge, only 15 cases of GMS are described in the international literature and always occurred in patients with CD (Table 1). Apart from GMS, orbital myositis, which is currently considered as a subtype of idiopathic orbital inflammation, has also been reported in patients with IBD, mainly CD[5]. Few cases of dermatomyositis (DM) and polymyositis have also been described during the course of IBDs and a recent study showed that DM was more frequent in ulcerative colitis patients than CD patients and control subjects[7]. Nevertheless, the true incidence of IM occurring in this context is probably underestimated as myalgia can be confused with joint manifestations or with non-inflammatory muscle disorders (*e.g.*, secondary to hypokalemia or medications) and by the fact that clinicians may rule out myositis’ diagnosis in the absence of CK elevation in serum.

The first case of myositis affecting gastrocnemius muscles in CD was reported in 1979 by Ménard *et al* [8] who described a 44-year-old man with granulomatous myositis localized to the calf occurring two months before CD diagnosis[8]. Since then, several cases have been reported, sharing the classically following features: (1) Calf-limited myalgia revealing localized myositis; (2) Normal serum CK levels; and (3) A high early-response rate to CS therapy[9]. In 2003, this entity was denominated as “GMS” by Christopoulos *et al*[3], a term adopted in the literature ever since[10]. Most patients developed GMS months or years after the onset of CD but myositis could precede gastrointestinal manifestations by up to 10 years[11]. When CD had been diagnosed before GMS, the intestinal disease was active in most cases at myositis’ diagnosis (Table 1). Other EIMs were associated with GMS in 50% of patients which is in accordance with previous observations that patients who presented an EIM are at higher risk to develop another one[1].

Table 1 Case descriptions of gastrocnemius myalgia syndrome reported in Crohn's disease

Ref.	Age (yr)/sex at GMS onset	Initial presentation, time-to-onset	Active CD at time of GMS dx	CK serum level	Biopsy	Treatment	Corticosteroids-dependence (d) or resistance (r)
Ménard <i>et al</i> [8], 1976	44/M	Muscular, 2 mo	No	N	Granulomatous myositis	PDS ¹ (80 mg/d)	No
Gilliam <i>et al</i> [13], 1981	19/M	Digestive, 6 mo	Yes	N	Necrotizing vasculitis	PDS ¹ (60 mg/d)	No
Hall <i>et al</i> [10], 1985	32/F	Muscular, 120 mo	Yes	N	Non-granulomatous myositis	5-ASA ¹ , PDS ¹ (25 mg/d)	No
Drabble and Gani [14], 1992	50/M	Digestive, 168 mo	Yes	N	Not performed	Hydrocortisone ¹ (400 mg/d), PDS ¹	No
Disdier <i>et al</i> [11], 1997, Case 1	26/F	Muscular, 48 mo	Yes	N	Necrotizing vasculitis	PDS ¹ (60 mg/d), CYC ¹ , 5-ASA ¹	Yes (r)
Disdier <i>et al</i> [11], 1997, Case 2	21/F	Simultaneous	Yes	N	Vasculitis	PDS (1 mg/kg/d), AZA ¹	Yes (d)
Christopoulos <i>et al</i> [3], 2003	19/F	Simultaneous	Yes	N	Granulomatous myositis	PDS ¹ (0.5 mg/kg/d)	No
Ullrich <i>et al</i> [15], 2009	25/F	Digestive, 84 mo	Yes	N	Vasculitis	PDS (50 mg/d), AZA, IFX ¹	Yes (d)
Co <i>et al</i> [16], 2010	15/F	Digestive, 8 mo	Yes	N	Not performed	IFX ¹	/
Mogul <i>et al</i> [17], 2010	15/M	Digestive, 60 mo	No	N	Non-granulomatous myositis	PDS ¹ (40 mg/d), MTX ¹	No
Piette <i>et al</i> [18], 2010	45/M	Simultaneous	Yes	(3-13 × N)	Vasculitis	PDS ¹ (1 mg/kg/d)	No
Goldshmid <i>et al</i> [19], 2011	24/F	Simultaneous	Yes	(330 U/L)	Not performed	MPDS (100 mg/d), IFX ¹ , AZA ¹	Yes (d)
Vadala di Prampero <i>et al</i> [20], 2016	26/M	Digestive, 72 mo	Yes	N	Non-granulomatous myositis	PDS (60 mg/d), AZA ¹ (chronic), Adalimumab ¹	Yes (d)
Saffar[12], 2017	33/F	Digestive, 120 mo	Yes	N	Not performed	PDS, IFX ¹	Yes (r)
Osada <i>et al</i> [9], 2018	38/M	Digestive, 3 mo	Yes	N	Non-granulomatous myositis	PDS, AZA ¹ , 5-ASA ¹	Yes (d)
Current case	33/F	Simultaneous	Yes	N	Granulomatous myositis	MDPS (0.8/kg/d), IFX ¹	Yes (d)

¹These treatment modalities are those that induced a persistent remission of myositis-related symptoms.

GMS: Gastrocnemius myalgia syndrome; CD: Crohn's disease; MDPS: Mitochondrial-derived peptides; IFX: Infliximab; ASA: Aminosaliclylate; AZA: Azathioprine; PDS: Peroxydisulfate.

While clinical and biological features in patients with GMS are generally characteristics, histomorphopathological findings are rather heterogeneous. In fact, our case is only the third in which granulomatous lesions were observed while all remaining reported cases were characterized by non-granulomatous inflammation (4 cases) or localized vasculitis (5 cases) (Table 1). However, whatever the histopathologic image observed, the inflammatory infiltrate was more often localized in the perimysium and more discrete in the endomysium, probably explaining why most patients with GMS have normal CK values. GMS could therefore represent a form of localized “perimyositis” with no or limited myofiber injury. This observation also suggests that the immune response is directed against connective tissue components or vessels rather than against the myofibers themselves.

Finally, while GMS was initially controlled in this case by oral CS therapy, it ultimately relapsed during tapering. In this context, the presence of a concomitant severe active ileocolitis prompted us to start an anti-TNF- α agent. While CS were the first-line treatment prescribed in almost all cases of GMS, their efficacy, however, was not enduring as 6/16 patients (including ours) relapsed during dose de-escalation (Table 1). Moreover, two other patients were initially refractory to CS[12,13]. Various drugs were used in these corticosteroid-dependent or refractory cases. Anti-TNF- α agents were constantly associated with GMS remission in the six cases where they were introduced, suggesting that the

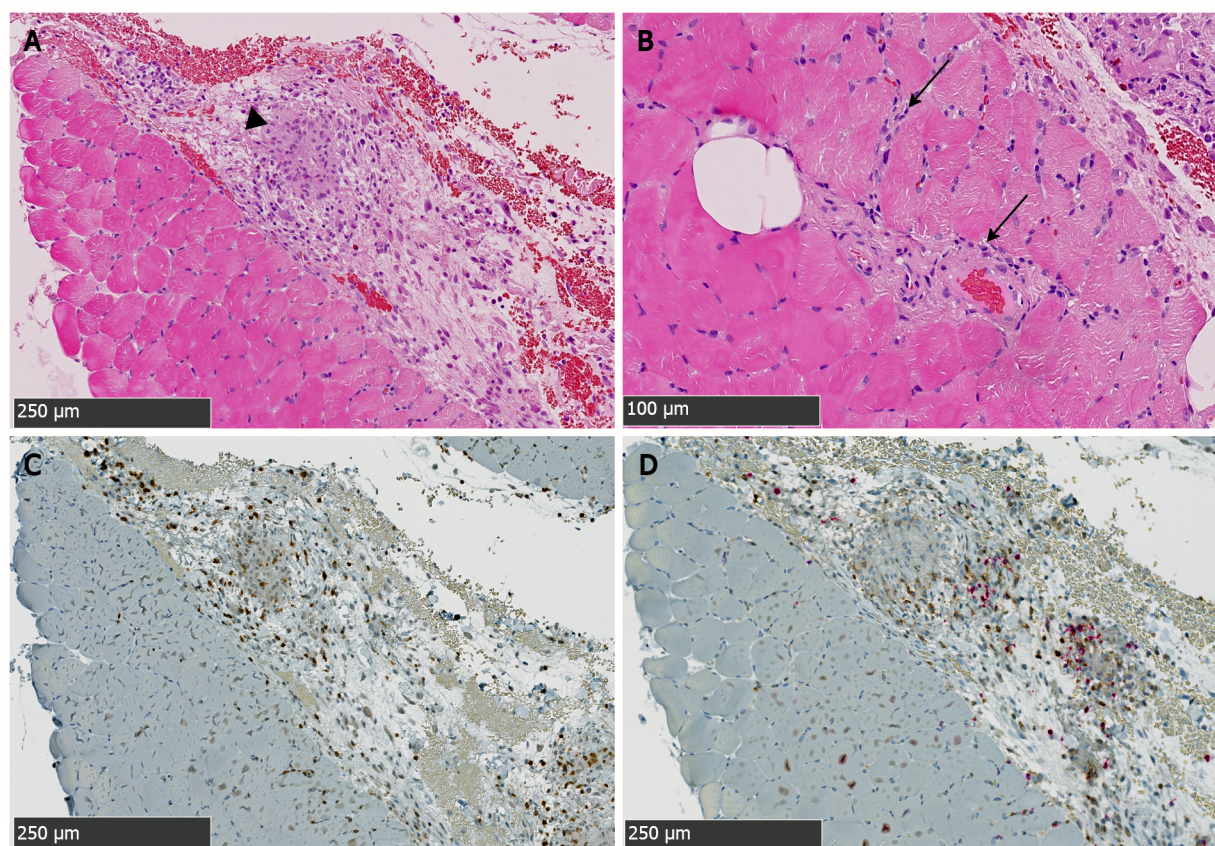


Figure 2 Biopsy specimen from the right gastrocnemius muscle showing the intense immune-inflammatory reaction. A: This hematoxylin and eosin-stained section shows the granulomatous nature (arrowhead) of this Crohn's disease-associated skeletal myositis, predominating in the perimysial compartment; B: Discrete and focal immune infiltrates are found in the endomysium and around vascular structures (arrows); C and D: Immunohistochemical staining characterize immune cell-types involved therein: Co-staining for CD3 (brown staining) and CD20 lymphocytes (red staining) shown in C reveals predominance of CD3⁺ lymphocytes over CD20⁺ cells. CD4 and CD8 T cells subtyping shown in D (brown and red staining respectively) further reveals a slight predominance of CD8⁺ over CD4⁺ cells.

muscular and intestinal affections in this context could share a common pathophysiological mechanism. Importantly, our case represents the first GMS with granulomatous inflammation treated with an anti-TNF- α agent. Further case descriptions and/or case series will be required to ascertain the role of such therapy in this specific context.

CONCLUSION

In conclusion, we report a rare extra-intestinal manifestation of CD, namely a GMS, characterized by a very rarely reported granulomatous perimyositis. The rapid relapse of GMS during CS tapering and the emergence of a severe active ileocolitis prompted the introduction of an anti-TNF- α agent that resulted in persistent clinical remission of both disorders. This might further suggest the effectiveness of such agents in CS-dependent or refractory cases. Finally, physicians should remain aware of the eventual emergence of a such complicating myositis when musculo-skeletal symptoms arise in IBD patients even in the absence of CK elevation.

ACKNOWLEDGEMENTS

We thank Anaïs Boisson (Laboratory of Molecular Immunology, Jules Bordet Institute, Brussels, 1000, Belgium) who performed immunohistochemistry stainings.

FOOTNOTES

Author contributions: Lambot F, Catherine J and Otero Sanchez L managed the patient; Kadhim H did myopathology

diagnosis and analyses; Catherine J, Otero Sanchez L and Meurant V designed the study and collected data; Catherine J and Otero Sanchez L drafted and wrote the manuscript; Liefferinckx C, Lambot F and Kadhim H provided their expertise throughout the course of the work by revising and editing the manuscript; all authors approved the final version of the manuscript to be published.

Supported by National Fund for Scientific Research (F.R.S-FNRS) as research fellows to Catherine J and Otero Sanchez L; Fonds Erasme to Otero Sanchez L; and F.R.S-FNRS as postdoctoral fellow to Liefferinckx C.

Informed consent statement: The study was performed in accordance with the ethical standards of the Helsinki Declaration and was approved by the institutional review board of CHU Tivoli (approval number #1396). Patient's informed consent was obtained by Meurant V.

Conflict-of-interest statement: Liefferinckx C received consultancy fees from Takeda and Galapagos; speaker fees from Sandoz, Janssen and AbbVie.

CARE Checklist (2016) statement: The authors have read the CARE Checklist (2016), and the manuscript was prepared and revised according to the CARE Checklist (2016).

Open-Access: This article is an open-access article that was selected by an in-house editor and fully peer-reviewed by external reviewers. It is distributed in accordance with the Creative Commons Attribution NonCommercial (CC BY-NC 4.0) license, which permits others to distribute, remix, adapt, build upon this work non-commercially, and license their derivative works on different terms, provided the original work is properly cited and the use is non-commercial. See: <https://creativecommons.org/licenses/by-nc/4.0/>

Country/Territory of origin: Belgium

ORCID number: Julien Catherine 0000-0001-8825-8126; Hazim Kadhim 0000-0003-4943-9172; Frédéric Lambot 0000-0003-3585-3444; Claire Liefferinckx 0000-0002-2046-4051; Virginie Meurant 0000-0002-7626-8543; Lukas Otero Sanchez 0000-0002-8013-1371.

S-Editor: Fan JR

L-Editor: A

P-Editor: Fan JR

REFERENCES

- 1 Vavricka SR, Schoepfer A, Scharl M, Lakatos PL, Navarini A, Rogler G. Extraintestinal Manifestations of Inflammatory Bowel Disease. *Inflamm Bowel Dis* 2015; **21**: 1982-1992 [PMID: 26154136 DOI: 10.1097/MIB.0000000000000392]
- 2 Ott C, Schölmerich J. Extraintestinal manifestations and complications in IBD. *Nat Rev Gastroenterol Hepatol* 2013; **10**: 585-595 [PMID: 23835489 DOI: 10.1038/nrgastro.2013.117]
- 3 Christopoulos C, Savva S, Pylarinou S, Diakakis A, Papavassiliou E, Economopoulos P. Localised gastrocnemius myositis in Crohn's disease. *Clin Rheumatol* 2003; **22**: 143-145 [PMID: 12740681 DOI: 10.1007/s10067-002-0679-9]
- 4 Bourikas LA, Roussomoustakaki M, Papadaki E, Valatas V, Koutroubakis IE, Papadakis KA, Kouroumalis EA. A case of orbital myositis preceding the intestinal symptoms of Crohn's disease. *J Crohns Colitis* 2010; **4**: 349-350 [PMID: 21122528 DOI: 10.1016/j.crohns.2010.05.005]
- 5 Culver EL, Salmon JF, Frith P, Travis SP. Recurrent posterior scleritis and orbital myositis as extra-intestinal manifestations of Crohn's disease: Case report and systematic literature review. *J Crohns Colitis* 2008; **2**: 337-342 [PMID: 21172235 DOI: 10.1016/j.crohns.2008.06.002]
- 6 Bourikas LA, Papadakis KA. Musculoskeletal manifestations of inflammatory bowel disease. *Inflamm Bowel Dis* 2009; **15**: 1915-1924 [PMID: 19408334 DOI: 10.1002/ibd.20942]
- 7 Tseng CC, Chang SJ, Liao WT, Chan YT, Tsai WC, Ou TT, Wu CC, Sung WY, Hsieh MC, Yen JH. Increased Cumulative Incidence of Dermatomyositis in Ulcerative Colitis: a Nationwide Cohort Study. *Sci Rep* 2016; **6**: 28175 [PMID: 27325143 DOI: 10.1038/srep28175]
- 8 Ménard DB, Haddad H, Blain JG, Beaudry R, Devroede G, Massé S. Granulomatous myositis and myopathy associated with crohn's colitis. *N Engl J Med* 1976; **295**: 818-819 [PMID: 958278 DOI: 10.1056/NEJM197610072951506]
- 9 Osada A, Yamada H, Takehara S, Tozuka Y, Fukushima T, Oka H, Okazaki H, Nagaoka S. Gastrocnemius Myalgia as a Rare Initial Manifestation of Crohn's Disease. *Intern Med* 2018; **57**: 2001-2006 [PMID: 29491286 DOI: 10.2169/internalmedicine.0327-17]
- 10 Hall MJ, Thomas WE, Cooper BT. Gastrocnemius myositis in a patient with inflammatory bowel disease. *Digestion* 1985; **32**: 296-300 [PMID: 2866130 DOI: 10.1159/000199251]
- 11 Disdier P, Swiader L, Harlé JR, Pellissier JF, Figarella-Branger D, Veit V, Gérolami A, Arlet Ph, Weiller PJ. Crohn's disease and gastrocnemius vasculitis: two new cases. *Am J Gastroenterol* 1997; **92**: 880-882 [PMID: 9149206]
- 12 Saffar H. An unusual case of gastrocnemius muscle syndrome in a patient with Crohn's Disease. (e-pub ahead of print 2017; DOI: 10.1594/EURORAD/CASE.14254). [cited 10 August 2021]. Available from: <https://journals.lww.com/pec-online/toc/9000/00000>
- 13 Gilliam JH 3rd, Challa VR, Agudelo CA, Albertson DA, Huntley CC. Vasculitis involving muscle associated with Crohn's

- colitis. *Gastroenterology* 1981; **81**: 787-790 [PMID: [7262523](#)]
- 14 **Drabble EM**, Gani JS. Acute gastrocnemius myositis. Another extraintestinal manifestation of Crohn's disease. *Med J Aust* 1992; **157**: 318-320 [PMID: [1435473](#)]
- 15 **Ullrich S**, Schinke S, Both M, Knop KC, Kirkiles-Smith NC, Gross WL, Lamprecht P. Refractory central nervous system vasculitis and gastrocnemius myalgia syndrome in Crohn's disease successfully treated with anti-tumor necrosis factor-alpha antibody. *Semin Arthritis Rheum* 2009; **38**: 337-347 [PMID: [18304612](#) DOI: [10.1016/j.semarthrit.2008.01.008](#)]
- 16 **Co M**, Batke M, Truding R. "Gastrocnemius Myalgia Syndrome" - First Description in a Pediatric Patient with Crohn's Disease. Case Report And Literature Review: 970. *Off J Am Coll Gastroenterol ACG* 2010; **105**: S351 [DOI: [10.14309/0000434-201010001-00970](#)]
- 17 **Mogul Z**, Katz S, Bachman TR, Urmacher C. Isolated gastrocnemius myositis related to Crohn's disease. *Gastroenterol Hepatol (N Y)* 2010; **6**: 453-455 [PMID: [20827369](#)]
- 18 **Piette AM**, Beaudouin C, Charles P, Ackermann F, François D, Leport J, Guth A, Blétry O, Kahn JE, Geffray L. Sale temps pour une grenouille. *Rev Médecine Interne* 2010; **31**: 570-574 [DOI: [10.1016/j.revmed.2010.06.004](#)]
- 19 **Goldshmid O**, Dovorish Z, Zehavi T, Eisen A, Bar-Dayyan Y, Amital H. Coexistent pyoderma gangrenosum and tibialis anterior myositis as presenting manifestations of Crohn's disease: case report and review of the literature. *Rheumatol Int* 2011; **31**: 525-527 [PMID: [19847433](#) DOI: [10.1007/s00296-009-1168-0](#)]
- 20 **Vadala di Prampero S**, Marino M, Toso F, Avellini C, Nguyen V, Sorrentino D. Isolated Bilateral Gastrocnemius Myositis in Crohn Disease Successfully Treated with Adalimumab. *Case Rep Gastroenterol* 2016; **10**: 661-667 [PMID: [27920658](#) DOI: [10.1159/000448880](#)]



Published by **Baishideng Publishing Group Inc**
7041 Koll Center Parkway, Suite 160, Pleasanton, CA 94566, USA

Telephone: +1-925-3991568

E-mail: bpgoffice@wjgnet.com

Help Desk: <https://www.f6publishing.com/helpdesk>

<https://www.wjgnet.com>

