

World Journal of *Gastroenterology*

World J Gastroenterol 2023 April 28; 29(16): 2359-2514



EDITORIAL

- 2359 Future therapeutic implications of new molecular mechanism of colorectal cancer
Lu S, Jia CY, Yang JS

OPINION REVIEW

- 2369 Current status and progress in laparoscopic surgery for gallbladder carcinoma
Sun J, Xie TG, Ma ZY, Wu X, Li BL

REVIEW

- 2380 Molecular regulation mechanism of intestinal stem cells in mucosal injury and repair in ulcerative colitis
Zheng L, Duan SL
- 2397 SARS-CoV-2 induced liver injury: Incidence, risk factors, impact on COVID-19 severity and prognosis in different population groups
Liatsos GD
- 2433 Ferroptosis regulates key signaling pathways in gastrointestinal tumors: Underlying mechanisms and therapeutic strategies
Rabitha R, Shivani S, Showket Y, Sudhandiran G
- 2452 Updates on global epidemiology, risk and prognostic factors of gastric cancer
Yang WJ, Zhao HP, Yu Y, Wang JH, Guo L, Liu JY, Pu J, Lv J

ORIGINAL ARTICLE

Retrospective Cohort Study

- 2469 Older adults with acute severe ulcerative colitis have similar steroid non-response and colectomy rates as younger adults
Subhaharan D, Ramaswamy PK, Willmann L, Moattar H, Bhullar M, Ishaq N, Dorrington A, Shukla D, McIvor C, Edwards J, Mohsen W
- 2479 Liver histopathological lesions is severe in patients with normal alanine transaminase and low to moderate hepatitis B virus DNA replication
Jiang SW, Lian X, Hu AR, Lu JL, He ZY, Shi XJ, Zhu DD, Wang ZY, Huang GC

Retrospective Study

- 2495 Cholangioscopy-assisted extraction through novel papillary support for small-calibre and sediment-like common bile duct stones
Zhang WG, Chai NL, Zhang B, Li X, Wang JF, Dong H, Feng YJ, Linghu EQ

Observational Study

- 2502** Predictive value of presepsin and acylcarnitines for severity and biliary drainage in acute cholangitis

Zhang HY, Xiao HL, Wang GX, Lu ZQ, Xie MR, Li CS

ABOUT COVER

Editorial Board of *World Journal of Gastroenterology*, Vasily Isakov, AGAF, DSc, MD, PhD, Chief Doctor, Full Professor, Senior Scientist, Department of Gastroenterology and Hepatology, Federal Research Center of Nutrition, Biotechnology and Food Safety, Moscow 115446, Russia. Vasily.isakov@gmail.com

AIMS AND SCOPE

The primary aim of *World Journal of Gastroenterology* (WJG, *World J Gastroenterol*) is to provide scholars and readers from various fields of gastroenterology and hepatology with a platform to publish high-quality basic and clinical research articles and communicate their research findings online. WJG mainly publishes articles reporting research results and findings obtained in the field of gastroenterology and hepatology and covering a wide range of topics including gastroenterology, hepatology, gastrointestinal endoscopy, gastrointestinal surgery, gastrointestinal oncology, and pediatric gastroenterology.

INDEXING/ABSTRACTING

The WJG is now abstracted and indexed in Science Citation Index Expanded (SCIE, also known as SciSearch®), Current Contents/Clinical Medicine, Journal Citation Reports, Index Medicus, MEDLINE, PubMed, PubMed Central, Scopus, Reference Citation Analysis, China National Knowledge Infrastructure, China Science and Technology Journal Database, and Superstar Journals Database. The 2022 edition of Journal Citation Reports® cites the 2021 impact factor (IF) for WJG as 5.374; IF without journal self cites: 5.187; 5-year IF: 5.715; Journal Citation Indicator: 0.84; Ranking: 31 among 93 journals in gastroenterology and hepatology; and Quartile category: Q2. The WJG's CiteScore for 2021 is 8.1 and Scopus CiteScore rank 2021: Gastroenterology is 18/149.

RESPONSIBLE EDITORS FOR THIS ISSUE

Production Editor: *Yu-Xi Chen*; Production Department Director: *Xiang Li*; Editorial Office Director: *Jia-Ru Fan*.

NAME OF JOURNAL

World Journal of Gastroenterology

ISSN

ISSN 1007-9327 (print) ISSN 2219-2840 (online)

LAUNCH DATE

October 1, 1995

FREQUENCY

Weekly

EDITORS-IN-CHIEF

Andrzej S Tarnawski

EDITORIAL BOARD MEMBERS

<http://www.wjgnet.com/1007-9327/editorialboard.htm>

PUBLICATION DATE

April 28, 2023

COPYRIGHT

© 2023 Baishideng Publishing Group Inc

INSTRUCTIONS TO AUTHORS

<https://www.wjgnet.com/bpg/gerinfo/204>

GUIDELINES FOR ETHICS DOCUMENTS

<https://www.wjgnet.com/bpg/GerInfo/287>

GUIDELINES FOR NON-NATIVE SPEAKERS OF ENGLISH

<https://www.wjgnet.com/bpg/gerinfo/240>

PUBLICATION ETHICS

<https://www.wjgnet.com/bpg/GerInfo/288>

PUBLICATION MISCONDUCT

<https://www.wjgnet.com/bpg/gerinfo/208>

ARTICLE PROCESSING CHARGE

<https://www.wjgnet.com/bpg/gerinfo/242>

STEPS FOR SUBMITTING MANUSCRIPTS

<https://www.wjgnet.com/bpg/GerInfo/239>

ONLINE SUBMISSION

<https://www.f6publishing.com>



Retrospective Study

Cholangioscopy-assisted extraction through novel papillary support for small-calibre and sediment-like common bile duct stones

Wen-Gang Zhang, Ning-Li Chai, Bo Zhang, Xiao Li, Jia-Feng Wang, Hao Dong, Yu-Jie Feng, En-Qiang Linghu

Specialty type: Gastroenterology and hepatology

Provenance and peer review:

Unsolicited article; Externally peer reviewed.

Peer-review model: Single blind

Peer-review report's scientific quality classification

Grade A (Excellent): 0
Grade B (Very good): 0
Grade C (Good): 0
Grade D (Fair): 0
Grade E (Poor): 0

P-Reviewer: De Luca L, Italy;
Demirli Atici S, Turkey

Received: February 2, 2023

Peer-review started: February 2, 2023

First decision: March 7, 2023

Revised: March 9, 2023

Accepted: April 7, 2023

Article in press: April 7, 2023

Published online: April 28, 2023



Wen-Gang Zhang, Ning-Li Chai, Bo Zhang, Xiao Li, Jia-Feng Wang, Hao Dong, Yu-Jie Feng, En-Qiang Linghu, Department of Gastroenterology, The First Medical Center of Chinese PLA General Hospital, Beijing 100853, China

Corresponding author: En-Qiang Linghu, PhD, Chief Physician, Department of Gastroenterology, The First Medical Center of Chinese PLA General Hospital, No. 28 Fuxing Road, Haidian District, Beijing 100853, China. linghuenqiang@vip.sina.com

Abstract

BACKGROUND

To date, endoscopic retrograde cholangiopancreatography has become a well-established treatment for common bile duct (CBD) stones. However, it is not suitable for some special patients, such as pregnant women, children or those who cannot stop taking anti-coagulation/anti-platelet agents because of radiation injury and the risk of postoperative bleeding resulting from endoscopic sphincterotomy. To overcome these two problems, this study introduced cholangioscopy-assisted extraction through a novel papillary support for small-calibre and sediment-like CBD stones.

AIM

To assess the feasibility and safety of cholangioscopy-assisted extraction through a novel papillary support (CEPTS) for small-calibre and sediment-like common bile duct (CBD) stones.

METHODS

This Retrospective study was approved by the Ethics Committee of the Chinese PLA General Hospital. We designed a covered single dumbbell-style papillary support between 2021 and 2022. Between July 2022 and September 2022, 7 consecutive patients with small-calibre (cross diameter ≤ 1.0 cm) or sediment-like CBD stones underwent CETPS procedures in our center. The clinical characteristics and treatment outcomes of these 7 patients were extracted from a prospectively collected database. And the related data were analyzed. Informed consent was obtained from all participating patients.

RESULTS

A total of 2 patients had yellow sediment-like CBD stones, and aspiration extraction was performed after the insertion of papillary support. Of the 5 patients with clumpy CBD stones (0.4-1.0 cm), 2 underwent basket extraction under direct

vision for a single stone (0.5-1.0 cm, black and black grey), 1 underwent balloon plus aspiration extraction under direct vision for 5 stones (0.4-0.6 cm, brown), and 2 underwent aspiration extraction only for a single stone (0.5-0.6 cm, yellow, none). Technical success, namely, no residual stones in the CBD or left and right hepatic ducts, was achieved in all 7 cases (100%). The median operating time was 45.0 minutes (range 13.0-87.0 minutes). Postoperative pancreatitis (PEP) occurred in one case (14.3%). Hyperamylasaemia without abdominal pain was noted in 2 of 7 patients. No residual stones or cholangitis were found during the follow-up.

CONCLUSION

CETPS appeared to be feasible to treat patients with small-calibre or sediment-like CBD stones. Patients, especially pregnant women and those who cannot stop anticoagulation/anti-platelet agents, could benefit from this technique.

Key Words: Cholangioscopy; Common bile duct stones; Papillary support

©The Author(s) 2023. Published by Baishideng Publishing Group Inc. All rights reserved.

Core Tip: Endoscopic retrograde cholangiopancreatography (ERCP) has become a well-established treatment for common bile duct (CBD) stones. However, the standard ERCP technique always requires endoscopic sphincterotomy (EST), which might lead to the loss of sphincter of Oddi function and some adverse events, including bleeding and perforation. Moreover, radiation injury makes the standard ERCP technique unsuitable for special patients, such as pregnant women and children. To overcome these problems, the present study introduced cholangioscopy-assisted extraction through a novel papillary support for small-calibre and sediment-like CBD stones, reducing radiation injury and avoiding EST.

Citation: Zhang WG, Chai NL, Zhang B, Li X, Wang JF, Dong H, Feng YJ, Linghu EQ. Cholangioscopy-assisted extraction through novel papillary support for small-calibre and sediment-like common bile duct stones. *World J Gastroenterol* 2023; 29(16): 2495-2501

URL: <https://www.wjgnet.com/1007-9327/full/v29/i16/2495.htm>

DOI: <https://dx.doi.org/10.3748/wjg.v29.i16.2495>

INTRODUCTION

Endoscopic retrograde cholangiopancreatography (ERCP) has become the standard treatment for common bile duct (CBD) stones[1,2]. However, how to reduce radiation injury for special patients, including pregnant women and children, during this technique remains an important issue. Moreover, endoscopic sphincterotomy (EST), which is always necessary during stone extraction procedures, might lead to the loss of sphincter of Oddi (SO) function, some early adverse events, including bleeding and perforation, and some late adverse events, such as cholangitis, malignant degeneration and recurrent CBD stones, owing to free duodenobiliary reflux[3-5]. Importantly, EST was not appropriate for those patients who could not stop taking anti-coagulation/anti-platelet agents.

The emergence of peroral cholangioscopy made it possible to remove CBD stones under direct vision with less radiation injury[6,7]. However, the relatively difficult operation hindered the further development of this technique. In terms of EST, some studies introduce the self-expandable metal stent (SEMS) to avoid EST[8,9]. However, the SEMS was relatively too long and not desirable.

To overcome the problems mentioned above, we optimized the existing metal stent and made a kind of single dumbbell-style papillary support to facilitate cholangioscopy-assisted stone extraction, avoid EST and preserve SO function. In this study, we introduced cholangioscopy-assisted extraction through a novel papillary support (CETPS) for small-calibre and sediment-like CBD stones. This technique combined the advantages of the preservation of SO function and cholangioscopy-assisted stone extraction under direct vision with less radiation injury.

MATERIALS AND METHODS

Patients

This retrospective study was approved by the Ethics Committee of the Chinese PLA General Hospital. Informed consent was obtained from all participating patients. Of note, some instruments, including the cholangioscope, basket and papillary support, were free for patients in this study.

Endoscopists made the clinical decision to perform CETPS for patients diagnosed with small-calibre (cross diameter ≤ 1.0 cm) or sediment-like CBD stones by magnetic resonance cholangiopancreatography (MRCP) and/or endoscopic ultrasound (EUS). Patients undergoing CETPS between July 2022 and September 2022 were enrolled in this study. Related data were extracted from a prospectively collected database.

The stone size was measured under MRCP on the maximal cross section. The definition of operation time was the course between the endoscope inserting into and withdrawing from the body. Technical success was defined as no residual stones in the CBD and left and right hepatic ducts, which was confirmed under cholangioscopy after stone extraction.

CETPS procedure

All procedures were performed by one endoscopist who has experience performing more than 2000 ERCP procedures in total.

First, biliary intubation was conducted. Second, a covered single dumbbell-style support (12 mm in diameter, 25–30 mm in length) was placed in the distal CBD and papilla (Figure 1A). Third, for sediment-like CBD stones, endoscopic aspiration was performed under negative pressure (Figures 1B and 2A); for single clumpy CBD stones, a cholangioscope (Micro-Tech, eyeMax, 9F) was inserted into the CBD, and basket extraction was performed through the working tunnel of the cholangioscope under direct vision (Figures 1C–E, 2B and Video 1); for multiple clumpy CBD stones, a cholangioscope (Micro-Tech, eyeMax, 11F) was inserted into the CBD, and balloon extraction was performed through the working tunnel of the cholangioscope under direct vision (Figures 1F and G, 2C and Video 1). Fourth, the cholangioscope was inserted into the CBD again to confirm whether there were remnant stones. Finally, the papillary support was removed (Figure 1H and I).

Postoperative management

Patients underwent routine blood examination and amylase and lipase tests 24 and 72 h postoperatively. Patients underwent computed tomography (CT) and/or endoscopy if abnormal symptoms or blood test parameters were found postoperatively.

Patients were fasted for 1 day after the procedure, and a liquid diet was followed for an additional 1 day if no adverse events occurred. The diet was gradually restored to normal starting on the third day. Postoperative medications mainly included a double-dose proton pump inhibitor and antibiotics for one day. Somatostatin was used if PEP occurred, and the fasting time was extended accordingly. Of note, of the 7 patients, 3 had gallstones and underwent cholecystectomy within 1 mo after CETPS to avoid the recurrence of CBD stones.

Follow-up with a routine duodenoscopy was performed at 2 wk postoperatively to observe the papillary morphology.

Adverse events

In the article, PEP, postoperative bleeding, perforation and cholangitis were regarded as major adverse events. The diagnostic criteria of postoperative bleeding was based on the onset of clinical symptoms, including melena or haematemesis or a decrease > 2 g/dL in haemoglobin level. The present study used the diagnostic and classification criteria of PEP proposed by Cotton *et al*[10]: (1) New or worsened abdominal pain; (2) Serum amylase at least three times the upper limit of normal, measured more than 24 h after the procedure; and (3) New or prolonged hospitalization for at least 2 days.

Statistical analysis

Nonparametric data are expressed as medians.

RESULTS

Between July 2022 and September 2022, 7 patients underwent CETPS at the Chinese PLA General Hospital. Clinical characteristics and treatment outcomes for the 7 patients are shown in Table 1.

A total of 2 patients had yellow sediment-like CBD stones, and aspiration extraction was performed after the insertion of papillary support. Of the 5 patients with clumpy CBD stones (0.4–1.0 cm), 2 underwent basket extraction under direct vision for a single stone (0.5–1.0 cm, black and black grey), 1 underwent balloon plus aspiration extraction under direct vision for 5 stones (0.4–0.6 cm, brown), and 2 underwent aspiration extraction only for a single stone (0.5–0.6 cm, yellow, none).

Technical success, namely, no residual stones in the CBD or left and right hepatic ducts, was achieved in all 7 cases (100%). The median operating time was 45.0 min (range 13.0–87.0 min).

Mild PEP occurred in one case (14.3%). Hyperamylasaemia without abdominal pain was noted in 2 of 7 patients. No residual stones or cholangitis were found during the follow-up.

In one case, the papillary support was dilated by an extraction balloon before the insertion of the cholangioscope, given that the papillary was not dilated enough after the insertion of support.

Table 1 Clinical characteristics and treatment outcomes for 7 patients with choledocholithiasis undergoing cholangioscopy-assisted extraction through novel papillary support

Case No.	Age (yr)/sex	Chief complaint	Stone size (cm) ¹	Stone colour	Number of stones	Operation time (min)	Balloon dilatation	Extraction method	Postoperative adverse events
1	44/female	Abdominal pain	0.6	None	1	64	Yes	Aspiration	Postoperative pancreatitis
2	54/female	Abdominal pain	1.0	Black grey	1	53	No	Basket	Hyperamylasaemia
3	25/female	Abdominal pain	0.4-0.6	Brown	5	45	No	Balloon and aspiration	None
4	68/male	Abdominal pain	0.5	Black	1	87	No	Basket	None
5	29/female	Abdominal pain	Sediment-like	Yellow	Sediment-like	13	No	Aspiration	None
6	83/male	Abdominal pain	Sediment-like	Yellow	Sediment-like	31	No	Aspiration	Hyperamylasaemia
7	32/female	Abdominal pain	0.5 cm	Yellow	1	39	No	Aspiration	None

¹The stone size was measured under computerized tomography on the maximal cross section.

DISCUSSION

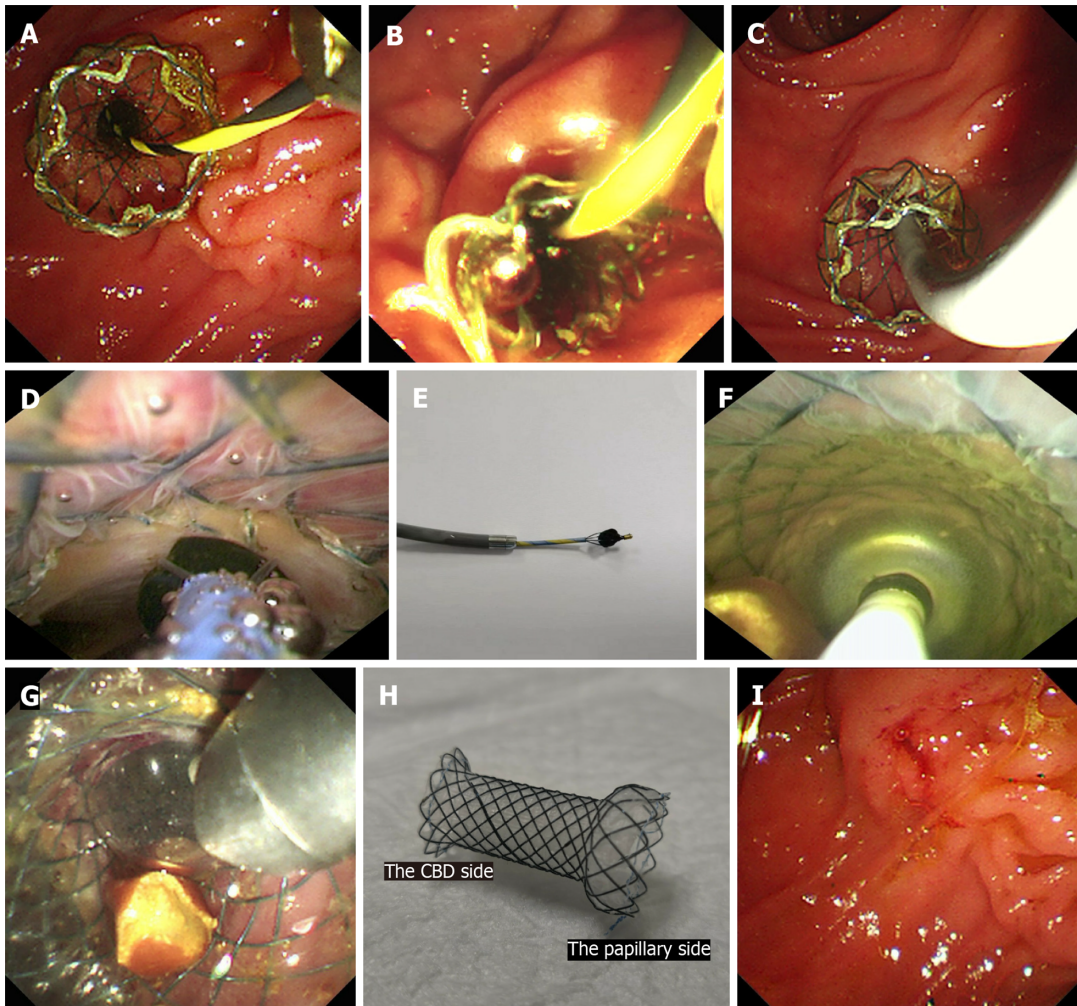
This study showed that CETPS appears to be a feasible and safe treatment option for small-calibre (cross diameter ≤ 1.0 cm) or sediment-like CBD stones with a 100.0% (7/7) technical success rate and a 14.3% (1/7) PEP rate without other adverse events, such as perforation, bleeding and cholangitis.

The major advantage of CETPS over ERCP with EST for CBD stones is that SO function is retained, avoiding relevant adverse events, including bleeding, perforation, malignant degeneration and recurrent CBD stones[11-13]. Jun *et al*[8] has confirmed that the use of transpapillary SEMSs was effective in the preservation of SO function. Moreover, Cho *et al*[9] concluded that SEMSs can be used for the extraction of CBD stones in patients on dual antiplatelet agents and do not lead to haemorrhagic or thromboembolic events. Of note, the papillary support introduced in the present study has the following merits compared with the SEMSs used in previous studies[8,9]: (1) The novel papillary support was shorter (25-30 mm) than other SEMSs (40-50 mm); (2) the CBD side of the support had a 70-degree angle; and (3) the papillary side of the support had a single dumbbell-style design. In the case of distal stones, the stones might get stuck in the middle between the relatively long SEMS and CBD wall after stent insertion, so Jun *et al*[8] recommended that the patient's position should be tilted to move the stones from the distal CBD to mid-CBD before stent insertion, although it did not always work. Therefore, we designed a support with a shorter length (25-30 mm) and 70-degree angle on the CBD side (Figure 1H), which could lift the stones into the proximal CBD during the process of stent insertion. On the other hand, the single dumbbell-style design (Figure 1H) on the papillary side could protect the support from entering the CBD due to the persistent friction from the cholangioscope. In terms of the PEP, this study presented a reasonable 14.3% (1/7) rate. Theoretically, the use of support could avoid the unintentional PD insertion of the instructions for stone extraction, which might reduce the PEP rate; however, excessive squeezing from the support would induce PEP. Our next method to improve the support is finding the optimal balance between a sufficient support force and a reasonable PEP rate.

Another important advantage of CETPS over traditional ERCP is how the treatment operation is under direct vision. First, radiation injury for patients and surgeons could be minimized, and special patients, including pregnant women and children, could benefit from this technique. Second, the basket and balloon, designed for cholangioscopy, could be opened in the most appropriate position and trap/hold the stones in a timely manner under direct vision. Moreover, operators could find related adverse events, including CBD perforation, bleeding and injury, in a timely manner.

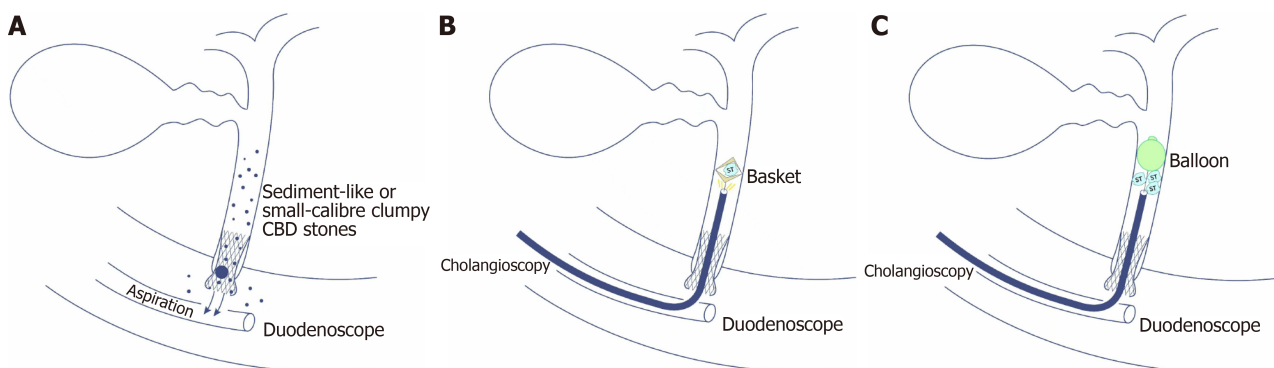
As mentioned above, CETPS combined the advantages of the SEMS technique with the SO function preservation and the cholangioscopy-assisted treatment operation under direct vision. Moreover, the application of novel papillary support established a smooth passageway for the ingress and egress of the cholangioscope and thus facilitated the operation of cholangioscopy-assisted extraction.

The major limitation of our study was the relatively small sample size. However, this paper introduced a novel papillary support that avoids EST during ERCP. Moreover, cholangioscopy-assisted stone extraction using a balloon under direct vision (Table 1, case 3) has not yet been reported.



DOI: 10.3748/wjg.v29.i16.2495 Copyright ©The Author(s) 2023.

Figure 1 The procedures of cholangioscopy-assisted extraction through novel papillary support for small-calibre and sediment-like common bile duct stones. A: The novel papillary support was placed in the lower common bile duct (CBD) and papilla; B: Many sediment-like CBD stones flowed from the support under endoscopic aspiration; C: The cholangioscope (Micro-Tech, eyeMax) was inserted into the CBD; D: The single clumpy CBD stone was collected by the basket under cholangioscopy; E: The stone, collected by the basket, was extracted from the CBD and body along with the cholangioscope; F: Multiple clumpy CBD stones were held by the balloon under cholangioscopy; G: One stone, held by the balloon, was extracted from the CBD along with the cholangioscope; H: The novel single dumbbell-style papillary support was removed from the body; I: Papillary morphology immediately after the removal of papillary support.



DOI: 10.3748/wjg.v29.i16.2495 Copyright ©The Author(s) 2023.

Figure 2 The sketch map of cholangioscopy-assisted extraction through novel papillary support for small-calibre and sediment-like common bile duct stones. A: The sketch map of cholangioscopy-assisted aspiration extraction through the support for small-calibre or sediment-like common bile duct (CBD) stones; B: The sketch map of cholangioscopy-assisted basket extraction through the support for small-calibre CBD stones; C: The sketch map of cholangioscopy-assisted balloon extraction through the support for multiple small-calibre CBD stones.

CONCLUSION

In conclusion, CETPS seemed to be a new, feasible and safe treatment strategy for small-calibre (cross diameter ≤ 1.0 cm) or sediment-like CBD stones. Patients, especially pregnant women and those who cannot stop taking anti-coagulation/anti-platelet agents, could benefit from this technique because of the visualized operation and absence of EST. However, further prospective studies with larger populations and longer follow-up periods are warranted.

FOOTNOTES

Author contributions: Zhang WG analyzed the data and wrote the manuscript; Zhang WG and Chai NL contributed equally for this study, and considered as co-first author; Linghu EQ and Chai NL performed the procedures; Zhang B, Li X, Wang JF, Dong H, and Feng YJ revised the manuscript.

Supported by National Key Research and Development Program of China, No. 2022YFC2503600.

Institutional review board statement: The study was carried out under the ethics committee approval from the Chinese PLA General Hospital (Beijing China).

Informed consent statement: Informed consent was obtained from all participating patients.

Conflict-of-interest statement: We declare that we have no financial and personal relationships with other people or organizations that can inappropriately influence our work.

Data sharing statement: No additional data are available.

Open-Access: This article is an open-access article that was selected by an in-house editor and fully peer-reviewed by external reviewers. It is distributed in accordance with the Creative Commons Attribution NonCommercial (CC BY-NC 4.0) license, which permits others to distribute, remix, adapt, build upon this work non-commercially, and license their derivative works on different terms, provided the original work is properly cited and the use is non-commercial. See: <https://creativecommons.org/licenses/by-nc/4.0/>

Country/Territory of origin: China

ORCID number: Wen-Gang Zhang 0000-0002-3314-0283; Ning-Li Chai 0000-0002-6791-5817; Bo Zhang 0000-0002-4333-0750; Xiao Li 0000-0003-0254-6675; Jia-Feng Wang 0000-0002-7413-770X; Hao Dong 0000-0001-8148-0410; Yu-Jie Feng 0000-0001-9892-9616; En-Qiang Linghu 0000-0003-4506-7877.

Corresponding Author's Membership in Professional Societies: Chinese Society of Digestive Endoscopy, President.

S-Editor: Ma YJ

L-Editor: A

P-Editor: Zhao S

REFERENCES

- 1 Cotton PB. Fifty years of ERCP: a personal review. *Gastrointest Endosc* 2018; **88**: 393-396 [PMID: 29654739 DOI: 10.1016/j.gie.2018.04.013]
- 2 Arvanitakis M, Devière J. Endoscopic retrograde cholangiopancreatography (ERCP). *Endoscopy* 2009; **41**: 890-894 [PMID: 19750450 DOI: 10.1055/s-0029-1215088]
- 3 Freeman ML, Nelson DB, Sherman S, Haber GB, Herman ME, Dorsher PJ, Moore JP, Fennerty MB, Ryan ME, Shaw MJ, Lande JD, Pheley AM. Complications of endoscopic biliary sphincterotomy. *N Engl J Med* 1996; **335**: 909-918 [PMID: 8782497 DOI: 10.1056/NEJM199609263351301]
- 4 Frimberger E. Long-term sequelae of endoscopic papillotomy. *Endoscopy* 1998; **30**: A221-A227 [PMID: 9932785 DOI: 10.1055/s-2007-1001444]
- 5 Hawes RH, Cotton PB, Vallon AG. Follow-up 6 to 11 years after duodenoscopic sphincterotomy for stones in patients with prior cholecystectomy. *Gastroenterology* 1990; **98**: 1008-1012 [PMID: 2311858 DOI: 10.1016/0016-5085(90)90026-w]
- 6 Han S, Shah RJ. Cholangioscopy-guided basket retrieval of impacted stones. *VideoGIE* 2020; **5**: 387-388 [PMID: 32954095 DOI: 10.1016/j.vgie.2020.04.009]
- 7 Fejle MP, Thaker AM, Kim S, Muthusamy VR, Sedarat A. Cholangioscopy-guided retrieval basket and snare for the removal of biliary stones and retained prostheses. *VideoGIE* 2019; **4**: 232-234 [PMID: 31061947 DOI: 10.1016/j.vgie.2019.03.001]
- 8 Jun CH, Park CH, Jeon J, Park IH, Lee HJ, Park SY, Kim HS, Choi SK, Rew JS. Feasibility of self-expandable metal stents for preservation of sphincter of Oddi function in patients with common bile duct stones: a pilot study. *Gastrointest*

- Endosc* 2015; **82**: 719-723 [PMID: 25887719 DOI: 10.1016/j.gie.2015.01.034]
- 9 **Cho E**, Park CH, Jun CH, Kim HS, Choi SK, Rew JS. Self-expandable metal stents for the extraction of common bile duct stones in patients receiving dual antiplatelet agents: a pilot study. *Surg Endosc* 2018; **32**: 1077-1081 [PMID: 28733742 DOI: 10.1007/s00464-017-5743-2]
 - 10 **Cotton PB**, Lehman G, Vennes J, Geenen JE, Russell RC, Meyers WC, Liguory C, Nickl N. Endoscopic sphincterotomy complications and their management: an attempt at consensus. *Gastrointest Endosc* 1991; **37**: 383-393 [PMID: 2070995 DOI: 10.1016/s0016-5107(91)70740-2]
 - 11 **Geenen JE**, Toouli J, Hogan WJ, Dodds WJ, Stewart ET, Mavrelis P, Riedel D, Venu R. Endoscopic sphincterotomy: follow-up evaluation of effects on the sphincter of Oddi. *Gastroenterology* 1984; **87**: 754-758 [PMID: 6468866]
 - 12 **Pereira-Lima JC**, Jakobs R, Winter UH, Benz C, Martin WR, Adamek HE, Riemann JF. Long-term results (7 to 10 years) of endoscopic papillotomy for choledocholithiasis. Multivariate analysis of prognostic factors for the recurrence of biliary symptoms. *Gastrointest Endosc* 1998; **48**: 457-464 [PMID: 9831832 DOI: 10.1016/s0016-5107(98)70085-9]
 - 13 **Escourrou J**, Cordova JA, Lazorthes F, Frexinos J, Ribet A. Early and late complications after endoscopic sphincterotomy for biliary lithiasis with and without the gall bladder 'in situ'. *Gut* 1984; **25**: 598-602 [PMID: 6735245 DOI: 10.1136/gut.25.6.598]



Published by **Baishideng Publishing Group Inc**
7041 Koll Center Parkway, Suite 160, Pleasanton, CA 94566, USA

Telephone: +1-925-3991568

E-mail: bpgoffice@wjgnet.com

Help Desk: <https://www.f6publishing.com/helpdesk>

<https://www.wjgnet.com>

