

World Journal of *Gastroenterology*

World J Gastroenterol 2023 June 14; 29(22): 3385-3573



REVIEW

- 3385 Overview of current detection methods and microRNA potential in *Clostridioides difficile* infection screening
Bocchetti M, Ferraro MG, Melisi F, Grisolia P, Scrima M, Cossu AM, Yau TO
- 3400 Epidemiology of small intestinal bacterial overgrowth
Efremova I, Maslennikov R, Poluektova E, Vasilieva E, Zharikov Y, Suslov A, Letyagina Y, Kozlov E, Levshina A, Ivashkin V

ORIGINAL ARTICLE

Basic Study

- 3422 Mechanism of annexin A1/N-formylpeptide receptor regulation of macrophage function to inhibit hepatic stellate cell activation through Wnt/ β -catenin pathway
Fan JH, Luo N, Liu GF, Xu XF, Li SQ, Lv XP
- 3440 Study of the roles of caspase-3 and nuclear factor kappa B in myenteric neurons in a P2X7 receptor knockout mouse model of ulcerative colitis
Magalhães HIR, Machado FA, Souza RF, Caetano MAF, Figliuolo VR, Coutinho-Silva R, Castelucci P
- 3469 Comparative analysis of the gut microbiota of wild adult rats from nine district areas in Hainan, China
Niu LN, Zhang GN, Xuan DD, Lin C, Lu Z, Cao PP, Chen SW, Zhang Y, Cui XJ, Hu SK

Case Control Study

- 3482 Plasma exosomal hsa_circ_0079439 as a novel biomarker for early detection of gastric cancer
Li X, Lin YL, Shao JK, Wu XJ, Li X, Yao H, Shi FL, Li LS, Zhang WG, Chang ZY, Chai NL, Wang YL, Linghu EQ

Retrospective Cohort Study

- 3497 Per-oral endoscopic myotomy is safe and effective for pediatric patients with achalasia: A long-term follow-up study
Bi YW, Lei X, Ru N, Li LS, Wang NJ, Zhang B, Yao Y, Linghu EQ, Chai NL

Retrospective Study

- 3508 Efficacy and safety of modified tetracycline dosing in a quadruple therapy for *Helicobacter pylori*: A retrospective single center study
Sun YC, Zhu MJ, Chen XQ, Yue L, Zhao YR, Wang XJ, Kim JJ, Du Q, Hu WL

Observational Study

- 3519 Pre-transjugular-intrahepatic-portosystemic-shunt measurement of hepatic venous pressure gradient and its clinical application: A comparison study
Wang XX, Yin XC, Gu LH, Guo HW, Cheng Y, Liu Y, Xiao JQ, Wang Y, Zhang W, Zou XP, Wang L, Zhang M, Zhu-Ge YZ, Zhang F

- 3534** Difference and clinical value of metabolites in plasma and feces of patients with alcohol-related liver cirrhosis

Xu YF, Hao YX, Ma L, Zhang MH, Niu XX, Li Y, Zhang YY, Liu TT, Han M, Yuan XX, Wan G, Xing HC

Prospective Study

- 3548** Prospective study comparing hepatic steatosis assessment by magnetic resonance imaging and four ultrasound methods in 105 successive patients

Collin R, Magnin B, Gaillard C, Nicolas C, Abergel A, Buchard B

SCIENTOMETRICS

- 3561** Research trends on artificial intelligence and endoscopy in digestive diseases: A bibliometric analysis from 1990 to 2022

Du RC, Ouyang YB, Hu Y

ABOUT COVER

Editorial Board Member of *World Journal of Gastroenterology*, Wolfgang Kreisel, MD, Emeritus Professor, Department of Medicine II, Gastroenterology, Hepatology, Endocrinology, and Infectious Diseases, Faculty of Medicine, Medical Center-University of Freiburg, Hugstetter Str. 55, Freiburg 79106, Germany. Wolfgang.Kreisel@uniklinik-freiburg.de

AIMS AND SCOPE

The primary aim of *World Journal of Gastroenterology* (WJG, *World J Gastroenterol*) is to provide scholars and readers from various fields of gastroenterology and hepatology with a platform to publish high-quality basic and clinical research articles and communicate their research findings online. WJG mainly publishes articles reporting research results and findings obtained in the field of gastroenterology and hepatology and covering a wide range of topics including gastroenterology, hepatology, gastrointestinal endoscopy, gastrointestinal surgery, gastrointestinal oncology, and pediatric gastroenterology.

INDEXING/ABSTRACTING

The WJG is now abstracted and indexed in Science Citation Index Expanded (SCIE, also known as SciSearch®), Current Contents/Clinical Medicine, Journal Citation Reports, Index Medicus, MEDLINE, PubMed, PubMed Central, Scopus, Reference Citation Analysis, China National Knowledge Infrastructure, China Science and Technology Journal Database, and Superstar Journals Database. The 2022 edition of Journal Citation Reports® cites the 2021 impact factor (IF) for WJG as 5.374; IF without journal self cites: 5.187; 5-year IF: 5.715; Journal Citation Indicator: 0.84; Ranking: 31 among 93 journals in gastroenterology and hepatology; and Quartile category: Q2. The WJG's CiteScore for 2021 is 8.1 and Scopus CiteScore rank 2021: Gastroenterology is 18/149.

RESPONSIBLE EDITORS FOR THIS ISSUE

Production Editor: Hua-Ge Yin; Production Department Director: Xu Guo; Editorial Office Director: Jia-Ru Fan.

NAME OF JOURNAL

World Journal of Gastroenterology

ISSN

ISSN 1007-9327 (print) ISSN 2219-2840 (online)

LAUNCH DATE

October 1, 1995

FREQUENCY

Weekly

EDITORS-IN-CHIEF

Andrzej S Tarnawski

EDITORIAL BOARD MEMBERS

<http://www.wjgnet.com/1007-9327/editorialboard.htm>

PUBLICATION DATE

June 14, 2023

COPYRIGHT

© 2023 Baishideng Publishing Group Inc

INSTRUCTIONS TO AUTHORS

<https://www.wjgnet.com/bpg/gerinfo/204>

GUIDELINES FOR ETHICS DOCUMENTS

<https://www.wjgnet.com/bpg/GerInfo/287>

GUIDELINES FOR NON-NATIVE SPEAKERS OF ENGLISH

<https://www.wjgnet.com/bpg/gerinfo/240>

PUBLICATION ETHICS

<https://www.wjgnet.com/bpg/GerInfo/288>

PUBLICATION MISCONDUCT

<https://www.wjgnet.com/bpg/gerinfo/208>

ARTICLE PROCESSING CHARGE

<https://www.wjgnet.com/bpg/gerinfo/242>

STEPS FOR SUBMITTING MANUSCRIPTS

<https://www.wjgnet.com/bpg/GerInfo/239>

ONLINE SUBMISSION

<https://www.f6publishing.com>



Retrospective Cohort Study

Per-oral endoscopic myotomy is safe and effective for pediatric patients with achalasia: A long-term follow-up study

Ya-Wei Bi, Xiao Lei, Nan Ru, Long-Song Li, Nan-Jun Wang, Bo Zhang, Yi Yao, En-Qiang Linghu, Ning-Li Chai

Specialty type: Gastroenterology and hepatology

Provenance and peer review:

Unsolicited article; Externally peer reviewed.

Peer-review model: Single blind

Peer-review report's scientific quality classification

Grade A (Excellent): 0

Grade B (Very good): B, B

Grade C (Good): 0

Grade D (Fair): 0

Grade E (Poor): 0

P-Reviewer: Lee HS, South Korea; Topi S, Italy

Received: May 8, 2023

Peer-review started: May 8, 2023

First decision: May 11, 2023

Revised: May 12, 2023

Accepted: May 19, 2023

Article in press: May 19, 2023

Published online: June 14, 2023



Ya-Wei Bi, Nan Ru, Long-Song Li, Nan-Jun Wang, Bo Zhang, Yi Yao, En-Qiang Linghu, Ning-Li Chai, Department of Gastroenterology, The First Medical Center of Chinese PLA General Hospital, Beijing 100853, China

Xiao Lei, Senior Department of Oncology, The Fifth Medical Center of PLA General Hospital, Beijing 100859, China

Corresponding author: Ning-Li Chai, MD, Chief Physician, Professor, Department of Gastroenterology, The First Medical Center of Chinese PLA General Hospital, No. 28 Fuxing Road, Haidian District, Beijing 100853, China. chainingli@vip.163.com

Abstract

BACKGROUND

Per-oral endoscopic myotomy (POEM) is emerging as a prefer treatment option for pediatric achalasia. However, data are limited on the long-term efficacy of POEM in children and adolescents with achalasia.

AIM

To evaluate the safety and long-term efficacy of POEM for pediatric patients with achalasia and compare those outcomes with adult patients.

METHODS

This retrospective cohort study was conducted in patients with achalasia who underwent POEM. Patients aged under 18 years were included in the pediatric group; patients aged between 18 to 65 years who underwent POEM in the same period were assigned to the control group. For investigation of long-term follow-up, the pediatric group were matched with patients from the control group in a 1:1 ratio. The procedure-related parameters, adverse events, clinical success, gastroesophageal reflux disease (GERD) after POEM, and quality of life (QoL) were evaluated.

RESULTS

From January 2012 to March 2020, POEM was performed in 1025 patients aged under 65 years old (48 in the pediatric group, 1025 in the control group). No significant differences were observed in the occurrence of POEM complications between the two groups (14.6% vs 14.6%; $P = 0.99$). Among the 34 pediatric patients (70.8%) who underwent follow-up for 5.7 years (range 2.6-10.6 years), clinical success was achieved in 35 patients (35/36; 97.2%). No differences were

observed in post-POEM GERD occurrence (17.6% *vs* 35.3%; $P = 0.10$). QoL was significantly improved in both groups after POEM.

CONCLUSION

POEM is safe and effective for pediatric patients with achalasia. It can achieve significant symptoms relief and improve QoL.

Key Words: Achalasia; Pediatric; Per-oral endoscopic myotomy; Long-term outcomes

©The Author(s) 2023. Published by Baishideng Publishing Group Inc. All rights reserved.

Core Tip: Per-oral endoscopic myotomy (POEM) is widely accepted in adult patients with achalasia. However, there is limited data on the application of POEM in pediatric patients, particularly regarding the long-term outcomes. In this study, we evaluated the safety and long-term efficacy of POEM in pediatric patients and compared those results with adult patients. The results show that POEM is safe and effective for pediatric patients with achalasia.

Citation: Bi YW, Lei X, Ru N, Li LS, Wang NJ, Zhang B, Yao Y, Linghu EQ, Chai NL. Per-oral endoscopic myotomy is safe and effective for pediatric patients with achalasia: A long-term follow-up study. *World J Gastroenterol* 2023; 29(22): 3497-3507

URL: <https://www.wjgnet.com/1007-9327/full/v29/i22/3497.htm>

DOI: <https://dx.doi.org/10.3748/wjg.v29.i22.3497>

INTRODUCTION

Achalasia is a rare disorder of the esophageal smooth muscle characterized by impaired relaxation of the lower esophageal sphincter (LES) and absent or spastic contractions in the esophageal body[1]. Recent studies have estimated that the annual incidence of achalasia in pediatric population is approximately 0.02-0.31 per 100000 individuals[2-4]. Despite this modest incidence rate, the disease burden of achalasia in pediatric patients is substantial owing to the extreme disruption caused to the patients' childhood and education. Children with achalasia suffer from dysphagia, regurgitation, vomiting, chest pain, weight loss, and respiratory symptoms (nocturnal cough, aspiration), with frequent emergency department visits, hospitalizations, and malnutrition caused by decreased dietary intake of these children[5].

The traditional management of achalasia includes medication, endoscopy, and laparoscopic Heller myotomy (LHM)[6]. Per-oral endoscopic myotomy (POEM) is a minimally invasive method of myotomy first applied in clinical since 2010[7]. Since then, numerous large scales, retrospective and prospective with long-term follow-up studies have shown that POEM is safe and effective in the treatment of achalasia in adult patients[8,9]. However, studies on the safety and long-term effectiveness of POEM in the treatment of pediatric population are limited[10-13]. Owing to the low incidence of achalasia in pediatric population, the sample sizes that can be included in studies are usually small which may affect the credibility of the results. POEM has been proved to be safe and effective in adult patients, comparing the results in pediatric patients with adult patients may further validated the effectiveness of POEM in pediatric patients. Furthermore, the long-term outcome of POEM is needed to be studied as children have a long-life expectancy. Therefore, the aim of this study was to comprehensively evaluate and analyze the safety and long-term outcomes of POEM in pediatric patients and compare with those in adults.

MATERIALS AND METHODS

Study design

We performed a retrospective cohort study to evaluate the outcome of pediatric patients with achalasia who underwent POEM in comparison to the outcome of all adult patients who underwent POEM within the same period. Written informed consent was obtained from each patient, and the study was approved by the Medical Ethics Committee of The First Medical Center of Chinese PLA General Hospital. Informed consent for patients aged less than 18 years was provided by their guardian.

Patients and data collection

The inclusion criteria in this study included: (1) Achalasia diagnosed by Eckardt score ≥ 4 and further confirmed by esophagogastroduodenoscopy (EGD), barium esophagram, and/or esophageal manometry; and excluding others secondary to tumor, autoimmune diseases, *etc.*; and (2) Patients with age ≤ 65 when performing POEM. Those patients with severe cardiopulmonary disease, blood coagulation disorders, or other underlying diseases were excluded from this study.

Patients aged less than 18 years who underwent POEM in The First Medical Center of Chinese PLA General Hospital, Beijing, China from January 2012 to March 2020 were included in the pediatric group, whereas patients between the ages of 18–65 who underwent POEM in the same period were assigned to the control group. Demographic data and the disease course of the achalasia, including the manifestations, diagnosis, and prior treatments, were recorded in detail upon admission to the hospital. In addition, the Urbach scale questionnaires were completed to assess the quality of life (QoL) of achalasia patients[14].

To evaluate the long-term outcomes of POEM in pediatric patients, we matched the pediatric group with patients from the control group in a 1:1 ratio. The matching principles were based on identical gender, the same type of Chicago classification and Ling classification, a surgery date that did not differ by more than three months, and the involvement of the same operating physician.

Patients were scheduled for follow-up visits at 3 mo, 6 mo, and 1 year after POEM, then yearly. EGD was performed to assess wound healing and to determine whether or not post-POEM reflux esophagitis existed. Moreover, esophageal high-resolution manometry, an X-ray barium meal, and 24-h esophageal pH monitoring were performed if possible. Patients were also contacted *via* telephone and the post-POEM complications, Eckardt score and the Urbach questionnaires were recorded.

POEM procedure

POEM was performed after the patients fasted for 48 h and underwent EGD to ensure that no food residue remained in the esophageal lumen. The standard POEM procedure was performed as previously described and generally consisted of the following major steps: First, a submucosal injection of methylene blue saline solution (1:10000) was administered, then a mucosal incision was made approximately 6–10 cm above the gastroesophageal junction (GEJ); second, a submucosal tunnel was established, passing over the GEJ and 2–3 cm into the proximal stomach; third, a myotomy started 2 cm distal to the incision and extended 2–3 cm into the stomach; and finally, after assuring hemostasis and verifying that the endoscope could easily pass the cardia, the mucosal incision was closed with clips (Figure 1). Adequate extension of the submucosal tunnel across the GEJ was confirmed by visualizing blanched gastric mucosa and a vascular pattern. Carbon dioxide gas was used for insufflation with a CO₂ insufflator (UCR; Olympus) during procedures.

All patients were kept fasting for 3 d after the procedure. A liquid diet was started for an additional day. Antibiotics and proton pump inhibitor (PPI) were administered intravenously during the fasting period. An oral PPI was required for at least 4 wk subsequently. X-ray or chest and abdominal computed tomography was performed to evaluate gas-related adverse events.

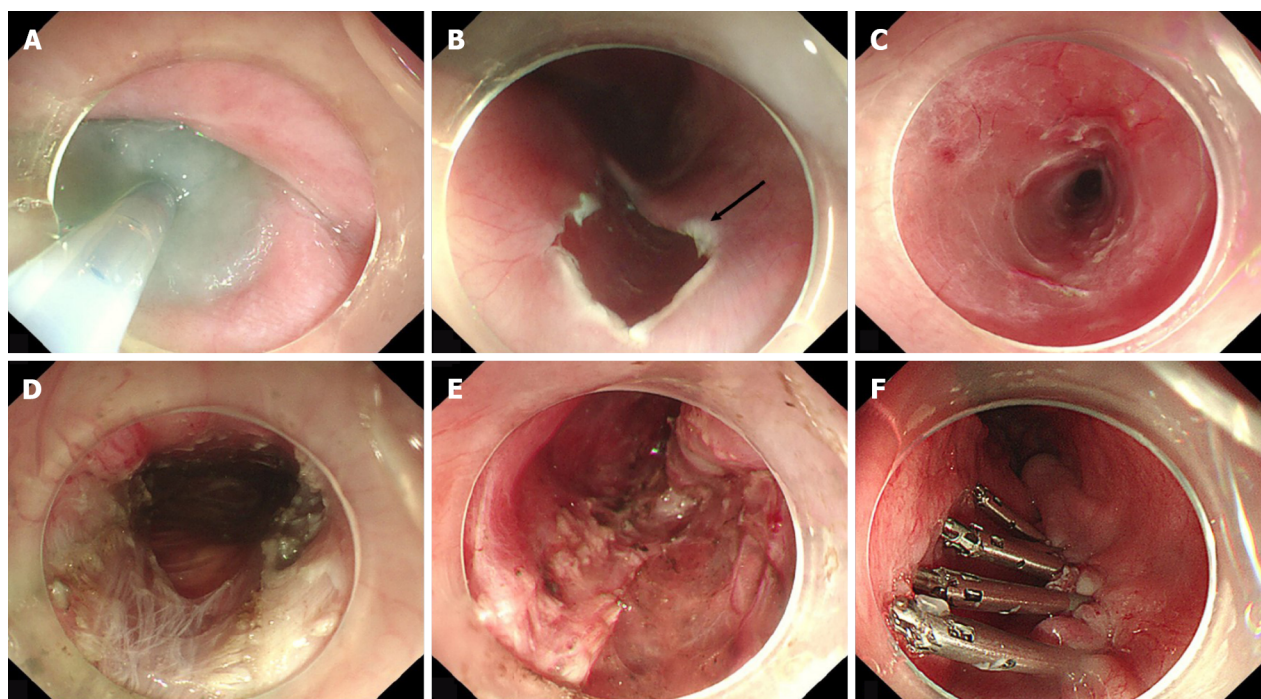
Endoscopic classifications and definitions

The Ling classification was based on the endoscopic morphology of the esophageal lumen[15]. According to multiring structures, crescent-like structures, and diverticula, the Ling classification was recorded as Ling I, Ling IIa, Ling Ib, Ling IIc, and Ling III.

Perioperative outcomes and clinical follow-up were evaluated. Perioperative outcomes included technical success, and perioperative adverse events. Technical success was defined as the successful completion of the entire POEM procedure; if the procedure was not completed, it was defined as technical failure. Perioperative adverse events include mucosa injury, gas-related adverse events (pneumothorax, pneumoperitoneum and subcutaneous emphysema), pleural effusion, and bleeding. Procedure time was defined as the time from submucosal injection to the end of incision closure with clips. Clinical success was defined as a post-POEM Eckardt score ≤ 3 . QoL was accessed by Urbach questionnaires.

Statistical analysis

Depending on the distributional properties, outcome measures were expressed as the mean \pm SD or as median values with ranges. For normally distributed continuous data, statistical significance was assessed by the Student's *t*-test; for categorical data, significance was assessed by the χ^2 test with Yates' correction when appropriate or by the Fisher's exact test; and for non-normally distributed continuous data, statistical significance was assessed by the Wilcoxon test. A *P* value of < 0.05 was established as the significance level.



DOI: 10.3748/wjg.v29.i22.3497 Copyright ©The Author(s) 2023.

Figure 1 The procedure of per-oral endoscopic myotomy. A: Submucosal injection of methylene blue saline solution; B: Mucosal incision. The black arrow points to the inverted T-shaped incision; C: The submucosal tunnel establishment; D and E: Myotomy in the submucosal tunnel; F: Mucosal incision was closed with clips.

RESULTS

From January 2012 to March 2020, POEM was performed in 1073 patients aged under 65 years old (48 in the pediatric group and 1025 in the control group).

Baseline characters

The demographic and clinical characteristics of the patients in the two groups are shown in Table 1. There was no significant difference in gender distribution between the two groups. The median age of the pediatric patients who underwent POEM in our hospital was 16 years (range 7-18 years). Compared with control group, body weight index of pediatric group was significantly lower (17.7 *vs* 20.9, $P < 0.001$). Although the median disease course was significantly shorter in the pediatric group (median 17.5 mo *vs* 48 mo, $P < 0.001$), no significant differences were observed between the two groups regarding the type of Chicago classification, type of Ling classification and residual LES pressure. Twelve pediatric patients and 183 adult patients had undergone prior treatments, including botulinum toxin injection, pneumatic balloon dilation, endoscopic stent placement, POEM and LHM. In terms of prior treatment history, there were 4 (8.3%) patients received botulinum toxin injection, 5 (10.4%) patients received pneumatic balloon dilation, 1 (2.1%) patient had POEM and 2 (4.2%) patients had more than one treatment method in pediatric group. While 46 (4.5%) patients had botulinum toxin injection, 92 (9.0%) patients had pneumatic balloon dilation, 9 (0.9%) patients had POEM, 10 (1.0%) had LHM, 14 (1.4%) patients had endoscopic stent placement, and 12 (1.2%) had more than one treatment method in control group.

Procedure-related characteristics and safety

The procedure results in the two groups are shown in Table 2. All pediatric patients successfully underwent POEM. Of the 1025 patients in control group, 1016 (99.1%) had technique success; nine patients could not complete the POEM procedure because of serious submucosal adhesions. No significant differences were observed between the pediatric and control groups regarding the length of tunnel, length of esophageal myotomy, length of gastric myotomy, types of myotomy and procedure time. The mean lengths of the tunnel were 10.8 cm (range, 7-14 cm) and 11.2 cm (range, 5-20 cm), respectively, whereas the length of the esophageal and gastric tunnels were 5.3 cm (range, 1-9 cm) and 1.9 cm (range, 0-4 cm) in pediatric group and were 5.2 cm (range, 3-15 cm) and 1.9 cm (range, 0-4 cm) in control group. A progressive full-thickness myotomy was the most common type of myotomy in both group (87.5% in pediatric group and 78.0% in control group). The types of myotomy in the remaining pediatric patients involved full thickness muscle myotomy (6.3%), circular muscle myotomy (2.1%), and other types (4.2%). In the control group, full-thickness myotomy accounted for 9.6%, circular myotomy

Table 1 General characteristics of the pediatric group and the control group

	Pediatric group (<i>n</i> = 48)	Control group (<i>n</i> = 1025)	<i>P</i> value
Sex, <i>n</i> (%)			
Male	26 (54.2)	469 (45.8)	0.253
Female	22 (45.8)	556 (54.2)	
Age, median (range), years	16 (7-18)	43 (19-65)	< 0.001
BMI, median (range), kg/m ²	17.7 (11.2-26.8)	20.9 (12.9-40.4)	< 0.001
Chicago classification, <i>n</i> (%)	<i>n</i> = 42, 87.5	<i>n</i> = 1003, 97.8	0.928
Type I	7 (16.7)	156 (15.5)	
Type II	32 (76.2)	787 (78.5)	
Type III	3 (7.1)	60 (6.0)	
Ling classification, <i>n</i> (%)			0.076
Ling I	9 (18.8)	189 (17.0)	
Ling IIa	17 (35.4)	340 (30.6)	
Ling IIb	18 (37.5)	249 (22.4)	
Ling IIc	4 (8.3)	206 (18.5)	
Ling III	0 (0.0)	41 (1.35)	
Disease course, median (range), month	17.5 (2-120)	48 (1-540)	< 0.001
LES pressure, median (range), mmHg	<i>n</i> = 42, 87.5	<i>n</i> = 1003, 97.8	0.214
	25.8 (8.4-65.9)	24.5 (1-83.2)	
Prior treatment			0.210
Patients without prior treatment, <i>n</i> (%)	36 (75.0)	842 (82.1)	
Patients with prior treatment, <i>n</i> (%)	12 (25.0)	183 (17.9)	
BTI	4 (8.3)	46 (4.5)	
PBD	5 (10.4)	92 (9.0)	
POEM	1 (2.1)	9 (0.9)	
LHM	0 (0.0)	10 (1.0)	
ESP	0 (0.0)	14 (1.4)	
PBD + BTI	1 (2.1)	3 (0.3)	
ESP + BTI	1 (2.1)	1 (0.1)	
POEM + PBD	0 (0.0)	2 (0.2)	
PBD + ESP	0 (0.0)	3 (0.3)	
PBD + LHM	0 (0.0)	1 (0.1)	
BTI + LHM	0 (0.0)	1 (0.1)	
ESP + LHM	0 (0.0)	1 (0.1)	

BTI: Botulinum toxin injection; BMI: Body mass index; PBD: Pneumatic balloon dilation; POEM: Per-oral endoscopic myotomy; LHM: Laparoscopic Heller myotomy; ESP: Endoscopic stent placement; LES: Lower esophageal sphincter.

accounted for 5.5%, and other incision types accounted for 6.9%. The mean procedure time was 43.9 min (range, 24-116 min) and 47.1 min (14-160 min) respectively.

No significant differences were observed between the pediatric and control groups regarding the overall complications of POEM (14.6 % *vs* 14.6 %; *P* = 0.997). All of the mucosa injuries were closed with titanium clips and porcine fibrin glue. Patients with pneumoperitoneum treated by puncture with a 10-mL syringe intra-operatively and patients with subcutaneous emphysema gradually absorbed the gas without special intervention. In the pediatric group, three complications of POEM occurred in seven patients (7/48; 14.6%), with three of these patients presenting with mucosa injury, two presenting with

Table 2 Procedure-related characteristics and complications of pediatric group and control group, *n* (%)

	Pediatric group	Control group	<i>P</i> value
Technique success	48 (100.0)	1016 (99.1)	> 0.999
Length of tunnel, mean (range), cm	10.8 (7-14)	11.2 (5-20)	0.206
Length of esophageal myotomy, mean (range), cm	5.3 (1-9)	5.2 (3-15)	0.529
Length of gastric myotomy, mean (range), cm	1.9 (0-4)	1.9 (0-4)	0.648
Types of myotomy			0.458
Progressive full-thickness myotomy	42 (87.5)	792 (78.0)	
Full-thickness muscle myotomy	3 (6.3)	98 (9.6)	
Circular muscle myotomy	1 (2.1)	56 (5.5)	
Others ¹	2 (4.2)	70 (6.9)	
Procedure time, mean (range), min	43.9 (24-116)	47.1 (14-160)	0.394
Complications	7 (14.6)	148 (14.6)	0.997
Mucosa injury	3 (6.2)	84 (8.3)	
Gas-related adverse event			
Pneumothorax	0 (0.0)	3 (0.3)	
Pneumoperitoneum	2 (4.2)	27 (2.7)	
Subcutaneous emphysema	2 (4.2)	32 (3.2)	
Pleural effusion	0 (0.0)	1 (0.1)	
Bleeding	0 (0.0)	1 (0.1)	

¹Other types of myotomy include circular muscle incision plus balloon plasty and glass-style anti-reflux myotomy.

pneumoperitoneum, and two presenting with subcutaneous emphysema. In control group, in addition to mucosa injury and gas-related complications, a 27-year-old male patient had delayed bleeding with hematemesis 11 d after the POEM and he underwent gastroscopic hemostasis. The patient with pleural effusion was treated with closed thoracic drainage. None of the patients with complications required surgical intervention or intensive care unit (ICU) transfer.

Efficacy

The median follow-up period was 5.7 years (range 2.6-10.6 years) for the pediatric group and 14 patients were lost for long-term follow-up. Significant differences were shown in the Eckardt score, QoL, height, weight, residual LES pressure and numbers of months absent from school of the pediatric patients before and after POEM (Table 3). The Eckardt score after median 5.7 years of follow-up was significantly declined compared with the score before POEM (8.0 *vs* 1.1, $P < 0.001$) and all symptom component of the Eckardt score decreased significantly. QoL was assessed by Urbach scale questionnaires, which is a 10-item measure of disease-specific health-related QoL that sampled the concepts of food tolerance, dysphagiarelated behavior modifications, pain, heartburn, distress, lifestyle limitation, and satisfaction. Scores on the Urbach scale questionnaires range from 10-33, and lower scores indicate better QoL. Urbach scores were significantly lower in pediatric patients at long-term follow-up after POEM treatment compared with pre-treatment scores (24.7 *vs* 12.8, $P < 0.001$). The height and weight of pediatric patients also improved significantly at follow-up (163.7 cm *vs* 170.5 cm and 49.9 kg *vs* 64.3 kg, $P < 0.001$). Moreover, the absences from school decreased significantly (median 3.3 mo *vs* 0.1 mo, $P < 0.001$).

To compare the long-term outcomes of POEM in pediatric patients and adult patients, we matched the pediatric group with patients from the control group in a 1:1 ratio. The matching principles were based on identical gender, the same type of Chicago classification and Ling classification, a surgery date that did not differ by more than three months, and the involvement of the same operating physician. The long-term outcomes of POEM in pediatric patients and matched adult patients were shown in Table 4. The median follow-up time in pediatric group and matched adult group was 5.7 years (range 2.6-10.6 years) and 6.0 years (range 2.7-10.7 years) respectively. Patients in both groups had clinical symptoms relief and QoL improvement after POEM. No significant differences were observed between the two groups regarding the Eckardt scores, Urbach scores, clinical failure and clinical reflux evaluation. Before POEM treatment and at post-operative follow-up, the body mass index (BMI) of matched control group was significantly greater than that of pediatric group (17.7 *vs* 20.0; 20.8 *vs* 24.0).

Table 3 The long-term outcomes of per-oral endoscopic myotomy in pediatric patients

	Pre-POEM	Post-POEM	P value
Eckardt score, mean (range)	8.0 (4-11)	1.1 (0-4)	< 0.001
Dysphagia, mean \pm SD	2.8 \pm 0.7	0.6 \pm 0.7	< 0.001
Regurgitation, mean \pm SD	1.7 \pm 0.8	0.1 \pm 0.2	< 0.001
Chest pain, mean \pm SD	1.0 \pm 0.9	0.4 \pm 0.6	< 0.001
Weight loss, mean \pm SD	1.5 \pm 1.2	0.0 \pm 0.0	< 0.001
Urbach score, mean (range)	12.8 (10-20)	24.7 (18-30)	< 0.001
Height, mean (range), cm	163.7 (120-184)	170.5 (159-185)	< 0.001
Weight, mean (range), kg	49.9 (22.2-82)	64.3 (47-100)	< 0.001
Number of months absent from school, mean (range), months	3.3 (0.5-24)	0.1 (0-1)	< 0.001

POEM: Per-oral endoscopic myotomy.

Table 4 The long-term outcomes of per-oral endoscopic myotomy in pediatric group and matched control group

	Pediatric group (n = 34)	Matched control group (n = 34)	P value
Follow-up time, median (range), years	5.7 (2.6-10.6)	6.0 (2.7-10.7)	0.954
Pre-POEM, Eckardt score, mean (range)	8.0 (4-11)	7.9 (4-12)	0.975
Post-POEM (3 mo), Eckardt score, mean (range)	0.3 (0-3)	0.3 (0-2)	0.978
Post-POEM, Eckardt score, mean (range)	1.1 (0-4)	1.4 (0-3)	0.088
Eckardt score ¹ (pre-post), mean (range)	6.9 (2-10)	6.4 (0-12)	0.578
Pre-POEM BMI, median (range), kg/m ²	17.7 (11.2-26.8)	20.0 (16.4-28.7)	< 0.001
Post-POEM BMI, median (range), kg/m ²	20.8 (15.8-29.5)	24.0 (19.5-29.4)	< 0.001
BMI (Post-pre) ² , median (range), kg/m ²	3.7 (-1.7-13)	3.5 (0.7-12.9)	0.502
Pre-POEM, Urbach score, mean (range)	12.8 (10-20)	12.7 (10-20)	0.842
Post-POEM, Urbach score, mean (range)	24.7 (18-30)	25.7 (17-33)	0.221
Urbach score ³ (pre-post), mean (range)	11.9 (1-18)	13.0 (4-23)	0.254
Clinical success, n (%)	33 (97.1)	34 (100.0)	> 0.999
Clinical reflux evaluation	6 (17.6)	12 (35.3)	0.099
Reflux esophagitis by gastroscopy	2 (5.9)	2 (5.9)	
Symptomatic reflux	4 (11.8)	10 (29.4)	

¹Eckardt score: The Eckardt score before per-oral endoscopic myotomy (POEM) minus the Eckardt score at last follow-up.

²Body mass index (BMI): The BMI value at the last follow-up minus the BMI value before POEM.

³Urbach score: The Urbach score before POEM minus the Urbach score at last follow-up.

POEM: Per-oral endoscopic myotomy; BMI: Body mass index.

However, the difference in BMI before and after POEM was similar in both groups (3.7 *vs* 3.5, *P* = 0.502).

All adult patients in matched group received clinical success. One pediatric patient was considered clinical failure because his Eckardt score was 4. The patient mainly has substernal pain and need to drink water to when eating dry food without weight loss and chest pain.

Gastroesophageal reflux disease (GERD) is the most common adverse event after POEM treatment [16]. Reflux esophagitis identified by EGD and assessed by the Los Angeles classification. A GerdQ score of GERD with a score of > 7 was defined as symptomatic reflux [11,13]. At median 5.7 years follow-up, 6 patients (6/34, 17.6%) were suffered from symptomatic reflux, with 2 patients (5.9%) showed reflux esophagitis (1 Los Angeles type A, 1 Los Angeles type B) on endoscopy and 4 patients (11.8%) were suffered from clinical reflux. In matched control group, 2 patients (5.9%) showed reflux esophagitis (1 Los Angeles type A, 1 Los Angeles type C) on endoscopy, 10 patients (29.4%) were suffered from clinical reflux. All patients were well controlled with medical therapy.

DISCUSSION

In this study, we included 48 pediatric patients and 1025 adult patients with achalasia and patients had a median 5.7 years followed-up. The risk of complications relating to POEM was not increased in pediatric patients, and the long-term efficacy of POEM in pediatric patients were similar to the results of adult group. Our results indicated that POEM is a safe and effective procedure for the management of pediatric achalasia.

Achalasia is a primary esophageal motility disorder with unknown etiology. While adults and children both present with progressive dysphagia initially to solids and in some cases to liquids, the manifestations can be more protean and challenging to diagnose in children. A majority of pediatric patients, especially those under 6-7 years of age, are often misdiagnosed as GERD and given acid-suppressive therapy[17]. Patients have dysphagia due to esophageal motility disorder, and some children may show reluctance to eat and be misdiagnosed as anorexia[18]. Up to 50% of children are treated with antacids or prokinetics before the diagnosis of achalasia is identified[19]. Dysphagia and regurgitation are the main symptoms of achalasia, and patients often suffer from malnutrition due to insufficient intake[20]. Upon majority of patients present normal BMI or even obese, there are almost 50% of patients to be at moderate or high risk for malnutrition at presentation[21]. Compared with adult patients, malnutrition in a pediatric patient may negatively affect long-term growth and development. Furthermore, psychology of children is immature, and the decline in QoL caused by achalasia can lead to a series of mental illnesses in pediatric patients such as low self-esteem, depression, anxiety, school stress or decreased performance[22]. Therefore, it is urgent to find an effective treatment method to relieve the symptoms of achalasia in pediatric patients. POEM is a less invasive therapy with promising treatment effect. Since the clinical application of POEM in 2010, a large number of studies have been conducted and shown that POEM is a safe and effective method for the treatment of achalasia in adult patients[7,23,24]. However, data of POEM for pediatric patients are limited. Due to the low incidence of achalasia in children and adolescents, the sample size is small in most studies which is difficult to systematically evaluate and avoid statistical bias. Therefore, comparing its outcomes with those in adults seems particularly necessary. In addition, pediatric patients have a long-life expectancy and the long-term outcomes of POEM should be investigated. To our best knowledge, this is the first study evaluated the safety and long-term efficacy of POEM in children and compared those with adults with the median follow-up time over 5 years.

In our study, we compare 48 pediatric patients with 1025 adults with a median follow-up over 5 years. The technique success achieved 100% in pediatric group and 99.1% in control group. Standard tunnel and the length of myotomy were applied during POEM procedure in both groups. According to the previous studies, pediatric patients were all received standard tunnel and myotomy length[11,13,25]. POEM-related parameters such as length of tunnel, length of myotomy, types of myotomy and operation time were similar to those of adult patients.

Our results showed that there are no significant differences between the pediatric and control groups regarding the overall complications of POEM. All pediatric patients who developed complications recovered with conservative management. While one adult patient had delayed bleeding with hematemesis need another endoscopic invention and one pleural effusion which treated with closed thoracic drainage. Liu *et al*[13] showed only five children (3.8%) experienced major adverse events, which were resolved by conservative treatment[13]. Peng *et al*[11] found two children (8.3%) developed perioperative subcutaneous emphysema during the procedure and were spontaneously absorbed without any intervention[11]. Wood *et al*[25] showed that among 21 pediatric patients who received POEM, one had mucosa injury and one had pneumoperitoneum. None of them need for reintervention[25]. Choné *et al*[26] indicated that 1 case (1%) of significant per-procedure bleeding, 7 cases (6%) had postoperative adverse events. None of them need surgery or transfer to ICU[26]. All these results indicate that POEM is a safe treatment method for pediatric patients.

In our study, all the pediatric patients with preoperative dysphagia and regurgitation reported improved or resolved symptoms at the median 5.7 years follow-up. All of them were free from the further intervention for achalasia after POEM. Compared with adult patients, POEM also achieved satisfactory long-term outcomes in pediatric patients. One pediatric patient was considered clinical failure at last time follow-up as his Eckardt score was 4. The patient began to experience intermittent dysphagia symptoms again in the second year after POEM and at last time follow-up the patient mainly has substernal pain and need to drink water to when eating dry food every day. In this patient, a submucosal tunnel of standard length was established, but the end of the tunnel was located at the EGJ, and only esophagomyotomy was performed. Studies had showed that in order to ensure the curative effect of POEM, the length of myotomy is routinely 8-10 cm, at least 2 cm below the EGJ[27]. Therefore, symptom recurrence of the patient may be related to insufficient myotomy and we suggested him could receive a re-POEM.

Several factors could limit the extent to which the results can be generalized in our study. First, we did not analysis the risk factors for complications of POEM in pediatric patients due to the small sample size. Second, the mean age was slightly older in pediatric group (median age was 16). This shortage is due to younger children tend to receive treatment in children's hospitals in China. Third, the study was retrospective and a single-center analysis.

CONCLUSION

In summary, POEM is safe treatment method and could achieve satisfactory long-term outcomes in pediatric patients. Furthermore, prospective, multicenter, and large sample studies are warranted to validate our conclusions.

ARTICLE HIGHLIGHTS

Research background

Achalasia is a rare disorder of the esophageal smooth muscle which cause dysphagia, regurgitation, chest pain and weight loss. In recent years, per-oral endoscopic myotomy (POEM) is emerging as a prefer treatment option for patients achalasia.

Research motivation

Although POEM was proved to be safe and efficacy for adult patients with achalasia, data of POEM in pediatric patients are limited.

Research objectives

To evaluate the safety and long-term efficacy of POEM for pediatric patients with achalasia.

Research methods

We performed a retrospective cohort study to evaluate the outcome of pediatric patients with achalasia who underwent POEM in comparison to the outcome of all adult patients who underwent POEM within the same period. To evaluate the safety of POEM, we compare the operation-related parameters and complications in the two groups. To evaluate the long-term efficacy of POEM, we compare the body mass index, clinical symptoms, quality of life in pediatric group before and after POEM; and we also compare those outcomes in pediatric group and matched adult group.

Research results

The risk of complications relating to POEM was not increased in pediatric patients, and the long-term efficacy of POEM in pediatric patients were similar to the results of adult group.

Research conclusions

POEM is safe treatment method and could achieve satisfactory long-term outcomes in pediatric patients.

Research perspectives

POEM can be an an effective treatment option for achalasia in pediatric patients.

FOOTNOTES

Author contributions: Bi YW, Lei X and Ru N contributed equally to this article; Bi YW, Lei X, Linghu EQ and Chai NL contributed to this paper with conception and design of the study; Bi YW, Lei X, Ru N, Li LS, Wang NJ, Zhang B and Yao Y did the data collection, literature review and analysis; Bi YW, Lei X and Ru N wrote the paper; all authors made the critical revision and editing of the article for important intellectual content, and approved the final version.

Supported by National Natural Science Foundation of China, No. 82070682.

Institutional review board statement: The study was reviewed and approved by the First Medical Center of Chinese PLA General Hospital Institutional Review Board, No. 20230301.

Informed consent statement: All study participants or their legal guardian provided informed written consent about personal and medical data collection prior to study enrolment.

Conflict-of-interest statement: All the authors report no relevant conflicts of interest for this article.

Data sharing statement: No additional data are available.

STROBE statement: The authors have read the STROBE Statement—checklist of items, and the manuscript was prepared and revised according to the STROBE Statement—checklist of items.

Open-Access: This article is an open-access article that was selected by an in-house editor and fully peer-reviewed by external reviewers. It is distributed in accordance with the Creative Commons Attribution NonCommercial (CC BY-

NC 4.0) license, which permits others to distribute, remix, adapt, build upon this work non-commercially, and license their derivative works on different terms, provided the original work is properly cited and the use is non-commercial. See: <https://creativecommons.org/licenses/by-nc/4.0/>

Country/Territory of origin: China

ORCID number: Ya-Wei Bi 0000-0003-3762-5920; Xiao Lei 0000-0002-0428-1749; Nan Ru 0009-0008-6212-6385; Long-Song Li 0000-0002-4000-7501; Nan-Jun Wang 0000-0002-6061-4798; Bo Zhang 0000-0002-4333-0750; Yi Yao 0000-0001-6976-3418; En-Qiang Linghu 0000-0003-4506-7877; Ning-Li Chai 0000-0002-6791-5817.

S-Editor: Fan JR

L-Editor: A

P-Editor: Fan JR

REFERENCES

- 1 **Savarino E**, Bhatia S, Roman S, Sifrim D, Tack J, Thompson SK, Gyawali CP. Achalasia. *Nat Rev Dis Primers* 2022; **8**: 28 [PMID: 35513420 DOI: 10.1038/s41572-022-00356-8]
- 2 **Sato H**, Yokomichi H, Takahashi K, Tominaga K, Mizusawa T, Kimura N, Kawata Y, Terai S. Epidemiological analysis of achalasia in Japan using a large-scale claims database. *J Gastroenterol* 2019; **54**: 621-627 [PMID: 30607612 DOI: 10.1007/s00535-018-01544-8]
- 3 **Miller J**, Khlevner J, Rodriguez L. Upper Gastrointestinal Functional and Motility Disorders in Children. *Pediatr Clin North Am* 2021; **68**: 1237-1253 [PMID: 34736587 DOI: 10.1016/j.pcl.2021.07.009]
- 4 **Smits M**, van Lennep M, Vrijlandt R, Benninga M, Oors J, Houwen R, Kokke F, van der Zee D, Escher J, van den Neucker A, de Meij T, Bodewes F, Schweizer J, Damen G, Busch O, van Wijk M. Pediatric Achalasia in the Netherlands: Incidence, Clinical Course, and Quality of Life. *J Pediatr* 2016; **169**: 110-5.e3 [PMID: 26616251 DOI: 10.1016/j.jpeds.2015.10.057]
- 5 **Meyer A**, Catto-Smith A, Crameri J, Simpson D, Alex G, Hardikar W, Cameron D, Oliver M. Achalasia: Outcome in children. *J Gastroenterol Hepatol* 2017; **32**: 395-400 [PMID: 27411173 DOI: 10.1111/jgh.13484]
- 6 **Vaezi MF**, Pandolfino JE, Yadlapati RH, Greer KB, Kavitt RT. ACG Clinical Guidelines: Diagnosis and Management of Achalasia. *Am J Gastroenterol* 2020; **115**: 1393-1411 [PMID: 32773454 DOI: 10.14309/ajg.0000000000000731]
- 7 **Werner YB**, Hakanson B, Martinek J, Repici A, von Rahden BHA, Bredenoord AJ, Bisschops R, Messmann H, Vollberg MC, Noder T, Kersten JF, Mann O, Izbicki J, Pazdro A, Fumagalli U, Rosati R, Germer CT, Schijven MP, Emmermann A, von Renteln D, Fockens P, Boeckxstaens G, Rösch T. Endoscopic or Surgical Myotomy in Patients with Idiopathic Achalasia. *N Engl J Med* 2019; **381**: 2219-2229 [PMID: 31800987 DOI: 10.1056/NEJMoa1905380]
- 8 **de Moura ETH**, Jukemura J, Ribeiro IB, Farias GFA, de Almeida Delgado AA, Coutinho LMA, de Moura DTH, Aissar Sallum RA, Nasi A, Sánchez-Luna SA, Sakai P, de Moura EGH. Peroral endoscopic myotomy vs laparoscopic myotomy and partial fundoplication for esophageal achalasia: A single-center randomized controlled trial. *World J Gastroenterol* 2022; **28**: 4875-4889 [PMID: 36156932 DOI: 10.3748/wjg.v28.i33.4875]
- 9 **Shiwaku H**, Inoue H, Sato H, Onimaru M, Minami H, Tanaka S, Sato C, Ogawa R, Okushima N, Yokomichi H. Peroral endoscopic myotomy for achalasia: a prospective multicenter study in Japan. *Gastrointest Endosc* 2020; **91**: 1037-1044.e2 [PMID: 31759035 DOI: 10.1016/j.gie.2019.11.020]
- 10 **Nabi Z**, Ramchandani M, Basha J, Goud R, Darisetty S, Reddy DN. POEM Is a Durable Treatment in Children and Adolescents With Achalasia Cardia. *Front Pediatr* 2022; **10**: 812201 [PMID: 35281245 DOI: 10.3389/fped.2022.812201]
- 11 **Peng D**, Tan Y, Li C, Lv L, Zhu H, Liang C, Li R, Liu D. Peroral Endoscopic Myotomy for Pediatric Achalasia: A Retrospective Analysis of 21 Cases With a Minimum Follow-Up of 5 Years. *Front Pediatr* 2022; **10**: 845103 [PMID: 35444970 DOI: 10.3389/fped.2022.845103]
- 12 **Miao S**, Wu J, Lu J, Wang Y, Tang Z, Zhou Y, Huang Z, Ying H, Zhou P. Peroral Endoscopic Myotomy in Children With Achalasia: A Relatively Long-term Single-center Study. *J Pediatr Gastroenterol Nutr* 2018; **66**: 257-262 [PMID: 28691974 DOI: 10.1097/MPG.0000000000001675]
- 13 **Liu Z**, Wang Y, Fang Y, Huang Y, Yang H, Ren X, Xu M, Chen S, Chen W, Zhong Y, Zhang Y, Qin W, Hu J, Cai M, Yao L, Li Q, Zhou P. Short-term safety and efficacy of peroral endoscopic myotomy for the treatment of achalasia in children. *J Gastroenterol* 2020; **55**: 159-168 [PMID: 31679066 DOI: 10.1007/s00535-019-01607-4]
- 14 **Urbach DR**, Tomlinson GA, Harnish JL, Martino R, Diamant NE. A measure of disease-specific health-related quality of life for achalasia. *Am J Gastroenterol* 2005; **100**: 1668-1676 [PMID: 16144120 DOI: 10.1111/j.1572-0241.2005.50141.x]
- 15 **Li HK**, Linghu EQ. New endoscopic classification of achalasia for selection of candidates for peroral endoscopic myotomy. *World J Gastroenterol* 2013; **19**: 556-560 [PMID: 23382636 DOI: 10.3748/wjg.v19.i4.556]
- 16 **Familiari P**, Greco S, Gigante G, Cali A, Boškoski I, Onder G, Perri V, Costamagna G. Gastroesophageal reflux disease after peroral endoscopic myotomy: Analysis of clinical, procedural and functional factors, associated with gastroesophageal reflux disease and esophagitis. *Dig Endosc* 2016; **28**: 33-41 [PMID: 26173511 DOI: 10.1111/den.12511]
- 17 **Hallal C**, Kieling CO, Nunes DL, Ferreira CT, Peterson G, Barros SG, Arruda CA, Fraga JC, Goldani HA. Diagnosis, misdiagnosis, and associated diseases of achalasia in children and adolescents: a twelve-year single center experience. *Pediatr Surg Int* 2012; **28**: 1211-1217 [PMID: 23135808 DOI: 10.1007/s00383-012-3214-3]
- 18 **Franklin AL**, Petrosyan M, Kane TD. Childhood achalasia: A comprehensive review of disease, diagnosis and therapeutic management. *World J Gastrointest Endosc* 2014; **6**: 105-111 [PMID: 24748917 DOI: 10.4253/wjge.v6.i4.105]
- 19 **Lee CW**, Kays DW, Chen MK, Islam S. Outcomes of treatment of childhood achalasia. *J Pediatr Surg* 2010; **45**: 1173-

- 1177 [PMID: 20620315 DOI: 10.1016/j.jpedsurg.2010.02.086]
- 20 **Mari A**, Sweis R. Assessment and management of dysphagia and achalasia. *Clin Med (Lond)* 2021; **21**: 119-123 [PMID: 33762370 DOI: 10.7861/clinmed.2021-0069]
 - 21 **Newberry C**, Vajravelu RK, Pickett-Blakely O, Falk G, Yang YX, Lynch KL. Achalasia Patients Are at Nutritional Risk Regardless of Presenting Weight Category. *Dig Dis Sci* 2018; **63**: 1243-1249 [PMID: 29468378 DOI: 10.1007/s10620-018-4985-8]
 - 22 **Frankhuisen R**, van Herwaarden MA, Heijkoop R, Smout AJ, Baron A, Vermeijden JR, Gooszen HG, Samsom M. Persisting symptoms and decreased health-related quality-of-life in a cross-sectional study of treated achalasia patients. *Aliment Pharmacol Ther* 2007; **26**: 899-904 [PMID: 17767474 DOI: 10.1111/j.1365-2036.2007.03423.x]
 - 23 **Bechara R**, Ikeda H, Inoue H. Peroral endoscopic myotomy: an evolving treatment for achalasia. *Nat Rev Gastroenterol Hepatol* 2015; **12**: 410-426 [PMID: 26035678 DOI: 10.1038/nrgastro.2015.87]
 - 24 **Xu S**, Chai N, Tang X, Linghu E, Li L, Wang S, Zhang X. Outcomes of peroral endoscopic myotomy in challenging achalasia patients: a long-term follow-up study. *Surg Endosc* 2021; **35**: 3732-3743 [PMID: 32794046 DOI: 10.1007/s00464-020-07864-2]
 - 25 **Wood LS**, Chandler JM, Portelli KE, Taylor JS, Kethman WC, Wall JK. Treating children with achalasia using per-oral endoscopic myotomy (POEM): Twenty-one cases in review. *J Pediatr Surg* 2020; **55**: 1006-1012 [PMID: 32197825 DOI: 10.1016/j.jpedsurg.2020.02.028]
 - 26 **Choné A**, Familiari P, von Rahden B, Desai P, Inoue H, Shimamura Y, Eleftheriadis N, Yamashita K, Khashab MA, Shiwaqui H, Seewald S, Draganov PV, Alvarez LBM, Chaussade S, Tantau M, Abraham M, Marks J, Arevalo G, Albéniz E, Mion F, Roman S, Rivory J, Dubois R, Lachaux A, Benech N, Subtil F, Ponchon T, Barret M, Pioche M. Multicenter Evaluation of Clinical Efficacy and Safety of Per-oral Endoscopic Myotomy in Children. *J Pediatr Gastroenterol Nutr* 2019; **69**: 523-527 [PMID: 31259787 DOI: 10.1097/MPG.0000000000002432]
 - 27 **Li L**, Chai N, Linghu E, Li Z, Du C, Zhang W, Zou J, Xiong Y, Zhang X, Tang P. Safety and efficacy of using a short tunnel versus a standard tunnel for peroral endoscopic myotomy for Ling type IIc and III achalasia: a retrospective study. *Surg Endosc* 2019; **33**: 1394-1402 [PMID: 30187204 DOI: 10.1007/s00464-018-6414-7]



Published by **Baishideng Publishing Group Inc**
7041 Koll Center Parkway, Suite 160, Pleasanton, CA 94566, USA

Telephone: +1-925-3991568

E-mail: bpgoffice@wjgnet.com

Help Desk: <https://www.f6publishing.com/helpdesk>

<https://www.wjgnet.com>

