

World Journal of *Gastroenterology*

World J Gastroenterol 2023 June 21; 29(23): 3574-3747



EDITORIAL

- 3574 Recent advances in treatment of nodal and gastrointestinal follicular lymphoma
Watanabe T

MINIREVIEWS

- 3595 Prognostic role of intestinal ultrasound in Crohn's disease
Manzotti C, Colombo F, Zurleni T, Danelli P, Maconi G

ORIGINAL ARTICLE

Basic Study

- 3606 BMI-1 activates hepatic stellate cells to promote the epithelial-mesenchymal transition of colorectal cancer cells
Jiang ZY, Ma XM, Luan XH, Liuyang ZY, Hong YY, Dai Y, Dong QH, Wang GY
- 3622 18 β -glycyrrhetic acid inhibits proliferation of gastric cancer cells through regulating the miR-345-5p/TGM2 signaling pathway
Li X, Ma XL, Nan Y, Du YH, Yang Y, Lu DD, Zhang JF, Chen Y, Zhang L, Niu Y, Yuan L

Retrospective Study

- 3645 High expression of the circadian clock gene NPAS2 is associated with progression and poor prognosis of gastric cancer: A single-center study
Cao XM, Kang WD, Xia TH, Yuan SB, Guo CA, Wang WJ, Liu HB
- 3658 SGK3 overexpression correlates with a poor prognosis in endoscopically resected superficial esophageal squamous cell neoplasia: A long-term study
Xu N, Li LS, Li H, Zhang LH, Zhang N, Wang PJ, Cheng YX, Xiang JY, Linghu EQ, Chai NL
- 3668 Hot snare polypectomy *vs* endoscopic mucosal resection using bipolar snare for intermediate size colorectal lesions: Propensity score matching
Minakata N, Murano T, Wakabayashi M, Sasabe M, Watanabe T, Mitsui T, Yamashita H, Inaba A, Sunakawa H, Nakajo K, Kadota T, Shinmura K, Ikematsu H, Yano T
- 3678 Lymphocyte-to-white blood cell ratio is associated with outcome in patients with hepatitis B virus-related acute-on-chronic liver failure
Zhang Y, Chen P, Zhu X

Observational Study

- 3688 Spatial cluster mapping and environmental modeling in pediatric inflammatory bowel disease
Michaux M, Chan JM, Bergmann L, Chaves LF, Klivenberg B, Jacobson K

Prospective Study

- 3703** Novel multi-parametric diagnosis of non-alcoholic fatty liver disease using ultrasonography, body mass index, and Fib-4 index

Funada K, Kusano Y, Gytoku Y, Shirahashi R, Suda T, Tamano M

- 3715** Robotic-assisted proctosigmoidectomy for Hirschsprung's disease: A multicenter prospective study

Zhang MX, Zhang X, Chang XP, Zeng JX, Bian HQ, Cao GQ, Li S, Chi SQ, Zhou Y, Rong LY, Wan L, Tang ST

SYSTEMATIC REVIEWS

- 3733** Paradoxical association between dyspepsia and autoimmune chronic atrophic gastritis: Insights into mechanisms, pathophysiology, and treatment options

Rossi RE, Elvevi A, Sciola V, Mandarino FV, Danese S, Invernizzi P, Massironi S

ABOUT COVER

Editorial Board Member of *World Journal of Gastroenterology*, Kamran Rostami, FRACP, MD, PhD, Department of Gastroenterology, MidCentral District Health Board Palmerston Hospital, Palmerston North 4472, New Zealand. kamran.rostami@midcentraldhsb.govt.nz

AIMS AND SCOPE

The primary aim of *World Journal of Gastroenterology* (WJG, *World J Gastroenterol*) is to provide scholars and readers from various fields of gastroenterology and hepatology with a platform to publish high-quality basic and clinical research articles and communicate their research findings online. WJG mainly publishes articles reporting research results and findings obtained in the field of gastroenterology and hepatology and covering a wide range of topics including gastroenterology, hepatology, gastrointestinal endoscopy, gastrointestinal surgery, gastrointestinal oncology, and pediatric gastroenterology.

INDEXING/ABSTRACTING

The WJG is now abstracted and indexed in Science Citation Index Expanded (SCIE, also known as SciSearch®), Current Contents/Clinical Medicine, Journal Citation Reports, Index Medicus, MEDLINE, PubMed, PubMed Central, Scopus, Reference Citation Analysis, China National Knowledge Infrastructure, China Science and Technology Journal Database, and Superstar Journals Database. The 2023 edition of Journal Citation Reports® cites the 2022 impact factor (IF) for WJG as 4.3; IF without journal self cites: 4.1; 5-year IF: 5.3; Journal Citation Indicator: 0.82; Ranking: 32 among 93 journals in gastroenterology and hepatology; and Quartile category: Q2. The WJG's CiteScore for 2021 is 8.3 and Scopus CiteScore rank 2022: Gastroenterology is 22/149.

RESPONSIBLE EDITORS FOR THIS ISSUE

Production Editor: Yi-Xuan Cai; Production Department Director: Xiang Li; Editorial Office Director: Jia-Ru Fan.

NAME OF JOURNAL

World Journal of Gastroenterology

ISSN

ISSN 1007-9327 (print) ISSN 2219-2840 (online)

LAUNCH DATE

October 1, 1995

FREQUENCY

Weekly

EDITORS-IN-CHIEF

Andrzej S Tarnawski

EDITORIAL BOARD MEMBERS

<http://www.wjgnet.com/1007-9327/editorialboard.htm>

PUBLICATION DATE

June 21, 2023

COPYRIGHT

© 2023 Baishideng Publishing Group Inc

INSTRUCTIONS TO AUTHORS

<https://www.wjgnet.com/bpg/gerinfo/204>

GUIDELINES FOR ETHICS DOCUMENTS

<https://www.wjgnet.com/bpg/GerInfo/287>

GUIDELINES FOR NON-NATIVE SPEAKERS OF ENGLISH

<https://www.wjgnet.com/bpg/gerinfo/240>

PUBLICATION ETHICS

<https://www.wjgnet.com/bpg/GerInfo/288>

PUBLICATION MISCONDUCT

<https://www.wjgnet.com/bpg/gerinfo/208>

ARTICLE PROCESSING CHARGE

<https://www.wjgnet.com/bpg/gerinfo/242>

STEPS FOR SUBMITTING MANUSCRIPTS

<https://www.wjgnet.com/bpg/GerInfo/239>

ONLINE SUBMISSION

<https://www.f6publishing.com>



Prospective Study

Robotic-assisted proctosigmoidectomy for Hirschsprung's disease: A multicenter prospective study

Meng-Xin Zhang, Xi Zhang, Xiao-Pan Chang, Ji-Xiao Zeng, Hong-Qiang Bian, Guo-Qing Cao, Shuai Li, Shui-Qing Chi, Ying Zhou, Li-Ying Rong, Li Wan, Shao-Tao Tang

Specialty type: Gastroenterology and hepatology

Provenance and peer review:

Unsolicited article; Externally peer reviewed.

Peer-review model: Single blind

Peer-review report's scientific quality classification

Grade A (Excellent): 0
Grade B (Very good): B, B
Grade C (Good): 0
Grade D (Fair): 0
Grade E (Poor): 0

P-Reviewer: Grawish ME, Egypt; Trébol J, Spain

Received: March 16, 2023

Peer-review started: March 16, 2023

First decision: April 21, 2023

Revised: April 29, 2023

Accepted: May 22, 2023

Article in press: May 22, 2023

Published online: June 21, 2023



Meng-Xin Zhang, Xi Zhang, Guo-Qing Cao, Shuai Li, Shui-Qing Chi, Ying Zhou, Li-Ying Rong, Li Wan, Shao-Tao Tang, Department of Pediatric Surgery, Union Hospital, Tongji Medical College, Huazhong University of Science and Technology, Wuhan 430022, Hubei Province, China

Xiao-Pan Chang, Ji-Xiao Zeng, Department of Pediatric Surgery, Guangzhou Women and Children's Medical Center, Guangzhou Medical University, Guangzhou 510623, Guangdong Province, China

Hong-Qiang Bian, Department of General Surgery, Wuhan Children's Hospital, Tongji Medical College, Huazhong University of Science and Technology, Wuhan 430019, Hubei Province, China

Corresponding author: Shao-Tao Tang, Doctor, MD, PhD, Chief Doctor, Professor, Surgeon, Department of Pediatric Surgery, Union Hospital, Tongji Medical College, Huazhong University of Science and Technology, No. 1277 Jiefang Avenue, Wuhan 430022, Hubei Province, China. tshaotao83@hust.edu.cn

Abstract

BACKGROUND

Robotic surgery is a cutting-edge minimally invasive technique that overcomes many shortcomings of laparoscopic techniques, yet few studies have evaluated the use of robotic surgery to treat Hirschsprung's disease (HSCR).

AIM

To analyze the feasibility and medium-term outcomes of robotic-assisted proctosigmoidectomy (RAPS) with sphincter- and nerve-sparing surgery in HSCR patients.

METHODS

From July 2015 to January 2022, 156 rectosigmoid HSCR patients were enrolled in this multicenter prospective study. Their sphincters and nerves were spared by dissecting the rectum completely from the pelvic cavity outside the longitudinal muscle of the rectum and then performing transanal Soave pull-through procedures. Surgical outcomes and continence function were analyzed.

RESULTS

No conversions or intraoperative complications occurred. The median age at surgery was 9.50 months, and the length of the removed bowel was 15.50 ± 5.23 cm. The total operation time, console time, and anal traction time were 155.22 ± 16.77 , 58.01 ± 7.71 , and 45.28 ± 8.15 min. There were 25 complications within 30 d and 48 post-30-d complications. For children aged ≥ 4 years, the bowel function score (BFS) was 17.32 ± 2.63 , and 90.91% of patients showed moderate-to-good bowel function. The postoperative fecal continence (POFC) score was 10.95 ± 1.04 at 4 years of age, 11.48 ± 0.72 at 5 years of age, and 11.94 ± 0.81 at 6 years of age, showing a promising annual trend. There were no significant differences in postoperative complications, BFS, and POFC scores related to age at surgery being ≤ 3 mo or > 3 mo.

CONCLUSION

RAPS is a safe and effective alternative for treating HSCR in children of all ages; it offers the advantage of further minimizing damage to sphincters and perirectal nerves and thus providing better continence function.

Key Words: Robotic-assisted; Hirschsprung's disease; Continence function; Sphincter; Nerve

©The Author(s) 2023. Published by Baishideng Publishing Group Inc. All rights reserved.

Core Tip: We present the largest series of patients with Hirschsprung's disease treated with robotic-assisted proctosigmoidectomy (RAPS). RAPS is a safe and effective alternative for treating Hirschsprung's disease in children of all ages. It offers the advantage of further minimizing damage to sphincters and perirectal nerves and thus providing better fecal function.

Citation: Zhang MX, Zhang X, Chang XP, Zeng JX, Bian HQ, Cao GQ, Li S, Chi SQ, Zhou Y, Rong LY, Wan L, Tang ST. Robotic-assisted proctosigmoidectomy for Hirschsprung's disease: A multicenter prospective study. *World J Gastroenterol* 2023; 29(23): 3715-3732

URL: <https://www.wjgnet.com/1007-9327/full/v29/i23/3715.htm>

DOI: <https://dx.doi.org/10.3748/wjg.v29.i23.3715>

INTRODUCTION

Although beneficial for children with Hirschsprung's disease (HSCR), laparoscopic operation is more challenging than open operation, especially in newborns and infants. To address the drawbacks of laparoscopic surgery, a robotic system may be considered. Robotic-assisted surgery is utilized in various areas due to its numerous advantages, particularly in complex operations, such as anorectal malformations in children[1] and prostate and rectal cancer in adults[2,3].

Recently, laparoscopic techniques have developed into an effective treatment for HSCR. As previously shown, these minimally invasive surgical techniques result in better early postoperative outcomes than the open procedure[4,5], and the long-term results are similar between laparoscopic and open procedures[6]. Nevertheless, laparoscopic surgery for HSCR is still considered to be one of the most difficult operations in anorectal surgery. With the introduction and application of robotic surgical platforms, this technology is gradually being adopted for the treatment of HSCR. However, the safety and efficacy of the technology in treating pediatric HSCR patients have been evaluated in only a few studies.

In this paper, we present our initial experience with robotic-assisted proctosigmoidectomy (RAPS) with sphincter- and nerve-sparing surgery (SNS) for treating HSCR. To our knowledge, this represents the largest series of SNS-RAPS in children reported to date. The SNS-RAPS procedure is thoroughly detailed.

MATERIALS AND METHODS

Study design

From July 2015 to January 2022, a multicenter prospective study of consecutive children with rectosigmoid HSCR who underwent uniform SNS-RAPS was carried out at three centers (Union Hospital, Tongji Medical College, Huazhong University of Science and Technology; Guangzhou Women and Children's Medical Center, Guangzhou Medical University; Wuhan Children's Hospital, Tongji Medical College, Huazhong University of Science and Technology). A total of 156 patients were

enrolled, and all operations were performed by experienced surgical teams from three centers. Since the time the da Vinci Surgical System Si (Intuitive Surgical, Sunnyvale, CA) was introduced at the three centers to treat HSCR, all HSCR cases have been recorded in a prospectively designed database. Patient demographics, surgical parameters, and postoperative data were recorded.

This study was approved by the ethics committee at each participating center and registered in the Chinese Clinical Trial Registry (Registration ID: ChiCTR2000035220). Written informed consent was obtained from the legal guardians of each patient. The study has been reported in accordance with the Declaration of Helsinki.

Patients

Patients diagnosed with rectosigmoid HSCR preoperatively were candidates for SNS-RAPS. The diagnosis was based on clinical symptoms and signs, barium enema results, rectal aspiration biopsy, anorectal manometry, and intraoperative biopsy. Patients with trisomy 21, total colonic aganglionosis, long-segment HSCR, HSCR combined with preoperative enterostomy, and surgical contraindications were excluded. The patient selection process is detailed in [Figure 1](#). All patients received a unified preoperative preparation and postoperative treatment plan at all centers.

Colonic irrigation with warm saline (100-200 mL/kg) was used to prepare the colon for 3-7 d. Metronidazole (25 mg/kg, bid) was given orally for 3 d (1-2 d for neonates) preoperatively, and one dose of cefoperazone was provided during anesthesia induction.

Operative procedure

Under general anesthesia, the patient was placed in the supine position, and three trocars were placed. The CO₂ insufflation pressure was set at 8-10 mmHg, and the flow rate at 2.5-4.5 L/min. The operation was performed using three ports, including a straight-cut umbilical trocar accommodating a 12 mm 30° telescope and two working trocars with 8 mm robotic devices on either side ([Figure 2](#)). The robotic arms were oriented from the caudal direction. The aganglionic segment range was assessed by seromusculature biopsy using robotic monopolar scissors and interrupted 5-0 sutures were placed in cases of bleeding or mucosal rupture. The needle and suction were alternately inserted for operation through the 8 mm port on one side, which required the process of removing and reinserting the operative instrument. A Maryland dissector and a robotic hook were used to perform the dissection. After creating a window on the sigmoid mesentery, we clipped and divided the sigmoid artery trunk and then mobilized the mesentery up to the level of the inferior mesenteric artery. SNS robotic endorectal dissection was performed circumferentially down to the pelvis, which was the most unique and crucial part of the operation. Dissection was begun circumferentially at 1.0 cm above the peritoneal reflection. The rectum was mobilized outside the longitudinal muscle layer (that is, under its serosa or proper rectal fascia extended serous layer below the peritoneal reflection), with the anatomical plane farther away from Denonvillier's fascia and the nerve plexus anterior or lateral to the rectum ([Figure 3A](#)). When we pulled the rectum cranially, intestinal wall muscle layers provided greater tensile strength than the mucosa, allowing the pelvis to be shallower ([Figure 4](#)) and avoiding intraoperative intestinal mucosal tearing with peritoneal contamination. Since the robotic platform allowed for dissection in a narrow field, we were able to dissect the rectum to a lower level, nearly up to the dentate line. The mobilization of the rectum reached 4-7 cm into the pelvis ([Figure 3B](#)).

After the robot was unlocked, a circular incision was made 0.5-1 cm from the dentate line ([Figure 5A](#)), dividing the mucosa upward by 0.2-0.4 cm, breaking through the muscular cuff, and exposing the robotic dissection plane in the pelvis. The diseased colon was then gently pulled out through the anus. The posterior wall was partially resected in a V-shape, and the pointed end of the "V" reached the level of the dentate line to release internal anal sphincter achalasia. To avoid residual dysfunctional bowel, we uniformly excised the dilated and thickened bowel; we then performed Soave's anastomosis with interrupted 5-0 or 4-0 absorbable sutures above the biopsy site. After the diseased bowel was removed, the specimen was measured for its overall length and the pelvic dissection length ([Figure 5B](#)).

Postoperative management

Intravenous antibiotics (cefoperazone, 50 mg/kg, bid) were given for the first 3 d, and a urinary catheter was left for 24-48 h after surgery. No nasogastric tube or drains were left in place, but a rectal tube was left for 5 d postoperatively to help the passage of intestinal contents and gas through the anus. Instead of sutures, we used butterfly shaped tape to fixate the tube and reduce postoperative discomfort. The patient was discharged after being confirmed to be clinically stable and tolerant of a full oral diet. A routine digital rectal examination was performed postoperatively at 2 wk, and an anal dilatation plan was formulated.

Postoperative variables and definitions

The bowel function score (BFS) was used to evaluate overall bowel function[7], while the postoperative fecal continence (POFC) score focused on SNS-related incontinence[8]. Children aged ≥ 4 years were assessed twice for each score as shown in [Tables 1](#) and [2](#). A BFS ≥ 17 was represented as the lower limit of good/normal functional outcomes as more than 90% of people aged ≥ 4 years in the normal

Table 1 Scale for bowel function score

Evaluation on fecal continence	Score
Feels the urge to defecate	
Always	3
Most of the time	2
Uncertain	1
Absent	0
Ability to hold back defecation	
Always	3
Problems less than once a week	2
Weekly problems	1
No voluntary control	0
Frequency of defecation	
Every other day-twice a day	2
More often	1
Less often	1
Soiling	
Never	3
Staining less than once a week, no change of underwear required	2
Frequent staining/soiling, change of underwear required	1
Daily soiling, requires protective aids	0
Accidents	
Never	3
Less than once a week	2
Weekly accidents, often requires protective aids	1
Daily, protective aids required day and night	0
Constipation	
No constipation	3
Manageable with diet	2
Manageable with laxatives	1
Manageable with enemas	0
Social problems	
No social problems	3
Sometimes (fouls odors)	2
Problems causing restrictions in social life	1
Major social/psychosocial problems	0

population met this criterion[9]. Soiling referred to the actual presence of feces in the underwear without the patient's awareness, while fecal marks on the underwear were regarded as staining. We briefly defined the normal stool frequency as 1-3 times daily or once every 1-3 d. The diagnosis of HSCR-associated enterocolitis was based on the definitions by Teitelbaum and Coran[10]. Post-30-d complications were defined as complications occurring 30 d to 1 year after surgery.

Statistical analysis

Categorical variables are presented as counts and percentages, while continuous variables are presented as the mean \pm SD or median (range). The Kolmogorov-Smirnov test was used to assess the normality

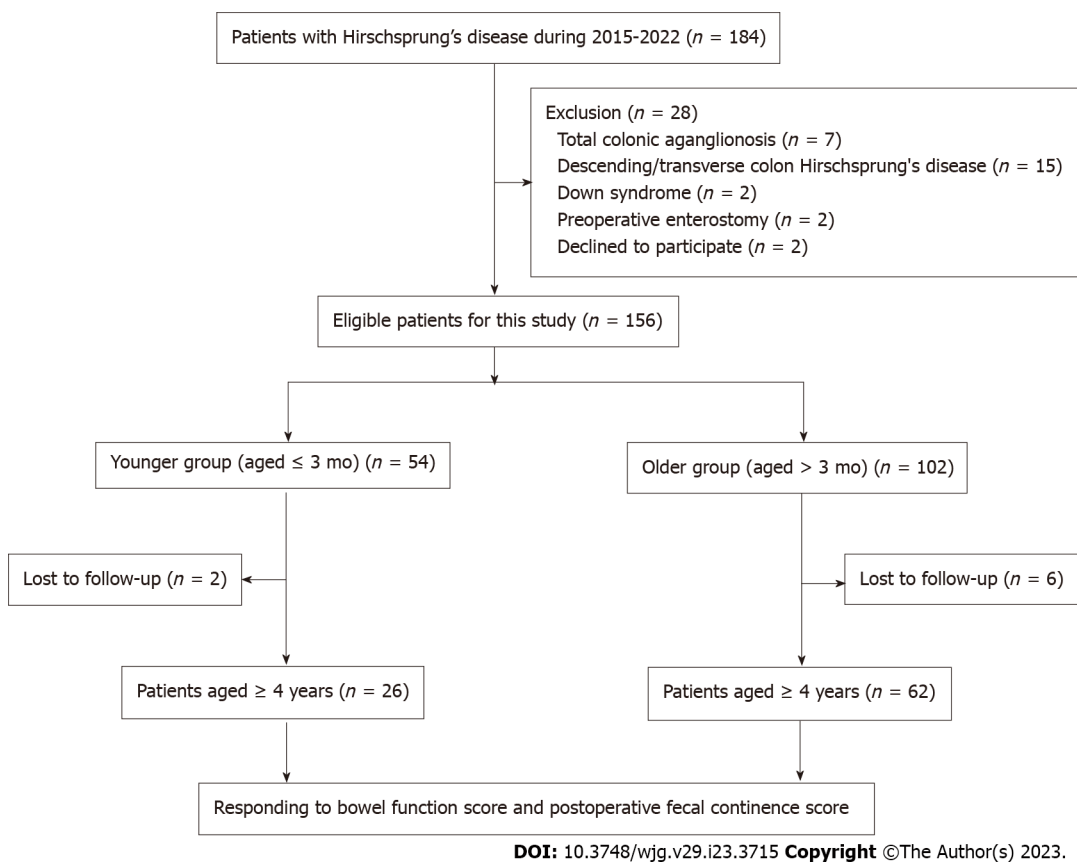
Table 2 Scale for postoperative fecal continence score

Evaluation on the POFC scores	0	1	2
Frequency of motions (/day)	≥ 6	3-5	1-2
Severity of staining/soiling	Soiling	Staining	None
Severity of perianal erosion	Often	Occasionally	Nil
Anal shape	Prolapse needing surgery	Mucosa visible	Normal
Requirement for medications	Antidiarrheals	Laxatives/enemas	Nil
Sensation of rectal fullness	Not at all ¹	Occasionally	Always ²
Ability to distinguish flatus from stool	Not at all ¹	Occasionally	Always ²

¹Full awareness or ability to distinguish less than once a week.

²Full awareness or ability to distinguish at least 4 out of 5 times (more than 80%).

POFC: postoperative fecal continence.

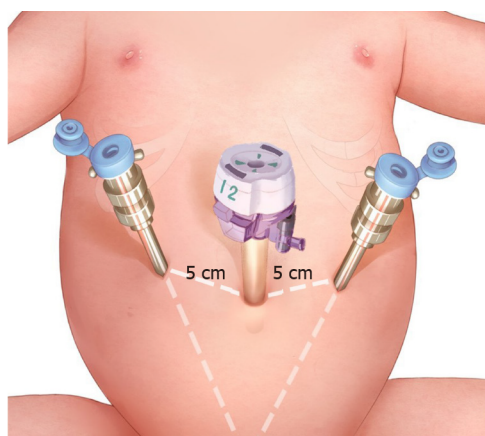
**Figure 1 Flowchart of patient selection.**

distribution of the data. To evaluate the differences between groups, the chi-square test or Fisher exact test was used to analyze categorical variables, and the Mann-Whitney U test was used to compare continuous variables because the data did not meet the normal distribution criteria. IBM SPSS Statistics version 26.0 was used for statistical analysis. A *P* value of < 0.05 was considered indicative of statistical significance.

RESULTS

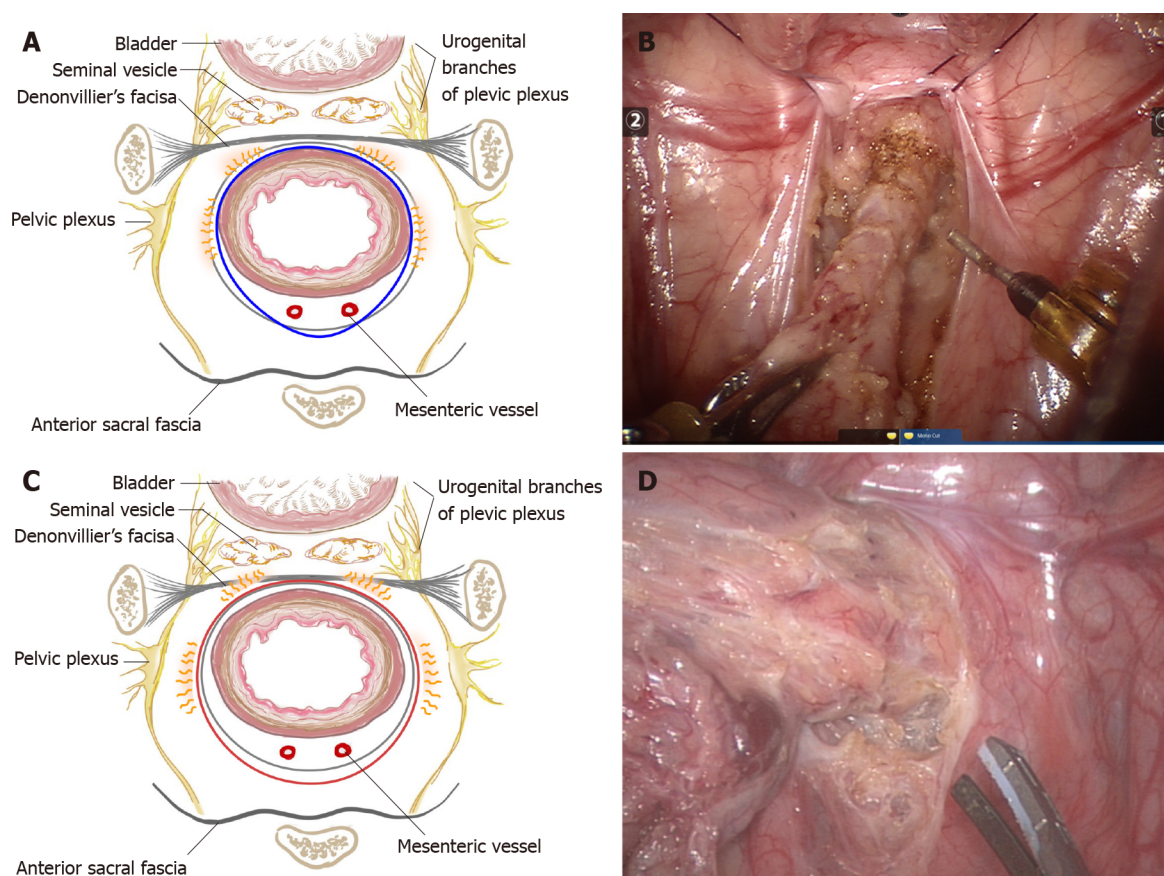
Patient demographics and operative data

A total of 184 participants were assessed for eligibility, and 156 patients were finally enrolled in this multicenter prospective study (Figure 1). The demographics and operative outcomes are shown in



DOI: 10.3748/wjg.v29.i23.3715 Copyright ©The Author(s) 2023.

Figure 2 Trocar site in robotic-assisted proctosigmoidectomy. There are three trocar ports, including a straight-cut umbilical trocar and two 8 mm working trocars located 5 cm from the umbilical trocar on either side.



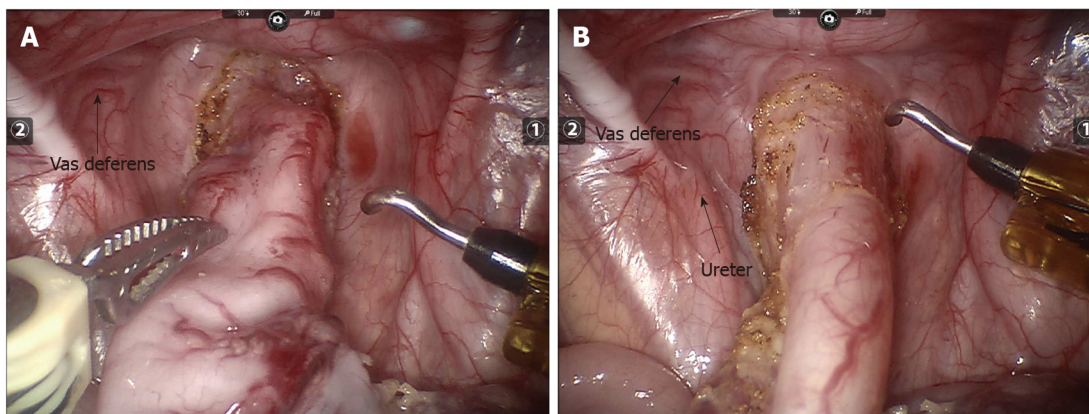
DOI: 10.3748/wjg.v29.i23.3715 Copyright ©The Author(s) 2023.

Figure 3 Diagram of pelvic dissection planes and intraoperative images of pelvic dissection. A: Pelvic dissection plane of robotic-assisted proctosigmoidectomy is under the serosa of the rectum or proper rectal fascia extended serous layer below the peritoneal reflection; B: Pelvic dissection under robotic endoscopy; C: Pelvic dissection plane of conventional laparoscopic Soave surgery is performed tightly around the rectal wall; D: Pelvic dissection under laparoscopy.

Table 3. No conversions or intraoperative complications occurred. The median age at surgery was 9.50 (range: 0.60-132.00) mo, and the weight was 9.09 ± 3.68 kg. The total operative time was 155.22 ± 16.77 min, and the robotic console time was 58.01 ± 7.71 min. The anal traction time was 45.28 ± 8.15 min, which included 15.21 ± 2.67 min for transanal dissection and 30.01 ± 5.82 min for anastomosis. The length of the removed bowel was 15.50 ± 5.23 cm, and the pelvic dissection depth under endoscopy was 4.50 ± 0.47 cm. The intraoperative estimated blood loss was 5.01 ± 1.81 mL.

Table 3 Operative parameters of patients

Parameter	<i>n</i> (%) or mean \pm SD/median (range)
Age at surgery (month)	9.50 (0.60-132.00)
≤ 1 mo	4 (2.56%)
≤ 3 mo	50 (32.05%)
≤ 1 yr	77 (49.36%)
≤ 3 yr	16 (10.26%)
> 3 yr	9 (5.77%)
Level of aganglionosis	
Sigmoid colon	29 (32.95%)
Upper rectum	39 (44.32%)
Lower rectum	20 (22.73%)
Weight at surgery (kg)	9.09 \pm 3.68
Operative time (min)	155.22 \pm 16.77
Console time (min)	58.01 \pm 7.71
Anal traction time (min)	45.28 \pm 8.15
Transanal dissection time (min)	15.21 \pm 2.67
Anastomosis time	30.01 \pm 5.82
Estimated blood loss (mL)	5.01 \pm 1.81
Pelvic dissection depth (cm)	4.50 \pm 0.47
Length of the removed bowel (cm)	15.50 \pm 5.23
Conversion	0 (0)
Intraoperative complications	0 (0)



DOI: 10.3748/wjg.v29.i23.3715 Copyright ©The Author(s) 2023.

Figure 4 The pelvic depth in robotic vision before and after pulling the rectum cranially; the depth becomes shallower after pulling. A: Before pulling; B: After pulling.**Postoperative outcomes**

Postoperative outcomes are detailed in Table 4. The hospital stay was 7.25 ± 1.67 d, and the median follow-up duration was 44.00 (range: 6.00-78.00) mo. Eight patients were lost to follow-up one year after surgery. Postoperative complications were assessed in accordance with the Classification of Surgical Complications[11]. The postoperative 30-d complications included Clavien-Dindo grade II complications in two patients with wound infections, two patients with lung infections, six patients with enterocolitis, and thirteen patients with perianal dermatitis, all of whom were corrected by conservative treatment. One patient exhibited a Clavien-Dindo grade IIIa complication (anastomotic leakage treated

Table 4 Postoperative outcomes of patients

Parameter	n (%) or mean \pm SD /median (range)
Hospital stay (day)	7.25 \pm 1.67
Follow-up time (month)	44.00 (6.00-78.00)
Outcomes within postoperative 30 d	
Omental hernia	1 (0.64%)
Wound infections	2 (1.28%)
Lung infections	2 (1.28%)
Perianal dermatitis	13 (8.33%)
Uroschesis	0 (0)
Urinary incontinence	0 (0)
Anastomotic leakage	1 (0.64%)
Enterocolitis	6 (3.85%)
Cuff abscess	0 (0)
Post 30-d complications	
Perianal dermatitis	0 (0)
Anastomotic strictures	2 (1.28%)
Sphincter spasm	0 (0)
Enterocolitis	16 (10.26%)
Soiling	7 (4.49%)
Staining	18 (11.54%)
Constipation	4 (2.56%)
Perianal dermatitis	1 (0.64%)

by resuturing with presacral drainage[12]), and one patient had a Clavien–Dindo grade IIIb complication (omental hernia requiring surgical correction). There was no uroschesis, urinary incontinence, or cuff abscess. Post-30-d complications included Clavien–Dindo grade I complications, namely, seven soilings (received bowel habit training) and eighteen stainings (no change of underwear required) as well as Clavien–Dindo grade II complications, namely, two cases of anastomotic strictures (underwent anal dilation treatment without anesthesia), sixteen cases of enterocolitis (received rectal decompression, irrigation, and broad-spectrum antibiotics), four cases of constipation (received a laxative and enema) and one case of perianal dermatitis (received topical medication).

Normal stool frequency and enterocolitis at 1-6 years after surgery

As listed in Table 5, we divided follow-up into four phases: ≤ 1 year, $1 < \text{years} \leq 2$, $2 < \text{years} \leq 4$, and $4 < \text{years} \leq 6$, with further analysis of short- to medium-term stool frequency and enterocolitis. The incidence of normal stool frequency increased steadily while the enterocolitis rate decreased gradually over time; the overall normal stool frequency rate increased from 55.13% to 89.06% under diet control (younger group: 53.70% to 86.36%, older group: 55.88% to 90.48%) (Figure 6A) and the overall enterocolitis rate declined from 10.26% to 4.69% (younger group: 11.11% to 4.55%, older group: 9.8% to 4.76%) (Figure 6B).

BFS and POFC score in the assessment of medium-term functional outcomes

The BFS and POFC score are shown in Table 6. Eighty-eight patients aged ≥ 4 years were evaluated with two scoring systems during follow-up. The bowel functional result was good (BFS ≥ 17) in 66 patients (75.00%), moderate ($12 \leq \text{BFS} \leq 16$) in 14 patients (15.91%), and poor (BFS < 12) in 8 patients (9.09%). The total BFS was 17.32 ± 2.63 , with satisfactory scores for each item. The POFC score at 4, 5 and 6 years of age postoperatively demonstrated a promising trend annually, with values of 10.95 ± 1.04 , 11.48 ± 0.72 , and 11.94 ± 0.81 , respectively (Figure 6C).

Comparison of efficacy between patients aged ≤ 3 mo and aged > 3 mo at surgery

The outcomes comparing normal stool frequency and enterocolitis are shown in Table 5. The comparison results of postoperative complications are detailed in Table 7, while the comparison results

Table 5 Normal stool frequency and enterocolitis 1-6 years after surgery

	Younger group				Older group				P value	Total			
	≤ 1 yr	1 < yr ≤ 2	2 < yr ≤ 4	4 < yr ≤ 6	≤ 1 yr	1 < yr ≤ 2	2 < yr ≤ 4	4 < yr ≤ 6		≤ 1 yr	1 < yr ≤ 2	2 < yr ≤ 4	4 < yr ≤ 6
	n = 54	n = 48	n = 38	n = 22	n = 102	n = 91	n = 74	n = 42		n = 156	n = 139	n = 112	n = 64
Normal stool frequency, n (%)	29 (53.70%)	34 (70.83%)	30 (78.95%)	19 (86.36%)	57 (55.88%)	67 (73.63%)	61 (82.43%)	38 (90.48%)	0.80, 0.73, 0.66, 0.94	86 (55.13%)	101 (72.66%)	91 (81.25%)	57 (89.06%)
Enterocolitis, n (%)	6 (11.11%)	5 (10.42%)	3 (7.89%)	1 (4.55%)	10 (9.80%)	7 (7.69%)	4 (5.41%)	2 (4.76%)	0.80, 0.82, 0.92, 1.00	16 (10.26%)	12 (8.63%)	7 (6.25%)	3 (4.69%)

of BFS and POFC scores are shown in Table 8. Due to the small number of neonates in this series, we carried out a subgroup analysis to assess defecation function in younger infants, grouping the patients by age into ≤ 3 mo (younger group, $n = 54$) and > 3 mo (older group, $n = 102$). There was no significant difference in postoperative complication rates, BFSs (younger group: 17.19 ± 2.87 , older group: 17.37 ± 2.54) or POFC scores at 4, 5 and 6 years of age postoperatively (younger group: 10.70 ± 0.99 , 11.38 ± 0.62 , 11.71 ± 0.76 ; older group: 11.07 ± 1.05 , 11.52 ± 0.76 , 12.00 ± 0.83) between the two groups (Figure 6C).

DISCUSSION

Robotic procedures are rapidly replacing open or laparoscopic procedures for the adult population in challenging procedures, such as operations for rectal and prostate cancer[2,3]. Nevertheless, the adoption of robots in pediatric surgery is low. Robotic surgery failed to show substantial benefits in studies comparing it to laparoscopic surgery because the procedures were initially used for less complex operations, such as the Nissen fundoplication[13]. In technically demanding situations, the application of robots for abdominal surgeries in children is relatively limited. Furthermore, only a few studies have revealed the feasibility of robotic-assisted surgery for HSCR, and the patient numbers were too small to generalize the application of robotic surgery in this field[14-17]. There is still a lack of studies involving large samples and long follow-up on functional outcomes. To our knowledge, 156 consecutive HSCR children who received RAPS represent the largest series in the literature. Long-segmental HSCR, total colonic aganglionosis, and trisomy 21 have been demonstrated to negatively affect the prognosis of HSCR patients[18-20]. Aiming to focus on the effect of surgical techniques on the postoperative outcomes of HSCR, we excluded these influencing factors and performed RAPS only on children with rectosigmoid HSCR.

The core of the original Soave procedure is pelvic endorectal dissection under the mucosa, but the mucosa is easily ruptured, resulting in pelvic contamination or mucosal residue. This explains the high rate of muscular sleeve infection following surgery in that era[4]. Pelvic endorectal dissection is a determining step in minimally invasive surgery for HSCR. Laparoscopic surgery facilitates tissue dissection in narrow spaces, and the technique still follows the concept of the original Soave procedure for nerve sparing. However, stiff laparoscopic instruments and unstable vision make submucosal rectal dissection more challenging, resulting in a higher mucosa rupture rate. Instead, extrarectal dissection is performed tightly around the rectal wall to 1-2 cm below the peritoneal reflection, and then a long-

Table 6 Bowel function scores and postoperative fecal continence scores among 88 patients aged 4 years or older

Parameter	Total (n = 88)
Bowel function score (Mean score \pm SD)/n (%)	
Feels the urge to defecate	
Always	66 (75.00%)
Most of the time	19 (21.59%)
Uncertain	3 (3.41%)
Absent	0 (0)
Mean score \pm SD	2.72 \pm 0.52
Ability to hold back defecation	
Always	63 (71.59%)
Problems less than once a week	17 (19.32%)
Weekly problems	8 (9.09%)
No voluntary control	0 (0)
Mean score \pm SD	2.63 \pm 0.65
Normal defecation frequency	55 (62.50%)
Mean score \pm SD	1.63 \pm 0.49
Fecal soiling	
Never	32 (36.36%)
Staining < 1/wk	42 (47.73%)
Frequent soiling, change of underwear required	14 (15.91%)
Daily soiling, protective aids required	0 (0)
Mean score \pm SD	2.23 \pm 0.69
Fecal accidents	
Never	63 (71.59%)
Less than once a week	18 (20.45%)
Weekly accidents, protective aids often required	6 (6.82%)
Daily, aids required day and night	1 (1.14%)
Mean score \pm SD	2.63 \pm 0.67
Constipation	
No constipation	82 (93.18%)
Manageable with diet	0 (0)
Manageable with laxatives	4 (4.55%)
Manageable with enemas	2 (2.27%)
Mean score \pm SD	2.84 \pm 0.60
Social problems	
No social problems	61 (69.32%)
Sometimes (fouls odors)	18 (20.45%)
Problems causing restrictions in social life	9 (10.23%)
Major social/psychosocial problems	0 (0)
Mean score \pm SD	2.59 \pm 0.67
Total score	17.32 \pm 2.63
Good bowel function (total score \geq 17)	66 (75.00%)

Moderate bowel function ($12 \leq \text{total score} \leq 16$)	14 (15.91%)
Poor bowel function (total score < 12)	8 (9.09%)
Postoperative fecal incontinence scores (Mean score \pm SD)	
Aged ≥ 4 years ($n = 88$)	10.95 \pm 1.04
Aged ≥ 5 years ($n = 60$)	11.48 \pm 0.72
Aged ≥ 6 years ($n = 34$)	11.94 \pm 0.81

Table 7 Comparison of postoperative outcomes between the younger group and the older group

Parameter	Younger group ($n = 54$)	Older group ($n = 102$)	P value
Outcomes within postoperative 30 d, n (%)			
Omental hernia	1 (1.85%)	0 (0)	0.35
Wound infections	1 (1.85%)	1 (0.98%)	1.00
Lung infections	2 (3.70%)	0 (0)	0.24
Perianal dermatitis	5 (9.26%)	8 (7.84%)	1.00
Uroschesis	0 (0)	0 (0)	-
Urinary incontinence	0 (0)	0 (0)	-
Anastomotic leakage	1 (1.85%)	0 (0)	0.35
Enterocolitis	4 (7.41%)	2 (1.96%)	0.21
Cuff abscess	0 (0)	0 (0)	-
Post-30-d complications, n (%)			
Perianal dermatitis	0 (0)	0 (0)	-
Anastomotic strictures	1 (1.85%)	1 (0.98%)	1.00
Sphincter spasm	0 (0)	0 (0)	-
Enterocolitis	6 (11.11%)	10 (9.80%)	0.80
Soiling	3 (5.56%)	4 (3.92%)	0.95
Staining	7 (12.96%)	11 (10.78%)	0.69
Constipation	1 (1.85%)	3 (2.94%)	1.00
Perianal dermatitis	1 (1.85%)	0 (0)	0.35

distance submucosal dissection is conducted through the anus as in Georgeson's technique (Figure 3C and D) [21]. For selected patients, a totally transanal endorectal technique with submucosal dissection can even be performed as in Torre's technique[22]. These procedures have been demonstrated to provide better short-term outcomes than open surgery, with similar long-term outcomes[6,23,24]. Nonetheless, some studies have found that minimally invasive surgery, particularly totally transanal surgery that requires more anal dissection, results in poorer long-term defecation function than open surgery, especially in neonates[7,25,26]. This is probably a result of the technique's increased risk of anal sphincter traction/injury[27]. Therefore, we hypothesized that RAPS could reduce these risks to support better long-term bowel function for patients.

Herein, the primary strength of our robotic-assisted technique is that a new endorectal dissection layer (outside the longitudinal muscle) can be established. This potential gap between anatomical structures exists objectively[28]. The new layer is farther away from the urinal nerves on both sides of the rectum and the sexual nerves ahead of the Denonvillier's fascia[29]. A diagram of the pelvic dissection layer is shown in Figure 3A. The robotic system provides a magnified 3D image, stable maneuverability, and articulated movement in the narrow area *via* small incisions. Another major advantage is the image stability from robotic arm support as minor camera movements can cause image shifting. These merits facilitate ideal identification of the subserosa and precise rectum dissection, thus guaranteeing nerve-sparing. In addition, the rectum with intact longitudinal and circular muscles can be pulled strongly and is less prone to rupture; thus, the surgeon is able to pull the rectum cranially to make the pelvis shallower (Figure 4), allowing the dissection to nearly reach the dentate line (Figure 3B). Extensive intra-abdominal endorectal dissection would result in less need for transanal dissection and

Table 8 Bowel function scores and postoperative fecal incontinence scores among patients aged 4 years or older between the younger group and the older group

Parameters	Younger group (n = 26)	Older group (n = 62)	P value
Bowel function scores (Mean score \pm SD)			
Feels the urge to defecate	2.65 \pm 0.63	2.74 \pm 0.48	0.68
Ability to hold back defecation	2.58 \pm 0.70	2.65 \pm 0.63	0.71
Normal defecation frequency	1.69 \pm 0.47	1.60 \pm 0.49	0.40
Fecal soiling	2.19 \pm 0.63	2.24 \pm 0.72	0.67
Fecal accidents	2.58 \pm 0.81	2.65 \pm 0.60	0.98
Constipation	2.81 \pm 0.69	2.85 \pm 0.57	0.82
Social problems	2.62 \pm 0.64	2.58 \pm 0.69	0.93
Total bowel function score	17.19 \pm 2.87	17.37 \pm 2.54	0.90
Postoperative fecal incontinence scores (Mean score \pm SD)			
Aged \geq 4 yr	10.70 \pm 0.99	11.07 \pm 1.05	0.16
Aged \geq 5 yr	11.38 \pm 0.62	11.52 \pm 0.76	0.46
Aged \geq 6 yr	11.71 \pm 0.76	12.00 \pm 0.83	0.35

simpler transanal procedures, thus permitting minor or no sphincter damage. **Figure 5C** and **D** show a comparison of the length of endorectal dissection and transanal dissection between two minimally invasive approaches. As our results show, the pelvic dissection could reach a depth of 4.50 ± 0.47 cm, so the length of the rectum dissected transanally was greatly shortened to 0.20-0.40 cm (**Figure 5B**). This reduces the time and intensity of sphincter traction. As reported, prolonged transanal dissection is prone to sphincter traction/injury[18,30]. Hence, robotic practice in pelvic rectal dissection may offer an excellent surgical tool.

Due to the additional docking and setting time of the robotic arms, the total operation time of robotic procedures is generally longer than that of open or laparoscopic procedures[15,31]. In our series, however, the operative time was 155.22 ± 16.77 min and was comparable to that of laparoscopic surgery, which varied from 94.00 to 294.00 min in previous large-sample studies[6,18,32-36]. Moreover, our results revealed that postoperative complication rates were similar or even lower than those of transanal or laparoscopic approaches[18,32-34]. There were no cuff abscesses in our series. This is related to precise and complete dissection of the rectum outside the longitudinal muscle up to the dentate line, preventing mucosal tube injury and ensuring no residual rectal mucosa. Previous studies have shown that the incidence of urinary incontinence in HSCR patients postoperatively ranges from 2.70%-22.00% [37-41], and urine retention ranges from 1.04%-6.67% [42-44]. Urinary complications following pelvic procedures may be caused by direct damage or indirect thermal radiation injury to the nerve endings controlling voiding. No uroschesis or urinary incontinence occurred after removal of the urinary catheter 24-48 h after surgery in any of the patients. This highlights the most obvious advantage of SNS-RAPS, which is the precise safeguarding of the urinal nerve around the rectum. Following this logic, good short-term bladder nerve protection after RAPS could indirectly predict better long-term defecation and sexual nerve function.

Postoperative bowel function and continence are the most important criteria for evaluating the effectiveness of SNS-RAPS. BFS was used for a comprehensive assessment of defecation, soiling, constipation, and social problems. Previous studies evaluating long-term outcomes (follow-up ranged from 9.5 to 28 years) after open, laparoscopic or transanal approaches have shown that 88.00% to 89.00% of HSCR patients obtained moderate-to-good bowel function (good: BFS \geq 17, 52.00%-63.00%; moderate: $12 \leq$ BFS \leq 16, 26.00%-36.00%)[7,45], with an overall score of 15.00 to 17.10[7,9,18,45-47]. One clinical trial even found that neonates with HSCR achieved a BFS of 17.44 for long-segment HSCR and 19.06 for short-segment HSCR after a transanal procedure (follow-up for more than 8 years)[48]. Our medium-term findings showed an overall BFS of 17.32 ± 2.63 and that 90.91% of patients achieved moderate-to-good bowel function (good: 75.00%; moderate: 15.91%), which was comparable to or better than the long-term results of previous studies. As studies have shown, postoperative bowel function improves with age[8, 46], so we predict that our series of patients will have better long-term bowel function. Furthermore, we used the POFC score to analyze fecal incontinence, reflecting the role of SNS-RAPS in nerve and sphincter protection[8]. The total POFC score gradually improved and was satisfactory in patients at 4, 5 and 6 years of age following surgery (10.95 ± 1.04 , 11.48 ± 0.72 and 11.94 ± 0.81), representing a result similar to or superior to that of laparoscopic operation (8.60-11.30)[8,49]. Postoperative functional results are strongly related to long-term quality of life (QoL)[9,46,47]. Satisfactory BFS and POFC scores in this

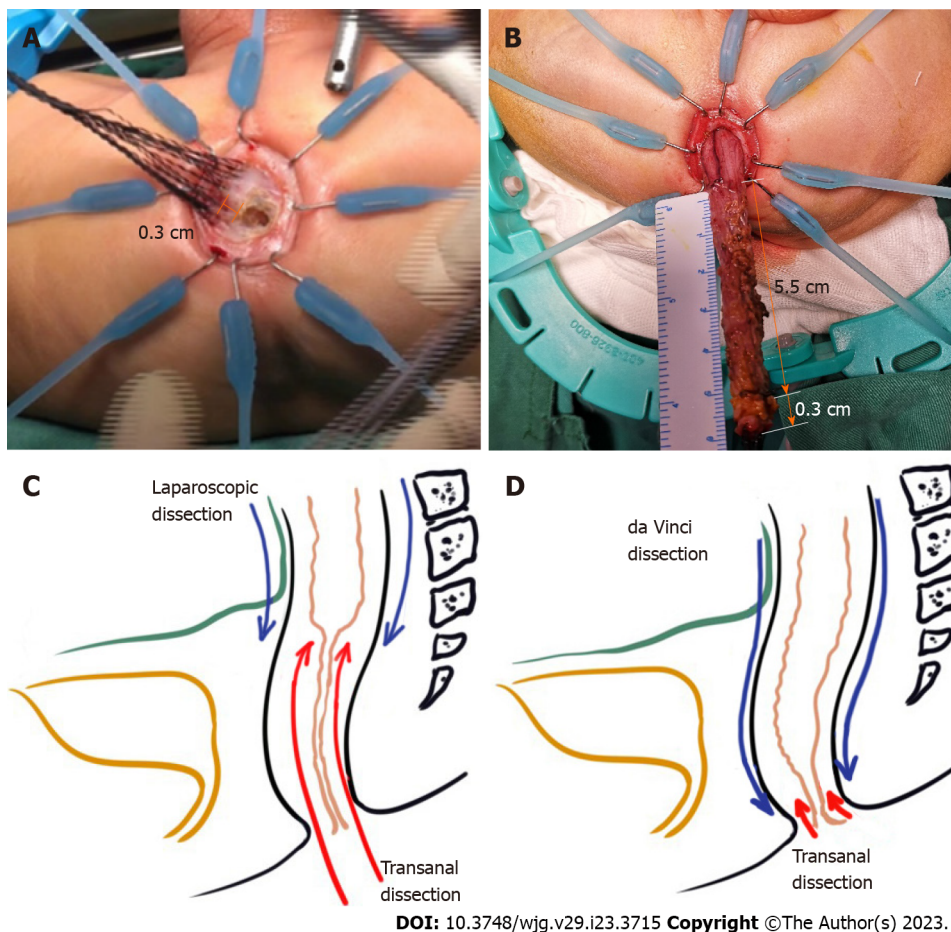


Figure 5 Comparison of two minimally invasive approaches and dissection length measurement of robotic-assisted proctosigmoidectomy. A: The transanal Soave anastomosis procedure is performed by making a circular incision 0.5-1 cm from the dentate line and dividing the mucosa upward by 0.2-0.4 cm; B: The length of pelvic dissection was 5.5 cm and the length of transanal dissection was 0.3 cm of robotic-assisted proctosigmoidectomy; C: The length of endorectal dissection and transanal dissection in the laparoscopic approach; D: The length of endorectal dissection and transanal dissection in the robotic approach.

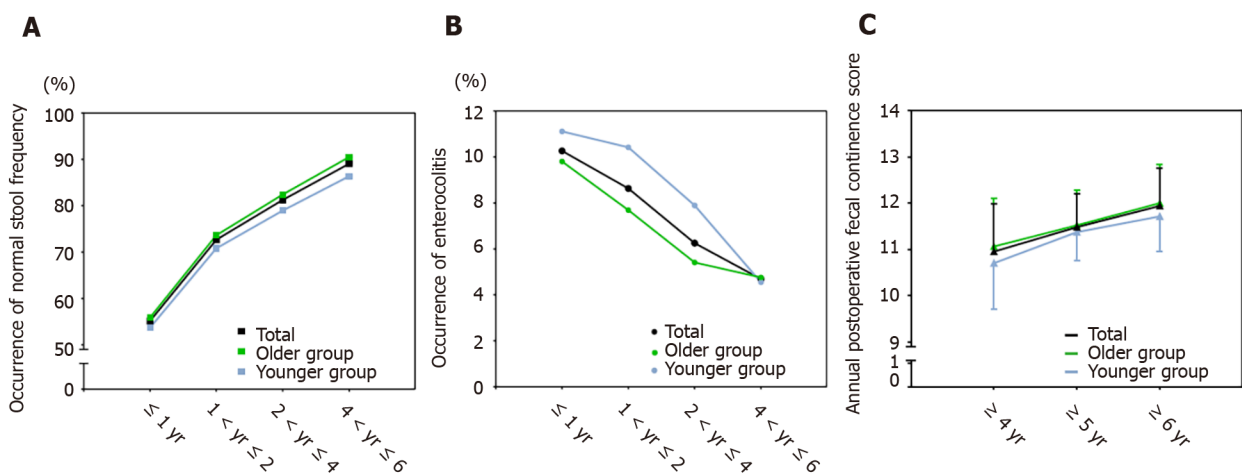


Figure 6 Short- to medium-term outcomes of robotic-assisted proctosigmoidectomy. A: Occurrence of normal stool frequency at 1-6 years after surgery; B: Occurrence of enterocolitis at 1-6 years after surgery; C: Annual postoperative fecal continence score analysis among patients aged 4 years or more.

series suggested that patients will achieve good long-term QoL.

Researchers in previous studies have mixed opinions on the efficacy in younger infants, especially neonates, compared with that in older children[49,50]. Although its appropriateness for younger infants with HSCR is debatable, robotic surgery could be successfully utilized for other diseases in the neonatal period[51]. We have gained experience in robotic surgery for these disorders and successfully applied

robotic surgery for neonates and infants with HSCR. As younger infants have a narrower pelvis and more compact structures than older children, the distance between the rectum and the surrounding structures is smaller. Moreover, younger age is associated with more fragile tissue that is vulnerable to operative injury[52]. These features increase the risk of injuring perirectal neurovascular tissues and sphincters during laparoscopic procedures, but the robotic system supplies a stable magnified 3D surgical field and precise rectal dissection to avoid the risk of disruption to the perirectal tissues. We found that HSCR patients in the younger group (aged ≤ 3 mo) and older group (aged > 3 mo) exhibited comparable complication rates, BFS and POFC scores. These data demonstrated that SNS-RAPS is feasible for HSCR patients aged ≤ 3 mo, and its efficacy was comparable to that in the older group. This also indicated that SNS-RAPS has better efficacy than previously reported open and laparoscopic procedures when considered from another perspective. Although totally transanal surgery was an option for 22.73% of patients with lower rectum HSCR in this study, our RAPS could reduce the time and intensity of sphincter traction and provide better outcomes. Taken together, our findings further support the view that the protection afforded by RAPS to the anal sphincter and perirectal nerves is no worse than other approaches and that RAPS is a preferred option for HSCR.

Although our study demonstrated favorable outcomes for RAPS, the limitations include only short- to medium-term outcomes and the absence of comparative data with other approaches. Therefore, a long-term follow-up and comparative trial should be performed to evaluate the effect of SNS-RAPS on HSCR. Currently, assessing long-term outcomes is not an option because SNS-RAPS has been used for less than 10 years. We intend to perform this clinical trial in the next several years. Moreover, the currently documented drawbacks of robotic surgery are longer operative time, expensive costs and oversized robotic devices for infants and neonates, creating economic and technical constraints. With the further advancement of pediatric robot devices, the reduction in surgical costs, and the improvement in surgeons' skills, the application of robots in pediatric surgery will mature. If surgery is to provide less pain and more effective therapy, then minimally invasive procedures achieved *via* robots that share the advantages of open or laparoscopic procedures may offer the answer.

CONCLUSION

SNS-RAPS is a safe and effective option for children of all ages with HSCR. The robotic platform can be utilized to further minimize surgical damage to the perirectal neurovascular tissue and anal sphincter, contributing to better bowel and urination function.

ARTICLE HIGHLIGHTS

Research background

Robotic-assisted surgery has been gradually introduced and applied to treat children with Hirschsprung's disease (HSCR). However, few studies have been conducted to evaluate its safety and efficacy for HSCR treatment.

Research motivation

We aimed to investigate the medium-term outcomes of robotic-assisted surgery for treating HSCR.

Research objectives

We aimed to analyze the feasibility and efficacy of robotic-assisted proctosigmoidectomy (RAPS) with sphincter- and nerve-sparing surgery (SNS) in the treatment of HSCR.

Research methods

We conducted a multicenter prospective study of 156 infants with rectosigmoid HSCR who underwent SNS-RAPS and divided them by age into a younger group (aged ≤ 3 mo) and an older group (aged > 3 mo) for comparison. Intraoperative data, postoperative complications, and medium-term outcomes were recorded and analyzed. In patients aged ≥ 4 years, the bowel function score (BFS) was used to assess overall bowel function, and the postoperative fecal continence (POFC) score was used to evaluate SNS-related incontinence.

Research results

A total of 156 patients underwent successful SNS-RAPS, with 25 complications within 30 d and 48 post-30-d complications after surgery. For children aged ≥ 4 years, the overall BFS was 17.32 ± 2.63 and 90.91% of patients showed moderate-to-good bowel function, while the POFC score increased annually from 4 to 6 years old (4 years old: 10.95 ± 1.04 , 5 years old: 11.48 ± 0.72 , 6 years old: 11.94 ± 0.81). There were no significant differences between the younger and older groups in postoperative complications.

and POFC score.

Research conclusions

SNS-RAPS is a safe and effective alternative treatment for children of all ages with HSCR. It provides the advantage of further minimizing damage to sphincters and perirectal nerves, thus providing better continence function.

Research perspectives

Robotic-assisted surgery is beneficial for treating HSCR in infants and young children.

ACKNOWLEDGEMENTS

We are grateful to Professor Ping Yin for the statistical evaluation.

FOOTNOTES

Author contributions: Zhang MX, Zhang X, Chang XP, and Tang ST contributed to conceptualization and design; Zhang MX, Zhang X, Chang XP, Cao GQ, Li S, Chi SQ, Wan L, Zeng JX, and Bian HQ contributed to material preparation, data acquisition, and analysis; Zhang MX, Zhang X, and Chang XP contributed equally to this study; All authors contributed to writing-draft manuscript and writing-revision and approved to submit the final version.

Supported by the National Health and Family Planning of China, No. 201402007; and the National Natural Science Foundation of China, No. 81873848 and No. 82170528.

Institutional review board statement: This study was approved by the Ethics Committee at three centers: Union Hospital, Tongji Medical College, Huazhong University of Science and Technology; Guangzhou Women and Children's Medical Center, Guangzhou Medical University; and Wuhan Children's Hospital, Tongji Medical College, Huazhong University of Science and Technology.

Clinical trial registration statement: The clinical trial is registered in the Chinese Clinical Trial Registry (Registration ID: ChiCTR2000035220). Details are available at <https://www.chictr.org.cn/showproj.aspx?proj=41379>.

Informed consent statement: All study participants, or their legal guardians, provided written consent prior to study enrollment.

Conflict-of-interest statement: All the authors report no relevant conflicts of interest for this article.

Data sharing statement: There is no additional data available.

CONSORT 2010 statement: The authors have read the CONSORT 2010 Statement, and the manuscript was prepared and revised according to the CONSORT 2010 Statement.

Open-Access: This article is an open-access article that was selected by an in-house editor and fully peer-reviewed by external reviewers. It is distributed in accordance with the Creative Commons Attribution NonCommercial (CC BY-NC 4.0) license, which permits others to distribute, remix, adapt, build upon this work non-commercially, and license their derivative works on different terms, provided the original work is properly cited and the use is non-commercial. See: <https://creativecommons.org/licenses/by-nc/4.0/>

Country/Territory of origin: China

ORCID number: Meng-Xin Zhang 0000-0001-9622-4882; Xi Zhang 0000-0001-8159-0855; Xiao-Pan Chang 0000-0002-6901-5716; Ji-Xiao Zeng 0000-0003-4854-4966; Hong-Qiang Bian 0000-0003-2417-1560; Guo-Qing Cao 0000-0002-1267-9714; Shuai Li 0000-0001-7585-018X; Shui-Qing Chi 0000-0002-7537-0255; Ying Zhou 0000-0002-9257-0523; Li-Ying Rong 0000-0001-6670-050X; Li Wan 0000-0003-2839-2475; Shao-Tao Tang 0000-0002-1851-0610.

S-Editor: Li L

L-Editor: A

P-Editor: Li Li

REFERENCES

- 1 Ahmad H, Shaul DB. Pediatric colorectal robotic surgery. *Semin Pediatr Surg* 2023; 32:151259 [PMID: 36739693 DOI: 10.1016/j.sempedsurg.2023.151259]

- 10.1016/j.sempedsurg.2023.151259]
- 2 **Crippa J**, Grass F, Dozois EJ, Mathis KL, Merchea A, Colibaseanu DT, Kelley SR, Larson DW. Robotic Surgery for Rectal Cancer Provides Advantageous Outcomes Over Laparoscopic Approach: Results From a Large Retrospective Cohort. *Ann Surg* 2021; **274**: e1218-e1222 [PMID: 32068552 DOI: 10.1097/SLA.0000000000003805]
- 3 **Stolzenburg JU**, Holze S, Arthanareeswaran VK, Neuhaus P, Do HM, Haney CM, Dietel A, Truss MC, Stützel KD, Teber D, Hohenfellner M, Rabenalt R, Albers P, Mende M. Robotic-assisted Versus Laparoscopic Radical Prostatectomy: 12-month Outcomes of the Multicentre Randomised Controlled LAP-01 Trial. *Eur Urol Focus* 2022; **8**: 1583-1590 [PMID: 35216946 DOI: 10.1016/j.euf.2022.02.002]
- 4 **Langer JC**, Seifert M, Minkes RK. One-stage Soave pull-through for Hirschsprung's disease: a comparison of the transanal and open approaches. *J Pediatr Surg* 2000; **35**: 820-822 [PMID: 10873018 DOI: 10.1053/jpsu.2000.6849]
- 5 **Tian Y**, Shi T, Wang F, Wu Y. Difference of efficacy between Laparoscopic Modified Soave operation and Open Radical Resection in the treatment of Hirschsprung's disease. *Pak J Med Sci* 2017; **33**: 1385-1389 [PMID: 29492064 DOI: 10.12669/pjms.336.13220]
- 6 **Kubota A**, Kawahara H, Okuyama H, Oue T, Tazuke Y, Okada A. Clinical outcome of laparoscopically assisted endorectal pull-through in Hirschsprung's disease: comparison of abdominal and perineal approaches. *J Pediatr Surg* 2004; **39**: 1835-1837 [PMID: 15616944 DOI: 10.1016/j.jpedsurg.2004.08.015]
- 7 **Neuvonen MI**, Kyrklund K, Rintala RJ, Pakarinen MP. Bowel Function and Quality of Life After Transanal Endorectal Pull-through for Hirschsprung Disease: Controlled Outcomes up to Adulthood. *Ann Surg* 2017; **265**: 622-629 [PMID: 28169931 DOI: 10.1097/SLA.0000000000001695]
- 8 **Miyano G**, Koga H, Okawada M, Doi T, Sueyoshi R, Nakamura H, Seo S, Ochi T, Yamada S, Imaizumi T, Lane GJ, Okazaki T, Urao M, Yamataka A. Rectal mucosal dissection commencing directly on the anorectal line vs commencing above the dentate line in laparoscopy-assisted transanal pull-through for Hirschsprung's disease: Prospective medium-term follow-up. *J Pediatr Surg* 2015; **50**: 2041-2043 [PMID: 26386879 DOI: 10.1016/j.jpedsurg.2015.08.022]
- 9 **Jarvi K**, Laitakari EM, Koivusalo A, Rintala RJ, Pakarinen MP. Bowel function and gastrointestinal quality of life among adults operated for Hirschsprung disease during childhood: a population-based study. *Ann Surg* 2010; **252**: 977-981 [PMID: 21107107 DOI: 10.1097/SLA.0b013e3182018542]
- 10 **Teitelbaum DH**, Coran AG. Enterocolitis. *Semin Pediatr Surg* 1998; **7**: 162-169 [PMID: 9718654 DOI: 10.1016/S1055-8586(98)70012-5]
- 11 **Dindo D**, Demartines N, Clavien PA. Classification of surgical complications: a new proposal with evaluation in a cohort of 6336 patients and results of a survey. *Ann Surg* 2004; **240**: 205-213 [PMID: 15273542 DOI: 10.1097/01.sla.0000133083.54934.ae]
- 12 **Chi S**, Guo J, Zhang X, Li K, Xu P, Cao G, Li S, Tang ST. Resuturing Without Enterostomy for the Treatment of Early-Stage Anastomotic Leaks After Laparoscopic Soave Procedure in Hirschsprung's Disease. *J Laparoendosc Adv Surg Tech A* 2020; **30**: 1295-1300 [PMID: 33181061 DOI: 10.1089/lap.2020.0640]
- 13 **Markar SR**, Karthikesalingam AP, Hagen ME, Talamini M, Horgan S, Wagner OJ. Robotic vs. laparoscopic Nissen fundoplication for gastro-oesophageal reflux disease: systematic review and meta-analysis. *Int J Med Robot* 2010; **6**: 125-131 [PMID: 20506440 DOI: 10.1002/res.309]
- 14 **Quynh TA**, Hien PD, Du LQ, Long LH, Tran NTN, Hung T. The follow-up of the robotic-assisted Soave procedure for Hirschsprung's disease in children. *J Robot Surg* 2022; **16**: 301-305 [PMID: 33843006 DOI: 10.1007/s11701-021-01238-z]
- 15 **Pini Prato A**, Arnoldi R, Dusio MP, Cimorelli A, Barbeta V, Felici E, Barbieri P, Barbero S, Carlini C, Petralia P, Mattioli G, Roveta A, Maconi A. Totally robotic soave pull-through procedure for Hirschsprung's disease: lessons learned from 11 consecutive pediatric patients. *Pediatr Surg Int* 2020; **36**: 209-218 [PMID: 31659436 DOI: 10.1007/s00383-019-04593-z]
- 16 **Delgado-Miguel C**, Camps JI. Robotic Soave pull-through procedure for Hirschsprung's disease in children under 12-months: long-term outcomes. *Pediatr Surg Int* 2022; **38**: 51-57 [PMID: 34557957 DOI: 10.1007/s00383-021-05018-6]
- 17 **Li W**, Lin M, Hu H, Sun Q, Su C, Wang C, Li Y, Chen J, Luo Y. Surgical Management of Hirschsprung's Disease: A Comparative Study Between Conventional Laparoscopic Surgery, Transumbilical Single-Site Laparoscopic Surgery, and Robotic Surgery. *Front Surg* 2022; **9**: 924850 [PMID: 35860198 DOI: 10.3389/fsurg.2022.924850]
- 18 **Bjørnland K**, Pakarinen MP, Stenström P, Stensrud KJ, Neuvonen M, Granström AL, Graneli C, Pripp AH, Arnbjörnsson E, Emblem R, Wester T, Rintala RJ; Nordic Pediatric Surgery Study Consortium. A Nordic multicenter survey of long-term bowel function after transanal endorectal pull-through in 200 patients with rectosigmoid Hirschsprung disease. *J Pediatr Surg* 2017; **52**: 1458-1464 [PMID: 28094015 DOI: 10.1016/j.jpedsurg.2017.01.001]
- 19 **Sakurai T**, Tanaka H, Endo N. Predictive factors for the development of postoperative Hirschsprung-associated enterocolitis in children operated during infancy. *Pediatr Surg Int* 2021; **37**: 275-280 [PMID: 33245447 DOI: 10.1007/s00383-020-04784-z]
- 20 **Morabito A**, Lall A, Gull S, Mohee A, Bianchi A. The impact of Down's syndrome on the immediate and long-term outcomes of children with Hirschsprung's disease. *Pediatr Surg Int* 2006; **22**: 179-181 [PMID: 16362310 DOI: 10.1007/s00383-005-1617-0]
- 21 **Georgeson KE**, Fuenfer MM, Hardin WD. Primary laparoscopic pull-through for Hirschsprung's disease in infants and children. *J Pediatr Surg* 1995; **30**: 1017-21; discussion 1021 [PMID: 7472924 DOI: 10.1016/0022-3468(95)90333-X]
- 22 **De la Torre-Mondragón L**, Ortega-Salgado JA. Transanal endorectal pull-through for Hirschsprung's disease. *J Pediatr Surg* 1998; **33**: 1283-1286 [PMID: 9722005 DOI: 10.1016/S0022-3468(98)90169-5]
- 23 **Chen Y**, Nah SA, Laksmi NK, Ong CC, Chua JH, Jacobsen A, Low Y. Transanal endorectal pull-through vs transabdominal approach for Hirschsprung's disease: a systematic review and meta-analysis. *J Pediatr Surg* 2013; **48**: 642-651 [PMID: 23480925 DOI: 10.1016/j.jpedsurg.2012.12.036]
- 24 **Zhang S**, Li J, Wu Y, Hu Y, Duan C, Wang M, Gai Z. Comparison of Laparoscopic-Assisted Operations and Laparotomy Operations for the Treatment of Hirschsprung Disease: Evidence From a Meta-Analysis. *Medicine (Baltimore)* 2015; **94**: e1632 [PMID: 26426651 DOI: 10.1097/MD.0000000000001632]

- 25 **El-Sawaf MI**, Drongowski RA, Chamberlain JN, Coran AG, Teitelbaum DH. Are the long-term results of the transanal pull-through equal to those of the transabdominal pull-through? A comparison of the 2 approaches for Hirschsprung disease. *J Pediatr Surg* 2007; **42**: 41-7; discussion 47 [PMID: [17208539](#) DOI: [10.1016/j.jpedsurg.2006.09.007](#)]
- 26 **Stensrud KJ**, Emblem R, Bjørnland K. Anal endosonography and bowel function in patients undergoing different types of endorectal pull-through procedures for Hirschsprung disease. *J Pediatr Surg* 2015; **50**: 1341-1346 [PMID: [25783406](#) DOI: [10.1016/j.jpedsurg.2014.12.024](#)]
- 27 **Stensrud KJ**, Emblem R, Bjørnland K. Functional outcome after operation for Hirschsprung disease--transanal vs transabdominal approach. *J Pediatr Surg* 2010; **45**: 1640-1644 [PMID: [20713213](#) DOI: [10.1016/j.jpedsurg.2010.02.065](#)]
- 28 **Zhang C**, Ding ZH, Li GX, Yu J, Wang YN, Hu YF. Perirectal fascia and spaces: annular distribution pattern around the mesorectum. *Dis Colon Rectum* 2010; **53**: 1315-1322 [PMID: [20706076](#) DOI: [10.1007/DCR.0b013e3181e74525](#)]
- 29 **He M**, Muro S, Akita K. Positional relationship between the lateral border of Denonvilliers' fascia and pelvic plexus. *Anat Sci Int* 2022; **97**: 101-109 [PMID: [34529236](#) DOI: [10.1007/s12565-021-00629-4](#)]
- 30 **Pratap A**, Gupta DK, Shakya VC, Adhikary S, Tiwari A, Shrestha P, Pandey SR, Yadav RK. Analysis of problems, complications, avoidance and management with transanal pull-through for Hirschsprung disease. *J Pediatr Surg* 2007; **42**: 1869-1876 [PMID: [18022438](#) DOI: [10.1016/j.jpedsurg.2007.07.017](#)]
- 31 **D'Annibale A**, Morpurgo E, Fiscon V, Trevisan P, Sovernigo G, Orsini C, Guidolin D. Robotic and laparoscopic surgery for treatment of colorectal diseases. *Dis Colon Rectum* 2004; **47**: 2162-2168 [PMID: [15657669](#) DOI: [10.1007/s10350-004-0711-z](#)]
- 32 **Karlsen RA**, Hoel AT, Fosby MV, Ertresvåg K, Austrheim AI, Stensrud KJ, Bjørnland K. Comparison of clinical outcomes after total transanal and laparoscopic assisted endorectal pull-through in patients with rectosigmoid Hirschsprung disease. *J Pediatr Surg* 2022; **57**: 69-74 [PMID: [35123788](#) DOI: [10.1016/j.jpedsurg.2022.01.011](#)]
- 33 **van de Ven TJ**, Sloots CE, Wijnen MH, Rassouli R, van Rooij I, Wijnen RM, de Blaauw I. Transanal endorectal pull-through for classic segment Hirschsprung's disease: with or without laparoscopic mobilization of the rectosigmoid? *J Pediatr Surg* 2013; **48**: 1914-1918 [PMID: [24074667](#) DOI: [10.1016/j.jpedsurg.2013.04.025](#)]
- 34 **Aubdoollah TH**, Li K, Zhang X, Li S, Yang L, Lei HY, Dolo PR, Xiang XC, Cao GQ, Wang GB, Tang ST. Clinical outcomes and ergonomics analysis of three laparoscopic techniques for Hirschsprung's disease. *World J Gastroenterol* 2015; **21**: 8903-8911 [PMID: [26269680](#) DOI: [10.3748/wjg.v21.i29.8903](#)]
- 35 **Tang ST**, Wang GB, Cao GQ, Wang Y, Mao YZ, Li SW, Li S, Yang Y, Yang J, Yang L. 10 years of experience with laparoscopic-assisted endorectal Soave pull-through procedure for Hirschsprung's disease in China. *J Laparoendosc Adv Surg Tech A* 2012; **22**: 280-284 [PMID: [22449115](#) DOI: [10.1089/lap.2011.0081](#)]
- 36 **Wang YJ**, He YB, Chen L, Lin Y, Liu MK, Zhou CM. Laparoscopic-assisted Soave procedure for Hirschsprung disease: 10-year experience with 106 cases. *BMC Surg* 2022; **22**: 72 [PMID: [35219304](#) DOI: [10.1186/s12893-022-01528-9](#)]
- 37 **Boemers TM**. Urinary incontinence and vesicourethral dysfunction in pediatric surgical conditions. *Semin Pediatr Surg* 2002; **11**: 91-99 [PMID: [11973761](#) DOI: [10.1053/spsu.2002.31807](#)]
- 38 **Ieiri S**, Nakatsuji T, Akiyoshi J, Higashi M, Hashizume M, Suita S, Taguchi T. Long-term outcomes and the quality of life of Hirschsprung disease in adolescents who have reached 18 years or older--a 47-year single-institute experience. *J Pediatr Surg* 2010; **45**: 2398-2402 [PMID: [21129554](#) DOI: [10.1016/j.jpedsurg.2010.08.040](#)]
- 39 **Granström AL**, Danielson J, Husberg B, Nordenskjöld A, Wester T. Adult outcomes after surgery for Hirschsprung's disease: Evaluation of bowel function and quality of life. *J Pediatr Surg* 2015; **50**: 1865-1869 [PMID: [26164226](#) DOI: [10.1016/j.jpedsurg.2015.06.014](#)]
- 40 **Allin BSR**, Opondo C, Bradnock TJ, Kenny SE, Kurinczuk JJ, Walker GM, Knight M; NETS2HD collaboration. Outcomes at five to eight years of age for children with Hirschsprung's disease. *Arch Dis Child* 2020; **106**: 484-490 [PMID: [33139346](#) DOI: [10.1136/archdischild-2020-320310](#)]
- 41 **Fuchs O**, Booss D. Rehbein's procedure for Hirschsprung's disease. An appraisal of 45 years. *Eur J Pediatr Surg* 1999; **9**: 389-391 [PMID: [10661849](#) DOI: [10.1055/s-2008-1072289](#)]
- 42 **Wang G**, Sun XY, Wei MF, Weng YZ. Heart-shaped anastomosis for Hirschsprung's disease: Operative technique and long-term follow-up. *World J Gastroenterol* 2005; **11**: 296-298 [PMID: [15633236](#) DOI: [10.3748/wjg.v11.i2.296](#)]
- 43 **Wang M**, Pang W, Zhou L, Ma J, Xie S. Effect of Transumbilical Single-Port Laparoscopic-Assisted Duhamel Operation on Serum CRP and IL-6 Levels in Children with Hirschsprung's Disease. *J Healthc Eng* 2022; **2022**: 8349851 [PMID: [35281524](#) DOI: [10.1155/2022/8349851](#)]
- 44 **Ateş O**, Hakgüder G, Kart Y, Olguner M, Akgür FM. The effect of dilated ganglionic segment on anorectal and urinary functions during 1-stage transanal endorectal pull through for Hirschsprung's disease. *J Pediatr Surg* 2007; **42**: 1271-1275 [PMID: [17618894](#) DOI: [10.1016/j.jpedsurg.2007.02.020](#)]
- 45 **Davidson JR**, Kyrklund K, Eaton S, Pakarinen MP, Thompson DS, Cross K, Blackburn SC, De Coppi P, Curry J. Long-term surgical and patient-reported outcomes of Hirschsprung Disease. *J Pediatr Surg* 2021; **56**: 1502-1511 [PMID: [33706942](#) DOI: [10.1016/j.jpedsurg.2021.01.043](#)]
- 46 **Stenström P**, Brautigam M, Borg H, Graneli C, Lilja HE, Wester T. Patient-reported Swedish nationwide outcomes of children and adolescents with total colonic aganglionosis. *J Pediatr Surg* 2017; **52**: 1302-1307 [PMID: [27912975](#) DOI: [10.1016/j.jpedsurg.2016.11.033](#)]
- 47 **Xiong X**, Chen X, Wang G, Feng J. Long term quality of life in patients with Hirschsprung's disease who underwent heart-shaped anastomosis during childhood: A twenty-year follow-up in China. *J Pediatr Surg* 2015; **50**: 2044-2047 [PMID: [26423683](#) DOI: [10.1016/j.jpedsurg.2015.08.027](#)]
- 48 **Zhang Y**, Liu Z, Li S, Yang S, Zhao J, Yang T, Chen Y, Guo W, Hou D, Li Y, Huang J. One-stage transanal endorectal pull-through for Hirschsprung disease: experience with 229 neonates. *Pediatr Surg Int* 2022; **38**: 1533-1540 [PMID: [36030350](#) DOI: [10.1007/s00383-022-05198-9](#)]
- 49 **Yamatoka A**, Kaneyama K, Fujiwara N, Hayashi Y, Lane GJ, Kawashima K, Okazaki T. Rectal mucosal dissection during transanal pull-through for Hirschsprung disease: the anorectal or the dentate line? *J Pediatr Surg* 2009; **44**: 266-9; discussion 270 [PMID: [19159754](#) DOI: [10.1016/j.jpedsurg.2008.10.054](#)]
- 50 **Lu C**, Hou G, Liu C, Geng Q, Xu X, Zhang J, Chen H, Tang W. Single-stage transanal endorectal pull-through procedure

for correction of Hirschsprung disease in neonates and nonneonates: A multicenter study. *J Pediatr Surg* 2017; **52**: 1102-1107 [PMID: [28185631](#) DOI: [10.1016/j.jpedsurg.2017.01.061](#)]

- 51 **Meehan JJ**, Sandler A. Robotic repair of a Bochdalek congenital diaphragmatic hernia in a small neonate: robotic advantages and limitations. *J Pediatr Surg* 2007; **42**: 1757-1760 [PMID: [17923210](#) DOI: [10.1016/j.jpedsurg.2007.06.013](#)]
- 52 **Onishi S**, Kaji T, Nakame K, Yamada K, Murakami M, Sugita K, Yano K, Matsui M, Nagano A, Harumatsu T, Yamada W, Matsukubo M, Muto M, Ieiri S. Optimal timing of definitive surgery for Hirschsprung's disease to achieve better long-term bowel function. *Surg Today* 2022; **52**: 92-97 [PMID: [34383138](#) DOI: [10.1007/s00595-021-02356-9](#)]



Published by **Baishideng Publishing Group Inc**
7041 Koll Center Parkway, Suite 160, Pleasanton, CA 94566, USA

Telephone: +1-925-3991568

E-mail: bpgoffice@wjgnet.com

Help Desk: <https://www.f6publishing.com/helpdesk>

<https://www.wjgnet.com>

