

# World Journal of *Gastroenterology*

*World J Gastroenterol* 2023 June 28; 29(24): 3748-3931



## MINIREVIEWS

- 3748 Vascular endothelial growth factor protein and gene delivery by novel nanomaterials for promoting liver regeneration after partial hepatectomy  
*Jin Y, Guo YH, Li JC, Li Q, Ye D, Zhang XX, Li JT*
- 3758 Current status and future perspectives for the treatment of resectable locally advanced esophagogastric junction cancer: A narrative review  
*Shoji Y, Koyanagi K, Kanamori K, Tajima K, Ogimi M, Yatabe K, Yamamoto M, Kazuno A, Nabeshima K, Nakamura K, Nishi T, Mori M*

## ORIGINAL ARTICLE

## Basic Study

- 3770 Mechanism of ELL-associated factor 2 and vasohibin 1 regulating invasion, migration, and angiogenesis in colorectal cancer  
*Feng ML, Sun MJ, Xu BY, Liu MY, Zhang HJ, Wu C*
- 3793 Transcriptome sequencing and experiments reveal the effect of formyl peptide receptor 2 on liver homeostasis  
*Liu H, Sun ZY, Jiang H, Li XD, Jiang YQ, Liu P, Huang WH, Lv QY, Zhang XL, Li RK*

## Retrospective Cohort Study

- 3807 Prediction of lymph node metastasis in early gastric signet-ring cell carcinoma: A real-world retrospective cohort study  
*Yang JJ, Wang XY, Ma R, Chen MH, Zhang GX, Li X*
- 3825 Regional variation in routes to diagnosis of cholangiocarcinoma in England from 2006 to 2017  
*Zalin-Miller A, Jose S, Knott C, Paley L, Tataru D, Morement H, Toledano MB, Khan SA*
- 3843 Effect of lifestyle modification on hepatocellular carcinoma incidence and mortality among patients with chronic hepatitis B  
*Park Y, Kang D, Sinn DH, Kim H, Hong YS, Cho J, Gwak GY*

## Retrospective Study

- 3855 Comparison and development of machine learning for thalidomide-induced peripheral neuropathy prediction of refractory Crohn's disease in Chinese population  
*Mao J, Chao K, Jiang FL, Ye XP, Yang T, Li P, Zhu X, Hu PJ, Zhou BJ, Huang M, Gao X, Wang XD*

## Clinical Trials Study

- 3871 Stereotactic body radiotherapy combined with sintilimab in patients with recurrent or oligometastatic hepatocellular carcinoma: A phase II clinical trial  
*Chen YX, Yang P, Du SS, Zhuang Y, Huang C, Hu Y, Zhu WC, Yu YY, Liu TS, Zeng ZC*

**Observational Study**

- 3883** Non-exposed endoscopic wall-inversion surgery with one-step nucleic acid amplification for early gastrointestinal tumors: Personal experience and literature review

*Crafa F, Vanella S, Morante A, Catalano OA, Pomykala KL, Baiamonte M, Godas M, Antunes A, Costa Pereira J, Giaccaglia V*

**SCIENTOMETRICS**

- 3899** Immunological factors in cirrhosis diseases from a bibliometric point of view

*Zhang D, Liu BW, Liang XQ, Liu FQ*

**CASE REPORT**

- 3922** Treatment of colonic varices and gastrointestinal bleeding by recanalization and stenting of splenic-vein-thrombosis: A case report and literature review

*Füssel LM, Müller-Wille R, Dinkhauser P, Schauer W, Hofer H*

**ABOUT COVER**

Editorial Board Member of *World Journal of Gastroenterology*, Mostafa Mohamed Sira, BM BCh, MD, MSc, PhD, Professor, Department of Pediatric Hepatology, Gastroenterology and Hepatology. National Liver Institute, Menoufia University, Shebin El-koom 32511, Menoufia, Egypt. msira@liver.menofia.edu.eg

**AIMS AND SCOPE**

The primary aim of *World Journal of Gastroenterology* (WJG, *World J Gastroenterol*) is to provide scholars and readers from various fields of gastroenterology and hepatology with a platform to publish high-quality basic and clinical research articles and communicate their research findings online. WJG mainly publishes articles reporting research results and findings obtained in the field of gastroenterology and hepatology and covering a wide range of topics including gastroenterology, hepatology, gastrointestinal endoscopy, gastrointestinal surgery, gastrointestinal oncology, and pediatric gastroenterology.

**INDEXING/ABSTRACTING**

The WJG is now abstracted and indexed in Science Citation Index Expanded (SCIE, also known as SciSearch®), Current Contents/Clinical Medicine, Journal Citation Reports, Index Medicus, MEDLINE, PubMed, PubMed Central, Scopus, Reference Citation Analysis, China National Knowledge Infrastructure, China Science and Technology Journal Database, and Superstar Journals Database. The 2022 edition of Journal Citation Reports® cites the 2021 impact factor (IF) for WJG as 5.374; IF without journal self cites: 5.187; 5-year IF: 5.715; Journal Citation Indicator: 0.84; Ranking: 31 among 93 journals in gastroenterology and hepatology; and Quartile category: Q2. The WJG's CiteScore for 2021 is 8.1 and Scopus CiteScore rank 2021: Gastroenterology is 18/149.

**RESPONSIBLE EDITORS FOR THIS ISSUE**

Production Editor: *Yu-Xi Chen*; Production Department Director: *Xu Guo*; Editorial Office Director: *Jia-Ru Fan*.

**NAME OF JOURNAL**

*World Journal of Gastroenterology*

**ISSN**

ISSN 1007-9327 (print) ISSN 2219-2840 (online)

**LAUNCH DATE**

October 1, 1995

**FREQUENCY**

Weekly

**EDITORS-IN-CHIEF**

Andrzej S Tarnawski

**EDITORIAL BOARD MEMBERS**

<http://www.wjgnet.com/1007-9327/editorialboard.htm>

**PUBLICATION DATE**

June 28, 2023

**COPYRIGHT**

© 2023 Baishideng Publishing Group Inc

**INSTRUCTIONS TO AUTHORS**

<https://www.wjgnet.com/bpg/gerinfo/204>

**GUIDELINES FOR ETHICS DOCUMENTS**

<https://www.wjgnet.com/bpg/GerInfo/287>

**GUIDELINES FOR NON-NATIVE SPEAKERS OF ENGLISH**

<https://www.wjgnet.com/bpg/gerinfo/240>

**PUBLICATION ETHICS**

<https://www.wjgnet.com/bpg/GerInfo/288>

**PUBLICATION MISCONDUCT**

<https://www.wjgnet.com/bpg/gerinfo/208>

**ARTICLE PROCESSING CHARGE**

<https://www.wjgnet.com/bpg/gerinfo/242>

**STEPS FOR SUBMITTING MANUSCRIPTS**

<https://www.wjgnet.com/bpg/GerInfo/239>

**ONLINE SUBMISSION**

<https://www.f6publishing.com>





## Treatment of colonic varices and gastrointestinal bleeding by recanalization and stenting of splenic-vein-thrombosis: A case report and literature review

Lisa-Michaela Füssel, Rene Müller-Wille, Patrick Dinkhauser, Walter Schauer, Harald Hofer

**Specialty type:** Gastroenterology and hepatology

**Provenance and peer review:**

Unsolicited article; Externally peer reviewed.

**Peer-review model:** Single blind

**Peer-review report's scientific quality classification**

Grade A (Excellent): A

Grade B (Very good): B

Grade C (Good): 0

Grade D (Fair): 0

Grade E (Poor): 0

**P-Reviewer:** Ding WW, China; Protopapas AA, Greece

**Received:** February 1, 2023

**Peer-review started:** February 1, 2023

**First decision:** April 14, 2023

**Revised:** April 27, 2023

**Accepted:** May 24, 2023

**Article in press:** May 24, 2023

**Published online:** June 28, 2023



**Lisa-Michaela Füssel, Patrick Dinkhauser, Harald Hofer**, Department of Internal Medicine I, Gastroenterology and Hepatology, Klinikum Wels-Grieskirchen, Wels 4600, Austria

**Rene Müller-Wille**, Department of Radiology, Klinikum Wels-Grieskirchen, Wels 4600, Austria

**Walter Schauer**, Department of Abdominal Surgery, Klinikum Wels-Grieskirchen, Wels 4600, Austria

**Corresponding author:** Harald Hofer, MD, Professor, Department of Internal Medicine I, Gastroenterology and Hepatology, Klinikum Wels-Grieskirchen, Grieskirchnerstraße 42, Wels 4600, Austria. [harald.hofer@klinikum-wegr.at](mailto:harald.hofer@klinikum-wegr.at)

### Abstract

#### BACKGROUND

Splenic vein thrombosis is a known complication of pancreatitis. It can lead to increased blood flow through mesenteric collaterals. This segmental hypertension may result in the development of colonic varices (CV) with a high risk of severe gastrointestinal bleeding. While clear guidelines for treatment are lacking, splenectomy or splenic artery embolization are often used to treat bleeding. Splenic vein stenting has been shown to be a safe option.

#### CASE SUMMARY

A 45-year-old female patient was admitted due to recurrent gastrointestinal bleeding. She was anemic with a hemoglobin of 8.0 g/dL. As a source of bleeding, CV were identified. Computed tomography scans revealed thrombotic occlusion of the splenic vein, presumably as a result of a severe acute pancreatitis 8 years prior. In a selective angiography, a dilated mesenteric collateral leading from the spleen to enlarged vessels in the right colonic flexure and draining into the superior mesenteric vein could be confirmed. The hepatic venous pressure gradient was within normal range. In an interdisciplinary board, transhepatic recanalization of the splenic vein *via* balloon dilatation and consecutive stenting, as well as coiling of the aberrant veins was discussed and successfully performed. Consecutive evaluation revealed complete regression of CV and splenomegaly as well as normalization of the red blood cell count during follow-up.

#### CONCLUSION

Recanalization and stenting of splenic vein thrombosis might be considered in

patients with gastrointestinal bleeding due to CV. However, a multidisciplinary approach with a thorough workup and discussion of individualized therapeutic strategies is crucial in these difficult to treat patients.

**Key Words:** Pancreatitis-induced splenic vein thrombosis; Gastrointestinal hemorrhage; Colonic varices; Splenic vein stenting; Segmental/sinistral hypertension; Case report

©The Author(s) 2023. Published by Baishideng Publishing Group Inc. All rights reserved.

**Core Tip:** Splenic vein thrombosis (SVT) is a complication of pancreatitis and can lead to development of varices with a high risk of gastrointestinal bleeding. While clear guidelines are lacking, splenectomy or splenic artery embolization are often employed. We present a rare case of recurrently bleeding colonic varices (CV) due to pancreatitis-induced (PI) SVT. In an interdisciplinary board, transhepatic recanalization of the splenic vein and consecutive stenting, as well as coiling of aberrant veins was decided and successfully performed. Follow-up revealed complete regression of varices. According to our knowledge, there is no case report in English literature describing stenting of PISVT in a patient with CV.

**Citation:** Füssel LM, Müller-Wille R, Dinkhauser P, Schauer W, Hofer H. Treatment of colonic varices and gastrointestinal bleeding by recanalization and stenting of splenic-vein-thrombosis: A case report and literature review. *World J Gastroenterol* 2023; 29(24): 3922-3931

**URL:** <https://www.wjgnet.com/1007-9327/full/v29/i24/3922.htm>

**DOI:** <https://dx.doi.org/10.3748/wjg.v29.i24.3922>

## INTRODUCTION

Gastrointestinal bleeding due to colonic varices (CV) is rare but can be severe[1,2]. CV may be caused by thrombosis of the splenic vein. In our patient this was due to an episode of acute pancreatitis. Moreover, treatment is challenging, and a multidisciplinary individualized approach is warranted in these patients. Cases are rare and clear guidelines for management are lacking, as the available data is heterogeneous and case numbers for interventional recanalization are low. Therefore, we present a patient with CV due to pancreatitis-induced splenic vein thrombosis (PISVT) and summarize the clinical features, treatment options and available data in the current literature.

### SVT

The splenic vein is located at the posterior surface of the pancreas and is fed by tributaries from the spleen, the inferior mesenteric vein, the short gastric veins, the left gastroepiploic vein and pancreatic veins[2]. Isolated obstruction can occur as a result of external compression due to malignancy, retroperitoneal disease or splenic artery aneurysms[2,3]. In addition, SVT can be associated with a variety of diseases shown in Table 1[2,4,5].

### PISVT

The predominant cause in approximately 50%-60% of isolated SVT is acute or chronic pancreatitis[5,6]. While Butler *et al*[7] yielded an overall incidence of PISVT of 14.1% in patients with pancreatitis (22.6% in acute and 12.4% in chronic pancreatitis), a meta-analysis including over 10000 patients reported the pooled prevalence of SVT in pancreatitis to be as high as 11.2%[7,8]. Thrombosis is a consequence of the associated inflammatory process of the pancreas, fostered by endothelial damage, the release of prothrombotic cytokines and vein compression due to edema, lymphadenopathy or pseudocysts causing stasis of blood flow[6]. However, it is still unclear if the risk of thrombosis correlates with the severity of pancreatitis[2,8]. Since PISVT is mainly diagnosed after the acute phase, recurrent indolent episodes of pancreatitis could play a major role in its development[6]. The diagnosis can be challenging as the accuracy of doppler sonography to diagnose SVT is low due to the small size, the location of the splenic vein and the presence of adjacent collaterals[6]. In addition, the incidence of compensatory splenomegaly in SVT was reported at 51.9%, rendering it unreliable for diagnosis[8]. Additionally, D-dimer levels can be elevated in SVT, but are also unspecific[4]. The diagnostic test of choice to assess the presence of SVT is late-phase celiac angiography [computed tomography (CT) or magnetic resonance imaging][6]. Ultimately, the gold standard to confirm SVT is selective angiography of the splenic artery with lacking drainage *via* the splenic vein[6]. Clinical symptoms of SVT are nonspecific and include abdominal pain and nausea[4]. Historically, patients with SVT were commonly described to present with acute bleeding, thereby overestimating the risk for hemorrhage, which has since been thought to

**Table 1 Possible etiologies of splenic vein thrombosis[2,4,5]**

|                                  |  |
|----------------------------------|--|
| Pancreatic diseases <sup>1</sup> | Carcinoma                                      |
|                                  | All forms of pancreatitis                      |
|                                  | Pseudocysts                                    |
|                                  | Abscess  |
|                                  | Pancreas divisum                               |
| Liver diseases                   | Liver cirrhosis                                |
|                                  | Budd-Chiari syndrome                           |
| Coagulation disorders            | Thrombocythemia                                |
|                                  | Deficiency of antithrombin III, Protein S or C |
|                                  | Antiphospholipid syndrome                      |
|                                  | Mutation of factor V                           |
|                                  | Myeloproliferative disorders                   |
| Inflammatory disorders           | Autoimmune disease                             |
|                                  | Inflammatory bowel disease                     |
|                                  | Intraabdominal inflammation                    |
| Others                           | Prior abdominal surgery                        |
|                                  | Hormonal therapy                               |
|                                  | Paroxysmal nocturnal hemoglobinuria            |
|                                  | Bechet's disease                               |
|                                  | Retroperitoneal fibrosis                       |
|                                  | Tuberculous adenitis                           |

<sup>1</sup>Most common due to local proximity.

be about 4%-17%[9,10]. Due to a broader availability and improvement of imaging, at present the majority of cases are diagnosed at an asymptomatic state[8].

### Segmental Hypertension

PISVT can lead to increased blood flow through splenoportal, gastroepiploic or mesenteric collaterals creating a localized form of venous hypertension referred to as “segmental”, “sinistral” or “linear hypertension”[8]. This results in the development of varices in the area decompressing the corresponding segment and entails an increased risk of severe hemorrhage[2]. Frequently, the short gastric veins collateralize through portosystemic esophageal veins to the azygos system leading to esophageal varices[11]. Other pathways decompress the short gastric veins *via* the coronary vein into the portal vein or *via* the gastroepiploic arcade into the vena mesenterica superior creating gastric varices[11]. Another path runs along the left gastroepiploic vein to the left colic and inferior mesenteric vein[11]. Furthermore, collateral channels along intercostal and diaphragmatic veins draining into the vena cava inferior and a pathway *via* the adrenal vein into the renal vein have been described[11]. Segmental hypertension occurred in 12.5% in acute pancreatitis and in 2.7% in chronic pancreatitis[10,12]. Identified risk factors for the development of PISVT in pancreatitis were smoking, alcohol consumption, hypertriglyceridemia, diabetes, recurrent acute pancreatitis, infection of necrosis and pseudocysts[10,12]. Gastrointestinal varices are found in 53% of PISVT and are gastric in the majority (77.3%) of cases[8]. This is especially relevant as the rate of bleeding in patients with PISVT was reported to be 12.3%[8]. In case of varices the bleeding rate was at 19.1% and seemed to be higher in alcoholic than in non-alcoholic pancreatitis[12,13].

### CV

CV associated with PISVT are very rare, data is scarce and only a few case reports exist[1,14-17]. In these cases, splenectomy was performed to manage bleeding and decompress the varices. The incidence rate of CV in general is estimated at 0.07%[3,18]. Causes of CV include liver cirrhosis (as the most frequent etiology), congestive heart failure, porto-mesenteric thrombosis, post-operative adhesions, inherited vascular anomalies (*e.g.*, Klippel-Trenaunay-Weber syndrome) and idiopathic varices[18,19]. Diagnosis

is primarily established *via* colonoscopy, although selective mesenteric angiography is the gold standard, as varices can be missed when flattened with insufflation and in hypotensive patients, especially if active bleeding is present[3]. Ectopic varices are reported to be more prone to bleeding and can have a mortality rate as high as 40%[20]. CV are rarer than small bowel and rectal varices; in one recent study only 3.5% of ectopic varices were situated in the colon[18,21].

## CASE PRESENTATION

### Chief complaints

We present a 45-year-old female who was admitted to the hospital due to recurrent hematochezia.

### History of present illness

She denied abdominal pain, weight loss, fever or night sweats and there was no history of malignancy or inflammatory bowel disease.

### History of past illness

Patient history included alcohol misuse, bipolar disorder, arterial hypertension, cholecystolithiasis, pancreatic insufficiency and an episode of severe acute pancreatitis 8 years prior, which required intensive care treatment.

### Personal and family history

Family history for gastrointestinal disease, tumor or bleeding was negative.

### Physical examination

On presentation, abdominal examination was unremarkable and vital signs were stable.

### Laboratory examinations

Blood work showed anemia with a hemoglobin of 8 g/dL (12-15.4 g/dL), a mean corpuscular volume of 70 fL (80-99 fL) and a mean corpuscular hemoglobin of 22 pg (27-33.5 pg) while coagulation parameters were within normal range.

### Imaging examinations

Gastroscopy revealed reflux esophagitis of grade A and a mild duodenitis. There was no evidence for varices or ulcers. During colonoscopy, largely dilated and tortuous varices spreading from the right transverse colon to just underneath the right colonic flexure were diagnosed (Figure 1). There was no active bleeding. A CT angiography confirmed an extensive venous convolute at the right colonic flexure and evidenced an aberrant mesenteric collateral coming from the splenic hilum as its feeding vein (Figure 2). The varices' draining vein could be identified and lead to the superior mesenteric vein. In addition, splenomegaly (15 cm) and thrombotic occlusion of the splenic vein were diagnosed, while the portal vein and superior mesenteric vein were perfused regularly.

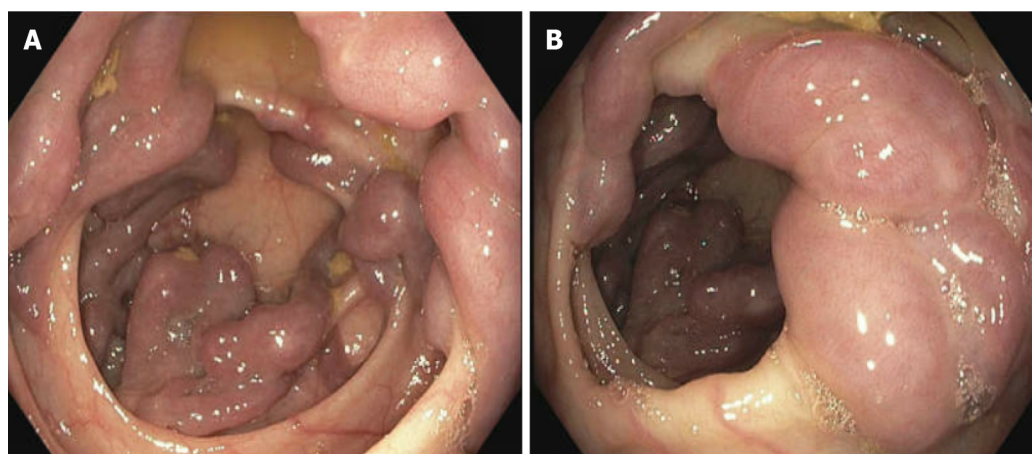
Selective angiography of the spleen *via* the femoral artery observed a long-segment occlusion of the splenic vein up to the confluence of the portal vein. It confirmed the findings of the CT angiography and noted that almost the entire venous drainage of the spleen occurred *via* mesenteric collaterals (Figure 2). Simultaneously, an arterio-portal fistula was ruled out. There was no evidence of liver cirrhosis or portal hypertension. Laboratory investigations showed transaminases, albumin and coagulation parameters within normal range. Platelets were slightly decreased due to splenomegaly. Transient elastography showed a value of 7.5 kPa and the hepatic venous pressure gradient was normal (3 mmHg).

## FINAL DIAGNOSIS

Presumably, the splenic vein thrombosis was a result of the reported acute severe pancreatitis 8 years prior. Consequently, we postulated that PISVT prompted the formation of collaterals which lead to CV and gastrointestinal bleeding.

## TREATMENT

In an interdisciplinary board, interventional transhepatic recanalization of the splenic vein *via* balloon dilatation and consecutive stenting, as well as coiling of the aberrant mesenteric veins under general anesthesia was planned. The splenic artery was cannulated *via* the femoral artery and a microcatheter was used to reach the splenic hilum and monitor venous drainage during the procedure (Figure 3A).



DOI: 10.3748/wjg.v29.i24.3922 Copyright ©The Author(s) 2023.

**Figure 1 Dilated and tortuous colonic varices on endoscopy without active bleeding.** A: Right transverse colon; B: Right colonic flexure.

Subsequently, right portal vein access was obtained transhepatically, a 6-French vascular sheath (Biotronik®, Berlin, Germany) was placed and a contrast venogram showed the expected occlusion of the splenic vein measuring 8 cm (Figure 3B and C). The aberrant vein feeding the varices was contrasted (Figure 3D). The obstructed vein was successfully cannulated using a 5-MP catheter and a Progreat-microcatheter (Terumo Interventional Systems, Somerset, NJ, United States). After crossing the occlusion, balloon angioplasty with a 3 mm × 12 mm and a 5 mm × 40 mm percutaneous transluminal angioplasty balloon was performed and was followed by deployment of two overlapping stentgrafts (8 mm × 57mm and 8 mm × 37 mm, BeGraft, Bentley), achieving successful recanalization of the splenic vein (Figure 3E and F). A follow-up venography confirmed restoration of antegrade flow. Afterwards, the dilated mesenteric collateral vein leading from the splenic hilum to the colon was cannulated *via* stentgrafts and a distal and proximal embolization by the deployment of multiple coils (Boston Scientific Interlock®, Marlborough, MA, United States) was performed (Figure 3G). A small gastral aberrant vein was also coiled. Follow-up angiography demonstrated patent stentgrafts allowing complete drainage of the spleen through the splenic vein (Figure 3H). The transhepatic access tract was occluded by means of gelfoam slurry (EmboCubes®; Merit Medical, South Jordan, UT, United States) and the femoral access using AngioSeal® (Terumo Interventional Systems).

## OUTCOME AND FOLLOW-UP

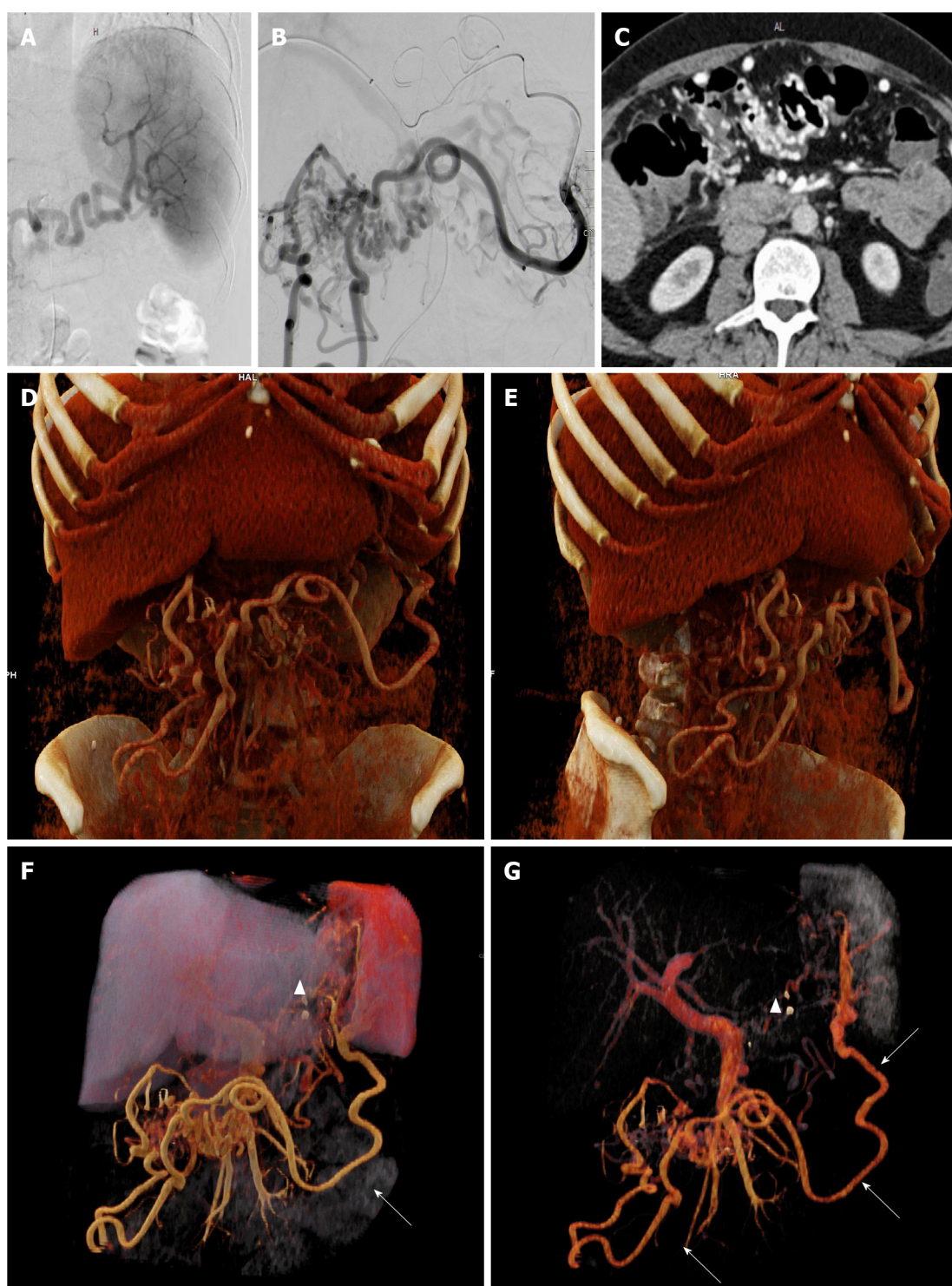
A consecutive Doppler examination revealed antegrade perfusion of the splenic vein and regression of splenomegaly (1 d post-recanalization 15 cm, after 4 d 13 cm). At follow-up 2 mo later, lab results found a normalization of red blood cell count (hemoglobin 12.1 g/dL) and a colonoscopy confirmed drastic regression of CV with few residual veins in the right colonic flexure (Figure 4A). One year post-intervention, hemoglobin was at 13.2 g/dL, the spleen measured 11.5 cm, the splenic vein stent was patent with orthograde perfusion on duplex sonography and residual veins had completely disappeared (Figure 4B).

## DISCUSSION

Gastrointestinal bleeding due to CV caused by PISVT is rare and difficult to treat[1,14-17]. Time from the onset of pancreatitis to the detection of SVT is highly variable ranging between 10 d and 9 years[10]. In our patient, there was an 8 year gap between the episode of pancreatitis and diagnosis of PISVT.

Due to limited data, clear guidelines for the treatment of CV are lacking. The use of non-selective beta-blockers for bleeding prophylaxis has been recommended with a low quality of evidence[22,23]. Conservative treatment also includes iron supplements and avoiding constipation[24]. The use of anticoagulation (AC) in chronic SVT with collaterals is controversial and dependent on etiology, risk of recurrence, progression and hemorrhage[5]. Considering the low rate of recanalization as well as the substantial bleeding risk if varices are present, an individualized risk assessment is necessary[4,5,10]. In our case, AC was not viable due to ongoing intermittent bleeding. However, our patient had suffered from acute pancreatitis previously and AC might be beneficial in acute pancreatitis to avoid SVT[25]. In acute pancreatitis and PISVT, data on AC are conflicting regarding recanalization and bleeding rate[10, 26-28].

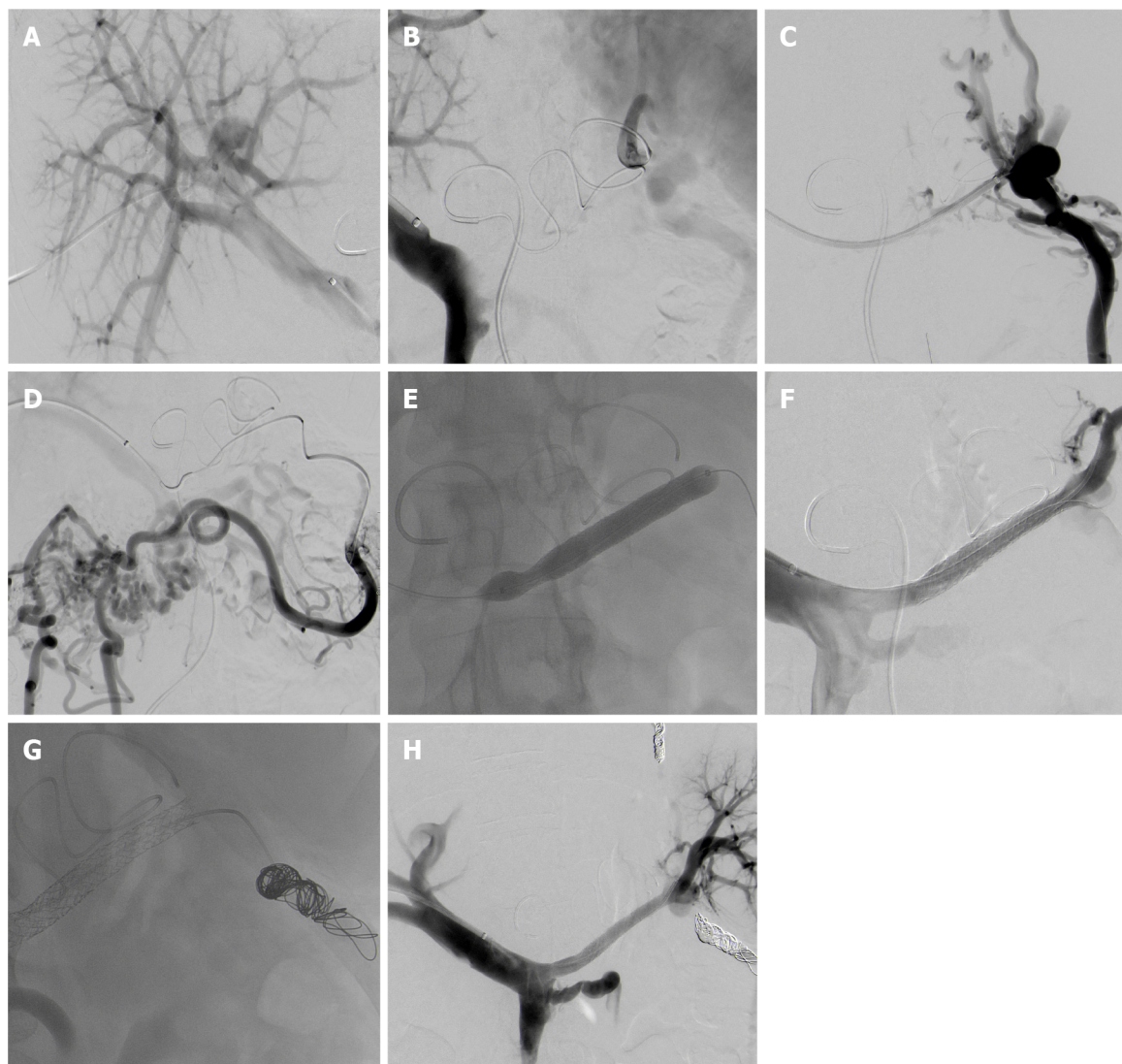




DOI: 10.3748/wjg.v29.i24.3922 Copyright ©The Author(s) 2023.

**Figure 2 Angiography images and computed tomography images.** A: Angiography of splenic artery; B: Angiography of the mesenteric vein draining the spleen; C: Computed tomography (CT)-angiography showing colonic varices; D-G: 3D-Reconstruction of CT imaging. 3D-Reconstruction with the thrombosis of the splenic vein (arrowhead) and collateral vessels to the colon indicated by arrows.

Endoscopic therapies such as variceal ligation, injection of cyanoacrylate or sclerotherapy may be performed for bleeding control in localized varices, but success depends on the location and expansion of the varices[2,18,23]. In addition, these techniques do not treat the underlying cause, thereby resulting in high re-bleeding rates[2,23]. In the setting of portal hypertension, transjugular intrahepatic portosystemic shunt (TIPS) is an option and achieved 100% initial hemostasis in ectopic variceal bleeding, with a subsequent re-bleeding rate of 21%[29]. Nevertheless, TIPS is not expedient in segmental hypertension when portal pressure and hepatic function are normal[2,23]. Another option to manage CV is embolization of the feeding veins[23,29]. Complications are rare and include post-embolization syndrome, infection, vessel injury and thromboembolism[30]. Embolization represents



DOI: 10.3748/wjg.v29.i24.3922 Copyright ©The Author(s) 2023.

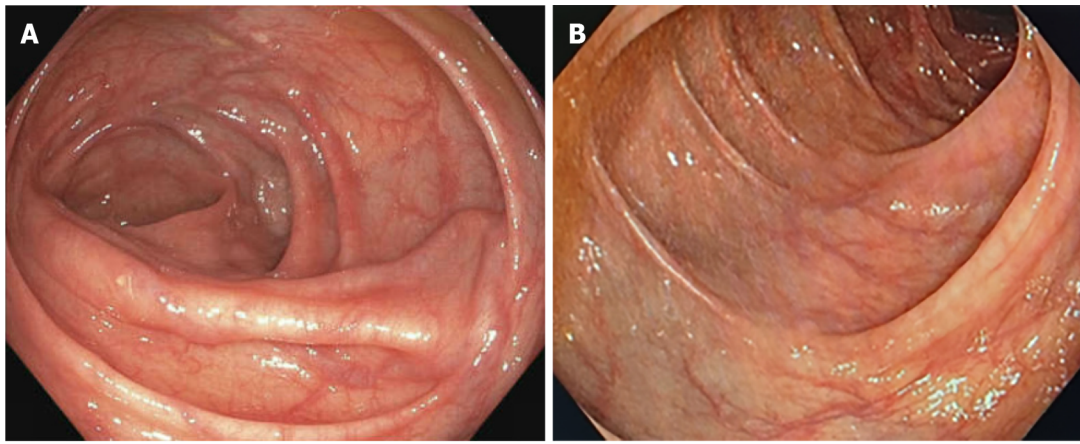
**Figure 3 Angiography images.** A: Right portal vein access; B: Simultaneously performed direct portography and indirect mesentericography via the splenic artery showing complete obstruction of the splenic vein; C: Successful cannulation of the obstructed splenic vein (SV); D: Phlebography of the colonic varices (CV) arising from the splenic hilum; E: Recanalization of the SV using balloon and stentgrafts; F: Successful recanalization of the SV; G: Coiling of the aberrant vein feeding the CV; H: Patent stentgraft with drainage of the spleen through the splenic vein.

another short-term therapy with a high rate of successful bleeding control, but does not influence portal pressure, thus entailing high re-bleeding rates[23].

Surgical treatment, as for example, colon resection, can be required in cases of uncontrolled bleeding or when extensive varices are present[24]. Surgical devascularization, shunt procedures or other local therapy depending on the underlying etiology have been reported[23,29]. Historically, the surgical treatment of choice for PISVT is splenectomy, which eliminates the collateral outflow[6,31]. In patients with hemorrhage unresponsive to conservative management or a history of bleeding, it is still the treatment of choice[2]. However, considering the reported lack of progression and rarity of hemorrhage in patients with asymptomatic varices, as well as operative risk, risk of postoperative infection and portal vein thrombosis, “prophylactic splenectomy” in patients without evidence of bleeding remains controversial[2,6,11,31]. Splenic artery embolization (SAE) resulting in splenic infarction represents an option, although the risk of splenic abscess and intervention associated morbidity is considerable[2,6].

Reports on splenic vein recanalization and thereby minimizing blood flow to collaterals in segmental hypertension are scarce[11]. A retrospective study of endovascular splenic vein recanalization in patients with SVT by a transjugular approach achieved success in 8 of 11 cases[32]. Another study reported effective splenic vein stenting in 3 patients using a transhepatic approach[33]. Recently, Liu *et al*[34] compared 9 patients with splenic vein stenting, 12 cases of splenectomy and 12 patients with conservative treatment in PISVT and there were no recurrent bleeding or major complications in the interventional group[34]. Stent patency was 100% and PISVT receded significantly[34]. Furthermore, a retrospective analysis comparing splenic vein stenting and SAE in SVT related bleeding found significantly less re-bleeding in the recanalization group[35].





DOI: 10.3748/wjg.v29.i24.3922 Copyright ©The Author(s) 2023.

**Figure 4** Follow-up colonoscopy. A: Right colonic flexure 2 mo after intervention; B: Transverse colon 1 year after intervention.

In our patient, endoscopic treatment and TIPS were not viable options due to the localization, size and extension of the varices and absence of portal hypertension. Embolization alone, balloon-occluded retrograde transvenous obliteration (commonly referred to as BROTO) or segmental colonic resection were considered as short-term options, but were unlikely to prevent future bleeding because of potential collateral development. Moreover, splenectomy to alleviate the segmental hypertension was discussed, but as the patient was stable and preferred a less invasive alternative, we opted to perform transhepatic recanalization of the splenic vein and consecutive stenting, as well as coiling of the feeding veins. Splenic vein stenting has been shown to be a safe option[32,33]. According to our knowledge, there is no case report in the English literature describing recanalization and stenting of PISVT in a patient with CV. We found two case reports using recanalization and stenting in superior mesenteric vein thrombosis – one in hepatitis with CV and one in PISVT and associated duodenal varices with excellent results[18,36]. Also, there is a case report of successful splenic vein stenting in PISVT with gastric varices[11]. In the current case, we describe a successful transhepatic endovascular recanalization and stenting of a fully occluded splenic vein and embolization of aberrant veins in the setting of PISVT and CV with gastrointestinal bleeding. It can be argued, that coiling of the dilated aberrant veins leads to faster recompensation but may increase risk of splenic rupture in acute stent failure[35].

## CONCLUSION

In summary, splenic vein recanalization seems to be an effective and safe procedure to resolve variceal complications in PISVT. An interdisciplinary discussion of potential therapeutic options is crucial as the available experience is important and an individualized approach to these patients is mandatory.

## FOOTNOTES

**Author contributions:** Füssel LM and Hofer H performed the research and drafting of the manuscript; Dinkhauser P, Müller-Wille R and Schauer W did a critical revision of the manuscript for important intellectual content; Füssel LM and Müller-Wille R performed image editing; All authors have read and approved the final manuscript.

**Informed consent statement:** Informed written consent was obtained from the patient for publication of this report and any accompanying images.

**Conflict-of-interest statement:** All the authors report having no relevant conflicts of interest for this article.

**CARE Checklist (2016) statement:** The authors have read CARE Checklist (2016), and the manuscript was prepared and revised according to CARE Checklist (2016).

**Open-Access:** This article is an open-access article that was selected by an in-house editor and fully peer-reviewed by external reviewers. It is distributed in accordance with the Creative Commons Attribution NonCommercial (CC BY-NC 4.0) license, which permits others to distribute, remix, adapt, build upon this work non-commercially, and license their derivative works on different terms, provided the original work is properly cited and the use is non-commercial. See: <https://creativecommons.org/licenses/by-nc/4.0/>

**Country/Territory of origin:** Austria

**ORCID number:** Lisa-Michaela Füssel 0000-0003-2928-6738; Rene Müller-Wille 0000-0003-3437-2817; Patrick Dinkhauser 0000-0003-4785-0873; Harald Hofer 0000-0002-2786-7689.

**S-Editor:** Li L

**L-Editor:** Filipodia

**P-Editor:** Li L

## REFERENCES

- 1 **Kitagawa S**, Sato T, Hirayama A. Colonic Varices Due to Chronic Pancreatitis: A Rare Cause of Lower Gastrointestinal Bleeding. *ACG Case Rep J* 2015; **2**: 168-170 [PMID: 26157952 DOI: 10.14309/crj.2015.43]
- 2 **Köklü S**, Coban S, Yüksel O, Arhan M. Left-sided portal hypertension. *Dig Dis Sci* 2007; **52**: 1141-1149 [PMID: 17385040 DOI: 10.1007/s10620-006-9307-x]
- 3 **Dina I**, Braticević CF. Idiopathic colonic varices: case report and review of literature. *Hepat Mon* 2014; **14**: e18916 [PMID: 25147571 DOI: 10.5812/hepatmon.18916]
- 4 **Valeriani E**, Riva N, Di Nisio M, Ageno W. Splanchnic Vein Thrombosis: Current Perspectives. *Vasc Health Risk Manag* 2019; **15**: 449-461 [PMID: 31695400 DOI: 10.2147/VHRM.S197732]
- 5 **Thatipelli MR**, McBane RD, Hodge DO, Wysokinski WE. Survival and recurrence in patients with splanchnic vein thromboses. *Clin Gastroenterol Hepatol* 2010; **8**: 200-205 [PMID: 19782767 DOI: 10.1016/j.cgh.2009.09.019]
- 6 **Weber SM**, Rikkers LF. Splenic vein thrombosis and gastrointestinal bleeding in chronic pancreatitis. *World J Surg* 2003; **27**: 1271-1274 [PMID: 14502405 DOI: 10.1007/s00268-003-7247-6]
- 7 **Butler JR**, Eckert GJ, Zyromski NJ, Leonardi MJ, Lillemoe KD, Howard TJ. Natural history of pancreatitis-induced splenic vein thrombosis: a systematic review and meta-analysis of its incidence and rate of gastrointestinal bleeding. *HPB (Oxford)* 2011; **13**: 839-845 [PMID: 22081918 DOI: 10.1111/j.1477-2574.2011.00375.x]
- 8 **Xu W**, Qi X, Chen J, Su C, Guo X. Prevalence of Splanchnic Vein Thrombosis in Pancreatitis: A Systematic Review and Meta-Analysis of Observational Studies. *Gastroenterol Res Pract* 2015; **2015**: 245460 [PMID: 26451142 DOI: 10.1155/2015/245460]
- 9 **Heider TR**, Azeem S, Galanko JA, Behrns KE. The natural history of pancreatitis-induced splenic vein thrombosis. *Ann Surg* 2004; **239**: 876-80; discussion 880 [PMID: 15166967 DOI: 10.1097/01.sla.0000128685.74686.1e]
- 10 **Li H**, Yang Z, Tian F. Clinical Characteristics and Risk Factors for Sinistral Portal Hypertension Associated with Moderate and Severe Acute Pancreatitis: A Seven-Year Single-Center Retrospective Study. *Med Sci Monit* 2019; **25**: 5969-5976 [PMID: 31400275 DOI: 10.12659/MSM.916192]
- 11 **El Kininy W**, Kearney L, Hosam N, Broe P, Keeling A. Recurrent variceal haemorrhage managed with splenic vein stenting. *Ir J Med Sci* 2017; **186**: 323-327 [PMID: 26911860 DOI: 10.1007/s11845-016-1420-z]
- 12 **Ru N**, He CH, Ren XL, Chen JY, Yu FF, Yan ZJ, Guo JY, Zhu JH, Wang YC, Qian YY, Pan J, Hu LH, Li ZS, Zou WB, Liao Z. Risk factors for sinistral portal hypertension and related variceal bleeding in patients with chronic pancreatitis. *J Dig Dis* 2020; **21**: 468-474 [PMID: 32584511 DOI: 10.1111/1751-2980.12916]
- 13 **Anand A**, Gunjan D, Agarwal S, Kaushal K, Sharma S, Gopi S, Mohta S, Madhusudhan KS, Singh N, Saraya A. Vascular complications of chronic pancreatitis: A tertiary center experience. *Pancreatol* 2020; **20**: 1085-1091 [PMID: 32800648 DOI: 10.1016/j.pan.2020.07.005]
- 14 **Burbige EJ**, Tarder G, Carson S, Eugene J, Frey CF. Colonic varices. A complication of pancreatitis with splenic vein thrombosis. *Am J Dig Dis* 1978; **23**: 752-755 [PMID: 685944 DOI: 10.1007/BF01072365]
- 15 **Alarco HA**, Gómez Rodríguez-Bethencourt MA, Díaz H, Pérez Palma J, Minguiñón A, Bordallo A, González Hermoso F. [Colonic lesion caused by acute pancreatitis. Use of minimal catheter jejunostomy. Apropos of 6 cases]. *Rev Esp Enferm Apar Dig* 1989; **75**: 465-469 [PMID: 2669046]
- 16 **Fraccaso P**, Caviglia R, Grassi A, Lapenta R, Stigliano V, Casole P, Casale V. [Colonic varices secondary to recurrent acute pancreatitis]. *Minerva Gastroenterol Dietol* 1993; **39**: 191-193 [PMID: 8161618]
- 17 **Van Wijngaarden P**, Van der Wiel HE, Tetteroo GW, Bode WA. A patient with gastric fundal varices and colonic varices due to splenic vein thrombosis. *Neth J Med* 1997; **51**: 187-191 [PMID: 9455099 DOI: 10.1016/s0300-2977(97)00062-4]
- 18 **Naffouj S**, Al-Shammari M, Salgia R. Treatment of colonic varices with a superior mesenteric venous stent: a case report describing a unique approach. *Gastroenterol Rep (Oxf)* 2021; **9**: 597-600 [PMID: 34925858 DOI: 10.1093/gastro/goab003]
- 19 **Krishna RP**, Singh RK, Ghoshal UC. Recurrent lower gastrointestinal bleeding from idiopathic ileocolonic varices: a case report. *J Med Case Rep* 2010; **4**: 257 [PMID: 20698946 DOI: 10.1186/1752-1947-4-257]
- 20 **Saad WE**, Lippert A, Saad NE, Caldwell S. Ectopic varices: anatomical classification, hemodynamic classification, and hemodynamic-based management. *Tech Vasc Interv Radiol* 2013; **16**: 158-175 [PMID: 23830673 DOI: 10.1053/j.tvir.2013.02.004]
- 21 **Watanabe N**, Toyonaga A, Kojima S, Takashimizu S, Oho K, Kokubu S, Nakamura K, Hasumi A, Murashima N, Tajiri T. Current status of ectopic varices in Japan: Results of a survey by the Japan Society for Portal Hypertension. *Hepatol Res* 2010; **40**: 763-776 [PMID: 20649816 DOI: 10.1111/j.1872-034X.2010.00690.x]
- 22 **Simonetto DA**, Singal AK, Garcia-Tsao G, Caldwell SH, Ahn J, Kamath PS. ACG Clinical Guideline: Disorders of the Hepatic and Mesenteric Circulation. *Am J Gastroenterol* 2020; **115**: 18-40 [PMID: 31895720 DOI: 10.14309/ajg.0000000000000486]
- 23 **Helmy A**, Al Kahtani K, Al Fadda M. Updates in the pathogenesis, diagnosis and management of ectopic varices. *Hepatol Int* 2008; **2**: 322-334 [PMID: 19669261 DOI: 10.1007/s12072-008-9074-1]

- 24 **Akküçük S**, Aydoğan A, Paltacı İ, Temiz M. Diffuse idiopathic varices in the colon characterized by lower gastrointestinal bleeding. *Ulus Cerrahi Derg* 2014; **30**: 109-111 [PMID: 25931906 DOI: 10.5152/UCD.2014.1814]
- 25 **Zhou J**, Zhang H, Mao W, Ke L, Li G, Ye B, Zhang J, Lin J, Gao L, Tong Z, Li W. Efficacy and Safety of Early Systemic Anticoagulation for Preventing Splanchnic Thrombosis in Acute Necrotizing Pancreatitis. *Pancreas* 2020; **49**: 1220-1224 [PMID: 32898006 DOI: 10.1097/MPA.0000000000001661]
- 26 **Vadlamudi RS**, Matli VVK, Thoguluva Chandrasekar V, Kalakonda A, Rawlins SR. Chemoprophylaxis to Prevent Deep Venous Thrombosis in Patients Hospitalized for Pancreatitis: Beneficial or Harmful? *Cureus* 2021; **13**: e19645 [PMID: 34956767 DOI: 10.7759/cureus.19645]
- 27 **Hajibandeh S**, Hajibandeh S, Agrawal S, Irwin C, Obeidallah R, Subar D. Anticoagulation Versus No Anticoagulation for Splanchnic Venous Thrombosis Secondary to Acute Pancreatitis: Do We Really Need to Treat the Incidental Findings? *Pancreas* 2020; **49**: e84-e85 [PMID: 33003093 DOI: 10.1097/MPA.0000000000001644]
- 28 **Sissingh NJ**, Groen JV, Koole D, Klok FA, Boekstijn B, Bollen TL, van Santvoort HC, Verdonk RC, Bonsing BA, van Eijck CHJ, van Hooft JE, Mieog JSD; Dutch Pancreatitis Study Group. Therapeutic anticoagulation for splanchnic vein thrombosis in acute pancreatitis: A systematic review and meta-analysis. *Pancreatology* 2022; **22**: 235-243 [PMID: 35012902 DOI: 10.1016/j.pan.2021.12.008]
- 29 **Sarin SK**, Kumar CKN. Ectopic varices. *Clin Liver Dis (Hoboken)* 2012; **1**: 167-172 [PMID: 31186880 DOI: 10.1002/cld.95]
- 30 **Ohs Z**, Jones M, Sharma N, Loveridge K. Percutaneous Transhepatic Embolization of Ectopic Varices in a Patient With Portal Hypertension Presenting With Hemorrhagic Shock. *Cureus* 2021; **13**: e18209 [PMID: 34589375 DOI: 10.7759/cureus.18209]
- 31 **Pandey V**, Patil M, Patel R, Chaubal A, Ingle M, Shukla A. Prevalence of splenic vein thrombosis and risk of gastrointestinal bleeding in chronic pancreatitis patients attending a tertiary hospital in western India. *J Family Med Prim Care* 2019; **8**: 818-822 [PMID: 31041207 DOI: 10.4103/jfmpe.jfmpe\_414\_18]
- 32 **Luo X**, Nie L, Wang Z, Tsao J, Tang C, Li X. Transjugular endovascular recanalization of splenic vein in patients with regional portal hypertension complicated by gastrointestinal bleeding. *Cardiovasc Intervent Radiol* 2014; **37**: 108-113 [PMID: 23636249 DOI: 10.1007/s00270-013-0625-z]
- 33 **Stein M**, Link DP. Symptomatic spleno-mesenteric-portal venous thrombosis: recanalization and reconstruction with endovascular stents. *J Vasc Interv Radiol* 1999; **10**: 363-371 [PMID: 10102204 DOI: 10.1016/s1051-0443(99)70044-8]
- 34 **Liu J**, Wang Q, Ding X, Liu Q, Huang W, Gu J, Wang Z, Wu W, Wu Z. The clinical applicability of percutaneous splenic vein stent implantation for pancreatic portal hypertension. *BMC Gastroenterol* 2022; **22**: 136 [PMID: 35337294 DOI: 10.1186/s12876-022-02214-z]
- 35 **Wei B**, Zhang L, Tong H, Wang Z, Wu H. Retrospective Comparison of Clinical Outcomes Following Splenic Vein Stenting and Splenic Arterial Embolization in Sinistral Portal Hypertension-Related Gastrointestinal Bleeding. *AJR Am J Roentgenol* 2021; **216**: 1579-1587 [PMID: 32845712 DOI: 10.2214/AJR.20.23859]
- 36 **Bhat AP**, Davis RM, Bryan WD. A rare case of bleeding duodenal varices from superior mesenteric vein obstruction - treated with transhepatic recanalization and stent placement. *Indian J Radiol Imaging* 2019; **29**: 313-317 [PMID: 31741602 DOI: 10.4103/ijri.IJRI\_21\_19]





Published by **Baishideng Publishing Group Inc**  
7041 Koll Center Parkway, Suite 160, Pleasanton, CA 94566, USA

**Telephone:** +1-925-3991568

**E-mail:** [bpgoffice@wjgnet.com](mailto:bpgoffice@wjgnet.com)

**Help Desk:** <https://www.f6publishing.com/helpdesk>

<https://www.wjgnet.com>

