

World Journal of *Gastroenterology*

World J Gastroenterol 2023 January 21; 29(3): 413-581



REVIEW

- 413** Salvage locoregional therapies for recurrent hepatocellular carcinoma
Criss CR, Makary MS
- 425** COVID-19 and hepatic injury: cellular and molecular mechanisms in diverse liver cells
Ali FEM, Abd El-Aziz MK, Ali MM, Ghogar OM, Bakr AG
- 450** Seronegative spondyloarthropathy-associated inflammatory bowel disease
Wang CR, Tsai HW
- 469** Review of ferroptosis in colorectal cancer: Friends or foes?
Wu Z, Fang ZX, Hou YY, Wu BX, Deng Y, Wu HT, Liu J

MINIREVIEWS

- 487** Clinical implications of COVID-19 in patients with metabolic-associated fatty liver disease
Jeeyavudeen MS, Chaudhari R, Pappachan JM, Fouda S
- 503** Potential role of the microbiome in liver injury during COVID-19: Further research is needed
Tovani-Palone MR, Pedersini P
- 508** Artificial intelligence and inflammatory bowel disease: Where are we going?
Da Rio L, Spadaccini M, Parigi TL, Gabbiadini R, Dal Buono A, Busacca A, Maselli R, Fugazza A, Colombo M, Carrara S, Franchellucci G, Alfarone L, Facciorusso A, Hassan C, Repici A, Armuzzi A
- 521** Role of advanced imaging techniques in the evaluation of oncological therapies in patients with colorectal liver metastases
Caruso M, Stanzione A, Prinster A, Pizzuti LM, Brunetti A, Maurea S, Mainenti PP

ORIGINAL ARTICLE

Retrospective Study

- 536** Magnetic resonance imaging-based deep learning model to predict multiple firings in double-stapled colorectal anastomosis
Cai ZH, Zhang Q, Fu ZW, Fingerhut A, Tan JW, Zang L, Dong F, Li SC, Wang SL, Ma JJ

SYSTEMATIC REVIEWS

- 549** Metabolic dysfunction associated fatty liver disease: The new nomenclature and its impact
Tang SY, Tan JS, Pang XZ, Lee GH

CASE REPORT

- 561** Small intestinal angiosarcoma on clinical presentation, diagnosis, management and prognosis: A case report and review of the literature

Ma XM, Yang BS, Yang Y, Wu GZ, Li YW, Yu X, Ma XL, Wang YP, Hou XD, Guo QH

LETTER TO THE EDITOR

- 579** Discussion on gemcitabine combined with targeted drugs in the treatment of pancreatic cancer

Huang JH, Guo W, Liu Z

ABOUT COVER

Editorial Board Member of *World Journal of Gastroenterology*, Dmitry S Bordin, MD, PhD, Chief Doctor, Professor, Department of Pancreatic, Biliary and Upper GI Tract Diseases, A.S. Loginov Moscow Clinical Scientific Center, Moscow 111123, Russia. dmitrybordin@gmail.com

AIMS AND SCOPE

The primary aim of *World Journal of Gastroenterology* (WJG, *World J Gastroenterol*) is to provide scholars and readers from various fields of gastroenterology and hepatology with a platform to publish high-quality basic and clinical research articles and communicate their research findings online. WJG mainly publishes articles reporting research results and findings obtained in the field of gastroenterology and hepatology and covering a wide range of topics including gastroenterology, hepatology, gastrointestinal endoscopy, gastrointestinal surgery, gastrointestinal oncology, and pediatric gastroenterology.

INDEXING/ABSTRACTING

The WJG is now abstracted and indexed in Science Citation Index Expanded (SCIE, also known as SciSearch®), Current Contents/Clinical Medicine, Journal Citation Reports, Index Medicus, MEDLINE, PubMed, PubMed Central, Scopus, Reference Citation Analysis, China National Knowledge Infrastructure, China Science and Technology Journal Database, and Superstar Journals Database. The 2022 edition of Journal Citation Reports® cites the 2021 impact factor (IF) for WJG as 5.374; IF without journal self cites: 5.187; 5-year IF: 5.715; Journal Citation Indicator: 0.84; Ranking: 31 among 93 journals in gastroenterology and hepatology; and Quartile category: Q2. The WJG's CiteScore for 2021 is 8.1 and Scopus CiteScore rank 2021: Gastroenterology is 18/149.

RESPONSIBLE EDITORS FOR THIS ISSUE

Production Editor: Yi-Xuan Cai; Production Department Director: Xiang Li; Editorial Office Director: Jia-Ru Fan.

NAME OF JOURNAL

World Journal of Gastroenterology

ISSN

ISSN 1007-9327 (print) ISSN 2219-2840 (online)

LAUNCH DATE

October 1, 1995

FREQUENCY

Weekly

EDITORS-IN-CHIEF

Andrzej S Tarnawski

EDITORIAL BOARD MEMBERS

<http://www.wjgnet.com/1007-9327/editorialboard.htm>

PUBLICATION DATE

January 21, 2023

COPYRIGHT

© 2023 Baishideng Publishing Group Inc

INSTRUCTIONS TO AUTHORS

<https://www.wjgnet.com/bpg/gerinfo/204>

GUIDELINES FOR ETHICS DOCUMENTS

<https://www.wjgnet.com/bpg/GerInfo/287>

GUIDELINES FOR NON-NATIVE SPEAKERS OF ENGLISH

<https://www.wjgnet.com/bpg/gerinfo/240>

PUBLICATION ETHICS

<https://www.wjgnet.com/bpg/GerInfo/288>

PUBLICATION MISCONDUCT

<https://www.wjgnet.com/bpg/gerinfo/208>

ARTICLE PROCESSING CHARGE

<https://www.wjgnet.com/bpg/gerinfo/242>

STEPS FOR SUBMITTING MANUSCRIPTS

<https://www.wjgnet.com/bpg/GerInfo/239>

ONLINE SUBMISSION

<https://www.f6publishing.com>



Small intestinal angiosarcoma on clinical presentation, diagnosis, management and prognosis: A case report and review of the literature

Xiao-Mei Ma, Bao-Shun Yang, Yuan Yang, Guo-Zhi Wu, Ying-Wen Li, Xiao Yu, Xiao-Li Ma, Yu-Ping Wang, Xu-Dong Hou, Qing-Hong Guo

Specialty type: Oncology

Provenance and peer review:

Unsolicited article; Externally peer reviewed.

Peer-review model: Single blind

Peer-review report's scientific quality classification

Grade A (Excellent): 0

Grade B (Very good): B, B, B

Grade C (Good): 0

Grade D (Fair): 0

Grade E (Poor): 0

P-Reviewer: Martino A, Italy;

Thongon N, Thailand; Zhai JF, China

Received: November 11, 2022

Peer-review started: November 11, 2022

First decision: November 24, 2022

Revised: December 3, 2022

Accepted: December 23, 2022

Article in press: December 23, 2022

Published online: January 21, 2023



Xiao-Mei Ma, Yuan Yang, Guo-Zhi Wu, Ying-Wen Li, Xiao Yu, Xiao-Li Ma, Yu-Ping Wang, Qing-Hong Guo, Department of Gastroenterology, The First Hospital of Lanzhou University, Lanzhou 730000, Gansu Province, China

Xiao-Mei Ma, Yuan Yang, Guo-Zhi Wu, Ying-Wen Li, Xiao Yu, Xiao-Li Ma, The First Clinical Medical College, Lanzhou University, Lanzhou 730000, Gansu Province, China

Bao-Shun Yang, Xu-Dong Hou, General Surgery Ward 5, The First Hospital of Lanzhou University, Lanzhou 730000, Gansu Province, China

Corresponding author: Qing-Hong Guo, PhD, Chief Physician, Department of Gastroenterology, The First Hospital of Lanzhou University, No. 1 Donggang West Road, Chengguan District, Lanzhou 730000, Gansu Province, China. gqh@lzu.edu.cn

Abstract

BACKGROUND

Angiosarcoma is a highly malignant soft-tissue sarcoma derived from vascular endothelial cells that mainly occurs in the skin and subcutaneous tissues. Small-intestinal angiosarcomas are rare, and the prognosis is poor.

CASE SUMMARY

We reported a case of primary multifocal ileal angiosarcoma and analyze previously reported cases to improve our understanding of small intestinal angiosarcoma. Small intestinal angiosarcoma is more common in elderly and male patients. Gastrointestinal bleeding, anemia, abdominal pain, weakness, and weight loss were the common symptoms. CD31, CD34, factor VIII-related antigen, ETS-related gene, friend leukemia integration 1, and von Willebrand factor are valuable immunohistochemical markers for the diagnosis of small-intestinal angiosarcoma. Small-intestinal angiosarcoma most commonly occurs in the jejunum, followed by the ileum and duodenum. Radiation and toxicant exposure are risk factors for angiosarcoma. After a definite diagnosis, the mean and median survival time was 8 mo and 3 mo, respectively. Kaplan-Meier survival analysis showed that age, infiltration depth, chemotherapy, and the number of small intestinal segments invaded by tumor lesions were prognostic factors for small intestinal angiosarcoma. Multivariate Cox regression analysis showed that

chemotherapy and surgery significantly improved patient prognosis.

CONCLUSION

Angiosarcoma should be considered for unexplained melena and abdominal pain, especially in older men and patients with a history of radiation exposure. Prompt treatment, including surgery and adjuvant chemotherapy, is essential to prolonging patient survival.

Key Words: Angiosarcoma; Small intestine; Pathological features; Diagnosis; Prognosis; Case report

©The Author(s) 2023. Published by Baishideng Publishing Group Inc. All rights reserved.

Core Tip: Small intestinal angiosarcoma is a rare malignant soft tissue tumor. We report a primary multifocal ileal angiosarcoma with metastases to the adrenal gland and lumbar spine. The patient died 4 mo after surgical resection. Further, we collected relevant case reports and analyzed statistically. We concluded that small intestinal angiosarcoma tend to occur in elderly men. Melena and anemia were the most common symptoms. The diagnosis depended on microscopic morphology and immunohistochemistry. CD31, CD34, factor VIII-related antigen, ETS-related gene, friend leukemia integration 1, and von Willebrand factor were valuable diagnostic markers. Surgery and chemotherapy could improve the prognosis of patients.

Citation: Ma XM, Yang BS, Yang Y, Wu GZ, Li YW, Yu X, Ma XL, Wang YP, Hou XD, Guo QH. Small intestinal angiosarcoma on clinical presentation, diagnosis, management and prognosis: A case report and review of the literature. *World J Gastroenterol* 2023; 29(3): 561-578

URL: <https://www.wjgnet.com/1007-9327/full/v29/i3/561.htm>

DOI: <https://dx.doi.org/10.3748/wjg.v29.i3.561>

INTRODUCTION

Angiosarcoma is a rare malignant mesenchymal sarcoma that arises from vascular or lymphatic endothelial cells and accounts for only 1%-2% of all soft tissue sarcomas[1]. Angiosarcoma can invade any location in the body due to the widespread distribution of the blood and lymphatic systems[2]. Angiosarcoma has skin, visceral, and soft tissue subtypes, with visceral angiosarcoma accountings for 15%-47% and being more challenging to diagnose than the other subtypes[3]. Small intestinal angiosarcoma has a low incidence and presents with atypical abdominal pain, weight loss, nausea, vomiting, and gastrointestinal bleeding[4]. Various factors, including trauma, vinyl chloride, and radiation, have been implicated in the development of angiosarcoma. However, morbidity following exposure to these risk factors is rare. For example, a previous follow-up study showed that the overall risk of angiosarcoma after radiotherapy ranged from 0.01%-0.30%[5]. Timely diagnosis of small intestinal angiosarcoma is challenging owing to the diversity and non-specificity of the clinical symptoms, signs, and limited diagnostic methods, resulting in poor prognosis[6].

In this study, we report a case of primary small-intestinal angiosarcoma with lumbar and bilateral adrenal metastases. Furthermore, we retrospectively analyzed previously reported cases to explore the clinicopathological factors, diagnosis, treatment, and prognosis of small-intestinal angiosarcoma to further optimize the management and treatment of the disease.

CASE PRESENTATION

Chief complaints

A 70-year-old Chinese man presented with abdominal pain and melena for 4 mo.

History of present illness

The patient's symptoms had started four months earlier, accompanied by distension, constipation, poor appetite. There was no apparent cause. The patient had lost 15 kg.

History of past illness

The patient had a history of hypertension but no history of abdominal surgery, toxicity, or radiation exposure.

Personal and family history

The patient denied any family history of malignant tumors.

Physical examination

Physical examination revealed a chronically ill man. In addition, his abdomen was mildly swollen, with tenderness around the navel.

Laboratory examinations

Laboratory data revealed hemoglobin, hematocrit, and C-reactive protein levels of 10.1 g/dL, 30.8%, and 17.18 mg/L, respectively. The tumor marker levels were not elevated.

Imaging examinations

Electron gastroscopy and colonoscopy revealed no abnormalities. Computed tomography (CT) revealed that the part of the lower abdominal intestinal wall was significantly thickened with different degrees of enhancement in the arterial phase. In addition, bilateral adrenal masses and multiple soft-tissue nodules were noted in the right perirenal fascia (Figure 1). Magnetic resonance imaging (MRI) showed local abnormally enhanced nodules in the cauda equina at the L1/L2 Level; thus, metastasis was considered. Moreover, multiple nodules with abnormal signals in the bilateral adrenal area and right kidney were apparent, also leading to the consideration of metastasis (Figure 2). Electron enteroscopy revealed continuous periannulus ulcers 2.4-2.5 m above the ileocecal valve (Figure 3). The ulcer surface was covered with mucous moss, and the surrounding mucosa showed an irregular eminence, bled easily when touched, and had a hard texture.

PATHOLOGIC FINDINGS

A laparotomy was performed that revealed multiple grayish-red ulcerative tumors in the mucosa of the ileum, with a thin film of foul moss on the surface (Figure 4). An 8 cm × 6 cm ulcerative mass was also detected 2 m distal to the ligament of Treitz, resulting in intestinal obstruction. All lesions were resected and sent for pathological examination. Microscopically, the tumor tissues were hemorrhagic and necrotic. Spindle tumor cell infiltration was observed with round or spindle nuclei, thick chromatin, and mitotic images. Giant tumor cells were arranged in cords or scattered singly. Some tumor cells formed vascular channels with erythrocytes in the center, and parts of the lumen anastomosed with each other (Figure 5). Tumor cells infiltrated the subserosal layer. No tumor tissue was detected at the resection margins or perienteral lymph nodes. Immunohistochemistry results showed that the tumor cells were positive for CD31, vimentin, ETS-related gene (ERG) and p53, but negative for CK (Pan), epithelial membrane antigen (EMA), CD34, SMA, CD117, DOG1, S100, Melan A, HMB45, and MyoD1. The Ki-67 proliferation index was 40%.

FINAL DIAGNOSIS

According to the pathological findings, the patient was definitely diagnosed with small intestinal angiosarcoma.

TREATMENT

The patient received R0 resection of small intestinal sarcoma with D2 Lymph node dissection and further functional end-to-end anastomosis. General supportive treatment was provided postoperatively. Further chemotherapy and molecular targeted therapy were suggested, but the patient declined owing to financial constraints.

OUTCOME AND FOLLOW-UP

Following surgery, the patient's symptoms were relieved and there was no further melena. The patient was discharged following an improvement in his general condition. Shortly after discharge, the patient developed anorexia and diarrhea. However, the patient did not visit the hospital for review. He died four months later.

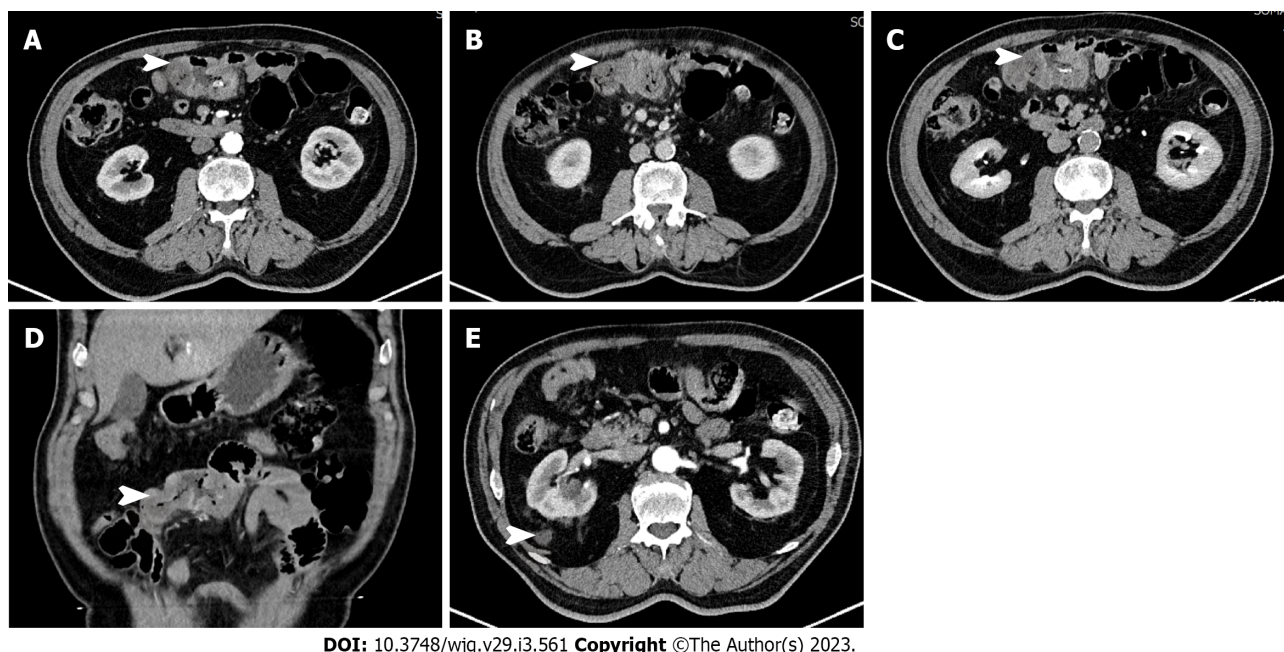


Figure 1 Computed tomography showed segmental thickening of the small intestine (white arrow), with lesion enhancement in the arterial phase. A: Arterial phase; B: Venous phase; C: Balanced phase; D: Coronal plane; E: Adrenal masses.

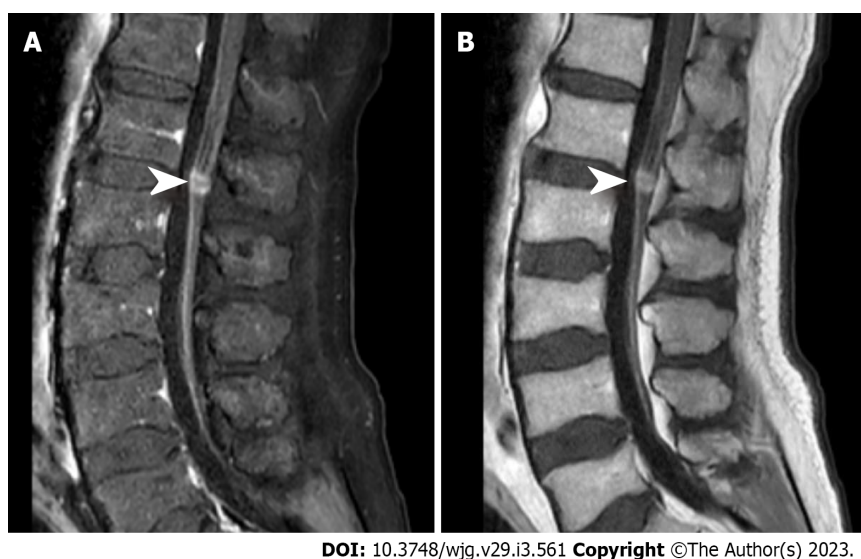


Figure 2 Magnetic resonance imaging showed local abnormally enhanced nodules (white arrow) at the L1/L2 level in the cauda equina. A: T1 phase; B: T2 phase.

DISCUSSION

Literature review

We searched PubMed, Embase, Web of Science, and CNKI for cases of small intestinal angiosarcoma (updated until August 01, 2022). Only original reports published in English language were included. The search terms were ("small bowel" OR "small intestine" OR "small intestinal") AND ("adenocarcinoma" OR "hemangiosarcoma" OR "angiomatous sarcoma"). Including our case, a total of 82 cases was collected [1-4,6-77]. Of all the cases, 62 were primary, and 14 were secondary. The primary site of 6 cases could not be determined as the tumor lesions were found at multiple sites simultaneously. The basic clinical data of the patients are presented in Table 1. Prognostic information was available for 62 cases and an endpoint event (death) was observed in 52. SPSS software was used for statistical analyses. Survival curves were obtained using the Kaplan-Meier method (log-rank test). Univariate and multivariate analyses were performed using the Cox proportional hazards model. Categorical variables were compared using the chi-squared test. All tests were two-tailed, and statistical significance was set

Table 1 The basic clinicopathological factors of 82 collected cases

Characteristics	Number of patients	%
Gender		
Male	55	67.07
Female	27	32.93
Age		
≤ 65	34	41.46
> 65	47	57.32
NA	1	1.22
Race		
North America	35	42.68
European	17	20.73
Asia	26	31.71
other	4	4.88
Year		
≤ 2000	20	24.39
> 2010	62	75.61
Tumor origin		
Primary	62	75.61
Secondary	14	17.07
NA	6	7.32
Radiation history		
With	21	25.61
Without	61	74.39

NA: Not available.

at $P < 0.05$ unless otherwise stated. Data are presented as mean \pm SD.

Age and gender characteristics of the patients

Of the 82 patients, 55 were men, and 27 were women, with a male-to-female ratio of 2.04:1.00. The ages of 55 men and 26 women were available (Table 2). The mean age of men was 64.44 years \pm 14.92 years, with a range of 25-87 years; the mean age of women was 60.85 years \pm 22.73 years, with a range of 20-92 years. The patients' age distribution is shown in Figure 6. There was no significant difference in age distribution between men and women ($P = 0.339$, Chi-square test).

Clinical symptoms and complications

The most frequent clinical symptoms (in order of frequency) were gastrointestinal bleeding (62.20%), anemia (57.32%), abdominal pain (37.80%), weakness (23.17%), weight loss (18.29%), shortness of breath (15.85%), nausea (13.41%), abdominal distention (12.20%), and loss of appetite (9.76%) (Table 3). Symptoms caused by angiosarcoma are challenging to distinguish from those of patients with gastrointestinal tumors, ulcers, and inflammatory diseases. The possibility of angiosarcoma should be considered in patients with unexplained gastrointestinal bleeding. The common abdominal complications were intestinal obstruction (18.29%), intestinal perforation (13.41%), intussusception (4.88%), and intraperitoneal hemorrhage (2.44%), which can result in an acute abdomen requiring emergency surgical management.

Detection of angiosarcoma lesions

The examination of the small intestine is difficult because of its anatomical location and structure. In recent years, the diagnostic rate of small-intestinal diseases has improved with the development of capsule endoscopy and enteroscopy. Among the cases collected, small bowel lesions or abnormalities were detected first by endoscopy in 23 cases, by CT in 12 cases, and capsule endoscopy in 6 cases. In

Table 2 Age distribution characteristics of patients

Gender	Number	Mean age	SD	Median age	Range of age
Female	26	60.85	22.73	70	20-92
Male	55	64.44	14.92	68	25-87
All	82	63.28	17.74	68	20-92

Table 3 Patients' symptoms during the disease

Symptoms	Number	Percentage (%)
Gastrointestinal bleeding	51	62.20
Anemia	47	57.32
Abdominal pain	31	37.80
Weak	19	23.17
Loss of weight	15	18.29
Short of breath	13	15.85
Nausea	11	13.41
Abdominal distention	10	12.20
Loss of appetite	8	9.76
Dizziness	5	6.10
Fever	3	3.66
Constipation	3	3.66
Chest pain	3	3.66
Back pain	3	3.66
Diarrhea	2	2.44
Syncope	2	2.44
Drowsiness	1	1.22
Peripheral edema	1	1.22
Lower limb weakness	1	1.22

addition, digestive tract radiography, MRI, barium meal, positron emission tomography (PET), and other examinations helped to detect lesions. In 26 cases, lesions were found by exploratory laparotomy, including those with an acute abdominal disease requiring emergency surgery and those in whom imaging and endoscopy examinations did not detect the lesion. In three cases, lesions were found on autopsy. The morphology of small intestinal angiosarcoma varies. Endoscopically, the tumors appear as deep or shallow ulcers, polyps, fungating lesion[22], nodules, huge masses, superficial elevations, depressions[48], or thickening and congestion of the small bowel wall[35]. Some lesions show varying degrees of hemorrhage[21,32,44,59] or are covered with filthy moss. On the CT scan, small intestinal angiosarcoma was characterized by segmental wall thickening of the small intestine[10,12,58,75,76], apple core lesion[11] and occupying lesion[6,20,33,67,70], with enlargement of the surrounding lymph nodes[52]. Necrosis was observed in the center of some lesions[33]. Contrast-enhanced CT scans showed different degrees of enhancement[4,57,61].

Diagnosis of small intestinal angiosarcoma

The diagnosis of angiosarcoma depends mainly on morphological characteristics and immunohistochemistry. Abnormal and malignant endothelial cells are the hallmarks of angiosarcoma and can be round, polygonal, spindle-shaped, or epithelioid in appearance. Well-differentiated angiosarcoma presents as well-formed vessels, papillary vascular spaces, or anastomotic narrow vascular channels with visible red blood cells in the lumen[29]. Poorly differentiated angiosarcomas are solid tumors characterized by continuous sheets of malignant cells[29]. Local necrosis and bleeding of tumor tissue are common. Table 4 presents the expression of immunohistochemical markers in the collected cases. CD31, CD34, factor VIII-related antigen (VIII), ERG, friend leukemia integration 1 (Fli-1), and von

Table 4 Characteristics of immunohistochemistry results

Pathological markers	Total	Positive	Negative
CD31	49	49	0
CD34	40	30	10
Vimentin	28	28	0
VIII	29	26	3
ERG	10	10	0
FLI-1	6	6	0
von Willebrand factor	2	2	0
EMA	17	1	16
SMA	10	0	10
CD117	10	0	10
Desmin	11	0	11
S100	28	1	27

VIII: Factor VIII-related antigen; ERG: ETS-related gene; FLI-1: Friend leukemia integration 1; EMA: Epithelial membrane antigen; SMA: Smooth muscle actin.

Willebrand factor (vWF) are important immune-positive markers of angiosarcoma. CD31 (49/49), ERG (10/10), FLI-1 (6/6), and vWF (2/2) were all positive in the stained cases. CD34 had a sensitivity of 75% (30/40), and VIII had a sensitivity of 89.7% (26/29). Besides, the immunohistochemistry results for EMA (16/17), SMA (10/10), CD117 (10/10), desmin (11/11), and S100 (27/28) were mostly negative in the collected angiosarcoma cases.

Distribution, characteristic, and metastasis of the lesions

The location of the small intestinal angiosarcoma, in descending order, was jejunum (28.0%), ileum (19.5%), duodenum (12.2%), whole small intestine (12.2%), duodenum/jejunum (11.0%), jejunum/ileum (6.1%), and unspecified small intestine (11.0%) (Table 5). Of the 76 cases that reported a definite location of the lesion, 42 cases invaded the jejunum (55.3%, A + D + E), 40 cases invaded ileum (52.6%, B + D + E + F) and 29 cases invaded duodenum (38.2%, C + D + F). There were 49 cases (64.5%) involving a single segment of the small intestine (A + B + C), 14 cases (18.4%) involving two segments of the small intestine (E + F), and 10 cases (13.2%) involving the entire small intestine. The characteristics of angiosarcoma lesions are shown in Table 6. Angiosarcomas of the small intestine tend to be multifocal (multifocal/single focal = 1.8). The size of the lesions varied, with a maximum diameter of < 40 mm for 38 Lesions and > 40 mm for 14 Lesions. The largest reported lesions can be up to 240 mm in diameter [33]. In two cases, the tumor lesions showed diffuse distribution[23,40]. Angiosarcoma lesions present as ulcer type (15.66%), superficial type (9.64%), diffuse infiltration type (7.23%), and protrusion (49.4%) types, including mass, polyp, mushroom type, and so on. Microscopically, the lesions invaded the mucosa in 3 cases, submucosa in 4 cases, muscularis propria in 5 cases, and serosa in 7 cases. In one case, the tumor lesion was located under the serosa. Among the 62 cases of primary small intestinal angiosarcoma, 35 cases (56.5%) had distant metastasis, 23 cases (37.1%) had no distant metastasis, and the other 4 (6.5%) were not specified (Table 7). The most frequent metastatic sites were the lung (22.6%), liver (21.0%), large intestine (21.0%), spleen (8.1%), bone (8.1%), pleural (6.5%) and stomach (6.5%). Of the 14 sary cases, 4 were primary in the skin of the head and face, 4 in the liver, 4 in the spleen, and one each in the pleuropulmonary, thyroid, sternocleidomastoid muscle, and rectum. Systemic examination and careful exploration are necessary for patients with angiosarcoma to prevent missing multiple or metastatic lesions.

Risk factors

A total of 21 cases had a clear history of radiation, including 15 women and 6 men (Table 8). There were 20 cases with a history of radiation therapy for tumors, and the remaining 1 had 30 years of severe occupational exposure to radiation and polyvinyl chloride. The time from radiation exposure to diagnosing small intestinal angiosarcoma fluctuated from 7 years to 45 years, with an average of 16.12 years \pm 10.05 years. The radiation sites were located in the pelvis in 16 cases, chest in 2 cases, abdomen in 1 case, and neck in 1 case. The radiation dose ranged from 15 Gray to 60 Gray, with a mean of 48.03 Gray \pm 14.18 Gray. Among the female patients, 10 were treated with radiation for uterine tumors, 2 for breast cancer, 2 for ovarian tumors, and 1 for colon cancer; of the male patients, 2 for prostate cancer, 1

Table 5 Location of small intestinal angiosarcoma

Tag	Location	Number	Percentage (%)
A	Jejunum	23	28.0
B	Ileum	16	19.5
C	Duodenum	10	12.2
D	Duodenum, Jejunum and Ileum	10	12.2
E	Duodenum and Jejunum	9	11.0
F	Jejunum and Ileum	5	6.1
G	Unspecified small intestine	9	11.0

Table 6 Characteristics of small intestinal angiosarcoma lesions

Characteristics	Number	%
Size		
≤ 40 mm	38	45.78
> 40 mm	14	16.87
Diffuse	2	2.41
NA	29	34.94
Small intestinal lesions		
Single focal	26	35.6
Multifocal	47	64.4
NA	9	
Pathological morphology		
Ulcerative	13	15.66
Protuberant	41	49.4
Superficial	8	9.64
Diffuse infiltrating	6	7.23
NA	15	18.07
Infiltration depth		
Mucosa	3	3.61
Submucosa	17	20.48
Muscularis propria	7	8.43
Serosa	17	20.48
Under the serosa	1	
NA	39	46.99

NA: Not available.

for abdominal lymphoma, 1 for tonsil cancer, and 1 for pelvic chondrosarcoma. In addition, a 45-year-old male patient had a history of hemodialysis for up to 21 years due to chronic renal insufficiency[46], and a 72-year-old male patient worked in the construction industry and may have had a long history of toxicological exposure[9].

Treatment

Treatment modalities were available for 74 cases among the reported cases. Among them, 42 patients (51.2%) underwent surgical resection only; 12 patients (14.6%) underwent surgical resection and chemotherapy; 11 patients (13.4%) received conservative treatment or no treatment; 5 patients (6.1%)

Table 7 Distant metastatic site of primary small intestinal angiosarcoma

Distant metastasis	Number	%
No metastasis	23	37.1
Lung	14	22.6
Liver	13	21.0
Large intestine	13	21.0
Spleen	5	8.1
Bone	5	8.1
Pleural	4	6.5
Stomach	4	6.5
Bladder	3	4.8
Kidney	2	3.2
Vein	2	3.2
Abdominal wall	2	3.2
Gallbladder	2	3.2
Pancreas	1	1.6
Heart	1	1.6
Adrenal gland	1	1.6
Pelvic cavity	1	1.6
Brain	1	1.6
Oropharynx	1	1.6
Diaphragm	1	1.6
NA	4	6.5
All	62	100%

NA: Not available.

received chemotherapy only; one underwent surgical resection, chemotherapy, and radiation therapy; one was treated with chemotherapy, radiotherapy, and immunotherapy; and one was treated with argon plasma coagulation. Of the patients who received chemotherapy, 2 with doxorubicin; 1 with paclitaxel plus carboplatin; 1 with adriamycin, vincristine, dacarbazine and Cytosan; 1 with liposomal non-pegylated doxorubicin and Ifosfamide. Bevacizumab was the immunotherapy drug. Some patients required repeated blood transfusion treatment owing to anemia caused by chronic gastrointestinal blood loss[3,28].

Prognostic factors

We collected the survival time and status of 62 patients and performed a prognosis analysis. The mean survival of patients with small intestinal angiosarcoma was 234.77 d \pm 41.88 d, with a range of 3 d to 3 years. Median survival time was 90.00 d \pm 20.56 d. Respiratory failure, hemorrhagic shock, and multiple metastases were common causes of death. Kaplan-Meier survival analysis showed that age ($P = 0.033$), infiltrating depth ($P = 0.038$), chemotherapy ($P = 0.025$), and the number of small intestinal segments tumor involved ($P = 0.020$) were prognostic factors for small intestinal angiosarcoma (Figure 7). Sex, risk factors, acute abdomen, tumor origin, tumor size, number of tumor lesions, and distant metastasis had no significant effect on patient prognosis ($P > 0.100$). In the COX regression survival analysis, infiltration depth was eliminated owing to a large amount of missing data. Univariate COX regression analysis showed that age > 65 years ($P = 0.047$) and tumor lesions involving three whole segments ($P = 0.020$) of the small intestine, without chemotherapy ($P = 0.032$) were risk factors for small intestinal angiosarcoma (Table 9). We included factors with $P < 0.100$ in the univariate COX regression analysis into the multivariate analysis to avoid missing important influencing factors. The results showed that chemotherapy [$P = 0.038$, HR: 0.442 (0.205-0.956)], and surgery [$P = 0.028$, HR: 0.407 (0.182--0.908)] effectively improved patient prognosis (Table 10).

Table 8 Analysis of risk factors for small intestinal angiosarcoma

Gender/age (yr)	Time ¹ (yr)	Cause of radiation	Radiation area	Dose (Gray)
F/66	20	Uterus cancer	Pelvis	NA
F/69	7	Adenocarcinoma of uterus	Pelvis	NA
F/50	14	Adenocarcinoma of uterine body	Pelvis	55.6
F/76	7	Adenocarcinoma of uterine body	Pelvis	45.1
F/78	10	Endometrial cancer	Pelvis	55.5
F/51	9	Adenocarcinoma of cervix	Pelvis	50
F/80	20	Squamous cell carcinoma of cervix	Pelvis	55
F/61	20	Squamous cell carcinoma of cervix	Pelvis	NA
F/NA	8	Cervical cancer	Pelvis	NA
F/72	24	Leiomyosarcoma of uterus	Pelvis	NA
F/26	14	Dysgerminoma of ovary	Pelvis	48
F/66	8	Ovarian cancer	Pelvis	60
F/88	18	Breast cancer	Chest	NA
F/37	NA	Breast cancer	Chest	NA
F/92	12	Colon cancer	Pelvis	NA
M/82	NA	Prostate cancer	Pelvis	NA
M/80	NA	Prostate cancer	Pelvis	NA
M/73	NA	Squamous cell carcinoma of tonsil	Neck	NA
M/63	45	Left lower abdominal lymphoma	Abdomen	15
M/57	8	Chondrosarcoma of right hemipelvis	Pelvis	NA
M/68	30	Occupational exposure	NA	Heavy

¹Time: Duration from exposure to risk factors to diagnosis of small intestinal angiosarcoma.

M: Male; F: Female; NA: Not available.

DISCUSSION

Primary small intestinal malignancies are rare, accounting for < 2% of gastrointestinal tumors[36]. Small intestinal malignant tumors are often discovered late, due to their nonspecific symptoms and limited examination methods, resulting poor prognosis[51]. Gastrointestinal bleeding caused by small intestinal angiosarcoma is difficult to detect using routine gastroscopy and electronic colonoscopy[17]. CT, capsule endoscopy[25], PET[29], tagged red blood cell scanning[18], and push enteroscopy[28] may aid in the detection of small intestinal lesions. However, lesions were not detected in some patients after multiple examinations, thus necessitating surgical exploration. Even with endoscopic tissue biopsies, definitive diagnosis requires several attempts in some patients[9]. Thus, small intestinal angiosarcoma should be considered in patients with early abdominal symptoms, especially in older adults with melena, to avoid rapid disease development due to missed diagnosis.

Angiosarcoma is an aggressive tumor with high lymph node and peripheral metastases[51]. In our literature review, primary small intestinal angiosarcoma had a distant metastasis rate of at least 56.5%. Small intestinal angiosarcoma often metastasizes to the lungs, liver, large intestine, and spleens. Respiratory failure due to pulmonary metastases is a common cause of death in patients with small intestinal angiosarcoma (15 cases). There was one case of metastasis to an uncommon site, the right atrial appendage and right ventricular septum, with a survival of only 12 d[34]. Therefore, for patients diagnosed with angiosarcoma of the small intestine, systemic examinations, such as PET-CT, are recommended, with attention paid specifically to pulmonary metastases.

Depending on the degree of differentiation, angiosarcoma can develop and range from being a well-differentiated vascular form to a poorly differentiated solid tissue. The solid growth pattern of angiosarcoma consists of two cell types: Sheets of spindle-shaped or large, polygonal epithelioid-type cells with a high mitotic rate[29]. The specific angiosarcoma subtype consisting of epithelioid tumor cells is called epithelioid angiosarcoma[32]. Epithelioid morphology is typical, but it can also express endothelial-related markers, such as cytokeratin, leading to confusion with other entities, such as

Table 9 Results of univariate COX regression analysis

Factors	HR (98%CI)	P value
Gender (male/female)	1.395 (0.772-2.521)	0.270
Age (> 65/≤ 65)	1.803 (1.007-3.227)	0.047
Tumor origin (secondary/primary)	1.708 (0.789-3.696)	0.174
Tumor size(> 40 mm/≤ 40 mm)	1.265 (0.578-2.767)	0.557
Tumor lesion (multifocal/single focal)	1.365 (0.722-2.579)	0.338
Distant metastases (yes/no)	1.140 (0.573-2.269)	0.708
Acute abdominal disease (yes/no)	0.780 (0.424-1.435)	0.424
Surgery (with/without)	0.570 (0.296-1.100)	0.094
Chemotherapy (with/without)	0.473 (0.238-0.940)	0.032
Gastrointestinal bleeding (yes/no)	1.076 (0.604-1.915)	0.803
Tumor distribution		
Two segments/one segment	2.116 (0.975-4.593)	0.058
Whole intestine/one segment	2.473 (1.156-5.289)	0.020

Table 10 Results of multivariate COX regression analysis

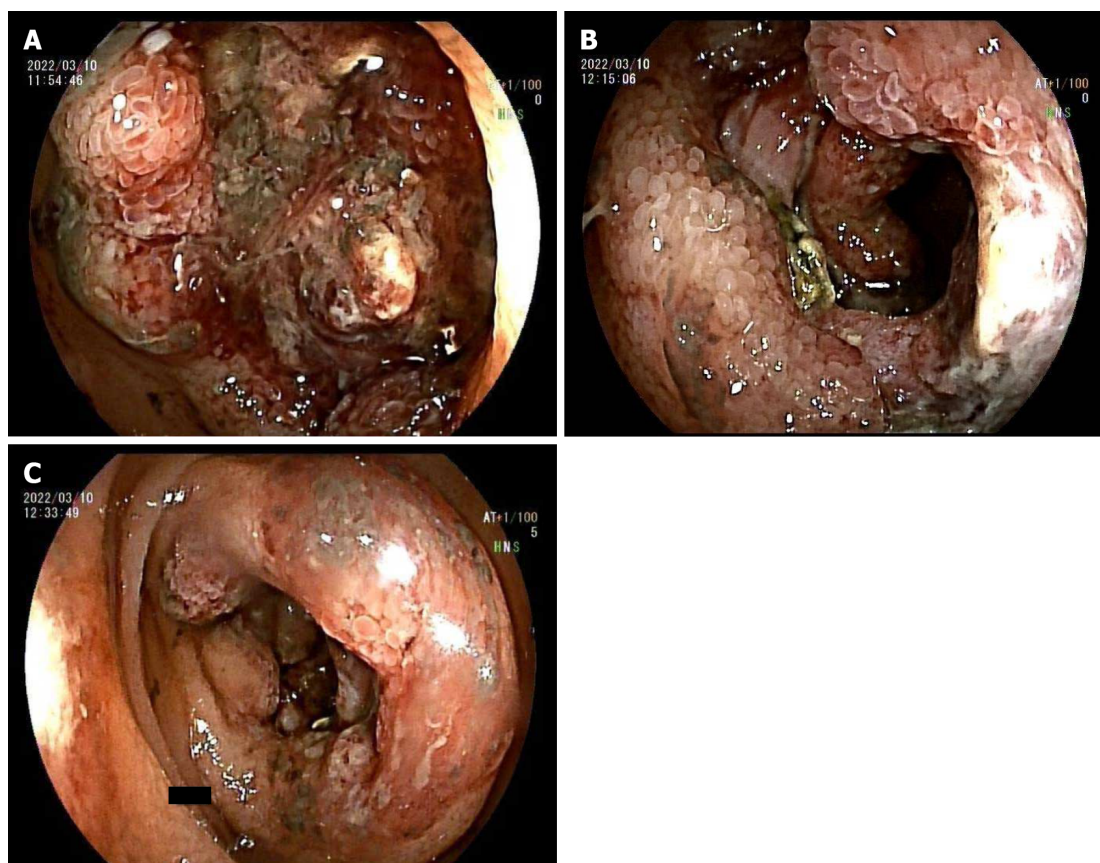
Factors	HR (98%CI)	P value
Chemotherapy (with/without)	0.442 (0.205-0.956)	0.038
Surgery (with/without)	0.407 (0.182-0.908)	0.028
Age (> 65/≤ 65)	1.944 (0.969-3.902)	0.061
Tumor distribution		
Two segments/one segment	0.434 (0.194-0.969)	0.042
Whole intestine/one segment	0.820 (0.323-2.086)	0.677

malignant melanoma, fibrosarcoma, mesothelioma, or sarcoma with epithelioid features (particularly gastrointestinal stromal tumors)[10,28].

Immunohistochemistry is essential for the diagnosis of angiosarcoma. Positive expression of endothelial markers, including CD31, CD34, factor VIII, ERG, Fli-1, and vWF, help define the vascular nature of the tumor[3]. CD31 and ERG show the highest positive detection rates. The specificity of CD34 is relatively low and is positively expressed in 60%-70% of gastrointestinal stromal tumors[78]. Vimentin is a marker of epithelial-mesenchymal transition, and its overexpression in tumors is closely related to accelerated growth, invasion, and poor prognosis[52]. Vimentin is also widely expressed in other tumors, including melanoma, malignant mesothelioma, and epithelioid sarcoma, thus lacking reliability in the differential diagnosis of angiosarcoma[3]. As a negative marker in angiosarcoma, S-100 proteins help differentiate angiosarcoma from carcinoma and melanoma[10]. EMA cannot be used definitively in the differential diagnosis of angiosarcoma as it can be positive for epithelioid angiosarcoma[3,52]. CD117 is commonly used to diagnose gastrointestinal stromal tumors[78]. However, previous studies have shown that > 50% of angiosarcomas are positive for CD117[79]. Additionally, epithelioid and some non-epithelioid angiosarcoma cases may express keratin[3,76].

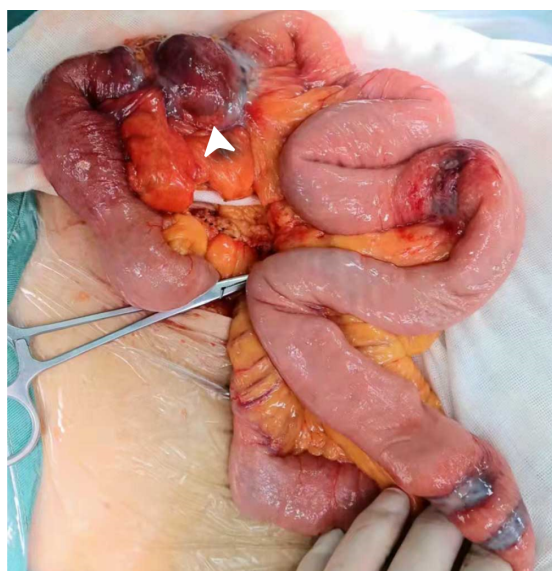
The prognosis for small intestinal angiosarcoma is poor, and the one-year survival rate was only 20.8% among the cases reviewed in the present study. Old age, infiltration depth, and involvement of two or all segments of the small intestine are risk factors for poor prognosis. Multivariate Cox regression analysis showed that surgery and chemotherapy can significantly improve the prognosis of patients with small intestinal angiosarcoma. In addition to surgical resection and chemotherapy, nutritional support, medication or endoscopic hemostasis, blood transfusion, and other treatments are also important. Local radiotherapy is also an alternative treatment.

With the development and clinical application of molecular targeted drugs, molecular targeted therapy for tumors has become a research hotspot in medical oncology. Studies have shown that vascular endothelial growth factor (VEGF) and its receptor (VEGFR) are highly expressed in angiosarcoma. VEGF and VEGFR inhibitors or multi-tyrosine kinase inhibitors, including bevacizumab and pazopanib, are potential drug targets for angiosarcoma. Malignant vascular tumors, including



DOI: 10.3748/wjg.v29.i3.561 Copyright ©The Author(s) 2023.

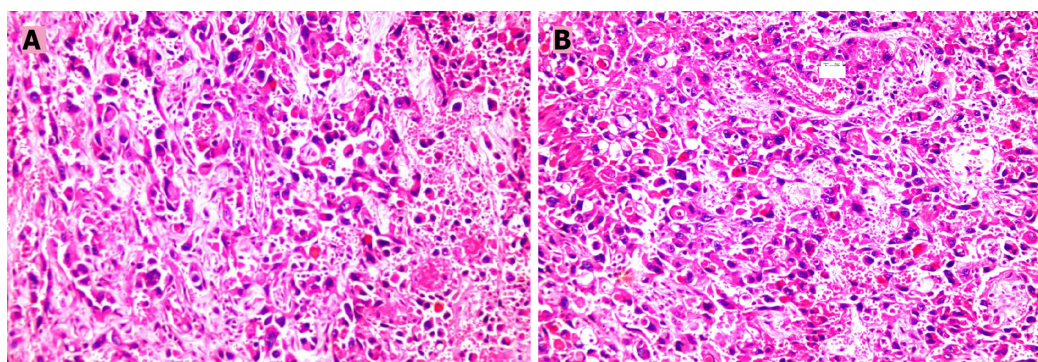
Figure 3 Electronic double-balloon enteroscopy. A-C: Electronic double-balloon enteroscopy showed continuous periannulus ulcers 2.4-2.5 m above the ileocecal valve, covered with mucous moss.



DOI: 10.3748/wjg.v29.i3.561 Copyright ©The Author(s) 2023.

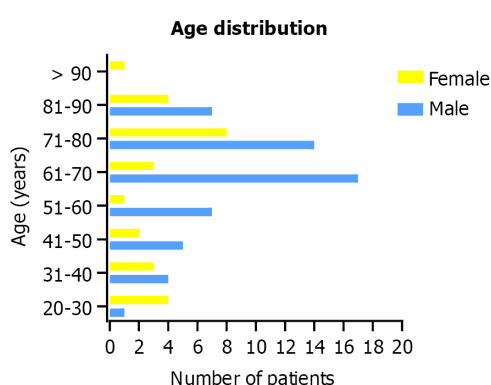
Figure 4 During the operation, multiple grey-red ulcerative tumors were observed in the ileum mucosa covered with moss. In addition, an 8 cm × 6 cm ulcerative mass (white arrow) resulted in intestinal obstruction.

angiosarcoma, express high levels of adrenergic receptors. Targeting these receptors with drugs such as protamine inhibited tumor growth in mouse vascular cell lines[80]. In addition, a few cases with cutaneous angiosarcoma showed significant responses to checkpoint inhibitors, including pembrolizumab, anti-PD-L1 antibody, and anti-CTLA-4 antibody[81]. However, existing immunotherapy



DOI: 10.3748/wjg.v29.i3.561 Copyright ©The Author(s) 2023.

Figure 5 Pathologic findings. A and B: Microscopically, spindle cell infiltration was observed with round or spindle-shaped nuclei. In some areas, tumor cells formed vascular channels with red blood cells in the middle ($\times 100$).



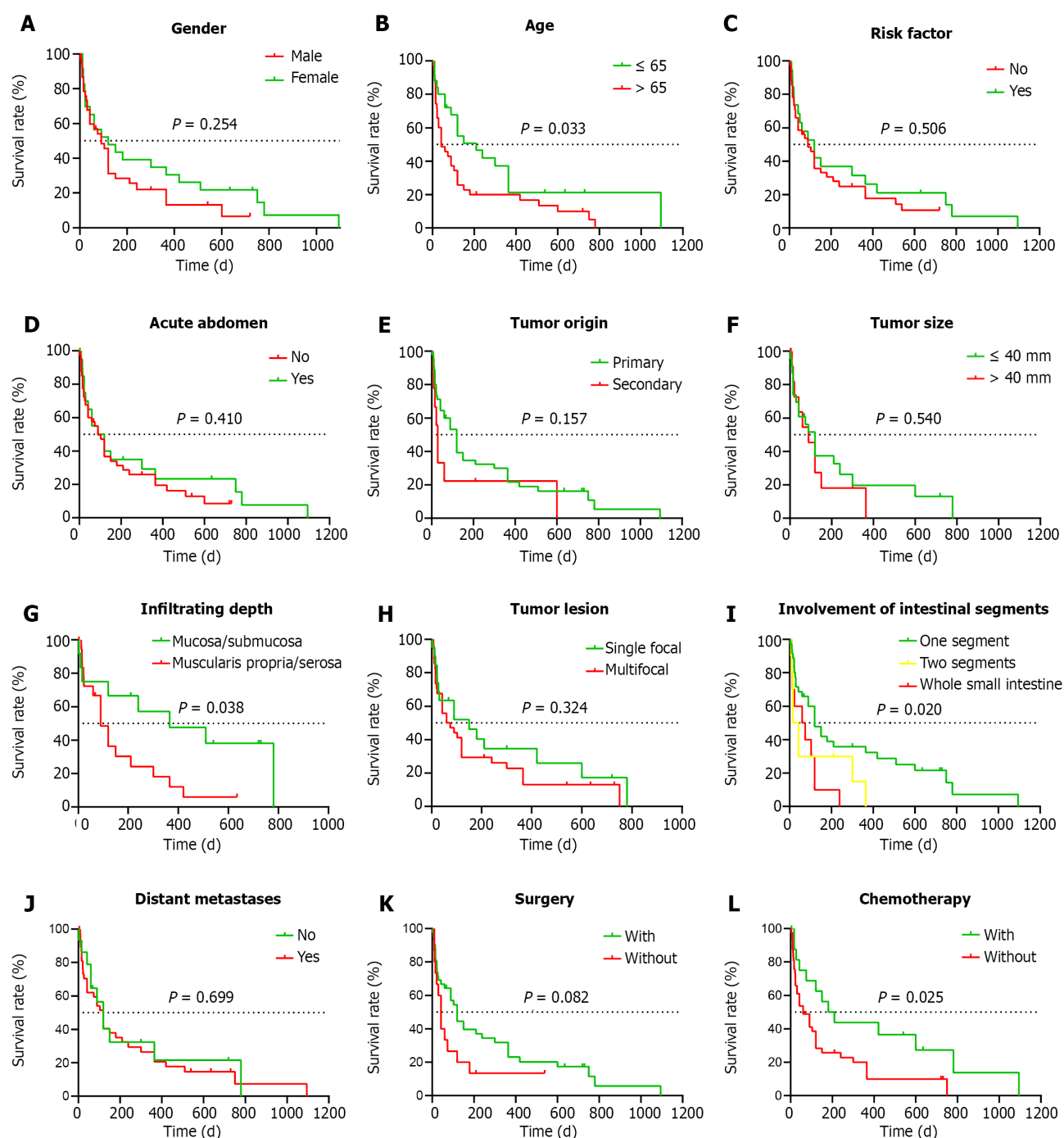
DOI: 10.3748/wjg.v29.i3.561 Copyright ©The Author(s) 2023.

Figure 6 Age distribution of male and female patients.

clinical trials mostly focused on cutaneous angiosarcoma, and relevant research on small intestinal angiosarcoma is lacking. Bevacizumab was administered to only one patient with angiosarcoma of the small intestine. However, due to the rapid progression of the patient's disease and failure to take drugs regularly, it was impossible to objectively evaluate its effect[17].

CONCLUSION

This study reported a case of multiple small intestinal angiosarcomas that resulted in intestinal obstruction with lumbar and bilateral adrenal metastases. Furthermore, we summarized the clinical features, diagnosis, treatment, and prognosis of 82 reported cases of small intestinal angiosarcoma. We found that small intestinal angiosarcoma occurred mainly in older men, and the most common symptom was gastrointestinal bleeding, which mainly manifested as melena. The main treatment methods were surgical resection and chemotherapy, which effectively improved patients' survival. This will help clinicians to understand small intestinal angiosarcomas and guide their clinical diagnosis and treatment. However, statistical bias is inevitable because of the small sample size. In addition, few clinical trials are related to chemotherapy and immunotherapy, and treatment methods are limited. Therefore, we expect that statistical analysis of larger samples and drug clinical trials will improve patients' clinical management and prognosis with small intestinal angiosarcoma.



DOI: 10.3748/wjg.v29.i3.561 Copyright ©The Author(s) 2023.

Figure 7 Kaplan-Meier survival analysis. A: Sex; B: Age; C: Risk factor; D: Acute abdomen; E: Tumor origin; F: Tumor size; G: Infiltrating depth; H: Number of tumor lesions; I: Intestinal segments involvement; J: Distant metastases; K: Surgery; L: Chemotherapy.

ACKNOWLEDGEMENTS

We sincerely appreciate the patient and his families for their cooperation in information acquisition, treatment, and follow-up.

FOOTNOTES

Author contributions: Ma XM contributed to data analysis and manuscript writing; Yang BS contributed to conceptualization and methodology; Yang Y contributed to data curation and visualization; Wu GZ contributed to data curation, writing-original draft preparation; Li YW, Yu X, and Ma XL contributed to literature search and screening; Wang YP and Hou XD contributed to revised the manuscript and approved the final version; Guo QH

contributed to supervision and final confirmation.

Informed consent statement: Informed written consent was obtained from the patients for the publication of this report and any accompanying images.

Conflict-of-interest statement: The authors declare that they have no conflict of interest to disclose.

CARE Checklist (2016) statement: The authors have read the CARE Checklist (2016), and the manuscript was prepared and revised according to the CARE Checklist (2016).

Open-Access: This article is an open-access article that was selected by an in-house editor and fully peer-reviewed by external reviewers. It is distributed in accordance with the Creative Commons Attribution NonCommercial (CC BY-NC 4.0) license, which permits others to distribute, remix, adapt, build upon this work non-commercially, and license their derivative works on different terms, provided the original work is properly cited and the use is non-commercial. See: <https://creativecommons.org/licenses/by-nc/4.0/>

Country/Territory of origin: China

ORCID number: Xiao-Mei Ma 0000-0003-1117-8309; Bao-Shun Yang 0000-0002-2772-694X; Yuan Yang 0000-0003-2212-4023; Guo-Zhi Wu 0000-0002-1223-1653; Yu-Ping Wang 0000-0003-0087-4771; Qing-Hong Guo 0000-0003-2456-7362.

S-Editor: Chen YL

L-Editor: A

P-Editor: Chen YL

REFERENCES

- Zhang Y, Chen Y, Li J, Li S, Wu Y, Zhan D, Wen X, Wang M. Poor prognosis of primary duodenum angiosarcoma: a case report. *ANZ J Surg* 2021; **91**: E600-E602 [PMID: 33577107 DOI: 10.1111/ans.16589]
- Amini A, Koury E, Vaezi Z, Melnick J, Su A, Chahla E. Duodenal angiosarcoma can be misdiagnosed as a Dieulafoy's lesion. *Gastroenterol Hepatol Bed Bench* 2020; **13**: 268-271 [PMID: 32821359]
- Nai Q, Ansari M, Liu J, Razjouyan H, Pak S, Tian Y, Khan R, Broder A, Bagchi A, Iyer V, Hamouda D, Islam M, Sen S, Yousif A, Hu M, Lou Y, Duhl J. Primary Small Intestinal Angiosarcoma: Epidemiology, Diagnosis and Treatment. *J Clin Med Res* 2018; **10**: 294-301 [PMID: 29511417 DOI: 10.14740/jocmr3153w]
- Hui YY, Zhu LP, Yang B, Zhang ZY, Zhang YJ, Chen X, Wang BM. Gastrointestinal bleeding caused by jejunal angiosarcoma: A case report. *World J Clin Cases* 2020; **8**: 4565-4571 [PMID: 33083419 DOI: 10.12998/wjcc.v8.i19.4565]
- Li R, Ouyang ZY, Xiao JB, He J, Zhou YW, Zhang GY, Li Q, Gu H, Leng AM, Liu T. Clinical Characteristics and Prognostic Factors of Small Intestine Angiosarcoma: a Retrospective Clinical Analysis of 66 Cases. *Cell Physiol Biochem* 2017; **44**: 817-827 [PMID: 29176321 DOI: 10.1159/000485345]
- Liu Z, Yu J, Xu Z, Dong Z, Suo J. Primary angiosarcoma of the small intestine metastatic to peritoneum with intestinal perforation: a case report and review of the literature. *Transl Cancer Res* 2019; **8**: 1635-1640 [PMID: 35116908 DOI: 10.21037/tcr.2019.06.40]
- Takamura Y, Seki H, Kasaoka C, Kono T, Murai T. Angiogenic tumor in the small intestine. A case report and review of the literature published in Japan. *Gastroenterol Jpn* 1975; **10**: 342-350 [PMID: 1241946 DOI: 10.1007/BF02776364]
- Chen KT, Hoffman KD, Hendricks EJ. Angiosarcoma following therapeutic irradiation. *Cancer* 1979; **44**: 2044-2048 [PMID: 389407 DOI: 10.1002/1097-0142(197912)44:6<2044::aid-cnrcr2820440614>3.0.co;2-u]
- Maeyashiki C, Nagata N, Uemura N. Angiosarcoma involving solid organs and the gastrointestinal tract with life-threatening bleeding. *Case Rep Gastroenterol* 2012; **6**: 772-777 [PMID: 23341800 DOI: 10.1159/000346398]
- Allison KH, Yoder BJ, Bronner MP, Goldblum JR, Rubin BP. Angiosarcoma involving the gastrointestinal tract: a series of primary and metastatic cases. *Am J Surg Pathol* 2004; **28**: 298-307 [PMID: 15104292 DOI: 10.1097/0000478-200403000-00002]
- Siderits R, Poblete F, Saraiya B, Rimmer C, Hazra A, Aye L. Angiosarcoma of small bowel presenting with obstruction: novel observations on a rare diagnostic entity with unique clinical presentation. *Case Rep Gastrointest Med* 2012; **2012**: 480135 [PMID: 23198186 DOI: 10.1155/2012/480135]
- Taxy JB, Battifora H. Angiosarcoma of the gastrointestinal tract. A report of three cases. *Cancer* 1988; **62**: 210-216 [PMID: 3383117 DOI: 10.1002/1097-0142(19880701)62:1<210::aid-cnrcr2820620132>3.0.co;2-8]
- Mohammed A, Aliyu HO, Liman AA, Abdullahi K, Abubakar N. Angiosarcoma of the small intestine. *Ann Afr Med* 2011; **10**: 246-248 [PMID: 21912012 DOI: 10.4103/1596-3519.84702]
- Hwang TL, Sun CF, Chen MF. Angiosarcoma of the small intestine after radiation therapy: report of a case. *J Formos Med Assoc* 1993; **92**: 658-661 [PMID: 7904504]
- Do Nguyen VQ, Mahmood A, Caberto M. Angiosarcoma of the Small Intestine With Metastases to the Colon and Gallbladder. *Consultant* 2017; **57** [DOI: 10.1002/9780470994764.ch7]
- Chami TN, Ratner LE, Henneberry J, Smith DP, Hill G, Katz PO. Angiosarcoma of the small intestine: a case report and literature review. *Am J Gastroenterol* 1994; **89**: 797-800 [PMID: 8172159]
- Reis E, Kalamaha K, Jia H, Fernandes HD. Angiosarcoma with Synchronous Cutaneous and Small Bowel Involvement: A Report of a Rare Presentation. *Cureus* 2018; **10**: e3650 [PMID: 30723649 DOI: 10.7759/cureus.3650]

- 18 **Huntington JT**, Jones C, Liebner DA, Chen JL, Pollock RE. Angiosarcoma: A rare malignancy with protean clinical presentations. *J Surg Oncol* 2015; **111**: 941-950 [PMID: 26031299 DOI: 10.1002/jso.23918]
- 19 **Bandorski D**, Arps H, Jaspersen D, Diehl KL. Severe intestinal bleeding caused by intestinal metastases of a primary angiosarcoma of the thyroid gland. *Z Gastroenterol* 2002; **40**: 811-814 [PMID: 12215951 DOI: 10.1055/s-2002-33876]
- 20 **Moriya Y**, Sugawara T, Arai M, Tsuda Y, Uchida K, Noguchi T, Arai T, Takahashi H. Bilateral massive bloody pleurisy complicated by angiosarcoma. *Intern Med* 2007; **46**: 125-128 [PMID: 17268128 DOI: 10.2169/internalmedicine.46.6146]
- 21 **Kamo R**, Ishina K, Hirata C, Doi K, Nakanishi T, Harada T, Ishii M. A case of ileoileal intussusception caused by metastatic pedunculated tumor of cutaneous angiosarcoma. *J Dermatol* 2005; **32**: 638-640 [PMID: 16334863 DOI: 10.1111/j.1346-8138.2005.tb00813.x]
- 22 **Ryu DY**, Hwang SY, Lee DW, Kim TO, Park DY, Kim GH, Heo J, Kang DH, Song GA, Cho M. [A case of primary angiosarcoma of small intestine presenting as recurrent gastrointestinal bleeding]. *Korean J Gastroenterol* 2005; **46**: 404-408 [PMID: 16301855]
- 23 **Suzuki F**, Saito A, Ishi K, Koyatsu J, Maruyama T, Suda K. Intra-abdominal angiosarcomatosis after radiotherapy. *J Gastroenterol Hepatol* 1999; **14**: 289-292 [PMID: 10197502 DOI: 10.1046/j.1440-1746.1999.01847.x]
- 24 **Selk A**, Wehrl B, Taylor BM. Chylous ascites secondary to small-bowel angiosarcoma. *Can J Surg* 2004; **47**: 383-384 [PMID: 15540697]
- 25 **Fleetwood VA**, Harris JC, Luu MB. Cutaneous angiosarcoma metastatic to small bowel with nodal involvement. *Gastroenterol Hepatol Bed Bench* 2016; **9**: 340-342 [PMID: 27895862]
- 26 **Panagiotakis P**, Alston M, Smyrk T. Disseminated Angiosarcoma of the Gastrointestinal Tract: A Rare Neoplasm Presenting with Melena and Anemia. *Am J Gastroenterol* 2013; **108**: S452
- 27 **Watanabe K**, Hoshi N, Suzuki T. Epithelioid angiosarcoma of the intestinal tract with endothelin-1-like immunoreactivity. *Virchows Arch A Pathol Anat Histopathol* 1993; **423**: 309-314 [PMID: 8236827 DOI: 10.1007/BF01606896]
- 28 **Al Ali J**, Ko HH, Owen D, Steinbrecher UP. Epithelioid angiosarcoma of the small bowel. *Gastrointest Endosc* 2006; **64**: 1018-1021 [PMID: 17140922 DOI: 10.1016/j.gie.2006.04.020]
- 29 **Khalil MF**, Thomas A, Aassad A, Rubin M, Taub RN. Epithelioid Angiosarcoma of the Small Intestine After Occupational Exposure to Radiation and Polyvinyl Chloride: A case Report and Review of Literature. *Sarcoma* 2005; **9**: 161-164 [PMID: 18521426 DOI: 10.1080/13577140500389069]
- 30 **Malik UE**, Hasak S. Epithelioid Angiosarcoma Presenting as Gastrointestinal Bleeding. *Am J Gastroenterol* 2021; **116**: S1243
- 31 **Pang M**, Gomez V, Mittra A, Krishna M, Stark M. Epithelioid Angiosarcoma: A Rare Culprit of Small Bowel Overt Bleeding. *Am J Gastroenterol* 2016; **111**: S1068
- 32 **Benedict M**, Gibson J, Zhang X. Epithelioid Angiosarcoma: An Unusual Cause of Gastrointestinal Bleeding. *Int J Surg Pathol* 2019; **27**: 277-279 [PMID: 29944034 DOI: 10.1177/1066896918784180]
- 33 **Takahashi M**, Ohara M, Kimura N, Domen H, Yamabuki T, Komuro K, Tsuchikawa T, Hirano S, Iwashiro N. Giant primary angiosarcoma of the small intestine showing severe sepsis. *World J Gastroenterol* 2014; **20**: 16359-16363 [PMID: 25473196 DOI: 10.3748/wjg.v20.i43.16359]
- 34 **GRAYSON RR**. Hemangioendotheliosarcoma of the ileum with metastases to the right auricle, rupture of the heart, and hemopericardium at least 10 days before death: a case report. *Ann Intern Med* 1954; **41**: 151-159 [PMID: 13171800 DOI: 10.7326/0003-4819-41-1-151]
- 35 **Ahmad Z**, Nisa A, Idrees R, Minhas K, Pervez S, Mumtaz K. Hepatic angiosarcoma with metastasis to small intestine. *J Coll Physicians Surg Pak* 2008; **18**: 50-52 [PMID: 18452671]
- 36 **Lopes RH**, Resende FAM, Fraga JBP, Oliveira AF, Pereira MSV, Maciel BAR. Angiosarcoma of small intestine: case report and literature review. *J Bras Patol Med Lab* 2016; **52**: 345-8
- 37 **Ginsberg F**, Slavin JD Jr, Spencer RP. Hepatic angiosarcoma: mimicking of angioma on three-phase technetium-99m red blood cell scintigraphy. *J Nucl Med* 1986; **27**: 1861-1863 [PMID: 3783274]
- 38 **Benis É**, Szilágyi A, Izbéki F, Varga I, Altörjay Á. [Intestinal bleeding and obstruction in the small intestine caused by metastatic thyroid angiosarcoma. Case report]. *Orv Hetil* 2014; **155**: 918-921 [PMID: 24880971 DOI: 10.1556/OH.2014.29934]
- 39 **Wolov RB**, Sato N, Azumi N, Lack EE. Intra-abdominal "angiosarcomatosis" report of two cases after pelvic irradiation. *Cancer* 1991; **67**: 2275-2279 [PMID: 2013033 DOI: 10.1002/1097-0142(19910501)67:9<2275::aid-cnrcr2820670911>3.0.co;2-6]
- 40 **Chaudhary D**. A Malignant Case of Gastrointestinal Bleeding. *Am J Gastroenterol* 2013; **108**: S316
- 41 **Yoshida R**, Takada H, Iwamoto S, Mouri T, Uedono Y, Kawanishi H, Hioki K, Sakaida N, Okamura A. Malignant hemangioendothelioma of the small intestine: report of a case. *Surg Today* 1999; **29**: 439-442 [PMID: 10333415 DOI: 10.1007/BF02483036]
- 42 **Cilursu AM**. Massive hemorrhage due to angiosarcomatosis diagnosed by intraoperative small bowel endoscopy. *Endoscopy* 1991; **23**: 245 [PMID: 1915151 DOI: 10.1055/s-2007-1010675]
- 43 **Aleksandra S-M**, Ljubiša T, Tijana G, Vera M, Marjan M, Srdan Đ. Melena as a first sign of metastatic hepatic angiosarcoma: A case report. *Vojnosanit Pregl* 2019; **76**: 219-223
- 44 **Meda S**, Ayyagari K, Vemuru T, Vemuru R. Metastatic Angiosarcoma of Small Intestine Presenting with Upper Gastrointestinal Bleeding. *Am J Gastroenterol* 2013; **108**: S291
- 45 **Paredes A**, Veerappan G. Metastatic Angiosarcoma: A Rare Cause of Gastrointestinal Bleeding. *Am J Gastroenterol* 2012; **107**: S351
- 46 **Usuda H**, Naito M. Multicentric angiosarcoma of the gastrointestinal tract. *Pathol Int* 1997; **47**: 553-556 [PMID: 9293536 DOI: 10.1111/j.1440-1827.1997.tb04539.x]
- 47 **Shi H**, Zhen T, Zhang F, Dong Y, Han A. Multifocal epithelioid angiosarcoma of the jejunum: a case report. *Pathology* 2016; **48**: 91-93 [PMID: 27020220 DOI: 10.1016/j.pathol.2015.11.013]
- 48 **Delvaux V**, Sciort R, Neuville B, Moerman P, Peeters M, Filez L, Van Beckevoort D, Ectors N, Geboes K. Multifocal

- epithelioid angiosarcoma of the small intestine. *Virchows Arch* 2000; **437**: 90-94 [PMID: 10963385 DOI: 10.1007/s004280000183]
- 49 **De Francesco V**, Bellesia A, Corsi F, Pennella A, Ridola L, Zullo A. Multifocal Gastrointestinal Angiosarcoma: a Challenging Diagnosis? *J Gastrointest Liver Dis* 2015; **24**: 519-522 [PMID: 26697580 DOI: 10.15403/jgld.2014.1121.244.asm]
 - 50 **Witt D**, Spenney JG, Peter S, Edwards AL. Not All That Ulcerates Is Crohn's: A Malignant Mimic of Small Bowel Crohn's Disease. *Am J Gastroenterol* 2019; **114**: S1408
 - 51 **Navarro-Chagoya D**, Figueroa-Ruiz M, López-Gómez J, Nava-Leyva H, Álvarez-Ponce CE, Guzmán-Sombrero G, Velazquez-García J. Obscure gastrointestinal bleeding due to multifocal intestinal angiosarcoma. *Int J Surg Case Rep* 2015; **10**: 169-172 [PMID: 25853844 DOI: 10.1016/j.ijscr.2015.03.049]
 - 52 **Kolli S**, Chan O, Choy CG, Ona MA. Outlasting a Rare Duodenal Angiosarcoma. *Cureus* 2019; **11**: e5097 [PMID: 31523530 DOI: 10.7759/cureus.5097]
 - 53 **Bruixola G**, Díaz-Beveridge R, Jiménez E, Caballero J, Salavert M, Escoin C, Aparicio J. Pleuropulmonary angiosarcoma involving the liver, the jejunum and the spine, developed from chronic tuberculosis pyothorax: Multidisciplinary approach and review of literature. *Lung Cancer* 2014; **86**: 105-111 [PMID: 25097031 DOI: 10.1016/j.lungcan.2014.07.012]
 - 54 **Policarpio-Nicolas ML**, Nicolas MM, Keh P, Laskin WB. Postradiation angiosarcoma of the small intestine: a case report and review of literature. *Ann Diagn Pathol* 2006; **10**: 301-305 [PMID: 16979525 DOI: 10.1016/j.anndiagpath.2005.09.006]
 - 55 **Policarpio-Nicolas ML**, Nicolas MM, Keh P, Laskin WB. Postradiation angiosarcoma of the small intestine: a case report and review of literature. *Ann Diagn Pathol* 2006; **10**: 301-305 [PMID: 16979525 DOI: 10.1016/j.anndiagpath.2005.09.006]
 - 56 **Zemheri E**, Engin P, Ozkanli S, Ozemir IA. Primary Angiosarcoma of Small Intestine Presenting With Intestinal Perforation: A Case Report. *J Med Cases* 2014; **5**: 113-115 [DOI: 10.14740/jmc1653w]
 - 57 **Ni Q**, Shang D, Peng H, Roy M, Liang G, Bi W, Gao X. Primary angiosarcoma of the small intestine with metastasis to the liver: a case report and review of the literature. *World J Surg Oncol* 2013; **11**: 242 [PMID: 24067058 DOI: 10.1186/1477-7819-11-242]
 - 58 **Gupta A**, Mehendiratta M, Sareen C, Aggarwal A. Primary Paranasal Tuberculosis in a Diabetic Mimicking Odontogenic Infection: A Rare Case; A Unique Presentation. *J Clin Diagn Res* 2016; **10**: ZD19-ZD21 [PMID: 27135017 DOI: 10.7860/JCDR/2016/17195.7501]
 - 59 **Jayaraman V**, Wilkinson MN, Nagula S, Siebel M, Bucobo JC, Zee S, Buscaglia JM. Primary jejunal angiosarcoma: an extremely rare tumor diagnosed by means of anterograde spiral enteroscopy. *Endoscopy* 2011; **43** Suppl 2 UCTN: E219-E220 [PMID: 21590614 DOI: 10.1055/s-0030-1256397]
 - 60 **Squillaci S**, Marasco A, Pizzi G, Chiarello M, Brisinda G, Tallarigo F. Primary post-radiation angiosarcoma of the small bowel. Report of a case and review of the literature. *Pathologica* 2020; **112**: 93-101 [PMID: 32760052 DOI: 10.32074/1591-951X-3-20]
 - 61 **Wen YY**, Fang S, Zheng Z, Qian LY, Wei JG. Primary small intestinal epithelioid angiosarcoma: a potential diagnostic pitfall due to abnormal expression of cytokeratin. 2020. Available from: <https://www.researchsquare.com/article/rs-13949/v1>
 - 62 **Hansen SH**, Holck S, Flyger H, Tange UB. Radiation-associated angiosarcoma of the small bowel. A case of multiploidy and a fulminant clinical course. Case report. *APMIS* 1996; **104**: 891-894 [PMID: 9048867]
 - 63 **Nanus DM**, Kelsen D, Clark DG. Radiation-induced angiosarcoma. *Cancer* 1987; **60**: 777-779 [PMID: 3297296 DOI: 10.1002/1097-0142(19870815)60:4<777::aid-cnrc2820600412>3.0.co;2-t]
 - 64 **Grewal JS**, Daniel AR, Carson EJ, Catanzaro AT, Shehab TM, Tworek JA. Rapidly progressive metastatic multicentric epithelioid angiosarcoma of the small bowel: a case report and a review of literature. *Int J Colorectal Dis* 2008; **23**: 745-756 [PMID: 18080128 DOI: 10.1007/s00384-007-0420-x]
 - 65 **Darr U**, Pak S, Khan Z, Srour K, Nawras A. Rare Presentation of Small Intestinal Angiosarcoma in an Elderly Gentleman. *Am J Gastroenterol* 2017; **112**: S1324
 - 66 **Thurner Jr JE**, Graf AH, Walter A, Hacker GW. Small Bleeding Hemangiosarcoma of the Jejunum: Case Report and Immunocytochemical Findings. *J Histotechnol* 1990; **13**: 141-5
 - 67 **Ogawa S**, Minowa O, Ozaki Y, Kuwatsuru R, Sumi Y, Maehara T. Small bowel intussusception caused by intestinal angiosarcomatosis: usefulness of MR enteroclysis with infusion of water through a nasojejunal catheter. *Eur Radiol* 2002; **12**: 534-536 [PMID: 11870466 DOI: 10.1007/s003300101021]
 - 68 **Uchihara T**, Imamura Y, Iwagami S, Kajihara I, Kanemaru H, Karashima R, Ida S, Ishimoto T, Baba Y, Sakamoto Y, Miyamoto Y, Yoshida N, Watanabe M, Iyama K, Ihn H, Baba H. Small bowel perforation due to indistinguishable metastasis of angiosarcoma: case report and brief literature review. *Surg Case Rep* 2016; **2**: 42 [PMID: 27156097 DOI: 10.1186/s40792-016-0169-y]
 - 69 **Kelemen K**, Yu QQ, Howard L. Small intestinal angiosarcoma leading to perforation and acute abdomen: a case report and review of the literature. *Arch Pathol Lab Med* 2004; **128**: 95-98 [PMID: 14692839 DOI: 10.5858/2004-128-95-SIALTP]
 - 70 **Liu DS**, Smith H, Lee MM, Djeri M. Small intestinal angiosarcoma masquerading as an appendiceal abscess. *Ann R Coll Surg Engl* 2013; **95**: e22-e24 [PMID: 23317721 DOI: 10.1308/rcsann.2013.95.6.e22]
 - 71 **Zacarias Föhrding L**, Macher A, Braunstein S, Knoefel WT, Topp SA. Small intestine bleeding due to multifocal angiosarcoma. *World J Gastroenterol* 2012; **18**: 6494-6500 [PMID: 23197897 DOI: 10.3748/wjg.v18.i44.6494]
 - 72 **Aitola P**, Poutiainen A, Nordback I. Small-bowel angiosarcoma after pelvic irradiation: a report of two cases. *Int J Colorectal Dis* 1999; **14**: 308-310 [PMID: 10663901 DOI: 10.1007/s003840050235]
 - 73 **Knop FK**, Hansen MB, Meisner S. Small-bowel hemangiosarcoma and capsule endoscopy. *Endoscopy* 2003; **35**: 637 [PMID: 12822111 DOI: 10.1055/s-2003-40224]
 - 74 **Hsu JT**, Lin CY, Wu TJ, Chen HM, Hwang TL, Jan YY. Splenic angiosarcoma metastasis to small bowel presented with gastrointestinal bleeding. *World J Gastroenterol* 2005; **11**: 6560-6562 [PMID: 16425436 DOI: 10.3748/wjg.v11.i41.6560]
 - 75 **Hori S**, Tachihara M, Tamura D, Kobayashi K, Nakata K, Kamiryo H, Sakai Y, Itoh T, Hirose T, Nishimura Y. Spontaneous Regression of Epithelioid Angiosarcoma in a Young Woman. *Intern Med* 2017; **56**: 3333-3339 [PMID: 29021485 DOI: 10.2169/internalmedicine.6754-15]

- 76 **Tamura K**, Matsuda K, Ito D, Sakanaka T, Tamiya M, Hyo T, Kitano M, Yamaue H. Successful endoscopic diagnosis of angiosarcoma of the small intestine: A case report. *DEN Open* 2022; **2**: e24 [PMID: [35310717](#) DOI: [10.1002/deo2.24](#)]
- 77 **Ruffolo C**, Angriman I, Montesco MC, Scarpa M, Polese L, Barollo M, Pagano D, D'Amico DF. Unusual cause of small bowel perforation: metastasis of a subcutaneous angiosarcoma of the head. *Int J Colorectal Dis* 2005; **20**: 551-552 [PMID: [15650826](#) DOI: [10.1007/s00384-004-0684-3](#)]
- 78 **Miettinen M**, Lasota J. Gastrointestinal stromal tumors--definition, clinical, histological, immunohistochemical, and molecular genetic features and differential diagnosis. *Virchows Arch* 2001; **438**: 1-12 [PMID: [11213830](#) DOI: [10.1007/s004280000338](#)]
- 79 **Miettinen M**, Sarlomo-Rikala M, Lasota J. KIT expression in angiosarcomas and fetal endothelial cells: lack of mutations of exon 11 and exon 17 of C-kit. *Mod Pathol* 2000; **13**: 536-541 [PMID: [10824925](#) DOI: [10.1038/modpathol.3880093](#)]
- 80 **Florou V**, Wilky BA. Current and Future Directions for Angiosarcoma Therapy. *Curr Treat Options Oncol* 2018; **19**: 14 [PMID: [29520447](#) DOI: [10.1007/s11864-018-0531-3](#)]
- 81 **Goerdts LV**, Schneider SW, Booken N. Cutaneous Angiosarcomas: Molecular Pathogenesis Guides Novel Therapeutic Approaches. *J Dtsch Dermatol Ges* 2022; **20**: 429-443 [PMID: [35218306](#) DOI: [10.1111/ddg.14694](#)]



Published by **Baishideng Publishing Group Inc**
7041 Koll Center Parkway, Suite 160, Pleasanton, CA 94566, USA

Telephone: +1-925-3991568

E-mail: bpgoffice@wjgnet.com

Help Desk: <https://www.f6publishing.com/helpdesk>

<https://www.wjgnet.com>

