

# World Journal of *Gastroenterology*

*World J Gastroenterol* 2023 August 14; 29(30): 4604-4705



## Contents

Weekly Volume 29 Number 30 August 14, 2023

## REVIEW

- 4604 Immune response modulation in inflammatory bowel diseases by *Helicobacter pylori* infection  
*Feilstrecker Balani G, dos Santos Cortez M, Picasky da Silveira Freitas JE, Freire de Melo F, Zarpelon-Schutz AC, Teixeira KN*
- 4616 *Helicobacter pylori* intragastric colonization and migration: Endoscopic manifestations and potential mechanisms  
*Mu T, Lu ZM, Wang WW, Feng H, Jin Y, Ding Q, Wang LF*

## MINIREVIEWS

- 4628 Systemic treatments for resectable carcinoma of the esophagus  
*Leowattana W, Leowattana P, Leowattana T*

## ORIGINAL ARTICLE

## Basic Study

- 4642 Exploring the regulatory mechanism of tRNA-derived fragments 36 in acute pancreatitis based on small RNA sequencing and experiments  
*Fan XR, Huang Y, Su Y, Chen SJ, Zhang YL, Huang WK, Wang H*
- 4657 Fecal microbiota transplantation alleviates experimental colitis through the Toll-like receptor 4 signaling pathway  
*Wen X, Xie R, Wang HG, Zhang MN, He L, Zhang MH, Yang XZ*

## Observational Study

- 4671 Incidence, prevalence, and comorbidities of chronic pancreatitis: A 7-year population-based study  
*Cai QY, Tan K, Zhang XL, Han X, Pan JP, Huang ZY, Tang CW, Li J*

## META-ANALYSIS

- 4685 Diagnostic value of conventional endoscopic ultrasound for lymph node metastasis in upper gastrointestinal neoplasia: A meta-analysis  
*Chen C, Song YL, Wu ZY, Chen J, Zhang Y, Chen L*

## LETTER TO THE EDITOR

- 4701 Pitfalls and promises of bile duct alternatives: There is plenty of room in the regenerative surgery  
*Klabukov ID, Baranovskii DS, Shegay PV, Kaprin AD*

**ABOUT COVER**

Editorial Board Member of *World Journal of Gastroenterology*, Goran Hauser, FEBG, MD, PhD, Professor, Department of Internal Medicine, Division of Gastroenterology, Clinical Hospital Centre, Faculty of Medicine Rijeka-University of Rijeka, Rijeka 51000, Croatia. [goran.hauser@medri.uniri.hr](mailto:goran.hauser@medri.uniri.hr)

**AIMS AND SCOPE**

The primary aim of *World Journal of Gastroenterology* (WJG, *World J Gastroenterol*) is to provide scholars and readers from various fields of gastroenterology and hepatology with a platform to publish high-quality basic and clinical research articles and communicate their research findings online. WJG mainly publishes articles reporting research results and findings obtained in the field of gastroenterology and hepatology and covering a wide range of topics including gastroenterology, hepatology, gastrointestinal endoscopy, gastrointestinal surgery, gastrointestinal oncology, and pediatric gastroenterology.

**INDEXING/ABSTRACTING**

The WJG is now abstracted and indexed in Science Citation Index Expanded (SCIE, also known as SciSearch®), Current Contents/Clinical Medicine, Journal Citation Reports, Index Medicus, MEDLINE, PubMed, PubMed Central, Scopus, Reference Citation Analysis, China National Knowledge Infrastructure, China Science and Technology Journal Database, and Superstar Journals Database. The 2023 edition of Journal Citation Reports® cites the 2022 impact factor (IF) for WJG as 4.3; IF without journal self cites: 4.1; 5-year IF: 5.3; Journal Citation Indicator: 0.82; Ranking: 33 among 93 journals in gastroenterology and hepatology; and Quartile category: Q2. The WJG's CiteScore for 2021 is 8.3 and Scopus CiteScore rank 2022: Gastroenterology is 22/149.

**RESPONSIBLE EDITORS FOR THIS ISSUE**

Production Editor: *Ying-Yi Yuan*; Production Department Director: *Xu Guo*; Editorial Office Director: *Jia-Ru Fan*.

**NAME OF JOURNAL**

*World Journal of Gastroenterology*

**ISSN**

ISSN 1007-9327 (print) ISSN 2219-2840 (online)

**LAUNCH DATE**

October 1, 1995

**FREQUENCY**

Weekly

**EDITORS-IN-CHIEF**

Andrzej S Tarnawski

**EDITORIAL BOARD MEMBERS**

<http://www.wjgnet.com/1007-9327/editorialboard.htm>

**PUBLICATION DATE**

August 14, 2023

**COPYRIGHT**

© 2023 Baishideng Publishing Group Inc

**INSTRUCTIONS TO AUTHORS**

<https://www.wjgnet.com/bpg/gerinfo/204>

**GUIDELINES FOR ETHICS DOCUMENTS**

<https://www.wjgnet.com/bpg/GerInfo/287>

**GUIDELINES FOR NON-NATIVE SPEAKERS OF ENGLISH**

<https://www.wjgnet.com/bpg/gerinfo/240>

**PUBLICATION ETHICS**

<https://www.wjgnet.com/bpg/GerInfo/288>

**PUBLICATION MISCONDUCT**

<https://www.wjgnet.com/bpg/gerinfo/208>

**ARTICLE PROCESSING CHARGE**

<https://www.wjgnet.com/bpg/gerinfo/242>

**STEPS FOR SUBMITTING MANUSCRIPTS**

<https://www.wjgnet.com/bpg/GerInfo/239>

**ONLINE SUBMISSION**

<https://www.f6publishing.com>



## Systemic treatments for resectable carcinoma of the esophagus

Wattana Leowattana, Pathomthep Leowattana, Tawitthep Leowattana

**Specialty type:** Gastroenterology and hepatology

**Provenance and peer review:** Invited article; Externally peer reviewed.

**Peer-review model:** Single blind

**Peer-review report's scientific quality classification**

Grade A (Excellent): A  
Grade B (Very good): 0  
Grade C (Good): C, C  
Grade D (Fair): 0  
Grade E (Poor): 0

**P-Reviewer:** Ogino S, United States; Tan X, China; Wang LH, China

**Received:** May 10, 2023

**Peer-review started:** May 10, 2023

**First decision:** July 9, 2023

**Revised:** July 18, 2023

**Accepted:** July 28, 2023

**Article in press:** July 28, 2023

**Published online:** August 14, 2023



**Wattana Leowattana, Pathomthep Leowattana,** Department of Clinical Tropical Medicine, Faculty of Tropical Medicine, Mahidol University, Rachatawee 10400, Bangkok, Thailand

**Tawitthep Leowattana,** Department of Medicine, Faculty of Medicine, Srinakharinwirot University, Wattana 10110, Bangkok, Thailand

**Corresponding author:** Wattana Leowattana, BMed, MD, MSc, PhD, Professor, Department of Clinical Tropical Medicine, Faculty of Tropical Medicine, Mahidol University, 420/6 Rajavithi road, Rachatawee 10400, Bangkok, Thailand. [wattana.leo@mahidol.ac.th](mailto:wattana.leo@mahidol.ac.th)

### Abstract

One of the most prevalent malignancies in the world is esophageal cancer (EC). The 5-year survival rate of EC remains pitiful despite treatment advancements. Neoadjuvant chemoradiotherapy in conjunction with esophagectomy is the standard of care for patients with resectable disease. The pathological complete response rate, however, is not acceptable. A distant metastasis or a locoregional recurrence will occur in about half of the patients. To increase the clinical effectiveness of therapy, it is consequently vital to investigate cutting-edge and potent therapeutic modalities. The approach to the management of resectable EC using immunotherapy has been considerably altered by immune checkpoint inhibitors. Systemic immunotherapy has recently been shown to have the potential to increase the survival of patients with resectable EC, according to growing clinical data. A combination of chemotherapy, radiation, and immunotherapy may have a synergistic antitumor impact because, according to mounting evidence, these treatments can stimulate the immune system *via* a number of different pathways. In light of this, it makes sense to consider the value of neoadjuvant immunotherapy for patients with surgically treatable EC. In this review, we clarify the rationale for neoadjuvant immunotherapy in resectable EC patients, recap the clinical outcomes of these approaches, go through the upcoming and ongoing investigations, and emphasize the difficulties and unmet research requirements.

**Key Words:** Systemic treatment; Resectable carcinoma of the esophagus; Personalized medicine; Biomarkers; Chemotherapy; Chemoradiotherapy; Immunotherapy; Immune checkpoint inhibitors

©The Author(s) 2023. Published by Baishideng Publishing Group Inc. All rights reserved.

**Core Tip:** Despite improvements in neoadjuvant and adjuvant treatment approaches in recent years, the average life expectancy of patients with resectable esophageal cancer (EC) still falls below 5 years. Immunotherapy has been effectively used as a first-line therapy for many oncological diseases at advanced stages for over ten years. Immunotherapy drugs are also making great progress in resectable situations, while it is still debatable whether this treatment should be limited to a certain patient subgroup based on biomarker selection. In order to treat resectable EC, immunotherapy, in particular immune checkpoint inhibitors, has made significant strides. This review also provides a brief overview of potential ongoing clinical studies.

**Citation:** Leowattana W, Leowattana P, Leowattana T. Systemic treatments for resectable carcinoma of the esophagus. *World J Gastroenterol* 2023; 29(30): 4628-4641

**URL:** <https://www.wjgnet.com/1007-9327/full/v29/i30/4628.htm>

**DOI:** <https://dx.doi.org/10.3748/wjg.v29.i30.4628>

## INTRODUCTION

With over 544000 expected deaths from esophageal cancer (EC) in 2020, EC is the sixth most common cancer-related cause of death globally. In East Asia, esophageal squamous cell carcinoma (ESCC) covers up around 90% of cases of EC, in contrast to Western nations[1-3]. Surgery continues to be the therapy of choice for early-stage EC. Unfortunately, the majority of EC patients are stage 4 or advanced stage at the time of diagnosis, and only surgery has a modest impact, hence a 5-year survival rate is only 25%. Systemic treatment, as opposed to surgery alone, may increase survival for resectable locally advanced EC. As a result, preoperative systemic treatment combined with surgery has become the norm for treating EC patients. Despite this, approximately half of these patients experience local recurrence or distant metastases following surgery[4-6]. To enhance survival, it is therefore vital to investigate innovative and effective therapies. Immune checkpoint inhibitors (ICIs) have recently made substantial advancements in a range of malignancies, including EC, with several trials demonstrating longer overall survival (OS), a higher objective response rate (ORR), and a decreased frequency of grade 3-5 adverse events (AEs) as second-line therapy. According to the most recent findings, treating resectable EC patients as first-line therapy with programmed death 1 (PD-1) inhibitors combined with chemotherapy resulted in considerably longer progression-free survival (PFS) and OS than treatment with only chemotherapy. These findings imply that ICIs have a bright future in EC management. ICI systemic treatment is now being extensively researched for EC patients and has been tested in a number of malignancies[7-10]. The rationale for ICI neoadjuvant treatment in EC, the published findings, the upcoming and ongoing studies, the unanswered questions, and the suggestions for more research will all be included in this review.

## ROLE OF DIET AND MICROBIOTA IN EC

Some of the traditional risk factors for EC seem to be linked to changes in the esophagus' natural microbiome. In ESCC patients, drinking alcohol has been connected to changes in the microbiota's diversity. In animal studies, high-fat diets have been related to esophageal dysplasia and changes in the microbiome. Gram-negative organisms, which are present in lesions that are precursors to EC, were shown to be more prevalent in those who consumed less fiber. Changes in the esophagus bacterial population have been linked to smoking and medications like proton pump inhibitors and antibiotics. Firmicutes, Proteobacteria, Bacteroidetes, Actinobacteria, and Fusobacteria make up the majority of the microbiota in a healthy esophagus. In comparison, reduced microbial diversity, which appears to start in the precursor stages of EC, is a characteristic of malignancy of the esophagus. The EC microbiome is distinguished at the taxonomic level by a switch from Gram-positive to Gram-negative bacteria. The genera *Fusobacterium*, *Streptococcus*, *Veillonella*, and *Prevotella* are those that are most often enriched in EC. Although particular changes in the EC microbiome can be detected, a consistent microbiota profile linked with EC has not yet been discovered. The varied technical processes, such as the sampling strategy, the types of samples examined, and the analytic approach used to profile the microbiome, as well as the relatively small number of people participated in each experiment, may be to blame for this discrepancy. Future research should take method standardization into account. To study and integrate the impacts of various exposures, including those of nutrition, with the microbiome and the changes that occur during the carcinogenesis process, multidisciplinary research efforts will be necessary. This is especially true in studies of esophageal carcinogenesis associated with the microbiome. Large, well-characterized prospective cohort studies would be beneficial for dissecting these complicated connections, and they would undoubtedly aid in the development of creative preventive and treatment plans that would lessen the incidence of EC[11].

## SYSTEMIC TREATMENT OPTIONS FOR RESECTABLE EC

Squamous cell carcinoma and adenocarcinoma, the two principal histological forms of EC, have very different epidemi-



ologies. To some extent, the therapy choices for these two categories differ. The two main therapeutic options for EC are local and systemic therapies. The tumor's histological type, location, extension, and size can all contribute to guiding therapy selections. Endoscopic and surgical resection are the primary treatments for locally advanced EC. Lymphatic node metastases arise early in EC due to the extensive lymphatic drainage in the esophagus submucosa, and the cancer is frequently detected at an advanced stage[12]. For resectable EC, the main systemic treatment options include neoadjuvant chemotherapy (NCT), neoadjuvant chemoradiotherapy (NCRT), and perioperative chemotherapy (PCT). According to the most recent National Comprehensive Cancer Network guidelines for esophageal and esophagogastric junction cancers, the optimal treatment options for both localized squamous cell carcinoma (SCC) and actinic cheilitis (AC) staged as Tis-T2 (low-risk lesions: < 3 cm, well-differentiated) without lymph node metastases include esophagectomy and endoscopic treatments. Patients with unresectable EC should get definitive chemoradiation. Current clinical research focuses mostly on locally progressed EC between the preferable single surgery and the recommended final chemoradiation. The systemic therapeutic approaches listed encompass NCT, NCRT, and PCT indicating a range between the two histological groups. As an adjuvant therapy, immunotherapy is employed[13].

The most prevalent subtype of EC in the world is ESCC, which manifests in the naturally occurring esophageal epithelium. An estimated 456000 people were diagnosed with EC in 2012, of whom 398000 had ESCC. Around 80% of ESCC cases worldwide were found in Central and Southeast Asia. More than half of all cases globally originated in China alone[14]. For 366 patients with locally advanced resectable esophageal or esophagogastric junctional cancer, NCRT that included carboplatin, paclitaxel, and concurrent 41.4 Gy radiotherapy was compared to surgery alone (178 for NCRT and surgery *vs.* 188 for surgery alone). A minimum projected follow-up term of 10 years was guaranteed by the follow-up period, which ended on December 31, 2018. In the first year, patients visited the outpatient clinic once every three months. In the second year, they visited once every six months, and so on until the fifth year, when they visited once a year. After 5 years of follow-up, patients with symptoms could visit the outpatient clinic. Participants in the chemoradiotherapy-surgery group survived more than those in the surgery arm, with 10-year OS rates of 38% and 25%, respectively. The respective 10-year OS rates in the chemoradiotherapy-surgery and surgery groups for patients with SCC were 46% and 23%, respectively, and 36% and 26% for patients with AC. Participants in the chemoradiotherapy-surgical group died from EC at a lower rate than those in the surgery arm, with 10-year absolute risks of 47% and 64%, respectively. Other causes of death were comparable in the chemoradiotherapy-surgery and surgery arms, with 10-year absolute risks of 15% and 11%, respectively. They concluded that the OS advantage of preoperative NCRT for patients with locally advanced resectable esophageal or junctional carcinoma, according to the ChemoRadiotherapy for Oesophageal cancer followed by Surgery Study (CROSS) study, lasts at least ten years[15].

NEOCRTEC 5010, a phase 3 randomized, open-label, multicenter, clinical trial, supported the findings of ESCC patients from the CROSS study. The NCRT group outperformed the surgery-only group in terms of R0 resection rate (98.4% *vs.* 91.2%), median OS (100.1 mo *vs.* 66.5 mo), and disease-free survival (DFS, 100.1 mos *vs.* 41.7 mos). According to the long-term efficacy of the NEOCRTEC 5010 research, the OS advantage in patients with locally advanced resectable ESCC who received the NCRT regimen was maintained for at least 10 years[16]. The CROSS trial also discovered that NCRT decreased solitary distant relapse (27% *vs.* 28%) but did not lessen isolated distant relapse (8% *vs.* 18%) or synchronous locoregional and distant relapse (13% *vs.* 22%). Relapse following NCRT is thus a critical obstacle to overcome[15].

Esophageal adenocarcinoma (EAC), also known as gastroesophageal adenocarcinoma or esophagogastric junction cancer, usually develops in the lower third of the esophagus. Obesity is its main risk factor since it mostly affects people with a history of gastroesophageal reflux disease[14]. About two-thirds of the histological categories of EC in high-income nations are AC. It is currently the most common histological type in seven high-income countries, including Canada, Denmark, Norway, Australia, New Zealand, Ireland, and the United Kingdom[17]. The CROSS-study's findings similarly positioned NCRT as the therapy of choice for resectable EAC, although superior NCRT effectiveness was shown in ESCC. As a result, depending on specific circumstances, PCT and NCT are different tactics. In order to successfully treat resectable EAC, PCT is crucial. The landmark-like phase 3 Medical Research Council Adjuvant Gastric Infusion Chemotherapy Study (MAGIC) initially showed the survival advantage of PCT in AC. This study revealed that patients with non-metastatic AC who had PCT with epirubicin, cisplatin, and fluorouracil (FU) had better PFS and OS. The MAGIC trial had more treatment-related AEs (TRAEs) than the CROSS study did[15,18]. The FU plus Leucovorin, Oxaliplatin, and Docetaxel triplet FU plus Leucovorin, Oxaliplatin, and Docetaxel (FLOT) regimen was used in a later, important phase 2/3 trial, the FLOT4 trial, which demonstrated superiority in R0 resection rate (85% *vs.* 78%) and median OS (50 mo *vs.* 35 mo). In recent score-matched research, the therapeutic effects of NCRT and PCT were contrasted. The findings demonstrated no discernible differences in tumor response or survival rates between these two common regimens. After PCT, there were more TRAEs (42/97 *vs.* 30/97)[19]. Another effective therapy for resectable EAC is NCT. Preoperative FU and cisplatin (FC) showed a survival benefit over surgery alone in the Medical Research Council OEO2 study[20,21]. The survival benefit remained at a median follow-up of 6 years [hazard ratio (HR), 0.84; 95% confidence interval (CI), 0.72-0.98; *P* = 0.03], while the cisplatin group had a better OS at 2 years (HR, 0.79; 95% CI, 0.67- 0.93; *P* = 0.004). Another sizable experiment, nevertheless, was unable to show the same result[22]. Triplet chemotherapy (epirubicin, cisplatin, and capecitabine) did not improve OS in the OE05 study. Additionally, it was connected to greater toxicity than FC[23]. NCT is therefore hardly employed.

A few noteworthy clinical studies on neoadjuvant therapy for resectable EC have recently been conducted. As a preoperative treatment for locally advanced ESCC, the NExT study seeks to demonstrate that docetaxel, cisplatin plus 5-FU (DCF), and radiotherapy with cisplatin plus 5-FU are superior than FC in terms of OS. The superior OS and manageable toxicity of DCF indicate a new standard therapeutic strategy for ESCC[24]. In 2021, Wang *et al*[25] conducted a prospective, multicenter, open-label, randomized clinical study on 264 patients with locally advanced ESCC to assess the efficacy and safety of NCRT *vs.* NCT followed by minimally invasive esophagectomy (MIE). The postoperative

morbidity rates of 264 patients, 47.4% in the NCRT group and 42.6% in the NCT group, did not significantly vary between the two groups. Based on the Clavien-Dindo classification, the degree of complications was distributed similarly across the two groups. For the NCRT group and the NCT group, the 90-day perioperative mortality rate was 3.5% and 2.8%, respectively. Patients in the NCRT group, however, showed higher rates of negative lymph nodes (66.1% *vs.* 46.2%) and pathologic complete responses (35.7% *vs.* 3.8%). They came to the conclusion that NCRT followed by MIE was safer and produced better histopathologic results than NCT followed by MIE for the treatment of locally advanced ESCC. According to a recent publication by Tang *et al* [26], among patients with cT3-4aN0-1M0 ESCC, NCRT followed by MIE was not significantly related to a better OS than NCT. The findings highlight the ongoing question of the ideal neoadjuvant therapeutic plan for locally progressing bulky ESCC. In the Neo-AEGIS study, 377 European patients were assigned at random to receive PCT, or CROSS. In the 3-year OS, the first OS analysis did not reveal any statistically significant differences (HR, 1.02; 95% CI, 0.74-1.42). However, the results must be taken seriously because the majority of the evaluable perioperative patients did not get the current standard of care FLOT (epirubicin, cisplatin and FU/epirubicin, cisplatin and capecitabine/epirubicin, oxaliplatin and FU/epirubicin, oxaliplatin and capecitabine prior to 2018, FLOT option 2019-2020, only 15% of chemotherapy arm patients received FLOT) [27].

## MOLECULAR MECHANISMS OF ICIS FOR EC TREATMENT

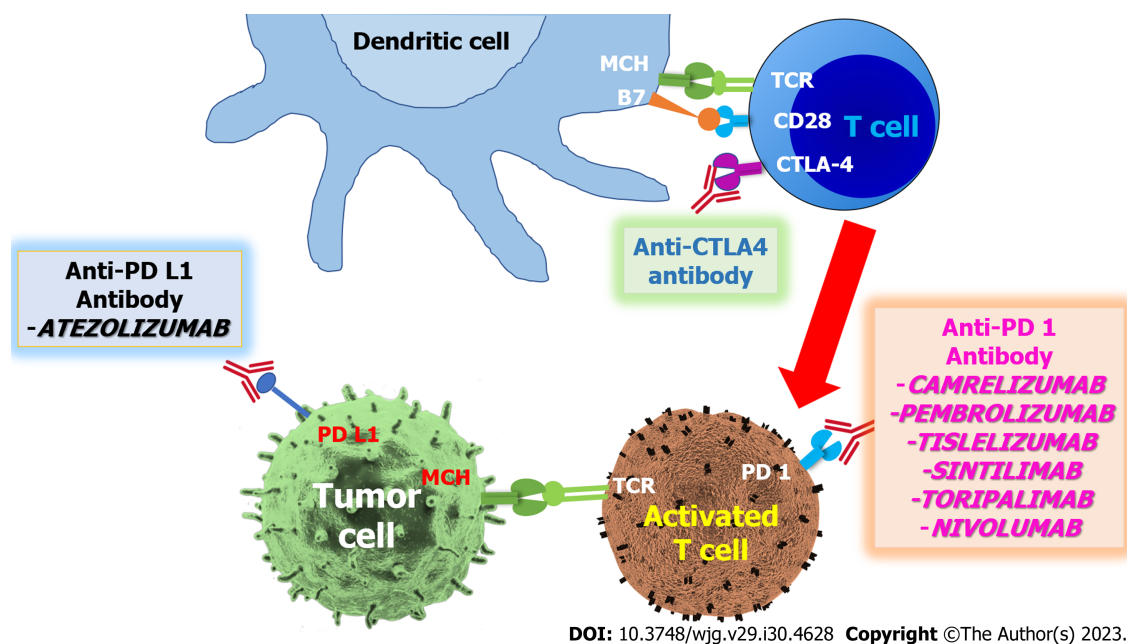
Utilizing one's own immune system to find and eliminate tumor cells is the goal of immunotherapy. Understanding the anti-tumor response and the strategies a malignancy may use to modify or inhibit the immune response has seen significant breakthroughs. This has made it possible for a new field of medicine to flourish, one that has shown considerable promise in treating conditions like EC that previously had a low survival rate. Our knowledge of the tumor microenvironment (TME) is one of the essential components for the creation of novel therapies. The TME is a complicated environment where a variety of immune and stromal cell subtypes interact to either promote or prevent tumor growth [28,29]. A crucial component of the immune response against tumors is the effector T cell. To maintain the immune system's equilibrium, negative regulators are produced on the surface of T cells during the activation process. Immune checkpoints are what they are known as. T cell activation, function, proliferation, and survival may be diminished when these immune checkpoints and their ligands are triggered during T cell receptor (TCR) signaling, which promotes tumor immune evasion. When compared to other solid tumor forms, EC is distinguished by having a significant amount of tumor-infiltrating T cells and monocytes/macrophages. The bulk of the tumor-infiltrating T cells are worn-out cluster of differentiation (CD) 8+ T cells and regulatory T cells (Tregs). Tregs, tumor-associated macrophages (TAMs), myeloid-derived suppressor cells, and cancer-associated fibroblasts all contribute to the immunosuppressive TME of EC through immune checkpoint-related mechanisms. The CD8+ T cells in the EC TME display high quantities of immunological checkpoint molecules such as the lymphocyte activation gene-3 (LAG-3), cytotoxic T lymphocyte antigen-4 (CTLA-4), programmed cell death PD-1, and programmed cell death-ligand (PD-L) 1 [30,31].

### PD-1 and PD-L1

Activated cytotoxic T cells and their primary ligands are the best examples of how PD-1 functions. Cancer cells and antigen-presenting cells (APCs) both have PD-L1 and PD-L2 molecules on their surfaces. T cell immunological fatigue is promoted by intracellular phosphorylation events that occur as a result of PD-1 engagement with its ligands, either through processes that depend on or are independent of TCR-CD28. The phosphoinositide 3-kinase route and the mitogen-activated protein kinase pathway are the two principals downstream signaling pathways involved in the TCR-CD28-dependent process. T cell depression that is not caused by TCR-CD28 is also caused by increased expression of the B-cell activating transcriptional factor [32-34]. CD8+ T cells in EC TME consistently exhibit significant levels of PD-1 expression. The findings of several clinical studies revealed that the objective response to immunotherapy was highly correlated with the high level of PD-L1 expression in EC tumor cells [35-37]. As a result, one of the suggested biomarkers for identifying EC patients who may benefit from ICIs is the degree of PD-L1 expression. Other than tumoral or healthy epithelial cells, TAMs play a significant role in the expression of PD-1 ligands in the EC TME. M2 polarization increases PD-L2 expression in TAMs and leads to immune evasion *via* the PD-1 signaling cascade regulated by the C-C motif chemokine ligand 2-C-C motif chemokine receptor 2 axis [38]. Additionally, TAMs showed PD-1 expression, which may increase PD-L1 expression in tumor cells. Increased CD8+ T cell abundance was seen in the responders in the clinical trials of PD-1 blockade therapy for EC, suggesting that the PD-1 inhibitors were successful in saving the worn-out T cells. To increase anti-tumor activity, these T cells settle on the tumor and fill the EC TME. Additionally, the decrease in the fraction of M2-type TAMs coincided with the rise in CD8+ T cell density, demonstrating that other innate immune cells in the EC TME were highly significant to the effectiveness of PD-1 blockade therapy for EC patients. In addition to the PD-1/PD-L1 pathway, interactions between PD-L1, CD80, and PD-L2-repulsive guidance molecule family member B are necessary for ICIs that target PD-L1 to be efficacious [39,40] (Figure 1).

### LAG-3

The precise signaling pathways downstream of LAG-3 are unclear, although it is known that LAG-3 has a distinct signaling route that is not shared by other immunological checkpoints. It is not unexpected that LAG-3 binds to major histocompatibility complex (MHC)-II given that their structures are comparable. However, the affinity of the interaction between LAG-3 and MHC-II is substantially stronger. LAG-3 affects CD8+ T cell activity as well, pointing to the possibility of new LAG-3 ligands. LAG-3 is one of the hallmarks of worn-out CD8+ T cells and is considerably overexpressed in ESCC. Positive LAG-3 expression strongly predicted lower recurrence-free survival and OS in ESCC patients



**Figure 1** The mechanisms of action of immune checkpoint inhibitors in resectable esophageal cancer immunotherapy. CD28: Cluster of differentiation 28; CTLA-4: Cytotoxic T lymphocyte antigen 4; MHC: Major histocompatibility complex; PD-1: Programmed cell death protein 1; PD-L1: Programmed death-ligand 1; TCR: T cell receptor.

and was significantly correlated with CTLA-4 expression. Strong correlations were found between high levels of CD8<sup>+</sup> tumor-infiltrating lymphocytes (TILs) in the EAC TME and high levels of LAG-3 expression. Research on individuals with unresectable EAC found connections between the LAG-3 gene and their response to the combination treatment of nivolumab and ipilimumab. Numerous LAG-3<sup>+</sup> CD8<sup>+</sup> T cells in the EAC TME are thought to be remnants of a robust anti-tumor immune response that was suppressed by PD-L1 and LAG-3-related mechanisms. The EAC patients who exhibit this TME trait are a good fit for ICIs. As a result, LAG-3 is a novel target for ICI's treatment of EC and is generating a lot of attention[41-44].

### CTLA-4

The engagement of the TCR by peptides from the MHC and crucial positive co-stimulatory signals produced by the interaction of CD80 (B7.1) or CD86 (B7.2) on the surface of APCs and CD28 on the surface of T cells are both necessary for T cell activation. This process is damaged by CTLA-4. Intracellularly stored CTLA-4 is transferred onto the surface of T cells during the initial stages of T cell activation, competing with CD80 with a higher affinity and diminishing the signal. Via phosphorylation reactions, CTLA-4 attenuates signals downstream of the TCR intrinsically after interacting with CD80. The primary professional APCs whose immunological capabilities are compromised in individuals with EC, along with a reduction in CD80 and CD86 expression, are dendritic cells. The high level of CTLA-4 expression on the surface of Tregs in the EC TME significantly contributes to immunosuppression. Further weakening the anti-tumor immune response, elevated expression of CTLA-4 is found in ESCC tumor cells on both an mRNA and protein level, in addition to effector T cells and Tregs in EC patients. Previous research has shown that ESCC patients with high tumor cell CTLA-4 expression had a poor prognosis, patients with ESCC who exhibited little tumor cell CTLA-4 expression, however, had a longer OS. Additionally, it's been proven that CD80 guards against metaplasia in inflammatory esophageal carcinogenesis, which is linked to EAC. In light of these findings, scientists developed ICIs that specifically target CTLA-4 to enhance EC's anti-tumor immunity. We still don't know how CTLA-4 blocking treatment impacts EC TME and effector T cells[45-47].

## ICIS FOR RESECTABLE EC TREATMENT

Neoadjuvant immunotherapy is the main subgroup of the clinical studies on ICI treatment for resectable EC. Camrelizumab, Pembrolizumab, Tremelimumab, Tislelizumab, Sintilimab, Atezolizumab, Nivolumab, Durvalumab, Relatlimab, Toripalimab, and IMC-001 were among the ICIs employed in these research. According to the CROSS-study's protocol, neoadjuvant immunotherapies are frequently used in conjunction with NCRT or NCT.

### Camrelizumab

The National Medical Products Administration has authorized the PD-1 inhibitor Camrelizumab as a first-line therapy for unresectable ESCC. The neoadjuvant use of Camrelizumab for resectable locally advanced ESCC has been the focus of a significant number of clinical trials, making it one of the most popular ICIs being studied for its therapeutic efficacy. The



majority of these trials have proven the beneficial effects of combining Camrelizumab with NCT and NCRT. In research done by Wu *et al*[48], 38 patients with resectable ESCC were examined to determine the effectiveness and safety of NCT coupled with immunotherapy. Pembrolizumab (55.26%) and Camrelizumab (31.58%) were the two drugs most often taken by patients. The results of their analysis of 19 individuals revealed that 13 patients (68.42%) had a radiological partial response (PR) on computed tomography scans. 35 patients (92.11%) underwent R0 resection, and postoperative problems occurred in 10 individuals (26.32%). A substantial positive correlation between the pathological remission rate and the regression rate of the sum of lesion diameters was also found. Major pathologic response (MPR) rates were 42.11% in ESCC patients.

In a trial by Liu *et al*[49,50], the primary endpoint was used to assess the safety as well as the efficacy of Camrelizumab with NCT in 60 patients with locally advanced ESCC. Fifty-five (91.7%) of these patients successfully completed the whole two-cycle therapy. Fifty-one patients had surgery, and 50 (98.0%) of them had R0 resection. Twenty patients (39.2%) had pathological complete response (pCR) (ypT0N0), while five patients (9%; ypT0N+) had a full response to the main tumor but persistent illness in the lymph nodes alone. Leukocytopenia (86.7%) was the most prevalent of the 58 TRAEs that affected individuals (96.7%). One patient (1.7% of patients) experienced a grade 5 adverse event, while 34 patients (56.7%) experienced AEs of grade 3 or worse. They stated that chemotherapy and Camrelizumab had strong anticancer effects that had been validated and shown without any unanticipated safety effects. These results demonstrated the efficacy of Camrelizumab with chemotherapy as a neoadjuvant therapy for locally advanced ESCC. It is necessary to conduct a phase 3 randomized controlled study to further illustrate potential survival gains (Table 1).

### Pembrolizumab

The United States Food and Drug Administration (FDA) has authorized the PD-1 inhibitor pembrolizumab as a first-line therapy for unresectable ESCC and EAC when combined with chemotherapy. Neoadjuvant immunotherapy has undergone clinical testing to treat both resectable ESCC and EAC. Preoperative Pembrolizumab with concurrent chemoradiotherapy for resectable locally advanced ESCC is being tested in the phase 1b, single-arm PALACE I trial, with safety as the main end measure. Of the 20 participants, 18 (90%) underwent surgery, and 19 (95%) received complete preoperative care. The patient had grade 3 lymphopenia and leukopenia, and she passed away while undergoing surgery, which is why the neoadjuvant therapy was not completed. The disease progression led to the discontinuation of surgery for one participant after full neoadjuvant therapy. All 20 patients experienced the development of TRAEs of any grade during the neoadjuvant therapy phase. The most frequent TRAEs were leukopenia (100%), lymphopenia (100%), anemia (80%), esophagitis (55%), alopecia (55%), and fatigue (55%), the majority of which were grade 1 or 2. With a pCR rate of 56% and a substantial pathological response of 89%, the R0 resection rate was 94%. All of the patients who received radical resection were free of disease recurrence at the median postoperative follow-up of 6.6 mo[51]. The PALACE II multicenter trial is still underway and has a larger sample size (143 participants), with pCR set as the major end measure[52]. Thirty-one eligible patients were included in a phase 1b/2 study to examine the effects of trimodal therapy with Pembrolizumab in the treatment of gastroesophageal junction (GEJ) adenocarcinoma. Twenty-eight individuals got R0 resection, and 29 of the 31 patients received all recommended doses of neoadjuvant Pembrolizumab. All safety criteria were satisfied. The primary efficacy goal was not attained [7/31 (22.6%)]. Individuals with high baseline expression of PD-L1 in the TME [combined positive score (CPS) > 10] had a substantially higher pCR rate than patients with low expression. Additionally, PFS and OS were longer for patients with high PD-L1 expression compared to propensity-score-matched patients. Extracellular vesicles (EV) were investigated to determine whether they may detect additional responders among trial participants with PD-L1 CPS < 10. A greater plasma level of PD-L1-expressing EVs was substantially linked with a higher pCR. They indicated that when Pembrolizumab was added to trimodal treatment, it did not achieve the intended pCR endpoint because of its satisfactory tolerability. Exploratory findings revealed that individuals who are most likely to achieve tumor response may be identified by having high levels of PD-L1 expression in the TME or on EVs[53].

Pembrolizumab in conjunction with chemotherapy and simple chemotherapy were compared for their effectiveness and safety in a trial by Huang *et al*[54], which involved 54 ESCC patients with stages II–IVa (23 in the combination group and 31 in the simple chemotherapy group). After two cycles of neoadjuvant therapy, major surgical intervention was given to all patients. They discovered that the combination group's pCR, ORR, and tumor regression 2 score were all considerably greater than those of the basic chemotherapy group (30.4% *vs.* 9.7% and 80.7% *vs.* 50.0%, respectively). Additionally, there was no statistically significant difference between the two groups' complete esophagectomy and R0/R1 resection rates. They concluded that pembrolizumab with chemotherapy demonstrated encouraging activity with a tolerable safety profile. Additionally, it might present a brand-new neoadjuvant treatment strategy for ESCC patients. In a single-arm study, Duan *et al*[55] evaluated the efficacy and safety of neoadjuvant pembrolizumab with chemotherapy in 18 patients with resectable ESCC. They found that postoperative pathology showed pCR in 6 cases (6/13, 46.2%) and MPR in 9 cases (9/13, 69.2%). Grade 3 or higher: Significant TRAEs occurred in 5 individuals (5/18, 27.8%). The amount of residual viable tumor (RVT) in pretreatment specimens was not substantially correlated with PD-L1 expression. While there was a weak association between postoperative forkhead box P3-positive+ T cells/CD4+ T cell ratios and RVT, there was a substantial correlation between changes in CD68+ macrophage counts between pre- and post-treatment specimens.

### Tislelizumab

Another inhibitor of PD-1 is Tislelizumab. Following systemic therapy, ESCCs that cannot be removed, have relapsed, or have spread have been approved for consideration by the FDA. Tislelizumab was combined with NCT in the TD-NICE study, a phase 2, single-arm clinical study. The MPR served as the study's main outcome indicator. Of the 45 patients, 36 had surgery and received comprehensive neoadjuvant care. Eighty percent of R0 resections were successful, with 72% of pCR and 50% of MPR. Leukopenia (73%), anemia (51%), and thrombocytopenia (49%) were the most prevalent TRAEs.

**Table 1 The immunotherapies for resectable esophageal cancer patients**

Name	Ref.	Number of patients	Treatment regimens	Outcome	Conclusion
Camrelizumab	Wu <i>et al</i> [48], 2021	12	Cisplatin + paclitaxel + camrelizumab = 8; carboplatin + paclitaxel + camrelizumab = 4	MPR, 5/7 (71.43%)	Patients with ESCC had an MPR rate of 42.11%; The SLD regression rate has a certain guiding relevance for the impact of immunotherapy, and the adoption of the NACI regimen may not raise the likelihood of problems in neoadjuvant treatment and surgery
Camrelizumab	Liu <i>et al</i> [49], 2022	60	Carboplatin + paclitaxel + camrelizumab	Proceeded to surgery, 51/60 (85.00%); R0 resection, 50/51 (98.00%); pCR, 5/20 (39.20%)	Camrelizumab plus weekly chemotherapy as a promising neoadjuvant treatment for locally advanced ESCC, and further phase 3 randomized controlled trial is warranted
Camrelizumab	Liu <i>et al</i> [50], 2022	56	Cisplatin + paclitaxel + camrelizumab	Proceeded to surgery, 51/56 (77.40%); pCR, 18/56 (39.20%); MPR, 12/56 (21.43%)	Camrelizumab plus neoadjuvant chemotherapy in resectable ESCC demonstrates promising efficacy with acceptable toxicity, providing a feasible and effective option
Pembrolizumab	Li <i>et al</i> [51], 2021	20	Carboplatin + paclitaxel + pembrolizumab + radiotherapy	Proceeded to surgery, 18/20 (90.00%); pCR, 10/18 (55.60%)	PPCT was safe and did not delay surgery in resectable EC
Pembrolizumab	Zhu <i>et al</i> [53], 2022	31	Carboplatin + paclitaxel + pembrolizumab + radiotherapy	Proceeded to surgery, 28/29 (96.55%); pCR, 7/31 (22.58%)	Incorporating anti-PD-1 therapy into neoadjuvant chemoradiation and adjuvant treatment of GEJ adenocarcinoma may improve pCR and survival
Pembrolizumab	Huang <i>et al</i> [54], 2021	54	Nedaplatin + docetaxel + pembrolizumab = 23 vs. nedaplatin + docetaxel = 31	pCR 30.4%/9.7%; ORR 86.9%/95.7%	Pembrolizumab combined with chemotherapy showed promising activity with a manageable safety profile and it could offer a potential new neoadjuvant treatment approach for patients with ESCC
Pembrolizumab	Duan <i>et al</i> [55], 2022	18	Nedaplatin + paclitaxel + pembrolizumab = 13 or nedaplatin + docetaxel + pembrolizumab = 5	Proceeded to surgery, 13/18 (72.22%); MPR, 9/13 (69.20%); pCR, 6/13 (46.15%)	The combination of neoadjuvant immunotherapy and chemotherapy for ESCC is associated with a high pathological response and immunologic effects in the tumor microenvironment
Tislelizumab	Yan <i>et al</i> [56], 2022	45	Carboplatin + paclitaxel + tislelizumab	Proceeded to surgery, 36/45 (80.00%); MPR (69.20%); pCR (50.00%)	Tislelizumab plus chemotherapy as neoadjuvant therapy demonstrates promising antitumor activity for resectable ESCC with high rates of MPR, pCR, and R0 resection, as well as acceptable tolerability
Sintilimab	Chen <i>et al</i> [57], 2023	30	Cisplatin + S1 + paclitaxel + sintilimab	Proceeded to surgery, 30/30 (100.00%); MPR (50.00%); pCR (20.00%)	Neoadjuvant sintilimab plus platinum-based triplet chemotherapy appeared safe and feasible, did not delay surgery and induced a pCR rate of 20.0% in patients with potentially resectable ESCC
Atezolizumab	van den Ende <i>et al</i> [58], 2021	40	Carboplatin + Paclitaxel + Atezolizumab + Radiotherapy	Proceeded to surgery, 33/40 (82.50%); MPR (50.00%); pCR, 10/40 (25.00%)	The addition of atezolizumab to conventional nCRT for resectable EC was feasible without compromising surgical outcomes
Toripalimab	Xing <i>et al</i> [59], 2021	30	Cisplatin + paclitaxel + toripalimab D3 vs. cisplatin + paclitaxel + toripalimab D1	Proceeded to surgery, 11/15 vs. 13/15; pCR 4/15 vs. 1/15	The study showed that delaying toripalimab to day 3 in chemoimmunotherapy might achieve a higher pCR rate than that on the same day
Toripalimab	He <i>et al</i> [60], 2022	20	Carboplatin + paclitaxel + toripalimab	Proceeded to surgery, 16/20; R0 resection, 14/16; MPR, 7/16; pCR, 4/16	The combination of toripalimab plus paclitaxel and carboplatin is safe, feasible, and effective in locally advanced resectable ESCC
Toripalimab	Gao <i>et al</i> [61], 2022	20	Cisplatin + docetaxel + toripalimab	ORR, 14/20; MPR, 5/12; pCR, 2/12	Toripalimab combined with docetaxel and cisplatin as a novel neoadjuvant therapy was safe and effective in locally advanced ESCC
Toripalimab	Zhang <i>et al</i> [62], 2023	60	S1 + paclitaxel + toripalimab	R0 resection, 55/60; MPR, 27/60; pCR, 16/60	Neoadjuvant therapy with toripalimab, nab-paclitaxel and S1 was less toxic and showed promising antitumor activity in patients with resectable ESCC
Nivolumab	Kelly <i>et al</i> [63], 2021	794	Chemoradiotherapy + nivolumab = 532 vs. chemoradiotherapy + placebo = 262	DFS, 22.4/11.0 mo; distant recurrence, 29/39%; locoregional recurrence, 12/17%	Nivolumab adjuvant treatment significantly increased DFS compared to placebo in patients with resected esophagus or gastroesophageal junction cancer who had received neoadjuvant chemoradiotherapy

DFS: Disease-free survival; EC: Esophageal cancer; ESCC: Esophageal squamous cell carcinoma; GEJ: Gastroesophageal junction; MPR: Major pathological

response; NACI: Neoadjuvant chemotherapy combined with immunotherapy; nCRT: Neoadjuvant chemoradiotherapy; ORR: Objective response rate; pCR: Pathological complete response; PD-1: Programmed cell death protein 1; SLD: Sum of lesion diameter; PPCT: Preoperative pembrolizumab with concurrent chemoradiotherapy.

Nineteen (42.2%) of the 45 patients had TRAEs in grades 3 to 4. Seventy-eight percent of the 36 individuals had postoperative problems. There were no surgical delays or deaths brought on by the therapy. They discovered that Tislelizumab in combination with chemotherapy as neoadjuvant therapy shows encouraging anticancer effectiveness for resectable ESCC with high rates of MPR, pCR, and R0 resection, as well as moderate tolerability[56].

### Sintilimab

Sintilimab, another PD-1 inhibitor, has been approved by the FDA for the treatment of certain subtypes of non-small cell lung cancer (NSCLC) and Hodgkin's lymphoma. The primary use of Sintilimab is as a neoadjuvant therapy for ESCC. In 30 patients with possibly resectable ESCC, Chen *et al*[57] performed a single-arm, phase 2, open-label study to evaluate the safety and surgical viability of intravenous Sintilimab preoperatively with triplet chemotherapy (cisplatin, liposomal paclitaxel, and S-1) for a total of two cycles every 3 wk. The MPR and pCR rates were discovered to be 50.0% and 20.0%, respectively. Patients were more likely to react if they had a greater TMB and more clonal mutations. Changes in the circulating tumor DNA high-releaser status and the v-erb-b2 avian erythroblastic leukemia viral oncogene homolog 2 are adversely linked with the response to neoadjuvant ICI. They discovered that neoadjuvant Sintilimab in conjunction with platinum-based triplet chemotherapy was safe and effective, did not delay surgery, and led to a 20.0% pCR rate in patients with ESCC who would be eligible for resection. A total of 36.7% (11/30) of patients experienced TRAEs of grades 3–4. Reduced neutrophil count (73.3%), anemia (76.7%), and reduced white cell count (76.7%) were the most common TRAEs. Hematological toxicities constituted all TRAEs. This confirmed that it was safe to use. To confirm the viability of the suggested approach, more investigation is needed.

### Atezolizumab

A PD-L1 inhibitor called Atezolizumab has been given FDA approval for the treatment of melanoma, NSCLC, small cell lung cancer, and some types of urothelial cancer. In the phase 2 feasibility trial PD-L1 Targeting in Resectable EC (PERFECT), NCRT is coupled with Atezolizumab to treat resectable EAC. The major end measure of this trial was feasibility, which was determined as the percentage of Atezolizumab treatments that were completed. Thirty-four (85%) of the 40 patients finished the full course of atezolizumab treatment. Any missed cycles were brought on by autoimmune-related toxicity ( $n = 3$ ), progression ( $n = 2$ ), and death ( $n = 1$ ). The R0 resection rate was 100% with 30% pCR. The PERFECT study had a median OS of 29.7 mo and a median PFS of 19.4 mo[58]. Fatigue (95%), mucositis (60%), nausea (53%), and anorexia (43%) were the most prevalent TRAEs. A grade 3–4 TRAE was encountered by 16 patients (40%). The three most prevalent symptoms were syncope (8%), nausea (8%), and anorexia (10%). The aforementioned TRAEs mostly took place during NCRT in conjunction with ICI. One patient who passed away from a pulmonary embolus had a grade 5 TRAE. Thirteen individuals (33%) had serious TRAEs that resulted in hospitalization or death.

### Toripalimab

The FDA authorized Toripalimab, an anti-PD-1 monoclonal antibody, for the treatment of ESCC, nasopharyngeal carcinoma, mucosal melanoma, and sarcoma. In order to assess the efficacy of neoadjuvant chemoimmunotherapy (Toripalimab) in 30 patients with locally advanced ESCC, Xing *et al*[59] conducted an open-label, randomized phase 2 investigation. The patients were divided into two groups: The experimental group, which got chemotherapy on day 1 and Toripalimab on day 3, and the control group, which received chemotherapy and Toripalimab on day 1. The patients were then randomly allocated to either group. Paclitaxel and cisplatin were the components of the chemotherapy regimen. Four to six weeks following the second course of chemoimmunotherapy, surgery was undertaken. They reported that 13 participants in the control group and 11 participants in the experimental group had surgery. In each of these 24 cases, a R0 resection was done. Four patients (36%) in the experimental group and one patient (7%) in the control group both achieved pCR. Statistically non-significantly increased pCR rates were observed in the experimental group. One patient in the control group had a PD-L1 CPS of 10, and pCR was achieved. The other 13 patients all had PD-L1 CPSs of 1, and 11 of the 13 underwent surgery, with two of the 13 patients (in the experimental group) attaining pCR. After one round of chemoimmunotherapy, two patients experienced grade 3 adverse effects, and one patient withdrew out of the research due to immune-related enteritis that was grade 3. After surgery, a second patient passed away from a severe lung infection and elevated troponin. They concluded that postponing Toripalimab until day 3 of chemotherapy could result in a greater pCR rate than that on the same day.

In a study conducted by He *et al*[60], 20 patients with locally advanced resectable ESCC were examined to determine the effectiveness of Toripalimab with paclitaxel and carboplatin as neoadjuvant treatment and the possible prognostic biomarkers. For the 16 patients who underwent surgery without a related delay in treatment, the R0 resection rate was 87.5% (14/16). The pCR rate was 18.8% (3/16), and the MPR rate was 43.8% (7/16) among the 16 patients. Following neoadjuvant treatment, the fraction of M2-type TAMs reduced, and the number of CD8+ T cells rose in surgical tissues. Responders had greater baseline C-X-C motif chemokine 5 gene expression levels and lower baseline chemokine (C-C motif) ligand 19 and uromodulin-like 1 gene expression levels. They concluded that the treatment of locally progressed resectable ESCC with the combination of Toripalimab, paclitaxel, and carboplatin is dependable, doable, and effective, indicating its promise as a neoadjuvant therapy for ESCC. An open-label, non-randomized, single-arm, single-center

phase 2 study also looked at Toripalimab for usage as neoadjuvant treatment in conjunction with Docetaxel and Cisplatin in 20 patients with locally advanced ESCC. The ORR was reported to be 70% (14/20). McKeown's MIE was performed on twelve individuals. Sixteen percent (2/12) of initial tumors achieved pCR, while 41.7% (5/12) of primary tumors achieved MPR. The median time before surgery was 33.2 d, and no patients had surgery delayed as a result of AEs from the medication. The most typical 30-day postoperative consequence (3/12, 25%) was pneumonia. Only 1 patient experienced anastomotic leakage while they were in the hospital. No patients passed away as a result of medical care or surgery. They concluded that Toripalimab was a safe and effective new neoadjuvant treatment for locally progressed ESCC when coupled with Docetaxel and Cisplatin[61]. Toripalimab combined with nab-Paclitaxel and S-1 was evaluated in a phase 2 single-center, open-label, single-arm study in 60 ESCC patients. They discovered that 55 patients (98.21%) had successful R0 resections. In 27 patients (49.09%) with MPR, pCR was attained in 16 individuals (29.09%). There were 37 (61.67%), 21 (35.00%), and 2 (3.33%) patients with PR, stable illness, and progressing disease, respectively. Following therapy, the overall staging, Stooler dysphagia scores, and daily living ability were considerably reduced. Eleven patients (18.3%) had grade 3 AEs. Patients with PD-L1-high levels exhibited a considerably greater PR ratio than those with PD-L1-low levels. In patients who had a PR, the TMB and tumor neoantigen burden considerably decreased with treatment[62].

### Nivolumab

The first immunotherapy to be recommended for resectable EC is adjuvant immunotherapy, which is appropriate for both ESCC and EAC with R0 resection following NCRT but staged as ypT-positive and/or N-positive. A PD-1 inhibitor known as Nivolumab is the ICI employed in this treatment plan. With a median follow-up of 24.4 mo, Kelly *et al* [63] conducted the worldwide, randomized, double-blind, placebo-controlled phase 3 study CheckMate 577 to assess Nivolumab as adjuvant treatment in 794 patients with esophageal or GEJ cancer. In contrast to the 262 patients who received a placebo, the authors found that the median DFS for the 532 individuals who received Nivolumab was 22.4 mo, as opposed to 11.0 mo for those who received the placebo (HR for disease recurrence or death, 0.69; 96.4% CI, 0.56 to 0.86;  $P = 0.001$ ). In the Nivolumab group, 71 of 532 patients (13%), and 15 of 260 (6%) patients in the placebo group, encountered grade 3 or higher AEs. The trial regimen was discontinued in 9% of participants receiving Nivolumab and 3% of patients receiving a placebo owing to adverse drug or placebo-related events. They concluded that DFS was significantly longer in patients with resectable esophageal or GEJ cancer who had received NCRT who got Nivolumab adjuvant treatment than in those who received a placebo.

## SUMMARY

Neoadjuvant ICIs are often used to treat ESCC patients, whereas perioperative ICIs are frequently used to treat EAC patients from the perspective of therapeutic models. This could be a result of NCRT having a better pathological outcome for ESCC than for EAC in earlier investigations[64]. A few clinical studies have moved into phase 3, and the majority are still in phase 2. It's important to be aware of phase 2 trial limitations, such as the limited sample size and lack of a control group. Trials investigating the use of ICIs in combination with NCRT, NCT, and PCT for resectable EC are still in their early phases in general. Credibility and generality are insufficient and need to be enhanced going forward. To get over these restrictions, multicenter or international phase 3 studies should be conducted. Very few studies have revealed the specifics of the response evaluation criteria and methodologies used in the various preoperative systemic therapy trials. The full metabolic response was the criterion used in the PALACE I investigation, which made use of the positron emission tomography-computed tomography scan. To help choose the best course of therapy, it is necessary to confirm how to more accurately gauge the reaction and specify the circumstances warranting surgery. TRAEs continue to endanger the safety of ICI therapy regimens, even if an acceptable rate of them has been recorded. All the research mentioned the above-mentioned TRAEs, and in certain situations, TRAE-related surgical delay or mortality happened. The safety of the ICIs is anticipated to drastically increase.

Immunotherapy for resectable EC patients primarily focuses on blocking the PD-1 and PD-L1 pathways, which have demonstrated impressive anti-tumor effects. But for some patients, ICIs treatment was ineffective, and in certain instances, medication resistance developed. PD-L1 expression in ESCC and microsatellite instability-high (MSI-H) or microsatellite instability-deficiency in mismatch repair are two indicators for successful ICIs treatment[65]. Unfortunately, PD-L1-positive ESCC did not significantly improve objective response to ICI treatment in a clinical investigation[66]. Furthermore, only 7% of EAC patients have MSI-H. Their predictive values are constrained. A critical issue that has to be solved is how to more effectively identify the EC patients who will benefit from PD-1 blocking treatment. A number of processes are involved in the PD-1/PD-L1 pathway's signaling process, such as chromosomal changes, mechanisms controlling molecule expression during and after transcription, and post-translational modification of molecules[67,68]. Scientists have identified various immune-related genes and chromosomal alterations unique to EC through the ongoing improvement of gene analysis techniques[69-71]. These are all possible biomarkers for EC patients who react to PD-1/PD-L1 blocking drugs. Furthermore, an immune-related long non-coding RNA signature of this pathway in ESCC was discovered, and it has the potential to be exploited as a stand-alone predictor of ESCC immunotherapy prognosis. PD-L1 expression inside the EC TME is now linked to immune infiltration frequency, which is what makes PD-1/PD-L1 blocking therapy beneficial. The frequencies of TILs, TAMs, CD8+ T cells, and Tregs are among the factors that are connected to clinical outcomes[72].

There aren't many active clinical studies of anti-CTLA-4 immunotherapy for resectable EC, in contrast to PD-1/PD-L1 blocking treatment. Severe TRAEs, the bulk of which were immune-related AEs (irAEs), limited the efficacy of CTLA-4 inhibiting therapy for a number of solid tumors. A deadly autoimmune illness is prevented by the intrinsic immune



checkpoint CTLA-4 on Tregs. Inhibiting CTLA-4 increases anti-cancer immunity but also upregulates auto-immune responses, leading to irAEs. For a safer and more effective immune checkpoint treatment, several scientists concluded that the CTLA-4 checkpoint should be preserved rather than blocked. Some people overcome this obstacle by creating anti-CTLA-4 antibodies that are specific to TMEs. There is an ongoing debate about whether CTLA-4-targeted immunotherapy should be permitted[73,74].

The immunosuppressive mechanism of LAG-3 is a recent area of study that has drawn a lot of interest. According to a recent study, MHC-II-independent fibrinogen-like protein 1 (FGL1) was a significant LAG-3 functional ligand. A poor prognosis and resistance to anti-PD-1 therapy are associated with high levels of FGL1 expression in the plasma of cancer patients, and it has been abundantly produced by human cancer cells[75,76]. The results of the clinical trial employing the Nivolumab and Relatlimab combination treatment for resectable EC may provide some insight into the riddle. Certainly, the positive results of immunotherapy for resectable EC in recent times give reason for optimism, but there are still many shortcomings to be overcome. The ICIs therapy for resectable EC will be ideal with a dependable effect and high safety in the next few days if these problems are promptly addressed.

## CONCLUSION

Although systemic immunotherapy has produced encouraging preliminary findings in resectable EC in some clinical studies, and although preoperative immunotherapy may potentially be more beneficial than adjuvant therapy, more confirmation of the feasibility, safety, and effectiveness of neoadjuvant immunotherapy in sizable randomized clinical trials is still needed. Additionally, before neoadjuvant ICI techniques can be extensively used as the standard of treatment, a number of unsolved concerns must be overcome. To choose the right populations, it will be essential to identify predictive biomarkers, and the function of adjuvant treatment must be clearly understood. In order to assess any delayed toxicity and ascertain the long-term consequences, long-term follow-up is also required. Systemic immunotherapy will undoubtedly enter a new phase soon.

## FOOTNOTES

**Author contributions:** Leowattana W wrote the paper; Leowattana T and Leowattana P collected the data.

**Conflict-of-interest statement:** The authors declare no conflicts of interest related to this article.

**Open-Access:** This article is an open-access article that was selected by an in-house editor and fully peer-reviewed by external reviewers. It is distributed in accordance with the Creative Commons Attribution NonCommercial (CC BY-NC 4.0) license, which permits others to distribute, remix, adapt, build upon this work non-commercially, and license their derivative works on different terms, provided the original work is properly cited and the use is non-commercial. See: <https://creativecommons.org/licenses/by-nc/4.0/>

**Country/Territory of origin:** Thailand

**ORCID number:** Wattana Leowattana 0000-0003-4257-2480; Tawitthep Leowattana 0000-0003-2316-3585.

**S-Editor:** Lin C

**L-Editor:** A

**P-Editor:** Cai YX

## REFERENCES

1. Sung H, Ferlay J, Siegel RL, Laversanne M, Soerjomataram I, Jemal A, Bray F. Global Cancer Statistics 2020: GLOBOCAN Estimates of Incidence and Mortality Worldwide for 36 Cancers in 185 Countries. *CA Cancer J Clin* 2021; **71**: 209-249 [PMID: 33538338 DOI: 10.3322/caac.21660]
2. Jiang Y, Lin Y, Wen Y, Fu W, Wang R, He J, Zhang J, Wang Z, Ge F, Huo Z, Peng H, Wu X, Li S. Global trends in the burden of esophageal cancer, 1990-2019: results from the Global Burden of Disease Study 2019. *J Thorac Dis* 2023; **15**: 348-364 [PMID: 36910098 DOI: 10.21037/jtd-22-856]
3. Huang J, Koulaouzidis A, Marlicz W, Lok V, Chu C, Ngai CH, Zhang L, Chen P, Wang S, Yuan J, Lao XQ, Tse SLA, Xu W, Zheng ZJ, Xie SH, Wong MCS. Global Burden, Risk Factors, and Trends of Esophageal Cancer: An Analysis of Cancer Registries from 48 Countries. *Cancers (Basel)* 2021; **13** [PMID: 33466239 DOI: 10.3390/cancers13010141]
4. Yang H, Liu H, Chen Y, Zhu C, Fang W, Yu Z, Mao W, Xiang J, Han Y, Chen Z, Yang H, Wang J, Pang Q, Zheng X, Li T, Lordick F, D'Journo XB, Cerfolio RJ, Korst RJ, Novoa NM, Swanson SJ, Brunelli A, Ismail M, Fernando HC, Zhang X, Li Q, Wang G, Chen B, Mao T, Kong M, Guo X, Lin T, Liu M, Fu J; AME Thoracic Surgery Collaborative Group. Neoadjuvant Chemoradiotherapy Followed by Surgery Versus Surgery Alone for Locally Advanced Squamous Cell Carcinoma of the Esophagus (NEOCRTEC5010): A Phase III Multicenter, Randomized, Open-Label Clinical Trial. *J Clin Oncol* 2018; **36**: 2796-2803 [PMID: 30089078 DOI: 10.1200/JCO.2018.79.1483]
5. Ajani JA, D'Amico TA, Bentrem DJ, Chao J, Corvera C, Das P, Denlinger CS, Enzinger PC, Fanta P, Farjah F, Gerdes H, Gibson M, Glasgow RE, Hayman JA, Hochwald S, Hofstetter WL, Ilson DH, Jaroszewski D, Johung KL, Keswani RN, Kleinberg LR, Leong S, Ly QP,



- Matkowskyj KA, McNamara M, Mulcahy MF, Paluri RK, Park H, Perry KA, Pimiento J, Poultides GA, Roses R, Strong VE, Wiesner G, Willett CG, Wright CD, McMillian NR, Pluchino LA. Esophageal and Esophagogastric Junction Cancers, Version 2.2019, NCCN Clinical Practice Guidelines in Oncology. *J Natl Compr Canc Netw* 2019; **17**: 855-883 [PMID: [31319389](#) DOI: [10.6004/jnccn.2019.0033](#)]
- 6 **Shapiro J**, van Lanschot JJB, Hulshof MCCM, van Hagen P, van Berge Henegouwen MI, Wijnhoven BPL, van Laarhoven HWM, Nieuwenhuijzen GAP, Hospers GAP, Bonenkamp JJ, Cuesta MA, Blaisse RJB, Busch ORC, Ten Kate FJW, Creemers GM, Punt CJA, Plukker JTM, Verheul HMW, Bilgen EJS, van Dekken H, van der Sangen MJC, Rozema T, Biermann K, Beukema JC, Piet AHM, van Rij CM, Reinders JG, Tilanus HW, Steyerberg EW, van der Gaast A; CROSS study group. Neoadjuvant chemoradiotherapy plus surgery versus surgery alone for oesophageal or junctional cancer (CROSS): long-term results of a randomised controlled trial. *Lancet Oncol* 2015; **16**: 1090-1098 [PMID: [26254683](#) DOI: [10.1016/S1470-2045\(15\)00040-6](#)]
- 7 **Shen L**, Kato K, Kim SB, Ajani JA, Zhao K, He Z, Yu X, Shu Y, Luo Q, Wang J, Chen Z, Niu Z, Zhang L, Yi T, Sun JM, Chen J, Yu G, Lin CY, Hara H, Bi Q, Satoh T, Pazo-Cid R, Arkenau HT, Borg C, Lordick F, Li L, Ding N, Tao A, Shi J, Van Cutsem E; RATIONALE-302 Investigators. Tislelizumab Versus Chemotherapy as Second-Line Treatment for Advanced or Metastatic Esophageal Squamous Cell Carcinoma (RATIONALE-302): A Randomized Phase III Study. *J Clin Oncol* 2022; **40**: 3065-3076 [PMID: [35442766](#) DOI: [10.1200/JCO.21.01926](#)]
- 8 **de Miguel M**, Calvo E. Clinical Challenges of Immune Checkpoint Inhibitors. *Cancer Cell* 2020; **38**: 326-333 [PMID: [32750319](#) DOI: [10.1016/j.ccell.2020.07.004](#)]
- 9 **Kojima T**, Shah MA, Muro K, Francois E, Adenis A, Hsu CH, Doi T, Moriwaki T, Kim SB, Lee SH, Bennouna J, Kato K, Shen L, Enzinger P, Qin SK, Ferreira P, Chen J, Girotto G, de la Fouchardiere C, Senellart H, Al-Rajabi R, Lordick F, Wang R, Suryawanshi S, Bhagia P, Kang SP, Metges JP; KEYNOTE-181 Investigators. Randomized Phase III KEYNOTE-181 Study of Pembrolizumab Versus Chemotherapy in Advanced Esophageal Cancer. *J Clin Oncol* 2020; **38**: 4138-4148 [PMID: [33026938](#) DOI: [10.1200/JCO.20.01888](#)]
- 10 **Luo H**, Lu J, Bai Y, Mao T, Wang J, Fan Q, Zhang Y, Zhao K, Chen Z, Gao S, Li J, Fu Z, Gu K, Liu Z, Wu L, Zhang X, Feng J, Niu Z, Ba Y, Zhang H, Liu Y, Zhang L, Min X, Huang J, Cheng Y, Wang D, Shen Y, Yang Q, Zou J, Xu RH; ESCORT-1st Investigators. Effect of Camrelizumab vs Placebo Added to Chemotherapy on Survival and Progression-Free Survival in Patients With Advanced or Metastatic Esophageal Squamous Cell Carcinoma: The ESCORT-1st Randomized Clinical Trial. *JAMA* 2021; **326**: 916-925 [PMID: [34519801](#) DOI: [10.1001/jama.2021.12836](#)]
- 11 **Moreira C**, Figueiredo C, Ferreira RM. The Role of the Microbiota in Esophageal Cancer. *Cancers (Basel)* 2023; **15** [PMID: [37174041](#) DOI: [10.3390/cancers15092576](#)]
- 12 **Tanaka T**, Ueno M, Iizuka T, Hoteya S, Haruta S, Udagawa H. Comparison of long-term outcomes between esophagectomy and chemoradiotherapy after endoscopic resection of submucosal esophageal squamous cell carcinoma. *Dis Esophagus* 2019; **32** [PMID: [30980070](#) DOI: [10.1093/dote/doz023](#)]
- 13 **Ajani JA**, D'Amico TA, Bentrem DJ, Cooke D, Corvera C, Das P, Enzinger PC, Enzler T, Farjah F, Gerdes H, Gibson M, Grierson P, Hofstetter WL, Ilson DH, Jalal S, Keswani RN, Kim S, Kleinberg LR, Klempner S, Lacy J, Licciardi F, Ly QP, Matkowskyj KA, McNamara M, Miller A, Mukherjee S, Mulcahy MF, Outlaw D, Perry KA, Pimiento J, Poultides GA, Reznik S, Roses RE, Strong VE, Su S, Wang HL, Wiesner G, Willett CG, Yakoub D, Yoon H, McMillian NR, Pluchino LA. Esophageal and Esophagogastric Junction Cancers, Version 2.2023, NCCN Clinical Practice Guidelines in Oncology. *J Natl Compr Canc Netw* 2023; **21**: 393-422 [PMID: [37015332](#) DOI: [10.6004/jnccn.2023.0019](#)]
- 14 **Arnold M**, Soerjomataram I, Ferlay J, Forman D. Global incidence of oesophageal cancer by histological subtype in 2012. *Gut* 2015; **64**: 381-387 [PMID: [25320104](#) DOI: [10.1136/gutjnl-2014-308124](#)]
- 15 **Eyck BM**, van Lanschot JJB, Hulshof MCCM, van der Wilk BJ, Shapiro J, van Hagen P, van Berge Henegouwen MI, Wijnhoven BPL, van Laarhoven HWM, Nieuwenhuijzen GAP, Hospers GAP, Bonenkamp JJ, Cuesta MA, Blaisse RJB, Busch OR, Creemers GM, Punt CJA, Plukker JTM, Verheul HMW, Spillenaar Bilgen EJ, van der Sangen MJC, Rozema T, Ten Kate FJW, Beukema JC, Piet AHM, van Rij CM, Reinders JG, Tilanus HW, Steyerberg EW, van der Gaast A; CROSS Study Group. Ten-Year Outcome of Neoadjuvant Chemoradiotherapy Plus Surgery for Esophageal Cancer: The Randomized Controlled CROSS Trial. *J Clin Oncol* 2021; **39**: 1995-2004 [PMID: [33891478](#) DOI: [10.1200/JCO.20.03614](#)]
- 16 **Yang H**, Liu H, Chen Y, Zhu C, Fang W, Yu Z, Mao W, Xiang J, Han Y, Chen Z, Yang H, Wang J, Pang Q, Zheng X, Li T, Zhang X, Li Q, Wang G, Chen B, Mao T, Kong M, Guo X, Lin T, Liu M, Fu J. Long-term Efficacy of Neoadjuvant Chemoradiotherapy Plus Surgery for the Treatment of Locally Advanced Esophageal Squamous Cell Carcinoma: The NEOCRTEC5010 Randomized Clinical Trial. *JAMA Surg* 2021; **156**: 721-729 [PMID: [34160577](#) DOI: [10.1001/jamasurg.2021.2373](#)]
- 17 **Morgan E**, Soerjomataram I, Gavin AT, Rutherford MJ, Gatenby P, Bardot A, Ferlay J, Bucher O, De P, Engholm G, Jackson C, Kozie S, Little A, Möller B, Shack L, Tervonen H, Thursfield V, Vernon S, Walsh PM, Woods RR, Finley C, Merrett N, O'Connell DL, Reynolds JV, Bray F, Arnold M. International trends in oesophageal cancer survival by histological subtype between 1995 and 2014. *Gut* 2021; **70**: 234-242 [PMID: [32554620](#) DOI: [10.1136/gutjnl-2020-321089](#)]
- 18 **Cunningham D**, Allum WH, Stenning SP, Thompson JN, Van de Velde CJ, Nicolson M, Scarffe JH, Lofts FJ, Falk SJ, Iveson TJ, Smith DB, Langley RE, Verma M, Weeden S, Chua YJ, MAGIC Trial Participants. Perioperative chemotherapy versus surgery alone for resectable gastroesophageal cancer. *N Engl J Med* 2006; **355**: 11-20 [PMID: [16822992](#) DOI: [10.1056/NEJMoa055531](#)]
- 19 **Al-Batran SE**, Homann N, Pauligk C, Goetze TO, Meiler J, Kasper S, Kopp HG, Mayer F, Haag GM, Luley K, Lindig U, Schmiegel W, Pohl M, Stoecklacher J, Folprecht G, Probst S, Prasnikar N, Fischbach W, Mahlberg R, Trojan J, Koenigsmann M, Martens UM, Thuss-Patience P, Egger M, Block A, Heinemann V, Illerhaus G, Moehler M, Schenk M, Kullmann F, Behringer DM, Heike M, Pink D, Teschendorf C, Lohr C, Bernhard H, Schuch G, Rethwisch V, von Weikersthal LF, Hartmann JT, Kneba M, Daum S, Schulmann K, Weniger J, Belle S, Gaiser T, Oduncu FS, Güntner M, Hozaeel W, Reichart A, Jäger E, Kraus T, Mönig S, Bechstein WO, Schuler M, Schmalenberg H, Hofheinz RD; FLOT4-AIO Investigators. Perioperative chemotherapy with fluorouracil plus leucovorin, oxaliplatin, and docetaxel versus fluorouracil or capecitabine plus cisplatin and epirubicin for locally advanced, resectable gastric or gastro-oesophageal junction adenocarcinoma (FLOT4): a randomised, phase 2/3 trial. *Lancet* 2019; **393**: 1948-1957 [PMID: [30982686](#) DOI: [10.1016/S0140-6736\(18\)32557-1](#)]
- 20 **Medical Research Council Oesophageal Cancer Working Group**. Surgical resection with or without preoperative chemotherapy in oesophageal cancer: a randomised controlled trial. *Lancet* 2002; **359**: 1727-1733 [PMID: [12049861](#) DOI: [10.1016/S0140-6736\(02\)08651-8](#)]
- 21 **Allum WH**, Stenning SP, Bancewicz J, Clark PI, Langley RE. Long-term results of a randomized trial of surgery with or without preoperative chemotherapy in esophageal cancer. *J Clin Oncol* 2009; **27**: 5062-5067 [PMID: [19770374](#) DOI: [10.1200/JCO.2009.22.2083](#)]
- 22 **Kelsen DP**, Winter KA, Gunderson LL, Mortimer J, Estes NC, Haller DG, Ajani JA, Kocha W, Minsky BD, Roth JA, Willett CG; Radiation Therapy Oncology Group; USA Intergroup. Long-term results of RTOG trial 8911 (USA Intergroup 113): a random assignment trial

- comparison of chemotherapy followed by surgery compared with surgery alone for esophageal cancer. *J Clin Oncol* 2007; **25**: 3719-3725 [PMID: 17704421 DOI: 10.1200/JCO.2006.10.4760]
- 23 **Alderson D**, Cunningham D, Nankivell M, Blazeby JM, Griffin SM, Crellin A, Grabsch HI, Langer R, Pritchard S, Okines A, Krysztopik R, Coxon F, Thompson J, Falk S, Robb C, Stenning S, Langley RE. Neoadjuvant cisplatin and fluorouracil versus epirubicin, cisplatin, and capecitabine followed by resection in patients with oesophageal adenocarcinoma (UK MRC OE05): an open-label, randomised phase 3 trial. *Lancet Oncol* 2017; **18**: 1249-1260 [PMID: 28784312 DOI: 10.1016/S1470-2045(17)30447-3]
- 24 **Nakamura K**, Kato K, Igaki H, Ito Y, Mizusawa J, Ando N, Udagawa H, Tsubosa Y, Daiko H, Hironaka S, Fukuda H, Kitagawa Y; Japan Esophageal Oncology Group/Japan Clinical Oncology Group. Three-arm phase III trial comparing cisplatin plus 5-FU (CF) versus docetaxel, cisplatin plus 5-FU (DCF) versus radiotherapy with CF (CF-RT) as preoperative therapy for locally advanced esophageal cancer (JCOG1109, NExT study). *Jpn J Clin Oncol* 2013; **43**: 752-755 [PMID: 23625063 DOI: 10.1093/jcco/hty061]
- 25 **Wang H**, Tang H, Fang Y, Tan L, Yin J, Shen Y, Zeng Z, Zhu J, Hou Y, Du M, Jiao J, Jiang H, Gong L, Li Z, Liu J, Xie D, Li W, Lian C, Zhao Q, Chen C, Zheng B, Liao Y, Li K, Li H, Wu H, Dai L, Chen KN. Morbidity and Mortality of Patients Who Underwent Minimally Invasive Esophagectomy After Neoadjuvant Chemoradiotherapy vs Neoadjuvant Chemotherapy for Locally Advanced Esophageal Squamous Cell Carcinoma: A Randomized Clinical Trial. *JAMA Surg* 2021; **156**: 444-451 [PMID: 33729467 DOI: 10.1001/jamasurg.2021.0133]
- 26 **Tang H**, Wang H, Fang Y, Zhu JY, Yin J, Shen YX, Zeng ZC, Jiang DX, Hou YY, Du M, Lian CH, Zhao Q, Jiang HJ, Gong L, Li ZG, Liu J, Xie DY, Li WF, Chen C, Zheng B, Chen KN, Dai L, Liao YD, Li K, Li HC, Zhao NQ, Tan LJ. Neoadjuvant chemoradiotherapy versus neoadjuvant chemotherapy followed by minimally invasive esophagectomy for locally advanced esophageal squamous cell carcinoma: a prospective multicenter randomized clinical trial. *Ann Oncol* 2023; **34**: 163-172 [PMID: 36400384 DOI: 10.1016/j.annonc.2022.10.508]
- 27 **Reynolds JV**, Preston SR, O'Neill B, Lowery MA, Baekgaard L, Crosby T, Cunningham M, Cuffe S, Griffiths GO, Roy R, Falk S, Hanna G, Bartlett FR, Parker I, Alvarez-Iglesias A, Nilsson M, Piessen G, Risum S, Ravi N, McDermott RS. Neo-AEGIS (Neoadjuvant trial in Adenocarcinoma of the Esophagus and Esophago-Gastric Junction International Study): Preliminary results of phase III RCT of CROSS versus perioperative chemotherapy (Modified MAGIC or FLOT protocol). (NCT01726452). *J Clin Oncol* 2021; **39** [DOI: 10.1200/JCO.2021.39.15\_suppl.4004]
- 28 **Murciano-Goroff YR**, Warner AB, Wolchok JD. The future of cancer immunotherapy: microenvironment-targeting combinations. *Cell Res* 2020; **30**: 507-519 [PMID: 32467593 DOI: 10.1038/s41422-020-0337-2]
- 29 **Davern M**, Donlon NE, Power R, Hayes C, King R, Dunne MR, Reynolds JV. The tumour immune microenvironment in oesophageal cancer. *Br J Cancer* 2021; **125**: 479-494 [PMID: 33903730 DOI: 10.1038/s41416-021-01331-y]
- 30 **Zheng Y**, Chen Z, Han Y, Han L, Zou X, Zhou B, Hu R, Hao J, Bai S, Xiao H, Li WV, Bueker A, Ma Y, Xie G, Yang J, Chen S, Li H, Cao J, Shen L. Immune suppressive landscape in the human esophageal squamous cell carcinoma microenvironment. *Nat Commun* 2020; **11**: 6268 [PMID: 33293583 DOI: 10.1038/s41467-020-20019-0]
- 31 **Cui K**, Hu S, Mei X, Cheng M. Innate Immune Cells in the Esophageal Tumor Microenvironment. *Front Immunol* 2021; **12**: 654731 [PMID: 33995371 DOI: 10.3389/fimmu.2021.654731]
- 32 **Dermani FK**, Samadi P, Rahmani G, Kohlan AK, Najafi R. PD-1/PD-L1 immune checkpoint: Potential target for cancer therapy. *J Cell Physiol* 2019; **234**: 1313-1325 [PMID: 30191996 DOI: 10.1002/jcp.27172]
- 33 **Jiang Y**, Chen M, Nie H, Yuan Y. PD-1 and PD-L1 in cancer immunotherapy: clinical implications and future considerations. *Hum Vaccin Immunother* 2019; **15**: 1111-1122 [PMID: 30888929 DOI: 10.1080/21645515.2019.1571892]
- 34 **Yi M**, Zheng X, Niu M, Zhu S, Ge H, Wu K. Combination strategies with PD-1/PD-L1 blockade: current advances and future directions. *Mol Cancer* 2022; **21**: 28 [PMID: 35062949 DOI: 10.1186/s12943-021-01489-2]
- 35 **Schneider BJ**, Chang AC. ASO Perspectives: Adjuvant Nivolumab in Resected Esophageal or Gastroesophageal Junction Cancer: Never Stop Questioning. *Ann Surg Oncol* 2022; **29**: 2735-2738 [PMID: 35182309 DOI: 10.1245/s10434-021-11276-4]
- 36 **Zhang W**, Yan C, Gao X, Li X, Cao F, Zhao G, Zhao J, Er P, Zhang T, Chen X, Wang Y, Jiang Y, Wang Q, Zhang B, Qian D, Wang J, Zhou D, Ren X, Yu Z, Zhao L, Yuan Z, Wang P, Pang Q. Safety and Feasibility of Radiotherapy Plus Camrelizumab for Locally Advanced Esophageal Squamous Cell Carcinoma. *Oncologist* 2021; **26**: e1110-e1124 [PMID: 33893689 DOI: 10.1002/onco.13797]
- 37 **Huang J**, Xu J, Chen Y, Zhuang W, Zhang Y, Chen Z, Chen J, Zhang H, Niu Z, Fan Q, Lin L, Gu K, Liu Y, Ba Y, Miao Z, Jiang X, Zeng M, Fu Z, Gan L, Wang J, Zhan X, Liu T, Li Z, Shen L, Shu Y, Zhang T, Yang Q, Zou J; ESCORT Study Group. Camrelizumab versus investigator's choice of chemotherapy as second-line therapy for advanced or metastatic oesophageal squamous cell carcinoma (ESCORT): a multicentre, randomised, open-label, phase 3 study. *Lancet Oncol* 2020; **21**: 832-842 [PMID: 32416073 DOI: 10.1016/S1470-2045(20)30110-8]
- 38 **Pan C**, Wang Y, Liu Q, Hu Y, Fu J, Xie X, Zhang S, Xi M, Wen J. Phenotypic profiling and prognostic significance of immune infiltrates in esophageal squamous cell carcinoma. *Oncoimmunology* 2021; **10**: 1883890 [PMID: 33628625 DOI: 10.1080/2162402X.2021.1883890]
- 39 **Yang H**, Zhang Q, Xu M, Wang L, Chen X, Feng Y, Li Y, Zhang X, Cui W, Jia X. CCL2-CCR2 axis recruits tumor associated macrophages to induce immune evasion through PD-1 signaling in esophageal carcinogenesis. *Mol Cancer* 2020; **19**: 41 [PMID: 32103760 DOI: 10.1186/s12943-020-01165-x]
- 40 **Bagchi S**, Yuan R, Engleman EG. Immune Checkpoint Inhibitors for the Treatment of Cancer: Clinical Impact and Mechanisms of Response and Resistance. *Annu Rev Pathol* 2021; **16**: 223-249 [PMID: 33197221 DOI: 10.1146/annurev-pathol-042020-042741]
- 41 **Andrews LP**, Marciscano AE, Drake CG, Vignali DA. LAG3 (CD223) as a cancer immunotherapy target. *Immunol Rev* 2017; **276**: 80-96 [PMID: 28258692 DOI: 10.1111/imr.12519]
- 42 **Chen Z**, Zhao M, Liang J, Hu Z, Huang Y, Li M, Pang Y, Lu T, Sui Q, Zhan C, Lin M, Guo W, Wang Q, Tan L. Dissecting the single-cell transcriptome network underlying esophagus non-malignant tissues and esophageal squamous cell carcinoma. *EBioMedicine* 2021; **69**: 103459 [PMID: 34192657 DOI: 10.1016/j.ebiom.2021.103459]
- 43 **Gebauer F**, Krämer M, Bruns C, Schlößer HA, Thelen M, Lohnes P, Schröder W, Zander T, Alakus H, Buettner R, Loeser H, Quaas A. Lymphocyte activation gene-3 (LAG3) mRNA and protein expression on tumour infiltrating lymphocytes (TILs) in oesophageal adenocarcinoma. *J Cancer Res Clin Oncol* 2020; **146**: 2319-2327 [PMID: 32592066 DOI: 10.1007/s00432-020-03295-7]
- 44 **Wang W**, Chen D, Zhao Y, Zhao T, Wen J, Mao Y, Chen C, Sang Y, Zhang Y, Chen Y. Characterization of LAG-3, CTLA-4, and CD8(+) TIL density and their joint influence on the prognosis of patients with esophageal squamous cell carcinoma. *Ann Transl Med* 2019; **7**: 776 [PMID: 32042792 DOI: 10.21037/atm.2019.11.38]
- 45 **Zhang CY**, Zhang J, Ma YF, Zhe H, Zhao R, Wang YY. Prognostic Value of Combined Analysis of CTLA-4 and PLR in Esophageal Squamous Cell Carcinoma (ESCC) Patients. *Dis Markers* 2019; **2019**: 1601072 [PMID: 31485274 DOI: 10.1155/2019/1601072]
- 46 **Cai Z**, Ang X, Xu Z, Li S, Zhang J, Pei C, Zhou F. A pan-cancer study of PD-1 and CTLA-4 as therapeutic targets. *Transl Cancer Res* 2021;

- 10: 3993-4001 [PMID: 35116697 DOI: 10.21037/tcr-21-561]
- 47 **Zhang XF**, Pan K, Weng DS, Chen CL, Wang QJ, Zhao JJ, Pan QZ, Liu Q, Jiang SS, Li YQ, Zhang HX, Xia JC. Cytotoxic T lymphocyte antigen-4 expression in esophageal carcinoma: implications for prognosis. *Oncotarget* 2016; **7**: 26670-26679 [PMID: 27050369 DOI: 10.18632/oncotarget.8476]
- 48 **Wu Z**, Zheng Q, Chen H, Xiang J, Hu H, Li H, Pan Y, Peng Y, Yao X, Liu P, Sun Y, Li B, Zhang Y. Efficacy and safety of neoadjuvant chemotherapy and immunotherapy in locally resectable advanced esophageal squamous cell carcinoma. *J Thorac Dis* 2021; **13**: 3518-3528 [PMID: 34277047 DOI: 10.21037/jtd-21-340]
- 49 **Liu J**, Yang Y, Liu Z, Fu X, Cai X, Li H, Zhu L, Shen Y, Zhang H, Sun Y, Chen H, Yu B, Zhang R, Shao J, Zhang M, Li Z. Multicenter, single-arm, phase II trial of camrelizumab and chemotherapy as neoadjuvant treatment for locally advanced esophageal squamous cell carcinoma. *J Immunother Cancer* 2022; **10** [PMID: 35338088 DOI: 10.1136/jitc-2021-004291]
- 50 **Liu J**, Li J, Lin W, Shao D, Depypere L, Zhang Z, Li Z, Cui F, Du Z, Zeng Y, Jiang S, He P, Gu X, Chen H, Zhang H, Lin X, Huang H, Lv W, Cai W, Liang W, Liang H, Jiang W, Wang W, Xu K, Wu K, Lerut T, Fu J, He J. Neoadjuvant camrelizumab plus chemotherapy for resectable, locally advanced esophageal squamous cell carcinoma (NIC-ESCC2019): A multicenter, phase 2 study. *Int J Cancer* 2022; **151**: 128-137 [PMID: 35188268 DOI: 10.1002/ijc.33976]
- 51 **Li C**, Zhao S, Zheng Y, Han Y, Chen X, Cheng Z, Wu Y, Feng X, Qi W, Chen K, Xiang J, Li J, Lerut T, Li H. Preoperative pembrolizumab combined with chemoradiotherapy for oesophageal squamous cell carcinoma (PALACE-1). *Eur J Cancer* 2021; **144**: 232-241 [PMID: 33373868 DOI: 10.1016/j.ejca.2020.11.039]
- 52 **Zheng Y**, Li C, Yu B, Zhao S, Li J, Chen X, Li H. Preoperative pembrolizumab combined with chemoradiotherapy for esophageal squamous cell carcinoma: Trial design. *JTCVS Open* 2022; **9**: 293-299 [PMID: 36003437 DOI: 10.1016/j.xjon.2021.11.003]
- 53 **Zhu M**, Chen C, Foster NR, Hartley C, Mounajjed T, Salomao MA, Fruth BF, Beamer SE, Kim Y, Harrington SM, Pitot HC, Sanhueza CT, Feng Y, Herrmann J, McWilliams RR, Lucien F, Huang BQ, Ma WW, Bekaii-Saab TS, Dong H, Wigle D, Ahn DH, Hallemeier CL, Blackmon S, Yoon HH. Pembrolizumab in Combination with Neoadjuvant Chemoradiotherapy for Patients with Resectable Adenocarcinoma of the Gastroesophageal Junction. *Clin Cancer Res* 2022; **28**: 3021-3031 [PMID: 35552651 DOI: 10.1158/1078-0432.CCR-22-0413]
- 54 **Huang B**, Shi H, Gong X, Yu J, Xiao C, Zhou B, Liang Z, Li X. Comparison of efficacy and safety between pembrolizumab combined with chemotherapy and simple chemotherapy in neoadjuvant therapy for esophageal squamous cell carcinoma. *J Gastrointest Oncol* 2021; **12**: 2013-2021 [PMID: 34790369 DOI: 10.21037/jgo-21-610]
- 55 **Duan H**, Shao C, Pan M, Liu H, Dong X, Zhang Y, Tong L, Feng Y, Wang Y, Wang L, Newman NB, Sarkaria IS, Reynolds JV, De Cobelli F, Ma Z, Jiang T, Yan X. Neoadjuvant Pembrolizumab and Chemotherapy in Resectable Esophageal Cancer: An Open-Label, Single-Arm Study (PEN-ICE). *Front Immunol* 2022; **13**: 849984 [PMID: 35720388 DOI: 10.3389/fimmu.2022.849984]
- 56 **Yan X**, Duan H, Ni Y, Zhou Y, Wang X, Qi H, Gong L, Liu H, Tian F, Lu Q, Sun J, Yang E, Zhong D, Wang T, Huang L, Wang J, Chaoyang Wang, Wang Y, Wan Z, Lei J, Zhao J, Jiang T. Tislelizumab combined with chemotherapy as neoadjuvant therapy for surgically resectable esophageal cancer: A prospective, single-arm, phase II study (TD-NICE). *Int J Surg* 2022; **103**: 106680 [PMID: 35595021 DOI: 10.1016/j.ijsu.2022.106680]
- 57 **Chen X**, Xu X, Wang D, Liu J, Sun J, Lu M, Wang R, Hui B, Li X, Zhou C, Wang M, Qiu T, Cui S, Sun N, Li Y, Wang F, Liu C, Shao Y, Luo J, Gu Y. Neoadjuvant sintilimab and chemotherapy in patients with potentially resectable esophageal squamous cell carcinoma (KEEP-G 03): an open-label, single-arm, phase 2 trial. *J Immunother Cancer* 2023; **11** [PMID: 36759013 DOI: 10.1136/jitc-2022-005830]
- 58 **van den Ende T**, de Clercq NC, van Berge Henegouwen MI, Gisbertz SS, Geijsen ED, Verhoeven RHA, Meijer SL, Schokker S, Dings MPG, Bergman JJGHM, Haj Mohammad N, Ruurda JP, van Hillegersberg R, Mook S, Nieuwdorp M, de Gruijl TD, Soeratrtram TTD, Ylstra B, van Grieken NCT, Bijlsma MF, Hulshof MCCM, van Laarhoven HWM. Neoadjuvant Chemoradiotherapy Combined with Atezolizumab for Resectable Esophageal Adenocarcinoma: A Single-arm Phase II Feasibility Trial (PERFECT). *Clin Cancer Res* 2021; **27**: 3351-3359 [PMID: 33504550 DOI: 10.1158/1078-0432.CCR-20-4443]
- 59 **Xing W**, Zhao L, Zheng Y, Liu B, Liu X, Li T, Zhang Y, Ma B, Yang Y, Shang Y, Fu X, Liang G, Yuan D, Qu J, Chai X, Zhang H, Wang Z, Lin H, Liu L, Ren X, Zhang J, Gao Q. The Sequence of Chemotherapy and Toripalimab Might Influence the Efficacy of Neoadjuvant Chemoimmunotherapy in Locally Advanced Esophageal Squamous Cell Cancer-A Phase II Study. *Front Immunol* 2021; **12**: 772450 [PMID: 34938292 DOI: 10.3389/fimmu.2021.772450]
- 60 **He W**, Leng X, Mao T, Luo X, Zhou L, Yan J, Peng L, Fang Q, Liu G, Wei X, Wang K, Wang C, Zhang S, Zhang X, Shen X, Huang D, Yi H, Bei T, She X, Xiao W, Han Y. Toripalimab Plus Paclitaxel and Carboplatin as Neoadjuvant Therapy in Locally Advanced Resectable Esophageal Squamous Cell Carcinoma. *Oncologist* 2022; **27**: e18-e28 [PMID: 35305102 DOI: 10.1093/oncolo/oyab011]
- 61 **Gao L**, Lu J, Zhang P, Hong ZN, Kang M. Toripalimab combined with docetaxel and cisplatin neoadjuvant therapy for locally advanced esophageal squamous cell carcinoma: a single-center, single-arm clinical trial (ESONICT-2). *J Gastrointest Oncol* 2022; **13**: 478-487 [PMID: 35557591 DOI: 10.21037/jgo-22-131]
- 62 **Zhang G**, Yuan J, Pan C, Xu Q, Cui X, Zhang J, Liu M, Song Z, Wu L, Wu D, Luo H, Hu Y, Jiao S, Yang B. Multi-omics analysis uncovers tumor ecosystem dynamics during neoadjuvant toripalimab plus nab-paclitaxel and S-1 for esophageal squamous cell carcinoma: a single-center, open-label, single-arm phase 2 trial. *EBioMedicine* 2023; **90**: 104515 [PMID: 36921563 DOI: 10.1016/j.ebiom.2023.104515]
- 63 **Kelly RJ**, Ajani JA, Kuzdzal J, Zander T, Van Cutsem E, Piessen G, Mendez G, Feliciano J, Motoyama S, Lièvre A, Uronis H, Elimova E, Grootscholten C, Geboes K, Zafar S, Snow S, Ko AH, Feeney K, Schenker M, Kocon P, Zhang J, Zhu L, Lei M, Singh P, Kondo K, Cleary JM, Moehler M; CheckMate 577 Investigators. Adjuvant Nivolumab in Resected Esophageal or Gastroesophageal Junction Cancer. *N Engl J Med* 2021; **384**: 1191-1203 [PMID: 33789008 DOI: 10.1056/NEJMoa2032125]
- 64 **van Hagen P**, Hulshof MC, van Lanschot JJ, Steyerberg EW, van Berge Henegouwen MI, Wijnhoven BP, Richel DJ, Nieuwenhuijzen GA, Hospers GA, Bonenkamp JJ, Cuesta MA, Blaisse RJ, Busch OR, ten Kate FJ, Creemers GJ, Punt CJ, Plukker JT, Verheul HM, Spillenaar Bilgen EJ, van Dekken H, van der Sangen MJ, Rozema T, Biermann K, Beukema JC, Piet AH, van Rij CM, Reinders JG, Tilanus HW, van der Gaast A; CROSS Group. Preoperative chemoradiotherapy for esophageal or junctional cancer. *N Engl J Med* 2012; **366**: 2074-2084 [PMID: 22646630 DOI: 10.1056/NEJMoa1112088]
- 65 **Luchini C**, Bibeau F, Ligtenberg MJL, Singh N, Nottegar A, Bosse T, Miller R, Riaz N, Douillard JY, Andre F, Scarpa A. ESMO recommendations on microsatellite instability testing for immunotherapy in cancer, and its relationship with PD-1/PD-L1 expression and tumour mutational burden: a systematic review-based approach. *Ann Oncol* 2019; **30**: 1232-1243 [PMID: 31056702 DOI: 10.1093/annonc/mdz116]
- 66 **Huang J**, Xu B, Mo H, Zhang W, Chen X, Wu D, Qu D, Wang X, Lan B, Yang B, Wang P, Zhang H, Yang Q, Jiao Y. Safety, Activity, and Biomarkers of SHR-1210, an Anti-PD-1 Antibody, for Patients with Advanced Esophageal Carcinoma. *Clin Cancer Res* 2018; **24**: 1296-1304

- [PMID: 29358502 DOI: 10.1158/1078-0432.CCR-17-2439]
- 67 **Nihira NT**, Miki Y. Regulation of Intrinsic Functions of PD-L1 by Post-Translational Modification in Tumors. *Front Oncol* 2022; **12**: 825284 [PMID: 35402280 DOI: 10.3389/fonc.2022.825284]
  - 68 **Dudley JC**, Lin MT, Le DT, Eshleman JR. Microsatellite Instability as a Biomarker for PD-1 Blockade. *Clin Cancer Res* 2016; **22**: 813-820 [PMID: 26880610 DOI: 10.1158/1078-0432.CCR-15-1678]
  - 69 **Qiu R**, Wang W, Li J, Wang Y. Roles of PTEN inactivation and PD-1/PD-L1 activation in esophageal squamous cell carcinoma. *Mol Biol Rep* 2022; **49**: 6633-6645 [PMID: 35301651 DOI: 10.1007/s11033-022-07246-y]
  - 70 **Li L**, Wei JR, Dong J, Lin QG, Tang H, Jia YX, Tan W, Chen QY, Zeng TT, Xing S, Qin YR, Zhu YH, Li Y, Guan XY. Laminin  $\gamma$ 2-mediating T cell exclusion attenuates response to anti-PD-1 therapy. *Sci Adv* 2021; **7** [PMID: 33536206 DOI: 10.1126/sciadv.abc8346]
  - 71 **Zheng S**, Liu B, Guan X. The Role of Tumor Microenvironment in Invasion and Metastasis of Esophageal Squamous Cell Carcinoma. *Front Oncol* 2022; **12**: 911285 [PMID: 35814365 DOI: 10.3389/fonc.2022.911285]
  - 72 **Wu X**, Ke X, Ni Y, Kuang L, Zhang F, Lin Y, Lin W, Xiong X, Huang H, Lin X, Zhang H. Tumor-Infiltrating Immune Cells and PD-L1 as Prognostic Biomarkers in Primary Esophageal Small Cell Carcinoma. *J Immunol Res* 2020; **2020**: 8884683 [PMID: 33457428 DOI: 10.1155/2020/8884683]
  - 73 **Liu Y**, Zheng P. Preserving the CTLA-4 Checkpoint for Safer and More Effective Cancer Immunotherapy. *Trends Pharmacol Sci* 2020; **41**: 4-12 [PMID: 31836191 DOI: 10.1016/j.tips.2019.11.003]
  - 74 **Pai CS**, Simons DM, Lu X, Evans M, Wei J, Wang YH, Chen M, Huang J, Park C, Chang A, Wang J, Westmoreland S, Beam C, Banach D, Bowley D, Dong F, Seagal J, Ritacco W, Richardson PL, Mitra S, Lynch G, Bousquet P, Mankovich J, Kingsbury G, Fong L. Tumor-conditional anti-CTLA4 uncouples antitumor efficacy from immunotherapy-related toxicity. *J Clin Invest* 2019; **129**: 349-363 [PMID: 30530991 DOI: 10.1172/JCI123391]
  - 75 **Duan J**, Xie Y, Qu L, Wang L, Zhou S, Wang Y, Fan Z, Yang S, Jiao S. A nomogram-based immunoprofile predicts overall survival for previously untreated patients with esophageal squamous cell carcinoma after esophagectomy. *J Immunother Cancer* 2018; **6**: 100 [PMID: 30285868 DOI: 10.1186/s40425-018-0418-7]
  - 76 **Zhang Y**, Liu YD, Luo YL, Liu BL, Huang QT, Wang F, Zhong Q. Prognostic Value of Lymphocyte Activation Gene-3 (LAG-3) Expression in Esophageal Squamous Cell Carcinoma. *J Cancer* 2018; **9**: 4287-4293 [PMID: 30519331 DOI: 10.7150/jca.26949]



Published by **Baishideng Publishing Group Inc**  
7041 Koll Center Parkway, Suite 160, Pleasanton, CA 94566, USA

**Telephone:** +1-925-3991568

**E-mail:** [bpgoffice@wjgnet.com](mailto:bpgoffice@wjgnet.com)

**Help Desk:** <https://www.f6publishing.com/helpdesk>

<https://www.wjgnet.com>

