

World Journal of *Gastroenterology*

World J Gastroenterol 2023 September 7; 29(33): 4920-5019



OPINION REVIEW

- 4920 Very early onset perinatal constipation: Can it be cow's milk protein allergy?
Arakoni R, Kamal H, Cheng SX

REVIEW

- 4927 Non-coding RNAs: The potential biomarker or therapeutic target in hepatic ischemia-reperfusion injury
Shao JL, Wang LJ, Xiao J, Yang JF
- 4942 Prevention and management of hepatitis B virus reactivation in patients with hematological malignancies in the targeted therapy era
Mak JWY, Law AWH, Law KWT, Ho R, Cheung CKM, Law MF
- 4962 Direct oral anticoagulants for the treatment of splanchnic vein thrombosis: A state of art
Monaco G, Bucherini L, Stefanini B, Piscaglia F, Foschi FG, Ielasi L

ORIGINAL ARTICLE

Basic Study

- 4975 Angiotensin-converting enzyme 2 improves liver fibrosis in mice by regulating autophagy of hepatic stellate cells
Wu Y, Yin AH, Sun JT, Xu WH, Zhang CQ
- 4991 Diabetes exacerbates inflammatory bowel disease in mice with diet-induced obesity
Francis KL, Alonge KM, Pacheco MC, Hu SJ, Kruttsch CA, Morton GJ, Schwartz MW, Scarlett JM
- 5005 Novel deformable self-assembled magnetic anastomosis ring for endoscopic treatment of colonic stenosis via natural orifice
Zhang MM, Zhao GB, Zhang HZ, Xu SQ, Shi AH, Mao JQ, Gai JC, Zhang YH, Ma J, Li Y, Lyu Y, Yan XP

CASE REPORT

- 5014 Carcinoid syndrome caused by a pulmonary carcinoid mimics intestinal manifestations of ulcerative colitis: A case report
Reyes CM, Klein H, Stögbauer F, Einwächter H, Boxberg M, Schirren M, Safi S, Hoffmann H

ABOUT COVER

Editorial Board Member of *World Journal of Gastroenterology*, Luca Mastracci, MD, Full Professor, Department of Surgical Sciences and Integrated Diagnostics, University of Genoa and Ospedale Policlinico San Martino, Genoa 16132, Italy. luca.mastracci@unige.it

AIMS AND SCOPE

The primary aim of *World Journal of Gastroenterology* (WJG, *World J Gastroenterol*) is to provide scholars and readers from various fields of gastroenterology and hepatology with a platform to publish high-quality basic and clinical research articles and communicate their research findings online. WJG mainly publishes articles reporting research results and findings obtained in the field of gastroenterology and hepatology and covering a wide range of topics including gastroenterology, hepatology, gastrointestinal endoscopy, gastrointestinal surgery, gastrointestinal oncology, and pediatric gastroenterology.

INDEXING/ABSTRACTING

The WJG is now abstracted and indexed in Science Citation Index Expanded (SCIE, also known as SciSearch®), Current Contents/Clinical Medicine, Journal Citation Reports, Index Medicus, MEDLINE, PubMed, PubMed Central, Scopus, Reference Citation Analysis, China Science and Technology Journal Database, and Superstar Journals Database. The 2023 edition of Journal Citation Reports® cites the 2022 impact factor (IF) for WJG as 4.3; Quartile category: Q2. The WJG's CiteScore for 2021 is 8.3.

RESPONSIBLE EDITORS FOR THIS ISSUE

Production Editor: *Hua-Ge Yu*; Production Department Director: *Xiang Li*; Editorial Office Director: *Jia-Rui Fan*.

NAME OF JOURNAL

World Journal of Gastroenterology

ISSN

ISSN 1007-9327 (print) ISSN 2219-2840 (online)

LAUNCH DATE

October 1, 1995

FREQUENCY

Weekly

EDITORS-IN-CHIEF

Andrzej S Tarnawski

EXECUTIVE ASSOCIATE EDITORS-IN-CHIEF

Xian-Jun Yu (Pancreatic Oncology), Jian-Gao Fan (Chronic Liver Disease)

EDITORIAL BOARD MEMBERS

<http://www.wjgnet.com/1007-9327/editorialboard.htm>

PUBLICATION DATE

September 7, 2023

COPYRIGHT

© 2023 Baishideng Publishing Group Inc

PUBLISHING PARTNER

Pancreatic Cancer Institute, Fudan University

INSTRUCTIONS TO AUTHORS

<https://www.wjgnet.com/bpg/gerinfo/204>

GUIDELINES FOR ETHICS DOCUMENTS

<https://www.wjgnet.com/bpg/GerInfo/287>

GUIDELINES FOR NON-NATIVE SPEAKERS OF ENGLISH

<https://www.wjgnet.com/bpg/gerinfo/240>

PUBLICATION ETHICS

<https://www.wjgnet.com/bpg/GerInfo/288>

PUBLICATION MISCONDUCT

<https://www.wjgnet.com/bpg/gerinfo/208>

POLICY OF CO-AUTHORS

<https://www.wjgnet.com/bpg/GerInfo/310>

ARTICLE PROCESSING CHARGE

<https://www.wjgnet.com/bpg/gerinfo/242>

STEPS FOR SUBMITTING MANUSCRIPTS

<https://www.wjgnet.com/bpg/GerInfo/239>

ONLINE SUBMISSION

<https://www.f6publishing.com>

PUBLISHING PARTNER'S OFFICIAL WEBSITE

<https://www.shca.org.cn/>



Basic Study

Novel deformable self-assembled magnetic anastomosis ring for endoscopic treatment of colonic stenosis *via* natural orifice

Miao-Miao Zhang, Guang-Bin Zhao, Han-Zhi Zhang, Shu-Qin Xu, Ai-Hua Shi, Jian-Qi Mao, Jing-Ci Gai, Yu-Han Zhang, Jia Ma, Yun Li, Yi Lyu, Xiao-Peng Yan

Specialty type: Gastroenterology and hepatology

Provenance and peer review:

Unsolicited article; Externally peer reviewed.

Peer-review model: Single blind

Peer-review report's scientific quality classification

Grade A (Excellent): A, A

Grade B (Very good): 0

Grade C (Good): 0

Grade D (Fair): 0

Grade E (Poor): 0

P-Reviewer: Martino A, Italy;

Şurlin VM, Romania

Received: June 14, 2023

Peer-review started: June 14, 2023

First decision: August 5, 2023

Revised: August 7, 2023

Accepted: August 15, 2023

Article in press: August 15, 2023

Published online: September 7, 2023



Miao-Miao Zhang, Shu-Qin Xu, Yun Li, Yi Lyu, Xiao-Peng Yan, Department of Hepatobiliary Surgery, The First Affiliated Hospital of Xi'an Jiaotong University, Xi'an 710061, Shaanxi Province, China

Miao-Miao Zhang, Shu-Qin Xu, Ai-Hua Shi, Yi Lyu, Xiao-Peng Yan, National Local Joint Engineering Research Center for Precision Surgery & Regenerative Medicine, The First Affiliated Hospital of Xi'an Jiaotong University, Xi'an 710061, Shaanxi Province, China

Guang-Bin Zhao, State Key Laboratory for Manufacturing System Engineering, School of Mechanical Engineering, Xi'an Jiaotong University, Xi'an 710054, Shaanxi Province, China

Han-Zhi Zhang, Jing-Ci Gai, Yu-Han Zhang, Qide College, Xi'an Jiaotong University, Xi'an 710061, Shaanxi Province, China

Jian-Qi Mao, Zonglian College, Xi'an Jiaotong University, Xi'an 710061, Shaanxi Province, China

Jia Ma, Department of Surgical Oncology, Shaanxi Provincial People's Hospital, Xi'an 710068, Shaanxi Province, China

Corresponding author: Xiao-Peng Yan, MD, PhD, Associate Research Scientist, Department of Hepatobiliary Surgery, The First Affiliated Hospital of Xi'an Jiaotong University, No. 277 West Yanta Road, Xi'an 710061, Shaanxi Province, China. yanxiaopeng9966@163.com

Abstract

BACKGROUND

Although endoscope-assisted magnetic compression anastomosis has already been reported for colonic anastomosis, there is no report on a single-approach operation using the natural orifice.

AIM

To design a deformable self-assembled magnetic anastomosis ring (DSAMAR) for colonic anastomosis for use in single-approach operation and evaluate its feasibility and safety through animal experiments.

METHODS

The animal model for colonic stenosis was prepared by partial colonic ligation in

eight beagles. The magnetic compression anastomosis of their colonic stricture was performed by endoscopically assisted transanal implantation of the DSAMAR. The anastomotic specimen, obtained 2 wk after the operation, was observed by both the naked eye and a light microscope.

RESULTS

The DSAMAR was successfully inserted into the proximal end of colon stenosis through the anus. The DSAMAR of seven dogs was successfully transformed into rings, while that of the remaining dog was removed after the first deformation failed. The rings were successfully retransformed after optimization. All animals underwent colonic anastomosis using the DSAMAR. No device-related or procedure-related adverse events were observed. The colostomy specimens of the experimental dogs were obtained 2 wk after the operation. Both gross and histological observations showed good anastomotic healing.

CONCLUSION

The DSAMAR is a safe and feasible option for the treatment of colon stenosis. Its specific deformation and self-assembly capability maximize the applicability of the minimally invasive treatment.

Key Words: Magnetic surgery; Magnamosis; Colonic stenosis; Natural orifice; Endoscopy

©The Author(s) 2023. Published by Baishideng Publishing Group Inc. All rights reserved.

Core Tip: By combining magnetic compression anastomosis with endoscopic technology, we could design a deformable self-assembled magnetic anastomosis ring (DSAMAR) to perform magnetic compression anastomosis with only a single channel. We then verified the feasibility of magnetic compression anastomosis for the recanalization of colonic stenosis through animal experiments. The results showed that minimally invasive treatment of colonic stenosis can be achieved using the DSAMAR.

Citation: Zhang MM, Zhao GB, Zhang HZ, Xu SQ, Shi AH, Mao JQ, Gai JC, Zhang YH, Ma J, Li Y, Lyu Y, Yan XP. Novel deformable self-assembled magnetic anastomosis ring for endoscopic treatment of colonic stenosis *via* natural orifice. *World J Gastroenterol* 2023; 29(33): 5005-5013

URL: <https://www.wjgnet.com/1007-9327/full/v29/i33/5005.htm>

DOI: <https://dx.doi.org/10.3748/wjg.v29.i33.5005>

INTRODUCTION

Benign colonic stenosis is a disease with various causes, including post-colectomy anastomotic stenosis[1], transcatheter arterial embolization[2], and acute pancreatitis[3]. Benign colonic stenosis is generally treated by endoscopic balloon dilatation (EBD)[4] and surgery[5]. EBD is widely performed in clinics because of its effectiveness, technical safety, and ease of process. However, in some cases, sufficient dilatation is not achieved because of the formation of stiff fibrosis tissue at the stenosis site, which is often resistant to balloon pressure[6]. Open surgery, laparoscopic stenosis resection, and bypass anastomosis are the traditional treatment strategies for benign colonic stenosis. Although a good therapeutic effect can be obtained through surgery, it is no longer the first choice of clinicians because of trauma and various perioperative adverse events.

Magnetic compression anastomosis or magnamosis, a novel technique, can be used for managing digestive tract anastomosis[7-9], vascular anastomosis[10,11], pathologic fistula[12], and therapeutic fistula[13]. The use of magnamosis along with endoscopy for treating gastrointestinal stenosis has been reported[14]. The cylinder or circle is the most commonly used shape of the magnet in such cases. In endoscopic magnetic compression anastomosis, the daughter and parent magnets are placed at the two opposite ends of the narrow digestive duct. The patient must have two channels: A natural orifice and the digestive tract fistula[14,15]. However, some patients only have a natural orifice, making magnetic compression anastomosis very difficult to perform. Therefore, for successful magnamosis, the magnet must be designed in a way that allows efficient optimization of the operation path. The design of the magnet must meet two conditions: first, the magnet should be able to pass through the narrow digestive cavity; and second, the magnet should be able to create wide anastomoses.

This study aims to design a novel deformable self-assembled magnetic anastomosis ring (DSAMAR) that can be placed at the natural orifice of the body. It also explores the feasibility of the DSAMAR in digestive tract anastomosis using dogs as experimental animals.

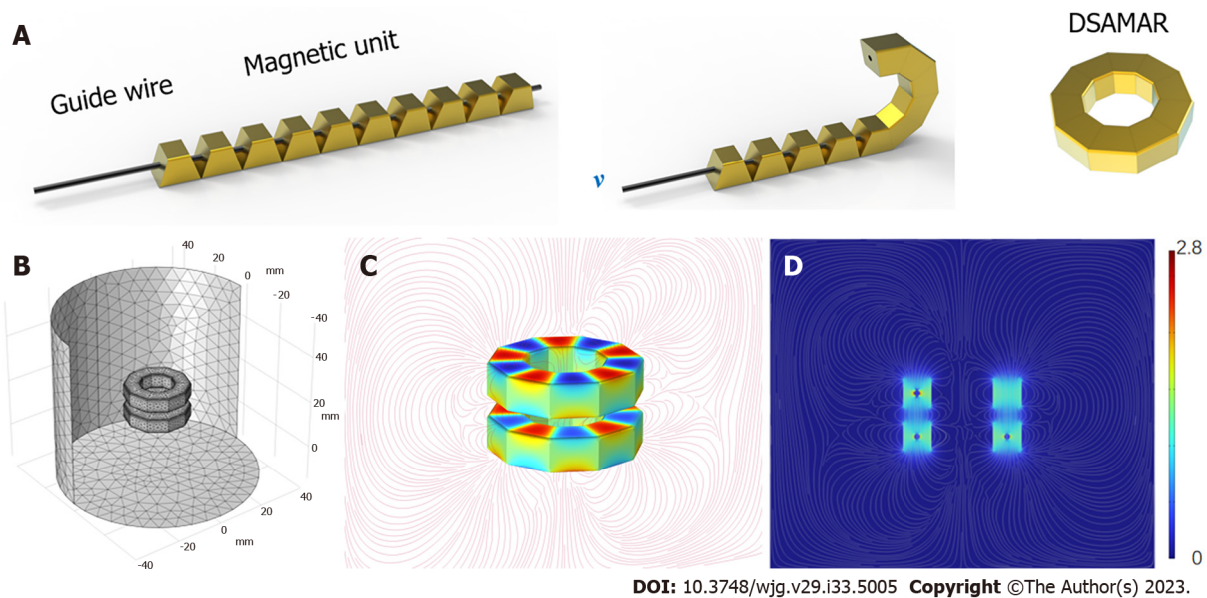


Figure 1 A schematic of the deformable self-assembled magnetic anastomosis ring. A: Transformation of the deformable self-assembled magnetic anastomosis ring from a linear structure to a ring; B to D: Computer simulation of magnetic flux density. DSAMAR: Deformable self-assembled magnetic anastomosis ring.

MATERIALS AND METHODS

Ethical statement

The experimental protocol was approved by the Committee for Ethics of Animal Experiments of Xi'an Jiaotong University (license No. 2022-1451). Eight beagles (male = 4, female = 4) were acquired from the Laboratory Animal Center of the Xi'an Jiaotong University (Xi'an, China) as experimental animals. The research protocol and all the experimental procedures were conducted strictly in accordance with the Guidelines for the Care and Use of Experimental Animals issued by the Xi'an Jiaotong University Medical Center.

DSAMAR

The DSAMAR consists of 10 trapezoidal magnetic units assembled in the opposite order of the N and S poles of the adjacent magnetic units. The long-axis direction of each magnetic unit contains a 1-mm diameter round hole that allows the stainless steel guide wire to pass through. Owing to the opposite N-S polarity of each magnetic unit, passing 10 sequentially arranged trapezoidal magnetic units through a hard guide wire and forming a linear arrangement is possible. When the guide wire is slowly drawn out, the inclined planes of the adjacent magnetic units attract each other and are sequentially arranged and assembled into a DSAMAR (Figure 1A) (Video 1). The magnetic unit is processed by N50-sintered neodymium-iron-boron, and its surface is coated with titanium nitride. Each magnetic unit of a DSAMAR weighs 1.25 g, the maximal magnetic field intensity at its compression surfaces is 480 mT, and the suction of two DSAMARs at zero distance can reach 184 N. The magnetic flux density can be calculated by computer simulations (Figure 1B-D).

Study design

This study aimed to verify the feasibility of the DSAMAR, an innovative surgical method. Hence, no control group was used. Eight beagles (age: > 1 year; weight: 12–15 kg) were used as experimental animals. Their operation time, postoperative adverse events, survival rate, and magnetic-ring-expel time were recorded. One month after the operation, the anastomosis was achieved and its healing was observed both by the naked eye and a light microscope.

Colonic stenosis model

The beagles were given a slag-free liquid diet 2 d before surgery. In addition, they were fasted and their water intake was restricted 6 h before surgery. They were anesthetized by an intravenous injection of 3% pentobarbital sodium (1 mL/kg) and fixed in the supine position. Repeat enemas with soapy water were conducted to clean the intestines. A 14Fr gastric tube was inserted into the colon through the anus. An approximately 10-cm-long incision in the middle of the lower abdomen was made into the abdominal cavity. The descending colon was exposed and ligated on the 14Fr gastric tube with a 1-0 silk thread in the middle part of the descending colon. The gastric tube was removed and a colon stenosis model was formed. The diameter of the colon in the narrow segment was approximately 4.5 mm. The abdomen was then closed layer by layer. The colon stenosis model was evaluated both by colonoscopy and colonography (Figure 2).

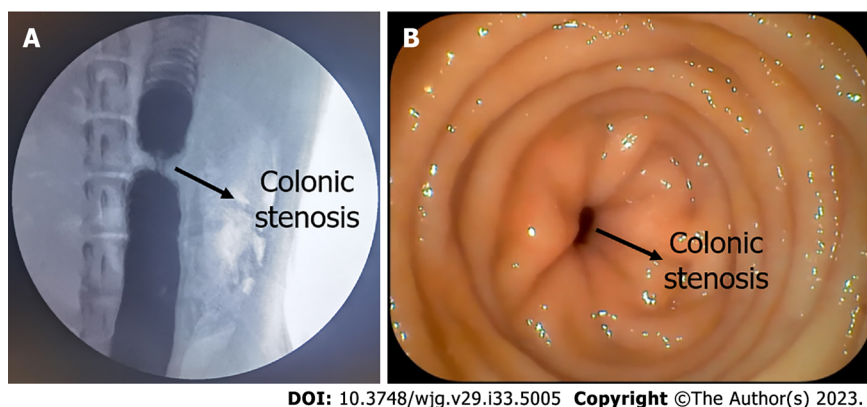


Figure 2 Colonic stenosis model. A: Colonic stenosis as seen by colonography; B: Colonic stenosis as seen by colonoscopy.

Endoscopic procedures

First, transanal colonoscopy was performed to determine the location and extent of colon stenosis. A guide wire was inserted through the colonoscopy biopsy hole. Under X-ray, the head end of the guide wire was passed through the colon stenosis segment. The position of the head end of the guide wire was maintained, and then the colonoscope was withdrawn (Figure 3A). Through the other end of the guide wire, 10 trapezoidal magnetic units were successively inserted in the opposite order of the N and S poles of the adjacent magnetic units. Again, under X-ray, a 5Fr push tube was used to push the magnetic units along the guide wire to make them enter the proximal end of the stenosis colon (Figure 3B and C). The magnetic units were then slowly pushed out of the guide wire one by one and transformed into a ring in the colon according to a predetermined plan. Then, the guide wire and the push tube were removed. Another DSAMAR, self-assembled in vitro, was inserted through the anus. Under X-ray, a colonoscope was used to push the magnet to the distal end of the stenosis colon. At this time, the two DSAMARs could automatically attract and compress the colon stenosis (Figure 3D and E). The two DSAMARs were then placed in the colon.

Postoperative care

All dogs were managed in a single cage after emergence from anesthesia. Pethidine hydrochloride (1 mg/kg) was intramuscularly injected every 12 h for 3 d after the operation for analgesia. The dogs were given intravenous nutritional support until the DSAMAR detached from the anus. The time that the magnets took to get expelled from all dogs was recorded. The dogs resumed oral feeding after the DSAMAR was expelled. Colonoscopy and colonography were performed to evaluate the patency of the colon.

Tissue harvest and analysis

All dogs were euthanized 2 wk after the operation, and their colonic anastomosis specimens were obtained. The healing of anastomosis was observed by the naked eye. The anastomotic specimen was then soaked overnight in 10% formalin for fixation. Then, the specimen was embedded in paraffin and a 4- μ m-thick section from the anastomosis was prepared. The sections were stained with hematoxylin and eosin (H&E) and Masson trichrome and examined under a bright-field microscope.

Statistical analysis

SPSS statistical 20.0 software was used for data analysis. The quantitative data of normal distribution were described by mean \pm SD, while those of non-normal distribution were described by the median. Differences between the groups were compared by an independent sample *t*-test or a nonparametric test. $P < 0.05$ indicated a significant difference.

RESULTS

Procedural parameters

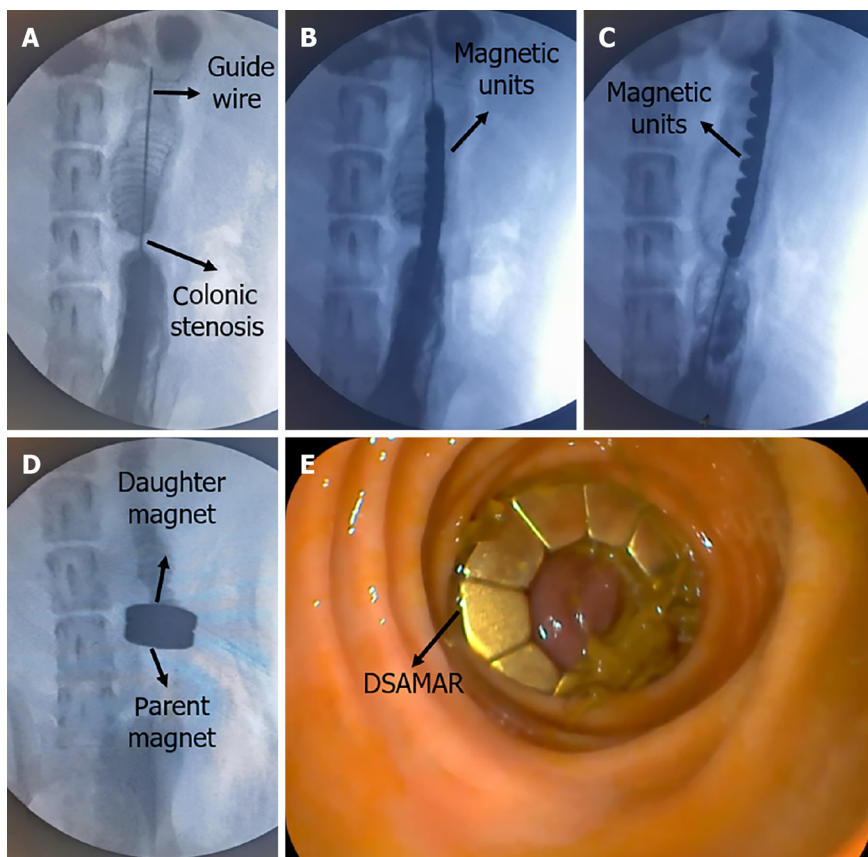
The colonic stenosis model was successfully prepared in all dogs (success rate = 100%). In seven of the eight beagles, the DSAMAR was successfully deformed only once after implantation in the proximal colon. In the remaining dog, the DSAMAR did not form during deformation, but it was successfully deformed after the removal of the magnetic ring and its re-implantation. The distal colon magnet was placed without any issue, and the DSAMARs at both ends of the stenosis were automatically attracted to each other. The endoscopic procedures (except for the model-preparation time) took 20.88 ± 5.69 min to complete, which was within the acceptable range (15–32 min). The average expulsion time of the magnets was 6.13 ± 0.99 d, again within the accepted range (5–8 d). The data related to animal experiments are listed in Table 1. The discharged DSAMARs are shown in Figure 4A–C. Colonoscopy and colonography were performed after the discharge of the magnet and a good patency of the colon was observed (Figure 4D and E).

Table 1 Data related to animal experiments

Animal	Male/female	Weight (kg)	Operation time (min)	DSAMAR expelled time (d)	Device failure (Y/N)	Device-related adverse events (Y/N)
No. 1	M	12.5	26	5	N	N
No. 2	F	12.0	18	6	N	N
No. 3	F	14.5	32	7	Y ¹	N
No. 4	M	12.0	15	6	N	N
No. 5	F	13.5	18	5	N	N
No. 6	M	14.0	20	8	N	N
No. 7	M	12.0	22	6	N	N
No. 8	F	15.0	16	6	N	N

¹The deformable self-assembled magnetic anastomosis ring was not formed during deformation; instead, it was successfully deformed after the removal of the magnetic ring and its re-implantation.

DSAMAR: Deformable self-assembled magnetic anastomosis ring; M: Male; F: Female; Y: Yes; N: No.

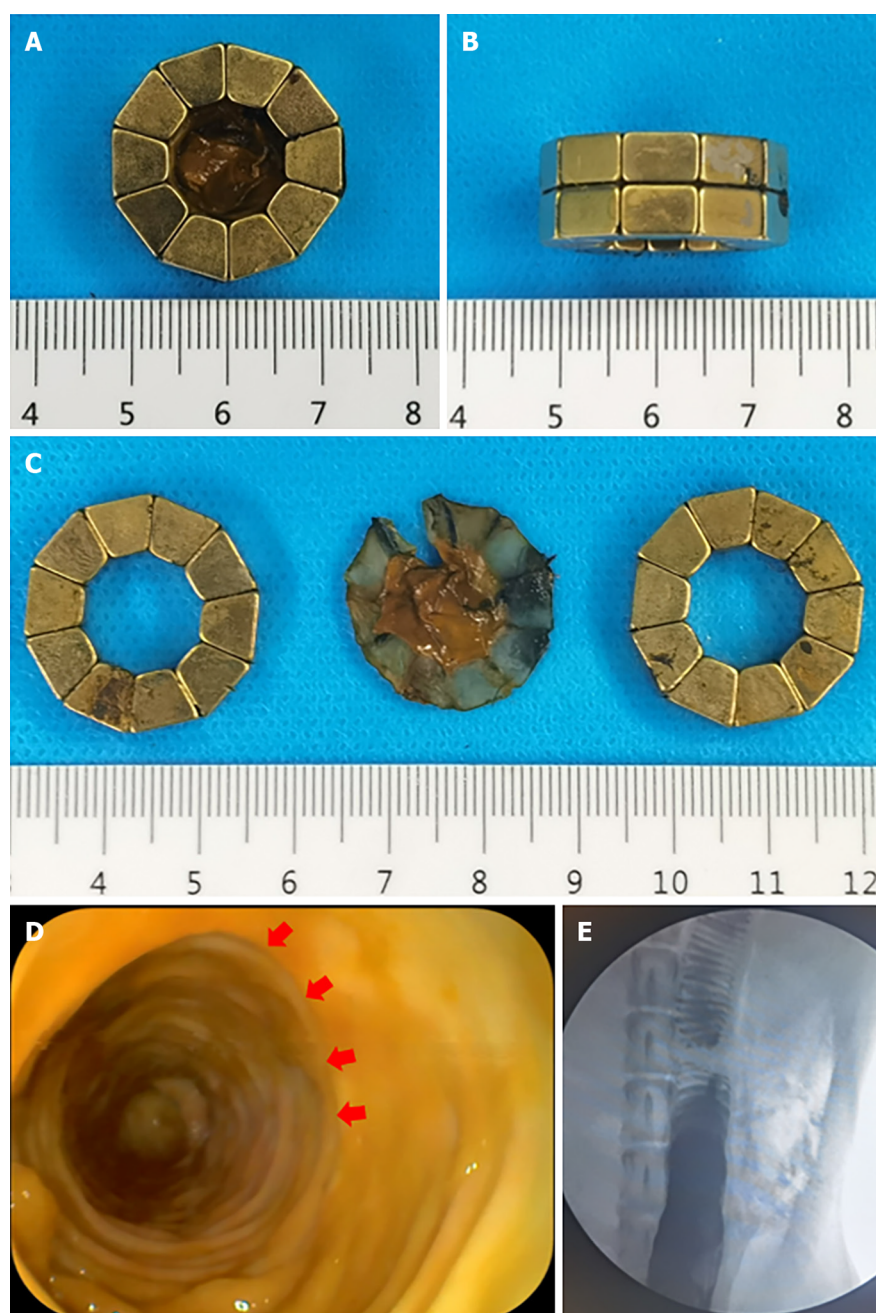


DOI: 10.3748/wjg.v29.i33.5005 Copyright ©The Author(s) 2023.

Figure 3 Animal experiment process. A: Hard guide wire passes through the stenosis into the proximal colon; B: Linear deformable self-assembled magnetic anastomosis ring (DSAMAR) passes through the narrow segment of the colon; C: DSAMAR enters the proximal colon completely; D: Magnetic rings at both ends of the narrow colon were attracted to each other; E: DSAMAR in the distal colon as seen by colonoscopy.

Survival rate and postoperative adverse events

The survival rate of all dogs was 100% in 2 wk after surgery. The dogs were generally in good condition after surgery, with no intestinal bleeding, perforation, obstruction, and other adverse events. After the dogs resumed normal feeding, they all excreted formed feces.



DOI: 10.3748/wjg.v29.i33.5005 Copyright ©The Author(s) 2023.

Figure 4 Magnetic compression anastomosis was established. A to C: Deformable self-assembled magnetic anastomosis rings expelled from the body; D: Magnetic compression anastomosis as seen by colonoscopy; E: Colonography showed good patency of the colon.

Gross and histological appearance of anastomosis

The experimental dogs were euthanized 2 wk after surgery, and their colonic anastomosis gross specimens were obtained by laparotomy. The colonic stenosis was not observed by the naked eye. The mucosa of the magnetic compression anastomosis was smooth and flat (Figure 5A and B). H&E and Masson staining showed good continuity and mucosal healing of the anastomotic mucosa (Figure 5C and D).

DISCUSSION

The DSAMAR along with endoscopy is a feasible treatment for gastrointestinal stenosis. Magnetic compression anastomosis is a safe technique for digestive tract anastomosis[7-9]. Non-surgical digestive tract anastomosis can be achieved when magnetic compression anastomosis is combined with endoscopy. Although most of the cases have been reported in clinical settings[14-16], the safety and feasibility of magnetic compression anastomosis are beyond doubt. To the best of our knowledge, the DSAMAR is the only magnet that can enter the narrow intestine through the natural orifice and perform the self-assembly anastomosis, which greatly increases the potential application of the magnamosis

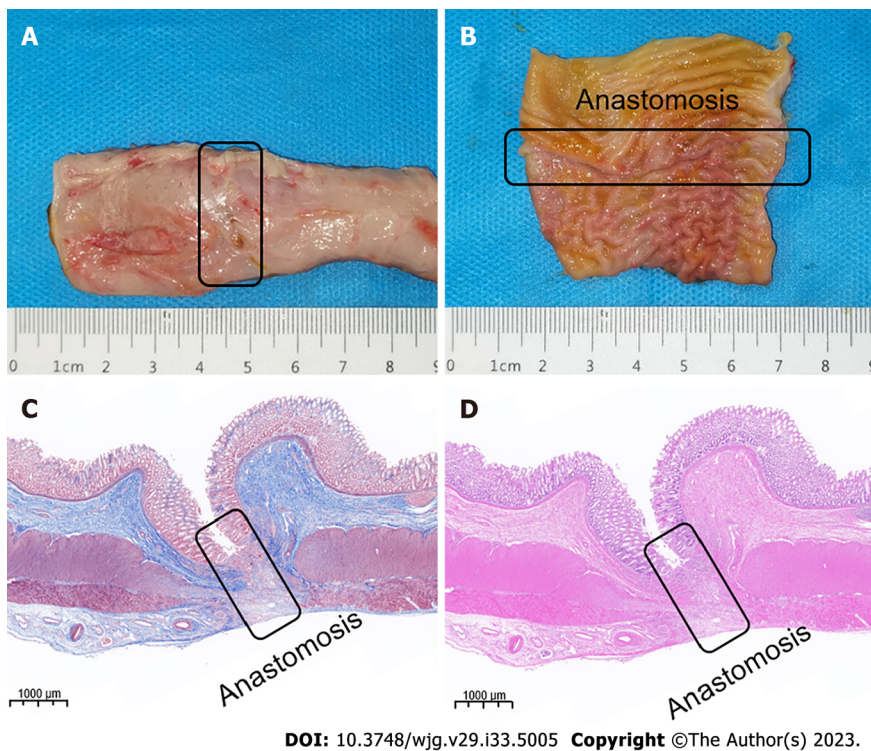


Figure 5 Magnetic compression anastomosis specimen. A: Serous surface of the anastomosis; B: Colonic anastomosis seen on mucosal surface; C: Masson's staining of anastomosis; D: Hematoxylin and eosin staining of anastomosis.

technology.

The special deformation mode of the DSAMAR allows the magnet to pass through the narrow section of the digestive tract with a minimal cross-section. The DSAMAR then deforms and self-assembles into a ring, with a slimming deformation ratio of up to 1:16.35. This creates suitable conditions for the implantation of a magnet ring through the single channel of the natural orifice. Approximately 100% success rate of the deformation self-assembly of the DSAMAR *in vitro* can be achieved. Only one of the eight dogs had an unplanned deformation of the DSAMAR when failed to form a ring. This happened because the colon was not inflated enough to provide sufficient space for the DSAMAR to deform. In this case, the DSAMAR was re-inserted into the proximal colon and inflated by a colonoscope to fully expand the colon, which helped successfully complete the deformable self-assembly.

The result of animal experiments provides the best proof of the potential clinical transformation of the DSAMAR. The gross specimen and histological observation of the colonic anastomosis in dogs showed that the DSAMAR established a good anastomosis, which was not significantly different from that achieved using the conventional magnetic ring of digestive tract anastomosis reported previously. Different degrees of the narrowing of the human digestive tract after magnetic compression anastomosis have been reported, consistent with the results of previous studies[17-18]. There may be still some differences in the long-term anastomosis effect of magnetic compression anastomosis in humans and animals. This phenomenon needs to be further investigated through clinical studies with larger samples. Nevertheless, our study not only confirms the advantages of magnamosis, but also fully affirms the ingenious design of the DSAMAR. Compared with the currently available magnamosis rings, the DSAMAR can further optimize the magnetic compression anastomosis of colorectal anastomosis stenosis in postoperative patients with esophageal stenosis (non-atresia) and no fistula. This is because the DSAMAR uses only the natural orifice of a patient to successfully place the magnet.

This study has certain limitations also. The animal experiments only verified the application of the DSAMAR for the treatment of colonic stenosis. The animal sample size was small and the observation time of anastomosis was also quite short. We plan to verify the feasibility of the application of the DSAMAR in esophageal and duodenal stenoses in future studies and further observe the long-term patency of magnetic compression anastomosis. In previous studies on animal experiments[19], the colonic stenosis model was prepared by the partial ligation of silk thread, which was different from that used clinically. It may lead to differences in the anastomosis effect of the clinical application compared to that observed with animal experiments.

CONCLUSION

This study demonstrated the feasibility and safety of the DSAMAR for the treatment of digestive tract stenosis through the natural orifice by conducting animal experiments. Because of its unique deformable self-assembly, the DSAMAR can be used to handle complex gastrointestinal stenosis cases. In our next studies, we plan to further optimize the design of the DSAMAR and improve the endoscopic operation process through more animal experiments. It is expected to be used

in clinical practice in the near future.

ARTICLE HIGHLIGHTS

Research background

Magnetic compression anastomosis, or magnamosis, has been widely used for anastomotic recanalization of gastrointestinal stenosis. At present, the magnets applied to the digestive tract lumen anastomosis are usually cylindrical or circular.

Research motivation

In order to achieve magnetic anastomosis recanalization through a single-access natural orifice, we designed a deformable self-assembled magnetic anastomosis ring (DSAMAR). It is expected to provide a more minimally invasive treatment method for patients with colonic stenosis.

Research objectives

To verify the feasibility and safety of using DSAMAR to recanalize colonic stenosis through the single-approach natural orifice.

Research methods

Colonic stricture models were established in 8 beagle dogs. DSAMAR was used to achieve magnamosis recanalization of colonic stenosis and evaluate the formation of colonic anastomosis.

Research results

The results showed that the use of DSAMAR for recanalization of colonic stenosis was feasible and the anastomosis formation was good.

Research conclusions

The feasibility and safety of using DSAMAR to achieve colonic stenosis recanalization through a single-approach natural orifice were verified through animal experiments.

Research perspectives

The design of DSAMAR is ingenious. In addition to colon stenosis, it can also be used for minimally invasive treatment of digestive tract stenosis such as esophageal stricture and duodenal obstruction. It could provide a more minimally invasive treatment for patients with gastrointestinal stenosis.

FOOTNOTES

Author contributions: Lyu Y and Yan XP designed and coordinated the study; Zhang MM, Zhao GB, Zhang HZ, Xu SQ, Mao JQ, Zhang YH, Ma J, Li Y, Yan XP performed the research and acquired the data; Zhang MM, Zhao GB, Zhang HZ analyzed the data; Shi AH, Zhao GB, Zhang MM tested and analyzed the magnetic test; Zhang MM, Zhao GB, and Yan XP wrote the manuscript; Yan XP and Lyu Y conceived of the study and contributed to the study design, the interpretation of the results, and the critical revision of the manuscript; all authors read and approved the final manuscript.

Supported by the Institutional Foundation of The First Affiliated Hospital of Xi'an Jiaotong University, No. 2022MS-07; the Key Research & Development Program-Social Development of Shaanxi Province of China, No. 2023-YBSF-247.

Institutional review board statement: The experimental protocol was approved by the Committee for Ethics of Animal Experiments of Xi'an Jiaotong University (No. 2022-1451).

Institutional animal care and use committee statement: The study protocol and all experimental procedures were carried out strictly in accordance with the Guidelines for Care and Use of Experimental Animals issued by the Xi'an Jiaotong University Medical Center. This experimental study was approved by the Experimental Ethics Committee of Xi'an Jiaotong University (No. 2022-1451).

Conflict-of-interest statement: All the authors report no relevant conflicts of interest for this article.

Data sharing statement: The authors declare that the data supporting the findings of this study are available within the article or from the corresponding authors upon request.

ARRIVE guidelines statement: The authors have read the ARRIVE guidelines, and the manuscript was prepared and revised according to the ARRIVE guidelines.

Open-Access: This article is an open-access article that was selected by an in-house editor and fully peer-reviewed by external reviewers.

It is distributed in accordance with the Creative Commons Attribution NonCommercial (CC BY-NC 4.0) license, which permits others to distribute, remix, adapt, build upon this work non-commercially, and license their derivative works on different terms, provided the original work is properly cited and the use is non-commercial. See: <https://creativecommons.org/licenses/by-nc/4.0/>

Country/Territory of origin: China

ORCID number: Miao-Miao Zhang 0000-0001-5679-7061; Guang-Bin Zhao 0009-0008-1730-3506; Han-Zhi Zhang 0000-0002-9972-9875; Shu-Qin Xu 0000-0002-1035-2750; Ai-Hua Shi 0000-0002-5412-1401; Jian-Qi Mao 0000-0003-2984-0102; Jing-Ci Gai 0009-0007-8844-6910; Yu-Han Zhang 0000-0001-5839-1380; Jia Ma 0000-0002-9176-0472; Yun Li 0009-0002-9270-0508; Yi Lyu 0000-0003-3636-6664; Xiao-Peng Yan 0000-0002-0335-829X.

S-Editor: Lin C

L-Editor: A

P-Editor: Yu HG

REFERENCES

- Zhou W**, Xia L, Wang Z, Cao G, Chen L, Chen E, Zhang W, Song Z. Transanal Minimally Invasive Surgery for Rectal Anastomotic Stenosis After Colorectal Cancer Surgery. *Dis Colon Rectum* 2022; **65**: 1062-1068 [PMID: 35421009 DOI: 10.1097/DCR.0000000000002361]
- Murata M**, Watanabe Y, Miyamoto S. Colonic Stenosis Caused by Transcatheter Arterial Embolization. *Clin Gastroenterol Hepatol* 2022; **20**: e645-e646 [PMID: 33781940 DOI: 10.1016/j.cgh.2021.03.032]
- Mandal AK**, Kafle P, Puri P, Chaulagai B, Hassan M, Bhattarai B, Kanth R, Gayam V. Acute Pancreatitis Causing Descending Colonic Stricture: A Rare Sequelae. *J Investig Med High Impact Case Rep* 2019; **7**: 2324709619834594 [PMID: 30917672 DOI: 10.1177/2324709619834594]
- Hirai F**. Current status of endoscopic balloon dilation for Crohn's disease. *Intest Res* 2017; **15**: 166-173 [PMID: 28522945 DOI: 10.5217/ir.2017.15.2.166]
- Bemelman WA**, Allez M. The surgical intervention: earlier or never? *Best Pract Res Clin Gastroenterol* 2014; **28**: 497-503 [PMID: 24913388 DOI: 10.1016/j.bpg.2014.04.013]
- Moroi R**, Shiga H, Nochioka K, Chiba H, Shimoyama Y, Kuroha M, Tosa M, Kakuta Y, Kayaba S, Takahashi S, Kinouchi Y, Masamune A. Endoscopic radial incision and cutting for benign stenosis of the lower gastrointestinal tract: An investigation of novel endoscopic treatment in multicenter trial. *J Gastroenterol Hepatol* 2022; **37**: 1554-1560 [PMID: 35506307 DOI: 10.1111/jgh.15882]
- Gagner M**, Krinke T, Lapointe-Gagner M, Buchwald JN. Side-to-side duodeno-ileal magnetic compression anastomosis: design and feasibility of a novel device in a porcine model. *Surg Endosc* 2023; **37**: 6197-6207 [PMID: 37170025 DOI: 10.1007/s00464-023-10105-x]
- Hornok Z**, Kubiak R, Csukas D, Ferencz A, Cserni T. Esophageal Magnetic Anastomosis Device (EMAD) to Simplify and Improve Outcome of Thoracoscopic Repair for Esophageal Atresia with Tracheoesophageal Fistula: A Proof of Concept Study. *J Pediatr Surg* 2023; **58**: 1489-1493 [PMID: 36307298 DOI: 10.1016/j.jpedsurg.2022.09.040]
- Muensterer OJ**, Sterlin A, Oetzmann von Sochaczewski C, Lindner A, Heimann A, Balus A, Dickmann J, Nuber M, Patel VH, Manfredi MA, Jennings RW, Smithers CJ, Fauza DO, Harrison MR. An experimental study on magnetic esophageal compression anastomosis in piglets. *J Pediatr Surg* 2020; **55**: 425-432 [PMID: 31128845 DOI: 10.1016/j.jpedsurg.2019.04.029]
- Obora Y**, Tamaki N, Matsumoto S. Nonsuture microvascular anastomosis using magnet rings: preliminary report. *Surg Neurol* 1978; **9**: 117-120 [PMID: 625696]
- Zhang M**, Ma J, An Y, Lyu Y, Yan X. Construction of an intrahepatic portosystemic shunt using the magnetic compression technique: preliminary experiments in a canine model. *Hepatobiliary Surg Nutr* 2022; **11**: 611-615 [PMID: 36016743 DOI: 10.21037/hbsn-22-209]
- Gao Y**, Wu RQ, Lv Y, Yan XP. Novel magnetic compression technique for establishment of a canine model of tracheoesophageal fistula. *World J Gastroenterol* 2019; **25**: 4213-4221 [PMID: 31435174 DOI: 10.3748/wjg.v25.i30.4213]
- Uygun I**, Okur MH, Cimen H, Keles A, Yalcin O, Ozturk H, Otcu S. Magnetic compression ostomy as new cystostomy technique in the rat: magnacystostomy. *Urology* 2012; **79**: 738-742 [PMID: 22386431 DOI: 10.1016/j.urology.2011.11.048]
- Kamada T**, Ohdaira H, Hoshimoto S, Narihiro S, Suzuki N, Marukuchi R, Takeuchi H, Yoshida M, Yamanouchi E, Suzuki Y. Magnetic compression anastomosis with atypical anastomosis for anastomotic stenosis of the sigmoid colon: a case report. *Surg Case Rep* 2020; **6**: 59 [PMID: 32291530 DOI: 10.1186/s40792-020-00826-9]
- Russell KW**, Rollins MD, Feola GP, Scaife ER. Magnamosis: a novel technique for the management of rectal atresia. *BMJ Case Rep* 2014; **2014** [PMID: 25096648 DOI: 10.1136/bcr-2013-201330]
- Kamada T**, Ohdaira H, Takeuchi H, Takahashi J, Ito E, Suzuki N, Narihiro S, Yoshida M, Yamanouchi E, Suzuki Y. New Technique for Magnetic Compression Anastomosis Without Incision for Gastrointestinal Obstruction. *J Am Coll Surg* 2021; **232**: 170-177.e2 [PMID: 33190786 DOI: 10.1016/j.jamcollsurg.2020.10.012]
- Lu G**, Li J, Ren M, Ma F, Sun X, Lv Y, He S. Endoscopy-assisted magnetic compression anastomosis for rectal anastomotic atresia. *Endoscopy* 2021; **53**: E437-E439 [PMID: 33506462 DOI: 10.1055/a-1322-1899]
- Ellebaek MBB**, Qvist N, Rasmussen L. Magnetic Compression Anastomosis in Long-Gap Esophageal Atresia Gross Type A: A Case Report. *European J Pediatr Surg Rep* 2018; **6**: e37-e39 [PMID: 29796381 DOI: 10.1055/s-0038-1649489]
- Hiratsuka T**, Inomata M. A novel animal model of colonic stenosis to aid the development of new stents for colon strictures. *Surg Endosc* 2022; **36**: 3152-3159 [PMID: 34159466 DOI: 10.1007/s00464-021-08618-4]



Published by **Baishideng Publishing Group Inc**
7041 Koll Center Parkway, Suite 160, Pleasanton, CA 94566, USA

Telephone: +1-925-3991568

E-mail: bpgoffice@wjgnet.com

Help Desk: <https://www.f6publishing.com/helpdesk>

<https://www.wjgnet.com>

