

# World Journal of *Gastroenterology*

*World J Gastroenterol* 2023 January 28; 29(4): 582-765



## REVIEW

- 582 Cytotoxic synergism of *Clostridioides difficile* toxin B with proinflammatory cytokines in subjects with inflammatory bowel diseases  
*Bassotti G, Fruganti A, Stracci F, Marconi P, Fettucciari K*
- 597 Immune and metabolic cross-links in the pathogenesis of comorbid non-alcoholic fatty liver disease  
*Kotlyarov S*
- 616 Iron as a therapeutic target in chronic liver disease  
*Kouroumalis E, Tsomidis I, Voumvouraki A*

## MINIREVIEWS

- 656 COVID-19 and the liver: Are footprints still there?  
*Gupta T, Sharma H*
- 670 Nanomedicine-based multimodal therapies: Recent progress and perspectives in colon cancer  
*He YC, Hao ZN, Li Z, Gao DW*
- 682 Gaseous metabolites as therapeutic targets in ulcerative colitis  
*Yao CK, Sarbagili-Shabat C*

## ORIGINAL ARTICLE

## Retrospective Cohort Study

- 692 Disease trends after *Helicobacter pylori* eradication based on Japanese nationwide claims and the health check-up database  
*Mizukami K, Sugano K, Takeshima T, Murakami K*

## Retrospective Study

- 706 Diagnostic and economic value of carcinoembryonic antigen, carbohydrate antigen 19-9, and carbohydrate antigen 72-4 in gastrointestinal cancers  
*Liu HN, Yao C, Wang XF, Zhang NP, Chen YJ, Pan D, Zhao GP, Shen XZ, Wu H, Liu TT*
- 731 Feasibility and efficacy of endoscopic purse-string suture-assisted closure for mucosal defects induced by endoscopic manipulations  
*Li MM, Zhang Y, Sun F, Huai MX, Zhang FY, Qu CY, Shen F, Li ZH, Xu LM*

## Observational Study

- 744 Trends in gastrointestinal disease hospitalizations and outcomes during the first year of the coronavirus pandemic  
*Adekunle AD, Rubens M, Sedarous M, Tariq T, Okafor PN*

**CASE REPORT**

- 758** Pulmonary cryptococcosis after immunomodulator treatment in patients with Crohn's disease: Three case reports

*Fang YF, Cao XH, Yao LY, Cao Q*

**ABOUT COVER**

Editorial Board Member of *World Journal of Gastroenterology*, Angela Peltec, PhD, Associate Professor, Department of Internal Medicine, Discipline of Gastroenterology, State University of Medicine and Pharmacy "Nicolae Testemitanu", Chishinev 2019, Moldova. [apeltec@yahoo.com](mailto:apeltec@yahoo.com)

**AIMS AND SCOPE**

The primary aim of *World Journal of Gastroenterology* (WJG, *World J Gastroenterol*) is to provide scholars and readers from various fields of gastroenterology and hepatology with a platform to publish high-quality basic and clinical research articles and communicate their research findings online. WJG mainly publishes articles reporting research results and findings obtained in the field of gastroenterology and hepatology and covering a wide range of topics including gastroenterology, hepatology, gastrointestinal endoscopy, gastrointestinal surgery, gastrointestinal oncology, and pediatric gastroenterology.

**INDEXING/ABSTRACTING**

The WJG is now abstracted and indexed in Science Citation Index Expanded (SCIE, also known as SciSearch®), Current Contents/Clinical Medicine, Journal Citation Reports, Index Medicus, MEDLINE, PubMed, PubMed Central, Scopus, Reference Citation Analysis, China National Knowledge Infrastructure, China Science and Technology Journal Database, and Superstar Journals Database. The 2022 edition of Journal Citation Reports® cites the 2021 impact factor (IF) for WJG as 5.374; IF without journal self cites: 5.187; 5-year IF: 5.715; Journal Citation Indicator: 0.84; Ranking: 31 among 93 journals in gastroenterology and hepatology; and Quartile category: Q2. The WJG's CiteScore for 2021 is 8.1 and Scopus CiteScore rank 2021: Gastroenterology is 18/149.

**RESPONSIBLE EDITORS FOR THIS ISSUE**

Production Editor: *Yu-Xi Chen*; Production Department Director: *Xu Guo*; Editorial Office Director: *Jia-Ru Fan*.

**NAME OF JOURNAL**

*World Journal of Gastroenterology*

**ISSN**

ISSN 1007-9327 (print) ISSN 2219-2840 (online)

**LAUNCH DATE**

October 1, 1995

**FREQUENCY**

Weekly

**EDITORS-IN-CHIEF**

Andrzej S Tarnawski

**EDITORIAL BOARD MEMBERS**

<http://www.wjgnet.com/1007-9327/editorialboard.htm>

**PUBLICATION DATE**

January 28, 2023

**COPYRIGHT**

© 2023 Baishideng Publishing Group Inc

**INSTRUCTIONS TO AUTHORS**

<https://www.wjgnet.com/bpg/gerinfo/204>

**GUIDELINES FOR ETHICS DOCUMENTS**

<https://www.wjgnet.com/bpg/GerInfo/287>

**GUIDELINES FOR NON-NATIVE SPEAKERS OF ENGLISH**

<https://www.wjgnet.com/bpg/gerinfo/240>

**PUBLICATION ETHICS**

<https://www.wjgnet.com/bpg/GerInfo/288>

**PUBLICATION MISCONDUCT**

<https://www.wjgnet.com/bpg/gerinfo/208>

**ARTICLE PROCESSING CHARGE**

<https://www.wjgnet.com/bpg/gerinfo/242>

**STEPS FOR SUBMITTING MANUSCRIPTS**

<https://www.wjgnet.com/bpg/GerInfo/239>

**ONLINE SUBMISSION**

<https://www.f6publishing.com>



## Retrospective Study

# Feasibility and efficacy of endoscopic purse-string suture-assisted closure for mucosal defects induced by endoscopic manipulations

Ming-Ming Li, Yi Zhang, Fang Sun, Man-Xiu Huai, Fei-Yu Zhang, Chun-Ying Qu, Feng Shen, Zheng-Hong Li, Lei-Ming Xu

**Specialty type:** Gastroenterology and hepatology

### Provenance and peer review:

Unsolicited article; Externally peer reviewed.

**Peer-review model:** Single blind

### Peer-review report's scientific quality classification

Grade A (Excellent): 0  
Grade B (Very good): B  
Grade C (Good): C  
Grade D (Fair): 0  
Grade E (Poor): 0

**P-Reviewer:** Sulbaran MN, Brazil; Takita M, Japan

**Received:** October 16, 2022

**Peer-review started:** October 16, 2022

**First decision:** November 17, 2022

**Revised:** November 27, 2022

**Accepted:** January 9, 2023

**Article in press:** January 9, 2023

**Published online:** January 28, 2023



Ming-Ming Li, Yi Zhang, Fang Sun, Man-Xiu Huai, Fei-Yu Zhang, Chun-Ying Qu, Feng Shen, Zheng-Hong Li, Lei-Ming Xu, Department of Gastroenterology, Xinhua Hospital, Shanghai Jiaotong University School of Medicine, Shanghai 200092, China

**Corresponding author:** Lei-Ming Xu, MD, Chief Doctor, Professor, Department of Gastroenterology, Xinhua Hospital, Shanghai Jiaotong University School of Medicine, No. 1665 Kongjiang Road, Shanghai 200092, China. [xuleiming@xinhuaamed.com.cn](mailto:xuleiming@xinhuaamed.com.cn)

## Abstract

### BACKGROUND

Large or transmural defects induced by gastrointestinal endoscopic manipulations are difficult to close, although complete closure is recommended for better recovery. Endoscopic purse-string assisted suturing (EPSS) has been used in clinical practice and has proven to be an effective and safe technique for the closure of large mucosal defects. However, details regarding the efficacy of endoscopic pre-purse-string suture (P-EPSS) are unknown, especially that it offers several advantages over conventional EPSS (C-EPSS).

### AIM

To elucidate the outcomes of EPSS-assisted closure in different clinical situations, and evaluate the efficacy of P-EPSS.

### METHODS

This retrospective observational study included a total of 180 patients who underwent closure assisted by P-EPSS ( $n = 63$ ) or C-EPSS ( $n = 117$ ) between July 2014 and June 2020. The P-EPSS and C-EPSS groups were compared and the intergroup differences in aspects such as the lesion size, location, and morphology, incidence of complete closure, intraoperative perforation, and delayed adverse events were evaluated. Data on the features and clinical course of cases with adverse events were collected for further analysis.

### RESULTS

Patients with lesion size larger than 3 cm, lesions located at the fundus of stomach, or submucosal tumors originating from the deep mucosa were more likely to undergo P-EPSS-assisted closure. The P-EPSS group showed a significantly higher proportion of intraoperative perforation (56% vs 17%) and a much

shorter procedure time ( $9.06 \pm 6.14$  min *vs*  $14.84 \pm 7.25$  min). Among adverse events, the incidence of delayed perforation (5% *vs* 4%;  $P = 0.82$ ) and delayed bleeding (3% *vs* 4%;  $P = 0.96$ ) did not differ significantly between the groups. Multivariate analysis revealed that lesions with incomplete closure [odds ratio (OR) = 21.33; 95% confidence interval (CI): 5.45-83.45;  $P < 0.01$ ] or size greater than 3 cm (OR = 3.14; 95%CI: 1.08-9.18;  $P = 0.039$ ) showed a statistical tendency to result in an increase in delayed adverse events.

## CONCLUSION

The present study revealed that EPSS could achieve secure complete closure of mucosal defect. P-EPSS could shorten the procedure and yield complete closure of mucosal defects. Rather than closure-type selection, incomplete closure or lesion size larger than 3 cm were associated with worse outcomes.

**Key Words:** Endoscopic purse-string suture; Mucosal defect; Endoscopic full-thickness resection; Endoscopic submucosal dissection

©The Author(s) 2023. Published by Baishideng Publishing Group Inc. All rights reserved.

**Core Tip:** Endoscopic purse-string assisted suturing (EPSS) has proven to be an effective and safe technique for the closure of large mucosal defects. Endoscopic pre-purse-string suture (P-EPSS) is recently introduced and offers several advantages over conventional endoscopic purse-string suture (C-EPSS). We found that the novel method could offer several advantages over C-EPSS. This retrospective observational study included a total of 180 patients who underwent P-EPSS ( $n = 63$ ) or C-EPSS ( $n = 117$ ), and evaluate the feasibility and efficacy of P-EPSS-assisted closure in different clinical situations. In conclusion, EPSS could achieve secure complete closure of mucosal defect. P-EPSS could shorten the procedure and yield complete closure of mucosal defects rather than the C-EPSS closure-type.

**Citation:** Li MM, Zhang Y, Sun F, Huai MX, Zhang FY, Qu CY, Shen F, Li ZH, Xu LM. Feasibility and efficacy of endoscopic purse-string suture-assisted closure for mucosal defects induced by endoscopic manipulations. *World J Gastroenterol* 2023; 29(4): 731-743

**URL:** <https://www.wjgnet.com/1007-9327/full/v29/i4/731.htm>

**DOI:** <https://dx.doi.org/10.3748/wjg.v29.i4.731>

## INTRODUCTION

The endoscopic purse-string assisted suturing (EPSS) method has been used in clinical practice for nearly 20 years and has proven to be an effective and safe technique for the closure of large mucosal defects induced by endoscopic manipulations[1-5]. Inspired by the surgical purse-string suture strategy, an endoloop and repositionable clips have been successfully combined to manage intraluminal wounds *via* an endoscope[6-10]. However, some defects are difficult to resect and are expected to induce perforation during endoscopic manipulations, necessitating the application of an endoscopic pre-purse-string suture (P-EPSS) procedure. This novel suture method was first described by Wu *et al*[11] and was usually applied in cases involving exposed endoscopic full-thickness resections (EFTRs). At our medical center, we expanded the indications for P-EPSS and attempted to use it in more procedures such as endoscopic submucosal dissection (ESD) and endoscopic submucosal excavation (ESE) of big defects, potentially simplifying the process of closure and avoiding the possibility of postoperative adverse events.

To our knowledge, no previous reports have described the advantages of P-EPSS over conventional EPSS (C-EPSS). Furthermore, previous clinical studies on the application of EPSS usually had small sample sizes and mainly focused on providing detailed descriptions of endoscopic procedures rather than assessing the feasibility and efficacy of the technique[12-15]. Therefore, we conducted a large-scale analysis of case series focusing on the effectiveness and safety of EPSS. We compared the differences between the P-EPSS and C-EPSS group in many aspects and tried to illustrate the considerations involved in choosing the appropriate closure type according to the defect's clinical characteristics.

## MATERIALS AND METHODS

### Study design

This was a retrospective observational study performed in accordance with the Helsinki Declaration. It was approved by the Ethics Committee at Xinhua Hospital (approval number: XHEC-C-2018-109), Shanghai Jiaotong University School of Medicine. Written informed consent for the procedures was obtained from all patients.

### Eligible patients

A total of 180 consecutive patients with large mucosal defects who underwent C-EPSS or P-EPSS at our institute from July 2014 to June 2020 were included in the study. We compared the findings between the P-EPSS group ( $n = 63$ ) and C-EPSS group ( $n = 117$ ) for further analysis. All patients had undergone different endoscopic manipulations (ESD, ESE, or exposed EFTR), and the endoscopic suture method was applied to close large mucosal defects with or without transmural defects. All the procedures were completed by four chief physicians who had more than 10 years of experience in performing endoscopic operations. The patient database included data pertaining to patient demographics, location and size of the mucosal defects after resection, procedure time, successful closure rate, delayed adverse events, duration of hospitalization, and total cost of hospitalization.

### C-EPSS and P-EPSS procedures

The endoscopic manipulation always started with the mucosa marking procedure, in which markings were placed 3 to 5 mm outside the circumference of the lesion. After injection of epinephrine diluted in saline solution (1:100000) into the submucosal layer to raise the submucosa, endoscopists performed the resection procedure. The C-EPSS procedure is a common method used for closure of defects. After dissection of precancerous lesions or tumor specimens, an endoloop and clips were inserted simultaneously into the location of defect through the therapeutic endoscope for complete closure. Single-channel or double-channel endoscopy was used according to the specific defect status. The endoloop was anchored onto the full thickness of the defect's distal margin with the clip, followed by insertion of three to six additional clips to anchor the endoloop at different sides of the margin. Finally, the endoloop was tightened by slightly pulling all the edges together. Other clips were used if any clip was not accurately positioned or the purse-string suture was not tight.

The P-EPSS procedure was always used when defects were difficult to resect and expected to induce perforation. In these cases, to reduce difficulties in manipulation in the suturing process, decrease the entry of gas into the abdominal cavity, and avoid postoperative adverse events, the endoloop and clips were advanced around the defect before the end of the dissection phase; this procedure was routinely performed with one or two clips. The remaining clips were anchored around the defects when the lesions were resected. Tightening of the endoloop was immediately performed after placement of the clips. This procedure was named P-EPSS. An example of the closure procedure is shown in Figures 1A-I and the [Video\(Supplementary material\)](#).

The procedure time of the P-EPSS-assisted closure was defined as the time from the usage of the first clip in the operation to completion of the closure, but the time required for the resection procedure was excluded (as shown in Figures 1C and 1F-I). Exclusion of the time required for the resection procedure was considered appropriate due to the differences in the difficulty levels in the operation.

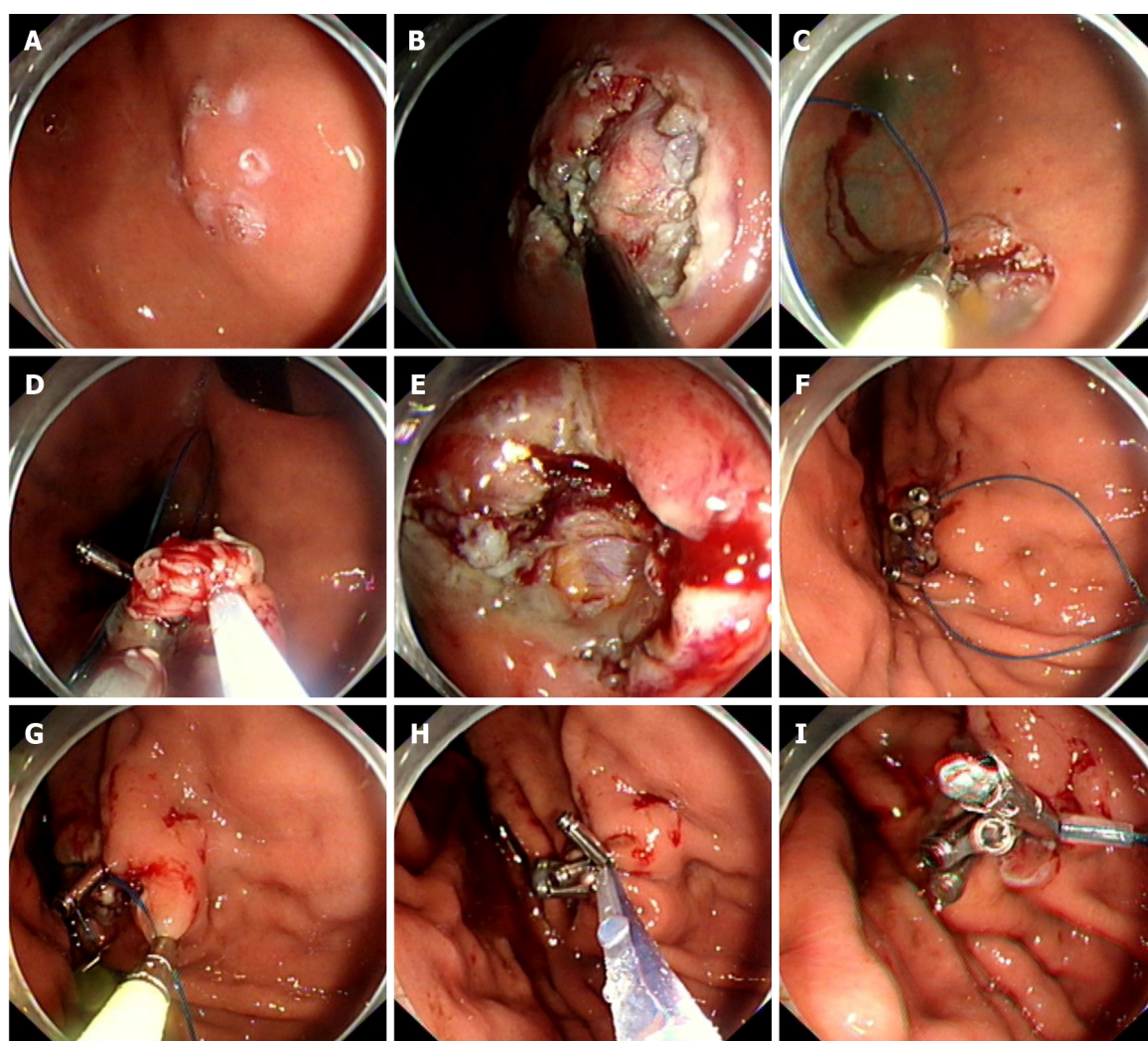
### Postoperative management

After the manipulations, the patients received drug therapy and were fasted for 2-4 d; body temperature was monitored daily, and postoperative adverse events were recorded as required. After evaluating the results of blood examinations and abdominal radiographs, the patients were allowed to drink, which was followed by a liquid diet. Proton pump inhibitors (rabeprazole 20 mg/d, lansoprazole 30 mg/d, or esomeprazole 20 mg/d) were administered for 1 mo if the patients had undergone upper gastrointestinal (GI) tract surgeries. Prophylactic antibiotics were routinely used in patients who showed intraoperative perforation and in patients with elevated white blood cell counts. If the patients showed good outcomes, they were discharged after 3-5 d. The first clinical follow-up was performed 3-6 mo after the manipulation, and then annually after the first year. The follow-up assessments included evaluation of digestive symptoms and gastro/enteroscopy.

### Measured outcomes

The success rate of complete closure, incidence of adverse events (delayed perforation and bleeding), procedure time, duration of hospitalization, and total costs were analysed as outcomes of EPSS-assisted closure of mucosal defects and compared them between the P-EPSS and C-EPSS groups. The definition of perforation required elucidation in advance and included intraoperative and delayed perforation. The former was defined as a perforation observed before the end of the endoscopic manipulation, indicating the formation of a transmural defect during the operation; the latter was defined as any perforation found thereafter. Delayed bleeding was defined as hematemesis or melena requiring endoscopic hemostasis after the procedure. We did not treat adverse events occurring during the





DOI: 10.3748/wjg.v29.i4.731 Copyright ©The Author(s) 2023.

**Figure 1** Schematic figure of the pre-endoscopic purse-string assisted suturing procedure. A: Mucosa marking step: Dots were marked around the tumor; B: Expose the lesion; C: Pre-endoscopic purse-string assisted suturing by using an endoloop and a metal clip; D and E: Intraoperative perforation in exposed endoscopic full-thickness resection; F-I: Immediate closure of the perforation by tightening endoloop.

endoscopic procedure, such as intraoperative perforation in exposed EFTR, as events; only delayed adverse events such as perforations or bleeding appearing after the end of closure were treated as events. We collected data on the features and clinical course of cases with adverse events, and analyzed associations between the unsatisfactory outcomes and defect features (complete closure or not, location, size, morphology, and closure type).

### Statistical analyses

Categorical variables were analyzed using Pearson's chi-squared test or Fisher's exact test, as appropriate. For instance, as listed in Table 1, we used Pearson's chi-squared test to analyze the predictors when using the P-EPSS method. Continuous variables were analyzed using the student *t* test. The data for duration and cost of hospitalization were analyzed and summarized in Table 2. *P* values < 0.05 were considered statistically significant. All data were analyzed using the SPSS for Windows statistical software package (version 22.0; SPSS, Chicago, IL, United States).

## RESULTS

### Baseline characteristics

Patient details are described in Table 3. During the study period, 117 patients underwent C-EPSS, while 63 patients underwent P-EPSS for closure of defects induced by endoscopic manipulations. The ratio of different endoscopic manipulations (exposed EFTR:ESE:ESD) used in the study was approximately 1:1:3 (36:32:112), but this ratio showed no significant difference between the P-EPSS and C-EPSS groups (*P* >



**Table 1 Predictors for closure of mucosal defects using endoscopic pre-purse-string suture method**

Predictors	P-EPSS/C-EPSS (n)	Odds ratio	95%CI	P value
Location (%)				
Fundus	35/44	2.07	1.11-3.86	0.03 <sup>1</sup>
Others	28/73	1		
Defect size				
≥ 3 cm	44/8	31.55	12.86-77.40	< 0.01 <sup>1</sup>
< 3 cm	19/109	1		
Morphology				
Deep SMT	36/40	2.57	1.37-4.81	< 0.01 <sup>1</sup>
Others	27/77	1		

<sup>1</sup>Statistically significant.

P-EPSS: Endoscopic pre-purse-string suture; C-EPSS: Conventional endoscopic purse-string suture; SMT: Submucosal tumor; CI: Confidence interval.

**Table 2 Outcomes of purse-string suture according to different closure type**

Outcomes	Total	P-EPSS	C-EPSS	P value
Complete closure, n (%)	169 (94)	59 (94)	110 (94)	0.80
Intraoperative perforation, n (%)	55 (31)	35 (56)	20 (17)	< 0.01 <sup>1</sup>
Delayed adverse events, n (%)				
Delayed perforation	8 (4)	3 (5)	5 (4)	0.82
Delayed bleeding	7 (4)	2 (3)	5 (4)	0.96
Operation time (min), mean ± SD	12.82 ± 7.83	9.06 ± 6.14	14.84 ± 7.25	< 0.01 <sup>1</sup>
Fasting period (d), median (range)	2 (1-5)	2 (1-5)	2 (1-5)	0.88
Hospital stay (d), median (range)	6 (4-11)	6 (4-10)	6 (4-11)	0.87
Total cost (dollars), mean ± SD	2481 ± 445	2448 ± 365	2498 ± 418	0.47

<sup>1</sup>Statistically significant.

SD: Standard deviation; P-EPSS: Endoscopic pre-purse-string suture; C-EPSS: Conventional endoscopic purse-string suture.

0.05). In terms of the location, more than three-quarters of the defects were located in the stomach, especially in the part of the fundus (44%). The mean defect size was  $2.5 \pm 1.46$  cm. The difference in defect size between the P-EPSS and C-EPSS groups was significant ( $3.6 \pm 1.13$  cm *vs*  $2.5 \pm 0.68$  cm,  $P < 0.05$ ). In terms of defect morphology, more than 70% of the defects were submucosal tumors; 42% were submucosal tumors (SMTs) located in the deep muscularis propria and 31% were superficial SMTs. The size and morphology of the defects in the two groups were different, and a detailed analysis of these characteristics is provided in the next section.

### **P-EPSS predictors related to the defect's clinical features**

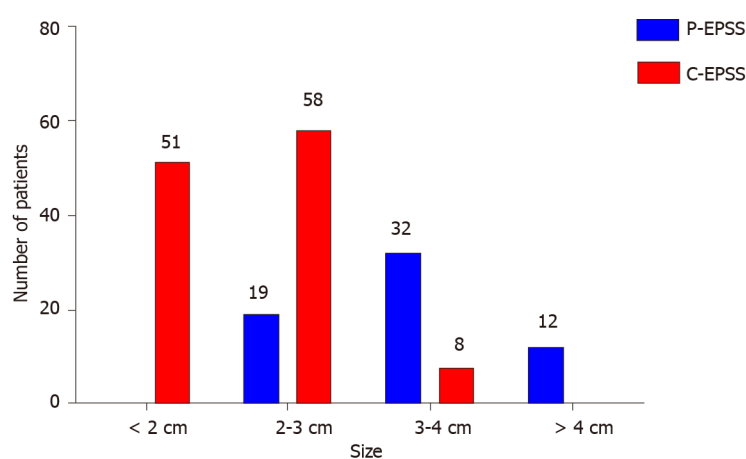
As mentioned above, many factors, including the defect's position, size, and morphology, could indicate and predict the choice of the P-EPSS method. In terms of position, more than half (54%) of the defects in the P-EPSS group were located at the fundus of the stomach, which was much higher than the corresponding proportion in the C-EPSS group (38%). In terms of the size, the proportion of cases with defects larger than 3 cm in the P-EPSS group was significantly more than the proportion of cases with defects < 3 cm in size ( $P < 0.01$ ), indicating a significant trend toward the use of P-EPSS to close large defects. We designed a histogram to illustrate the choice of closure type according to the defect size, as shown in Figure 2. In terms of the morphology, no significant increase was observed in the proportion of cases involving P-EPSS in relation to the morphology of SMTs (33% *vs* 41%,  $P > 0.05$ ). The difference between the P-EPSS and C-EPSS groups was significant only for patients with SMTs originating from the muscularis propria (57% *vs* 34%,  $P < 0.01$ ). In terms of differences in endoscopic manipulations, no significant increase was observed in the proportion of P-EPSS cases in the exposed EFTR group (42% *vs*

**Table 3** Baseline characteristics of the cases in this study

Patients detail	Total (n = 180)	P-EPSS (n = 63)	C-EPSS (n = 117)	P value
Age (yr), mean (range)	60 (38-78)	62 (42-76)	60 (38-78)	0.19
Sex, n (%)				0.75
Female	112 (62)	38 (60)	74 (63)	
Male	68 (38)	25 (40)	43 (37)	
Manipulation, n (%)				0.40
EFTR	36 (20)	15 (24)	21 (18)	
ESE	32 (18)	13 (21)	19 (16)	
ESD	112 (62)	35 (55)	77 (66)	
Location, n(%)				0.10
Stomach				
Fundus	79 (44)	35 (56)	44 (38)	
Body	45 (25)	11 (17)	34 (29)	
Antrum	22 (12)	8 (13)	14 (12)	
Colon and rectum	34 (19)	9 (14)	25 (21)	
Defect size (cm), mean $\pm$ SD	2.89 $\pm$ 1.46	3.6 $\pm$ 1.13	2.5 $\pm$ 0.68	0.02 <sup>1</sup>
Morphology, n(%)				0.01 <sup>1</sup>
Deep SMT	76 (42)	36 (57)	40 (34)	
Superficial SMT	55 (31)	15 (24)	40 (34)	
Precancerous lesions	49 (27)	12 (19)	37 (32)	

<sup>1</sup>Statistically significant.

SD: Standard deviation; SMT: Submucosal tumor; ESD: Endoscopic submucosal dissection; ESE: Endoscopic submucosal excavation; EFTR: Endoscopic full-thickness resection; P-EPSS: Endoscopic pre-purse-string suture; C-EPSS: Conventional endoscopic purse-string suture.



DOI: 10.3748/wjg.v29.i4.731 Copyright ©The Author(s) 2023.

**Figure 2** Histogram of the choice of closure type according to the defect size. P-EPSS: Endoscopic pre-purse-string suture; C-EPSS: Conventional endoscopic purse-string suture.33%,  $P > 0.05$ ).

Next, we performed multivariate analysis to identify predictors for P-EPSS. Defect location at the fundus of the stomach [odds ratio (OR) = 2.07; 95% confidence interval (CI): 1.11-3.86;  $P = 0.03$ ], defect size larger than 3 cm (OR = 31.55; 95%CI: 12.86-77.40;  $P < 0.01$ ), and SMTs originating from the deep mucosa (OR = 2.57; 95%CI: 1.37-4.81;  $P < 0.01$ ) were significantly associated with a high rate of P-EPSS (Table 1).

### Comparison of treatment outcomes between the P-EPSS and C-EPSS groups

**Table 2** presents a comparison of treatment outcomes between the P-EPSS and C-EPSS groups. The proportion of complete closure assisted by purse-string sutures was 94% and was similar between the two groups. Patients with incomplete closure received conservative treatment and eventually recovered from the trauma. None of them required alternative surgical repair procedures. While more patients from the P-EPSS group were inclined to experience intraoperative perforation (56% *vs* 17%,  $P < 0.01$ ), the procedure time was significantly shorter in the P-EPSS group ( $9.06 \pm 6.14$  min *vs*  $14.84 \pm 7.25$  min,  $P < 0.01$ ).

In the assessment of adverse events, the two groups showed no significant differences in the proportions of delayed perforation (5% *vs* 4%;  $P = 0.82$ ) and delayed bleeding (3% *vs* 4%;  $P = 0.96$ ). Cases of adverse events were successfully managed by endoscopic treatment and conservative therapy. After the treatment, the fasting period, duration of hospitalization, and total cost of hospitalization were similar between the two groups.

### Analysis of risk factors for delayed adverse events

The features and clinical course of the 15 cases showing delayed adverse events are shown in **Table 4**, and the results of the logistic regression analysis are shown in **Table 5**. Multivariate analysis revealed that incomplete closure of the defect was the main independent predictor for an increased number of delayed perforation or bleeding events, and it showed approximately 95% significant increase in delayed adverse events (OR = 21.33; 95%CI: 5.45-83.45;  $P < 0.01$ ). Moreover, cases with defect size more than 3 cm showed a statistical tendency toward an increase in delayed adverse events (OR = 3.14; 95%CI: 1.08-9.18;  $P = 0.039$ ). However, defect position (fundus or others) or morphology (SMT or precancerous lesions) as well as the closure type selected (P-EPSS or C-EPSS) were not related to significant differences in delayed adverse events.

## DISCUSSION

With the development and popularization of endoscopic techniques, more GI diseases can be detected early and manipulated using minimally invasive methods[16-18]. GI endoscopy procedures such as ESD, ESE, EFTR, and submucosal tunnel endoscopic resection are widely used for the treatment of precancerous lesions or SMTs within the GI tract[19-23]. However, their increasing usage has led to the problem of achieving successful complete closure of the mucosal defects induced by different endoscopic manipulations.

Clips can be applied to effectively manage small defects, but they are too small to work well for large mucosal defects. More importantly, tissue approximation with full-thickness closure is technically impossible with clips, and clips may prematurely drop off the mucosa due to peristalsis and the radial forces of large post-EFTR defects, resulting in delayed perforation and severe complications. Furthermore, clip-closure methods appear to be strongly operator-dependent[9,24,25].

These factors have necessitated the development of new techniques. As reported in one study, various techniques have been used for closure of large defects (especially for exposed defects after EFTR), and these mainly consist of clip- and endoloop-assisted closure methods[26]. For instance, multiple studies reported that over-the-scope-clip (OTSC) application, which can close defects with serosa-to-serosa apposition, unlike mucosa-to-mucosa apposition, can successfully close defects with long-term reliability[27-30]. However, OTSCs can close GI defects only up to 2.5-3 cm in size[31,32], and the OTSC system shows limited effectiveness in some anatomic sites, such as the pylorus and the proximal esophagus. In addition, the edema and tissue folding associated with the usage of OTSCs can potentially narrow the lumen[33], and the OTSC technique is expensive, which can increase the financial burden on patients.

Purse-string assisted suturing has been widely used and is a financially feasible approach in cases with large defects induced by endoscopic manipulations. However, previous studies on the efficacy of EPSS methods evaluated a limited source of cases. Moreover, most of these studies focused on providing a detailed introduction of the procedure for purse-string sutures rather than performing a detailed analysis of its feasibility and efficacy. Wang *et al*[12] reported that the purse-string suture for colonic mucosal defects could be successfully completed using a single-channel endoscope. They described the detailed procedure of the EPSS method and concluded that no severe complications were recorded in all 18 cases. Kato *et al*[34] summarized their findings for duodenal ESD and found that complete closure of the mucosal defect by the EPSS method was relatively easy and involved a reduced delayed adverse event rate. Other related studies always introduced the use of this technique for some specific conditions, such as iatrogenic perforations in the colon or duodenum. Ryu *et al*[13] performed the purse-string suture technique to close iatrogenic colon perforations in eight cases and verified that EPSS can be appropriate for closing large colon perforations. In their analyses of the data obtained from 23 cases involving the closure of large iatrogenic duodenal perforations with purse-string sutures, Zhu *et al*[14] concluded that the EPSS method was feasible, effective, and easy for closure of perforations. Furthermore, some other studies focused on endoloop-assisted closure of exposed defects after EFTR

Table 4 Clinical features of 15 patients with adverse events												
Age (yr)	Sex	Manipulation	Location	Size (cm)	Morphology	Closure type	Complete closure	Intraoperative perforation	Procedure time (min)	Delayed adverse events	Discharge (d)	Total cost (dollars)
60	Male	ESD	Fundus	3	Superficial SMT	C-EPSS	Yes	Yes	20	Delayed bleeding	10	2522
58	Male	EFTR	Fundus	4	Deep SMT	P-EPSS	Yes	Yes	15	Delayed perforation	11	2835
75	Female	ESD	Rectum	2.5	Superficial SMT	C-EPSS	No	No	22	Delayed bleeding	9	2710
56	Female	ESE	Fundus	3.5	Deep SMT	P-EPSS	No	No	24	Delayed perforation	6	2238
74	Female	ESD	Antrum	2	Precancerous lesion	C-EPSS	Yes	No	20	Delayed bleeding	7	2489
68	Male	ESD	Body	2.5	Deep SMT	C-EPSS	No	No	10	Delayed perforation	8	2470
58	Male	EFTR	Fundus	4	Superficial SMT	P-EPSS	Yes	Yes	15	Delayed perforation	7	2556
62	Male	ESE	Rectum	3.5	Precancerous lesion	C-EPSS	No	No	20	Delayed perforation	10	2884
63	Female	ESD	Antrum	3.5	Precancerous lesion	C-EPSS	No	No	12	Delayed bleeding	8	2690
71	Male	ESD	Rectum	2.5	Precancerous lesion	C-EPSS	Yes	No	14	Delayed perforation	6	2729
69	Male	ESE	Colon	2	Precancerous lesion	C-EPSS	Yes	No	18	Delayed perforation	8	2577
76	Male	EFTR	Fundus	3.5	Deep SMT	P-EPSS	Yes	Yes	25	Delayed perforation	8	2306
56	Female	ESD	Fundus	2.5	Superficial SMT	C-EPSS	Yes	Yes	10	Delayed bleeding	7	2423
61	Male	EFTR	Fundus	2.5	Deep SMT	C-EPSS	No	Yes	15	Delayed perforation	6	2789
70	Female	EFTR	Body	3.5	Superficial SMT	P-EPSS	Yes	Yes	20	Delayed bleeding	7	2687

SMT: Submucosal tumor; P-EPSS: Endoscopic pre-purse-string suture; C-EPSS: Conventional endoscopic purse-string suture; ESD: Endoscopic submucosal dissection; ESE: Endoscopic submucosal excavation; EFTR: Endoscopic full-thickness resection.

[35-39]. In comparison with other closure methods, the adoption in combination with endoclips may allow the management of larger post-EFTR defects and may reinforce the wound closure[24,40]. To the best of our knowledge, the present study is the largest case series exploring the effectiveness and safety of the EPSS method. A total of 180 cases involving EPSS-assisted closure performed at our medical center were enrolled in this study for further analysis. More importantly, our study was the first to compare the feasibility and efficacy of different closure types (P-EPSS and C-EPSS) used in endoscopic manipulations.

**Table 5 Risk factors for delayed adverse events**

Factors	Total (AE)	Odds ratio	95%CI	P value
Closure of defects				
Incomplete	11 (6)	21.33	5.45-83.45	< 0.01 <sup>1</sup>
Complete	169 (9)	1		
Location (%)				
Fundus	79 (7)	1.13	0.39-3.26	0.82
Others	101 (8)	1		
Defect size				
≥ 3 cm	52 (8)	3.14	1.08-9.18	0.039 <sup>1</sup>
< 3 cm	128 (7)	1		
Morphology				
Deep SMT	76 (6)	0.90	0.31-2.66	0.86
Others (superficial SMT and precancerous lesion)	104 (9)	1		
Closure type				
P-EPSS	63 (5)	0.92	0.30-2.83	1.00
C-EPSS	117 (10)	1		
Intraoperative perforation				
Yes	55 (7)	2.13	0.73-6.21	0.24
No	125 (8)	1		
Dissection method				
EFTR	36 (5)	2.16	0.69-6.78	0.19
Others (ESD and ESE)	144 (10)	1		

<sup>1</sup>Statistically significant.

SMT: Submucosal tumor; P-EPSS: Endoscopic pre-purse-string suture; C-EPSS: Conventional endoscopic purse-string suture; AE: Adverse event; ESD: Endoscopic submucosal dissection; ESE: Endoscopic submucosal excavation; EFTR: Endoscopic full-thickness resection.

P-EPSS has been employed as a novel closure method at our institution, accounting for 63 cases between 2014 and 2020. The previous study mainly used P-EPSS in the treatment of gastric tumors originating from the muscularis propria or gastric extra-luminal growth tumors[11]. In this study, we expanded the indications of P-EPSS and used this novel closure method in more situations, such as ESD or ESE cases with big defects. This approach is especially appropriate for defects characterized by a large size and specific positions or morphologies (*e.g.*, fundus or deep SMTs). All of the above clinical characteristics point to the same tendency, *i.e.*, intraoperative perforation. Thus, it is difficult and time-consuming to achieve complete closure, highlighting the need for careful selection of cases treated with P-EPSS-assisted closure.

In the present study, the P-EPSS group showed a significantly higher incidence of intraoperative perforation and a significantly shorter procedure time in comparison with the C-EPSS group. In this regard, the approach used to measure the procedure time of the EPSS method requires elucidation in advance. The time required for the resection procedure should be excluded for fairness, because the difficulty of endoscopic resection is different. Since the endoscopist had to take more time and effort to achieve complete closure of transmural defects, most of them would prefer to avoid the possibility of perforation in manipulations. Unexpectedly, the novel P-EPSS method could solve this problem from a different perspective by turning passive perforation to active perforation, and thereby providing sufficient time for preparation of perforation closure. Subtle and sensitive handling of the endoscope is essential for accomplishing the manipulation in EPSS. Although closure of the defects of transmural GI lesions revealed clinical effectiveness, this approach was not technically easy. The maneuverability of the endoscope was poor, especially in portions with big size and specific positions or morphologies. Further modifications are required to generalize this method in the future.

Regarding adverse events, the present study did not show that P-EPSS reduced the occurrence of adverse events, although the sample size may have been insufficient to detect differences between



groups because of the retrospective design. Interestingly, the selection of P-EPSS- or C-EPSS-assisted closure showed no relationship with the adverse event rate, but defects with incomplete closure and defect size larger than 3 cm were associated with worse outcomes. Cases of adverse events were successfully managed by endoscopic treatment and conservative therapy. After the treatment, the fasting period, duration of hospitalization, and total cost were similar between the two groups. Taken together, our results suggest that the P-EPSS procedure is an effective and safe method for closing the defects of difficult targets in endoscopic operations.

Our study had several limitations, including a selection bias caused by the inclusion of more cases of large defects and intraoperative perforation in the P-EPSS group; this was primarily attributable to the single-center retrospective design and should be taken into account when interpreting the findings. However, we could not eliminate selection bias. We tried to overcome these limitations by including consecutive patients during the study period. Second, all procedures were performed by expert endoscopists at a high-volume center, limiting the generalizability of the findings. We hope to design a prospective study with a different cohort to compare the criteria for choosing between P-EPSS or C-EPSS before the endoscopic manipulation. Nevertheless, despite these limitations, our study is the largest case series on the topic of EPSS-assisted endoscopic closure and the first report to present a comparison of P-EPSS and C-EPSS.

## CONCLUSION

Our findings revealed that EPSS could achieve secure complete closure of mucosal defect. P-EPSS could shorten the procedure time and achieve secure complete closure of mucosal defects in clinical practice. Selection of P-EPSS was based on the defect's size, location, and the depth of the SMT. Defects with incomplete closure or size larger than 3 cm were associated with worse outcomes, rather than the selection of closure type.

## ARTICLE HIGHLIGHTS

### Research background

Endoscopic purse-string assisted suturing (EPSS) has proven to be an effective and safe technique for the closure of large mucosal defects. Recently, the endoscopic pre-purse-string suture (P-EPSS) procedure was invented and was widely used in clinical.

### Research motivation

The novel invented P-EPSS should be analysed and compared with the conventional EPSS (C-EPSS) procedure.

### Research objectives

Elucidate the outcomes of EPSS-assisted closure in different clinical situations, and evaluate the efficacy of P-EPSS.

### Research methods

The study included a total of 180 patients who underwent closure assisted by EPSS between July 2014 and June 2020. The P-EPSS ( $n = 63$ ) and C-EPSS ( $n = 117$ ) groups were compared and the intergroup differences in aspects such as the lesion size, location, and morphology, incidence of complete closure, intraoperative perforation, and delayed adverse events were evaluated.

### Research results

Patients with lesion size larger than 3 cm, lesions located at the fundus of stomach, or submucosal tumors originating from the deep mucosa were more likely to undergo P-EPSS-assisted closure. The P-EPSS group showed a significantly higher proportion of intraoperative perforation and a much shorter procedure time. But the incidence of adverse events did not differ significantly between P-EPSS and C-EPSS groups. Lesions with incomplete closure or size greater than 3 cm showed a statistical tendency to result in an increase in delayed adverse events.

### Research conclusions

EPSS could achieve secure complete closure of mucosal defect. P-EPSS could shorten the procedure and yield complete closure of mucosal defects.

### Research perspectives

To eliminate the selection bias, we would dedicate to design a new cohort prospective study to compare

the criteria of deciding in advance whether to use P-EPSS or C-EPSS before endoscopic manipulations.

## FOOTNOTES

**Author contributions:** Li MM and Zhang Y contributed equally to this work; Li MM and Zhang Y drafted the manuscript and analyzed the data; Xu LM and Zhang Y designed the study and supervised its implementation; Xu LM, Zhang Y, Qu CY, and Shen F completed the endoscopic manipulations; Sun F, Huai MX, Zhang FY and Li ZH, participated in the experiments; and all authors made critical revisions and approved the final version to be published.

**Supported by** the National Natural Science Foundation of China, No. 82172737 and 82003277; and Shanghai Municipal Education Commission, No. 16411950403 and 19411951605.

**Institutional review board statement:** The study was reviewed and approved by the Ethics Committee at Xinhua Hospital (approval number: XHEC-C-2018-109), Shanghai Jiaotong University School of Medicine.

**Informed consent statement:** Informed consent was obtained from all individual participants included in the study.

**Conflict-of-interest statement:** All the authors report no relevant conflicts of interest for this article.

**Data sharing statement:** Technical appendix, statistical code, and dataset available from the corresponding author at [xuleiming@xinhua.com.cn](mailto:xuleiming@xinhua.com.cn). Participants gave informed consent for data sharing.

**Open-Access:** This article is an open-access article that was selected by an in-house editor and fully peer-reviewed by external reviewers. It is distributed in accordance with the Creative Commons Attribution NonCommercial (CC BY-NC 4.0) license, which permits others to distribute, remix, adapt, build upon this work non-commercially, and license their derivative works on different terms, provided the original work is properly cited and the use is non-commercial. See: <https://creativecommons.org/licenses/by-nc/4.0/>

**Country/Territory of origin:** China

**ORCID number:** Ming-Ming Li 0000-0003-1753-6533; Yi Zhang 0000-0003-4208-6546; Fang Sun 0000-0003-4621-1332; Fei-Yu Zhang 0000-0002-5771-4579; Chun-Ying Qu 0000-0001-9076-081X; Feng Shen 0000-0002-8572-2074; Lei-Ming Xu 0000-0002-6735-4853.

**S-Editor:** Wang JJ

**L-Editor:** A

**P-Editor:** Wang JJ

## REFERENCES

- Li Y, Wu JH, Meng Y, Zhang Q, Gong W, Liu SD. New devices and techniques for endoscopic closure of gastrointestinal perforations. *World J Gastroenterol* 2016; **22**: 7453-7462 [PMID: 27672268 DOI: 10.3748/wjg.v22.i33.7453]
- Verlaan T, Voermans RP, van Berge Henegouwen MI, Bemelman WA, Fockens P. Endoscopic closure of acute perforations of the GI tract: a systematic review of the literature. *Gastrointest Endosc* 2015; **82**: 618-28.e5 [PMID: 26005015 DOI: 10.1016/j.gie.2015.03.1977]
- Qiao Z, Ling X, Zhu J, Ying G, Xu L, Zhu H, Tang J. Therapeutic application of purse-string sutures with nylon loops and metal clips under single-channel endoscopy for repair of gastrointestinal wall defects. *Exp Ther Med* 2018; **15**: 4356-4360 [PMID: 29849777 DOI: 10.3892/etm.2018.5956]
- Draganov PV, Wang AY, Othman MO, Fukami N. AGA Institute Clinical Practice Update: Endoscopic Submucosal Dissection in the United States. *Clin Gastroenterol Hepatol* 2019; **17**: 16-25.e1 [PMID: 30077787 DOI: 10.1016/j.cgh.2018.07.041]
- Matsuda T, Fujii T, Emura F, Kozu T, Saito Y, Ikematsu H, Saito D. Complete closure of a large defect after EMR of a lateral spreading colorectal tumor when using a two-channel colonoscope. *Gastrointest Endosc* 2004; **60**: 836-838 [PMID: 15557972 DOI: 10.1016/S0016-5107(04)02033-4]
- Shadhu K, Ramlagun D, Wang Y, Ping X, Chen T, Zhu Y, Xu Z. Re-evaluation of purse string suture in laparoscopic appendectomy. *Surg Endosc* 2020; **34**: 779-786 [PMID: 31087172 DOI: 10.1007/s00464-019-06828-5]
- Joo J, Custis T, Armstrong AW, King TH, Omlin K, Kappel ST, Eisen DB. Purse-string suture vs second intention healing: results of a randomized, blind clinical trial. *JAMA Dermatol* 2015; **151**: 265-270 [PMID: 25372450 DOI: 10.1001/jamadermatol.2014.2313]
- Shi D, Li R, Chen W, Zhang D, Zhang L, Guo R, Yao P, Wu X. Application of novel endoloops to close the defects resulted from endoscopic full-thickness resection with single-channel gastroscope: a multicenter study. *Surg Endosc* 2017; **31**: 837-842 [PMID: 27351654 DOI: 10.1007/s00464-016-5041-4]
- Zhou PH, Yao LQ, Qin XY, Cai MY, Xu MD, Zhong YS, Chen WF, Zhang YQ, Qin WZ, Hu JW, Liu JZ. Endoscopic full-thickness resection without laparoscopic assistance for gastric submucosal tumors originated from the muscularis

- propria. *Surg Endosc* 2011; **25**: 2926-2931 [PMID: [21424195](#) DOI: [10.1007/s00464-011-1644-y](#)]
- 10 **Zhang Y**, Wang X, Xiong G, Qian Y, Wang H, Liu L, Miao L, Fan Z. Complete defect closure of gastric submucosal tumors with purse-string sutures. *Surg Endosc* 2014; **28**: 1844-1851 [PMID: [24442680](#) DOI: [10.1007/s00464-013-3404-7](#)]
- 11 **Wu N**, Liu S, Chen M, Zeng X, Wang F, Zhang J, She Q. The prepurse-string suture technique for gastric defect after endoscopic full-thickness resection (with video). *Medicine (Baltimore)* 2018; **97**: e12118 [PMID: [30200096](#) DOI: [10.1097/MD.00000000000012118](#)]
- 12 **Wang J**, Zhao L, Wang X, Liu L, Wang M, Fan Z. A novel endoloop system for closure of colonic mucosal defects through a single-channel colonoscope. *Endoscopy* 2017; **49**: 803-807 [PMID: [28561196](#) DOI: [10.1055/s-0043-108547](#)]
- 13 **Ryu JY**, Park BK, Kim WS, Kim K, Lee JY, Kim Y, Park JY, Kim BJ, Kim JW, Choi CH. Endoscopic closure of iatrogenic colon perforation using dual-channel endoscope with an endoloop and clips: methods and feasibility data (with videos). *Surg Endosc* 2019; **33**: 1342-1348 [PMID: [30604267](#) DOI: [10.1007/s00464-018-06616-7](#)]
- 14 **Zhu S**, Lin J, Xu F, Guo S, Huang S, Wang M. Purse-string sutures using novel endoloops and repositionable clips for the closure of large iatrogenic duodenal perforations with single-channel endoscope: a multicenter study. *Surg Endosc* 2019; **33**: 1319-1325 [PMID: [30460503](#) DOI: [10.1007/s00464-018-6586-1](#)]
- 15 **Zhu H**, Tang JH, Ling X, Qian JP, Shen DM. [Application of purse string suture with Harmonious Clips and Olympus endoloop in single channel endoscopy for large gastric antrum mucosa defect]. *Zhonghua Yi Xue Za Zhi* 2018; **98**: 3074-3078 [PMID: [30392266](#) DOI: [10.3760/cma.j.issn.0376-2491.2018.38.006](#)]
- 16 **Pimentel-Nunes P**, Dinis-Ribeiro M, Ponchon T, Repici A, Vieth M, De Ceglie A, Amato A, Berr F, Bhandari P, Bialek A, Conio M, Haringsma J, Langner C, Meisner S, Messmann H, Morino M, Neuhaus H, Piessevaux H, Rugge M, Saunders BP, Robaszkiewicz M, Seewald S, Kashin S, Dumonceau JM, Hassan C, Deprez PH. Endoscopic submucosal dissection: European Society of Gastrointestinal Endoscopy (ESGE) Guideline. *Endoscopy* 2015; **47**: 829-854 [PMID: [26317585](#) DOI: [10.1055/s-0034-1392882](#)]
- 17 **Waddingham W**, Nieuwenburg SAV, Carlson S, Rodriguez-Justo M, Spaander M, Kuipers EJ, Jansen M, Graham DG, Banks M. Recent advances in the detection and management of early gastric cancer and its precursors. *Frontline Gastroenterol* 2021; **12**: 322-331 [PMID: [34249318](#) DOI: [10.1136/flgastro-2018-101089](#)]
- 18 **Li B**, Chen D, Wan X. Endoscopic purse-string suture technique: An effective remedy for a large iatrogenic rectal perforation. *Dig Endosc* 2019; **31**: e9-e10 [PMID: [30192417](#) DOI: [10.1111/den.13274](#)]
- 19 **Cai MY**, Martin Carreras-Presas F, Zhou PH. Endoscopic full-thickness resection for gastrointestinal submucosal tumors. *Dig Endosc* 2018; **30** Suppl 1: 17-24 [PMID: [29658639](#) DOI: [10.1111/den.13003](#)]
- 20 **Mori H**, Kobara H, Nishiyama N, Masaki T. Current status and future perspectives of endoscopic full-thickness resection. *Dig Endosc* 2018; **30** Suppl 1: 25-31 [PMID: [29658644](#) DOI: [10.1111/den.13042](#)]
- 21 **ASGE Technology Committee**, Aslanian HR, Sethi A, Bhutani MS, Goodman AJ, Krishnan K, Lichtenstein DR, Melson J, Navaneethan U, Pannala R, Parsi MA, Schulman AR, Sullivan SA, Thosani N, Trikudanathan G, Trindade AJ, Watson RR, Maple JT. ASGE guideline for endoscopic full-thickness resection and submucosal tunnel endoscopic resection. *VideoGIE* 2019; **4**: 343-350 [PMID: [31388606](#) DOI: [10.1016/j.vgie.2019.03.010](#)]
- 22 **Ye L**, Zeng X, Yuan X, Guo L, Zhang Y, Li Y, Hu B. Purse-string suture and double percutaneous endoscopic gastrostomies for treating a postoperative duodenal fistula. *Endoscopy* 2019; **51**: E55-E56 [PMID: [30634194](#) DOI: [10.1055/a-0800-8286](#)]
- 23 **Lu ZY**, Zhao DY. Gastric schwannoma treated by endoscopic full-thickness resection and endoscopic purse-string suture: A case report. *World J Gastroenterol* 2021; **27**: 3940-3947 [PMID: [34321856](#) DOI: [10.3748/wjg.v27.i25.3940](#)]
- 24 **Mangiavillano B**, Viaggi P, Masci E. Endoscopic closure of acute iatrogenic perforations during diagnostic and therapeutic endoscopy in the gastrointestinal tract using metallic clips: a literature review. *J Dig Dis* 2010; **11**: 12-18 [PMID: [20132426](#) DOI: [10.1111/j.1751-2980.2009.00414.x](#)]
- 25 **Dong HY**, Wang YL, Jia XY, Li J, Li GD, Li YQ. Modified laparoscopic intragastric surgery and endoscopic full-thickness resection for gastric stromal tumor originating from the muscularis propria. *Surg Endosc* 2014; **28**: 1447-1453 [PMID: [24671350](#) DOI: [10.1007/s00464-013-3375-8](#)]
- 26 **Ma LS**. What is the purpose of launching World Journal of Gastrointestinal Surgery? *World J Gastrointest Surg* 2009; **1**: 1-2 [PMID: [21160785](#) DOI: [10.4240/wjgs.v1.i1.1](#)]
- 27 **Tang SJ**, Naga YM, Wu R, Zhang S. Over-the-scope clip-assisted endoscopic full thickness resection: a video-based case series. *Surg Endosc* 2020; **34**: 2780-2788 [PMID: [32189117](#) DOI: [10.1007/s00464-020-07481-z](#)]
- 28 **Guo JT**, Zhang JJ, Wu YF, Liao Y, Wang YD, Zhang BZ, Wang S, Sun SY. Endoscopic full-thickness resection using an over-the-scope device: A prospective study. *World J Gastroenterol* 2021; **27**: 725-736 [PMID: [33716450](#) DOI: [10.3748/wjg.v27.i8.725](#)]
- 29 **Al-Bawardy B**, Rajan E, Wong Kee Song LM. Over-the-scope clip-assisted endoscopic full-thickness resection of epithelial and subepithelial GI lesions. *Gastrointest Endosc* 2017; **85**: 1087-1092 [PMID: [27569858](#) DOI: [10.1016/j.gie.2016.08.019](#)]
- 30 **Tashima T**, Nonaka K, Ryozaawa S, Tanisaka Y. Endoscopic purse-string suturing with an over-the-scope clip for closure of a large mucosal defect after gastric ESD. *Dig Liver Dis* 2018; **50**: 1247 [PMID: [29884557](#) DOI: [10.1016/j.dld.2018.05.010](#)]
- 31 **Weiland T**, Fehlker M, Gottwald T, Schurr MO. Performance of the OTSC System in the endoscopic closure of iatrogenic gastrointestinal perforations: a systematic review. *Surg Endosc* 2013; **27**: 2258-2274 [PMID: [23340813](#) DOI: [10.1007/s00464-012-2754-x](#)]
- 32 **Manta R**, Manno M, Bertani H, Barbera C, Pigò F, Mirante V, Longinotti E, Bassotti G, Conigliaro R. Endoscopic treatment of gastrointestinal fistulas using an over-the-scope clip (OTSC) device: case series from a tertiary referral center. *Endoscopy* 2011; **43**: 545-548 [PMID: [21409741](#) DOI: [10.1055/s-0030-1256196](#)]
- 33 **Coman RM**, Yang D, Draganov PV. Endoscopic full-thickness resection with use of the over-the-scope clip: a word of caution! *Gastrointest Endosc* 2017; **86**: 749-750 [PMID: [28917354](#) DOI: [10.1016/j.gie.2017.05.026](#)]
- 34 **Kato M**, Ochiai Y, Fukuhara S, Maehata T, Sasaki M, Kiguchi Y, Akimoto T, Fujimoto A, Nakayama A, Kanai T, Yahagi N. Clinical impact of closure of the mucosal defect after duodenal endoscopic submucosal dissection. *Gastrointest Endosc*

- 2019; **89**: 87-93 [PMID: [30055156](#) DOI: [10.1016/j.gie.2018.07.026](#)]
- 35 **Ye LP**, Yu Z, Mao XL, Zhu LH, Zhou XB. Endoscopic full-thickness resection with defect closure using clips and an endoloop for gastric subepithelial tumors arising from the muscularis propria. *Surg Endosc* 2014; **28**: 1978-1983 [PMID: [24619327](#) DOI: [10.1007/s00464-014-3421-1](#)]
  - 36 **Hu JW**, Ge L, Zhou PH, Li QL, Zhang YQ, Chen WF, Chen T, Yao LQ, Xu MD, Chu Y. A novel grasp-and-loop closure method for defect closure after endoscopic full-thickness resection (with video). *Surg Endosc* 2017; **31**: 4275-4282 [PMID: [28374258](#) DOI: [10.1007/s00464-017-5473-5](#)]
  - 37 **Li J**, Meng Y, Ye S, Wang P, Liu F. Usefulness of the thread-traction method in endoscopic full-thickness resection for gastric submucosal tumor: a comparative study. *Surg Endosc* 2019; **33**: 2880-2885 [PMID: [30456512](#) DOI: [10.1007/s00464-018-6585-2](#)]
  - 38 **Shi Q**, Chen T, Zhong YS, Zhou PH, Ren Z, Xu MD, Yao LQ. Complete closure of large gastric defects after endoscopic full-thickness resection, using endoloop and metallic clip interrupted suture. *Endoscopy* 2013; **45**: 329-334 [PMID: [23468195](#) DOI: [10.1055/s-0032-1326214](#)]
  - 39 **Tang AL**, Liao XQ, Shen SR, Xiao DH, Yuan YX, Wang XY. Application of clips assisted with foreign body forceps in defect closure after endoscopic full-thickness resection. *Surg Endosc* 2016; **30**: 2127-2131 [PMID: [26205558](#) DOI: [10.1007/s00464-015-4414-4](#)]
  - 40 **Akimoto T**, Goto O, Nishizawa T, Yahagi N. Endoscopic closure after intraluminal surgery. *Dig Endosc* 2017; **29**: 547-558 [PMID: [28181699](#) DOI: [10.1111/den.12839](#)]



Published by **Baishideng Publishing Group Inc**  
7041 Koll Center Parkway, Suite 160, Pleasanton, CA 94566, USA

**Telephone:** +1-925-3991568

**E-mail:** [bpgoffice@wjgnet.com](mailto:bpgoffice@wjgnet.com)

**Help Desk:** <https://www.f6publishing.com/helpdesk>

<https://www.wjgnet.com>

