

World Journal of *Gastroenterology*

World J Gastroenterol 2023 October 28; 29(40): 5526-5617



REVIEW

- 5526 Overview on the endoscopic treatment for obesity: A review

Abdulla M, Mohammed N, AlQamish J

ORIGINAL ARTICLE

Basic Study

- 5543 Roles of phosphatidylinositol-3-kinases signaling pathway in inflammation-related cancer: Impact of rs10889677 variant and buparlisib in colitis-associated cancer

Razali NN, Raja Ali RA, Muhammad Nawawi KN, Yahaya A, Mohd Rathi ND, Mokhtar NM

Retrospective Study

- 5557 Endoscopic transgastric fenestration versus percutaneous drainage for management of (peri)pancreatic fluid collections adjacent to gastric wall (with video)

Zhang HM, Ke HT, Ahmed MR, Li YJ, Nabi G, Li MH, Zhang JY, Liu D, Zhao LX, Liu BR

- 5566 Clinical significance of programmed cell death-ligand expression in small bowel adenocarcinoma is determined by the tumor microenvironment

Hoshimoto A, Tatsuguchi A, Hamakubo R, Nishimoto T, Omori J, Akimoto N, Tanaka S, Fujimori S, Hatori T, Shimizu A, Iwakiri K

Observational Study

- 5582 Expression characteristics of peripheral lymphocyte programmed death 1 and FoxP3⁺ Tregs in gastric cancer during surgery and chemotherapy

Li H, Cao GM, Gu GL, Li SY, Yan Y, Fu Z, Du XH

SCIENTOMETRICS

- 5593 Advances and key focus areas in gastric cancer immunotherapy: A comprehensive scientometric and clinical trial review (1999-2023)

Li YN, Xie B, Zhang Y, He MH, Xing Y, Mu DM, Wang H, Guo R

ABOUT COVER

Associate Editor of *World Journal of Gastroenterology*, Marc D Basson, MD, PhD, MBA, Professor, Departments of Surgery and Anatomy and Neurobiology, and Dean, College of Medicine, Northeast Ohio Medical University, Rootstown, OH 44272, United States. mbasson@neomed.edu

AIMS AND SCOPE

The primary aim of *World Journal of Gastroenterology* (WJG, *World J Gastroenterol*) is to provide scholars and readers from various fields of gastroenterology and hepatology with a platform to publish high-quality basic and clinical research articles and communicate their research findings online. WJG mainly publishes articles reporting research results and findings obtained in the field of gastroenterology and hepatology and covering a wide range of topics including gastroenterology, hepatology, gastrointestinal endoscopy, gastrointestinal surgery, gastrointestinal oncology, and pediatric gastroenterology.

INDEXING/ABSTRACTING

The WJG is now abstracted and indexed in Science Citation Index Expanded (SCIE), MEDLINE, PubMed, PubMed Central, Scopus, Reference Citation Analysis, China Science and Technology Journal Database, and Superstar Journals Database. The 2023 edition of Journal Citation Reports® cites the 2022 impact factor (IF) for WJG as 4.3; Quartile category: Q2. The WJG's CiteScore for 2021 is 8.3.

RESPONSIBLE EDITORS FOR THIS ISSUE

Production Editor: *Yu-Xi Chen*; Production Department Director: *Xu Guo*; Editorial Office Director: *Jia-Ru Fan*.

NAME OF JOURNAL

World Journal of Gastroenterology

ISSN

ISSN 1007-9327 (print) ISSN 2219-2840 (online)

LAUNCH DATE

October 1, 1995

FREQUENCY

Weekly

EDITORS-IN-CHIEF

Andrzej S Tarnawski

EXECUTIVE ASSOCIATE EDITORS-IN-CHIEF

Xian-Jun Yu (Pancreatic Oncology), Jian-Gao Fan (Chronic Liver Disease), Hou-Bao Liu (Biliary Tract Disease), Naohisa Yoshida (Gastrointestinal Endoscopy)

EDITORIAL BOARD MEMBERS

<http://www.wjgnet.com/1007-9327/editorialboard.htm>

PUBLICATION DATE

October 28, 2023

COPYRIGHT

© 2023 Baishideng Publishing Group Inc

PUBLISHING PARTNER

Shanghai Pancreatic Cancer Institute and Pancreatic Cancer Institute, Fudan University
Biliary Tract Disease Institute, Fudan University

INSTRUCTIONS TO AUTHORS

<https://www.wjgnet.com/bpg/gerinfo/204>

GUIDELINES FOR ETHICS DOCUMENTS

<https://www.wjgnet.com/bpg/GerInfo/287>

GUIDELINES FOR NON-NATIVE SPEAKERS OF ENGLISH

<https://www.wjgnet.com/bpg/gerinfo/240>

PUBLICATION ETHICS

<https://www.wjgnet.com/bpg/GerInfo/288>

PUBLICATION MISCONDUCT

<https://www.wjgnet.com/bpg/gerinfo/208>

POLICY OF CO-AUTHORS

<https://www.wjgnet.com/bpg/GerInfo/310>

ARTICLE PROCESSING CHARGE

<https://www.wjgnet.com/bpg/gerinfo/242>

STEPS FOR SUBMITTING MANUSCRIPTS

<https://www.wjgnet.com/bpg/GerInfo/239>

ONLINE SUBMISSION

<https://www.f6publishing.com>

PUBLISHING PARTNER's OFFICIAL WEBSITE

<https://www.shca.org.cn>
<https://www.zs-hospital.sh.cn>



Overview on the endoscopic treatment for obesity: A review

Maheeba Abdulla, Nafeesa Mohammed, Jihad AlQamish

Specialty type: Gastroenterology and hepatology

Provenance and peer review: Unsolicited article; Externally peer reviewed.

Peer-review model: Single blind

Peer-review report's scientific quality classification

Grade A (Excellent): 0
Grade B (Very good): B, B
Grade C (Good): 0
Grade D (Fair): D
Grade E (Poor): 0

P-Reviewer: Rabago LR, Spain; Seretis C, Greece; Osera S, Japan

Received: August 3, 2023

Peer-review started: August 3, 2023

First decision: September 5, 2023

Revised: September 15, 2023

Accepted: October 23, 2023

Article in press: October 23, 2023

Published online: October 28, 2023



Maheeba Abdulla, Jihad AlQamish, Department of Internal Medicine, Ibn Al Nafees Hospital, Manama 54533, Bahrain

Nafeesa Mohammed, Department of Intensive Care Unit, Salmaniya Medical Complex, Manama 5616, Bahrain

Corresponding author: Maheeba Abdulla, MD, MRCP, Consultant Physician, Gastroenterologist & Hepatologist, Department of Internal Medicine, Ibn Al Nafees Hospital, No. 3302 Road, Manama 54533, Bahrain. amaheeba@hotmail.com

Abstract

Obesity rates have increased, and so has the need for more specific treatments. This trend has raised interest in non-surgical weight loss techniques that are novel, safe, and straightforward. Thus, the present review describes the endoscopic bariatric treatment for obesity, its most recent supporting data, the questions it raises, and its future directions. Various endoscopic bariatric therapies for weight reduction, such as intragastric balloons (IGBs), aspiration therapy (AT), small bowel endoscopy, endoscopic sleeve gastropasty, endoluminal procedures, malabsorption endoscopic procedures, and methods of regulating gastric emptying, were explored through literature sourced from different databases. IGBs, AT, and small bowel endoscopy have short-term effects with a possibility of weight regain. Minor adverse events have occurred; however, all procedures reduce weight. Vomiting and nausea are common side effects, although serious complications have also been observed.

Key Words: Overweight; Gastric bypass; Malabsorption; Intragastric balloons

©The Author(s) 2023. Published by Baishideng Publishing Group Inc. All rights reserved.

Core Tip: To enhance endoscopic intervention effectiveness and patient satisfaction, the research recommends device design, procedures, patient selection, and personalized therapy. Endoscopists, bariatric surgeons, and researchers must collaborate to solve problems, improve patient comfort, and reduce treatment risks. Effective weight maintenance through endoscopic methods and patient education requires comprehensive and long-term follow-up. Robotic-assisted endoscopy and tissue-engineered implants may revolutionize obesity treatment and patient outcomes in five to ten years.

Citation: Abdulla M, Mohammed N, AlQamish J. Overview on the endoscopic treatment for obesity: A review. *World J Gastroenterol* 2023; 29(40): 5526-5542

URL: <https://www.wjgnet.com/1007-9327/full/v29/i40/5526.htm>

DOI: <https://dx.doi.org/10.3748/wjg.v29.i40.5526>

INTRODUCTION

Obesity prevalence has increased dramatically over the last thirty years, now approaching 35% in men and 40% in women[1]. Obesity affects 39 million children, 340 million teenagers, and 650 million adults worldwide. This figure is still rising; by 2025, 167 million children and adults will have suffered as a result of being obese or overweight[2]. As a multi-faceted illness with pandemic proportions, obesity is prevalent nowadays. Since 1975, obesity prevalence has virtually tripled during the last three decades globally, primarily due to an increase in sedentary behavior and intake of less nutrient-dense foods[3]. There are severe public health issues with obesity[4]. Such as diabetes, hyperlipidemia, mortality all-causes, and all-cause cardiovascular mortality[5]. In 2015, the World Obesity Federation established World Obesity Day as a day of commitment and action to promote an integrated, cross-sector approach to combating obesity[6]. A new index for Obesity-Non-Communicable Disease Preparedness is presented in the World Obesity Federation report; worries about the consequences of inactivity for already vulnerable people have grown. The top 30 most prepared countries are all high-income countries, whereas the least prepared 30 are all lower-middle and low-income countries[7]. Obesity-related yearly healthcare costs are predicted to total 1.2 trillion USD globally by 2025[6].

A bio-socio-ecological framework, in which biological predisposition, environmental factors, and socioeconomic factors interact to promote the deposition and proliferation of adipose tissue, can explain the process of persistence and development of obesity[8]. In wealthy nations, poverty and obesity appear to be related. However, a more thorough examination of the empirical literature leads one to believe that the relationship between income and obesity is more nuanced because it can be either positive or negative, or it can alter as nations grow older[9]. Among the numerous therapies for obesity, pharmaceutical substances, surgical procedures, and lifestyle changes can be used[10] as shown in Figure 1.

Despite being the least invasive and expensive approach, lifestyle changes have been demonstrated to be the least effective[11]. Adults with obesity can lose > 5% of their body weight with many sessions of intensive behavioral interventions, such as identification of different barriers, peer support, and self-monitoring of weight, combined with dietary plans, lifestyle modifications, and increased exercise[12]. The central nervous system, adipose tissue, gastrointestinal hormones, liver, kidney, and skeletal muscle are only a few of the systems and tissues that are now modulated by some anti-obesity drugs under investigation[13]. Bariatric surgery is currently the only treatment that causes significant and long-lasting decrease in body weight[14]. However, even if there are clinically significant comorbidities (metabolic, psychological, *etc.*), patients with a body mass index (BMI) of 35 kg/m² or over are not suitable for bariatric surgery. Only a small number of eligible patients can potentially benefit from bariatric surgery[15]. This may be due to various reasons, such as a less favorable risk-benefit profile, as higher BMI levels often correlate with increased surgical complications, postoperative mortality, and reduced success rates[16]. Additionally, the potential benefits of surgery, such as weight loss and improvement in comorbidities, might be outweighed by the surgical risks and associated challenges in this specific BMI range. Moreover, alternative interventions, including lifestyle modifications, pharmacotherapy, and non-surgical interventions, might be considered more appropriate due to the complexities posed by the patient's heightened obesity levels. However, carefully assessing individual risks and benefits remains essential in determining the most suitable treatment approach[17]. Lastly, advanced studies have questioned the longevity of bariatric surgery due to the regular occurrence of weight regain and adverse effects[17].

Endoscopic procedures can be used in a multidisciplinary approach to managing obesity. Endoscopists should become familiar with the gastrointestinal pathology that might develop after bariatric surgery, such as malnutrition, anastomotic stenosis, acid reflux, gallstone disease, leaks, fistulas, and weight gain[17]. The creation of new obesity treatment modalities without a high operational risk is the current area of research; thus, obesity endoscopic management is garnering major attention. Endoscopy has an indisputable role in the assessment and management of bariatric surgery complications as well as the evaluation of patients in the preoperative stage of the procedure[18]. Additionally, in order to lower the risks associated with surgery connected to obesity, endoscopic techniques have been employed as a "bridge to surgery"[19]. Thus, the present review describes the present endoscopic treatment for obesity, the most recent data supporting it, the questions, and the future directions the field will face in the next ten years.

BARIATRIC ENDOSCOPY

Endoscopic weight loss therapies have been developed as a result of increased interest and innovation in the fields of gastroenterology and endoscopy, as well as the proven results of bariatric surgery for weight loss[20]. Although surgery is a successful approach for weight loss, it is constrained by its high resource requirements and low patient acceptance [21]. However, endoscopic bariatric therapy (EBT) may be more effective than anti-obesity medicines[22]. Endoscopic weight loss procedures are becoming more popular in Western countries where obesity has escalated rapidly[23]. Indeed, EBT has demonstrated outstanding results in the treatment of obesity and associated surgical consequences[24], therefore, must be included in the arsenal in the battle against obesity[25]. In fact, EBT has evolved into a significant tool for exami-

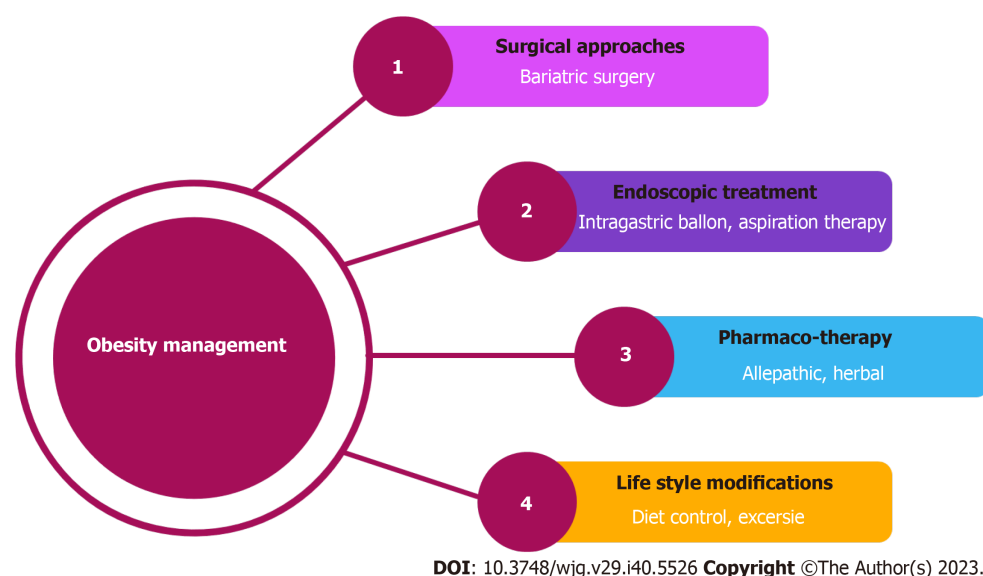


Figure 1 Different approaches for the management of obesity.

nation, diagnosis, surgical complication management[26] and even primary bariatric therapies[27]. It can also be a more effective alternative than dietary and lifestyle changes[28]. Additionally, EBTs are being used increasingly as a treatment therapy option for obesity in different settings due to their minimally intrusive nature and ease of administration. These treatments induce weight loss primarily by reducing meal volume and promoting early satiety[29]. Currently, a wide range of endoscopic procedures, based on the principles of stomach volume reduction, small bowel or gastric bypass, and size restriction, are being investigated, with a few being used in daily practice[30]. Innovative endoscopic therapies, such as double-pigtail stents, septostomy, and endoscopic vacuum therapy, have been developed[31]. Newer endoscopic approaches, such as intragastric balloons (IGBs), aspiration therapy (AT), small bowel devices, and endoscopic plication and suturing techniques, have been developed[32] and show significant effects.

Space occupying techniques

Space-occupying devices limit stomach capacity, thus reducing hunger and food intake as a result. There are various versions of silicon-made balloons that can be filled with liquid or air. Because of its reduced likelihood for issues, the most popular type is the non-adjustable liquid-filled balloon. The mechanism of action is multifaceted, with neurohormonal and physiological alterations involved[33]. Generally, there are two types of space-occupying techniques: Intragastric fluid filled balloons, and intragastric air or gas filled balloons.

IGBs (fluid filled)

Over 20000 papers have been published in the previous 20 years covering a wide range of topics connected to the effects of the IGBs, including weight reduction outcomes, complications, hormonal impacts, quality of life (QoL), and other aspects[34]. IGBs are invasive therapies that are used to enhance satiety by neuroendocrine and mechanical mechanisms [35] as well as limiting stomach capacity as a space-occupying device, resulting in decreased food intake and hunger[33]. The Bubble (Garren-Edwards) was the first-developed IGB in 1985. The Food and Drug Administration (FDA) of the United States approved it as a temporary weight loss device[36]. IGB therapy is helpful in decreasing weight and improving depression, anxiety, symptoms of eating disorders, and overall QoL in obese individuals primarily within 6 mo of device placement and when used in tandem with conventional therapies[37] and found to be more effective in pre-obese individuals[38]. Although significant morbidity is possible, it is a useful way to lose weight when implemented in conjunction with dietary modifications and physical exercise[39]. However, due to the consequent regain of weight, different methods are now favored in adults. Balloons may be an option for less reversible operations in teens, who are more open to lifestyle modification[40]. The drawbacks of IGBs, such as risks during insertion and removal, and unknown long-term weight loss benefits, prevent their widespread use[41]. Considering conscious sedation *vs* general anesthesia during balloon withdrawal, with or without anesthetic intubation, is pivotal due to its potential implications for procedural complications[42]. The choice between these approaches hinges on patient health status, procedure complexity, and anticipated discomfort. Utilizing conscious sedation may offer benefits like reduced risks associated with intubation but could lead to patient discomfort or inadequate sedation levels, potentially increasing complications[43]. In contrast, employing general anesthesia with intubation might mitigate patient discomfort but could introduce intubation-related risks. Balancing these considerations is essential to optimize patient comfort and procedural safety during balloon withdrawal, and a comprehensive understanding of the relationship between sedation choices and associated complications is critical for informed decision-making. Meanwhile, utilizing a dual-channel gastroscope, specialized foreign body forceps, and a symmetrical snare designed for polyp removal enables a secure, efficient, and straightforward extraction of the balloon. This approach ensures the balloon is removed without any misplacement risk while maintaining patient comfort throughout the procedure[44].

Endoscopically-placed balloons are normally placed in the stomach for no longer than 6 mo, after which they are removed, as they can cause complications[45]. A meta-analysis of 5668 participants found there was moderate indication of improvement in most metabolic markers in participants (IGB therapy *vs* standard non-surgical therapy)[46]. In another review, the total body weight loss (TBWL) of the IGBs after 6-mo implantation was 6.8%-13.2% at 12 mo *i.e.*, 7.6%-11.3% TBWL[47]. Furthermore, 20 randomized controlled trials (RCTs) were used in a meta-analysis involving 1195 patients, indicating significant effects following IGB use[48]. Another similar meta-analysis was comprised of thirteen RCTs with a total of 1523 subjects. At follow-up, the difference in mean % excess weight loss (EWL) was 17.98% [total weight loss (TWL) was 4.40%] and was substantially larger in the IGB group. This concluded that, in overweight and obese individuals, IGB therapy is more effective than lifestyle change alone for weight loss[49]. Additionally, in the RCT, 288 patients were assigned at random to one of two groups: IGB or control group. At 32 wk, the mean TWL in the IGB group was 15% [95% confidence interval (CI): 13.9-16.1] against 3.3% (2-4.6) in the second group which remained as a control without any intervention ($P < 0.0001$). Seven (4%) patients experienced major adverse events (AEs) associated with the device, with no deaths. When therapy was combined with lifestyle changes, substantial weight loss was obtained and sustained for 6 mo after IGB removal[50]. A 10-year review was performed and initially, 49 patients (IGB *vs* control group) were included with a 51.6% follow-up rate. TBWL favored the IGB group at 6 mo [9.75 *vs* 7.48 kg ($P = 0.03$)], at 12 mo [6.52 *vs* 4.42 kg ($P = 0.05$)], at 18 mo [5.42 *vs* 3.57 ($P = 0.32$)], and 24 mo [4.07 *vs* 2.93 kg ($P = 0.56$)]. TWL at 10 years was 0.03 *vs* -2.32 kg ($P = 0.05$) and %TWL was $-0.16\% \pm 12.8\%$ *vs* $-2.84\% \pm 5.6\%$ ($P = 0.39$), which were not statistically different between groups. BMI at follow-up [30.97 ± 1.6 *vs* 30.38 ± 1.8 kg/m² ($P = 1.00$)] was comparable and it was concluded that IGB provides weight loss for up to two years and is superior to the control[51]. In contrast, in one of the studies only 2910 (0.4%) of the 652927 individuals identified received IGB treatment. Patients who received IGB therapy were older, had a lower BMI at baseline (37.0 ± 6.2 kg/m² *vs* 45.3 ± 7.8 kg/m²), and had a greater rate of early non-operative re-intervention (7.7% *vs* 1.1%; $P < 0.0001$). Between 2016 and 2019, according to the Metabolic and Bariatric Surgery Accreditation and Quality Improvement Program the number of IGB procedures reported decreased considerably [953 (0.62%) *vs* 418 (0.25%); $P < 0.0001$]. Given the safety and efficacy of current bariatric surgery and novel pharmaceutical treatments for weight loss, the function of IGBs in treating obesity remains uncertain[52]. In another study, the mean preoperative BMI for all 20680 IGBs, encompassing 12 distinct models, was 34.05 kg/m². On average 17.66% $\pm 2.5\%$ of TBWL was noted. There were 3.62% early removals because of intolerance. Consensual management had an AE rate of 0.70% and 6.37% for major and mild problems, respectively. Only one death was reported[53]. In short, many patients have benefited from the IGBs, which bridges the gap between clinical management of obesity, medications, and bariatric surgery while also helping thousands of patients lose weight and improve their comorbidities[34]. A summary is also described in Table 1.

The United States FDA has approved three IGBs. Orbera is an endoscopically implanted single balloon[54]. ReShape is a duo balloon system, connected in the middle by a tube. The third balloon, Obalon (Figure 2), is filled with nitrogen gas and is part of a three-balloon treatment. All systems require endoscopic placement and removal after 6 mo[55].

A single balloon (Orbera IGB)

The Orbera IGB (OIB) is a single fluid filled IGB authorized for weight loss induction and obesity treatment[56]. The FDA-approved Orbera is a single 13 cm silicone-made balloon that arrives commercially deflated and is inflated at the end by a filling tube connected to a radiopaque self-sealing valve. Following a diagnostic endoscopy, the balloon implantation assembly is inserted directly into the stomach, and a volume of 500 to 700 mL saline solution [this volume range (500 to 700 mL) is chosen based on optimal balloon expansion and effective positioning within the stomach] with 5 mL of methylene blue used for balloon inflation *via* a closed infusion system, with the entire procedure being performed under direct endoscopic observation[57,58]. The FDA has approved Orbera for a 6-mo placement in people with a BMI of 30-40 kg/m². To rule out contraindications, such as a big hiatal hernia or a stomach ulcer, an endoscopy should be performed before or concurrently with placement[54].

Orbera® meets the obesity therapy “preservation and incorporation of valuable endoscopic innovations” thresholds of 5% TBWL and 15% EWL over control, respectively[59]. Similarly, a review of a database of individuals who had the OIB endoscopically placed revealed that it was effective, safe at inducing weight loss, and reduced complications related to obesity[56]. There were no spontaneous deflations observed in employing the OIB system. In this device, deflation can be detected through weight changes or patient-reported loss of satiety; however, current practice mandates a very simple method of detection through observing any irregular change in urine output[60].

A double balloon system (ReShape Integrated Dual Balloon System)

The ReShape IGB is a temporary implantation of a fluid-filled balloon that is designed to encourage weight loss by occupying space in the stomach. Endoscopy is utilized to deliver the balloon trans-orally. After positioning, inflation is done with saline (sterile) and methylene blue, which is used as an indicator in case the balloon mistakenly leaks or deflates. The balloon can remain in the stomach for six months[61].

In one study, total body weight was found to be lowered by 6.8% $\pm 7.3\%$ ($P < 0.001$) and BMI was reduced by 2.7 ± 2.9 kg/m² ($P < 0.001$) in all patients who had the ReShape IGB implanted, with completed follow-up of 6 mo. According to subgroup analyses, patients with > 40 kg/m² BMIs reported significant reductions in TBWL and BMI[61].

A three-balloon system

The three-balloon system is made up of three distinct balloons. These are placed through the mouth and subsequently filled with gas nitrogen to a capacity of roughly 250 mL by a connected catheter. One balloon is implanted monthly, with a maximum of three balloons. All balloons are removed endoscopically six months after the placement of the first balloon. The anticipated TBWL is 7.1%[62]. In one study, a swallowable gas-filled IGB device was deemed safe after six months

Table 1 A summary of endoscopic procedures for reducing weight in obese patients

Method	Indication (BMI)	Duration	Efficacy	Adverse events	Limitations	Ref.
IGBs	30-40 kg/m ²	6 mo	IGB therapy is a successful short-term weight loss strategy	Nausea/vomiting and stomach pain were the most common consequences, but mortality and gastric perforation were unusual. Other serious problems included dehydration, which required hospitalization, and intestinal obstruction due to balloon deflation, which required surgery	Short-term effects and weight regain	[45, 48, 50, 54, 87]
AT	35-55 kg/m ²	Long term usage	AT is an implantable device that drains a portion of the stomach contents after each meal, removing up to 30% of the calories consumed	Postoperative peristomal granulation tissue and peristomal irritation, cardiac arrhythmias, hypokalemia, hypochloremic hypokalemic metabolic alkalosis, rather than gastric botox and eating problems	It cannot be used for patients with eating disorders. For this technology to be effective and long-lasting, significant patient commitment, motivation, and adherence are necessary. In addition to adhering to correct device operation, chewing food thoroughly is a significant crucial aspect in attaining successful weight reduction using this device; thus, patients who fail to stick to thoroughly chewing their meal are unlikely to get ideal outcomes	[91, 94, 99]
Small bowel endoscopic procedures	41.5 kg/m ²	6-12 mo	10.6% TBWL and 40.2% EWL after one year	There were no AEs, and the nausea and diarrhea were self-limiting	Short-term efficacy, no small bowel EBTs are currently FDA-approved	[32, 83, 102, 103, 150]
Endoscopic sleeve gastropasty	> 30 kg/m ²	6-24 mo	%TBWL 12%-19% [150]	Leaks, perforation, hemorrhage, improved depth perception, improved visualization, severe stomach discomfort, and perigastric collection are all possible AEs	Required expertise and skills	[105, 111, 119, 150]
Endoluminal procedures	30-40 kg/m ²	6-12 mo	41.5 kg/m ² , which reduced to 33.1 kg/m ²	Pain, nausea, and vomiting	N/A	[129, 130]
DJBS	> 35 kg/m ²	6-12 mo	Effective patients lost 15% of their body weight at 12 mo, compared to 4% of controls	Nausea, vomiting, pancreatitis, GI bleeds, hepatic abscess, obstruction of the sleeve	As the common channel length shortens, so do diarrhea and severe vitamin A and D deficits	[132, 135, 137-139]
GJBS	30-40 kg/m ²	N/A	Patients reduced 39.7% of their excess	N/A	N/A	[140, 141]
Regulation gastric emptying	N/A	N/A	Weight loss was within 10% of their optimum weight	N/A	Hormonal imbalance and weight regain	[148, 149]

IGBs: Intra-gastric balloons; AT: Aspiration therapy; TBWL: Total body weight loss; EWL: Excess weight loss; N/A: Not applicable; GJBS: Gastroduodenal jejunal bypass sleeve; DJBS: Duodenal-jejunal bypass sleeve; GI: Gastrointestinal; AEs: Adverse events; EBT: Endoscopic bariatric therapy; FDA: Food and Drug Administration; BMI: Body mass index.

and resulted in double the weight loss than a sham control, with significant weight loss maintenance at 48 wk[63]. However, a study with 87 individuals who were successfully implanted with IGBs (gas-filled IGB; fluid-filled IGB) showed no differences in %TBWL between balloon systems at removal and 12 mo ($P = 0.39$). Although both gastric balloon systems were equally effective, the gas filled IGB had fewer significant side effects[64].

Orbera 365 balloon

The revolutionary ORBERA 365® balloon, made by Apollo Endosurgery, can remain within the stomach for a full year, hence its name[65,66]. Up to this point, limited studies with clinical data have been published. In one study, 97 individuals had an Orbera365 implanted. Prior to the treatment, the average weight and BMI of participants were 93.8 kg and 35.2 kg/m², respectively. After the procedure, these values decreased to 80.6 kg and 29.8 kg/m² after 8.2 mo and to 82.4 kg and 30.4 kg/m² on the last day of follow-up after 12.9 mo[62]. In another study, the weight reduction at IGB (Orbera) removal after 6 mo and at IGB (Orbera 365) removal after 12 mo was retrospectively examined. Mean TBWL was 15.2 and 15.8 kg in patients undergoing IGB placement for 6 and 12 mo, respectively. In patients receiving IGB placement for 6 or 12 mo, there was no discernible change in the mean %TBWL (15.3% vs 14.7%, $P = 0.7$)[67].

A single balloon system

The Catheter with the deflated balloon is inserted in the stomach and then the balloon is inflated with saline (500-700 mL)

A double balloon system

The Catheter with the two deflated balloons is inserted in the stomach and then the balloons are inflated with saline (500-700 mL)

A three balloon system

The Catheter with the three deflated balloons is inserted in the stomach and then the balloons are inflated with saline (500-700 mL) and the third balloon is filled with gas nitrogen

DOI: 10.3748/wjg.v29.i40.5526 Copyright ©The Author(s) 2023.

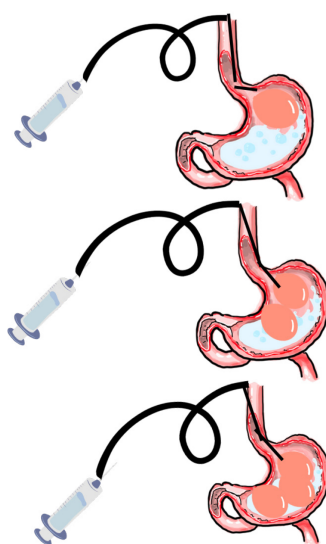


Figure 2 Different types of intra-gastric balloon system.

IGBS (AIR-FILLED)

IGBs, like air-filled balloons, as a temporary endoscopic treatment for obesity, have the potential to play an important role for the obese population[54]. They can also be used as a preoperative test before doing restricted bariatric surgery on patients. Furthermore, an intragastric device can be used as a “bridge treatment” before major surgery in individuals with severe obesity to lower the risk of operation-related complications[68]. Furthermore, IG balloons play a pivotal role as a transitional measure before bariatric surgery by serving as a bridge to reduce BMI and potentially mitigate the associated surgical risks. IGBs help patients achieve a lower BMI by facilitating initial weight loss, which may lead to improved overall health and decreased comorbidities. This reduction in BMI can also contribute to decreased surgical complications during subsequent bariatric procedures. Acting as a preoperative intervention, IGBs offer a safer trajectory for individuals with high BMI, allowing them to undergo bariatric surgery with potentially reduced morbidity and an enhanced surgical outcome. According to research, the air-filled balloon is effective and well tolerated, with weight reduction comparable to other types of balloons[69].

The air-filled IGB has not been shown to be harmful. It appears to have the same effect on weight loss as other balloons. After removal of the balloon, 30% of the patients in one study sustained a weight decrease of more than 10%[70]. However, in a comparative study, patients undergoing saline-filled balloon therapy (4.66 ± 4.75) lost considerably more weight than patients undergoing air-filled balloon surgery ($P < 0.001$). The variation in early withdrawal rates between the two groups, on the other hand, was minor ($P = 0.21$)[71]. With the air-filled IGB, the balloon is inflated with a specific gas, such as air or a mixture of air and nitrogen, using a catheter or a small tube connected to the balloon. The gas inflates the balloon, causing it to expand and take up space within the stomach[41].

Obalon

The United States FDA approved Obalon for the treatment of obesity[72]. This device, which is swallowed as a gel at the end of thin tubing, can be used anywhere. The device is then filled with a gas, and fluoroscopy is used to ensure proper installation. As a result, removal requires only one endoscopic treatment[73].

In one study, patients were randomly assigned to receive 3 balloon capsules (Obalon) or three sugar filled dummy capsules in a RCT with 15 facilities in the United States. A licensed dietician provided lifestyle advice to all subjects every three weeks. The treatment group's %TBWL was $6.81\% \pm 5.1\%$, while the control group's TBWL was $3.59\% \pm 5.0\%$. In the therapy group, the responder rate was 64.3%, defined as %TBWL $> 5\%$. Minor AEs, such as abdominal pain and nausea, occurred in most patients, with only one serious AE, which was a gastric ulcer in a patient who violated the research protocol by using a nonsteroidal anti-inflammatory medicine[71]. Mion *et al*[74] reported a prospective feasibility study, and all balloons were retrieved *via* upper gastrointestinal (GI) endoscopy 12 wk after the ingestion of the first balloon. Of the 44 balloon swallowing attempts, 43 (98%) were successful. Nausea and stomach pain were the most common AEs. Significant weight reduction was reported as well[64].

Heliosphere

The Heliosphere Bag is a silicone-encased air-filled polymer balloon[74]. When compared to fluid-filled balloons, this endoscopy-inserted device weighs less than 30 g, shows a 30-fold weight reduction, and it is certified for 6-mo use[41]. This device demonstrates a high effectiveness and tolerance profile. Loss of weight seems to be comparable to that of other types of balloons. In contrast, technical issues, particularly during removal, are most likely related to the device's substance and create a low safety profile[74].

In one study, the average weight reduction and BMI drop were 14.5 ± 8.2 kg and 5.3 ± 2.8 kg/m², respectively ($P < 0.001$). During the first week after Heliosphere Bag implantation, 7.4% of patients experienced nausea and vomiting[75]. Even though mid/long-term follow-up may result in some weight gain, Heliosphere® BAG allows for short-term loss of weight with few AEs[76]. Furthermore, De Castro *et al*[77] showed comparable weight reduction outcomes. Meanwhile, fluid-filled balloons are found to be more beneficial for weight loss[77]. In addition, a life-threatening complication was also reported in a patient using Heliosphere Bag[78].

Elipse

The Elipse balloon is a unique non-endoscopic weight loss approach[79]. At 16 wk, the Elipse IGB is naturally excreted out as it is a swallowable balloon[80]. Although Elipse has a shorter residence period in the stomach than other standard IGBs that need endoscopy, the procedure appears to have identical results[81]. Vomiting and nausea are the most common AEs. There were no major AEs[82].

In prospective research, 51 Elipse insertions were performed, and the patients' total weight reduction was 8.84 kg, %EWL 40.84%, %TBWL 10.44%, and change in BMI 3.42 kg/m². The device was proven to be effective; however, several limits were discovered that must be overcome for improved results[83]. Furthermore, a meta-analysis showed that the Elipse IGB is effective in weight reduction, safe, and is an efficient obesity technology with a low AE profile. A study conducted in Italy found early results after 4 mo with a mean %EWL of 26%. There were no balloon passage issues in the included patients[84].

COMPLICATIONS WITH IGBS

Despite the extremely low rates of difficulties and death linked with IGBs, AEs and complications can occur, and they can range from mild to severe[85]. The most prevalent AEs reported were vomiting, nausea, and stomach pain, while fatalities and gastric perforation were uncommon[86]. However, a 58-year-old Pakistani female presented with 2 wk of vomiting and abdominal bloating. While the external pigtail catheter and blue clasp for retrieval were stretching into D1/D2, the balloon was impacted at the antrum and pylorus. This is a relatively uncommon IGB complication[87]. Other severe complications included dehydration, which necessitated hospitalization, and intestinal blockage induced by balloon deflation, requiring surgery[88].

In conclusion, fluid-filled balloons are much more likely to result in weight loss than gas-filled balloons. They may, however, be associated with a higher likelihood of intolerance and removal. This data will assist clinicians in selecting devices and engaging patients in collaborative decision-making[89].

AT

The AspireAssist AT is the first FDA-approved device for the treatment of class II and III obesity[90]. AT comprises an endoscopic placement of a gastrostomy tube (A-tube) and an AspireAssist siphon component to aspirate gastric contents 20 min after meal consumption[91] (Figure 3), in conjunction with lifestyle modifications and an external device to allow drainage of around 30% of the calories taken in a meal[92]. It is approved for long-term usage in persons with BMIs of 35–55 kg/m² in the United States[93].

Studies show 14.2% to 21.5% TBWL in participants who complete one year of treatment and weight loss maintenance when treated for two years[94]. A pilot study was conducted, and patients in the AT group dropped $18.6 \pm 2.3\%$ of their body weight with $49.0 \pm 7.7\%$ EWL after one year, while in the lifestyle therapy group patients lost $5.9 \pm 5.0\%$ and $14.9 \pm 12.2\%$ EWL ($P < 0.04$). AT was found to be effective and safe as a long-term obesity weight loss therapy[95]. Similarly, a multicenter study with 82 individuals was carried out where the patients' average baseline BMI was 41.6 ± 4.5 kg/m². At the conclusion of the first year, participants had 34.1 ± 5.4 kg/m² BMI and $18.3 \pm 8.0\%$ TWL. Patients experienced 15.3% TWL after 2 years, 16.6% after 3 years and 18.7% TWL after 4 years with a significant difference ($P < 0.01$). The safety profile of AT was found to be satisfactory, effective, and approved for long-term weight loss treatment. Additionally, AT was found to be a safe and effective therapy for reducing weight as the mean percent total weight reduction was $18.2 \pm 9.4\%$, $19.8 \pm 11.3\%$, $21.3 \pm 9.6\%$, and $19.2 \pm 13.1\%$, at 1, 2, 3, and 4 years, respectively[96]. Similarly, a study with 25 obese participants was undertaken, and after 2 years of AT, BMI was 31.0 ± 5.1 kg/m², $P < 0.01$, and EWL was $61.5 \pm 28.5\%$, $P < 0.01$. It was concluded that AT is a safe and efficient treatment for obesity, and weight loss enhances QoL[97]. Furthermore, the effects were not limited to obesity; comorbidities related to obesity, such as diabetes, blood pressure, triglycerides, and lipoproteins, were significantly improved with AT[98].

However, the most commonly observed AEs with AT were perioperative discomfort and stomach pain as well as postoperative peristomal granulation tissue and peristomal irritation[91]. This can cause more serious hypokalemia, cardiac arrhythmias, and hypochloremic hypokalemic metabolic alkalosis than gastric botox. Some eating disorders can also be caused by AT[99]. Indeed, gastric irrigation and aspiration may result in persistent loss of chloride and hydrogen ions. The physiologic response is renal potassium ion secretion and hydrogen ion resorption; hypochloremic hypokalemic metabolic alkalosis may occur[100].

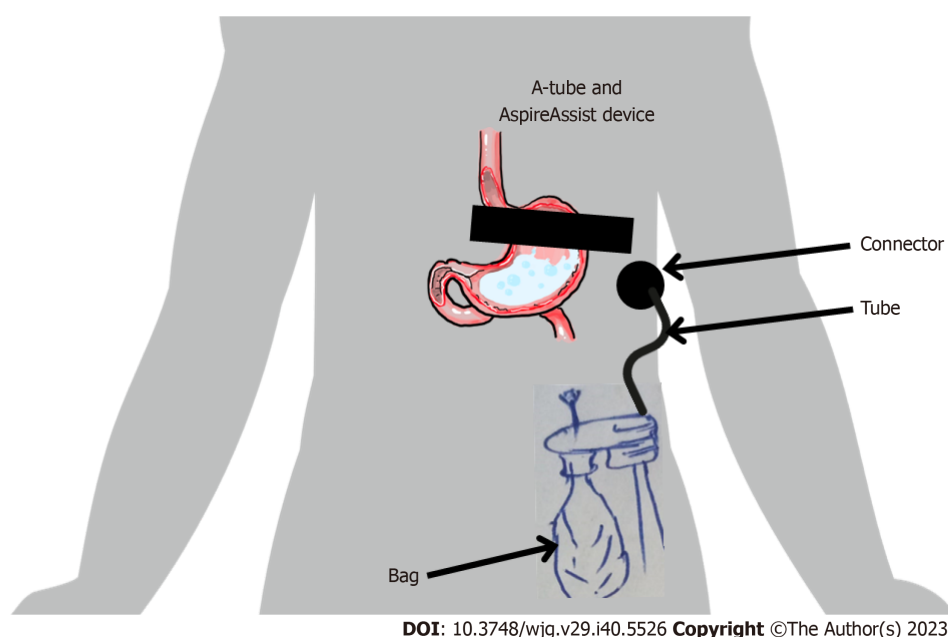


Figure 3 Schematic illustration of aspire assist device when in place.

SMALL BOWEL ENDOSCOPIC BARIATRIC TECHNIQUE

Endoscopic bariatric therapies for the small bowel include incisionless anastomosis devices (IAS), bypass sleeves and duodenal mucosal resurfacing. Endoscopic bariatric treatments can be performed safely and efficiently for weight loss and metabolic improvement, according to clinical evidence, employing tiny intestinal devices[98]. These therapies focus on foregut and hindgut processes to achieve weight loss and enhance glucose homeostasis[101]. When fully deployed, the IAS magnets form an octagonal shape. Pairs of IAS magnets are inserted into distinct segments of the small bowel, *via* simultaneous enteroscopy and colonoscopy, and are connected under endoscopic and fluoroscopic view[102].

In a research pilot, ten patients with a 41 kg/m² mean BMI had the operation. Laparoscopy was performed in this pilot study to establish appropriate magnet coupling and to validate limb lengths. The anastomosis developed in about a week, and the magnets were ejected without any pain or hindrance. At the 2 and 6-mo follow-up endoscopies, all anastomoses were patented. After six months, the patient had a 10.6% TBWL and 40.2% EWL after one year, and all anastomosis endured a patent[103]. There were no AEs. Diarrhea and nausea were self-limiting[102], as shown in Table 1.

ENDOSCOPIC SLEEVE GASTROPLASTY

Endoscopic sleeve gastroplasty (ESG) is a newer type of noninvasive weight loss procedure that uses a suturing device [104]. The endoscopist uses sutures to form a tube-like configuration in the stomach to promote restriction. If diet and exercise are not working and one is extremely overweight (BMI of 30 or higher), this treatment may be possible (Table 1). The technique is minimally invasive, which reduces the risk of operational impediments and allows for a speedy return to normal activities[105]. Additionally, the overstitch system also includes a double-channel endoscope with a suturing platform attached to it. A tissue grasper device is used to mobilize and capture the desired position of the suture on the stomach wall, after which the tissue is retracted into the device's suturing arm [106].

A recent study discovered that a customized running suture adopting a Z-pattern had a good effect on producing a homogeneous distribution of the suture's disruptive force across all stitch positions[107] and a "U" stitch pattern was also used[108]. Furthermore, a review of seven of the eight trials with adequate data revealed a weight loss which was statistically significant ($P < 0.05$). In an RCT, for the ESG group, the primary endpoint of mean %EWL was 49.2%, and for the control group, it was 32% at 52 wk ($P < 0.00001$). ESG had a significant weight loss, which was sustained at 104 wk and is also safe, with significant improvements in metabolic comorbidities[109]. Similarly, in another study, 435 patients from various obesity classes were included. At all-time intervals, ESG had a significantly higher %TBWL, TBWL, and BMI decrease in class III obesity compared to obesity of classes I and II ($P < 0.001$). In all types of obesity, ESG causes considerable weight loss[110]. Furthermore, efficacy was well established in a multicenter study conducted with 91 patients, and after treatment, BMI reduction after 3 mo was 7.3, after 6 mo 9.3, and after 12 mo 8.6 from baseline. EBWL was 17.3% after one month, 29.2% after three months, and 35.6% after six months with significant difference ($P < 0.000$)[111]. In addition, a meta-analysis was performed, the ESG resulted in around 15% TBWL or 58% EWL at 6-mo, and there was sustainability in weight loss at 12, 18, and 24 mo[112]. However, a study found laparoscopic sleeve gastrectomy (LSG) to be more efficient than ESG as it improved weight related QoL significantly[113]. Seven studies in a meta-analysis encompassed 6775 patients, with 3413 undergoing ESG and 3362 undergoing LSG procedures. Notable disparities were observed in the percentage of %TBWL, all of which favored LSG over ESG. While there was a tendency towards a decreased occurrence

of AEs with ESG compared to LSG, this distinction did not achieve statistical significance [risk ratio (RR) = 0.51, 95% CI: 0.23-1.11, $P = 0.09$]. The frequency of new-onset gastroesophageal reflux disease was markedly lower following ESG as opposed to LSG, at 1.3% compared to 17.9%, respectively (RR = 0.10, 95% CI: 0.02-0.53, $P = 0.006$) [114]. Moreover, a total of 2188 patients (1429 for LSG and 759 for ESG) from sixteen studies were included in another meta-analysis. The mean percentage of %EWL was 80.32% ($\pm 12.20\%$; 95% CI; $P = 0.001$; $I^2 = 98.88$) for the LSG group and 62.20% ($\pm 4.38\%$; 95% CI; $P = 0.005$; $I^2 = 65.52$) for the ESG group. This represents an absolute difference of 18.12% ($\pm 0.89\%$; 95% CI, $P = 0.0001$) between the two groups. The variation in the average rate of AEs was 0.19% ($\pm 0.37\%$; 95% CI; $\chi^2 = 1.602$; $P = 0.2056$) [115]. Similarly, ESG results in weight loss comparable to LSG, with similar improvements in comorbidity resolution and safety profiles was shown in another study [116].

Meanwhile, around 2.3% of patients had serious post-procedure issues; nevertheless, no deaths were documented [117]. Leaks, perforation, bleeding [112], better depth perception, better visualization [118], severe abdominal pain and a perigastric collection [119] have all been reported. Intraabdominal collection, refractory symptoms requiring ESG reversal, hemorrhage requiring transfusion or endoscopic intervention, pneumoperitoneum and pneumothorax and pulmonary embolism [120] are among the serious AEs that have been documented.

In conclusion, as with any weight loss intervention, the success of the ESG procedure can be influenced by factors such as patient adherence to lifestyle changes, dietary habits, and individual metabolic factors. Comparing the lasting utility of ESG with LSG, a surgical procedure, the latter has a longer track record and more established data on long-term outcomes. LSG has demonstrated sustained weight loss and metabolic improvements over several years. However, it is essential to note that LSG is a more invasive procedure with potential surgical risks and complications. When evaluating the choice between ESG and LSG, patients and healthcare providers should consider the balance between the invasiveness of the procedure and the expected long-term outcomes, as well as individual patient preferences and medical considerations.

ENDOLUMINAL PROCEDURES

Endoluminal procedures performed exclusively using gastrointestinal flexible endoscopy provide safer and more cost-effective alternatives to currently used surgical techniques for obesity management. However, endoscopic gastroplasty is one of the promising applications of endoluminal procedures in the field of metabolic obesity disorder [121]. Several endoluminal treatments for the loss of weight in obese patients have been developed, claiming to be as effective as surgery but safer [122]. Endoluminal obesity treatments show promise, and recent technology breakthroughs have been amazing. However, new therapies have had to meet the same requirements as present surgical treatments [123]. In fact, until the success of endoluminal treatments was proven, most surgeons were unwilling to consider them for their patients [124].

The transoral gastroplasty (TOGA) method conducts a vertical gastroplasty along the smaller curvature of the stomach using transoral endoscopy [125]. As a result, a gastric pouch forms, which restricts the food quantity or liquids that the patient can intake, resulting in an early feeling of fullness [126]. Another technique is the incisionless operating platform (IOP) which is used in primary obesity surgery endoluminal (POSE). The IOP is a four-part device used to regulate a full-thickness plication system endoscopically. It delivers a series of anchors into the stomach to encourage gastric imbrication [127].

In a systematic review, it was concluded that endoluminal plication devices were more successful in 91.8% of patients with 5.02% lower recurrence rates than sclerotherapy and Argon Plasma coagulation, which also had 46.8% success and 21.5% recurrence rates, respectively [128]. The same findings were reported in a multicenter trial with a one-year follow-up that included 67 patients with a mean BMI of 41.5 kg/m², which decreased to 33.1 kg/m² at 6 mo after TOGA treatment, with consequences including respiratory insufficiency and an asymptomatic pneumoperitoneum [129]. In a 12-mo multicenter RCT in the United States, 221 patients got the POSE surgery in conjunction with low-intensity lifestyle interventions. They attained a TBWL of 4.95% \pm 7.04% against 1.38% \pm 5.58% in the sham group with complications such as pain, nausea, and vomiting also reported [130].

The POSE and ESG methods are distinct endoscopic approaches for obesity control. Meanwhile, the POSE method involves the creation of tissue folds within the stomach to reduce its size and restrict food intake without removing tissue. In contrast, the ESG method involves suturing and narrowing the stomach's capacity, resembling a sleeve, to induce weight loss. While both methods are minimally invasive and avoid surgical incisions, the POSE method focuses on tissue folding, while the ESG method centers on suturing, leading to different mechanisms of action. The choice between these techniques depends on individual patient characteristics, preferences, and specific weight loss goals.

MALABSORPTIVE ENDOSCOPIC PROCEDURES

Malabsorptive endoscopic procedures may potentially provide an opportunity for an ambulatory technique that is both safer and less expensive than laparoscopic surgery. Endoscopic malabsorptive treatments can result in weight loss and have improved metabolic parameters associated with obesity [131].

Duodenal-jejunal bypass sleeve

The Duodenal-jejunal bypass sleeve (DJBS), known as DJBS is introduced using endoscopic and fluoroscopic methods. This implant consists of a non-porous fluoropolymer sleeve, temporarily anchored within the duodenal bulb and

extending approximately 80 cm into the small intestine, typically ending in the proximal jejunum[132,133]. It allows chyme to move from the stomach to the jejunum without contacting the duodenum. By not allowing mixing with pancreatic exocrine secretions and bile in the jejunum, it replicates a duodenal-jejunal bypass and promotes weight reduction through malabsorption[123]. Which has similarities to Roux-en-Y gastric bypass (RYGB) and this combined mechanism aims to achieve weight loss by reducing calorie intake and altering nutrient absorption patterns. The DJBS procedure offers a potentially reversible option for individuals with obesity seeking to manage their weight and improve metabolic health[134].

In a cohort trial, after 6 mo of DJBS treatment, there was a substantial rise in EWL and a drop in weight[135]. Similarly, a blinded, randomized, prospective clinical trial was carried out to assess the safety and efficacy of a new device for obese weight loss. The DJBS device was successfully implanted. At the end of the three-month research period, the device was removed endoscopically. The patient's TBWL was 9.09 kg[136]. Additionally, in another multicenter study, RCT was conducted with 41 patients and the EndoBarrier Gastrointestinal Liner device was implanted. After 3 mo, the mean EWL for the intervention group was 19% *vs* 6.9% for control patients ($P < 0.002$). The BMI absolute change was 5.5 and 1.9 kg/m², respectively. The device was discovered to be a practical and safe noninvasive weight loss device with outstanding short-term weight loss results[133]. Similar to previous research, in a multicenter open-label RCT, 24% of DJBS patients lost 15% of their body weight at 12 mo, compared to 4% of controls (odds ratio = 8.3, 95%CI: 1.8-39; $P = 0.007$). The inclusion of the DJBS to intense medical care was linked to greater weight loss and improvements in QoL[137]. However, significant weight recovery happens during long-term follow-up after device removal, particularly in people with BMIs larger than 35 kg/m²[138].

In total, 3.7% of patients experienced serious AEs such as pancreatitis (2 cases), GI bleeds (7 cases), hepatic abscess, obstruction of the sleeve, and esophageal tears[139]. There were no reported fatalities. Mild AEs primarily comprised nausea, vomiting, and anchor ulceration. Meanwhile, the attachment point of the DJBL was responsible for inducing or potentially inducing 85% of the SAEs[140].

Gastroduodenal-jejunal bypass sleeve

The gastroduodenal jejunal bypass sleeve (GJBS) treatment can help patients lose weight while also managing comorbidities such as diabetes, hypertension, and obstructive sleep apnea[15]. In theory, this device is the same as the EndoBarrier®. Its sleeve, on the contrary, is attached at the esophagogastric junction and continues about 120 cm through the stomach into the small bowel, imitating the ultimate anatomical structure in RYGB surgery. As a result, food passes immediately from the esophagus to the intestine, with no nutritional absorption occurring in the stomach, duodenum, or jejunum[141].

In one study, the GJBS was implanted in 24 patients. These patients reduced 39.7% of their excess weight by the end of the study. AEs were limited and resolved after the endoscopic device was removed[142]. Similarly, the implementation and retrieval were both safe. It is generally tolerated and has a favorable safety profile. It provides effective weight loss results, with more than 70% of all comorbidities cured or improved[143].

REGULATING GASTRIC EMPTYING

Changes in gastrointestinal motility, which are critical in food absorption and digestion in the gastrointestinal tract, may be one of the reasons why obesity develops[144]. The functions of incretins, particularly glucagon-like peptide-1, gastric inhibitory polypeptide, peptide tyrosine-tyrosine, glucagon, the duodenal and pancreatic hormones motilin, amylin, motilin, and the gastric orexigenic hormones ghrelin have the greatest impact on stomach emptying. Except for ghrelin and motilin, which accelerate stomach emptying, all these hormones delay gastric emptying[144]. The vagus nerve regulates the change in fundic compliance (also known as accommodation) once food enters the stomach, allowing the stomach to develop a reservoir with just a slight increase in intragastric pressure, boosting food intake[145,146]. Changes in circulating gut hormone concentrations activate a variety of pathways, especially in the brain stem and hypothalamus, which influence eating behavior and a variety of metabolic progressions[147]. In addition, gastric emptying inhibition may contribute to a decrease in energy intake. Mechanoreceptor activation caused by stomach distension may restrict additional food intake *via* neuronal reflex arcs[148]. However, diet-induced weight reduction causes long-term alterations in gut hormones for appetite, which are thought to favor increased desire and weight regain[149].

In an experimental study, the subjects were all subjected to quantitative fluid/solid gastric emptying experiments using a dual radionuclide method. In the solid phase, obese patients had a faster emptying rate than nonobese subjects ($P < 0.05$). Repeat gastric emptying investigations on four obese participants whose weight loss was within 10% of their optimum weight found no change in liquid or solid emptying rates. Obese patients have an abnormally fast rate of solid stomach emptying[150].

FUTURE DIRECTIONS

The future directions as follows: (1) A customized step-up approach aimed at improving and sustaining health performance is ideal, such as lifestyle therapies, nutrition modification, psychiatric treatment, medication and, if necessary, bariatric surgery; (2) In obese patients, EBTs successfully control metabolic comorbidities, improve overall weight loss and lower adverse risk events; (3) There should be some proper peer-reviewed guidelines for the implementation of

EBTs; (4) Studies should be conducted to increase the efficacy of EBTs as they are effective for a short time, and the problem of weight regain is also observed in EBTs, which should also be addressed; (5) Due to the vast variety of accessible therapies, the majority of which are not FDA-approved, first, there is a need to follow FDA and other quality control organizations to get approval; (6) There is a lack of a consistent therapeutic strategy, as well as a lack of training programs, which has limited their distribution and usage, short training programs should be organized and, if possible, should be added in the curriculum of medical schools; (7) Sophisticated endoscopy is now becoming a major component of minimally invasive fellowships, preparing surgeons to take on the role of bariatric endoscopists; (8) Cost benefits analysis should be made for a better understanding of the total expenditure on the use of therapy; and (9) Longer follow-up and larger multicenter RCTs are required to confirm current outcomes and improve the standardization process of these procedures.

CONCLUSION

Obesity is a chronic systemic disease that requires a multidisciplinary approach for prevention, treatment, and management. Proper treatment must be personalized and tailored to the degree of the patient's obesity and the combination of comorbidities. According to different studies, lifestyle changes and medicines can only achieve moderate weight loss results. Despite the fact that bariatric surgery has been shown to be a game-changing strategy in obesity, many patients find it unappealing due to its adverse effect profile and potential long-term difficulties. Compared to standard surgical treatments, bariatric endoscopic therapies may offer a valuable armamentarium in the therapy of obesity because their success in loss of weight is accompanied by being less intrusive, reversible, cost-effective and having a positive safety profile. It may become increasingly popular in the coming years because, when compared to surgery, it has a lower chance of AEs. Long-term efficacy is unknown at this moment. Additional research on long-term efficacy, metabolic disease outcomes, and RCTs is required. However, the future of obesity treatment lies in a multidisciplinary strategy requiring various treatment methods.

FOOTNOTES

Author contributions: Abdulla M, Mohammed N, and AlQamish J contributed to the collecting the data, review, editing, and finalizing the manuscript; Abdulla M designed the review and wrote the manuscript.

Conflict-of-interest statement: All the authors report no relevant conflicts of interest for this article.

Open-Access: This article is an open-access article that was selected by an in-house editor and fully peer-reviewed by external reviewers. It is distributed in accordance with the Creative Commons Attribution NonCommercial (CC BY-NC 4.0) license, which permits others to distribute, remix, adapt, build upon this work non-commercially, and license their derivative works on different terms, provided the original work is properly cited and the use is non-commercial. See: <https://creativecommons.org/licenses/by-nc/4.0/>

Country/Territory of origin: Bahrain

ORCID number: Maheeba Abdulla 0000-0001-5319-2892; Nafeesa Mohammed 0000-0003-4718-9325; Jehad AlQamish 0000-0001-8597-9913.

S-Editor: Wang JJ

L-Editor: A

P-Editor: Wang JJ

REFERENCES

- 1 Flegal KM, Kruszon-Moran D, Carroll MD, Fryar CD, Ogden CL. Trends in Obesity Among Adults in the United States, 2005 to 2014. *JAMA* 2016; **315**: 2284-2291 [PMID: 27272580 DOI: 10.1001/jama.2016.6458]
- 2 World Health Organization. World Obesity Day 2022—Accelerating action to stop obesity. [cited 15 June 2023]. Available from: <https://www.who.int/news/item/04-03-2022-world-obesity-day-2022-accelerating-action-to-stop-obesity>
- 3 Boutari C, Mantzoros CS. A 2022 update on the epidemiology of obesity and a call to action: as its twin COVID-19 pandemic appears to be receding, the obesity and dysmetabolism pandemic continues to rage on. *Metabolism* 2022; **133**: 155217 [PMID: 35584732 DOI: 10.1016/j.metabol.2022.155217]
- 4 Wang L, Zhou B, Zhao Z, Yang L, Zhang M, Jiang Y, Li Y, Zhou M, Wang L, Huang Z, Zhang X, Zhao L, Yu D, Li C, Ezzati M, Chen Z, Wu J, Ding G, Li X. Body-mass index and obesity in urban and rural China: findings from consecutive nationally representative surveys during 2004-18. *Lancet* 2021; **398**: 53-63 [PMID: 34217401 DOI: 10.1016/S0140-6736(21)00798-4]
- 5 Adams KF, Schatzkin A, Harris TB, Kipnis V, Mouw T, Ballard-Barbash R, Hollenbeck A, Leitzmann MF. Overweight, obesity, and mortality in a large prospective cohort of persons 50 to 71 years old. *N Engl J Med* 2006; **355**: 763-778 [PMID: 16926275 DOI: 10.1056/NEJMoa055643]
- 6 Peng W, Zhang J, Zhou H, Zhang A, Wang Y, Tian X, Wen D. Obesity intervention efforts in China and the 2022 World Obesity Day. *Global Health J* 2022; **6**: 118-121 [DOI: 10.1016/j.glohj.2022.07.007]

- 7 **Lobstein T**, Brinsden H, Neveux M. World Obesity Atlas 2022. London: World Obesity Federation, 2022
- 8 **Jebeile H**, Kelly AS, O'Malley G, Baur LA. Obesity in children and adolescents: epidemiology, causes, assessment, and management. *Lancet Diabetes Endocrinol* 2022; **10**: 351-365 [PMID: [35248172](#) DOI: [10.1016/S2213-8587\(22\)00047-X](#)]
- 9 **Mathieu-Bolh N**. The elusive link between income and obesity. *J Econ Surv* 2022; **36**: 935-968 [DOI: [10.1111/joes.12458](#)]
- 10 **Fisher BL**, Schauer P. Medical and surgical options in the treatment of severe obesity. *Am J Surg* 2002; **184**: 9S-16S [PMID: [12527344](#) DOI: [10.1016/s0002-9610\(02\)01173-x](#)]
- 11 **Wing RR**, Goldstein MG, Acton KJ, Birch LL, Jakicic JM, Sallis JF Jr, Smith-West D, Jeffery RW, Surwit RS. Behavioral science research in diabetes: lifestyle changes related to obesity, eating behavior, and physical activity. *Diabetes Care* 2001; **24**: 117-123 [PMID: [11194216](#) DOI: [10.2337/diacare.24.1.117](#)]
- 12 **US Preventive Services Task Force**, Curry SJ, Krist AH, Owens DK, Barry MJ, Caughey AB, Davidson KW, Doubeni CA, Epling JW Jr, Grossman DC, Kemper AR, Kubik M, Landefeld CS, Mangione CM, Phipps MG, Silverstein M, Simon MA, Tseng CW, Wong JB. Behavioral Weight Loss Interventions to Prevent Obesity-Related Morbidity and Mortality in Adults: US Preventive Services Task Force Recommendation Statement. *JAMA* 2018; **320**: 1163-1171 [PMID: [30326502](#) DOI: [10.1001/jama.2018.13022](#)]
- 13 **Angelidi AM**, Belanger MJ, Kokkinos A, Koliaki CC, Mantzoros CS. Novel Noninvasive Approaches to the Treatment of Obesity: From Pharmacotherapy to Gene Therapy. *Endocr Rev* 2022; **43**: 507-557 [PMID: [35552683](#) DOI: [10.1210/endrev/bnab034](#)]
- 14 **Albaugh VL**, Abumrad NN. Surgical treatment of obesity. *F1000Res* 2018; **7** [PMID: [29904577](#) DOI: [10.12688/f1000research.13515.1](#)]
- 15 **Buchwald H**, Avidor Y, Braunwald E, Jensen MD, Pories W, Fahrbach K, Schoelles K. Bariatric surgery: a systematic review and meta-analysis. *JAMA* 2004; **292**: 1724-1737 [PMID: [15479938](#) DOI: [10.1001/jama.292.14.1724](#)]
- 16 **Ri M**, Aikou S, Seto Y. Obesity as a surgical risk factor. *Ann Gastroenterol Surg* 2018; **2**: 13-21 [PMID: [29863119](#) DOI: [10.1002/ags3.12049](#)]
- 17 **McCarty TR**, Kumar N. Revision Bariatric Procedures and Management of Complications from Bariatric Surgery. *Dig Dis Sci* 2022; **67**: 1688-1701 [PMID: [35347535](#) DOI: [10.1007/s10620-022-07397-9](#)]
- 18 **Asge Standards of Practice Committee**, Anderson MA, Gan SI, Fanelli RD, Baron TH, Banerjee S, Cash BD, Dominitz JA, Harrison ME, Ikenberry SO, Jagannath SB, Lichtenstein DR, Shen B, Lee KK, Van Guilder T, Stewart LE. Role of endoscopy in the bariatric surgery patient. *Gastrointest Endosc* 2008; **68**: 1-10 [PMID: [18577471](#) DOI: [10.1016/j.gie.2008.01.028](#)]
- 19 **Behary J**, Kumbhari V. Advances in the Endoscopic Management of Obesity. *Gastroenterol Res Pract* 2015; **2015**: 757821 [PMID: [26106413](#) DOI: [10.1155/2015/757821](#)]
- 20 **Mccarty TR**, Thompson CC. Bariatric endoscopy. In: Wang TC, Camilleri M, Lebwohl B, Wang KK, LOK AS, Wu GD, Sandborn WJ, editors. Yamada's Textbook of Gastroenterology, 3 Volume Set, 7th ed. New Jersey: Wiley-Blackwell, 2022
- 21 **Staudenmann DA**, Sui Z, Saxena P, Kaffes AJ, Marinos G, Kumbhari V, Aepli P, Sartoretto A. Endoscopic bariatric therapies for obesity: a review. *Med J Aust* 2021; **215**: 183-188 [PMID: [34333788](#) DOI: [10.5694/mja2.51179](#)]
- 22 **Saunders KH**, Igel LI, Saumoy M, Sharaiha RZ, Aronne LJ. Devices and Endoscopic Bariatric Therapies for Obesity. *Curr Obes Rep* 2018; **7**: 162-171 [PMID: [29667157](#) DOI: [10.1007/s13679-018-0307-x](#)]
- 23 **Tawadros A**, Makar M, Kahaleh M, Sarkar A. Overview of bariatric and metabolic endoscopy interventions. *Ther Adv Gastrointest Endosc* 2020; **13**: 2631774520935239 [PMID: [32964206](#) DOI: [10.1177/2631774520935239](#)]
- 24 **Reja D**, Zhang C, Sarkar A. Endoscopic bariatrics: current therapies and future directions. *Transl Gastroenterol Hepatol* 2022; **7**: 21 [PMID: [35548475](#) DOI: [10.21037/tgh.2020.03.09](#)]
- 25 **de Moura DTH**, Dantas ACB, Ribeiro IB, McCarty TR, Takeda FR, Santo MA, Nahas SC, de Moura EGH. Status of bariatric endoscopy-what does the surgeon need to know? A review. *World J Gastrointest Surg* 2022; **14**: 185-199 [PMID: [35317547](#) DOI: [10.4240/wjgs.v14.i2.185](#)]
- 26 **De Moura DTH**, Jirapinyo P, Thompson CC. 2022b. Training in Bariatric Endoscopy. In: Cohen J. Successful Training in Gastrointestinal Endoscopy, 2nd ed. New Jersey: John Wiley & Sons Ltd, 2022
- 27 **Malli CP**, Sioulas AD, Emmanouil T, Dimitriadis GD, Triantafyllou K. Endoscopy after bariatric surgery. *Ann Gastroenterol* 2016; **29**: 249-257 [PMID: [27366025](#) DOI: [10.20524/aog.2016.0034](#)]
- 28 **Mehta A**, Sharaiha RZ. Bariatric and metabolic endoscopy: impact on obesity and related comorbidities. *Ther Adv Gastrointest Endosc* 2021; **14**: 26317745211019156 [PMID: [34179778](#) DOI: [10.1177/26317745211019156](#)]
- 29 **Negi A**, Asokkumar R, Ravi R, Lopez-Nava G, Bautista-Castaño I. Nutritional Management and Role of Multidisciplinary Follow-Up after Endoscopic Bariatric Treatment for Obesity. *Nutrients* 2022; **14** [PMID: [36014956](#) DOI: [10.3390/nu14163450](#)]
- 30 **Král J**, Machytká E, Horká V, Selucká J, Doleček F, Špičák J, Kovářová V, Haluzík M, Bužga M. Endoscopic Treatment of Obesity and Nutritional Aspects of Bariatric Endoscopy. *Nutrients* 2021; **13** [PMID: [34959819](#) DOI: [10.3390/nu13124268](#)]
- 31 **Castro M**, Guerron AD. Bariatric endoscopy: current primary therapies and endoscopic management of complications and other related conditions. *Mini-invasive Sur* 2020; **4**: 47 [DOI: [10.20517/2574-1225.2020.14](#)]
- 32 **Dolan RD**, Schulman AR. Endoscopic Approaches to Obesity Management. *Annu Rev Med* 2022; **73**: 423-438 [PMID: [34554827](#) DOI: [10.1146/annurev-med-042320-125832](#)]
- 33 **Silva LB**, Neto MG. Intra-gastric balloon. *Minim Invasive Ther Allied Technol* 2022; **31**: 505-514 [PMID: [33571068](#) DOI: [10.1080/13645706.2021.1874420](#)]
- 34 **Neto MG**, Silva LB, Usuy Jr EN, Campos JM. Intra-gastric Balloon for Weight Management: A Practical Guide. Switzerland: Springer International, 2020
- 35 **Lari E**, Burhamah W, Lari A, Alsaeed T, Al-Yaqout K, Al-Sabah S. Intra-gastric balloons - The past, present and future. *Ann Med Surg (Lond)* 2021; **63**: 102138 [PMID: [33664941](#) DOI: [10.1016/j.amsu.2021.01.086](#)]
- 36 **Gleysteen JJ**. A history of intra-gastric balloons. *Surg Obes Relat Dis* 2016; **12**: 430-435 [PMID: [26775045](#) DOI: [10.1016/j.soard.2015.10.074](#)]
- 37 **Pietrabissa G**, Bertuzzi V, Simpson S, Guerrini Usubini A, Cattivelli R, Bertoli S, Mozzi E, Roviario G, Castelnuovo G, Molinari E. Psychological Aspects of Treatment with Intra-gastric Balloon for Management of Obesity: A Systematic Review of the Literature. *Obes Facts* 2022; **15**: 1-18 [PMID: [34818229](#) DOI: [10.1159/000518200](#)]
- 38 **Carvalho GL**, Barros CB, Moraes CE, Okazaki M, Ferreira Mde N, Silva JS, de Albuquerque PP, Coelho Rde M. The use of an improved intra-gastric balloon technique to reduce weight in pre-obese patients--preliminary results. *Obes Surg* 2011; **21**: 924-927 [PMID: [19756895](#) DOI: [10.1007/s11695-009-9947-y](#)]
- 39 **Zafar S**, Haque I, Farooq M, Bashir H, Khan GM, Chaudry NU. Intra-gastric balloon for weight loss: preliminary analysis of efficacy & tolerability. *P J M H S* 2014; **8**: 224-229

- 40 **Sachdev P**, Reece L, Thomson M, Natarajan A, Copeland RJ, Wales JK, Wright NP. Intra-gastric balloon as an adjunct to lifestyle programme in severely obese adolescents: impact on biomedical outcomes and skeletal health. *Int J Obes (Lond)* 2018; **42**: 115-118 [PMID: [28871150](#) DOI: [10.1038/sj.ijo.2017.215](#)]
- 41 **Choi SJ**, Choi HS. Various Intra-gastric Balloons Under Clinical Investigation. *Clin Endosc* 2018; **51**: 407-415 [PMID: [30257544](#) DOI: [10.5946/ce.2018.140](#)]
- 42 **Messina T**, Genco A, Favaro R, Maselli R, Torchia F, Guidi F, Razza R, Aloï N, Piattelli M, Lorenzo M. Intra-gastric balloon positioning and removal: sedation or general anesthesia? *Surg Endosc* 2011; **25**: 3811-3814 [PMID: [21656325](#) DOI: [10.1007/s00464-011-1794-y](#)]
- 43 **Tsaousi G**, Fyntanidou B, Stavrou G, Papakostas P, Kotzampassi K, Grosomanidis V. Propofol Sedation for Intra-gastric Balloon Removal: Looking for the Optimal Body Weight Descriptor. *Obes Surg* 2019; **29**: 3882-3890 [PMID: [31290110](#) DOI: [10.1007/s11695-019-04075-0](#)]
- 44 **Galloro G**, Sivero L, Magno L, Diamantis G, Pastore A, Karagiannopoulos P, Inzirillo M, Formisano C, Iovino P. New technique for endoscopic removal of intra-gastric balloon placed for treatment of morbid obesity. *Obes Surg* 2007; **17**: 658-662 [PMID: [17658026](#) DOI: [10.1007/s11695-007-9110-6](#)]
- 45 **Sioulas AD**, Polymeros D, Kourikou A, Papanikolaou IS, Triantafyllou K. Intra-gastric balloon left in the stomach for more than a year: two case reports. *Obes Facts* 2012; **5**: 436-439 [PMID: [22797371](#) DOI: [10.1159/000341134](#)]
- 46 **Popov VB**, Ou A, Schulman AR, Thompson CC. The Impact of Intra-gastric Balloons on Obesity-Related Co-Morbidities: A Systematic Review and Meta-Analysis. *Am J Gastroenterol* 2017; **112**: 429-439 [PMID: [28117361](#) DOI: [10.1038/ajg.2016.530](#)]
- 47 **Vargas EJ**, Rizk M, Bazerbachi F, Abu Dayyeh BK. Medical Devices for Obesity Treatment: Endoscopic Bariatric Therapies. *Med Clin North Am* 2018; **102**: 149-163 [PMID: [29156183](#) DOI: [10.1016/j.mcna.2017.08.013](#)]
- 48 **Saber AA**, Shoar S, Almadani MW, Zundel N, Alkuwari MJ, Bashah MM, Rosenthal RJ. Efficacy of First-Time Intra-gastric Balloon in Weight Loss: a Systematic Review and Meta-analysis of Randomized Controlled Trials. *Obes Surg* 2017; **27**: 277-287 [PMID: [27465936](#) DOI: [10.1007/s11695-016-2296-8](#)]
- 49 **Kotinda APST**, de Moura DTH, Ribeiro IB, Singh S, da Ponte Neto AM, Proença IM, Flor MM, de Souza KL, Bernardo WM, de Moura EGH. Efficacy of Intra-gastric Balloons for Weight Loss in Overweight and Obese Adults: a Systematic Review and Meta-analysis of Randomized Controlled Trials. *Obes Surg* 2020; **30**: 2743-2753 [PMID: [32300945](#) DOI: [10.1007/s11695-020-04558-5](#)]
- 50 **Abu Dayyeh BK**, Maselli DB, Rapaka B, Lavin T, Noar M, Hussan H, Chapman CG, Popov V, Jirapinyo P, Acosta A, Vargas EJ, Storm AC, Bazerbachi F, Ryou M, French M, Noria S, Molina D, Thompson CC. Adjustable intra-gastric balloon for treatment of obesity: a multicentre, open-label, randomised clinical trial. *Lancet* 2021; **398**: 1965-1973 [PMID: [34793746](#) DOI: [10.1016/S0140-6736\(21\)02394-1](#)]
- 51 **Chan DL**, Cruz JR, Mui WL, Wong SKH, Ng EKW. Outcomes with Intra-gastric Balloon Therapy in BMI < 35 Non-morbid Obesity: 10-Year Follow-Up Study of an RCT. *Obes Surg* 2021; **31**: 781-786 [PMID: [33034015](#) DOI: [10.1007/s11695-020-04986-3](#)]
- 52 **Chow A**, Mocanu V, Verhoeff K, Switzer N, Birch D, Karmali S. Trends in the Utilization of Intra-gastric Balloons: a 5-Year Analysis of the MBSAQIP Registry. *Obes Surg* 2022; **32**: 1649-1657 [PMID: [35290611](#) DOI: [10.1007/s11695-022-06005-z](#)]
- 53 **Espinete Coll E**, Del Pozo García AJ, Turró Arau R, Nebreda Durán J, Cortés Rizo X, Serrano Jiménez A, Escartí Usó MÁ, Muñoz Tórner M, Carral Martínez D, Bernabéu López J, Sierra Bernal C, Martínez-Ares D, Espinete Díez J, Marra-López Valenciano C, Sola Vera J, Sanchis Artero L, Domínguez Jiménez JL, Carreño Macián R, Juanmartiñena Fernández JF, Fernández Zulueta A, Consiglieri Alvarado C, Grecco E, Bezerra Silva L, Galvao Neto M. Spanish Intra-gastric Balloon Consensus Statement (SIBC): practical guidelines based on experience of over 20 000 cases. *Rev Esp Enferm Dig* 2023; **115**: 22-34 [PMID: [36426855](#) DOI: [10.17235/reed.2022.9322/2022](#)]
- 54 **Kumar N**, Sullivan S, Thompson CC. The role of endoscopic therapy in obesity management: intra-gastric balloons and aspiration therapy. *Diabetes Metab Syndr Obes* 2017; **10**: 311-316 [PMID: [28740414](#) DOI: [10.2147/DMSO.S95118](#)]
- 55 **Abu Dayyeh BK**. Intra-gastric Balloons for Obesity Management. *Gastroenterol Hepatol (N Y)* 2017; **13**: 737-739 [PMID: [29339949](#)]
- 56 **Vargas EJ**, Pesta CM, Bali A, Ibegbu E, Bazerbachi F, Moore RL, Kumbhari V, Sharaiha RZ, Curry TW, DosSantos G, Schmitz R, Agnihotri A, Novikov AA, Pitt T, Dunlap MK, Herr A, Aronne L, Ledonne E, Kadouh HC, Cheskin LJ, Mundi MS, Acosta A, Gostout CJ, Abu Dayyeh BK. Single Fluid-Filled Intra-gastric Balloon Safe and Effective for Inducing Weight Loss in a Real-World Population. *Clin Gastroenterol Hepatol* 2018; **16**: 1073-1080.e1 [PMID: [29425781](#) DOI: [10.1016/j.cgh.2018.01.046](#)]
- 57 **Giardiello C**, Borrelli A, Silvestri E, Antognozzi V, Iodice G, Lorenzo M. Air-filled vs water-filled intra-gastric balloon: a prospective randomized study. *Obes Surg* 2012; **22**: 1916-1919 [PMID: [23054576](#) DOI: [10.1007/s11695-012-0786-x](#)]
- 58 **Cho JH**, Bilal M, Kim MC, Cohen J; Study Group for Endoscopic Bariatric and Metabolic Therapies of the Korean Society of Gastrointestinal Endoscopy. The Clinical and Metabolic Effects of Intra-gastric Balloon on Morbid Obesity and Its Related Comorbidities. *Clin Endosc* 2021; **54**: 9-16 [PMID: [33684281](#) DOI: [10.5946/ce.2020.302](#)]
- 59 **Abu Dayyeh BK**, Eaton LL, Woodman GF, Fusco M, Shayani V, Billy HT, Courcoulas A, Pambianco DJ, Gostout CJ. A randomized, multi-center study to evaluate the safety and effectiveness of an intra-gastric balloon as an adjunct to a behavioral modification program, in comparison with a behavioral modification program alone in the weight management of obese subjects. *Gastrointest Endosc* 2015; **81**: AB147 [DOI: [10.1016/j.gie.2015.03.1235](#)]
- 60 **Vyas D**, Deshpande K, Pandya Y. Advances in endoscopic balloon therapy for weight loss and its limitations. *World J Gastroenterol* 2017; **23**: 7813-7817 [PMID: [29209122](#) DOI: [10.3748/wjg.v23.i44.7813](#)]
- 61 **Suchartlikitwong S**, Laoveeravat P, Mingbunjerdusuk T, Vuthikraivit W, Ismail A, Islam S, Islam E. Usefulness of the ReShape intra-gastric balloon for obesity. *Proc (Bayl Univ Med Cent)* 2019; **32**: 192-195 [PMID: [31191125](#) DOI: [10.1080/08998280.2018.1559397](#)]
- 62 **Gollisch KSC**, Raddatz D. Endoscopic intra-gastric balloon: a gimmick or a viable option for obesity? *Ann Transl Med* 2020; **8**: S8 [PMID: [32309412](#) DOI: [10.21037/atm.2019.09.67](#)]
- 63 **Sullivan S**, Swain J, Woodman G, Edmundowicz S, Hassanein T, Shayani V, Fang JC, Noar M, Eid G, English WJ, Tariq N, Larsen M, Jonnalagadda SS, Riff DS, Ponce J, Early D, Volckmann E, Ibele AR, Spann MD, Krishnan K, Bucobo JC, Pryor A. Randomized sham-controlled trial of the 6-month swallowable gas-filled intra-gastric balloon system for weight loss. *Surg Obes Relat Dis* 2018; **14**: 1876-1889 [PMID: [30545596](#) DOI: [10.1016/j.soard.2018.09.486](#)]
- 64 **Swei E**, Almuhaideb A, Sullivan S, Al-Shahrani A, D'Souza FR, Altayar O, Bell S, Maday R, Wagh MS, Mullady D, Bennett M, Early D, Kushnir V. Comparison of the Efficacy and Safety of the FDA-approved Intra-gastric Balloon Systems in a Clinical Setting. *J Clin Gastroenterol* 2023; **57**: 578-585 [PMID: [35604348](#) DOI: [10.1097/MCG.0000000000001718](#)]
- 65 **Jamal MH**, Al-Kanawati N, Elabd R, Al-Haddad M, AlKhader T, Hamshari F, Akrouf S. A Study Examining the Orbera365 Intra-gastric Balloon Safety and Effects on Weight Loss. *Obes Surg* 2021; **31**: 5342-5347 [PMID: [34591263](#) DOI: [10.1007/s11695-021-05729-8](#)]
- 66 **Genco A**, Ernesti I, Gualtieri L. Intra-gastric Occupying Space Devices. In: Testoni PA, Inoue H, Wallace MB. Gastrointestinal and

- Pancreatico-Biliary Diseases: Advanced Diagnostic and Therapeutic Endoscopy. Cham: Springer, 2021
- 67 **Kozłowska-Petriczko K**, Pawlak KM, Wojciechowska K, Reiter A, Błaszczyk Ł, Szelemej J, Petriczko J, Wiechowska-Kozłowska A. The Efficacy Comparison of Endoscopic Bariatric Therapies: 6-Month Versus 12-Month Intra-gastric Balloon Versus Endoscopic Sleeve Gastroplasty. *Obes Surg* 2023; **33**: 498-505 [PMID: [36525237](#) DOI: [10.1007/s11695-022-06398-x](#)]
 - 68 **Giuricin M**, Nagliati C, Palmisano S, Simeth C, Urban F, Buri L, Balani A, de Manzini N. Short- and long-term efficacy of intra-gastric air-filled balloon (Heliosphere® BAG) among obese patients. *Obes Surg* 2012; **22**: 1686-1689 [PMID: [22820924](#) DOI: [10.1007/s11695-012-0700-6](#)]
 - 69 **Falcão M**, Martins MC. Air-Filled Intra-gastric Balloon Implant. In: Galvao Neto M, Silva LB, Usuy Jr, EN, Campos JM. Intra-gastric Balloon for Weight Management: A Practical Guide. Cham: Springer, 2020
 - 70 **Mion F**, Gincul R, Roman S, Beorchia S, Hedelius F, Claudel N, Bory RM, Malvoisin E, Trepo F, Napoleon B. Tolerance and efficacy of an air-filled balloon in non-morbidly obese patients: results of a prospective multicenter study. *Obes Surg* 2007; **17**: 764-769 [PMID: [17879576](#) DOI: [10.1007/s11695-007-9141-z](#)]
 - 71 **Abdelbadie M**, Hashem M, Fawzy M, Lababidi R, Abbsi S, Nabil M, Fathy A, Almahdy A, Subei I. Air-Filled versus Water-Filled Intra-gastric Balloon: A Comparative Retrospective Study 1033. *Am J Gastroenterol* 2018; **113**: S587-S589
 - 72 **Tate CM**, Geliebter A. Intra-gastric Balloon Treatment for Obesity: Review of Recent Studies. *Adv Ther* 2017; **34**: 1859-1875 [PMID: [28707286](#) DOI: [10.1007/s12325-017-0562-3](#)]
 - 73 **Kazi D**, Khaitan L. Endoscopic Bariatric/Metabolic Surgery. *Digest Dis Interven* 2018; **2**: 375-382
 - 74 **Mion F**, Ibrahim M, Marjoux S, Ponchon T, Dugardeyn S, Roman S, Deviere J. Swallowable Obalon® gastric balloons as an aid for weight loss: a pilot feasibility study. *Obes Surg* 2013; **23**: 730-733 [PMID: [23512445](#) DOI: [10.1007/s11695-013-0927-x](#)]
 - 75 **Trande P**, Mussetto A, Mirante VG, De Martinis E, Olivetti G, Conigliaro RL, De Micheli EA. Efficacy, tolerance and safety of new intra-gastric air-filled balloon (Heliosphere BAG) for obesity: the experience of 17 cases. *Obes Surg* 2010; **20**: 1227-1230 [PMID: [19082675](#) DOI: [10.1007/s11695-008-9786-2](#)]
 - 76 **Lecumberri E**, Krekshi W, Matia P, Hermida C, de la Torre NG, Cabrerizo L, Rubio MÁ. Effectiveness and safety of air-filled balloon Heliosphere BAG® in 82 consecutive obese patients. *Obes Surg* 2011; **21**: 1508-1512 [PMID: [21221835](#) DOI: [10.1007/s11695-010-0314-9](#)]
 - 77 **De Castro ML**, Morales MJ, Del Campo V, Pineda JR, Pena E, Sierra JM, Arbones MJ, Prada IR. Efficacy, safety, and tolerance of two types of intra-gastric balloons placed in obese subjects: a double-blind comparative study. *Obes Surg* 2010; **20**: 1642-1646 [PMID: [20390374](#) DOI: [10.1007/s11695-010-0128-9](#)]
 - 78 **Caglar E**, Dobrucali A, Bal K. Gastric balloon to treat obesity: filled with air or fluid? *Dig Endosc* 2013; **25**: 502-507 [PMID: [23369002](#) DOI: [10.1111/den.12021](#)]
 - 79 **Drozdowski R**, Wyleźół M, Frączek M, Hevelke P, Giaro M, Sobański P. Small bowel necrosis as a consequence of spontaneous deflation and migration of an air-filled intra-gastric balloon - a potentially life-threatening complication. *Wideochir Inne Tech Maloinwazyjne* 2014; **9**: 292-296 [PMID: [25097704](#) DOI: [10.5114/wiitm.2011.38177](#)]
 - 80 **Ienca R**, Al Jarallah M, Caballero A, Giardiello C, Rosa M, Kolmer S, Sebbag H, Hansoulle J, Quartararo G, Zouaghi SAS, Juneja G, Murcia S, Turro R, Pagan A, Badiuddin F, Dargent J, Urbain P, Paveliu S, di Cola RS, Selvaggio C, Al Kuwari M. The Procedureless Elipse Gastric Balloon Program: Multicenter Experience in 1770 Consecutive Patients. *Obes Surg* 2020; **30**: 3354-3362 [PMID: [32279182](#) DOI: [10.1007/s11695-020-04539-8](#)]
 - 81 **Ramai D**, Singh J, Mohan BP, Madedor O, Brooks OW, Barakat M, Ofosu A, Khan SR, Chandan S, Dhindsa B, Dhaliwal A, Facciorusso A, McDonough S, Adler DG. Influence of the Elipse Intra-gastric Balloon on Obesity and Metabolic Profile: A Systematic Review and Meta-Analysis. *J Clin Gastroenterol* 2021; **55**: 836-841 [PMID: [33394629](#) DOI: [10.1097/MCG.0000000000001484](#)]
 - 82 **Raftopoulos I**, Giannakou A. The Elipse Balloon, a swallowable gastric balloon for weight loss not requiring sedation, anesthesia or endoscopy: a pilot study with 12-month outcomes. *Surg Obes Relat Dis* 2017; **13**: 1174-1182 [PMID: [28372952](#) DOI: [10.1016/j.soard.2017.02.016](#)]
 - 83 **Machytka E**, Chuttani R, Bojkova M, Kupka T, Buzga M, Stecco K, Levy S, Gaur S. Elipse™, a Procedureless Gastric Balloon for Weight Loss: a Proof-of-Concept Pilot Study. *Obes Surg* 2016; **26**: 512-516 [PMID: [26253980](#) DOI: [10.1007/s11695-015-1783-7](#)]
 - 84 **Al-Subaie S**, Khalifa S, Buhaimed W, Al-Rashidi S. A prospective pilot study of the efficacy and safety of Elipse intra-gastric balloon: A single-center, single-surgeon experience. *Int J Surg* 2017; **48**: 16-22 [PMID: [28989057](#) DOI: [10.1016/j.ijssu.2017.10.001](#)]
 - 85 **Genco A**, Ernesti I, Ienca R, Casella G, Mariani S, Francomano D, Soricelli E, Lorenzo M, Monti M. Safety and Efficacy of a New Swallowable Intra-gastric Balloon Not Needing Endoscopy: Early Italian Experience. *Obes Surg* 2018; **28**: 405-409 [PMID: [28871497](#) DOI: [10.1007/s11695-017-2877-1](#)]
 - 86 **Ribeiro IB**, Kotinda APST, Sánchez-Luna SA, de Moura DTH, Mancini FC, de Souza TF, Matuguma SE, Sakai CM, Rocha RSP, Luz GO, Lera Dos Santos ME, Chaves DM, Franzini TAP, de Moura ETH, de Moura EGH. Adverse Events and Complications with Intra-gastric Balloons: a Narrative Review (with Video). *Obes Surg* 2021; **31**: 2743-2752 [PMID: [33788158](#) DOI: [10.1007/s11695-021-05352-7](#)]
 - 87 **Yorke E**, Switzer NJ, Reso A, Shi X, de Gara C, Birch D, Gill R, Karmali S. Intra-gastric Balloon for Management of Severe Obesity: a Systematic Review. *Obes Surg* 2016; **26**: 2248-2254 [PMID: [27444806](#) DOI: [10.1007/s11695-016-2307-9](#)]
 - 88 **Mujtaba G**, Zehra R, Balkhi F, Shaikh N. Impact of Intra-gastric Balloon: A Rare Complication. *J Coll Physicians Surg Pak* 2022; **32**: S89-S91 [PMID: [36210657](#) DOI: [10.29271/jcpsp.2022.Supp2.S89](#)]
 - 89 **Mathus-Vliegen EM**, Alders PR, Chuttani R, Scherpenisse J. Outcomes of intra-gastric balloon placements in a private practice setting. *Endoscopy* 2015; **47**: 302-307 [PMID: [25479562](#) DOI: [10.1055/s-0034-1390860](#)]
 - 90 **Bazerbachi F**, Haffar S, Sawas T, Vargas EJ, Kaur RJ, Wang Z, Prokop LJ, Murad MH, Abu Dayyeh BK. Fluid-Filled Versus Gas-Filled Intra-gastric Balloons as Obesity Interventions: a Network Meta-analysis of Randomized Trials. *Obes Surg* 2018; **28**: 2617-2625 [PMID: [29663250](#) DOI: [10.1007/s11695-018-3227-7](#)]
 - 91 **Thompson CC**, Abu Dayyeh BK, Kushner R, Sullivan S, Schorr AB, Amaro A, Apovian CM, Fullum T, Zarrinpar A, Jensen MD, Stein AC, Edmundowicz S, Kahaleh M, Ryou M, Bohning JM, Ginsberg G, Huang C, Tran DD, Glaser JP, Martin JA, Jaffe DL, Farraye FA, Ho SB, Kumar N, Harakal D, Young M, Thomas CE, Shukla AP, Ryan MB, Haas M, Goldsmith H, McCrea J, Aronne LJ. Percutaneous Gastrostomy Device for the Treatment of Class II and Class III Obesity: Results of a Randomized Controlled Trial. *Am J Gastroenterol* 2017; **112**: 447-457 [PMID: [27922026](#) DOI: [10.1038/ajg.2016.500](#)]
 - 92 **Sullivan S**, Stein R, Jonnalagadda S, Mullady D, Edmundowicz S. Aspiration therapy leads to weight loss in obese subjects: a pilot study. *Gastroenterology* 2013; **145**: 1245-52.e1 [PMID: [24012983](#) DOI: [10.1053/j.gastro.2013.08.056](#)]
 - 93 **Thompson CC**, Abu Dayyeh BK, Kushnir V, Kushner RF, Jirapinyo P, Schorr AB, Aronne LJ, Amaro A, Jaffe DL, Schulman AR, Early D,

- Stein AC, Sharaiha R, Edmundowicz SA, Bohning JM, Jensen MD, Shukla AP, Apovian C, Kim DW, Tran D, Zarrinpar A, Ryan MB, Young M, Lowe A, Haas M, Goldsmith H, McCrea J, Sullivan S. Aspiration therapy for the treatment of obesity: 4-year results of a multicenter randomized controlled trial. *Surg Obes Relat Dis* 2019; **15**: 1348-1354 [PMID: 31302000 DOI: 10.1016/j.soard.2019.04.026]
- 94 PMA P150024: FDA Summary of safety and effectiveness data (SSED). [cited 15 June 2023]. Available from: https://www.accessdata.fda.gov/cdrh_docs/pdf15/p150024b.pdf
- 95 Sullivan S. Aspiration Therapy for Obesity. *Gastrointest Endosc Clin N Am* 2017; **27**: 277-288 [PMID: 28292406 DOI: 10.1016/j.giec.2016.12.001]
- 96 Nyström M, Machytka E, Norén E, Testoni PA, Janssen I, Turró Homedes J, Espinos Perez JC, Turro Arau R. Aspiration Therapy As a Tool to Treat Obesity: 1- to 4-Year Results in a 201-Patient Multi-Center Post-Market European Registry Study. *Obes Surg* 2018; **28**: 1860-1868 [PMID: 29388050 DOI: 10.1007/s11695-017-3096-5]
- 97 Norén E, Forssell H. Aspiration therapy for obesity; a safe and effective treatment. *BMC Obes* 2016; **3**: 56 [PMID: 28035287 DOI: 10.1186/s40608-016-0134-0]
- 98 Jirapinyo P, de Moura DTH, Horton LC, Thompson CC. Effect of Aspiration Therapy on Obesity-Related Comorbidities: Systematic Review and Meta-Analysis. *Clin Endosc* 2020; **53**: 686-697 [PMID: 32106362 DOI: 10.5946/ce.2019.181]
- 99 Ülger TG, Tayfur M, Çakıroğlu FP. The role of aspiration therapy and intragastric botulinum toxin A injection in obesity treatment. *Obes Med* 2021; **26**: 100367 [DOI: 10.1016/j.obmed.2021.100367]
- 100 Gennari FJ. Pathophysiology of metabolic alkalosis: a new classification based on the centrality of stimulated collecting duct ion transport. *Am J Kidney Dis* 2011; **58**: 626-636 [PMID: 21849227 DOI: 10.1053/j.ajkd.2011.06.004]
- 101 Gong EJ, Kim DH. Small Bowel Endoscopic Bariatric Therapies. *Clin Endosc* 2018; **51**: 425-429 [PMID: 30257545 DOI: 10.5946/ce.2018.153]
- 102 Machytka E, Bužga M, Zonca P, Lautz DB, Ryou M, Simonson DC, Thompson CC. Partial jejunal diversion using an incisionless magnetic anastomosis system: 1-year interim results in patients with obesity and diabetes. *Gastrointest Endosc* 2017; **86**: 904-912 [PMID: 28716404 DOI: 10.1016/j.gie.2017.07.009]
- 103 Machytka E, Buzga M, Ryou M, Lautz DB, Thompson CCJG. Endoscopic dual-path enteral anastomosis using self-assembling magnets: first-in-human clinical feasibility. *Gastroenterology* 2016; **150**: S232 [DOI: 10.1016/S0016-5085(16)30848-4]
- 104 Abu Dayyeh BK, Acosta A, Camilleri M, Mundi MS, Rajan E, Topazian MD, Gostout CJ. Endoscopic Sleeve Gastroplasty Alters Gastric Physiology and Induces Loss of Body Weight in Obese Individuals. *Clin Gastroenterol Hepatol* 2017; **15**: 37-43 [PMID: 26748219 DOI: 10.1016/j.cgh.2015.12.030]
- 105 Sujka J, Teixeira A, Galvao Neto M. Endoscopic Sleeve Gastroplasty for Obesity. In: Agrawal, S. editor. Obesity, Bariatric and Metabolic Surgery: A Comprehensive Guide. Cham: Springer, 2020
- 106 Bazerbachi F, Vargas Valls EJ, Abu Dayyeh BK. Recent Clinical Results of Endoscopic Bariatric Therapies as an Obesity Intervention. *Clin Endosc* 2017; **50**: 42-50 [PMID: 28147472 DOI: 10.5946/ce.2017.013]
- 107 Graus Morales J, Crespo Pérez L, Marques A, Marín Arribas B, Bravo Arribas R, Ramo E, Escalada C, Arribas C, Himpens J. Modified endoscopic gastroplasty for the treatment of obesity. *Surg Endosc* 2018; **32**: 3936-3942 [PMID: 29492709 DOI: 10.1007/s00464-018-6133-0]
- 108 Barrichello S, Hourneaux de Moura DT, Hourneaux de Moura EG, Jirapinyo P, Hoff AC, Fittipaldi-Fernandez RJ, Baretta G, Felício Lima JH, Usuy EN, de Almeida LS, Ramos FM, Matz F, Galvão Neto MDP, Thompson CC. Endoscopic sleeve gastroplasty in the management of overweight and obesity: an international multicenter study. *Gastrointest Endosc* 2019; **90**: 770-780 [PMID: 31228432 DOI: 10.1016/j.gie.2019.06.013]
- 109 Jain D, Bhandari BS, Arora A, Singhal S. Endoscopic Sleeve Gastroplasty - A New Tool to Manage Obesity. *Clin Endosc* 2017; **50**: 552-561 [PMID: 28607328 DOI: 10.5946/ce.2017.032]
- 110 Abu Dayyeh BK, Bazerbachi F, Vargas EJ, Sharaiha RZ, Thompson CC, Thamer BC, Teixeira AF, Chapman CG, Kumbhari V, Ujiki MB, Ahrens J, Day C; MERIT Study Group, Galvao Neto M, Zundel N, Wilson EB. Endoscopic sleeve gastroplasty for treatment of class 1 and 2 obesity (MERIT): a prospective, multicentre, randomised trial. *Lancet* 2022; **400**: 441-451 [PMID: 35908555 DOI: 10.1016/S0140-6736(22)01280-6]
- 111 Lopez-Nava G, Laster J, Negi A, Fook-Chong S, Bautista-Castaño I, Asokkumar R. Endoscopic sleeve gastroplasty (ESG) for morbid obesity: how effective is it? *Surg Endosc* 2022; **36**: 352-360 [PMID: 33492503 DOI: 10.1007/s00464-021-08289-1]
- 112 Sarkar A, Tawadros A, Andalib I, Shahid HM, Tyberg A, Alkhairi R, Gaidhane M, Kedia P, John ES, Bushe B, Martinez GM, Zamarripa F, Carames MC, Carames JC, Casarodriguez F, Bove V, Costamagna G, Boskoski I, Kahaleh M. Safety and efficacy of endoscopic sleeve gastroplasty for obesity management in new bariatric endoscopy programs: a multicenter international study. *Ther Adv Gastrointest Endosc* 2022; **15**: 26317745221093883 [PMID: 35694412 DOI: 10.1177/26317745221093883]
- 113 Hedjoudje A, Abu Dayyeh BK, Cheskin LJ, Adam A, Neto MG, Badurdeen D, Morales JG, Sartoretto A, Nava GL, Vargas E, Sui Z, Fayad L, Farha J, Khashab MA, Kalloo AN, Alqahtani AR, Thompson CC, Kumbhari V. Efficacy and Safety of Endoscopic Sleeve Gastroplasty: A Systematic Review and Meta-Analysis. *Clin Gastroenterol Hepatol* 2020; **18**: 1043-1053.e4 [PMID: 31442601 DOI: 10.1016/j.cgh.2019.08.022]
- 114 Beran A, Matar R, Jaruvongvanich V, Rapaka BB, Alalwan A, Portela R, Ghanem O, Dayyeh BKA. Comparative Effectiveness and Safety Between Endoscopic Sleeve Gastroplasty and Laparoscopic Sleeve Gastrectomy: a Meta-analysis of 6775 Individuals with Obesity. *Obes Surg* 2022; **32**: 3504-3512 [PMID: 36053446 DOI: 10.1007/s11695-022-06254-y]
- 115 Marincola G, Gallo C, Hassan C, Raffaelli M, Costamagna G, Bove V, Pontecorvi V, Orlandini B, Boškoski I. Laparoscopic sleeve gastrectomy versus endoscopic sleeve gastroplasty: a systematic review and meta-analysis. *Endosc Int Open* 2021; **9**: E87-E95 [PMID: 33403240 DOI: 10.1055/a-1300-1085]
- 116 Carr P, Keighley T, Petocz P, Blumfield M, Rich GG, Cohen F, Soni A, Maimone IR, Fayet-Moore F, Isenring E, Marshall S. Efficacy and safety of endoscopic sleeve gastroplasty and laparoscopic sleeve gastrectomy with 12+ months of adjuvant multidisciplinary support. *BMC Prim Care* 2022; **23**: 26 [PMID: 35123409 DOI: 10.1186/s12875-022-01629-7]
- 117 Sharaiha R. Managing Obesity With Endoscopic Sleeve Gastroplasty. *Gastroenterol Hepatol (N Y)* 2017; **13**: 547-549 [PMID: 29038645]
- 118 Afonso M, Soares R, Ramos R, Balkestahl J, Andrade E, Machado L. Three-Dimensional (3D) Endoscopic Sleeve Gastroplasty: Single center case series. *Endoscopy* 2022
- 119 Manos T, Costil V, Karsenty L, Costil P, Noel P, Carandina S, Nedelcu M. Safety of Endoscopic Sleeve Gastroplasty with a Single-Channel Endoscope. *Obes Surg* 2022; **32**: 3074-3078 [PMID: 35857182 DOI: 10.1007/s11695-022-06210-w]
- 120 Storm AC, Abu Dayyeh BK. Endoscopic sleeve gastroplasty for obesity: defining the risk and reward after more than 1600 procedures.

- Gastrointest Endosc* 2019; **89**: 1139-1140 [PMID: 31104746 DOI: 10.1016/j.gie.2019.02.025]
- 121 **Choi HS**, Chun HJ. Recent Trends in Endoscopic Bariatric Therapies. *Clin Endosc* 2017; **50**: 11-16 [PMID: 28147471 DOI: 10.5946/ce.2017.007]
- 122 Recent Advances in Laparoscopic Surgery. [cited 15 June 2023]. Available from: <http://dx.doi.org/10.5772/intechopen.78455>
- 123 **Coté GA**, Edmundowicz SA. Emerging technology: endoluminal treatment of obesity. *Gastrointest Endosc* 2009; **70**: 991-999 [PMID: 19879407 DOI: 10.1016/j.gie.2009.09.016]
- 124 **Brethauer SA**, Pryor AD, Chand B, Schauer P, Rosenthal R, Richards W, Bessler M; American Society for Metabolic and Bariatric Surgery Emerging Technologies Committee. Endoluminal procedures for bariatric patients: expectations among bariatric surgeons. *Surg Obes Relat Dis* 2009; **5**: 231-236 [PMID: 19136306 DOI: 10.1016/j.soard.2008.09.019]
- 125 **Moreno C**, Closset J, Dugardeyn S, Baréa M, Mehdi A, Collignon L, Zalcmán M, Baurain M, Le Moine O, Devière J. Transoral gastroplasty is safe, feasible, and induces significant weight loss in morbidly obese patients: results of the second human pilot study. *Endoscopy* 2008; **40**: 406-413 [PMID: 18459077 DOI: 10.1055/s-2007-995748]
- 126 **ASGE Technology Committee**, Kethu SR, Banerjee S, Barth BA, Desilets DJ, Kaul V, Pedrosa MC, Pfau PR, Pleskow DK, Tokar JL, Wang A, Song LM, Rodriguez SA. Endoluminal bariatric techniques. *Gastrointest Endosc* 2012; **76**: 1-7 [PMID: 22579259 DOI: 10.1016/j.gie.2012.02.020]
- 127 **Brunaldi VO**, Galvao Neto M. Endoscopic techniques for weight loss and treating metabolic syndrome. *Curr Opin Gastroenterol* 2019; **35**: 424-431 [PMID: 31219828 DOI: 10.1097/MOG.0000000000000561]
- 128 **Goh YM**, James NE, Goh EL, Khanna A. The use of endoluminal techniques in the revision of primary bariatric surgery procedures: a systematic review. *Surg Endosc* 2020; **34**: 2410-2428 [PMID: 32112253 DOI: 10.1007/s00464-020-07468-w]
- 129 **Familiari P**, Costamagna G, Bléro D, Le Moine O, Perri V, Boskoski I, Coppens E, Barea M, Iaconelli A, Mingrone G, Moreno C, Devière J. Transoral gastroplasty for morbid obesity: a multicenter trial with a 1-year outcome. *Gastrointest Endosc* 2011; **74**: 1248-1258 [PMID: 22136774 DOI: 10.1016/j.gie.2011.08.046]
- 130 **Sullivan S**, Swain JM, Woodman G, Antonetti M, De La Cruz-Muñoz N, Jonnalagadda SS, Ujiki M, Ikramuddin S, Ponce J, Ryou M, Reynoso J, Chhabra R, Sorenson GB, Clarkston WK, Edmundowicz SA, Eagon JC, Mullady DK, Leslie D, Lavin TE, Thompson CC. Randomized sham-controlled trial evaluating efficacy and safety of endoscopic gastric plication for primary obesity: The ESSENTIAL trial. *Obesity (Silver Spring)* 2017; **25**: 294-301 [PMID: 28000425 DOI: 10.1002/oby.21702]
- 131 **Park JM**. Role of Malabsorptive Endoscopic Procedures in Obesity Treatment. *Clin Endosc* 2017; **50**: 26-30 [PMID: 28147470 DOI: 10.5946/ce.2017.004]
- 132 **Ruban A**, Miras AD, Glaysheer MA, Goldstone AP, Prechtel CG, Johnson N, Chhina N, Al-Najim W, Aldhwayan M, Klimowska-Nassar N, Smith C, Lord J, Li JV, Flores L, Al-Lababidi M, Dimitriadis GK, Patel M, Moore M, Chahal H, Ahmed AR, Cousins J, Aldubaikhi G, Glover B, Falaschetti E, Ashrafian H, Roux CWL, Darzi A, Byrne JP, Teare JP. Duodenal-Jejunal Bypass Liner for the management of Type 2 Diabetes Mellitus and Obesity: A Multicenter Randomized Controlled Trial. *Ann Surg* 2022; **275**: 440-447 [PMID: 34647708 DOI: 10.1097/SLA.0000000000004980]
- 133 **Schouten R**, Rijs CS, Bouvy ND, Hameeteman W, Koek GH, Janssen IM, Greve JW. A multicenter, randomized efficacy study of the EndoBarrier Gastrointestinal Liner for presurgical weight loss prior to bariatric surgery. *Ann Surg* 2010; **251**: 236-243 [PMID: 19858703 DOI: 10.1097/SLA.0b013e3181bdfbff]
- 134 **Chen JH**, Yu ZH, Liu QF, Meng QG, Chen X. Research Progress of Duodenal-Jejunal Bypass Liner in the Treatment of Obesity and Type 2 Diabetes Mellitus. *Diabetes Metab Syndr Obes* 2022; **15**: 3319-3327 [PMID: 36329806 DOI: 10.2147/DMSO.S382324]
- 135 **van Rijn S**, Betzel B, de Jonge C, van Dijk DPJ, Janssen IM, Berends FJ, Bouvy ND, Greve JWM. The Effect of 6 and 12 months Duodenal-Jejunal Bypass Liner Treatment on Obesity and Type 2 Diabetes: a Crossover Cohort Study. *Obes Surg* 2018; **28**: 1255-1262 [PMID: 29110244 DOI: 10.1007/s11695-017-2997-7]
- 136 **Gersin KS**, Keller JE, Stefanidis D, Simms CS, Abraham DD, Deal SE, Kuwada TS, Heniford BT. Duodenal-jejunal bypass sleeve: a totally endoscopic device for the treatment of morbid obesity. *Surg Innov* 2007; **14**: 275-278 [PMID: 18178916 DOI: 10.1177/1553350607312901]
- 137 **Boonchaya-Anant P**, Bueter M, Gubler C, Gerber PA. Sustained weight loss after duodenal-jejunal bypass liner treatment in patients with body mass index below, but not above 35 kg/m(2) : A retrospective cohort study. *Clin Obes* 2023; **13**: e12561 [PMID: 36239531 DOI: 10.1111/cob.12561]
- 138 **Betzel B**, Koehestanie P, Aarts EO, Dogan K, Homan J, Janssen IM, Wahab PJ, Groenen MJ, Berends FJ. Safety experience with the duodenal-jejunal bypass liner: an endoscopic treatment for diabetes and obesity. *Gastrointest Endosc* 2015; **82**: 845-852 [PMID: 25952090 DOI: 10.1016/j.gie.2015.03.1911]
- 139 **Betzel B**, Drenth JPH, Siersema PD. Adverse Events of the Duodenal-Jejunal Bypass Liner: a Systematic Review. *Obes Surg* 2018; **28**: 3669-3677 [PMID: 30121857 DOI: 10.1007/s11695-018-3441-3]
- 140 **Sandler BJ**, Rumbaut R, Swain CP, Torres G, Morales L, Gonzales L, Schultz S, Talamini M, Horgan S. Human experience with an endoluminal, endoscopic, gastrojejunal bypass sleeve. *Surg Endosc* 2011; **25**: 3028-3033 [PMID: 21487876 DOI: 10.1007/s00464-011-1665-6]
- 141 **Sandler BJ**, Rumbaut R, Swain CP, Torres G, Morales L, Gonzales L, Schultz S, Talamini MA, Jacobsen GR, Horgan S. One-year human experience with a novel endoluminal, endoscopic gastric bypass sleeve for morbid obesity. *Surg Endosc* 2015; **29**: 3298-3303 [PMID: 25631114 DOI: 10.1007/s00464-015-4081-5]
- 142 **Fu XY**, Li Z, Zhang N, Yu HT, Wang SR, Liu JR. Effects of gastrointestinal motility on obesity. *Nutr Metab (Lond)* 2014; **11**: 3 [PMID: 24398016 DOI: 10.1186/1743-7075-11-3]
- 143 **Camilleri M**. Gastrointestinal hormones and regulation of gastric emptying. *Curr Opin Endocrinol Diabetes Obes* 2019; **26**: 3-10 [PMID: 30418188 DOI: 10.1097/MED.0000000000000448]
- 144 **Jahnberg T**, Martinson J, Hultén L, Fasth S. Dynamic gastric response to expansion before and after vagotomy. *Scand J Gastroenterol* 1975; **10**: 593-598 [PMID: 1179152 DOI: 10.1080/00365521.1975.12097017]
- 145 **Kuiken SD**, Vergeer M, Heisterkamp SH, Tytgat GN, Boeckstaens GE. Role of nitric oxide in gastric motor and sensory functions in healthy subjects. *Gut* 2002; **51**: 212-218 [PMID: 12117882 DOI: 10.1136/gut.51.2.212]
- 146 **Adamska E**, Ostrowska L, Górka M, Krętkowski A. The role of gastrointestinal hormones in the pathogenesis of obesity and type 2 diabetes. *Prz Gastroenterol* 2014; **9**: 69-76 [PMID: 25061485 DOI: 10.5114/pg.2014.42498]
- 147 **Chaudhri O**, Small C, Bloom S. Gastrointestinal hormones regulating appetite. *Philos Trans R Soc Lond B Biol Sci* 2006; **361**: 1187-1209 [PMID: 16815798 DOI: 10.1098/rstb.2006.1856]

- 148 **Lean ME**, Malkova D. Altered gut and adipose tissue hormones in overweight and obese individuals: cause or consequence? *Int J Obes (Lond)* 2016; **40**: 622-632 [PMID: 26499438 DOI: 10.1038/ijo.2015.220]
- 149 **Wright RA**, Krinsky S, Fleeman C, Trujillo J, Teague E. Gastric emptying and obesity. *Gastroenterology* 1983; **84**: 747-751 [PMID: 6825986 DOI: 10.1016/0016-5085(83)90141-5]
- 150 **Dixon JB**, Eaton LL, Vincent V, Michaelson R. LAP-BAND for BMI 30-40: 5-year health outcomes from the multicenter pivotal study. *Int J Obes (Lond)* 2016; **40**: 291-298 [PMID: 26283140 DOI: 10.1038/ijo.2015.156]



Published by **Baishideng Publishing Group Inc**
7041 Koll Center Parkway, Suite 160, Pleasanton, CA 94566, USA

Telephone: +1-925-3991568

E-mail: bpgoffice@wjgnet.com

Help Desk: <https://www.f6publishing.com/helpdesk>

<https://www.wjgnet.com>

