

# World Journal of *Gastroenterology*

*World J Gastroenterol* 2023 October 28; 29(40): 5526-5617



## REVIEW

- 5526 Overview on the endoscopic treatment for obesity: A review

*Abdulla M, Mohammed N, AlQamish J*

## ORIGINAL ARTICLE

## Basic Study

- 5543 Roles of phosphatidylinositol-3-kinases signaling pathway in inflammation-related cancer: Impact of rs10889677 variant and buparlisib in colitis-associated cancer

*Razali NN, Raja Ali RA, Muhammad Nawawi KN, Yahaya A, Mohd Rathi ND, Mokhtar NM*

## Retrospective Study

- 5557 Endoscopic transgastric fenestration versus percutaneous drainage for management of (peri)pancreatic fluid collections adjacent to gastric wall (with video)

*Zhang HM, Ke HT, Ahmed MR, Li YJ, Nabi G, Li MH, Zhang JY, Liu D, Zhao LX, Liu BR*

- 5566 Clinical significance of programmed cell death-ligand expression in small bowel adenocarcinoma is determined by the tumor microenvironment

*Hoshimoto A, Tatsuguchi A, Hamakubo R, Nishimoto T, Omori J, Akimoto N, Tanaka S, Fujimori S, Hatori T, Shimizu A, Iwakiri K*

## Observational Study

- 5582 Expression characteristics of peripheral lymphocyte programmed death 1 and FoxP3<sup>+</sup> Tregs in gastric cancer during surgery and chemotherapy

*Li H, Cao GM, Gu GL, Li SY, Yan Y, Fu Z, Du XH*

## SCIENTOMETRICS

- 5593 Advances and key focus areas in gastric cancer immunotherapy: A comprehensive scientometric and clinical trial review (1999-2023)

*Li YN, Xie B, Zhang Y, He MH, Xing Y, Mu DM, Wang H, Guo R*

**ABOUT COVER**

Associate Editor of *World Journal of Gastroenterology*, Marc D Basson, MD, PhD, MBA, Professor, Departments of Surgery and Anatomy and Neurobiology, and Dean, College of Medicine, Northeast Ohio Medical University, Rootstown, OH 44272, United States. mbasson@neomed.edu

**AIMS AND SCOPE**

The primary aim of *World Journal of Gastroenterology* (WJG, *World J Gastroenterol*) is to provide scholars and readers from various fields of gastroenterology and hepatology with a platform to publish high-quality basic and clinical research articles and communicate their research findings online. WJG mainly publishes articles reporting research results and findings obtained in the field of gastroenterology and hepatology and covering a wide range of topics including gastroenterology, hepatology, gastrointestinal endoscopy, gastrointestinal surgery, gastrointestinal oncology, and pediatric gastroenterology.

**INDEXING/ABSTRACTING**

The WJG is now abstracted and indexed in Science Citation Index Expanded (SCIE), MEDLINE, PubMed, PubMed Central, Scopus, Reference Citation Analysis, China Science and Technology Journal Database, and Superstar Journals Database. The 2023 edition of Journal Citation Reports® cites the 2022 impact factor (IF) for WJG as 4.3; Quartile category: Q2. The WJG's CiteScore for 2021 is 8.3.

**RESPONSIBLE EDITORS FOR THIS ISSUE**

Production Editor: *Yu-Xi Chen*; Production Department Director: *Xu Guo*; Editorial Office Director: *Jia-Ru Fan*.

**NAME OF JOURNAL**

*World Journal of Gastroenterology*

**ISSN**

ISSN 1007-9327 (print) ISSN 2219-2840 (online)

**LAUNCH DATE**

October 1, 1995

**FREQUENCY**

Weekly

**EDITORS-IN-CHIEF**

Andrzej S Tarnawski

**EXECUTIVE ASSOCIATE EDITORS-IN-CHIEF**

Xian-Jun Yu (Pancreatic Oncology), Jian-Gao Fan (Chronic Liver Disease), Hou-Bao Liu (Biliary Tract Disease), Naohisa Yoshida (Gastrointestinal Endoscopy)

**EDITORIAL BOARD MEMBERS**

<http://www.wjgnet.com/1007-9327/editorialboard.htm>

**PUBLICATION DATE**

October 28, 2023

**COPYRIGHT**

© 2023 Baishideng Publishing Group Inc

**PUBLISHING PARTNER**

Shanghai Pancreatic Cancer Institute and Pancreatic Cancer Institute, Fudan University  
Biliary Tract Disease Institute, Fudan University

**INSTRUCTIONS TO AUTHORS**

<https://www.wjgnet.com/bpg/gerinfo/204>

**GUIDELINES FOR ETHICS DOCUMENTS**

<https://www.wjgnet.com/bpg/GerInfo/287>

**GUIDELINES FOR NON-NATIVE SPEAKERS OF ENGLISH**

<https://www.wjgnet.com/bpg/gerinfo/240>

**PUBLICATION ETHICS**

<https://www.wjgnet.com/bpg/GerInfo/288>

**PUBLICATION MISCONDUCT**

<https://www.wjgnet.com/bpg/gerinfo/208>

**POLICY OF CO-AUTHORS**

<https://www.wjgnet.com/bpg/GerInfo/310>

**ARTICLE PROCESSING CHARGE**

<https://www.wjgnet.com/bpg/gerinfo/242>

**STEPS FOR SUBMITTING MANUSCRIPTS**

<https://www.wjgnet.com/bpg/GerInfo/239>

**ONLINE SUBMISSION**

<https://www.f6publishing.com>

**PUBLISHING PARTNER'S OFFICIAL WEBSITE**

<https://www.shca.org.cn>  
<https://www.zs-hospital.sh.cn>



## Retrospective Study

# Endoscopic transgastric fenestration versus percutaneous drainage for management of (peri)pancreatic fluid collections adjacent to gastric wall (with video)

Hong-Mei Zhang, Hui-Ting Ke, Md Robin Ahmed, Ya-Juan Li, Ghulam Nabi, Mu-Han Li, Ji-Yu Zhang, Dan Liu, Li-Xia Zhao, Bing-Rong Liu

**Specialty type:** Gastroenterology and hepatology

**Provenance and peer review:**

Unsolicited article; Externally peer reviewed.

**Peer-review model:** Single blind

**Peer-review report's scientific quality classification**

Grade A (Excellent): A  
Grade B (Very good): B, B  
Grade C (Good): 0  
Grade D (Fair): D  
Grade E (Poor): 0

**P-Reviewer:** Kitamura K, Japan; Shelat VG, Singapore; Thandassery RB, United States; Sharma S, India

**Received:** July 24, 2023

**Peer-review started:** July 24, 2023

**First decision:** September 18, 2023

**Revised:** October 1, 2023

**Accepted:** October 23, 2023

**Article in press:** October 23, 2023

**Published online:** October 28, 2023



**Hong-Mei Zhang, Md Robin Ahmed, Ya-Juan Li, Mu-Han Li, Ji-Yu Zhang, Dan Liu, Li-Xia Zhao, Bing-Rong Liu,** Department of Gastroenterology and Hepatology, The First Affiliated Hospital of Zhengzhou University, Zhengzhou 450000, Henan Province, China

**Hui-Ting Ke,** Department of Ultrasound, Ezhou Central Hospital, Ezhou 436099, Hubei Province, China

**Ghulam Nabi,** Institute of Nature Conservation, Polish Academy of Sciences, Krakow 31120, Poland

**Bing-Rong Liu,** State Key Laboratory of Esophageal Cancer Prevention and Treatment, Zhengzhou University, Zhengzhou 450052, Henan Province, China

**Corresponding author:** Bing-Rong Liu, PhD, Chief Physician, Department of Gastroenterology and Hepatology, The First Affiliated Hospital of Zhengzhou University, No. 1 Eastern Jianshe Road, Zhengzhou 450000, Henan Province, China. [fccliubr@zzu.edu.cn](mailto:fccliubr@zzu.edu.cn)

## Abstract

### BACKGROUND

Percutaneous drainage (PCD) and endoscopic approaches have largely replaced surgical drainage as the initial approach for (peri) pancreatic fluid collections (PFC)s, while complications associated with endoscopic stent implantation are common.

### AIM

To introduce a novel endoscopic therapy named endoscopic transgastric fenestration (ETGF), which involves resection of tissue by endoscopic accessory between gastric and PFCs without stent implantation, and to evaluate its efficacy and safety compared with PCD for the management of PFCs adjacent to the gastric wall.

### METHODS

Patients diagnosed with PFCs adjacent to the gastric wall and who subsequently received ETGF or PCD were retrospectively enrolled. Indications for intervention were consistent with related guidelines. We analyzed patients baseline character-



istics, technical and clinical success rate, recurrence and reintervention rate, procedure-related complications and adverse events.

## RESULTS

Seventy-two eligible patients were retrospectively identified (ETGF = 34, PCD = 38) from October 2017 to May 2021. Patients in the ETGF group had a significantly higher clinical success rate than those in the PCD group (97.1 vs 76.3%,  $P = 0.01$ ). There were no statistically significant differences regarding recurrence, reintervention and incidence of complication between the two groups. While long-term catheter drainage was very common in the PCD group.

## CONCLUSION

Compared with PCD, ETGF has a higher clinical success rate in the management of PFCs adjacent to the gastric wall. ETGF is an alternative effective strategy for the treatment of PFCs adjacent to the gastric wall.

**Key Words:** (Peri) Pancreatic fluid collections; Endoscopic transgastric fenestration; Percutaneous drainage

©The Author(s) 2023. Published by Baishideng Publishing Group Inc. All rights reserved.

**Core Tip:** Inspired by endoscopic full-thickness resection, we proposed the concept of endoscopic transgastric fenestration (ETGF), which involves resection of connect tissue between the gastric wall and (peri) pancreatic fluid collections (PFCs) with the assistance of endoscopic accessory to treat PFCs secondary to pancreatitis adjacent to the gastric wall, avoiding the stent implantation. In the current study, we evaluate the efficacy and safety of ETGF by comparing with percutaneous drainage for the management of PFCs adjacent to the gastric wall.

**Citation:** Zhang HM, Ke HT, Ahmed MR, Li YJ, Nabi G, Li MH, Zhang JY, Liu D, Zhao LX, Liu BR. Endoscopic transgastric fenestration versus percutaneous drainage for management of (peri)pancreatic fluid collections adjacent to gastric wall (with video). *World J Gastroenterol* 2023; 29(40): 5557-5565

**URL:** <https://www.wjgnet.com/1007-9327/full/v29/i40/5557.htm>

**DOI:** <https://dx.doi.org/10.3748/wjg.v29.i40.5557>

## INTRODUCTION

Pancreatic and peripancreatic fluid collections (PFCs) are causes of fluid leakage or liquefaction of pancreatic necrosis following acute pancreatitis, chronic pancreatitis, surgery or abdominal trauma[1]. Collections usually forms 4 wk after the onset of acute pancreatitis and the majority resolve spontaneously[1]. Indications to intervene PFCs include infection and symptomatic sterile necrosis, while persistent collections that are asymptomatic may be observed[1-3]. Percutaneous drainage (PCD) and an endoscopic approach with stent implantation have replaced surgical drainage as the initial treatment for PFCs which reduce the complications and costs of hospitalization[3-7]. The European Society of Gastrointestinal Endoscopy recommends endoscopy or PCD as the first interventional method for PFCs[8]. PCD is an attractive and conventional approach that appears to be safe and the least invasive. However, inability to remove necrotic debris in the cavity has restricted its use[5,6,9]. Commonly, transluminal endoscopic drainage with stent implantation is an effective method[4,7]. However, embedding, displacement, and bleeding related to stent implantation are common complications, which leads to multi-interventions, and hence resulting in additional cost[10-12]. In addition, application of stent has been limited due to its high cost and is not commercial in some tertiary hospitals in China. Inspired by endoscopic full-thickness resection (EFTR), Liu *et al*[13] first conducted endoscopic transgastric fenestration (ETGF), an innovative endoscopic treatment avoiding the implantation of a stent to manage PFCs. ETGF involves endoscopic resection of connected tissues between gastric and pancreatic lesions with the assistance of endoscopic accessory, which can drain the collection of fluid in the cavity and debride the necrotic debris inside. In this retrospective study, the primary objective was to assess the availability of ETGF by comparing the rate of technical and clinical success, recurrence and reintervention with patients who received PCD. The secondary objective was to assess its safety by evaluating complications related to the procedure.

## MATERIALS AND METHODS

### Patient enrollment

Patients diagnosed with PFCs at the First Affiliated Hospital of Zhengzhou University between October 2017 and May 2021 were enrolled in this study. Inclusion criteria included patients diagnosed with PFCs that was adjacent to the gastric wall and who subsequently received ETGF or PCD. Indications to intervene PFCs were consistent with related guidelines

[1,8]. Patients with incomplete clinical data and who were lost to follow-up were excluded. All patients underwent ultrasonography (USG), computed tomography (CT) scan or magnetic resonance cholangiopancreatography to evaluate the lesion prior to the procedure. Patients in the ETGF group underwent endoscopy at least twice to observe the absorption of the cavity and the natural healing of the artificial fistula between the gastric wall and the cavity, the majority of which almost healed within 1 mo. CT or USG was reviewed within 6 mo after treatment. The study was approved by the institutional ethics committee and all patients were provided written informed consent to undergo the procedures (KY-2021-00642).

### Definitions

PFCs were defined according to the revised Atlanta consensus related to acute pancreatitis[1]. Technical success was defined as the ability to access the lesion. Clinical success was defined as symptom relief with PFCs reduced to < 2 cm within 6 mo without another alternative drainage procedure.

### ETGF technique

Endoscopic drainages were performed under general anesthesia with endotracheal intubation as follows: (1) Endoscopic ultrasonography (EUS) was used to determine the lesion location, whether a large vessel was hidden in the operative region and marked the site of fenestration using a Hook knife (KD-620LR, Olympus); (2) then the mucosal layer of the fenestration site was then removed with an endoscopic snare and full-thickness incision was subsequently made with the Hook knife, fluid in the collection was seen to pour out spontaneously; (3) re-evaluation of the fistula between the stomach and cavity; (4) the gastric-collections incision was enlarged to a diameter of approximately 2 cm to facilitate the operation and drainage by EFTR; (5) coagulating styptic forcep was used for hemostasis (Coagrasper, FD-410LR; Olympus); (6) the endoscope was advanced into the collection, and the content of the PFCs was further cleaned with saline rinse and vacuum suction, debris was removed by snare assistance, and (7) nasocystic tube (18 Fr) was indwelled if necessary (large or complicated with infection) and endoscopy was undertaken twice to observe the healing of the artificial fistula, most of which closed within one month (Figures 1 and 2, Video).

### PCD technique

Under local anesthesia using lignocaine, an 18-gauge needle was placed into the PFCs percutaneously with the guidance of USG or CT scan and the fluid was aspirated. A guidewire was then advanced into the collection. The tract was dilated and then a pigtail catheter of 8 or 10 Fr was inserted into the lesion. The catheter was replaced when the drainage tube failed due to obstruction and eventually removed when the collections was < 2 cm in length.

### Statistical analysis

Statistical analysis was performed using SPSS Statistics v26.0. For continuous variables, the mean  $\pm$  SD was used to describe data that fitted a normal distribution and quartiles were used for data that did not conform to normal distribution. Statistical significance was analyzed by the t-test and nonparametric test respectively. Counting card information was described by percentage and performed by the chi-square test.  $P < 0.05$  was considered statistically significant.

## RESULTS

Between October 2017 and May 2021, a total of 72 patients were enrolled in this study (ETGF = 34, PCD = 38, Figure 3). There were no statistically differences regarding sex and size of the lesion between the two groups. Patients in the ETGF group were younger than in PCD group ( $36.8 \pm 12.9$  years *vs*  $46.0 \pm 16.8$  years,  $P = 0.01$ ). The clinical success rate in the ETGF group was significantly higher than that in the PCD group (97.1 *vs* 76.3%,  $P = 0.01$ ). There were no statistically significant differences regarding recurrence and reintervention between the two groups. Although the complication rate was similar in the two groups, catheter related adverse events were common in the PCD group (2.9 *vs* 34.3 %,  $P = 0.001$ ). Patients were followed up by the electronic medical record system combined with telephone consultation for a median follow-up of 35 wk (9-85 wk). There was no procedure related mortality in either groups. The largest lesion was encountered in the endoscopic group with a length of 220 mm. Baseline characteristics and patient demographics are shown in Table 1. Primary and secondary outcomes are shown in Table 2.

### ETGF approach

Six of 34 patients had previous therapeutic history in another hospital: one received ETGF, one received surgical treatment, and the other four received PCD. The average age of the participants was  $36.8 \pm 12.9$  years old. The mean length of PFCs was  $109.4 \pm 7.8$  mm. The average total interventions were 1.03 sessions. The total duration of hospital stays and total cost was 14.5 d and 4852 \$ respectively. Clinical success was achieved in 33 patients (97.1%). One recurrence was observed in this group. With regard to reintervention, 9 cases received a second therapeutic endoscopy for infection in the cavity, and another patient transferred to PCD as a result of inadequate drainage due to small caliber of the fenestration. Procedure related bleeding occurred in 4 patients (11.76%) and was resolved by endoscopy. An nasocystic tube was inserted in seven patients for pus or necrosis collection, and the mean duration of the indwelling nasocystic tube was 8.6 d.

**Table 1** Baseline characteristics

|  | ETGF (%)     | PCD (%)           | P value |
|--|--------------|-------------------|---------|
| Total                                    | 34           | 38                |         |
| Male                                     | 24 (70.6)    | 26 (68.4)         | 0.84    |
| Mean age                                 | 36.8 ± 12.9  | 46.0 ± 16.8       | 0.01    |
| Mean length of lesions (mm)              | 109.4 ± 7.8  | 94.8 (80.8-133.2) | 0.89    |
| Cause of pancreatitis                    |              |                   |         |
| Hyperlipidemia                           | 10 (29.4)    | 8 (21.1)          |         |
| Gallstone                                | 8 (23.5)     | 8 (21.1)          |         |
| Alcohol                                  | 9 (26.5)     | 6 (15.8)          |         |
| Trauma                                   | 1 (2.9)      | 4 (10.5)          |         |
| Autoimmunity                             | 1 (2.9)      | 3 (7.9)           |         |
| Pancreatic duct stones                   | 3 (8.8)      |                   |         |
| Choledochocyst                           |              | 1 (2.6)           |         |
| Idiopathic                               | 1 (2.9)      | 8 (21.1)          |         |
| Clinical symptoms <sup>1</sup>           |              |                   |         |
| Abdominal pain (%)                       | 24 (70.6)    | 27 (71.1)         |         |
| Abdominal distention (%)                 | 6 (17.65)    | 5 (13.2)          |         |
| Nausea or vomiting                       | 5            | 3                 |         |
| Fever                                    | 6            | 1                 |         |
| Asymptomatic                             | 1            | 2                 |         |
| Preintervention                          | 6            | 4                 |         |
| PCD                                      | 4            | 3                 |         |
| ETGF                                     | 1            |                   |         |
| Surgery                                  | 1            | 1                 |         |
| Opportunity of intervention <sup>2</sup> |              |                   | 0.381   |
| < 4 wk                                   | 7            | 13                |         |
| > 4 wk                                   | 21           | 24                |         |
| Total interventions                      | 1.03 ± 0.03  | 1.32 ± 0.09       | 0.003   |
| Total hospital visits                    | 1.0 (0)      | 1.0 (1.0)         | 0.278   |
| Total hospital stays(days)               | 14.5 (10.25) | 19.0 (20.5)       | 0.177   |
| Total cost (\$)                          | 4852 (3877)  | 5206 (8377)       | 0.955   |

<sup>1</sup>Multiple symptoms may coexist in one patient, so we didn't calculate percentages of each item.

<sup>2</sup>Here, we excluded patients that preintervention was inconsistent with original treatment in our hospital.

ETGF: Endoscopic transgastric fenestration; PCD: Percutaneous drainage.

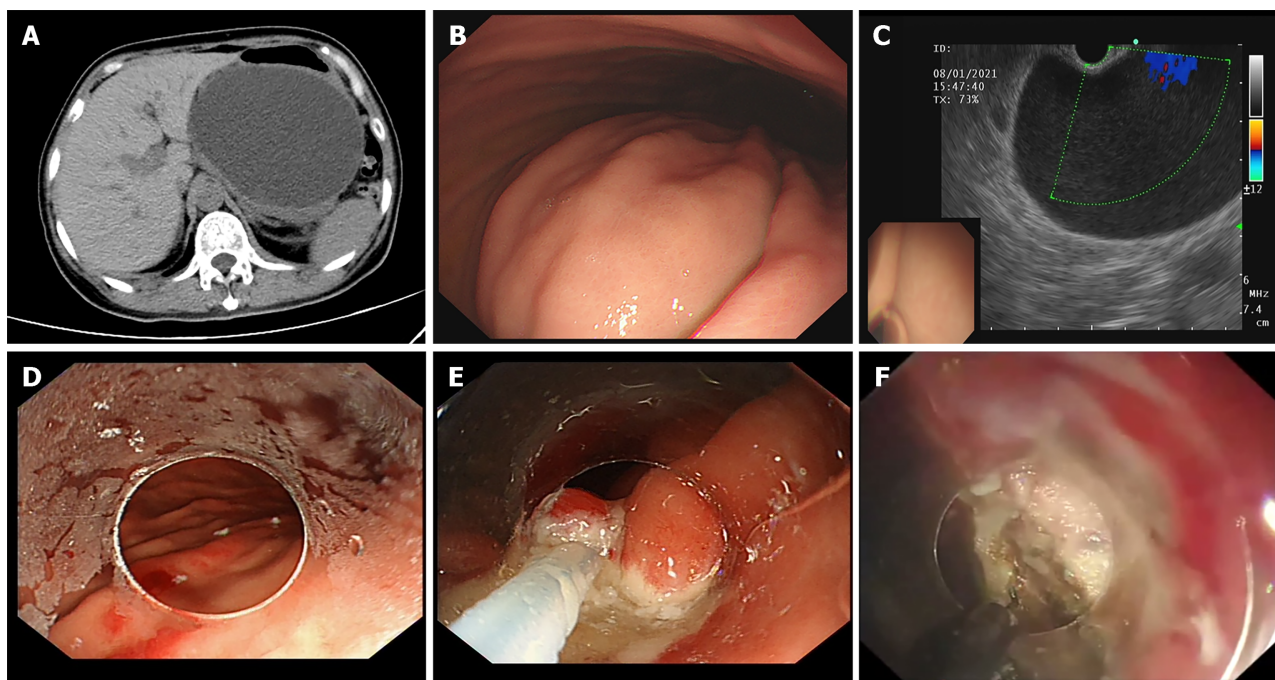
### PCD approach

Four of 38 patients received preintervention but failed, which included one open surgery and 3 cases of PCD. The average age of the participants was 46.0 ± 16.8 years old with more male patients than female patients (26 *vs* 12). Approximately three quarters of patients suffered from abdominal pain (27/38). The average length of PFCs was 94.8 mm (80.8-133.2 mm). Hyperlipidemia, gallstones, and alcohol-related pancreatitis were the etiologies in 57.9% of patients (22/38). The average total interventions was 1.32 sessions. The total duration of hospital stays and total cost was 19 days and 5206 \$ respectively. Clinical success was achieved in 29 patients (76.3%). Four patients showed recurrence (10.5%) and reintervention occurred in 17 of 38 patients (44.7%). With regard to adverse events, two patients developed bleeding which stopped spontaneously, two had local infection, and one had drainage adhesion to surrounding tissue. In 11 patients, the duration of catheterization was more than 8 wk. Drainage obstruction was encountered in 5 cases.

**Table 2 Endoscopic transgastric fenestration vs percutaneous drainage for management of (peri) pancreatics, *n* (%)**

|                                 | ETGF                     | PCD                                     | <i>P</i> value |
|---------------------------------|--------------------------|---|----------------|
| Technical success               | 34 (100)                 | 38 (100)                                |                |
| Clinical success                | 33/34 (97.1)             | 29/38 (76.3)                            | 0.01           |
| Recurrence                      | 1/34 (2.94)              | 4/38 (10.5)                             | 0.42           |
| Reintervention                  | 10/34 (29.4)             | 17 <sup>1</sup> /38 (44.7)              | 0.18           |
| Complication                    |                          |   | 1.00           |
|                                 | Bleeding 4 (11.76)       | Bleeding 2 (5.26)                       |                |
|                                 |                          | Local infection 2 (5.26)                |                |
|                                 |                          | Adhesion to surrounding tissue 1 (2.63) |                |
| Catheter related adverse events |                          |   | 0.001          |
|                                 | Tube dislodgment 1 (2.9) | Intubation time > 8 wk 11 (28.9)        |                |
|                                 |                          | Drainage obstruction 5 (13.2)           |                |

<sup>1</sup>There were 8 patients who received a twice percutaneous drainage (PCD) and another 3 required no less than three times of PCD, 2 transferred to endoscopic transgastric fenestration and 7 to surgery after PCD failure. ETGF: Endoscopic transgastric fenestration; PCD: Percutaneous drainage.



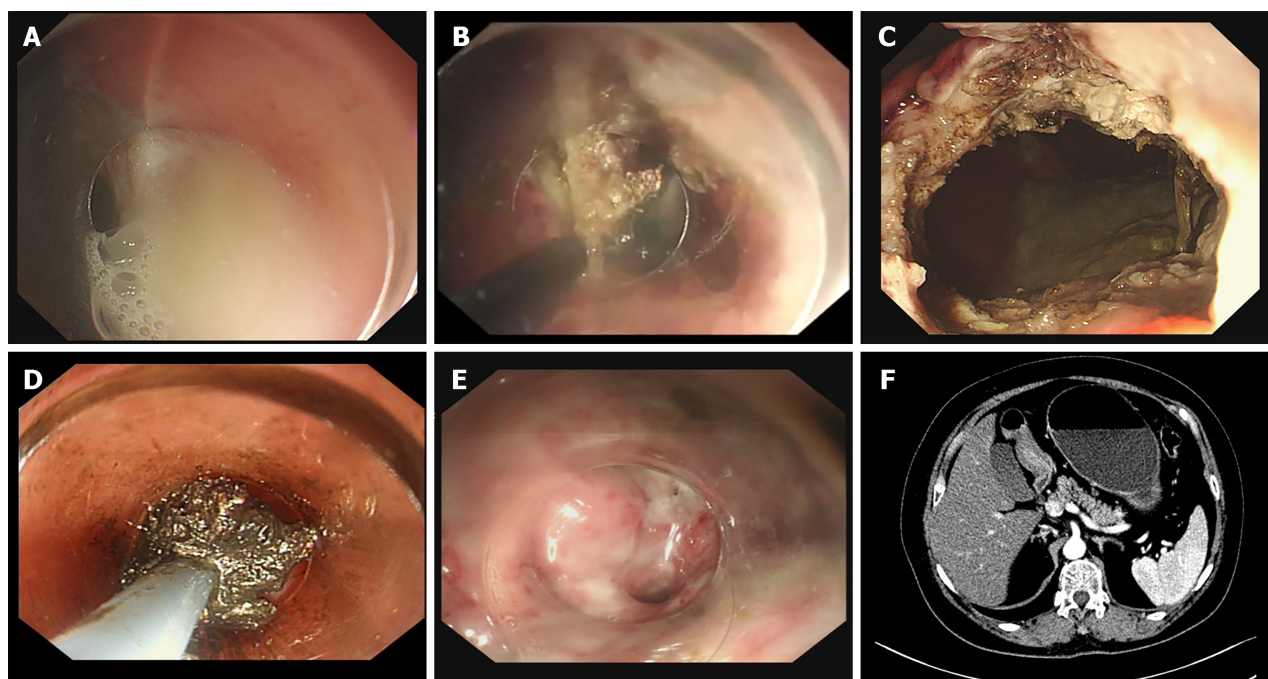
DOI: 10.3748/wjg.v29.i40.5557 Copyright ©The Author(s) 2023.

**Figure 1 Endoscopic transgastric fenestration: From location to endoscopic full-thickness resection.** A: Preoperative computed tomography scan of (peri) pancreatic collections; B: Gastric bulge caused by (peri) pancreatic collections under upper endoscope view; C: Assessment of fenestration site under endoscopic ultrasound; D: Marked the mucous layer; E: Resect the mucosal layer by endoscopic mucosal resection; F: Full-thickness incision was operated.

## DISCUSSION

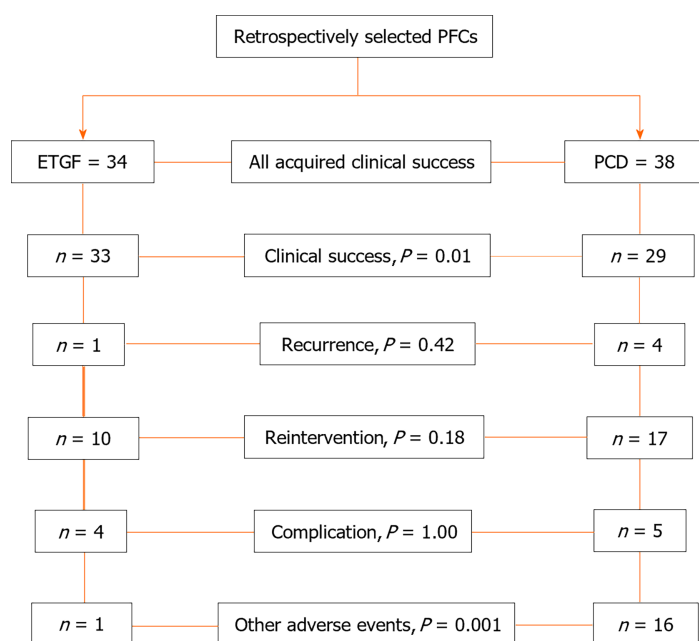
Surgical treatment has been traditionally used for PFCs[3]. Recently, PCD and endoscopic management have replaced surgery as the main treatment for PFCs due to their minimal invasiveness[6,8]. However, PCD cannot debride necrosis and an external drainage tube affects quality of life, which has limited its clinical use[5,14-16]. Endoscopic treatment can not only drainage the pus inside but also remove debris in the cavity and is beneficial to patient's health[5,6,14,17]. While previously endoscopic therapy involved stent implantation, embedding, displacement, and bleeding were inevitable[10-12]. Different to conventional endoscopic management, ETGF was conducted by means of ETFR to drain and debride PFCs adherent to the gastric wall, avoiding stent implantation.





DOI: 10.3748/wjg.v29.i40.5557 Copyright ©The Author(s) 2023.

**Figure 2 Endoscopic transgastric fenestration: Enlarge the aperture of opening and debridement.** A: Collections inflowing via the artificial fistula; B: Enlarged the aperture of opening with hook knife; C: The artificial fistula (about 2 cm in diameter) between the gastric wall and the cavity was made; D: Debridement of necrotic tissue under endoscopic direct vision; E: Endoscopic review of the fistula showed fistula almost healed one months later; F: The reviewed computed tomography scan one month after endoscopic transgastric fenestration.



DOI: 10.3748/wjg.v29.i40.5557 Copyright ©The Author(s) 2023.

**Figure 3 Flow-chart for this retrospective study.** ETGF: Endoscopic transgastric fenestration; PFCs: (peri) Pancreatic collections; PCD: Percutaneous drainage.

Our findings are basically consistent with previous studies on conventional endoscopic drainage which actually involves plastic or metal stent implantation and the PCD approach[16,18-20]. A respective study from the United States reported that the technical and clinical success rate of EUS-guided drainage of PFCs was 100% and 97% respectively[18]. Similarly, ETGF had a relatively favorable effect with 100% technical success and 97.1% clinical success. Jianhua *et al* performed a comparative study on drainage of PFCs and initial clinical success was considerably higher in patients who received transluminal endoscopic drainage than those in the PCD group (94.9% *vs* 65.0%)[20]. In our study, the clinical success rate in the PCD group was 65.8% which was also lower than that in the ETGF group.

PCD was associated with a high rate of reintervention and the endoscopic stent implantation approach was shown to significantly reduce the rate of retreatment, which resulted in short hospital stay, low cost and a reduced number of follow-up abdominal imaging studies[9,15]. In the present study, the total cost and reintervention rate following ETGF was lower than that in PCD, but was not statistically significantly different.

Keane *et al*[15] agreed that there was no difference between PCD and transluminal endoscopic drainage of PFCs in terms of recurrence. In another study, endoscopic drainage with stent implantation was an effective and appropriate method with the advantage of fewer recurrences compared to PCD[19]. In the present study, we found that there was no difference in the recurrence rate between two groups. In a long-term follow up study about PFCs, the recurrence of transluminal endoscopic drainage reported by Nabi *et al* was 6.7%[11]. In this study, one recurrence was encountered in ETGF group (2.94%).

The procedural adverse events rate was high in the PCD group compared with the transluminal endoscopic drainage with stent implantation group[20]. In the current study, the rate of complications in the ETGF group was similar with that in the PCD. Bleeding was encountered in ETGF patients and was managed by conservative treatment totally, which was consistent with previous studies[21].

Research by Storm *et al*[18] on endoscopic drainage of PFCs discovered that size of collections > 100 mm was correlated with an increased risk of adverse events. The size of PFCs was an independent risk factor for infection related to the cavity, and large PFCs with a diameter > 150 mm were more likely to become infected[22]. In the present study, seven patients had nasocystic tube implanted due to pus and necrosis in the cavity, of which 3 lesions were more than 150 mm and another 3 lesions were > 100 mm. A study on ETGF found that there were 3 of 5 patients received a nasocystic tube and the mean catheterization time was 10 d, which was longer than that in our study (8.6 d)[23]. We also recommended an indwelling nasocystic tube for large lesion or lesions combined with infection.

A previous study reported that the average length of time the drainage catheter in place was as long as 44.5 d in PCD [14]. Similarly, in our study, there were 28.9% of patients (11/38) whose underwent drainage for more than 8 wk. In addition, drainage obstruction occurred in 5 patients due to pus or necrosis, all of which led to further discomfort. Furthermore, an external catheter requires long-term care, as well as reminding the patient of their underlying disease state, and results in significant patient discomfort and compromised the quality of life[14]. During ETGF we used a natural orifice as the access route, avoiding an external catheter and scarring, which was beneficial to mental health and improved quality of life.

The limitations of this study were as follows. Firstly, we didn't examine how different types of PFCs affected the therapeutic efficacy. Secondly, prognostic factors associated with postoperative infection (size of PFCs, the area of fenestration) were not been identified in ETGF. A quality of life scale was not used in this study, thus, how the two different methods affected the quality of life is not known. A large, prospective, multicenter study is necessary to confirm our results.

## CONCLUSION

Both PCD and ETGF can be used effectively for the treatment of PFCs, although ETGF is superior to PCD as it has a higher rate of clinical success and a lower rate of adverse events. ETGF is an innovative, effective, safe and scarless strategy for the management of PFCs adherent to the gastric wall. However, further studies especially clinical trials are needed before final recommendations are made.

## ARTICLE HIGHLIGHTS

### Research background

Percutaneous drainage (PCD) and endoscopic approaches with stent implantation have largely replaced surgical drainage as the initial approach for (peri) pancreatic fluid collections (PFCs). While stent implantation guided by endoscopic ultrasound has been mature and preferred treatment, but stent displacement, bleeding and embedding should not be neglected.

### Research motivation

Inspired by endoscopic full-thickness resection, we conducted endoscopic transgastric fenestration (ETGF), which involves resection of connected tissues between gastric wall and PFCs, so as to drain the collection of fluid in the cavity and debride the necrosis inside.

### Research objectives

The study aimed to evaluate the efficacy and safety of ETGF by accessing its success and complication rate compared with PCD.

### Research methods

This retrospective analysis enrolled patients diagnosed with PFCs adjacent to the gastric wall and subsequently received ETGF or PCD during 4 years, analyzed patients baseline characteristics, technical and clinical success rate, recurrence and

reintervention rate, procedure related complication and adverse events.

### Research results

Seventy-two eligible patients were retrospectively identified (ETGF = 34, PCD = 38). Patients in the ETGF group acquired significantly higher clinical success rate than that in PCD (97.1 *vs* 76.3%,  $P = 0.01$ ). There was no statistical difference about recurrence, reintervention and incidence of complication between the two groups.

### Research conclusions

ETGF would be an alternative effective and safe strategy for the treatment of PFCs adjacent to the gastric wall.

### Research perspectives

ETGF can drainage fluid inside and debride necrosis, which improves its clinical success. Therefore, in our opinion ETGF may be an alternative treatment for PFCs adjacent to gastric, especially for large lesions or lesions that associated with infection or necrosis.

---

## ACKNOWLEDGEMENTS

We express our gratitude to Professor Shi Niu, Department of Gastroenterology and Hepatology, Inner Mongolia People's Hospital, China, for his encouragement and assistance in preparing the audio and revising the manuscript.

---

## FOOTNOTES

**Co-first authors:** Hong-Mei Zhang and Hui-Ting Ke.

**Author contributions:** Zhang HM, Ke HT and Li YJ contributed to the design of the study, collected data and drafted the manuscript; Ke HT and Nabi G performed the data analysis; Ahmed MR, Liu D and Zhao LX conceived the work; Zhang JY and Li MH contributed to video clip of endoscopic transgastric fenestration; Liu BR revised the manuscript; All authors issued final approval for the version to be submitted. Here are the reasons for designating Zhang HM and Ke HT as co-first authors: During the period of the study, Ke HT was a postgraduate student of the First Affiliated Hospital of Zhengzhou University and fully participated in the study. Ke HT graduated one year ago and worked in Ezhou Central Hospital. Zhang HM and Ke HT proposed the concept of this study, searched relevant literature and then discussed the research design together, and finally determined the research idea. Before the paper was drafted, they collected the research data together, and carried out the collation, statistical analysis and later verification work. They worked together on the first draft. Zhang HM explained the data charts and graphs and Ke HT selected typical case pictures and illustrated them.

**Supported by** Zhongyuan Talent Program, No. ZYYCYU202012113; The Key R and D Program of Henan Province, No. 222102310038.

**Institutional review board statement:** This study was reviewed and approved by the Ethics Committee of the First Affiliated Hospital of Zhengzhou University.

**Informed consent statement:** All study participants or their legal guardian provided informed written consent regarding personal and medical data collection prior to study enrollment.

**Conflict-of-interest statement:** We have no financial relationships to disclose.

**Data sharing statement:** No additional data are available.

**Open-Access:** This article is an open-access article that was selected by an in-house editor and fully peer-reviewed by external reviewers. It is distributed in accordance with the Creative Commons Attribution NonCommercial (CC BY-NC 4.0) license, which permits others to distribute, remix, adapt, build upon this work non-commercially, and license their derivative works on different terms, provided the original work is properly cited and the use is non-commercial. See: <https://creativecommons.org/licenses/by-nc/4.0/>

**Country/Territory of origin:** China

**ORCID number:** Ghulam Nabi 0000-0001-5256-0083; Mu-Han Li 0000-0003-0064-8942; Ji-Yu Zhang 0000-0003-1919-4418; Dan Liu 0000-0001-8313-4343; Li-Xia Zhao 0000-0002-1114-9754; Bing-Rong Liu 0000-0001-6101-8675.

**S-Editor:** Qu XL

**L-Editor:** A

**P-Editor:** Chen YX

## REFERENCES

- 1 **Banks PA**, Bollen TL, Dervenis C, Gooszen HG, Johnson CD, Sarr MG, Tsiotos GG, Vege SS; Acute Pancreatitis Classification Working Group. Classification of acute pancreatitis--2012: revision of the Atlanta classification and definitions by international consensus. *Gut* 2013; **62**: 102-111 [PMID: [23100216](#) DOI: [10.1136/gutjnl-2012-302779](#)]
- 2 **Hines OJ**, Pandol SJ. Management of severe acute pancreatitis. *BMJ* 2019; **367**: l6227 [PMID: [31791953](#) DOI: [10.1136/bmj.l6227](#)]
- 3 **Saftoiu A**, Vilmann A, Vilmann P. Endoscopic ultrasound-guided drainage of pancreatic pseudocysts. *Endosc Ultrasound* 2015; **4**: 319-323 [PMID: [26643700](#) DOI: [10.4103/2303-9027.170424](#)]
- 4 **Singhal S**, Rotman SR, Gaidhane M, Kahaleh M. Pancreatic fluid collection drainage by endoscopic ultrasound: an update. *Clin Endosc* 2013; **46**: 506-514 [PMID: [24143313](#) DOI: [10.5946/ce.2013.46.5.506](#)]
- 5 **Kawakami H**, Itoi T, Sakamoto N. Endoscopic ultrasound-guided transluminal drainage for peripancreatic fluid collections: where are we now? *Gut Liver* 2014; **8**: 341-355 [PMID: [25071899](#) DOI: [10.5009/gnl.2014.8.4.341](#)]
- 6 **Baron TH**, DiMaio CJ, Wang AY, Morgan KA. American Gastroenterological Association Clinical Practice Update: Management of Pancreatic Necrosis. *Gastroenterology* 2020; **158**: 67-75.e1 [PMID: [31479658](#) DOI: [10.1053/j.gastro.2019.07.064](#)]
- 7 **Bang JY**, Arnoletti JP, Holt BA, Sutton B, Hasan MK, Navaneethan U, Feranec N, Wilcox CM, Tharian B, Hawes RH, Varadarajulu S. An Endoscopic Transluminal Approach, Compared With Minimally Invasive Surgery, Reduces Complications and Costs for Patients With Necrotizing Pancreatitis. *Gastroenterology* 2019; **156**: 1027-1040.e3 [PMID: [30452918](#) DOI: [10.1053/j.gastro.2018.11.031](#)]
- 8 **Arvanitakis M**, Dumonceau JM, Albert J, Badaoui A, Bali MA, Barthet M, Besselink M, Deviere J, Oliveira Ferreira A, Gyökeres T, Hritz I, Hucl T, Milashka M, Papanikolaou IS, Poley JW, Seewald S, Vanbiervliet G, van Lienden K, van Santvoort H, Voermans R, Delhaye M, van Hooff J. Endoscopic management of acute necrotizing pancreatitis: European Society of Gastrointestinal Endoscopy (ESGE) evidence-based multidisciplinary guidelines. *Endoscopy* 2018; **50**: 524-546 [PMID: [29631305](#) DOI: [10.1055/a-0588-5365](#)]
- 9 **Akshintala VS**, Saxena P, Zaheer A, Rana U, Hutfless SM, Lennon AM, Canto MI, Kalloo AN, Khashab MA, Singh VK. A comparative evaluation of outcomes of endoscopic versus percutaneous drainage for symptomatic pancreatic pseudocysts. *Gastrointest Endosc* 2014; **79**: 921-8 [PMID: [24315454](#) DOI: [10.1016/j.gie.2013.10.032](#)]
- 10 **Bang JY**, Navaneethan U, Hasan MK, Sutton B, Hawes R, Varadarajulu S. Non-superiority of lumen-apposing metal stents over plastic stents for drainage of walled-off necrosis in a randomised trial. *Gut* 2019; **68**: 1200-1209 [PMID: [29858393](#) DOI: [10.1136/gutjnl-2017-315335](#)]
- 11 **Nabi Z**, Lakhtakia S, Basha J, Chavan R, Gupta R, Ramchandani M, Kalapala R, Pal P, Darisetty S, Rao GV, Nageshwar Reddy D. Endoscopic drainage of pancreatic fluid collections: Long-term outcomes in children. *Dig Endosc* 2017; **29**: 790-797 [PMID: [28374894](#) DOI: [10.1111/den.12884](#)]
- 12 **Yang J**, Chen YI, Friedland S, Holmes I, Paiji C, Law R, Hosmer A, Stevens T, Matheus F, Pawa R, Mathur N, Sejjal D, Inamdar S, Berzin TM, DiMaio CJ, Gupta S, Yachimski PS, Anderloni A, Repici A, James T, Jamil LH, Ona M, Lo SK, Gaddam S, Dollhopf M, Alammari N, Shieh E, Bukhari M, Kumbhari V, Singh V, Brewer O, Sanaei O, Fayad L, Ngamruengphong S, Shin EJ, Baron TH, Khashab MA. Lumen-apposing stents versus plastic stents in the management of pancreatic pseudocysts: a large, comparative, international, multicenter study. *Endoscopy* 2019; **51**: 1035-1043 [PMID: [30536255](#) DOI: [10.1055/a-0759-1353](#)]
- 13 **Liu BR**, Song JT, Zhang XY. Video of the Month: Emergency Endoscopic Fenestration for Treatment of a Recurrence Pancreatic Pseudocyst. *Am J Gastroenterol* 2015; **110**: 644 [PMID: [25942297](#) DOI: [10.1038/ajg.2015.13](#)]
- 14 **Kwon YM**, Gerdes H, Schattner MA, Brown KT, Covey AM, Getrajdman GI, Solomon SB, D'Angelica MI, Jarnagin WR, Allen PJ, Dimaio CJ. Management of peripancreatic fluid collections following partial pancreatectomy: a comparison of percutaneous versus EUS-guided drainage. *Surg Endosc* 2013; **27**: 2422-2427 [PMID: [23361258](#) DOI: [10.1007/s00464-012-2752-z](#)]
- 15 **Keane MG**, Sze SF, Cieplik N, Murray S, Johnson GJ, Webster GJ, Thorburn D, Pereira SP. Endoscopic versus percutaneous drainage of symptomatic pancreatic fluid collections: a 14-year experience from a tertiary hepatobiliary centre. *Surg Endosc* 2016; **30**: 3730-3740 [PMID: [26675934](#) DOI: [10.1007/s00464-015-4668-x](#)]
- 16 **Fabbri C**, Luigiano C, Lisotti A, Cennamo V, Virgilio C, Caletti G, Fusaroli P. Endoscopic ultrasound-guided treatments: are we getting evidence based--a systematic review. *World J Gastroenterol* 2014; **20**: 8424-8448 [PMID: [25024600](#) DOI: [10.3748/wjg.v20.i26.8424](#)]
- 17 **Varadarajulu S**, Bang JY, Sutton BS, Trevino JM, Christein JD, Wilcox CM. Equal efficacy of endoscopic and surgical cystogastrostomy for pancreatic pseudocyst drainage in a randomized trial. *Gastroenterology* 2013; **145**: 583-90.e1 [PMID: [23732774](#) DOI: [10.1053/j.gastro.2013.05.046](#)]
- 18 **Storm AC**, Levy MJ, Kaura K, Abu Dayyeh BK, Cleary SP, Kendrick ML, Truty MJ, Vargas EJ, Topazian M, Chandrasekhara V. Acute and early EUS-guided transmural drainage of symptomatic postoperative fluid collections. *Gastrointest Endosc* 2020; **91**: 1085-1091.e1 [PMID: [31843369](#) DOI: [10.1016/j.gie.2019.11.045](#)]
- 19 **Xie LT**, Zhao QY, Gu JH, Ying HJ, Tian G, Jiang TA. Endoscopic Ultrasonography-Guided Versus Percutaneous Drainage for the Recurrent Pancreatic Fluid Collections. *Med Sci Monit* 2019; **25**: 5785-5794 [PMID: [31377748](#) DOI: [10.12659/MSM.915193](#)]
- 20 **Wan J**, Wu D, He W, Zhu Y, Zeng H, Liu P, Xia L, Lu N. Comparison of percutaneous vs endoscopic drainage in the management of pancreatic fluid collections: A prospective cohort study. *J Gastroenterol Hepatol* 2020; **35**: 2170-2175 [PMID: [32473080](#) DOI: [10.1111/jgh.15121](#)]
- 21 **Künzli HT**, Timmer R, Schwartz MP, Wittman BJ, Weusten BL, van Oijen MG, Siersema PD, Vleggaar FP. Endoscopic ultrasonography-guided drainage is an effective and relatively safe treatment for peripancreatic fluid collections in a cohort of 108 symptomatic patients. *Eur J Gastroenterol Hepatol* 2013; **25**: 958-963 [PMID: [23571613](#) DOI: [10.1097/MEG.0b013e3283612f03](#)]
- 22 **Guo J**, Feng L, Sun S, Ge N, Liu X, Wang S, Wang G, Sun B. Risk factors for infection after endoscopic ultrasonography-guided drainage of specific types of pancreatic and peripancreatic fluid collections (with video). *Surg Endosc* 2016; **30**: 3114-3120 [PMID: [26801793](#) DOI: [10.1007/s00464-015-4557-3](#)]
- 23 **Liu F**, Wu L, Wang XD, Xiao JG, Li W. Endoscopic gastric fenestration of debriding pancreatic walled-off necrosis: A pilot study. *World J Gastroenterol* 2020; **26**: 6431-6441 [PMID: [33244203](#) DOI: [10.3748/wjg.v26.i41.6431](#)]





Published by **Baishideng Publishing Group Inc**  
7041 Koll Center Parkway, Suite 160, Pleasanton, CA 94566, USA

**Telephone:** +1-925-3991568

**E-mail:** [bpgoffice@wjgnet.com](mailto:bpgoffice@wjgnet.com)

**Help Desk:** <https://www.f6publishing.com/helpdesk>

<https://www.wjgnet.com>

