

World Journal of *Gastroenterology*

World J Gastroenterol 2024 April 14; 30(14): 1934-2067



EDITORIAL

- 1934 Topic highlight on texture and color enhancement imaging in gastrointestinal diseases
Toyoshima O, Nishizawa T, Hata K
- 1941 Immune checkpoint inhibitor-associated gastritis: Patterns and management
Lin J, Lin ZQ, Zheng SC, Chen Y
- 1949 Liver biopsy in the post-hepatitis C virus era in Japan
Ikura Y, Okubo T, Sakai Y
- 1958 Current status of liver transplantation for human immunodeficiency virus-infected patients in mainland China
Tang JX, Zhao D
- 1963 Bowel function and inflammation: Is motility the other side of the coin?
Panarese A

REVIEW

- 1968 Necroptosis contributes to non-alcoholic fatty liver disease pathoetiology with promising diagnostic and therapeutic functions
Sun HJ, Jiao B, Wang Y, Zhang YH, Chen G, Wang ZX, Zhao H, Xie Q, Song XH

MINIREVIEWS

- 1982 Omics-based biomarkers as useful tools in metabolic dysfunction-associated steatotic liver disease clinical practice: How far are we?
Trinks J, Mascardi MF, Gadano A, Marciano S

ORIGINAL ARTICLE

Retrospective Study

- 1990 Characteristics of early gastric tumors with different differentiation and predictors of long-term outcomes after endoscopic submucosal dissection
Zhu HY, Wu J, Zhang YM, Li FL, Yang J, Qin B, Jiang J, Zhu N, Chen MY, Zou BC

Observational Study

- 2006 Preoperative albumin-bilirubin score and liver resection percentage determine postoperative liver regeneration after partial hepatectomy
Takahashi K, Gosho M, Miyazaki Y, Nakahashi H, Shimomura O, Furuya K, Doi M, Owada Y, Ogawa K, Ohara Y, Akashi Y, Enomoto T, Hashimoto S, Oda T

Basic Study

- 2018** *Fusobacterium nucleatum*-induced imbalance in microbiome-derived butyric acid levels promotes the occurrence and development of colorectal cancer
Wu QL, Fang XT, Wan XX, Ding QY, Zhang YJ, Ji L, Lou YL, Li X
- 2038** Comparative transcriptomic analysis reveals the molecular changes of acute pancreatitis in experimental models
Zheng P, Li XY, Yang XY, Wang H, Ding L, He C, Wan JH, Ke HJ, Lu NH, Li NS, Zhu Y

CASE REPORT

- 2059** Outcomes of endoscopic sclerotherapy for jejunal varices at the site of choledochojejunostomy (with video): Three case reports
Liu J, Wang P, Wang LM, Guo J, Zhong N

ABOUT COVER

Editorial Board Member of *World Journal of Gastroenterology*, Sandro Contini, MD, Former Associate Professor, Department of Surgical Sciences, University of Parma, Parma 43123, Italy. sandrocontini46@gmail.com

AIMS AND SCOPE

The primary aim of *World Journal of Gastroenterology* (WJG, *World J Gastroenterol*) is to provide scholars and readers from various fields of gastroenterology and hepatology with a platform to publish high-quality basic and clinical research articles and communicate their research findings online. WJG mainly publishes articles reporting research results and findings obtained in the field of gastroenterology and hepatology and covering a wide range of topics including gastroenterology, hepatology, gastrointestinal endoscopy, gastrointestinal surgery, gastrointestinal oncology, and pediatric gastroenterology.

INDEXING/ABSTRACTING

The WJG is now abstracted and indexed in Science Citation Index Expanded (SCIE), MEDLINE, PubMed, PubMed Central, Scopus, Reference Citation Analysis, China Science and Technology Journal Database, and Superstar Journals Database. The 2023 edition of Journal Citation Reports® cites the 2022 impact factor (IF) for WJG as 4.3; Quartile category: Q2. The WJG's CiteScore for 2021 is 8.3.

RESPONSIBLE EDITORS FOR THIS ISSUE

Production Editor: *Ying-Yi Yuan*, Production Department Director: *Xiang Li*, Cover Editor: *Jia-Ru Fan*.

NAME OF JOURNAL

World Journal of Gastroenterology

ISSN

ISSN 1007-9327 (print) ISSN 2219-2840 (online)

LAUNCH DATE

October 1, 1995

FREQUENCY

Weekly

EDITORS-IN-CHIEF

Andrzej S Tarnawski

EXECUTIVE ASSOCIATE EDITORS-IN-CHIEF

Xian-Jun Yu (Pancreatic Oncology), Jian-Gao Fan (Chronic Liver Disease), Hou-Bao Liu (Biliary Tract Disease)

EDITORIAL BOARD MEMBERS

<http://www.wjgnet.com/1007-9327/editorialboard.htm>

PUBLICATION DATE

April 14, 2024

COPYRIGHT

© 2024 Baishideng Publishing Group Inc

PUBLISHING PARTNER

Shanghai Pancreatic Cancer Institute and Pancreatic Cancer Institute, Fudan University
Biliary Tract Disease Institute, Fudan University

INSTRUCTIONS TO AUTHORS

<https://www.wjgnet.com/bpg/gerinfo/204>

GUIDELINES FOR ETHICS DOCUMENTS

<https://www.wjgnet.com/bpg/gerinfo/287>

GUIDELINES FOR NON-NATIVE SPEAKERS OF ENGLISH

<https://www.wjgnet.com/bpg/gerinfo/240>

PUBLICATION ETHICS

<https://www.wjgnet.com/bpg/gerinfo/288>

PUBLICATION MISCONDUCT

<https://www.wjgnet.com/bpg/gerinfo/208>

POLICY OF CO-AUTHORS

<https://www.wjgnet.com/bpg/gerinfo/310>

ARTICLE PROCESSING CHARGE

<https://www.wjgnet.com/bpg/gerinfo/242>

STEPS FOR SUBMITTING MANUSCRIPTS

<https://www.wjgnet.com/bpg/gerinfo/239>

ONLINE SUBMISSION

<https://www.f6publishing.com>

PUBLISHING PARTNER's OFFICIAL WEBSITE

<https://www.shca.org.cn>
<https://www.zs-hospital.sh.cn>



Outcomes of endoscopic sclerotherapy for jejunal varices at the site of choledochojejunostomy (with video): Three case reports

Jun Liu, Peng Wang, Li-Mei Wang, Jing Guo, Ning Zhong

Specialty type: Gastroenterology and hepatology

Provenance and peer review: Unsolicited article; Externally peer reviewed.

Peer-review model: Single blind

Peer-review report's scientific quality classification

Grade A (Excellent): 0
Grade B (Very good): B, B
Grade C (Good): 0
Grade D (Fair): 0
Grade E (Poor): 0

P-Reviewer: Salvadori M, Italy;
Yoshida H, Japan

Received: January 2, 2024

Peer-review started: January 2, 2024

First decision: January 30, 2024

Revised: February 9, 2024

Accepted: March 26, 2024

Article in press: March 26, 2024

Published online: April 14, 2024



Jun Liu, Peng Wang, Li-Mei Wang, Jing Guo, Ning Zhong, Department of Gastroenterology, Qilu Hospital of Shandong University, Jinan 250012, Shandong Province, China

Corresponding author: Ning Zhong, MD, PhD, Professor, Department of Gastroenterology, Qilu Hospital of Shandong University, No. 107 Wenhua West Road, Jinan 250012, Shandong Province, China. nathan.zhongning@foxmail.com

Abstract

BACKGROUND

Hemorrhage associated with varices at the site of choledochojejunostomy is an unusual, difficult to treat, and often fatal manifestation of portal hypertension. So far, no treatment guidelines have been established.

CASE SUMMARY

We reported three patients with jejunal varices at the site of choledochojejunostomy managed by endoscopic sclerotherapy with lauromacrogol/ α -butyl cyanoacrylate injection at our institution between June 2021 and August 2023. We reviewed all patient records, clinical presentation, endoscopic findings and treatment, outcomes and follow-up. Three patients who underwent pancreaticoduodenectomy with a Whipple anastomosis were examined using conventional upper gastrointestinal endoscopy for suspected hemorrhage from the afferent jejunal loop. Varices with stigmata of recent hemorrhage or active hemorrhage were observed around the choledochojejunostomy site in all three patients. Endoscopic injection of lauromacrogol/ α -butyl cyanoacrylate was carried out at jejunal varices for all three patients. The bleeding ceased and patency was observed for 26 and 2 months in two patients. In one patient with multiorgan failure and internal environment disturbance, rebleeding occurred 1 month after endoscopic sclerotherapy, and despite a second endoscopic sclerotherapy, repeated episodes of bleeding and multiorgan failure resulted in eventual death.

CONCLUSION

We conclude that endoscopic sclerotherapy with lauromacrogol/ α -butyl cyanoacrylate injection can be an easy, effective, safe and low-cost treatment option for jejunal varicose bleeding at the site of choledochojejunostomy.

Key Words: Endoscopic sclerotherapy; Jejunal varices; Choledochojejunostomy; Portal vein hypertension; Case report

Core Tip: This is the first series of case reports on endoscopic sclerotherapy for venous varices at the choledochojejunostomy, including videos. From the experiences of our center, endoscopic sclerotherapy with lauromacrogol/ α -butyl cyanoacrylate injection may be considered as an easy, cost-effective and efficient treatment option for hemorrhage from venous varices at the choledochojejunostomy site. For patients without complications, underlying diseases, and significant organ dysfunction, as well as those who have undergone pancreaticoduodenectomy for benign diseases, endoscopic sclerotherapy tends to have better outcomes.

Citation: Liu J, Wang P, Wang LM, Guo J, Zhong N. Outcomes of endoscopic sclerotherapy for jejunal varices at the site of choledochojejunostomy (with video): Three case reports. *World J Gastroenterol* 2024; 30(14): 2059-2067

URL: <https://www.wjgnet.com/1007-9327/full/v30/i14/2059.htm>

DOI: <https://dx.doi.org/10.3748/wjg.v30.i14.2059>

INTRODUCTION

The prevalence of gastrointestinal hemorrhage from ectopic varices is relatively low, ranging from 1% to 5% [1,2]. Bilioenteric anastomosis is an uncommonly affected site of ectopic variceal bleeding [3]. Hemorrhage associated with varices at the site of choledochojejunostomy is an unusual, difficult to treat, and often fatal manifestation of portal hypertension (PHT). The possible cause of hemorrhage from ruptured jejunal varices could be extrahepatic portal vein obstruction or stenosis at the site where choledochojejunostomy was previously carried out, which leads to the development of hepatopetal portal collaterals through the anastomosis and PHT [4,5].

Diagnosis of ectopic variceal hemorrhage at a bilioenteric anastomosis can be difficult because varices are located deep within the jejunal loop and factors such as postsurgical adhesions make early detection of the bleeding source more difficult [6]. Treatment of ectopic variceal hemorrhage at bilioenteric anastomoses can be challenging because of their hemodynamic complexity. So far, no treatment guidelines have been established, so it may require a multidisciplinary approach and depend on the patient's conditions [7]. There are two treatment choices: Portal decompression and obliteration of the varices [8-11]. Endoscopic sclerotherapy has been reported as a minimally invasive therapeutic method for jejunal varices [12-14].

We report three patients with jejunal varices at the site of choledochojejunostomy managed by endoscopic sclerotherapy with lauromacrogol/ α -butyl cyanoacrylate injection. We highlight the outcomes of endoscopic sclerotherapy for such rare causes of bleeding, and analyze the possible factors affecting treatment effectiveness.

CASE PRESENTATION

Chief complaints

Case 1: A 25-year-old woman was admitted to hospital because of hematemesis, melena and hematochezia for 1 wk (Table 1).

Case 2: A 55-year-old man was admitted to our hospital with hematochezia for 1 month and hematemesis for 12 d (Table 1).

Case 3: A 68-year-old man presented to our hospital with intermittent melena, dizziness and fatigue for 1 month (Table 1).

History of present illness

Case 1: Local laboratory tests showed a minimum hemoglobin level of 45 g/L, which necessitated blood transfusions for 8 months. The location of the bleeding could not be definitively identified by repeated gastroscopy and colonoscopy.

Case 2: Gastroscopy and angiography at the local hospital did not definitively identify the site of bleeding.

Case 3: Gastroscopy at the local hospital revealed esophageal and gastric varices, no signs of bleeding.

History of past illness

Case 1: The patient had undergone pancreaticoduodenectomy with a Whipple anastomosis for a solid pseudopapillary tumor of the pancreas 29 months prior to the current visit. Eighteen days after surgery, follow-up computed tomography (CT) revealed formation of thrombosis in the portal vein and superior mesenteric vein, and anticoagulation therapy was administered.

Table 1 The patients' basic information and clinical data

Patient No.	Age (yr)	Sex	Primary disease	Duration from operation to admission	Injection mixture composition	Pre-Clipping	Carvedilol intake	Rebleeding
1	25	Female	Solid pseudopapillary tumor of pancreas	29 months	Auromacrogol/ α -butyl cyanoacrylate (5.0/0.5 mL)	No	No	No
2	55	Male	Cholangio; carcinoma	14 months	Lauromacrogol/ α -butyl cyanoacrylate (12/1 mL)	Yes	No	Yes
3	68	Male	Cholangio; carcinoma	47 months	Lauromacrogol/ α -butyl cyanoacrylate (30/3 mL)	No	Yes	No

Case 2: He had undergone pancreaticoduodenectomy 14 months previously with a Whipple anastomosis for moderately to poorly differentiated adenocarcinoma of the bile duct. The portal vein and the right wall of the superior mesenteric vein were affected by tumor invasion and were partially resected during the operation.

Case 3: He had undergone pancreaticoduodenectomy with a Whipple-Braun anastomosis for moderately differentiated adenocarcinoma of the bile duct (pathological staging pT2N0) 47 months previously.

Personal and family history

All the three patients denied any family history of genetic disease and malignant tumours.

Physical examination

Case 1: The vital sign were as follows: Blood pressure, 104/72 mmHg; heart rate, 104 beats per min.

Case 2: On physical examination, the vital sign were as follows: Blood pressure, 121/63 mmHg; heart rate, 83 beats per min. Furthermore, anemic appearance and right abdominal tenderness were detected.

Case 3: On physical examination, the vital sign were as follows: Blood pressure, 121/74 mmHg; heart rate, 75 beats per min.

Laboratory examinations

Case 1: Hemoglobin: 77.0 g/L; white blood counts (WBC): 19.94×10^9 /L; platelet (PLT): 97×10^9 /L.

Case 2: After admission, laboratory assessments revealed that the patient had heart failure, kidney failure and severe internal environment disorder. Hemoglobin: 73.0 g/L; PLT: 98×10^9 /L; blood urea nitrogen: 42.70 mmol/L; serum creatinine: 367 μ mol/L; carbon dioxide combining power: 6.5 mmol/L; carbohydrate antigen 19-9: 42.85 U/mL.

Case 3: Hemoglobin: 84.0 g/L; WBC: 3.46×10^9 /L; PLT: 104×10^9 /L.

Imaging examinations

Case 1: After another episode of hematochezia, emergency gastroscopic examination the afferent loop revealed tortuous dilated blood vessels around the choledochojejunostomy site (Figure 1A), along with mucosal rupture (Figure 1B). Endoscopic ultrasonography confirmed the presence of numerous varicose veins near the choledochojejunostomy site, with abundant blood flow (Figure 1C).

Case 2: A nonenhanced abdominal CT scan revealed liver cirrhosis and PHT. With adequate adjustment of the internal environment and continuous renal replacement therapy, we performed emergency endoscopy on the afferent loop, which revealed a significant number of tortuous dilated varicose veins near the choledochojejunostomy site, along with several sites of active bleedings (Figure 1D).

Case 3: CT showed prehepatic PHT, suspicious tumor recurrence in the hepatic hilum area, and varices around the choledochojejunostomy site (Figure 1E). Gastroscopy and colonoscopy detected no particular bleeding point, and only detected nonbleeding signs of esophageal and gastric fundus varices. From these findings, his condition was suspected to be due to repeated rupturing of jejunal varices of the afferent loop, which had developed because of extrahepatic portal venous obstruction at the hepatic hilum area. Colonoscopy was undertaken to assess the possible varices around the choledochojejunostomy site at the afferent loop. There were three varicose veins visible with signs of erythema (Figure 1F) and thrombus head (Figure 1G), along with spontaneous bleeding (Figure 1H).

FINAL DIAGNOSIS

The final diagnosis of the three patients were jejunal varices at the site of choledochojejunostomy.

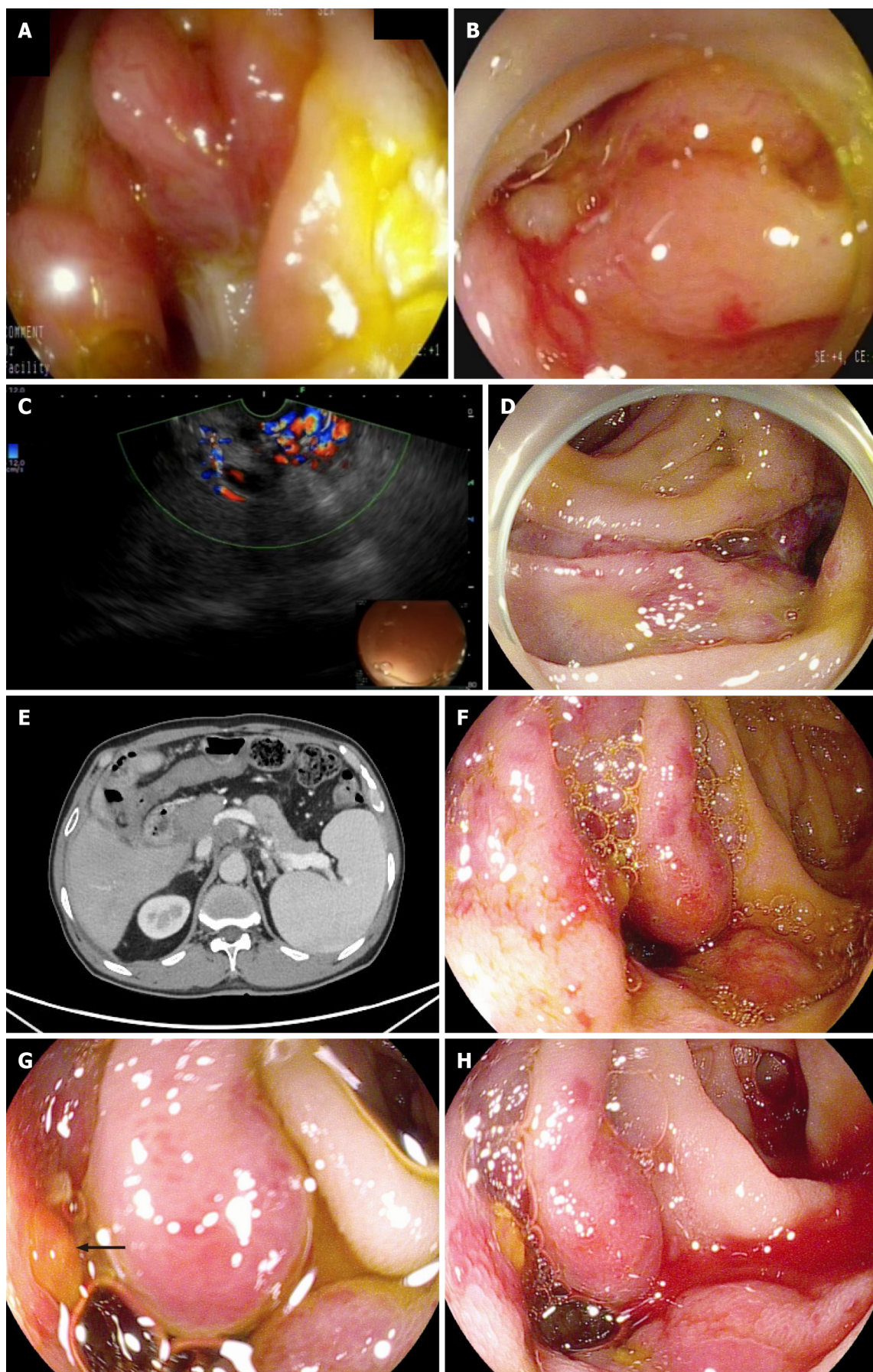


Figure 1 Emergency endoscopy confirmed the presence of numerous varicose veins before endoscopic sclerotherapy and was validated by endoscopic ultrasonography. A: Emergency gastroscopy revealed tortuous dilated blood vessels around the choledochojejunostomy site (Case 1); B: A

mucosal rupture was detected with spontaneous bleeding (Case 1); C: Endoscopic ultrasonography confirmed the presence of numerous varicose veins with abundant blood flow (Case 1); D: Emergency gastroscopy revealed a significant number of tortuous dilated varicose veins near the choledochojejunostomy site, along with several active bleedings. Hemostatic clips were used before endoscopic sclerotherapy (Case 2); E: Computed tomography showed prehepatic portal hypertension, suspicious tumor recurrence in the hepatic hilum area and the formation of varices around the choledochojejunostomy site (Case 3); F: Colonoscopy revealed three varicose veins visible with signs of erythema (Case 3); G: Thrombus head (arrow) was detected (Case 3); H: Spontaneous bleeding was observed at the site of varicose veins (Case 3).

TREATMENT

Case 1

Injection sclerotherapy with lauromacrogol/ α -butyl cyanoacrylate (5.0/0.5 mL) was carried out at the mucosal rupture (Figure 2A). Vascular angiography showed a patent portal vein and segmental occlusion of the superior mesenteric vein with old mural thrombus (arrow, Figure 2B). Therefore, balloon angioplasty of the superior mesenteric vein was not feasible. Considering the risk of bleeding, anticoagulant medication was not administered.

Case 2

Hemostatic clips were used to close off the bleeding points. Subsequently, combined injection of lauromacrogol/ α -butyl cyanoacrylate (12/1 mL) was administered to the varicose veins (Figure 2C).

Case 3

A sandwich method was used to inject a mixture of lauromacrogol/ α -butyl cyanoacrylate (30/3 mL) at multiple points for endoscopic sclerotherapy (Figure 2D and Video).

OUTCOME AND FOLLOW-UP

Case 1

Hemorrhage has remained stable for 27 months of follow-up.

Case 2

Rebleeding occurred 1 month after endoscopic sclerotherapy, and despite two further endoscopic sclerotherapy procedures, repeated episodes of bleeding and multi-organ failure resulted in eventual death.

Case 3

The patient developed moderate abdominal discomfort that disappeared within 2 d. He declined further examinations regarding tumor recurrence and was discharged with 6.25 mg carvedilol orally once daily after sclerotherapy to reduce portal vein pressure. One month later, the patient returned to the hospital for a follow-up examination. Enhanced CT revealed increased soft tissue density in the hepatic hilum, suggesting metastasis. There was also localized narrowing of the portal vein, with increased pressure on the right side of the narrowed segment. The peritoneum was thickened, and abdominal lymph nodes were enlarged (Figure 3A). The endoscopic follow-up revealed adhesive clumps and exudative ulcers near the choledochojejunostomy site, with no signs of bleeding (Figure 3B). The patient underwent endoscopic ultrasound-guided fine needle aspiration (EUS-FNA) of the hepatic hilum mass, which was confirmed to be high-grade intraepithelial neoplasia, suggesting metastasis. However, the patient declined portal vein stenting intervention and was subsequently discharged. Two months after undergoing endoscopic sclerotherapy, a follow-up call revealed the patient had no further gastrointestinal bleeding and continued to take carvedilol consistently.

DISCUSSION

Anastomotic jejunal varices are a rare and often easily ignored cause of bleeding from the gastrointestinal tract and are typically diagnosed in patients with portal vein hypertension due to cirrhotic or extrahepatic PHT[15,16]. In some patients who have previously undergone cholangiojejunostomy, portal vein hypertension may occur as a result of extrahepatic portal venous stenosis or obstruction, leading to the development of hepatopetal portal collaterals through the anastomosis in the afferent loop[17]. Extrahepatic portal venous stenosis or obstruction can result from thrombophlebitis of the portal or superior mesenteric vein associated with an infection, compression or invasion of the portal vein by benign and malignant tumor, radiation-induced portal vein stenosis, thrombosis caused by portal stasis associated with hepatic cirrhosis, or surgical adhesions[18,19]. The most likely causes in our patients were as follows. Case 1 was considered to have a long-segment occlusion in the superior mesenteric vein due to an obsolete thrombus associated with potential infection. Case 2 had a tumor invading the right wall of the portal vein and superior mesenteric vein, leading to an intraoperative vascular wall resection. In case 3, it was believed to have resulted from local stenosis of the portal vein caused by recurrence of a tumor at the hepatic portal region, leading to portal vein hypertension on the

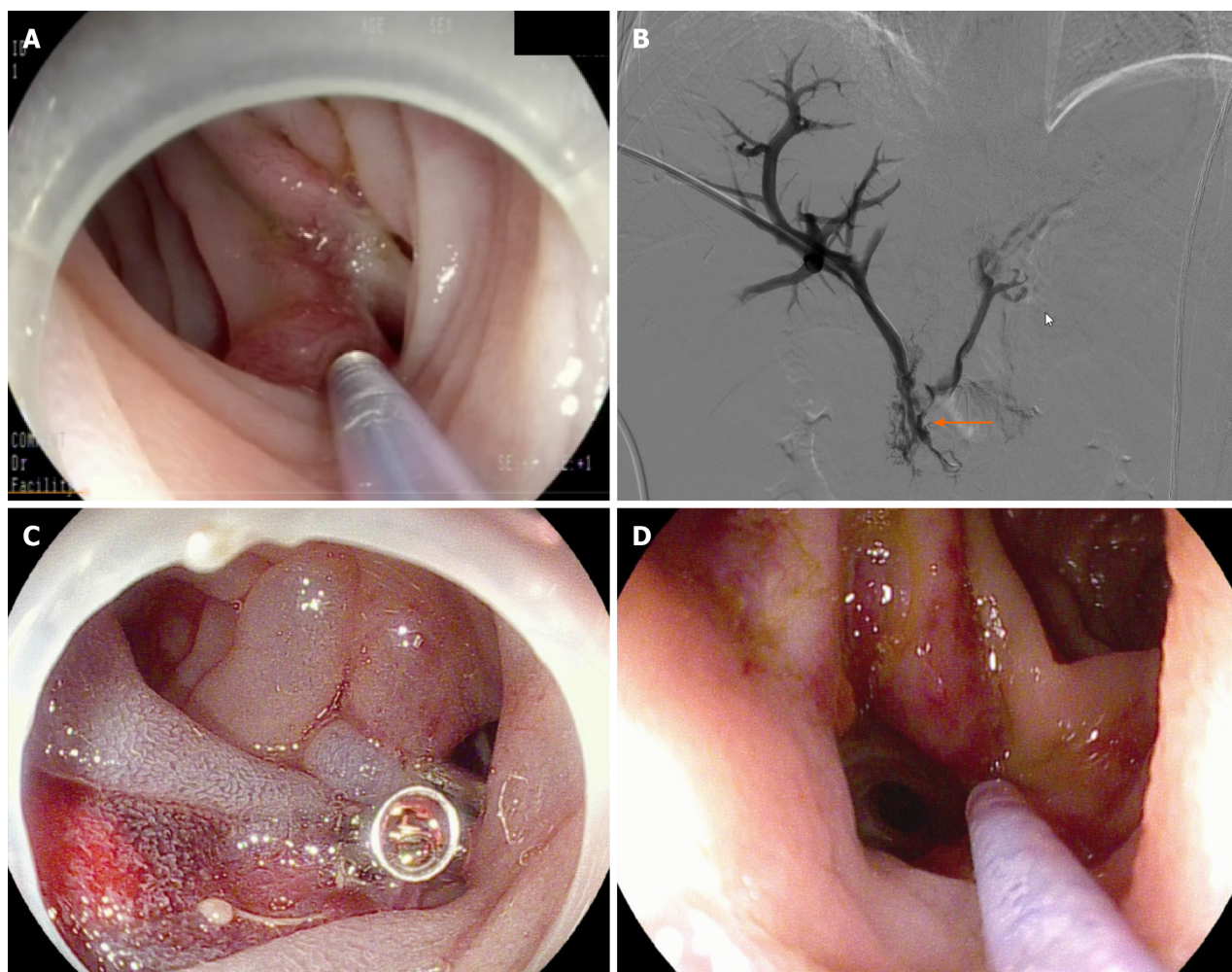


Figure 2 Hemostatic clips were used to close off the bleeding points. A: Injection sclerotherapy mixture of lauromacrogol/ α -butyl cyanoacrylate (5.0/0.5 mL) (Case 1); B: Vascular angiography showed a patent portal vein, but a segment occlusion of the superior mesenteric vein with old mural thrombus (arrow) (Case 1); C: A combined injection of lauromacrogol/ α -butyl cyanoacrylate (12/1 mL) was administered at the varicose veins (Case 2); D: Endoscopic sclerotherapy with lauromacrogol/ α -butyl cyanoacrylate (30/3 mL) injection for jejunal varices were carried out immediately (Case 3).

right side of the stenotic segment.

Although the number of long-term survival cases after cholangiojejunostomy has increased, only a few have so far been reported. Despite the low incidence, jejunal varices should be considered in the differential diagnosis of digestive bleeding in patients with a history of pancreaticoduodenectomy. Clinical features for variceal bleeding are similar to those of typical varices. Depending on the bleeding rate, venous varices at the site of cholangiojejunostomy can present with hematemesis, melena or hematochezia. Based on previous reports, venous varices at the site of cholangiojejunostomy can lead to hemorrhagic shock, often requiring multiple blood transfusions during the treatment process. All three patients we reported received multiple blood transfusions during treatment.

Ectopic varices at the site of cholangiojejunostomy, which can trigger life-threatening bleeding, are usually overlooked in the differential diagnosis when hemorrhage occurs, owing to the length of small bowel, tortuosity and the intermittent nature of bleeding[3]. Enteroscopy can serve as an effective interventional diagnostic tool with therapeutic capabilities [14]. For patients who have undergone the Whipple procedure, experienced endoscopists can also reach the site of choledochojejunostomy using conventional gastroscopy and colonoscopy, and endoscopic treatment can also be performed. Capsule endoscopy cannot show the anastomosis because it is in the afferent limb[20].

Treatment of jejunal loop varices is difficult and has no definitive conclusion because of their hemodynamic complexity. Two treatment options are available: Obliteration of the varices (by endoscopic sclerotherapy or ligation, embolization using interventional radiology, surgery for re-anastomosis); and portal decompression (by portal venous dilatation and stent placement, splenectomy, and shunt operation)[9,21-26]. A multidisciplinary approach with the cooperation of endoscopists, interventional radiologists, and surgeons is critical for timely treatment of these patients [27]. The choice of treatment strategy depends on the patient's overall condition, and the physician's skill and equipment available at the institution. Norton *et al*[12]. used an algorithmic approach for treatment, and endoscopic therapy was recommended as the primary option. Embolization, surgical shunt or transjugular intrahepatic portosystemic shunt should be taken into consideration if the hemorrhage cannot be successfully controlled by endoscopic therapy and the portal vein is patent. Surgical ligation should be selected if the portal vein is obstructed. In summary, endoscopic therapy should be the first-choice management for ectopic variceal bleeding. Additionally, second or third rounds of treatment

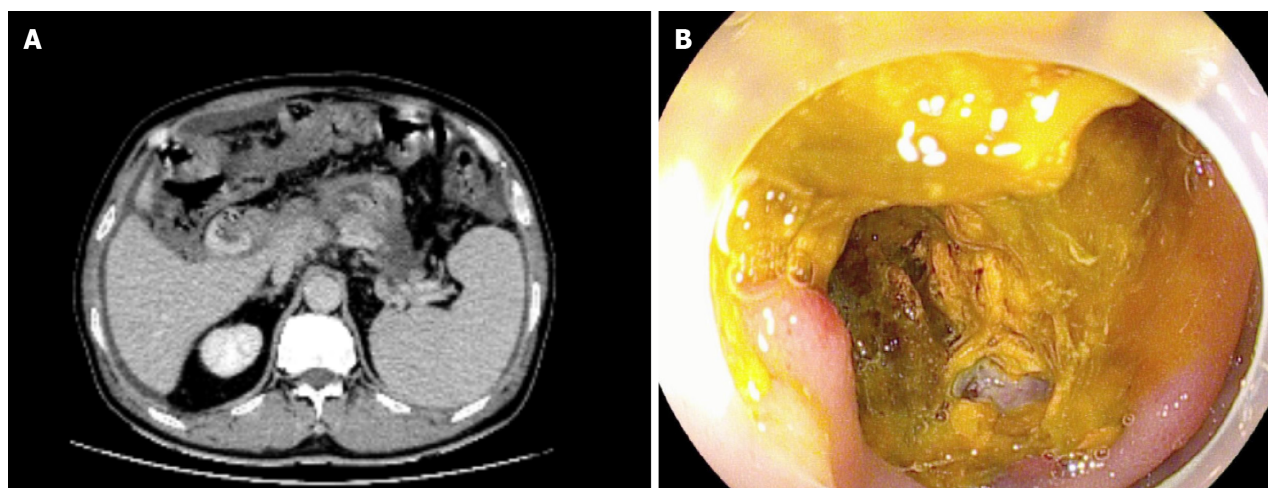


Figure 3 Endoscopic re-examination confirmed no signs of bleeding after endoscopic sclerotherapy (Case 3). A: Follow-up enhanced computed tomography revealed increased soft tissue density in the hepatic hilum, suggesting metastasis; B: Follow-up endoscopy revealed adhesive clumps and exudative ulcers near the choledochojejunostomy site, with no signs of bleeding observed.

should be taken into consideration, because control of ectopic bleeding is sometimes difficult[5].

In case 1, vascular angiography showed patent portal vein blood flow, but the superior mesenteric vein was occluded due to chronic thrombosis, making balloon angioplasty with stent placement impossible. For case 2, the previous surgical records indicated that the primary tumor had a wide-ranging involvement, affecting the portal vein and superior mesenteric vein. The patient's poor general physical condition and cardiac and renal functions led him ultimately to decide upon repeated endoscopic sclerotherapy as the treatment option. For case 3, CT confirmed the presence of a soft tissue mass in the hepatic hilum area, which encased and compressed the portal vein, resulting in significant narrowing. EUS-FNA was inclined towards a possible recurrence. However, the patient ultimately refused the placement of a portal vein stent.

Some factors may affect the clinical outcomes of endoscopic sclerotherapy for variceal bleeding at the site of cholangiojejunostomy. The severity of varices can affect the difficulty and success rate of treatment. More severe varices may require more treatment sessions or a greater amount of sclerosant, increasing the risk and complexity of the treatment. The overall condition of the patient can influence the risk and recovery of the procedure. Some patients may have failure of other organs that could increase the risk of treatment. The endoscopist's expertise and skill can directly affect the success rate of treatment and the incidence of complications. Post-treatment follow-up and strategies to prevent recurrence are also crucial factors. From the prospective of pathophysiology, beta-blockers make sense in patients with ectopic varices[28]. Case 3 has been regularly taking carvedilol after sclerotherapy to reduce portal vein pressure; however, large-scale clinical data are still needed to evaluate the benefits of using carvedilol in patients with varices at the biliary-enteric anastomosis.

There were some limitations to the current study. First, the results were obtained retrospectively, and the number of cases was small. However, due to the short survival period caused by the underlying neoplastic disease and post-pancreaticoduodenectomy, as well as the low incidence of venous varices at the choledochojejunostomy site, there are a small number of reports of these patients. Further studies with larger sample size or prospective cohort studies are needed to confirm the safety and effectiveness. Second, all endoscopic sclerotherapeutic procedures were performed by an endoscopist at a single center. Therefore, it is difficult to generalize the current results. Despite these limitations, to our knowledge, this is the first series of case reports on endoscopic sclerotherapy for venous varices at the choledochojejunostomy site, including videos.

CONCLUSION

Endoscopic sclerotherapy with lauromacrogol/ α -butyl cyanoacrylate injection may be considered as an easy, cost-effective and efficient treatment option for hemorrhage from venous varices at the choledochojejunostomy site in patients who have undergone pancreaticoduodenectomy. For patients without complications, underlying diseases, and significant organ dysfunction, as well as those who have undergone pancreaticoduodenectomy for benign diseases, endoscopic sclerotherapy tends to have better outcomes. The treatment of this rare cause of bleeding will increasingly require a multidisciplinary approach and personalized treatment choices in the future.

FOOTNOTES

Author contributions: Liu J designed the research study; Liu J and Wang P analyzed the data and wrote the manuscript; Wang LM and

Guo J performed the primary literature and data extraction; Zhong N was responsible for revising the manuscript; and all authors read and approved the final version.

Informed consent statement: All study participants or their legal guardian provided informed written consent about personal and medical data collection prior to study enrolment.

Conflict-of-interest statement: The authors declare no conflicts of interest for this article.

CARE Checklist (2016) statement: The authors have read the CARE Checklist (2016), and the manuscript was prepared and revised according to the CARE Checklist (2016).

Open-Access: This article is an open-access article that was selected by an in-house editor and fully peer-reviewed by external reviewers. It is distributed in accordance with the Creative Commons Attribution NonCommercial (CC BY-NC 4.0) license, which permits others to distribute, remix, adapt, build upon this work non-commercially, and license their derivative works on different terms, provided the original work is properly cited and the use is non-commercial. See: <https://creativecommons.org/licenses/by-nc/4.0/>

Country/Territory of origin: China

ORCID number: Ning Zhong 0009-0002-5315-8197.

S-Editor: Fan JR

L-Editor: A

P-Editor: Zheng XM

REFERENCES

- 1 Wilson SE, Stone RT, Christie JP, Passaro E Jr. Massive lower gastrointestinal bleeding from intestinal varices. *Arch Surg* 1979; **114**: 1158-1161 [PMID: 314792 DOI: 10.1001/archsurg.1979.01370340064011]
- 2 Sato T, Akaike J, Toyota J, Karino Y, Ohmura T. Clinicopathological features and treatment of ectopic varices with portal hypertension. *Int J Hepatol* 2011; **2011**: 960720 [PMID: 21994879 DOI: 10.4061/2011/960720]
- 3 Watanabe N, Toyonaga A, Kojima S, Takashimizu S, Oho K, Kokubu S, Nakamura K, Hasumi A, Murashima N, Tajiri T. Current status of ectopic varices in Japan: Results of a survey by the Japan Society for Portal Hypertension. *Hepatol Res* 2010; **40**: 763-776 [PMID: 20649816 DOI: 10.1111/j.1872-034X.2010.00690.x]
- 4 Hiraoka K, Kondo S, Ambo Y, Hirano S, Omi M, Okushiba S, Katoh H. Portal venous dilatation and stenting for bleeding jejunal varices: report of two cases. *Surg Today* 2001; **31**: 1008-1011 [PMID: 11766071 DOI: 10.1007/s005950170013]
- 5 Sasamoto A, Kamiya J, Nimura Y, Nagino M. Successful embolization therapy for bleeding from jejunal varices after choledochojejunostomy: report of a case. *Surg Today* 2010; **40**: 788-791 [PMID: 20676866 DOI: 10.1007/s00595-009-4129-z]
- 6 Hekmat H, Al-toma A, Mallant MP, Mulder CJ, Jacobs MA. Endoscopic N-butyl-2-cyanoacrylate (Histoacryl) obliteration of jejunal varices by using the double balloon enteroscope. *Gastrointest Endosc* 2007; **65**: 350-352 [PMID: 17259003 DOI: 10.1016/j.gie.2006.07.001]
- 7 Wakasugi M, Tsujie M, Goda S, Ohnishi K, Koga C, Tei M, Kawabata R, Hasegawa J. Laparotomy-assisted transcatheter variceal embolization for bleeding jejunal varices formed at the site of choledochojejunostomy: Report of a case and review of the literature. *Int J Surg Case Rep* 2020; **77**: 554-559 [PMID: 33395844 DOI: 10.1016/j.ijscr.2020.11.091]
- 8 Sato T, Yasui O, Kurokawa T, Hashimoto M, Asanuma Y, Koyama K. Jejunal varix with extrahepatic portal obstruction treated by embolization using interventional radiology: report of a case. *Surg Today* 2003; **33**: 131-134 [PMID: 12616377 DOI: 10.1007/s005950300029]
- 9 Sakai M, Nakao A, Kaneko T, Takeda S, Inoue S, Yagi Y, Okochi O, Ota T, Ito S. Transhepatic portal venous angioplasty with stenting for bleeding jejunal varices. *Hepatogastroenterology* 2005; **52**: 749-752 [PMID: 15966197]
- 10 Sone M, Arai Y, Morita S, Tomimatsu H, Sugawara S, Ishii H, Takeuchi Y. Percutaneous creation of an extraanatomic splenoportal shunt in a patient with bleeding ectopic varices. *J Vasc Interv Radiol* 2014; **25**: 1301-1303 [PMID: 25085063 DOI: 10.1016/j.jvir.2014.05.006]
- 11 Abdalla AO, Abdallah MA, Calvo LA. Successful Treatment of a Case of Ectopic Jejunal Varices with Portal Venous Stenting. *Am J Case Rep* 2019; **20**: 948-952 [PMID: 31266933 DOI: 10.12659/AJCR.916003]
- 12 Norton ID, Andrews JC, Kamath PS. Management of ectopic varices. *Hepatology* 1998; **28**: 1154-1158 [PMID: 9755256 DOI: 10.1002/hep.510280434]
- 13 Prachayakul V, Aswakul P, Kachintorn U. Bleeding hepaticojejunostomy anastomotic varices successfully treated with Histoacryl injection, using single-balloon enteroscopy. *Endoscopy* 2011; **43** Suppl 2 UCTN: E153 [PMID: 21563058 DOI: 10.1055/s-0030-1256233]
- 14 Takashima K, Matsui S, Komeda Y, Nagai T, Toshiharu S, Kashida H, Kudo M. Endoscopic sclerotherapy under balloon-assisted enteroscopy for hemorrhagic jejunal varices after choledochojejunostomy. *Endoscopy* 2020; **52**: E41-E42 [PMID: 31434157 DOI: 10.1055/a-0987-9780]
- 15 Akhter NM, Haskal ZJ. Diagnosis and management of ectopic varices. *Gastrointest Interv* 2012; **1**: 3-10 [DOI: 10.1016/j.gii.2012.08.001]
- 16 Kastanakis M, Anyfantakis D, Katsougris N, Bobolakis E. Massive gastrointestinal bleeding due to isolated jejunal varices in a patient without portal hypertension. *Int J Surg Case Rep* 2013; **4**: 439-441 [PMID: 23528981 DOI: 10.1016/j.ijscr.2013.01.029]
- 17 Heiberger CJ, Mehta TI, Yim D. Jejunal varices: an unconsidered cause of recurrent gastrointestinal haemorrhage. *BMJ Case Rep* 2019; **12** [PMID: 30850571 DOI: 10.1136/bcr-2018-228680]
- 18 Moncure AC, Waltman AC, Vandersalm TJ, Linton RR, Levine FH, Abbott WM. Gastrointestinal hemorrhage from adhesion-related mesenteric varices. *Ann Surg* 1976; **183**: 24-29 [PMID: 1082310 DOI: 10.1097/0000658-197601000-00005]
- 19 Sakurai K, Amano R, Yamamoto A, Nishida N, Matsutani S, Hirata K, Kimura K, Muguruma K, Toyokawa T, Kubo N, Tanaka H, Yashiro M, Ohira M, Hirakawa K. Portal vein stenting to treat portal vein stenosis in a patient with malignant tumor and gastrointestinal bleeding. *Int Surg* 2014; **99**: 91-95 [PMID: 24444277 DOI: 10.9738/INTSURG-D-13-00128.1]

- 20 Ali S, Asad Ur Rahman, Navaneethan U. An Unusual Cause of Recurrent Gastrointestinal Bleeding After Whipple's Surgery. *Gastroenterology* 2017; **153**: e1-e2 [PMID: [28672119](#) DOI: [10.1053/j.gastro.2016.12.046](#)]
- 21 Saeki Y, Ide K, Kakizawa H, Ishikawa M, Tashiro H, Ohdan H. Controlling the bleeding of jejunal varices formed at the site of choledochojejunostomy: report of 2 cases and a review of the literature. *Surg Today* 2013; **43**: 550-555 [PMID: [22777133](#) DOI: [10.1007/s00595-012-0243-4](#)]
- 22 Taniguchi H, Moriguchi M, Amaike H, Fuji N, Murayama Y, Kosuga T. Hemorrhage from varices in hepaticojejunostomy in the fifth and tenth year after surgery for hepatic hilar bile duct cancer: a case report. *Cases J* 2008; **1**: 59 [PMID: [18652705](#) DOI: [10.1186/1757-1626-1-59](#)]
- 23 Rezende-Neto JB, Petroianu A, Santana SK. Subtotal splenectomy and central splenorenal shunt for treatment of bleeding from Roux en Y jejunal loop varices secondary to portal hypertension. *Dig Dis Sci* 2008; **53**: 539-543 [PMID: [17597406](#) DOI: [10.1007/s10620-007-9878-1](#)]
- 24 Ota S, Suzuki S, Mitsuoka H, Unno N, Inagawa S, Takehara Y, Sakaguchi T, Konno H, Nakamura S. Effect of a portal venous stent for gastrointestinal hemorrhage from jejunal varices caused by portal hypertension after pancreatoduodenectomy. *J Hepatobiliary Pancreat Surg* 2005; **12**: 88-92 [PMID: [15754107](#) DOI: [10.1007/s00534-004-0941-4](#)]
- 25 Maeda N, Maruyama H, Higashimori A, Ominami M, Fukunaga S, Nagami Y, Fujiwara Y. Successful treatment using balloon-assisted enteroscopy for jejunal loop variceal bleeding after pancreaticoduodenectomy. *Endoscopy* 2023; **55**: E536-E537 [PMID: [36931298](#) DOI: [10.1055/a-2037-5581](#)]
- 26 Nasr S, Dahmani W, Jaziri H, Becheikh Y, Ameer WB, Elleuch N, Jmaa A. Massive hematochezia due to jejunal varices successfully treated with coil embolization. *Clin Case Rep* 2022; **10**: e6339 [PMID: [36188043](#) DOI: [10.1002/ccr3.6339](#)]
- 27 Kohli DR, Levy MF, Smallfield GB. Laparotomy-Assisted Endoscopic Injection of Jejunal Varices for Overt Small Bowel Bleeding. *ACG Case Rep J* 2017; **4**: e79 [PMID: [28670593](#) DOI: [10.14309/crj.2017.79](#)]
- 28 Biecker E. Portal hypertension and gastrointestinal bleeding: diagnosis, prevention and management. *World J Gastroenterol* 2013; **19**: 5035-5050 [PMID: [23964137](#) DOI: [10.3748/wjg.v19.i31.5035](#)]



Published by **Baishideng Publishing Group Inc**
7041 Koll Center Parkway, Suite 160, Pleasanton, CA 94566, USA

Telephone: +1-925-3991568

E-mail: office@baishideng.com

Help Desk: <https://www.f6publishing.com/helpdesk>

<https://www.wjgnet.com>

