

Early apoptosis in intestinal and diffuse gastric carcinomas

Hong Ping Zhou¹, Xu Wang¹ and Nan Zheng Zhang²

Subject headings stomach neoplasms/pathology; apoptosis; flow cytometry; Bcl-2 protein; phosphatidylserines

Zhou HP, Wang X, Zhang NZ. Early apoptosis in intestinal and diffuse gastric carcinomas. *World J Gastroentero*, 2000;6(6):898-901

INTRODUCTION

Apoptosis, described by Kerr^[1] in 1972, plays a key role in all types of regulated cellular processes in multicellular organisms. It is defined as a morphologic change, including fragmentation of the DNA, cell shrinkage, dilation of the endoplasmatic reticulum, cell fragmentation and formation of apoptotic bodies^[2,3]. One of the abilities of apoptotic cell is to trigger its own engulfment by phagocytic cells prior to cell lysis, which is crucial to the avoidance of the tissue damage and inflammation associated with necrosis^[4]. Apoptotic cells lose membrane phospholipid asymmetry and expose phosphatidylserine (PS) on the outer leaflet of the plasma membrane, macrophages then phagocytose apoptotic cells after specific recognition of the exposed PS^[5]. Annexin V (AV), having a high affinity for PS in the presence of Ca²⁺ ions^[6] and inhibition to PS-dependent procoagulant reactions^[7], is proved to be a very useful general probe for early apoptosis-associated membrane change on live cells before the nuclear condensation events and fragmentation of the DNA^[8].

Gastric carcinoma is estimated to be one of the most frequent *Cancers* in the world. According to Lauren's classification^[9], gastric carcinoma can be divided into adenocarcinomas of diffuse and intestinal type, which differ in growth pattern, morphology, and some phenotypic markers. Recently, apoptotic index and apoptotic genes have been found different in both types^[10,11]. In this study, we investigated the quantitations of early

apoptosis in both intestinal and diffuse gastric carcinoma and their adjacent non-neoplastic tissues with regard to classification and differentiation, and whether the exposure of PS could be inhibited by Bcl-2 protein through various pathways.

MATERIALS AND METHODS

Patients

The 27 surgically resected specimens used for this study were obtained from consecutive patients with gastric Cancer in the Department of General Surgery, Affiliated Hospital of Xuzhou Medical College during the period from April to September 1999. The patients received neither chemotherapy nor radio therapy before undergoing gastrectomy. After tissue sections of 0.5cm³ were excised from the carcinomatous and adjacent non-neoplastic tissues, they were embedded in ice box, and brought back to FCM laboratory. In addition, formalin fixed and paraffin embedded tissue specimens were used for pathological diagnosis according to the Lanren's classification. All cases had adequate clinical information.

Preparation of single-cell suspension

The tissues (carcinomatous and adjacent non-neoplastic tissues) were thoroughly washed with an excess of ice-cold phosphate buffered saline (PBS), immersed in PBS and minced quickly to approximately 0.5mm³ pieces using a pair of sharp scissors. After two more washings with PBS to remove red blood cells, these pieces were dispersed into single cells through an nylon screen (300 holes/cm³) by the press of an glass rod.

Detection of early apoptosis

The cell samples were washed with ice-cold PBS after centrifugation at 500×g for 5 minutes at 4°C. Supernatant was discarded, and finally the cell pellets were resuspended in ice-cold, diluted bind buffer to 2×10⁶ cells/mL. Five µL AV FITC (Immunotech, Cat. No.2375) solution and 5µL propidium iodide (PI, Immunotech, Cat. No.2375) were added to 490µL of the prepared cell suspension. And then the mixture was mixed gently and kept on ice and incubated for 10min in the dark. Aliquots were directly aspirated into a FACSCalibur flow cytometer (USA BD Company) for analysis with simultaneous monitoring of green fluorescence for AV-FITC and red fluorescence for PI. The FCM software (Cell Quest) was used to

¹Institute of Oncology, Xuzhou Medical College, Xuzhou 221002, Jiangsu Province, China

²Department of Oncology, the PLA 97th Hospital, Xuzhou 221004, Jiangsu Province, China

Hong Ping Zhou, graduated from Xuzhou Medical College as a postgraduate in 2000, now attending physician, Second Affiliated Hospital of Xuzhou Medical College, specialized in gastrointestinal oncology, having 3 papers published.

Supported by a grant from the Science and Technology Committee of Jiangsu Province, No.BJ98110

Correspondence to: Xu Wang, Department of Radiology, Affiliated Hospital of Xuzhou Medical College, 99 Huaihaixilu, Xuzhou 221002, Jiangsu Province, China

Tel 0086-516-5802118

Received 2000-05-12 Accepted 2000-06-23

calculate and analyze the AV+/PI- cells^[12].

Statistical analysis

To analyse the correlation among early apoptosis, necrosis, viable cells in gastric carcinomatous and adjacent non-neoplastic tissues, the Student's *t* test and the Pearson's correlation coefficient were performed with State statistical software.

RESULTS

Clinical and pathological information

The 27 patients with gastric carcinomas (16 male and 11 female), including 9 intestinal and 18 diffuse tumors, with a mean age at operation of 57.4 ± 13.1 years (ranging from 31 to 88 years). There were 7 cases of early (restricted to mucosa and submucosa) and 20 cases of advanced gastric carcinomas, respectively. The mean tumor size was $4.4 \text{ cm} \pm 2.0 \text{ cm}$ (ranging from 1.0 cm - 8.0 cm). Lymph node metastasis was found in 16 cases.

Detection of early apoptosis with AV and PI

Figure 1 shows typical flow cytometer histograms for gastric carcinoma and adjacent non-neoplastic tissues. AV was an able to bind to viable cells of normal or abnormal tissues as it can not penetrate the phospholipid bilayer and PS did not expose to the outer leaflet. In apoptotic cells, however, the bilayer lose its symmetry when PS was flipflopped from the inner to outer leaflet. Once the cells were dead, the integrity of the plasma membrane was lost and the penetration was enhanced promptly. The bivariate AV/PI analysis by cytogram showed that viable cells were negative for both AV and PI (LL), apoptotic cells were AV positive (LR), while dead cells were positive for both AV and PI (UR).

Early apoptosis in various histological types

By bivariate AV/PI analysis using flow cytometer, the percentages of early apoptosis of carcinomatous or non-plastic tissues were $16.7\% \pm 5.2\%$ ($\bar{x} \pm s$) and $9.3\% \pm 3.9\%$, respectively. The apoptotic index of carcinoma was significantly higher than that of the adjacent non-neoplastic tissue, the difference being statistically significant (Table 1). However, the same result only appeared in carcinomatous tissues of diffuse and intestinal carcinomas, whereas no difference was found in adjacent non-neoplastic tissues (Figure 2).

Table 1 Percentages of three subpopulations in gastric carcinomas

	AV+/PI-	AV+/PI+	AV-/PI-
Normal	9.3 ± 3.9	4.1 ± 2.5	85.7 ± 5.6
Vicious	16.7 ± 5.2^a	6.1 ± 2.7^b	76.7 ± 8.1^b

^a $P < 0.001$, ^b $P < 0.01$ vs normal (adjacent non-plastic tissues).

Correlation between early apoptosis and necrosis

The early apoptosis did not demonstrate a dose correlation with the necrosis, i.e. the correlation coefficients between AV+/PI- and AV+/PI+ in tumors or normal tissues were 0.3650 and 0.3877 respectively. And the early apoptosis was not correlated with sex, age, tumor size, lymph nodes metastasis, whereas closely correlated with depth of invasion.

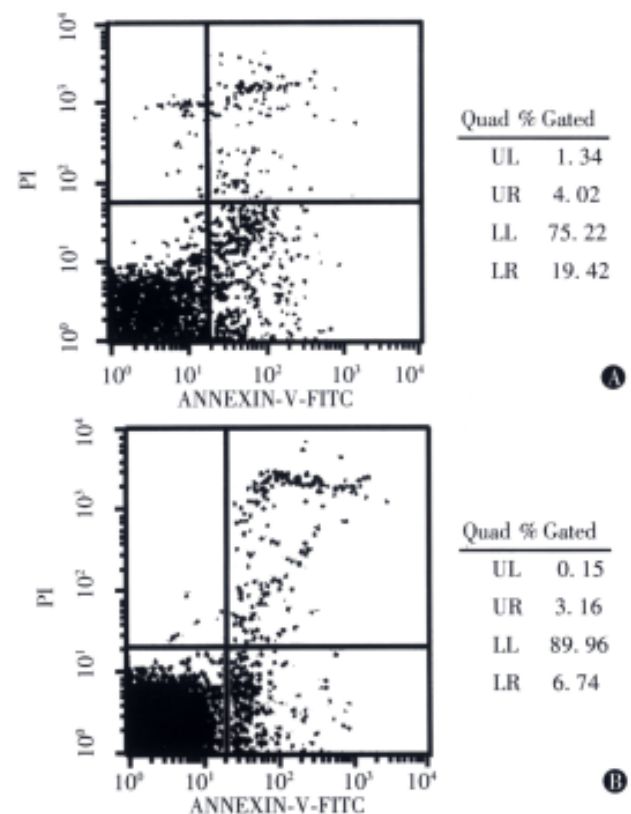


Figure 1 Bivariate AV/PI analysis of the gastric carcinoma (A) and adjacent non-neoplastic (B) tissues. The different labeling patterns in this assay identify the different cell subpopulations. i.e. region LL, viable cells (AV-/PI-), region LR, apoptotic cells (AV+/PI-), region UR, dead cells (AV+/PI+).

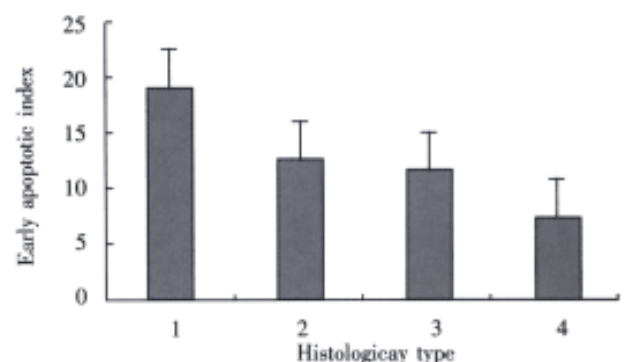


Figure 2 Early apoptosis in diffuse and intestinal gastric carcinomas. 1 and 2 were EAIs in carcinomatous tissues of diffuse and intestinal tumor, $19.0\% \pm 3.9\%$ and $12.0\% \pm 4.3\%$ ($P = 0.0002$); 3 and 4 were in adjacent non-neoplastic tissues, $10.8\% \pm 3.3\%$ and $7.3\% \pm 4.2\%$ ($P = 0.0516$).

DISCUSSION

In this report, we investigated the early apoptosis in diffuse and intestinal gastric carcinomatous and adjacent non-neoplastic tissues by AV/PI bivariate flow cytometry. Apoptosis, found in the normal tissues and in virtually all malignant tumors^[13], is defined morphologically as the double-strand cleavage leading to the formation of fragments that are detected usually by agarose gel electrophoresis (Ladder) or terminal deoxynucleotidyl transferase mediated dUTP-digoxigenin nick end labelling technique (TUNEL). The results, however, derived from the Ladder or TUNEL methods only presents the latter process of apoptosis and can not be analyzed quantitatively^[14-16].

With the development of the study on the role and basic mechanisms underlying apoptosis, the externalization of phosphatidylserine (PS), a kind of plasma membrane lipid, which results in the loss of phospholipid asymmetry, is a downstream event of early caspase activation^[8,17] and recognized as an early and ubiquitous phenomenon event in apoptosis^[5]. Based on the abilities of annexin V (AV) to bind to PS with high affinity and of propidium iodide (PI) to permeate the membrane losing integrity to stain DNA, AV and PI can be added simultaneously to the cell suspension to discriminate among viable, apoptotic and dead cells^[18]. Viable cells with its membrane's integrity and asymmetry were kept, and AV negative/PI negative were manifested (Figure 1, LL). After PS was exposed to the surface of membrane, apoptotic cells were presented with AV positive/PI negative (Figure 1, LR), whereas the necrotic cells with AV positive/PI positive (Figure 1, UR) were indicated when the membrane loses its integrity. In our study on fresh specimens, we found that the suspension from gastric carcinomatous and adjacent non-neoplastic tissues was identified easily to three subpopulations, among which the EAIs were different statistically. The percentages of apoptosis (AV positive/PI negative) were $16.7\% \pm 5.2\%$ and $9.3\% \pm 3.9\%$, respectively, being higher than those reported in literature^[19]. The reason might be that the experiments method are different and the sensitivity and specificity of AV/PI bivariate FCM are high, we therefore think that the results from our study can reflect objectively the spontaneous occurrence of apoptosis.

The externalization of phosphatidylserine (PS) plays a potential role in cellular kinetic significance. It has been shown that tumorigenic cells expressed relatively larger amounts than that of normal keratinocytes by semiquantitative analysis^[20] of PS in the outer leaflet of the cells. The same results were seen in our study. At the execution phase of apoptosis, PS was displayed at the outer membrane by flippases, scramblase and other proteinases. Possibly, with the participation of autologous cytophilic antibodies, components of the clotting

cascade, and special phospholipases, macrophages discriminate between "self" and altered "self" by recognizing, phagocytosing, and disposing of effete or tumorigenic cells. Furthermore, it was found in cells that the binding of PS and AV could suppress phagocytosis^[21]. That is, the expression of PS on the outer membrane leaflet of cells serves as a recognition moiety for macrophages.

There are various reports regarding the relationship between apoptotic indices and histological type in gastric carcinomas^[22,23], the significance of apoptosis in human gastric carcinomas suggested that the higher occurrence of apoptosis in well differentiated carcinomas reflects their slow-growing nature, and poorly differentiated carcinomas escape from this process. However, our results differed from the reports above. According to Lauren's classification, gastric carcinomas can be divided into adenocarcinomas of diffuse and intestinal type. One of the main difference between them is the degree of infiltration by macrocytes histologically, i.e. intestinal carcinomas grow with no or little infiltration whereas diffuse carcinomas do inversely. It might be that the heterogeneity of diffuse carcinomas is higher than that of intestinal carcinomas, the cells are prone to be initiated by multiple triggers of apoptosis, such as DNA damage, Fas ligand binding or withdrawal of growth factors^[24-27].

In recent studies, at the trigger and execution phase of apoptosis, the expression of bcl-2, bax^[28-30] was demonstrated to play important roles in cell life. Bcl-2 and Bax are members of the group proteins that regulate the apoptotic pathway, that is, Bcl-2 acts as an inhibitor of apoptosis, opposing Bax effects on cell life. Bcl-2 could protect cells from apoptosis in several ways, such as inhibition from transmembrane streaming of Ca^{2+} ion, blockage in releasing of cytochrome C, formation of heterodimers with Bax. In addition, Bcl-2 may regulate special PS-sensitive signal transduction pathway by protecting lipids from peroxidation^[31,32]. Some clinicopathological studies demonstrated that Bcl-2 appears to be preferentially associated with the intestinal type carcinomas and more prevalent in poorly differentiated ones^[33-35].

In conclusion, the early apoptosis has been investigated in gastric carcinomatous and adjacent non-neoplastic tissues by AV/PI bivariate flow cytometry. The early apoptosis is clearly related to tumor and its differentiation and depth of invasion.

REFERENCES

- 1 Kerr JFR, Wyllie AH, Currie AR. Apoptosis: a basis biological phenomenon with wide ranging implications in tissue kinetics. *Br J Cancer*, 1972;26:239-257
- 2 Kerr JFR, Winterford CM, Harmon BV. Apoptosis, its significance in Cancer and Cancer therapy. *Cancer*, 1994;73:2013-2026
- 3 Deng LY, Zhang YH, Zhang HX, Ma CL, Chen ZG. Observation of morphological changes and cytoplasmic movement in apoptosis process. *World J Gastroentero*, 1998;4(Suppl 2):66-67
- 4 Wyllie AH, Kerr JFR, Currie AR. Cell death: the significance of

- apoptosis. *Int Res Cytol*, 1980;68:251-306
- 5 Fadok VA, Voelker DR, Campbell PA, Cohen JJ, Bratton DL, Henson PM. Exposure of phosphatidylserine on the surface of apoptotic lymphocytes triggers specific recognition and removal by macrophages. *J Immunol*, 1992;148:2207
 - 6 Raynal P, Pollard HB. Annexins: the problem of assessing the biological role for a gene family of multifunctional calcium and phospholipid binding proteins. *Biochem Biophys Acta*, 1994;1179: 63-93
 - 7 Reutelingsperger CPM, Hornstra G, Hemker HC. Isolation and partial purification of a novel anticoagulant from arteries of human umbilical cord. *Eur J Biochem*, 1985;151:625-629
 - 8 Martin SJ, Reutelingsperger CPMR, McGahon AJ, Rader JA, van Schie RCAA, La Face DM, Green DR. Early redistribution of plasma membrane phosphatidylserine is a general feature of apoptosis regardless of the initiating stimulus: inhibition by over-expression of bcl-2 and abl. *J Exp Med*, 1995;182:1545-1556
 - 9 Lanren P. The two histological main types of gastric carcinoma: diffuse and so-call intestinal type carcinoma. *Acta Pathol Microbiol Scand*, 1965;64331-64349
 - 10 Shinohara T, Ohshima K, Murayama H, Kikuchi M, Yamashita Y, Shirakusa T. Apoptosis and proliferation in gastric carcinoma: the association with histological type. *Histopathology*, 1996;29: 123-129
 - 11 Vollmers HP, D-mmrch J, Hensel F, Ribbert H, Meyer-Bahlburg A, Ufken-Gaul T, v.Korff M, Malier-Hermelink HK. Differential expression of apoptosis receptors on diffuse and intestinal type stomach carcinoma. *Cancer*, 1997;79:433-440
 - 12 Zhou HP, Wang X, Zhang NZ, Huang J. Quantification of early apoptosis of gastric carcinoma with AV and PI by flow cytometer. *CTM*, 2000;12:84-87
 - 13 Sun ZX, Ma QW, Zhao TD, Wei YL, Wang GS, Li JS. Apoptosis induced by norcantharidin in human tumor cells. *World J Gastroentero*, 2000;6:263-265
 - 14 Wyllie AH, Morris RG, Smith AL, Dunlop D. Chromatin cleavage in apoptosis: association with condensed chromatin morphology and dependence on macromolecular synthesis. *J Pathol*, 1984; 142:67-73
 - 15 Gorczyca W, Gong J, Darzynkiewicz Z. Detection of DNA strand breaks in individual apoptotic cells by the in situ terminal deoxynucleotidyl transferase and nick translation assays. *Cancer Res*, 1993;53:1945-1952
 - 16 Wu P, Li X, Zhou T, Zhang MJ, Chen JL, Wang WM, Chen N, Dong DC. Role of P-selectin and anti-P-selectin monoclonal antibody in apoptosis during hepatic/renal ischemia reperfusion injury. *World J Gastroentero*, 2000;6:244-247
 - 17 Martin SJ, Finucane DM, Amarante Mendes GP, O'Flaherty GA, Green DR. Phosphatidylserine externalization during CD95 induced apoptosis of cells and cytoplasts requires ICE/CED-3 protease activity. *J Biochem*, 1996;271:28753-28756
 - 18 Koopman G, Reutelingsperger CPM, Kuijten GAM, Keehnen RM, Pals SZ, van Oers MH. Annexin V for flow cytometric detection of phosphatidylserine expression on B cells undergoing apoptosis. *Blood*, 1994;84:1415-1420
 - 19 Saegusa M, Takaano Y, Wakabayashi T, Okayasu I. Apoptosis in gastric carcinoma and its association with cell proliferation and differentiation. *Jpn J Cancer Res*, 1995;86:743-749
 - 20 Utsugi T, Schroit AJ, Connor J, Bucana CD, Fidler IJ. Elevated expression of phosphatidylserine in the outer membrane leaflet of human tumor cells and recognition by activated human blood monocytes. *Cancer Res*, 1991;51:3062-3066
 - 21 Bennett MR, Gibson DF, Schwartz SM, Tait JF. Binding and phagocytosis of apoptosis vascular smooth muscle cells is mediated in part by exposure of phosphatidylserine. *Circulation Res*, 1995; 77:1136-1142
 - 22 Staunton MJ, Graffney EF. Tumor type is a determinant of susceptibility to apoptosis. *Am J Clin Pathol*, 1995;103:300-307
 - 23 Kasagi N, Gomyo Y, Shirai H, Tsujitani S, Ito H. Apoptotic cell death in human gastric carcinoma: analysis by terminal deoxynucleotidyl transferase-mediated dUTP-biotin nick end labeling. *Jpn J Cancer Res*, 1994;85:939-945
 - 24 Berke G. The CTL's kiss of death. *Cell*, 1995;81:9-12
 - 25 Chen XQ, Zhang WD, Song YG, Zhou DY. Induction of apoptosis of lymphocytes in rat mucosal immune system. *World J Gastroentero*, 1998;4:19-23
 - 26 Xiao B, Shi YQ, Zhao YQ, You H, Wang ZY, Liu XL, Yin F, Qiao TD, Fan DM. Transduction of Fas gene or Bcl-2 antisense RNA sensitizes cultured drug resistant gastric Cancer cells to chemotherapeutic drugs. *World J Gastroentero*, 1998;4:421-425
 - 27 Wang XW, Xie H. Presence of Fas and Bcl-2 proteins in BEL-7404 human hepatoma cells. *World J Gastroentero*, 1998;4: 540-543
 - 28 Oltvai ZN, Millman CL, Korsmeyer SJ. Bcl-2 heterodimerizes *in vivo* with a conserved homolog, bax that accelerates programmed cell death. *Cell*, 1993;74:609-619
 - 29 Liang YR, Zheng SY, Shen YQ, Wu XY, Huang ZZ. Relationship between expression of apoptosis related antigens in hepatocellular carcinoma and in situ end labeling. *World J Gastroentero*, 1998;4:99
 - 30 Hockenberry DM, Oltavi ZN, Yin XM, Millman CL, Korsmeyer SJ. Bcl-2 function in an antioxidant pathway to prevent apoptosis. *Cell*, 1993;75:241-251
 - 31 Liu HF, Liu WW, Fang DC, Men RP. Expression and significance of proapoptotic gene Bax in gastric carcinoma. *World J Gastroentero*, 1999;5:15-17
 - 32 Fabisiak JP, Kagan VE, Ritov VB, Johnson DE, Lazo J. Bcl-2 inhibits selective oxidation and externalization of phosphatidylserine during paraquat-induced apoptosis. *Am J Physiol*, 1997;C675-C684
 - 33 Koshida Y, Saegusa M, Okayasu I. Apoptosis, cell proliferation and expression of bcl-2 and bax in gastric carcinomas: immunohistochemical and clinicopathological study. *Br J Cancer*, 1997;75: 367-373
 - 34 Wang LD, Zhou Q, Wei JP, Yang WC, Zhao X, Wang LX, Zou JX, Gao SS, Li YX, Yang CS. Apoptosis and its relationship with cell proliferation, p53, Waf1p21, bcl-2 and c-myc in esophageal carcinogenesis studied with a high-risk population in northern China. *World J Gastroentero*, 1998;4:287-293
 - 35 Lauwer GY, Scott GV, Karpeh MS. Immunohistochemical evaluation of bcl-2 protein expression in gastric adenocarcinomas. *Cancer*, 1995; 75:2209-2213