

Tri-iodothyronine supplement protects gut barrier in septic rats

Zhi-Li Yang, Lian-Yue Yang, Geng-Wen Huang, He-Li Liu

Zhi-Li Yang, Lian-Yue Yang, Geng-Wen Huang, He-Li Liu,
Department of Surgery, Xiangya Hospital, Central South University,
Changsha 410008, Hunan Province, China

Supported by the Scientific Research Fund of Chinese Ministry of Health, No.98-1-112

Correspondence to: Lian-Yue Yang, MD, Department of Surgery, Xiangya Hospital, Central South University, Changsha 410008, Hunan Province, China. damoyzl@163.net

Telephone: +86-731-4327326

Received: 2002-06-17 **Accepted:** 2002-07-19

Abstract

AIM: To investigate the role of tri-iodothyronine supplement in protecting gut barrier in septic rats.

METHODS: Twenty-two rats were randomized into three groups: sham group ($n=6$), sepsis group ($n=8$), and sepsis plus tri-iodothyronine (T_3) group ($n=8$). Septic rat model was established through cecal ligation and puncture (CLP). After 5 h, sham and sepsis groups received saline, and the remaining group received T_3 intraperitoneally. Twenty-one hrs After CLP, intestinal permeability and serum free T_3 and T_4 were measured with fluorescence spectrophotometer and by radioimmunoassay, respectively. Intestinal ultrastructure and histologic morphology were observed under transmission electron microscopy (TEM) and light microscopy, respectively.

RESULTS: After 21 h, septic symptoms and signs in sepsis plus T_3 group were milder than those in sepsis group. Serum FT_3 or FT_4 concentration in sepsis group was lower than that in sham group (1.59 ± 0.20 , 3.41 ± 2.14 pmol/L vs 3.44 ± 1.40 , 9.53 ± 3.39 pmol/L, $P<0.05$), and FT_3 concentration in sepsis plus T_3 group (3.40 ± 1.65 pmol/L, $P<0.05$) was corrected. Portal concentration of fluorescein isothiocyanate-dextran (FITC-D) in sepsis group (2.51 ± 0.56 mg/L) was higher than that in sham group (1.22 ± 0.21 mg/L) ($P<0.01$), and in sepsis plus T_3 group (1.68 ± 0.38 mg/L) it was decreased significantly ($P<0.01$). TEM and light microscopy showed that T_3 supplement preserved well ultrastructure and morphology of intestinal mucosa in septic rats.

CONCLUSION: Tri-iodothyronine supplement protects gut barrier in septic rats.

Yang ZL, Yang LY, Huang GW, Liu HL. Tri-iodothyronine supplement protects gut barrier in septic rats. *World J Gastroenterol* 2003; 9(2): 347-350
<http://www.wjgnet.com/1007-9327/9/347.htm>

INTRODUCTION

In recent years, laboratory and clinical researches have strongly shown that the gastrointestinal tract plays a pivotal role in the occurrence of sepsis and multiple organ dysfunction syndrome (MODS)^[1-4]. It is believed that gut barrier failure is a "trigger point" in sepsis and MODS, and some substances including intestinal trefoil factor^[5], glucagons-like peptide 2^[6-8] and glutamine^[9,10] may protect gut barrier, but we are still facing

either poor efficacy in clinical application or the challenge of translating the findings from the bench to the bedside. Therefore, it has become a breakthrough that may prevent MODS occurrence, improve septic prognosis and further seek for protective substances of gut barrier.

The "euthyroid sick syndrome, ESS" is defined as a decreased concentration of plasma tri-iodothyronine (T_3) with normal or low thyroxine (T_4), but serum thyroid-stimulating hormone concentration is normal^[11,12]. This syndrome is seen in states in which there are significant insults to the host including surgery, starvation, myocardial infarction, hypothermia and sepsis. In the study of ESS, it was reported that T_3 supplement may protect some organ functions^[13], such as pulmonary function during sepsis^[14], and donor myocardial function after transplantation^[15]. Recently, in sepsis, T_3 augmentation was shown by Chapital *et al* to increase the circulating antithrombin III levels, which is a critical material to prevent disseminated intravascular coagulation(DIC)^[16]. An earlier study revealed that hypothyroid hormone resulted in atrophy of intestinal epithelial cells, decreased mucosal DNA and protein contents, shortened the villi height, decreased the crypt depth and rates of utilization of glucose and glutamine, and consequently impaired the gut barrier^[17]. Based on these studies, we hypothesized that T_3 supplement may protect gut barrier in sepsis. This study was to investigate the relationship between T_3 and gut barrier in septic rats.

MATERIALS AND METHODS

Animals

Twenty-two adult male specific pathogen free (SPF) Sprague-Dawley rats weighing from 250 to 350 g were utilized in this investigation. The animals were purchased from Department of Animal Laboratory of Xiangya Medical College. Rats used in the present study were cared in accordance with the directory of Central South University Animal Care Unit, and the guidelines of the National Institutes of Health on welfare of laboratory animals.

Animal model

Rats were randomly divided into three groups: sham group ($n=6$), sepsis group ($n=8$), and sepsis plus T_3 group ($n=8$). Sepsis was induced by cecal ligation and puncture (CLP) as described by Wichterman *et al*^[18]. Under 3 % pentobarbital sodium anesthesia, a laparotomy was performed (the size of the incision was 2.0 cm), and the cecum was ligated just distally to the ileocecal valve to avoid any intestinal obstruction and was punctured across the intestine once with an 18 gauge needle. Punctured holes were placed 1-0 silk thread in case they were blocked up. The cecum was then returned to the peritoneal cavity and the abdomen was closed in two layers. Laparotomy in sham group was performed and the cecum was manipulated, but neither ligated nor punctured. All animals were resuscitated subcutaneously with 50 ml/kg body weight of normal saline at the completion of surgery. After 5 h, sepsis plus T_3 group were injected intraperitoneally with 1.5 ml/kg body weight of T_3 (0.01 g/L, Sigma), and sham group and sepsis group received 1.5ml/kg body weight of normal saline. All animals were anesthetized 21hrs post-CLP once more with

two-thirds of original dose, their intestinal permeability and serum free T_3 and T_4 were measured, intestinal ultrastructure and histologic morphology were observed.

Intestinal permeability measurement

Intestinal permeability was determined essentially according to the method described by Chen *et al*^[19]. A 20 cm segment of the ileum was dissected beginning at 3 cm ileum proximal to ileocecal valve with well protected superior mesenteric vessels. The bilateral end of the isolated ileum was clamped with rubber bands to prevent the leakage of fluorescein isothiocyanate-dextran (FITC-D). One ml of 0.1M phosphate buffer saline (PBS, pH7.2) containing 25 mg of FITC-D (MW4400, Sigma) was injected into the lumen. After 30 min, a blood sample (100 μ L) was taken by a puncture of the portal vein and immediately diluted with 1.9 ml of 50 Mm Tris(pH10.3) containing 150 mM chloride sodium. The diluted plasma was centrifuged at 3 000 \times g, 4 $^{\circ}$ C for 7 min. The supernatant was analyzed for FITC-D concentration with a Hitachi fluorescence spectrophotometer (F-2000) at an excitation wavelength of 480 nm and an emission wavelength of 520 nm. Standard curves for calculating the FITC-D concentration in the samples were obtained by diluting various amounts of FITC-D in a pool of rat plasma, then diluted and centrifuged in the same manner as the samples before measurement.

Transmission electron microscopy (TEM)

Segments of intestine were removed, small rings were cut from the intestine, and immediately fixed in 2.5 % glutaraldehyde for at least 24 hours, and counter-fixed in 2 % osmium tetroxide prepared in 0.1M phosphate buffer, pH7.4 for one hour. They were then dehydrated in graded series of ethanol and propylene oxide and embedded in Epon 812. Sections were cut, collected on copper grids, counter stained with uranyl acetate and lead citrate, and examined under a Hitachi H-600 electron microscope.

Histological assessment

A longitudinal 1 cm segment of intestine was removed and rinsed in normal saline, fixed in 10 % neutral formalin, and processed by conventional methods. The tissue was embedded in paraffin wax. Tissue sections (5 μ m) were stained with haematoxylin and eosin. Intestinal morphologic characteristics were evaluated under light microscopy.

Assay of serum free T_3 and T_4 (FT₃, FT₄)

After 21hrs, 3 ml blood samples were collected from inferior vena cava, centrifuged at 1 500 \times g for 15 min. The supernatants were frozen at -20 $^{\circ}$ C for later FT₃ and FT₄ assay by radioimmunoassay (RIA).

Statistical analysis

Data were expressed as $\bar{x} \pm s$ and compared using one-way analysis of variance (ANOVA). The statistical analyses were made using the Statistical Package for the Social Science (SPSS10.0) software. Differences were considered as significant when the probability was less than 0.05.

RESULTS

All rats of sepsis group exhibited symptoms and signs of sepsis, including lethargy, piloerection, decreased grooming, and diarrhea. Above symptoms and signs of sepsis plus T_3 group were milder, and sham group were normal.

Serum FT₃ levels in sepsis group were decreased significantly compared with tri-iodothyronine treated rats at 21 hrs, sepsis plus T_3 rats had normal or slightly decreased FT₃ levels after CLP 21 hrs compared with sham operated rats,

and FT₄ levels in sepsis group were also much lower than those in sham operated rats (Table 1).

Table 1 Serum FT₃ and FT₄ concentrations measured by RIA ($\bar{x} \pm s$)

Groups	n	FT ₃ (pmol/L)	FT ₄ (pmol/L)
Sham	6	3.44 \pm 1.40 ^a	9.53 \pm 3.39 ^a
Sepsis	8	1.59 \pm 0.20	3.41 \pm 2.14
Sepsis plus T_3	8	3.40 \pm 1.65 ^a	6.37 \pm 4.45

^a $P < 0.05$ vs sepsis group.

Rats receiving normal saline after CLP showed a significant increase in intestinal permeability in comparison with sham group ($P < 0.01$), rats with administered T_3 after CLP showed a significant decrease in intestinal permeability in comparison with the sepsis plus normal saline group ($P < 0.01$) (Figure 1).

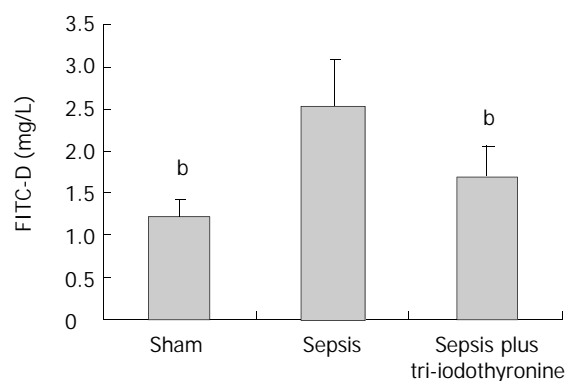


Figure 1 Effect of tri-iodothyronine on gut permeability. ^b $P < 0.01$ vs sepsis group.

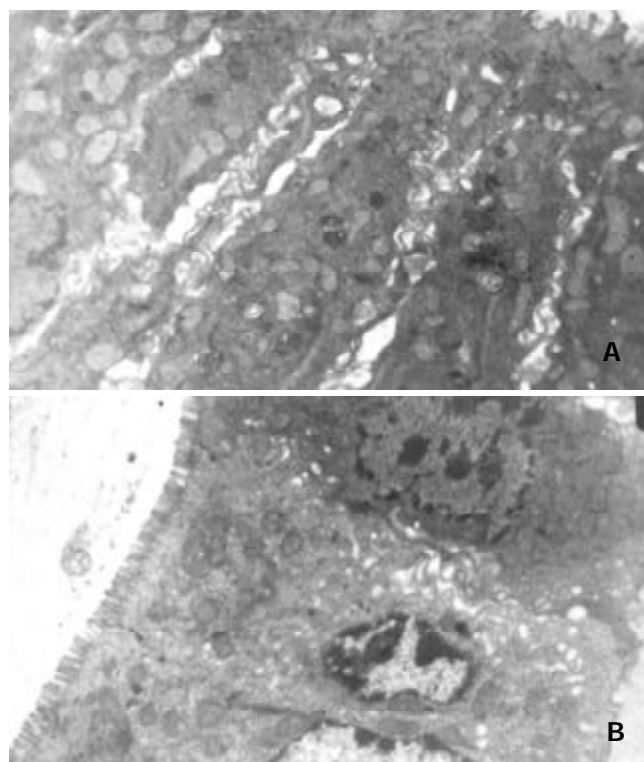


Figure 2 Transmission electron micrography of intestinal mucosal cells. (A) In sepsis group intestinal epithelial cells. (B) In sepsis plus T_3 group intestinal epithelial cells $\times 6 000$.

In sepsis group, the ultrastructure of intestinal epithelial cells showed that the microvilli were sharply reduced and deformed, and loss was patchy. The edema of the villi cells was more pronounced with the mitochondrias dropsy and vacuolar change, gaps of enterocytes were sharply widened, junctional complex among enterocytes were shortened and widened (Figure 2 A). In contrast, ultrastructure of sepsis plus T_3 group showed that the microvilli were dense and regular with a jagged and interlocking pattern among enterocytes and the mitochondrias were clear (Figure 2 B).

Under photomicrography, septic rats showed severe edema and sloughing of the villous tips compared with sham animals (Figure 3A and B). Rats with administered T_3 after CLP showed relatively normal villous tips without sloughing (Figure 3 C).

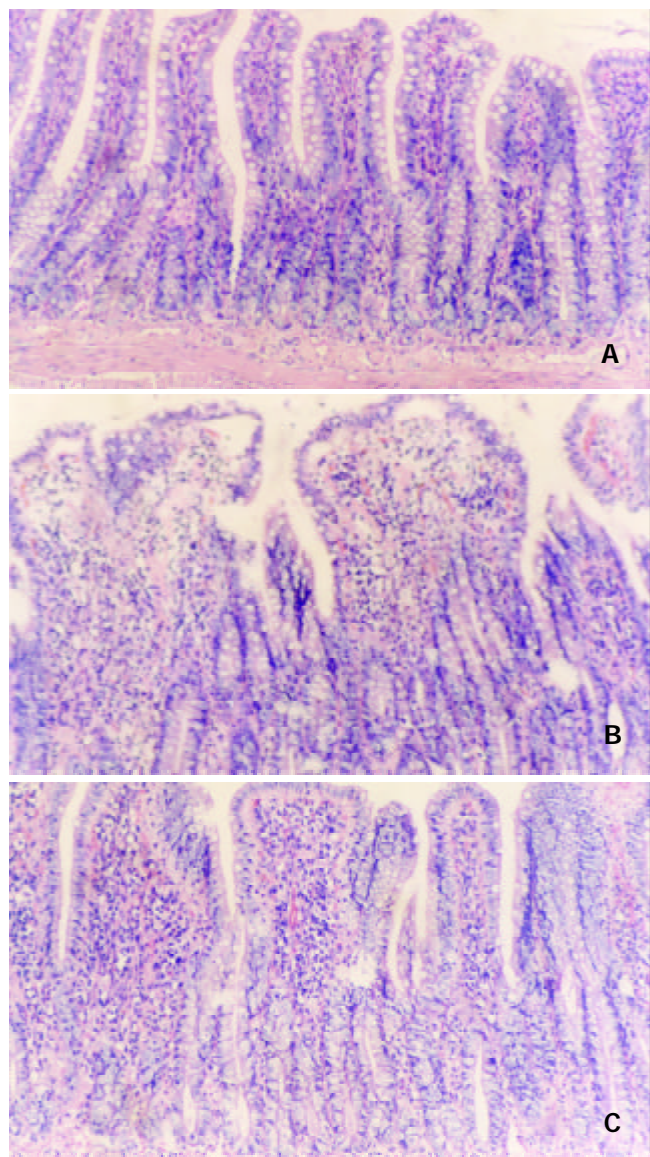


Figure 3 In sham rats, intestinal mucosal architecture is well preserved (A). Sepsis induced significantly edema of villous tips and sloughing of villous enterocytes (B). The tri-iodothyronine prevented the intestinal damages induced by sepsis (C). HE, $\times 100$.

DISCUSSION

For more than 3 decades, it has been known that the euthyroid sick syndrome exists probably in any severe illness, including starvation^[20], pulmonary tuberculosis^[21], sepsis^[22,23], surgery^[24,25], myocardial infarction^[26,27], bypass^[28] and bone marrow transplantation^[29]. The syndrome is also called low T_3 syndrome

or nonthyroidal illness, characterized by low serum T_3 levels, and serum free T_4 levels are commonly below normal, but may be normal or above normal. It is likely that mechanism of thyroid hormone suppression in these illness is multifactorial and may differ in different groups of patients, as for low serum T_3 levels in this syndrome, one important cause is a decreased generation of T_3 by type I iodothyronine deiodinase in the liver and a reduced degradation of r T_3 ^[30]. Subsequently, Nagaya *et al* demonstrated that in severe illness activated NF- κ B could inhibit T_3 -dependent induction of type I 5' - deiodinase mRNA and enzyme activity^[31]. In addition, the degree of low T_3 in circulation has been shown to correlate with the severity of the underlying disorders and the prognosis^[32]. Some authors believe that this is an abnormal state with decreased production rather than increased degradation, others content that this may be the body's adaptation to stress protecting the body against exaggerated catabolism. Hitherto, some T_3 supplementing studies suggested that the former might be more reasonable than the latter^[14-16,35].

In this study, we used cecum ligation and puncture (CLP) to establish classic animal model of sepsis. During the whole investigation, our septic models were coincident with the previous studies^[33,34]. An acute decrease in circulating levels of free T_3 and T_4 was seen after 21hrs CLP, T_3 supplement prevented the decrease in serum free T_3 concentration with sepsis. ESS was seen in our septic model. Moley *et al* showed in their study that absence of thyroid hormone abolished the hyperdynamic phase of sepsis, increased susceptibility to sepsis, and significantly increased the mortality in sepsis, and thyroxine replacement following thyroidectomy prevented the increased mortality from sepsis^[35]. In our research, T_3 supplement showed that septic symptoms and signs of the rats were abated to a certain extent. Thus, our data has confirmed that T_3 replacement in septic rats with ESS may be beneficial to the general condition of the patients.

The progression from sepsis to severe sepsis (sepsis with dysfunction of one organ) to multiple organ dysfunction syndrome and then to septic death requires escalation of treatment^[36]. During the course of the progression, gut barrier disruption is believed to be the "motor" of "irreversible" shock and multiple system organ failure^[37]. The critical cause is that translocation of bacteria and endotoxins contribute to the infection and injury of the body. Increased intestinal mucosal permeability is considered to be a quantitative index of injury or dysfunction of the intestinal mucosa barrier. The molecular probe FITC-D used in this study is considered to penetrate through a paracellular route toward portal vein via the tight junctions according to its size. Gut permeability indicated by FITC-D was coincident with the pathologic changes of injured gut in inflammation^[38]. Assay of FITC-D does not depend on systemic circulation and renal function compared with other probe molecule, and so application of FITC-D assay can indicate more exactly the gut permeability in this experimental model. Our data showed that T_3 administration significantly decreased gut permeability in septic rats. Photomicrography and TEM showed that T_3 supplement well preserved the ultrastructure and morphology of intestinal mucosa. Therefore, these data indicate that T_3 augmentation can protect from the structural and functional damages of gut barrier in septic rats. The proximate molecular mechanism by which T_3 regulates gut barrier in sepsis is not known. It is possible that T_3 administration is associated with protective substances synthesis of intestinal epithelial cells. Smith *et al* reported that administration of T_3 could induce expression of heme oxygenase-1 (HO-1) and stimulate activity of HO-1 in liver of thyroidectomized rats^[39]. HO-1 is a stress-associated protein whose expression is stimulated by hypoxia, and increases adaptive response of cells to hypoxia. Hypoxia inducible factor-1 (HIF-1) mediates transcriptional activation of HO-1 gene in

response to hypoxia^[40]. Our study showed that T₃ supplement increased expression of HIF-1 α in intestinal epithelial cells of septic rats (unpublished data). Thus, promoting adaptive response of cells to hypoxia may be one of approaches to improve gut barrier in sepsis by T₃.

In conclusion, thyroid hormone is one of the critical hormones in mammals and plays an indispensable role in development as well as in lipid, protein, and carbohydrate metabolism and energy generation. Our results demonstrate that tri-iodothyronine, active form of thyroid hormone, can protect gut barrier in septic rats. Obviously, biologic functions of thyroid hormone are expanded, and moreover, it may supply a novel method to protect from the injury of gut barrier in critic illness. It is of important theoretical significance and practical value to further investigate its protective mechanism.

ACKNOWLEDGEMENT

We are grateful to Professor Shi-Ling He and Professor Zhi-Qiang Xiao for their assistance in preparing this manuscript.

REFERENCES

- 1 **Moore FA**. Role of gastrointestinal tract in the postinjury multiple organ failure. *Am J Surg* 1999; **178**: 449-453
- 2 **Deitch EA**. Multiple organ failure: pathophysiology and potential future therapy. *Ann Surg* 1992; **216**: 117-134
- 3 **Wu CT**, Li ZL, Xiong DX. Relationship between enteric microecologic dysbiosis and bacterial translocation in acute necrotizing pancreatitis. *World J Gastroenterol* 1998; **4**: 242-245
- 4 **Yi JH**, Ni RY, Luo DO, Li SL. Intestinal flora translocation and overgrowth in upper gastrointestinal tract induced by hepatic failure. *World J Gastroenterol* 1999; **5**: 327-329
- 5 **Wong WM**, Poulsom R, Wright NA. Trefoil peptides. *Gut* 1999; **44**: 890-895
- 6 **Kouris GJ**, Liu Q, Rossi H, Djuricin G, Gattuso P, Nathan C, Weinstein RA, Prinz RA. The effect of glucagons-like peptide 2 on intestinal permeability and bacterial translocation in acute necrotizing pancreatitis. *Am J Surg* 2001; **181**: 571-575
- 7 **Wang FJ**, Zhao Y, Wang P, Wang SL, Liu J, Zhou X. Effects of glucagons-like peptide-2 on intestinal barrier function in severely burned rats. *Shijie Huaren Xiaohua Zazhi* 2002; **10**: 796-799
- 8 **Benjamin MA**, McKay DM, Yang PC, Cameron H, Perdue MH. Glucagon-like peptide-2 enhances intestinal epithelial barrier function of both transcellular and paracellular pathways in the mouse. *Gut* 2000; **47**: 112-119
- 9 **Wischmeyer PE**, Kahana M, Wolfson R, Ren H, Mush MM, Chang EB. Glutamine reduces cytokine release, organ damage, and mortality in a rat model of endotoxemia. *Shock* 2001; **16**: 398-402
- 10 **Zhou X**, Li YX, Li N, Li JS. Effect of bowel rehabilitative therapy on structural adaptation of remnant small intestine: animal experiment. *World J Gastroenterol* 2001; **7**: 66-73
- 11 **Utiger RD**. Altered thyroid function in nonthyroidal illness and surgery: to treat or not to treat? *N Engl J Med* 1995; **333**: 1562-1563
- 12 **Yang LY**, Huang GW. Advance and development of sick syndrome of normal thyroid in surgical severe patients. *Zhongguo Shiyong Waikexue* 2000; **20**: 114-115
- 13 **Liu JH**, Yang LY. Advance and development of research of protective mechanism of organ function by thyroxine. *Zhongguo Shiyong Waikexue* 2001; **21**: 372-374
- 14 **Dulchavsky SA**, Bailey J. Triiodothyronine treatment maintains surfactant synthesis during sepsis. *Surgery* 1992; **112**: 475-479
- 15 **Jeevanandam V**, Todd B, Regillo T, Hellman S, Eldridge C, McClurken J. Reversal of donor myocardial dysfunction by triiodothyronine replacement therapy. *J Heart Lung Transplant* 1994; **13**: 681-687
- 16 **Chapital AD**, Hendrick SR, Lloyd L, Pieper D. The effects of triiodothyronine augmentation on antithrombin III levels in sepsis. *Am Surg* 2001; **67**: 253-255
- 17 **Ardawi MSM**, Jalalah SM. Effects of hypothyroidism on glucose and glutamine metabolism by the gut of the rat. *Clin Science* 1991; **81**: 347-355
- 18 **Wichterman KA**, Chaudry IH, Baue AE. Studies of peripheral glucose uptake during sepsis. *Arch Surg* 1979; **114**: 740-743
- 19 **Chen LW**, Hsu CM, Cha MC, Chen JS, Chen SC. Changes in gut mucosal nitric oxide synthase (NOS) activity after thermal injury and its relation with barrier failure. *Shock* 1999; **11**: 104-110
- 20 **Hennemann G**, Docter R, Krenning EP. Causes and effects of the low T₃ syndrome during caloric deprivation and non-thyroidal illness: an overview. *Acta Med Scand* 1988; **15**: 42-45
- 21 **Chow CC**, Mak TW, Chan CH, Cockram CS. Euthyroid sick syndrome in pulmonary tuberculosis before and after treatment. *Ann Clin Biochem* 1995; **32**: 385-391
- 22 **Phillips RH**, Valente WA, Caplan ES, Connor TB, Wiswell JG. Circulating thyroid hormone changes in acute trauma: prognostic implications for clinical outcome. *J Trauma* 1984; **24**: 116-119
- 23 **Huang GW**, Yang LY, Yang JQ. Role of thyroid hormone in the protection of intestinal mucosal barrier of septic rats. *Zhonghua Shiyong Waikexue* 2000; **17**: 531-532
- 24 **Cheren HJ**, Nellen HH, Barabejski FG, Chong MBA, Lifshitz GA. Thyroid function and abdominal surgery. A longitudinal study. *Arch Med Res* 1992; **23**: 143-147
- 25 **Yang LY**, Liu HL. Application of thyroxine in surgery. *Zhongguo Shiyong Waikexue* 2001; **21**: 328-329
- 26 **Vardarli I**, Schmidt R, Wdowinski JM, Teuber J, Schwedes U, Usadel KH. The hypothalamo-hypophyseal thyroid axis, plasma protein concentrations and the hypophyseogonadal axis in low T₃ syndrome following acute myocardial infarct. *Klin Wochenschrift* 1987; **65**: 129-133
- 27 **Eber B**, Schumacher M, Langsteger W, Zweiker R, Fruhwald FM, Pokan R, Gasser R, Eber O, Klein W. Changes in thyroid hormone parameters after acute myocardial infarction. *Cardiology* 1995; **86**: 152-156
- 28 **Holland FW**, Brown PS, Weintraub BD, Clark RE. Cardiopulmonary by pass and thyroid function: a "euthyroid sick syndrome". *Ann Thorac Surg* 1991; **52**: 46-50
- 29 **Vexiau P**, Perez-Castiglioni P, Socie G, Devergie A, Toubert ME, Aractingi S, Gluckman E. The "euthyroid sick syndrome": incidence, risk factors and prognostic value soon after allogeneic bone marrow transplantation. *Br J Haematol* 1993; **85**: 778-782
- 30 **De Groot LJ**. Dangerous dogmas in medicine: the nonthyroidal illness syndrome. *J Clin Endocrinol Metab* 1999; **84**: 151-164
- 31 **Nagaya T**, Fujieda M, Otsuka G, Yang JP, Okamoto T, Seo H. A potential role of activated NF- κ B in the pathogenesis of euthyroid sick syndrome. *J Clin Invest* 2000; **106**: 393-402
- 32 **Yang LY**, Hu M, Huang YS. The relation of critical septic shock and peripheral metabolism malfunction of thyroxine. *Zhonghua Shiyong Waikexue* 1990; **7**: 134-135
- 33 **Shieh P**, Zhou M, Orman DA, Chaudry IH, Wang P. Upregulation of inducible nitric oxide synthase and nitric oxide occurs later than the onset of the hyperdynamic response during sepsis. *Shock* 2000; **13**: 325-329
- 34 **Wang P**, Chaudry IH. Mechanism of hepatocellular dysfunction during hyperdynamic sepsis. *Am J Physiol* 1996; **270**: R927-938
- 35 **Moley JF**, Ohkawa M, Chaudry IH, Clemens MG, Baue AE. Hypothyroidism abolishes the hyperdynamic phase and increases susceptibility to sepsis. *J Surg Res* 1984; **36**: 265-273
- 36 **Tabrizi AR**, Zehnbaue BA, Freeman BD, Buchman TG. Genetic markers in sepsis. *J Am Coll Surg* 2001; **192**: 106-117
- 37 **Antonsson JB**, Fiddian-Green RG. The role of the gut in shock and multiple system organ failure. *Eur J Surg* 1991; **157**: 3-12
- 38 **Travis S**, Menzies I. Intestinal permeability: functional assessment and significance. *Clin Sci* 1992; **82**: 471-488
- 39 **Smith TJ**, Drummand GS, Kourides IA, Kappas A. Thyroid hormone regulation of heme oxidation in the liver. *Proc Natl Acad Sci USA* 1982; **79**: 7537-7541
- 40 **Lee PJ**, Jiang BH, Chin BY, Iyer NV, Alam J, Semenza GL, Choi AMK. Hypoxia-inducible factor-1 mediates transcriptional activation of the heme oxygenase-1 gene in response to hypoxia. *J Bio Chem* 1997; **272**: 5375-5381