

• BASIC RESEARCH •

# Experimental study of effect of Ganyanping on fibrosis in rat livers

Wang-Xian Tang, Zi-Li Dan, Hong-Mei Yan, Cui-Huan Wu, Guo Zhang, Mei Liu, Qin Li, Shao-Bai Li

**Wang-Xian Tang, Zi-Li Dan, Guo Zhang, Mei Liu, Qin Li, Shao-Bai Li**, Institute of Liver Diseases, Tongji Hospital, Tongji Medical College, Huazhong University of Science and Technology, Wuhan 430030, Hubei Province, China

**Hong-Mei Yan**, The 7<sup>th</sup> Hospital of Wuhan, Wuhan 430071, Hubei Province, China

**Cui-Huan Wu**, Department of Pathology, Tongji Medical College, Huazhong University of Science and Technology, Wuhan 430030, Hubei Province, China

**Supported by** the Natural Science Foundation of Hubei Province, No. 1999 J151

**Correspondence to:** Professor Wang-Xian Tang, Institute of Liver Diseases, Tongji Hospital, Tongji Medical College, Huazhong University of Science and Technology, Wuhan 430030, Hubei Province, China. tangwx@tjh.tjmu.edu.cn

**Telephone:** +86-27-83662873 **Fax:** +86-27-83615970

**Received:** 2002-11-06 **Accepted:** 2003-02-11

## Abstract

**AIM:** To observe the effects of Ganyanping on CCl<sub>4</sub>-induced hepatic fibrosis in rats.

**METHODS:** The rats were separated randomly into five groups. Groups A to group D, each consisting of 15 rats, were for different tests, while 8 rats were used as normal controls (N). For group D, CCl<sub>4</sub> was injected subcutaneously, at a dosage of 3 ml/kg for 9 weeks. For group A, Ganyanping was administered via gastric tube at a dosage of 10 ml/kg. For group B, the treatment with Ganyanping was started 4 weeks after CCl<sub>4</sub> administration. In group C, Ganyanping was administered 8 weeks after the intoxication, and treatment lasted for 4 weeks. Liver tissues were fixed in 10 % formalin and embedded in paraffin. Pathologic changes, particularly fibrosis, were evaluated on the HE and V-G-stained sections. Ten middle-power fields were randomly selected for assessment of collagen deposition.

**RESULTS:** Loss of normal hepatic architecture, some with pseudo-lobule formation, was observed in group D, while hepatocytes steatosis and fibrosis were less pronounced in the animals treated with Ganyanping. Pseudo-lobule formation was not evident in the latter groups. The total collagen area and ratio were 840.23±81.65 and 7.0±0.9, respectively in group D, the ratio being reduced greatly in the Ganyanping-treated groups (148.73±45.89 and 1.16±0.33, respectively). The activities of MAO and ACP were elevated and that of SDH in group D decreased in the hepatic tissue as compared to the control group. The treatment with Ganyanping abrogated these enzymatic changes.

**CONCLUSION:** Our data approved that Ganyanping could improve the microcirculation in the liver, reduce oxygen-derived free radicals, and enhance the cellular metabolism and immune function, all resulting in an anti-fibrotic effect. Hence, Ganyanping can protect the liver from fibrosis. It

may be a safe and effective preparation for patient with fibrosis.

Tang WX, Dan ZL, Yan HM, Wu CH, Zhang G, Liu M, Li Q, Li SB. Experimental study of effect of Ganyanping on fibrosis in rat livers. *World J Gastroenterol* 2003; 9(6): 1292-1295

<http://www.wjgnet.com/1007-9327/9/1292.asp>

## INTRODUCTION

Ganyanping, a preparation of Chinese herbs proposed by Li Shaobai *et al*<sup>[1]</sup> has been used in clinical and experimental fields for many years. It has been shown to be protective for the animal liver against injury by D-GalN and cirrhosis caused by CCl<sub>4</sub> intoxication<sup>[2-6]</sup>. In this study, the effects of Ganyanping on liver fibrosis used a CCl<sub>4</sub>-intoxication model. The V-G and enzyme histochemistry techniques were employed to observe the effects of Ganyanping.

## MATERIALS AND METHODS

### Reagents

CCl<sub>4</sub> (Beijing Chemical Factory, Lot No. 20000225) was diluted to 40 % in vegetable oil (Southseas Oils & Fats Industrial (CHI Wan) Limited, Grade One, Lot No. KO'SOF Ts88). Ganyanping tablet preparation (Lot No.20001110) was provided by the Institute of Liver Disease, Tongji Hospital, Tongji Medical College, consisting of Radix Astragali seu Hedysari, Radix Salviae Miltiorrhizae, Rhizoma polygoni Cuspidati and other herbs. The tablets were prepared in the Chinese Medicine Pharmacy of Tongji Hospital. The powder of Ganyanping was dissolved into water (1.2 g/ml) before use.

### Animals

68 Wistar rats (♂ & ♀, 38 for ♂ and 30 for ♀), weighing between 170 and 250 g, were provided by the Laboratory Animal Center of Tongji Medical College. The rats were separated randomly into five groups. Group N, normal control, consisted of 8 rats. For group A to group D, rats (15 for each) were treated with CCl<sub>4</sub> by subcutaneous injection at a dosage of 3 ml/kg for 9 weeks. For group A, Ganyanping (10 ml/kg) was also administered via gastric tube along with the CCl<sub>4</sub> intoxication. For group B, Ganyanping treatment was started 4 weeks later and lasted for the remaining 5 weeks. For group C, Ganyanping was given after 8 weeks of CCl<sub>4</sub> administration, and the treatment lasted for 4 weeks. Ganyanping was administered in the form of an aqueous suspension (2 g/ml). After 9 weeks, the overnight fasting animals were anesthetized with sodium pentobarbital (30 mg/kg, per injection). Blood was taken from inferior vena cava for the estimation of biochemical parameters including values of ALT, AST, and concentrations of protein and albumin.

### Pathological observations

Hepatic tissues were fixed with formalin and embedded with paraffin. The sections were stained with hematoxylin and eosin.

Samples for electron microscopy were fixed in 25 g/L glutaraldehyde buffer for two hours, then with osmium acid, dehydrated in acetone, and embedded with epoxy resin. The sections were observed under an electron microscope (OPTON EM10C, Carl Zeiss Company, Made in Germany, No.5166, voltage is 60KV).

### V-G staining and enzymatic reactions

Van Gieson's method was used to demonstrate collagen fibers<sup>[7]</sup>. HPIAS-1000 auto medical image analyzing system was used for quantitative assessment of collagen fibers in liver. Ten middle power fields were selected randomly for the total area occupied by collagen fibers and its ratio against the total area observed. Activity of monoamine oxidase (MAO) was demonstrated using 15  $\mu$ m-thick frozen sections with the chayen method, that of succinic dehydrogenase (SDH) was visualized using lojda method, that of ALP with culling method, and that of ACP with Bancroft method<sup>[8]</sup>. NOS was shown using NADPH method<sup>[9]</sup>.

### Statistics

Statistical analysis with ANOVA: Data were presented as  $\bar{x} \pm s$ . Significant differences were determined by using ANOVA in statistical software SPSS11.0. Results were considered significant when  $P < 0.05$ .

## RESULTS

### Histologic and ultrastructural findings

Liver sample from group D showed loss of normal lobular architecture. The parenchyma showed steatosis, cellular swelling, necrosis, and was divided into rounded nodules, separated by bands of fibrous tissues, while in groups A, B and C, the steatosis was not severe and the fibrosis was not so pronounced, without any pseudo-lobule observed (Figures 1, 2). Hepatocellular degeneration was frequently seen in the intoxicated animals under electron microscope, characterized by marked swelling of mitochondria, loss of rough endoplasmic reticulum structures and distention of them. Glycogen particles were greatly reduced and more lipid droplets were found in the cytoplasmic compartment. In some hepatocytes, nuclear irregularity was noted, lipid droplets and some components resembling rough endoplasmic reticulum (nuclear or pseudo-nuclear inclusions) were also found within the nuclei. A few lipid droplets were found in the cytoplasm in the Ganyanping-treated groups (Figures 3, 4).

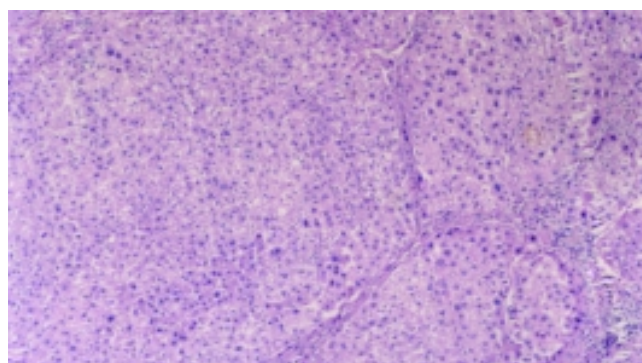
### VG staining

Fibrosis was shown in group D by VG staining, with hepatic parenchyma separated by the rough, red-stained fibrotic septa. The change was less pronounced in the Ganyanping-treated groups. The total collagen-deposited area and ratio in group D, but not in the Ganyanping-treated groups ( $P < 0.05$ ), were increased compared to those in the control group ( $P < 0.001$ ) (Table 1, Figures 5, 6).

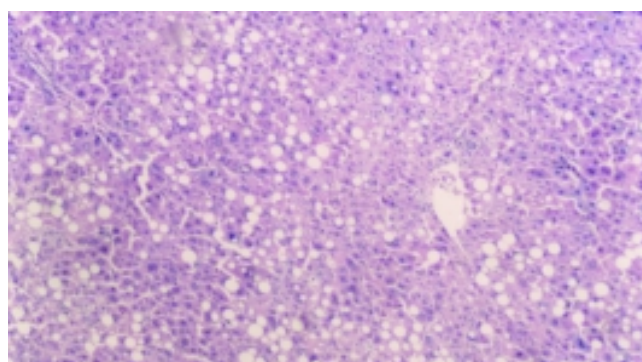
**Table 1** Area occupied by fibrotic septa and its ratio to the total area examined

Groups	n	Area covered by fibrotic septa ( $\mu\text{m}^2$ )	Ratio (%)
N	8	35.30 $\pm$ 13.86 <sup>b</sup>	0.32 $\pm$ 0.18 <sup>b</sup>
A	15	200.74 $\pm$ 33.84 <sup>a</sup>	1.63 $\pm$ 0.45 <sup>a</sup>
B	15	148.73 $\pm$ 45.89 <sup>a</sup>	1.16 $\pm$ 0.33 <sup>a</sup>
C	15	158.73 $\pm$ 40.89 <sup>a</sup>	1.12 $\pm$ 0.28 <sup>a</sup>
D	15	840.23 $\pm$ 81.65	7.00 $\pm$ 0.90

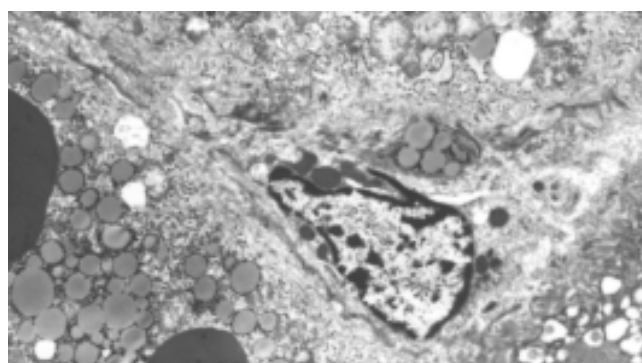
<sup>a</sup> $P < 0.05$  vs Group D, <sup>b</sup> $P < 0.001$  vs Group D.



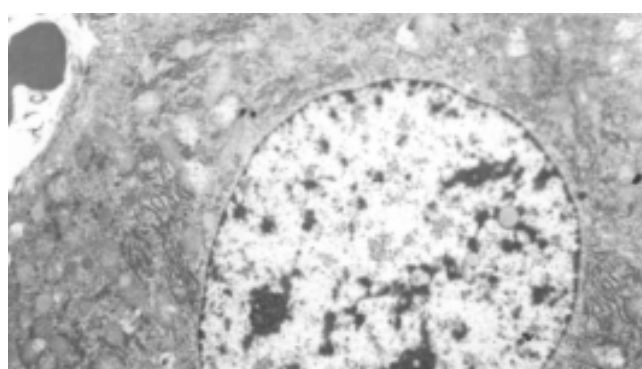
**Figure 1** Loss of normal lobular architecture, some had pseudo lobule formation in the CCl<sub>4</sub> intoxicated groups. HE $\times$ 100.



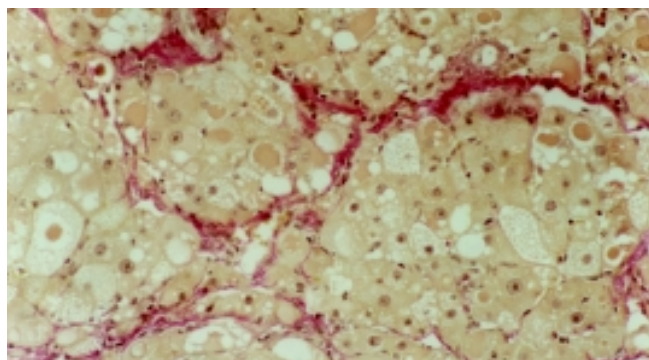
**Figure 2** Steatosis was not severe and fibrosis was not so pronounced, without any pseudo-lobule formation in the Ganyanping-treated groups. HE $\times$ 100.



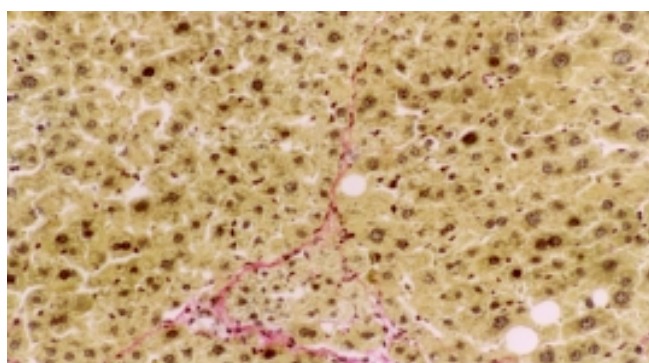
**Figure 3** The numbers of hepatic stellate cells and collagen fibrils increased in Disse's space and hepatocellular degeneration were frequently seen in the CCl<sub>4</sub> intoxicated groups.  $\times$ 4 000.



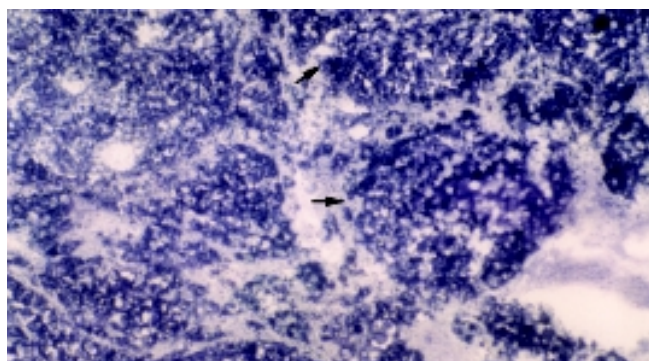
**Figure 4** Most of hepatocytes showed basically normal ultra-structure and a few lipid droplets were found in the cytoplasm in the Ganyanping-treated groups.  $\times$ 4 000.



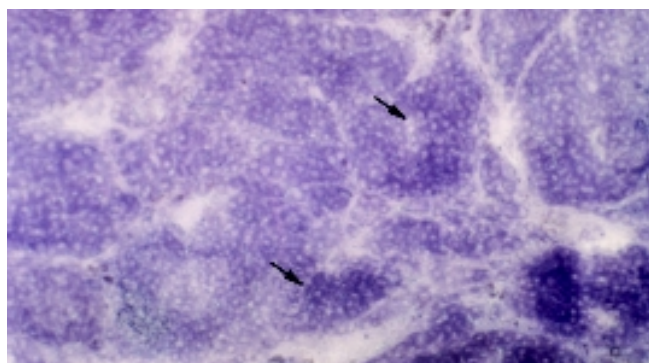
**Figure 5** Hepatic parenchyma separated by the rough, red-stained fibrotic septa in the CCl<sub>4</sub> intoxicated groups. VG×200.



**Figure 6** Collagen fibrosis was less pronounced in the Ganyanping-treated groups. VG×200.



**Figure 7** Increase in the activities of MAO(+++) in the CCl<sub>4</sub> intoxicated groups. ×75.



**Figure 8** Decrease in the activities of MAO in the Ganyanping-treated groups (××). ×75.

#### Enzymatical reactions

Activities of MAO, SDH, ALP and NOS were demonstrated in

frozen sections with the procedures described above. Those for MAO and ACP were found to be elevated and that of SDH was reduced in group D compared to those in the control group. The changes were not so marked in any of the Ganyanping-treated groups (Tables 2, 3; Figures 7, 8).

**Table 2** Semiquantitative assessment of enzymatic activities in different liver samples

Groups	n	MAO	SDH	ACP	LDH	NOS	ALP
N	8	++	+++	+	++	++	++
A	15	++	+++	++	+ <sub>1</sub> ŷ	++	++
B	15	++	+++	+	++	++	++
C	15	++	+++	+	++	++	++
D	15	+++ <sub>1</sub> ü	+++ <sub>1</sub> ŷ	+++ <sub>1</sub> ü	+ <sub>1</sub> ŷ	++	++

+: positive; ++: moderately positive; +++: strongly positive; <sub>1</sub>ü activity enhancement; <sub>1</sub>ŷ activity weakened.

**Table 3** Quantitative observation of the liver enzymatic activities (mean absorbance)

Groups	n	MAO	SDH	ACP	LDH
N	8	0.2042±0.041 <sup>a</sup>	0.4057±0.030 <sup>a</sup>	0.1160±0.0338 <sup>a</sup>	0.1685±0.0103
A	15	0.3201±0.066 <sup>a</sup>	0.2917±0.045 <sup>a</sup>	0.1623±0.0246 <sup>a</sup>	0.1948±0.0319
B	15	0.3308±0.079 <sup>a</sup>	0.3380±0.103 <sup>a</sup>	0.2101±0.0342 <sup>a</sup>	0.1331±0.0071
C	15	0.1835±0.060 <sup>a</sup>	0.3939±0.0434 <sup>a</sup>	0.1884±0.0542 <sup>a</sup>	0.1757±0.0216
D	15	0.5022±0.149	0.1819±0.1049	0.4235±0.0727	0.1656±0.0145

<sup>a</sup>P<0.05 vs group D.

#### DISCUSSION

It remains a problem to prevent cirrhosis or to control its progression in patients with a chronic liver disease<sup>[10,11]</sup>. Great efforts have been made to find safe and effective drugs. Recent clinical and experimental observations have demonstrated that Chinese medicines might be of some preventive and therapeutic values against fibrosis<sup>[12-20]</sup>. Ganyanping, prepared according to the regime of Li Shaobai *et al*<sup>[21]</sup>, has been used for many years for this purpose. However, its effect and associated mechanism need further experimental evidence. For this reason, we used CCl<sub>4</sub> to induce liver fibrosis and investigated herein the effects of Ganyanping on fibrosis.

Liver fibrosis is a pathologic process associated with over production and deposition of collagen fibers<sup>[22, 23]</sup> and other extracellular matrix (ECM) components<sup>[24-27]</sup> resulted from various hepatic diseases. It is considered a necessary intermediate step between liver parenchyma injury and cirrhosis<sup>[28]</sup>. Activation of hepatic stellate cells (HSCs) has been shown to be one of the critical steps during hepatic fibrosis<sup>[29-34]</sup>. It is associated to a number of pathological factors, resulting in ECM deposition and hepatic fibrosis. This was also observed in the fibrosis caused by CCl<sub>4</sub> intoxication, and this process could be effectively controlled by treatment with Ganyanping. The preparation was found to be inhibitory in the collagen production.

MAO is used as a marker for evaluating hepatic function in cirrhosis, its elevation indicating liver damage<sup>[35]</sup>. An increase in MAO activity was observed in the intoxication group. Ganyanping was found to be able to abrogate this change. Thus, Ganyanping is considered to have some anti-cirrhotic effect. SDH is a rate-limiting enzyme in the tricarboxylic acid cycle<sup>[36,37]</sup>. The elevation of its activities reflects more active metabolism. Our data indicate the treatment with Ganyanping might be helpful for liver parenchyma cells to

maintain this SDH activity through the intoxication. The treatment was also shown to be helpful for stabilizing the lysosome membrane in chronic hepatic injury, reflected by its interference to ACP values of the animals received intoxication. In the present study, activity of NOS was shown to be reduced in the CCl<sub>4</sub>-intoxicated group, but the effect was partially abrogated by the treatment with Ganyanping, indicating that the treatment might help the liver to recover its function through the stress caused by CCl<sub>4</sub> administration.

In summary, Ganyanping was found to play some anti-fibrotic role. According to the theory of traditional Chinese medicine, Ganyanping may possess multiple pharmaceutical effects, such as invigorating “qi” and activating “blood”, dispersing stagnated hepatic “qi” and facilitating the discharge of “bile”, delivering “heat” and “toxins”, and eliminating “dampness” in view of its composition. Our experimental data have proved that Ganyanping could reduce oxygen-derived free radicals, and enhance the cellular metabolism and immune function, all resulting in an anti-fibrotic effect. Ganyanping may be used as a safe and effective preparation for patients with fibrosis.

## REFERENCES

- 1 **Li XG**, Li SB, Wang TC, Tang WX, Du LJ, Zhang WY. Protective Effect of Gan Yanping on Con A induced liver injury. *Zhonghua Ganzhangbing Zazhi* 1996; **4**: 243-244
- 2 **Tang WX**, Yu DX, Dan ZL, Zhang WY, Du LJ, Li SB. Study on protective effect of Traditional Chinese herbs (Gan Yanping) on acute liver injury induced by D-GalN in rats. *Tongji Yike Daxue Xuebao* 1998; **27**: 56-58
- 3 **Tang WX**, Yu DX, Dan ZL, Du LJ, Zhang WY, Li SB. An experimental study on the effect of Gan Yanping on Collagen Fiber in rat Chronic Liver Induced by CCl<sub>4</sub>. *Weichang Bingxue He Ganbingxue Zazhi* 1998; **7**: 167-169
- 4 **Du LJ**, Tang WX, Dan ZL, Zhang WY, Li SB. Protective effect of gan yanping on CCl<sub>4</sub> induced liver fibrosis in rats. *Shijie Huaren Xiaohua Zazhi* 1998; **6**: 22-23
- 5 **Du LJ**, Tang WX, Dan ZL, Zhang WY, Li SB. Study of protective effect of GanYanping in acute liver injury model. *Tongji Yike Daxue Xuebao* 1997; **26**: 149-151
- 6 **Tang WX**, Du LJ, Zhang WY, Xiong XK, Zhang Y. Histochemistry study on the protective effect of Gan Yanping from liver injury induced by D-GalN in rats. *Zhongguo Zuzhi Huaxue He Xibao Huaxue Zazhi* 1996; **5**: 397-340
- 7 **Wei HS**, Li DG, Lu HM, Zhan YT, Wang ZR, Huang X, Zhang J, Chang JL, Xu OF. Effects of AT1 receptor antagonist, losartan, on rat hepatic induced by CCl<sub>4</sub>. *World J Gastroenterol* 2000; **6**: 540-545
- 8 **Pen CN**, Wang Y, Niu JZ, Weng JG, Shi SS, Shun PW, Piao YJ, Li SG, She Y, Guo SG, Peng JY, Ge ZH, Xie JY, Xiong XK. Histochemistry.1. Beijing: People's Medical Publishing Company 2001: 392-528
- 9 **Punkt K**, Zaitsev S, Vwlnner M, Schreiter T, Fitzl G, Buchwalow LB. Myopathy-dependent changes in activity of ATPase SDH and GPDH and NOS expression in the different fibre types of hamster muscles. *Acta histochem* 2002; **104**: 15-22
- 10 **Zeng MD**. Treatment of liver fibrosis. *Zhonghua Ganzhangbing Zazhi* 2001; **9**: 68-69
- 11 **Dai WJ**, Jiang HC. Advances in gene therapy of liver cirrhosis: a review. *World J Gastroenterol* 2001; **7**: 1-8
- 12 **Zheng LN**, Han T, Wang BE, Ma XM, Jia JD, Qian SC, Gao YT. Effect of Bupleurum on collagen content in hepatic stellate cell media *in vitro*. *Tianjing YiKe Daxue Xuebao* 2001; **7**: 502-504
- 13 **Cheng ML**, Wu YY, Huang KF, Luo TY, Ding YS, Lu YY, Liu RC, Wu J. Clinical study on the treatment of liver fibrosis due to hepatitis B by IFN- $\alpha$ 1 and traditional medicine preparation. *World J Gastroenterol* 1999; **5**: 267-269
- 14 **Liu P**, Liu C, Xu LM, Xue HM, Liu CH, Zhang ZQ. Effects of Fuzheng Huayu 319 recipe on liver fibrosis in chronic hepatitis B. *World J Gastroenterol* 1998; **4**: 348-353
- 15 **Li JM**. Recent condition of traditional chinese herb on treatment of fibrosis. *Tianjing Zhongyi Xueyuan Xuebao* 2002; **21**: 37-38
- 16 **Cai DY**, Zhao G, Chen JC, Ye GM, Bing FH, Fan BW. Therapeutic effect of Zijin capsule in liver fibrosis in rats. *World J Gastroenterol* 1998; **4**: 260-263
- 17 **Li JC**, Ding SP, Xu J. Regulating effect of Chinese herbal medicine on the peritoneal lymphatic stomata in enhancing ascites absorption of experimental hepatofibrotic mice. *World J Gastroenterol* 2002; **8**: 333-337
- 18 **Liu P**, Hu YY, Liu C, Zhu DY, Xue HM, Xu ZQ, Xu LM, Liu CH, Gu HT, Zhang ZQ. Clinical observation of salvianolic acid B in treatment of liver fibrosis in chronic hepatitis B. *World J Gastroenterol* 2002; **8**: 679-685
- 19 **Shen BS**, Wong XG, Qiao HC, Lu ZH, Han Q, Wang W, Guan HL. Preventive effect of Sanjia Yigan granule in hepatofibrosis in rats. *Shijie Huaren Xiaohua Zazhi* 1998; **6**: 386-388
- 20 **Liu CH**, Hu YY, Wang XL, Liu P, Xu LM. Effects of salvianolic acid-A on NIH/3T3 fibroblast proliferation, collagen synthesis and gene expression. *World J Gastroenterol* 2000; **6**: 361-364
- 21 **Du LJ**, Tang WX, Zhang WY, Li SB. Effect of Gan Yanping on Cytokines in acute liver injury induced by D-GalN in rats. *Zhongxiyi Jiehe Ganbingxue Zazhi* 1998; **8**: 28-30
- 22 **Wang AM**, Wang BE, Yang YW, Zhang B, Jiang LA, Du SC. Interstitial collagenase gene expression in patients with liver disease. *Linchuang Gandanbing Zazhi* 2000; **16**: 90-91
- 23 **Nie QH**, Cheng YQ, Xie YM, Zhou YX, Cao YZ. Inhibiting effect of antisense oligonucleotides phosphorothioate on gene expression of TIMP-1 in rat liver fibrosis. *World J Gastroenterol* 2001; **7**: 363-369
- 24 **Wang TL**, Wang BE, Zhang HH, Liu X, Dan ZP, Zhang J, Ma H, Li XM, Li NZ. Pathology study of the therapeutic effect on HBV-related liver fibrosis with herbal compound 861. *Zhongguo Weichang Bingxue He Ganbingxue Zazhi* 1998; **7**: 148-150
- 25 **Wang TL**, Zhang B, Jie J. Effect of anti-fibrosis compound on collagen expression of hepatic cells in experimental liver fibrosis of rats. *World J Gastroenterol* 2000; **6**: 877-880
- 26 **George J**, Rao KR, Stem R, Chandrakasan G. Dimethylnitrosamine-induced liver injury in rats: the early deposition of collagen. *Toxicology* 2001; **156**: 129-138
- 27 **Wang BE**. Hepatic stellate cell and Fibrosis. *Zhonghua Ganzhangbing Zazhi* 2000; **8**: 197-199
- 28 **Wang GY**, Cai WM, Wang JQ, Weng HR, Cheng F. An experimental study of histological quantitative method in the diagnosis of hepatic fibrosis. *Zhonghua Ganzhangbing Zazhi* 1998; **6**: 201-202
- 29 **Cheng ML**, Wu J, Wang HQ, Xue LM, Tan YZ, Ping L, Li CX, Huang NH, Yao YM, Ren LZ, Ye L, Li L, Jia ML. Effect of Maotai liquor in inducing metallothioneins and on hepatic stellate cells. *World J Gastroenterol* 2002; **8**: 520-523
- 30 **Wei HS**, Lu HM, Li DG, Zhan YT, Wang ZR, Huang X, Cheng JL, Xu QF. The regulatory role of AT 1 receptor on activated HSCs in hepatic fibrogenesis: effects of RAS inhibitors on hepatic fibrosis induced by CCl<sub>4</sub>. *World J Gastroenterol* 2000; **6**: 824-828
- 31 **Zhan YT**, Zhan CY, Chen YW, Li DG. Hepatic stellate cell and Fibrosis. *Linchuang Gandanbing Zazhi* 2000; **16**: 71-73
- 32 **Lou Y**, Dai LL, Shen DM. Research progress of hepatic stellate cell and fibrosis. *Zhonghua Ganzhangbing Zazhi* 2000; **8**: 251-252
- 33 **Liu J**, Zhao FD, Jia SJ, Han QR. The study of VG staining for liver fibrosis of chronic liver diseases. *Jilin Yixueyuan Xuebao* 1998; **18**: 21-22
- 34 **Ma H**, Wang BE, Ma XM, Jia JD. Effect of compound 861 on rat hepatic cell collagen synthesis and degradation *in vitro*. *Zhonghua Ganzhangbing Zazhi* 1999; **7**: 30-32
- 35 **Wang W**, Liu HL. Significance and change of HA, LN and MAO of hepatitis B patients' serum. *Bao Tou Yixue Zazhi* 2001; **17**: 41-42
- 36 **Shah V**, Toruner M, Haddad F, Cadelina G, Papapetropoulos A, Choo K, Sessa WC, Groszmann RJ. Impaired endothelial nitric oxide synthase activity associated with enhanced caveolin binding in experimental cirrhosis in the rat. *Gastroenterology* 1999; **117**: 1222-1228
- 37 **Song BC**, Yin SY, Tang WX, Xiong XK. Study on enzyme histochemistry of experimental cirrhosis liver. *Zhongguo Zuzhi Huaxue he Xibao Huaxue Zazhi* 1999; **8**: 47-50