

# Activation of phosphorylating-p38 mitogen-activated protein kinase and its relationship with localization of intestinal stem cells in rats after ischemia-reperfusion injury

Xiao-Bing Fu, Feng Xing, Yin-Hui Yang, Tong-Zhu Sun, Bao-Chen Guo

**Xiao-Bing Fu, Feng Xing, Yin-Hui Yang, Tong-Zhu Sun, Bao-Chen Guo**, Wound Healing and Cell Biology Laboratory, Institute of Burns, 304 Hospital, Trauma Center of Postgraduate Medical College, Beijing 100037, China

**Supported by** the National Basic Science and Development Program (973 Program, No. G1999054204), Grant for National Distinguished Young Scientists, No. 39525024, Grant for National Natural Science Foundation of China, No. 30170966, 30230370

**Correspondence to:** Xiao-Bing Fu, MD, Wound Healing and Cell Biology Laboratory, 304 Hospital, Institute of Burns, Trauma Center of Postgraduate Medical College, 51 Fu Cheng Road, Beijing 100037, China. fuxb@cgw.net.cn

**Telephone:** +86-10-66867396 **Fax:** +86-10-88416390

**Received:** 2003-05-10 **Accepted:** 2003-06-07

## Abstract

**AIM:** To investigate the expression of phosphorylating p38 mitogen-activated protein kinase (MAPK) in rat small intestine after ischemia-reperfusion (I/R) insult and its relationship with the localization of intestinal stem cells.

**METHODS:** Forty-eight Wistar rats were divided randomly into three groups, namely intestinal ischemia-reperfusion group (R), intestinal ischemia group (I) and sham-operated control group (C). In group I, the animals were killed 45 minutes after superior mesenteric artery (SMA) occlusion, while in group R the rats sustained SMA occlusion for 45 minutes and reperfusion for 2, 6, 12 or 24 hours respectively. In sham-operated control group, SMA was separated, but without occlusion. The activity of plasma diamine oxidase (DAO) was determined. Intestinal tissue samples were also taken for histological analysis and immunohistochemical analysis of MAPK p38 detection and intestinal stem cell localization.

**RESULTS:** The changes in histological structure and plasma DAO levels indicated that the intestinal barrier was damaged after intestinal I/R injury. In group C and I, each crypt contained 5-6 p38 MAPK positive cells, which were mainly located in the lower region of the crypts. This was consistent with the distribution of intestinal stem cells. The presence of positive cells in crypts increased with the time of reperfusion and reached its peak at 12 hours after reperfusion (35.6 %).

**CONCLUSION:** After intestinal I/R injury, the expression of phosphorylating-p38 MAPK in small intestine increased with the duration of reperfusion, and its distribution coincided with that of intestinal stem cells and their daughter cells, indicating that phosphorylating-p38 might be a possible marker of intestinal stem cells.

Fu XB, Xing F, Yang YH, Sun TZ, Guo BC. Activation of phosphorylating-p38 mitogen-activated protein kinase and its relationship with localization of intestinal stem cells in rats after ischemia-reperfusion injury. *World J Gastroenterol* 2003; 9(9):2036-2039  
<http://www.wjgnet.com/1007-9327/9/2036.asp>

## INTRODUCTION

The four principal differentiated cell lineages of the intestinal epithelium are derived from a common multipotent stem cell located near the base of each crypt. It is observed that normally there are about 1-4 stem cells in each small intestinal crypt. These crypt stem cells are divided to produce a daughter stem cell as well as more rapidly to replicate transit cells, which in turn undergo 4-6 rapid cell divisions in the proliferative zone located in the lower half of each crypt<sup>[1,2]</sup>. The mitogen-activated protein kinase (MAPK) cascade, a cytoplasm protein kinase which requires dual phosphorylation on specific threonine and tyrosine residues for their activation, can transmit the mitogen or the differentiating signals from the cell surface into the nucleus, thus regulating the gene expression. p38MAPK is an important member of the MAPK family<sup>[3-5]</sup>. There has been hardly any report to explore the expression characteristics of phosphorylating-p38 mitogen-activated protein kinase (MAPK) in rat small intestine after ischemia-reperfusion (I/R) insult and its relationship with the localization of intestinal stem cells. In the present study, we used SMA occlusion rats as an animal model to determine the expression of phosphorylating-p38 MAPK after intestinal I/R injury, and to investigate its relationship with small intestinal stem cells.

## MATERIALS AND METHODS

### *Animal model and experimental design*

Forty-eight healthy male Wistar rats (Animal Centre, Chinese Academy of Military Medical Sciences) weighing 200-250 g were used. After 1 week adaption in our animal centre and 12 hours fasting and free drinking just before the experiment, the animals were anaesthetised with 3 % sodium pentobarbital. Ischemia/reperfusion injury was produced by clamping the superior mesenteric artery (SMA) for 45 minutes and loosening the splint to form reperfusion injury. The animals were divided randomly into ischemia-reperfusion insult group (R), ischemia only group (I) and sham-operated control group (C). According to the different periods after reperfusion, group R was further divided into 2, 6, 12 and 24 hours subgroups. In group C, SMA was separated but without occlusion, and samples were taken after exposure of SMA for 45 minutes. In group I, animals were killed after occlusion for 45 minutes. In group R, rats were killed at different time points after reperfusion. Blood samples and intestinal tissue biopsies were taken. Blood samples were centrifuged and serum was frozen to measure plasma diamine oxidase (DAO). Tissue biopsies were fixed with 4 % paraformaldehyde for immunohistochemical detection of MAPK p38 and localization of stem cells.

### *Detection index*

**Plasma DAO activity** Plasma DAO activity was determined according to references 6 and 7.

**Histological staining** Polyformalin fixed, paraffin embedded small intestinal samples were also cut into 5 µm thick sections,

deparaffinized in xylene, and rehydrated in graded ethanol, and then stained with haematoxylin-eosine (HE) for histological observation under light microscope (Olympus, Japan).

#### Measurement of phosphorylated forms of p38 MAPK

Formalin-fixed, paraffin-embedded small intestinal tissues were used to measure the phosphorylated forms of p38 MAPK by immunohistochemistry. Immunohistochemistry was performed according to the instructions of the Power Vision™ kit (Santa Cruze, USA). Briefly, sections (5 µm) were dewaxed and rehydrated in graded alcohols. Endogenous peroxidase activity was quenched, antigen retrieval was performed by heating for 20 minutes at 100 °C in 0.01 mol/L sodium citrate. The primary monoclonal antibody for p38 MAPK (Cell Signaling Technology, Inc., USA) was diluted 1:100 with the dilute buffer and incubated for 40 minutes at 37 °C. Then sections were incubated with HRP-conjugated secondary antibody (Santa Cruz, USA) for 20 minutes at 37 °C. Positive expression was detected with diaminobenzidine (DAB, Sigma, St. Louis, MO, USA). Sections were lightly counterstained with hematoxylin, dehydrated in graded alcohols, and mounted. As negative control, the sections were processed in the same way as above, but PBS was used as primary antibody instead of the p38 MAPK monoclonal antibodies.

#### Results determination

The results of positive staining cells and their distribution were observed under 10 times eyepiece and 40 times object-lens microscope. Visions of relatively good morphology of crypts were chosen to count the positive staining cells. Among the cells in the centre of crypt basement, positive staining cells and negative cells were counted upward till reaching the boundary to villus. Fifty intestinal crypts were required for counting, and then the ratio of positive cells were calculated and analyzed.

#### Statistical analysis

Data were expressed as mean ± standard error. Comparisons between groups of data were analyzed by Students *t* test. *P* values <0.05 were considered as statistically significant.

## RESULTS

#### Histological changes

It was found under light microscopy that reperfusion resulted in the damage of intestinal barrier. HE staining showed that partial loss of mucosa was observed after 2 hours of reperfusion, while at 6 hours after reperfusion, the damage of epithelial cells of intestinal mucosa, hemorrhage and necrosis were observed and accompanied by inflammatory cell infiltration in intestinal wall.

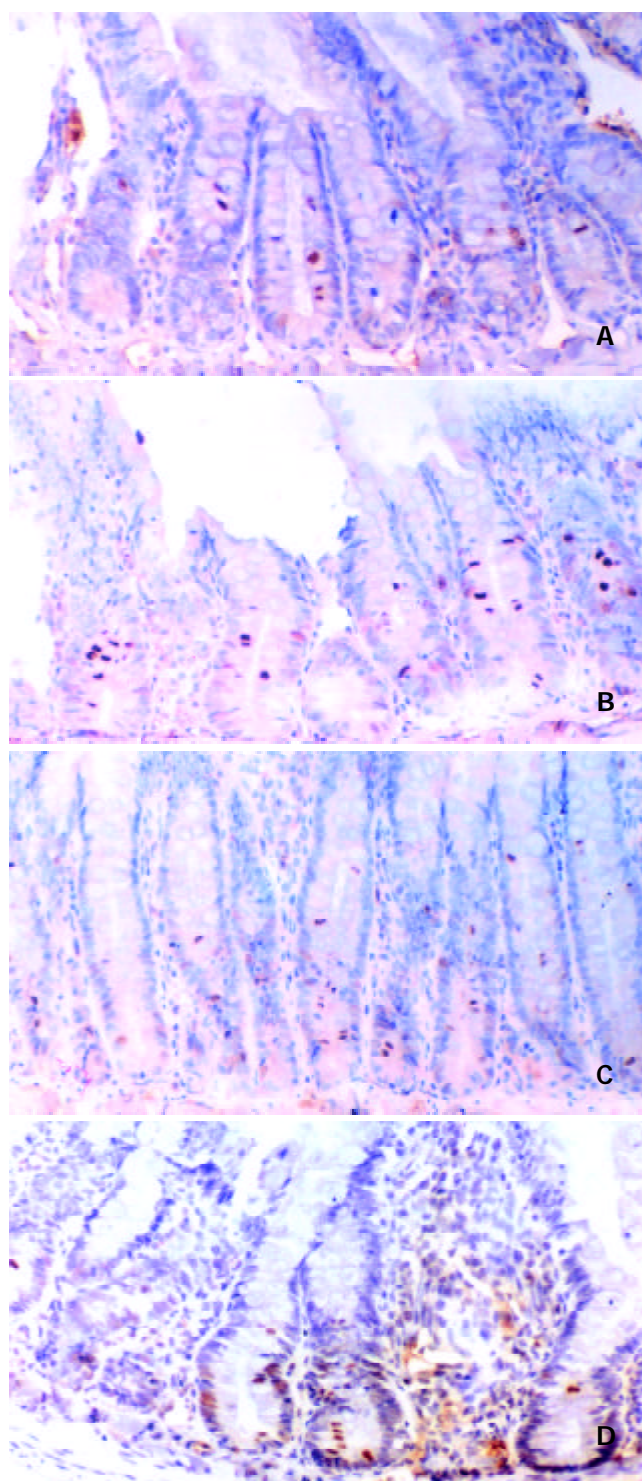
#### Changes of plasma DAO activity

Plasma DAO levels elevated from 2 hours after reperfusion in all groups, and reached their peak at 6 hours, which was an increase of 1.7 fold as compared with those in normal controls (*P*<0.05), and then decreased gradually, almost back to normal at 24 hours after the reperfusion (Table 1).

**Table 1** Changes of plasma DAO activities in different groups

Groups	DAO activity (U/ml)	Groups	DAO activity (U/ml)
Group C	0.70±0.19	Group R6	1.20±0.24 <sup>b</sup>
Group I	0.76±0.16	Group R12	1.00±0.28 <sup>a</sup>
Group R2	0.90±0.23	Group R24	0.80±0.17

<sup>a</sup>*P*<0.05, <sup>b</sup>*P*<0.01 compared with control.



**Figure 1** The expression of phosphorylated p38 MAPK in control group (A), ischemia group (B), ischemia-reperfusion 6 h (C) and 12 h (D) groups. The positive expression of p38 MAPK signals was localized mainly in the lower half of the crypts and in the cytoplasm of the crypt cells. The positively stained cells increased remarkably after 6 hours, and reached their peak at 12 hours after reperfusion, which was about 35.6 % of the total cells in crypts. At this stage, the positive staining was primarily localized in nucleus of crypt cells.

#### P38 MAPK expression

The immunohistochemical staining for phosphorylated forms of p38 MAPK was evaluated and summarized in Table 2. In groups C and I, there were only 5-6 p38 MAPK positive staining cells in each crypt, which were localized mainly in the lower half of the crypts and in the cytoplasm of the crypt cells. When the cell in base of crypt was regarded as layer 1,

then upward was counted till reaching the boundary to villus, there were normally about 30 cell layers. The p38 MAPK positive staining cells were mainly localized between layers 2 and 10, few positive cells were seen beyond this scale. The number was decreased slightly after 2 hours of reperfusion. The positively stained cells increased remarkably after 6 hours, and peaked at 12 hours after reperfusion, which was about 35.6 % of the total cells in crypts. At this stage, the positive staining was primarily localized in the nuclei of crypt cells. The number of positive cells was decreased and almost returned to normal after 24 hours of reperfusion. A few positive cells were found in the matrix of villus. However, no positive cells were observed in the epithelium of villus (Figure 1).

**Table 2** Ratio of p38 MAPK positively stained cells to total cells in small intestinal crypts ( $\bar{x} \pm s$ )

Groups	Expression ratio (%)	Groups	Expression ratio (%)
Group C	15.6 $\pm$ 1.5	Group R6	27.0 $\pm$ 1.8 <sup>a</sup>
Group I	14.0 $\pm$ 1.0	Group R12	35.6 $\pm$ 2.6 <sup>b</sup>
Group R2	10.5 $\pm$ 0.8	Group R24	19.3 $\pm$ 2.1

<sup>a</sup> $P < 0.05$ , <sup>b</sup> $P < 0.01$  compared with control.

## DISCUSSION

It has become the center to study the internal organ injury and repair after severe trauma and burns in recent years and a new focus to study stem cells and intestinal organ repair<sup>[8-13]</sup>. Especially, the regulatory effects of growth factors and stem cells in internal organs are the very important field<sup>[14,15]</sup>. However, little is known about the molecular mechanisms that regulate the dynamics of stem cell replication or stem cell fate in intestinal epithelium during either normal epithelial renewal or regeneration of a functional epithelium after injury. Unfortunately, there have been no sensitive markers which can be used to identify the intestinal stem cells. In the previous studies, some positive expression of both PCNA and Ki67 in G1 phase stem cells, transit cells and other daughter cells was observed, which made them unable to act as markers for stem cells, thus becoming extremely difficult to study intestinal stem cells<sup>[16-18]</sup>. This finding raises a basic question: is there any other index which can be used as the suitable marker for stem cells?

Mitogen-activated protein kinases (MAPK) are mainly composed of the "extracellular signal regulated" p42/p44 MAPK and "stress-regulated" (SR-MAPKs) stress-activated protein kinases (SAPKs)/c-Jun N-terminal kinases (JNKs) and the p38-MAPKs. On stimulation, MAPKs translocate to the nuclei where they may phosphorylate nuclear transcription factors, thus regulating gene expression<sup>[19,20]</sup>. Philips *et al*<sup>[21]</sup> found from an *in vitro* study of mouse embryo fibroblasts, that inhibiting the activation of p38 could improve the expression of cyclin A, which is closely related to cell proliferation. p38 not only promotes the apoptosis in hematopoietic cells containing some stem cell properties, but also mediates the proliferating effect of IL-1. Various MAPK subtypes have synergetic effects<sup>[22]</sup>. p38 may have a dual function, and is tissue specific. Its effect depends on the injury degree, period and its activated condition. p38 also has a close correlation with the activation of upstream and downstream components of signaling pathways.

p38 $\gamma$ , a subtype of p38, is involved in myoblast differentiation<sup>[23]</sup> and its expression is enhanced with hypoxia. p38 $\gamma$  mediates the signaling pathway of DNA damage induced by  $\gamma$  ray, which protects DNA from radiative damage by stopping the cells in G2 phase. p38 may exert its effect by different subtypes.

Up to date, the studies of p38 in intestinal cells have remained on *in vitro* tissues and cultured cells. It has been concluded that p38 is related to the differentiation of intestinal crypts and villi<sup>[24]</sup>. The results of this study showed that in normal rat small intestinal cells, phosphorylated forms of p38 MAPK were mainly located in the base of crypts and cytoplasm of crypt cells, and very few in the nuclei. This localization was similar to those of intestinal stem cells demonstrated by other investigations<sup>[1,2]</sup>. These positive cells might be composed of stem cells, daughter stem cells as well as more rapidly replicating transit cells. After 45 minutes' ischemia insults, no significant difference was found in the number of p38 positive cells, indicating that ischemia can not activate p38 pathway. Positively stained p38 cells increased markedly after 6 hours of reperfusion, which might be a result of activation of p38 MAPK signaling pathway. DAO is located in the upper part of intestinal mucosa in human as well as in mammals, and is a highly active intracellular enzyme. Changes in DAO activity are an ideal index to investigate intestinal barrier function damage after trauma, especially changes in plasma DAO activity<sup>[25-28]</sup>. Our histological observations and DAO examinations showed that I/R injury induced the damage of intestinal barrier function. The activation of p38 MAPK might be mediated by LPS, TNF $\alpha$  and peroxides generated after small intestinal damage. However we found no positively stained p38 cells in villus epithelial cells both in normal and injured intestines, which was different from the previous *in vitro* studies. This might be related to the ischemia period, injury degree we chose in the study and the distribution of p38 MAPK and its subtypes in small intestines<sup>[29-31]</sup>.

In summary, our results indicate that intestinal I/R injury can induce the activation of p38 MAPK pathway. The positively expressed cell number and their localization are more likely close to intestinal stem cells. Compared with PCNA and Ki67, the distribution and expression characteristics of p38 MAPK are similar to the intestinal stem cells. Based on these data, we suppose that p38 MAPK may not be an ideal marker for intestinal stem cells, it is more close to the goal and worthy of further investigation.

## REFERENCES

- Gordon JI, Hermiston ML. Differentiation and self-renewal in the mouse gastrointestinal epithelium. *Curr Opin Cell Biol* 1994; **6**: 795-803
- Potten CS, Booth C, Pritchard DM. The intestinal epithelial stem cell: the mucosal governor. *Int J Exp Pathol* 1997; **78**: 219-243
- Marshall CJ. Specificity of receptor tyrosine kinase signaling: transient versus sustained extracellular signal-regulated kinase activation. *Cell* 1995; **80**: 179-185
- Seeger R, Krebs EG. The MAPK signaling cascade. *FASEB J* 1995; **9**: 726-735
- Marais R, Wynne J, Treisman R. The SRF accessory protein Elk-1 contains a growth factor-regulated transcriptional activation domain. *Cell* 1993; **73**: 381-393
- Li JY, Yu Y, Hao J, Jin H, Xi HJ. Determination of deamine oxidase activity in intestinal tissue and blood using spectrophotometry. *An Ji Suan He Sheng Wu Zi Yuan* 1996; **18**: 28-30
- Brandt RB, Siegel SA, Waters MG, Bloch MH. Spectrophotometric assay for D-(-)-Lactate in plasma. *Anal Biochem* 1980; **102**: 39-46
- Fu X, Sheng Z, Wang Y, Ye Y, Xu M, Sun T, Zhou B. Basic fibroblast growth factor reduces the gut and liver morphologic and functional injuries after ischemia and reperfusion. *J Trauma* 1997; **42**: 1080-1085
- Yang YH, Fu XB, Sun TZ, Jiang LX, Gu XM. bFGF and TGF $\beta$  expression in rat kidneys after ischemic/reperfusional gut injury and its relationship with tissue repair. *World J Gastroenterol* 2000; **6**: 147-149
- Fu XB, Yang YH, Sun XQ, Sun TZ, Gu XM, Sheng ZY. Protective effects of endogenous basic fibroblast growth factor activated by 2, 3 butanedion monoxime on functional changes of ischemic

- intestine, liver and kidney in rats. *Zhongguo Weizhongbing Jijiu Yixue* 2000; **12**: 69-72
- 11 **Yang YH**, Fu XB, Sun TZ, Jiang LX, Gu XM. The effect of exogenous basic fibroblast growth factor on hepatic endogenous basic fibroblast growth factor and fibroblast growth factor receptor expression after intestinal ischemia-reperfusion injury. *Zhongguo Weizhongbing Jijiu Yixue* 1999; **11**: 734-736
  - 12 **Fu XB**, Yang YH, Sun TZ, Sun XQ, Gu XM, Chang GY, Sheng ZY. Effects of inhibition or anti-endogenous basic fibroblast growth factor on functional changes in intestine, liver and kidneys in rats after gut ischemia-reperfusion injury. *Zhongguo Weizhongbing Jijiu Yixue* 2000; **12**: 465-468
  - 13 **Yang YH**, Fu XB, Sun TZ, Jiang LX, Gu XM. Renal endogenous expression of basic fibroblast growth factor and transforming growth factor  $\beta$  after intestinal ischemia-reperfusion injury. *Zhongguo Weizhongbing Jijiu Yixue* 1999; **11**: 203-205
  - 14 **Dignass AU**, Tsunekawa S, Podolsky DK. Fibroblast growth factors modulate intestinal epithelial cell growth and migration. *Gastroenterology* 1994; **106**: 1254-1262
  - 15 **Estival A**, Monzat V, Miquel K, Gaubert F, Hollande E, Korc M, Vaysse N, Clemente F. Differential regulation of fibroblast growth factor (FGF) receptor-1 mRNA and protein by two molecular forms of basic FGF. Modulation of FGFR-1 mRNA stability. *J Biol Chem* 1996; **271**: 5663-5670
  - 16 **Bach SP**, Renahan AG, Potten CS. Stem cells: the intestinal stem cell as a paradigm. *Carcinogenesis* 2000; **21**: 469-476
  - 17 **Rhoads JM**, Argenzio RA, Chen W, Rippe RA, Westwick JK, Cox AD, Berschneider HM, Brenner DA. L-glutamine stimulates intestinal cell proliferation and activates mitogen-activated protein kinases. *Am J Physiol* 1997; **272**(5 Pt 1): G943-953
  - 18 **Houchen CW**, George RJ, Sturmoski MA, Cohn SM. FGF-2 enhances intestinal stem cell survival and its expression is induced after radiation injury. *Am J Physiol* 1999; **276**(1 Pt 1): G249-258
  - 19 **Paris F**, Fuks Z, Kang A, Capodieci P, Juan G, Ehleiter D, Haimovitz-Friedman A, Cordon-Cardo C, Kolesnick R. Endothelial apoptosis as the primary lesion initiating intestinal radiation damage in mice. *Science* 2001; **293**: 293-297
  - 20 **Nishida E**, Gotoh Y. The MAP kinase cascade is essential for diverse signal transduction pathways. *Trends Biochem Sci* 1993; **18**: 128-131
  - 21 **Philips A**, Roux P, Coulon V, Bellanger JM, Vie A, Vignais ML, Blanchard JM. Differential effect of Rac and Cdc42 on p38 kinase activity and cell cycle progression of nonadherent primary mouse fibroblasts. *J Biol Chem* 2000; **275**: 5911-5917
  - 22 **Birkenkamp KU**, Dokter WH, Esselink MT, Jonk LJ, Kruijer W, Vellenga E. A dual function for p38 MAP kinase in hematopoietic cells: involvement in apoptosis and cell activation. *Leukemia* 1999; **13**: 1037-1045
  - 23 **Lechner C**, Zahalka MA, Giot JF, Moller NP, Ullrich A. ERK6, a mitogen-activated protein kinase involved in C2C12 myoblast differentiation. *Proc Natl Acad Sci U S A* 1996; **93**: 4355-4359
  - 24 **Houde M**, Laprise P, Jean D, Blais M, Asselin C, Rivard N. Intestinal epithelial cell differentiation involves activation of p38 mitogen-activated protein kinase that regulates the homeobox transcription factor CDX2. *J Biol Chem* 2001; **276**: 21885-21894
  - 25 **Bragg LE**, Thompson JS, West WW. Intestinal diamine oxidase levels reflect ischemic injury. *J Surg Res* 1991; **50**: 228-233
  - 26 **Murray MJ**, Barbose BS, Cobb CF. Serum D (-)-lactate levels as a predictor of acute intestinal ischemia in a rat model. *J Surg Res* 1993; **54**: 507-509
  - 27 **Murray MJ**, Gonze MD, Nowak LR, Cobb CF. Serum D (-)-lactate levels as an aid to diagnosing acute intestinal ischemia. *Am J Surg* 1994; **167**: 575-578
  - 28 **Sun XQ**, Fu XB, Zhang R, Lü Y, Deng Q, Jiang XG, Sheng ZY. Relationship between plasma D(-)-lactate and intestinal damage after severe injuries in rats. *World J Gastroenterol* 2001; **7**: 555-558
  - 29 **Oliver BL**, Sha'afi RI, Hajjar JJ. Transforming growth factor- $\alpha$  and epidermal growth factor activate mitogen-activated protein kinase and its substrates in intestinal epithelial cells. *Proc Soc Exp Biol Med* 1995; **210**: 162-170
  - 30 **Goke M**, Kanai M, Lynch-Deraney K, Podolsky DK. Rapid mitogen-activated protein kinase activation by transforming growth factor  $\alpha$  in wounded rat intestinal epithelial cells. *Gastroenterology* 1998; **114**: 697-705
  - 31 **Aliaga JC**, Deschenes C, Beaulieu JF, Calvo EL, Rivard N. Requirement of the MAP kinase cascade for cell cycle progression and differentiation of human intestinal cells. *Am J Physiol* 1999; **277**(3Pt 1): G631-G641

Edited by Ma JY and Wang XL