

World Journal of *Diabetes*

World J Diabetes 2022 December 15; 13(12): 1001-1183



REVIEW

- 1001** Non-coding RNAs: Role in diabetic foot and wound healing
Tang YB, Uwimana MMP, Zhu SQ, Zhang LX, Wu Q, Liang ZX
- 1014** Diabetic foot ulcer: Challenges and future
Yang L, Rong GC, Wu QN
- 1035** Keeping an eye on the diabetic foot: The connection between diabetic eye disease and wound healing in the lower extremity
Ramsey DJ, Kwan JT, Sharma A
- 1049** Diabetic foot ulcers: Classification, risk factors and management
Wang X, Yuan CX, Xu B, Yu Z
- 1066** Mesenchymal stem cell-derived exosomes: The dawn of diabetic wound healing
Wu J, Chen LH, Sun SY, Li Y, Ran XW

MINIREVIEWS

- 1096** Prehabilitation of overweight and obese patients with dysglycemia awaiting bariatric surgery: Predicting the success of obesity treatment
Cigrovski Berkovic M, Bilic-Curcic I, Mrzljak A, Canecki Varzic S, Cigrovski V
- 1106** Diabetic foot ulcers: A devastating complication of diabetes mellitus continues non-stop in spite of new medical treatment modalities
Akkus G, Sert M
- 1122** Hyperbaric oxygen therapy and chemokine administration - a combination with potential therapeutic value for treating diabetic wounds
Venkataseshan J, Viswanathan P
- 1131** The role of artificial intelligence technology in the care of diabetic foot ulcers: the past, the present, and the future
Pappachan JM, Cassidy B, Fernandez CJ, Chandrabalan V, Yap MH
- 1140** Single nucleotide variations in the development of diabetic foot ulcer: A narrative review
Hu YJ, Song CS, Jiang N

ORIGINAL ARTICLE

Observational Study

- 1154** Baseline moderate-range albuminuria is associated with protection against severe COVID-19 pneumonia
Bashkin A, Shehadeh M, Shbita L, Namoura K, Haiek R, Kuyantseva E, Boulos Y, Yakir O, Kruzel-Davila E

SYSTEMATIC REVIEWS

- 1168** Comparison of gliclazide *vs* linagliptin on hypoglycemia and cardiovascular events in type 2 diabetes mellitus: A systematic review

Mohan V, Wangnoo S, Das S, Dhediya R, Gaurav K

ABOUT COVER

Editorial Board Member of *World Journal of Diabetes*, Joseph M Pappachan, Professor, MBBS, MD, MRCP, FRCP, Academic Editor, Consultant Endocrinologist, Senior Researcher, Department of Endocrinology & Metabolism, Lancashire Teaching Hospitals NHS Trust, Preston PR2 9HT & Manchester Metropolitan University, Manchester, M15 6BH, United Kingdom. drpappachan@yahoo.co.in

AIMS AND SCOPE

The primary aim of *World Journal of Diabetes* (*WJD*, *World J Diabetes*) is to provide scholars and readers from various fields of diabetes with a platform to publish high-quality basic and clinical research articles and communicate their research findings online.

WJD mainly publishes articles reporting research results and findings obtained in the field of diabetes and covering a wide range of topics including risk factors for diabetes, diabetes complications, experimental diabetes mellitus, type 1 diabetes mellitus, type 2 diabetes mellitus, gestational diabetes, diabetic angiopathies, diabetic cardiomyopathies, diabetic coma, diabetic ketoacidosis, diabetic nephropathies, diabetic neuropathies, Donohue syndrome, fetal macrosomia, and prediabetic state.

INDEXING/ABSTRACTING

The *WJD* is now abstracted and indexed in Science Citation Index Expanded (SCIE, also known as SciSearch®), Current Contents/Clinical Medicine, Journal Citation Reports/Science Edition, PubMed, PubMed Central, Reference Citation Analysis, China National Knowledge Infrastructure, China Science and Technology Journal Database, and Superstar Journals Database. The 2022 Edition of Journal Citation Reports® cites the 2021 impact factor (IF) for *WJD* as 4.560; IF without journal self cites: 4.450; 5-year IF: 5.370; Journal Citation Indicator: 0.62; Ranking: 62 among 146 journals in endocrinology and metabolism; and Quartile category: Q2.

RESPONSIBLE EDITORS FOR THIS ISSUE

Production Editor: *Yu-Xi Chen*; Production Department Director: *Xu Guo*; Editorial Office Director: *Yun-Xiaojiao Wu*.

NAME OF JOURNAL

World Journal of Diabetes

ISSN

ISSN 1948-9358 (online)

LAUNCH DATE

June 15, 2010

FREQUENCY

Monthly

EDITORS-IN-CHIEF

Lu Cai, Md. Shahidul Islam, Jian-Bo Xiao, Michael Horowitz

EDITORIAL BOARD MEMBERS

<https://www.wjnet.com/1948-9358/editorialboard.htm>

PUBLICATION DATE

December 15, 2022

COPYRIGHT

© 2022 Baishideng Publishing Group Inc

INSTRUCTIONS TO AUTHORS

<https://www.wjnet.com/bpg/gerinfo/204>

GUIDELINES FOR ETHICS DOCUMENTS

<https://www.wjnet.com/bpg/GerInfo/287>

GUIDELINES FOR NON-NATIVE SPEAKERS OF ENGLISH

<https://www.wjnet.com/bpg/gerinfo/240>

PUBLICATION ETHICS

<https://www.wjnet.com/bpg/GerInfo/288>

PUBLICATION MISCONDUCT

<https://www.wjnet.com/bpg/gerinfo/208>

ARTICLE PROCESSING CHARGE

<https://www.wjnet.com/bpg/gerinfo/242>

STEPS FOR SUBMITTING MANUSCRIPTS

<https://www.wjnet.com/bpg/GerInfo/239>

ONLINE SUBMISSION

<https://www.f6publishing.com>

Keeping an eye on the diabetic foot: The connection between diabetic eye disease and wound healing in the lower extremity

David J Ramsey, James T Kwan, Arjun Sharma

Specialty type: Endocrinology and metabolism

Provenance and peer review: Invited article; Externally peer reviewed.

Peer-review model: Single blind

Peer-review report's scientific quality classification

Grade A (Excellent): 0
Grade B (Very good): B
Grade C (Good): C, C
Grade D (Fair): 0
Grade E (Poor): 0

P-Reviewer: Morya AK, India; Wu QN, China

Received: August 28, 2022

Peer-review started: August 28, 2022

First decision: September 26, 2022

Revised: October 27, 2022

Accepted: November 18, 2022

Article in press: November 18, 2022

Published online: December 15, 2022



David J Ramsey, James T Kwan, Arjun Sharma, Department of Ophthalmology, Lahey Hospital and Medical Center, Burlington, MA 01805, United States

David J Ramsey, James T Kwan, Arjun Sharma, Department of Ophthalmology, Tufts University School of Medicine, Boston, MA 02111, United States

Corresponding author: David J Ramsey, MD, PhD, Associate Professor, Director of Research, Department of Ophthalmology, Lahey Hospital and Medical Center, 41 Mall Road, Burlington, MA 01805, United States. david.j.ramsey@lahey.org

Abstract

Diabetic eye disease is strongly associated with the development of diabetic foot ulcers (DFUs). DFUs are a common and significant complication of diabetes mellitus (DM) that arise from a combination of micro- and macrovascular compromise. Hyperglycemia and associated metabolic dysfunction in DM lead to impaired wound healing, immune dysregulation, peripheral vascular disease, and diabetic neuropathy that predisposes the lower extremities to repetitive injury and progressive tissue damage that may ultimately necessitate amputation. Diabetic retinopathy (DR) is caused by cumulative damage to the retinal microvasculature from hyperglycemia and other diabetes-associated factors. The severity of DR is closely associated with the development of DFUs and the need for lower extremity revascularization procedures and/or amputation. Like the lower extremity, the eye may also suffer end-organ damage from macrovascular compromise in the form of cranial neuropathies that impair its motility, cause optic neuropathy, or result in partial or complete blindness. Additionally, poor perfusion of the eye can cause ischemic retinopathy leading to the development of proliferative diabetic retinopathy or neovascular glaucoma, both serious, vision-threatening conditions. Finally, diabetic corneal ulcers and DFUs share many aspects of impaired wound healing resulting from neurovascular, sensory, and immunologic compromise. Notably, alterations in serum biomarkers, such as hemoglobin A1c, ceruloplasmin, creatinine, low-density lipoprotein, and high-density lipoprotein, are associated with both DR and DFUs. Monitoring these parameters can aid in prognosticating long-term outcomes and shed light on shared pathogenic mechanisms that lead to end-organ damage. The frequent co-occurrence of diabetic eye and foot problems mandate that patients affected by either condition undergo reciprocal comprehensive eye and foot evaluations in addition to optimizing diabetes management.

Key Words: Foot ulcer; Diabetic; Wound healing; Diabetes complications; Amputation; Diabetic retinopathy; Corneal ulcer

©The Author(s) 2022. Published by Baishideng Publishing Group Inc. All rights reserved.

Core Tip: This review explores the epidemiological and pathophysiological interconnections between diabetic foot and eye disease, especially the shared mechanisms that impact wound healing. Since diabetic foot and eye problems are often concurrent, it is imperative that patients affected by one or the other condition promptly undergo reciprocal examinations to reduce the risk of further complications. The best outcomes for patients with diabetic foot and eye disease are achieved by a team-based strategy that incorporates regular examinations, often performed by specialists, provides preventative health education, and delivers effective long-term management of the underlying diabetes and its associated metabolic consequences.

Citation: Ramsey DJ, Kwan JT, Sharma A. Keeping an eye on the diabetic foot: The connection between diabetic eye disease and wound healing in the lower extremity. *World J Diabetes* 2022; 13(12): 1035-1048

URL: <https://www.wjgnet.com/1948-9358/full/v13/i12/1035.htm>

DOI: <https://dx.doi.org/10.4239/wjd.v13.i12.1035>

INTRODUCTION

An estimated 131 million people worldwide have lower extremity complications related to diabetes mellitus (DM), such as diabetic foot ulcers (DFUs), peripheral vascular disease (PVD), neuropathy, and amputations[1,2]. Similarly, an estimated 103 million people worldwide have diabetic eye disease, including nearly one million people aged 50 and older who are blind from diabetic retinopathy (DR)[3, 4]. The frequent co-occurrence of diabetic eye and foot problems makes it imperative for patients affected by either condition to promptly undergo reciprocal examinations to reduce the risk of further complications (Figure 1). It is essential that individuals who have DM and the clinicians who care for them understand the likelihood of this association. With the worldwide prevalence of DM increasing because of changes in diet and lifestyle, aging of the population, and the ability of individuals to live longer with the disease, the need for well-informed clinicians has never been greater[3].

The connection between diabetic eye and foot problems is related, in part, to shared risk factors. In particular, the duration of DM and level of glycemic control as reflected by hemoglobin A1c (HbA1c) level strongly govern both the rate of onset and severity of diabetic foot disease[5,6] and DR[7]. Molecular biomarkers, particularly ceruloplasmin, have been demonstrated to be elevated in people with DM[8]. Other risk factors, such as age, male gender, race and ethnicity, smoking, insulin use, type of diabetes, and individual comorbid factors such as hypertension, elevated low-density lipoprotein (LDL), decreased high-density lipoprotein (HDL), coronary artery disease, cerebral vascular disease, PVD, neuropathy, and nephropathy, have been assessed, but not all studies agree on which of these risk factors affect the incidence or progression of these diabetic complications[5]. Some of this variation may possibly be ascribed to differences in DM care, improvements in treatment over time, and other less well-defined differences between individual populations studied. This paper reviews the shared pathogenic mechanisms underlying these conditions and the importance of comprehensive diabetes care to reduce morbidity and prevent disability.

DIABETES-ASSOCIATED LOWER EXTREMITY COMPLICATIONS AND THEIR OCULAR PARALLELS

DFUs

Individuals with DM are at a significantly increased risk of developing DFUs. DFUs are full-thickness wounds that penetrate the dermis (the deep vascular and collagenous inner layer of the skin) and are located below the ankle in patients with both type 1 and type 2 DM (Figure 2)[1,2]. DFUs arise from a combination of micro- and macrovascular compromise related to hyperglycemia and associated metabolic dysfunction that causes impaired growth and wound healing, immune dysregulation, and PVD[9]. In addition, the loss of protective sensation and proprioception caused by diabetic neuropathy and vision loss from diabetic eye disease predisposes patients to repetitive lower extremity trauma, with DFUs a common complication, especially among older adults[10,11]. Risk factors for DFUs include age,

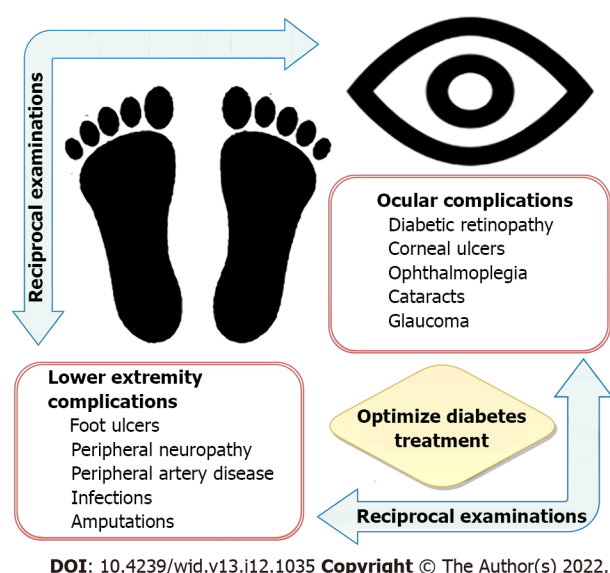


Figure 1 Upon identification of one or more of problems involving the lower extremity or the eye, reciprocal examinations are recommended to reduce the risk of further complications. Preventing diabetic foot and eye problems is best achieved through regular examinations, diabetes education, and optimal management of underlying diabetes mellitus and its associated metabolic consequences.

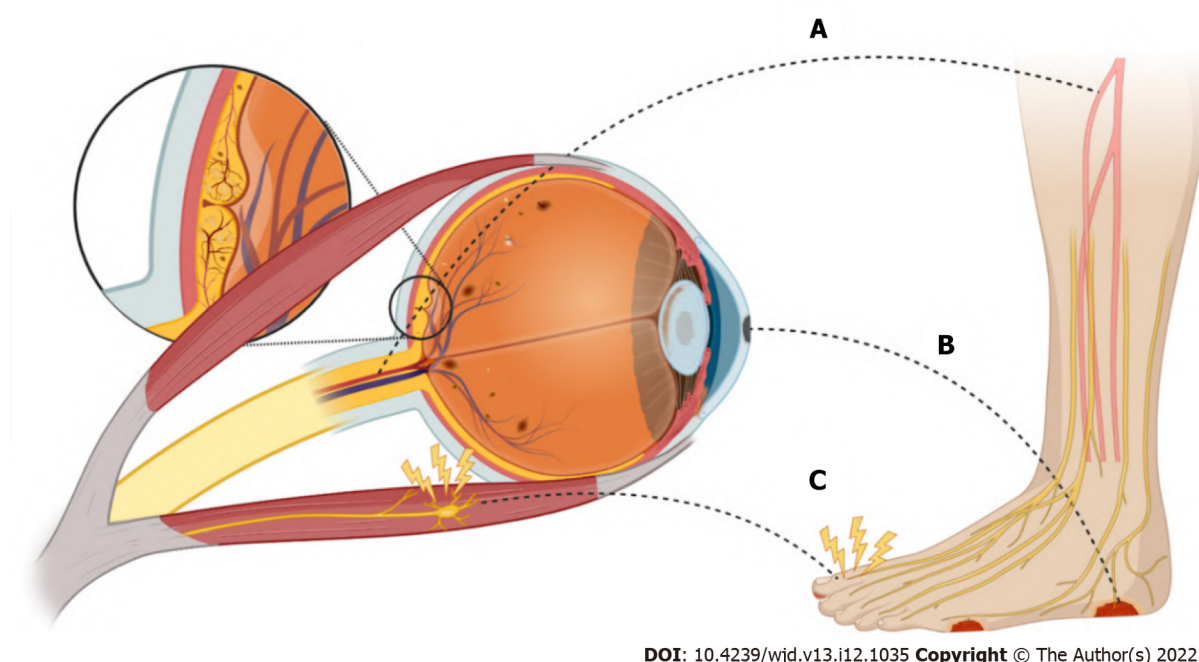


Figure 2 The connection between diabetic eye disease and diabetic foot and wound healing. A: Diabetic micro- and macrovascular complications; B: Diabetic ulcers; C: Diabetic neuropathy. Each of these diabetic complications has multifactorial etiologies. Figure 2 was made in ©BioRender-biorender.com.

deformity or prior ulceration, repetitive trauma, sensory and autonomic neuropathy, peripheral arterial disease (PAD), and infection[12]. Up to one third of patients with DM will be affected by a DFU in their lifetime[13]. DFUs are associated with a 10- to 20-fold increased risk of amputation[1] and have a one-year mortality rate as high as 5%[14]. As many as 20% of DFUs remain unhealed after one year of treatment, with unhealed ulcers posing a risk for infections, gangrene, amputation, and even death[15, 16].

There is a strong association between the development of DFUs and DR (Figure 2)[5]. Depending on the population studied, most individuals affected by DFUs also have DR[6,17-19], and those with DR are two to four times more likely to have DFUs or more serious forms of diabetic foot disease (Table 1) [20-22]. Even more concerning is the strong association between DFUs and proliferative diabetic retinopathy (PDR), with 31% to 55% of individuals having this more severe stage of DR (see below)[23]. Furthermore, patients with nonproliferative diabetic retinopathy (NPDR) who develop comorbid non-

Table 1 Studies examining association of diabetic foot disease and diabetic retinopathy

Ref.	Year	Type of study	Sample size (DFU; no DFU)	Source of population	Main findings
Jayaprakash <i>et al</i> [17]	2009	Prospective Case Study	94	India	73.4% prevalence of DR in patients with DFUs
Hwang <i>et al</i> [22]	2017	Retrospective Cohort	100	South Korea	90% prevalence of DR in patients with type 2 DM and DFUs; 55% had PDR
Karam <i>et al</i> [18]	2018	Cross-sectional	182	India	67.6% prevalence of DR in patients diabetic foot disease (including neuropathy, deformation, DFUs, or amputation)
Zafar <i>et al</i> [19]	2019	Cross-sectional	530 (225; 305)	Pakistan	96% of patients with DFUs had DR
Sellman <i>et al</i> [23]	2020	Case Control	270 (90; 180)	Sweden	31% prevalence of PDR in patients with DFUs
Banik <i>et al</i> [21]	2020	Cross-sectional	680 (8; 672)	Bangladesh	65.9% prevalence of DR in patients with DFUs
Ye <i>et al</i> [20]	2014	Retrospective Cohort	829 (61; 768)	China	OR 2.026 for DFUs in patients with DR
Al-Rubeaan <i>et al</i> [6]	2015	Retrospective Cohort	62681 (2071; 60610)	Saudi Arabia	OR 4.45 for diabetic foot disease (including DFUs, gangrene, and amputation) in patients with DR
Harris Nwanyanwu <i>et al</i> [24]	2013	Retrospective Cohort	4617	United States	1.54 HR for those with comorbid non-healing DFUs to progress from NPDR to PDR in three to five years

DR: Diabetic retinopathy; NPDR: Nonproliferative diabetic retinopathy; PDR: Proliferative diabetic retinopathy; DFU: Diabetic foot ulcer; OR: Odds ratio; HR: Hazard ratios.

healing DFUs have a greater than 50% increased risk of progressing to PDR relative to those without this condition[24]. Finally, diabetic keratopathy is an important ocular parallel of DFUs. It is a disruption of normal corneal wound healing and loss of protective mechanisms of corneal sensation and aqueous tear production. These aberrations create an ideal environment for persistent corneal epithelial defects, microbial infection, and ulceration. Around half of patients with DM are affected by this condition[25]. The pathophysiology accounting for diabetic structural and functional alterations in the cornea is discussed in depth below.

Microvascular complications

Microvascular dysfunction in the lower extremity contributes to impaired function and impedes wound healing, which promotes the development of DFUs. Damage to endothelial cells from chronic hyperglycemia, oxidative stress-induced injury, generation of advanced glycation end-products, increased polyol flux regulated by aldose reductase, activation of protein kinase C (PKC), and other pro-inflammatory processes from immune dysregulation cumulatively disrupt normal blood flow and affect vascular permeability[26]. In its most severe form, this compromise of the microvasculature leads to ischemia and a relative hypoxic state in the involved tissue. As a result, there is increased expression of hypoxia-inducible factor-1 (HIF-1) leading to the production of vascular endothelial growth factor (VEGF), a protein principally responsible for restorative angiogenesis[27]. However, in DM there are disturbances in cytokine growth factor expression and locally decreased concentrations of VEGF, which render the lower extremity vulnerable to poor wound healing[9]. Failure of the microvasculature also contributes to peripheral neuropathy and local immune dysfunction, including impaired cellular response, cytokine expression, and vascular tone[28].

In the eye, these same pathways driven by hyperglycemia and other diabetes-associated factors lead to progressive damage to the retinal microvasculature and cause the development of DR[29]. DR develops in roughly one quarter of patients with DM, with the prevalence being highest in Africa (36%) and lowest in South and Central America (13%)[3,30]. Initially, the disease manifests as clinically detectable changes in the retinal vasculature, including the development of microaneurysms and loss of capillaries which are the hallmarks of early NPDR[31]. As the disease progresses, the production of VEGF and other diabetes-associated factors promotes further dysfunction, vascular leakage, and bleeding (dot-blot hemorrhages)[32]. At this stage, visual acuity is increasingly likely to be affected and is often further limited by swelling in the center of the retina, known as diabetic macular edema (DME)[33]. The development of neovascularization on the optic nerve or at locations in the peripheral retina signifies the progression to PDR. This is the most vision-threatening complications of the disease also primarily driven by the abnormal expression of VEGF[29,30,34]. These fragile new vessels, which grow into the vitreous cavity and along the inner retinal surface, often bleed, causing vitreous hemorrhages, traction, or retinal detachment and thereby impair vision[3,32]. Finally, excessive expression of VEGF may also affect the anterior segment of the eye by causing neovascularization on the iris and ciliary body. When the growth of this fibrovascular tissue extends to the anterior chamber angle it may block

outflow of aqueous humor through the trabecular meshwork causing eye pressure to rise to levels capable of damaging the optic nerve in a disease process known as neovascular glaucoma[4,32]. When left unaddressed, irreversible blindness results.

Clinical examination supplemented by diagnostic color fundus photography and fluorescein angiography are the mainstays for staging DR; however, emerging modalities including ultrawide-angle imaging and optical coherence tomography and angiography increasingly allow clinicians to directly and noninvasively visualize the diseased retina and its microvasculature[31]. Advances in therapeutic modalities, such as intraocular injection of agents that target VEGF, steroids that target inflammation, and panretinal laser photocoagulation, have improved clinical outcomes for patients with DR[33-36]. However, effective long-term management is largely dependent upon regular follow-up care. Patients who fail to return for care are more likely to suffer vision loss[37,38].

The intraocular administration of agents that target VEGF are now the most common treatments for DR and DME[29,36]. Thankfully these agents are very unlikely to negatively impact wound healing in the lower extremity, especially at the doses employed to treat eye disease[39]. Similarly, intraocular corticosteroids, such as dexamethasone, and intravitreal steroid implants utilized to treat DME have been found to have no detectable influence on HbA1c or renal function[40,41]. However, when larger doses are administered as subconjunctival or peribulbar injections, some patients can experience elevations of blood glucose, similar to that observed with oral and intravenous administration of corticosteroids[42]. Finally, topical steroid drops have only very rarely been associated with endocrinological side effects in case reports[43].

Wound healing

Wound healing in the lower extremity requires coordinated cellular responses that cause an organized release of growth factors and cytokines. Under normal conditions, when an injury occurs, multiple cell types, including macrophages, fibroblasts, and epithelial cells, release VEGF and other cytokines in response to local ischemia caused by the wound[44]. However, in patients with DM, disturbances in cytokine and growth factor expression, including fibroblast growth factor, insulin-like growth factor, platelet derived growth factor, and VEGF, among others, lead to a condition that subsequently permits prolonged hypoxia[9,45]. Additionally, keratinocytes and fibroblasts in DFUs have demonstrated attenuated cellular migration, proliferation, and protein synthesis, resulting in impaired re-epithelialization which further exacerbates the oxygen-restricted wound[46]. Moreover, hyperglycemic states reduce the stability and function of HIF-1, which further impairs the wound healing response as a downstream consequence of sustained hypoxia[9]. Increased free radical damage is also a known causative factor in impaired wound healing in patients with DM. Inappropriately elevated concentrations of reactive oxygen species (ROS) and impaired antioxidant enzyme activity can cause nerve damage and directly contribute to the progression of peripheral neuropathy[47].

Individuals with DM also have abnormal wound healing pathways in the eye. Notably, corneal thinning is thought to be the earliest detectable pathological manifestation of DM in the eye[48]. Diabetic keratopathy leads to persistent corneal epithelial defects and neurotrophic corneal ulcers that respond poorly to treatments applied in the hyperglycemic environment[49]. Abnormalities in corneal cell morphology, varied number and disorganization of epithelial cell layers, impaired cellular migration, reduced endothelial cell number, and accumulation of acellular debris all contribute to poor wound healing[50]. Sectorial thinning, bullae, and persistent corneal epithelial defects from diabetic keratopathy often lead to corneal ulcers, scarring, and reactive neovascularization, which cause decreased visual acuity or permanent vision loss[50,51]. Although the cornea itself is avascular and ischemia does not play a significant role in diabetic keratopathy, wound healing in the cornea, like in the lower extremity, requires highly structured cellular processes which are impacted by hyperglycemia. These involve proliferation and migration of epithelial cells, fibroblasts, and the expression of numerous growth factors, including transforming growth factor beta, epidermal growth factor, insulin-like growth factor, and platelet derived growth factor[51]. Finally, diabetes-associated hyperglycemia may also impair vision by accelerating the progression of diabetic cataract and impact the health of the lens epithelium[52].

Most treatments for diabetic foot and eye problems are applied locally, but some treatments to aid the lower extremity may have theoretical consequences on the eye, and vice versa. Several adjuvant therapies have been found to reduce DFU healing times and amputation rates, including non-surgical debridement agents, topical dressings and agents, negative pressure wound therapy, oxygen therapies, acellular bioproducts, and human growth factors[53]. Oxygen is required for almost every step of the wound healing, affecting cell proliferation, collagen synthesis, and re-epithelialization, as well as immunologic defense against bacteria and other pathogens[54]. Oxygen may be delivered in the form of local, hyperbaric, or supplemental inspired oxygen therapy. Hyperbaric oxygen therapy has proven to be particularly useful in managing chronic, non-healing DFUs, especially in the relatively ischemic diabetic foot, albeit at a high financial cost[55]. Patients have been observed to have increased tissue concentrations of VEGF after completing hyperbaric therapy sessions; this has been attributed to the sharp decline of relative oxygen concentration once a session is completed[56]. As previously mentioned, the presence of VEGF is the primary driver of DR, so there is a theoretical risk that systemic or local oxygen therapy could exacerbate this condition. However, empiric evidence does not suggest

that oxygen therapy is harmful to the diabetic eye[23]. It has even been reported that patients with concurrent DR have benefitted from the administration of hyperbaric oxygen therapy through supranormal levels of oxygen delivered to the retina[57]. Nevertheless, it remains essential that the status of DR is assessed and regularly monitored in any patient undergoing oxygen therapy for DFUs.

Many growth factors that have been identified as integral to wound healing are also potential therapeutic targets. In the diabetic foot, among the most promising are hydrogels which contain recombinant PDGF, approved by the United States Food and Drug Administration for topical administration having demonstrated improved rates of DFU healing in randomized clinical trials[58]. In the diabetic cornea, recombinant human nerve growth factor (NGF), epidermal growth factor, and metalloprotease inhibitors have demonstrated some success in trials for the treatment of diabetic keratopathy[59]. Of note, the opioid antagonist naltrexone has been demonstrated to improve wound healing, corneal surface sensitivity, and tear secretion in diabetic animal models[60,61]. The future will also likely include gene- and cell-based therapies to accelerate wound healing, including in DFUs and diabetic cornea[62,63].

Diabetic neuropathy

Approximately half of adults with DM will be affected by peripheral neuropathy in their lifetime[64]. Peripheral neuropathy typically begins with diminution or loss of protective sensation. In addition, loss of proprioception contributes to injuries and falls[11]. Moreover, autonomic dysregulation in the foot may contribute to impaired cutaneous blood flow, sweating dysfunction, and loss of vascular tone that compromise integument integrity and wound healing[65]. Lower extremity deformities may also occur, such as hammer toes or claw toes, which are associated with loss of function[11]. Finally, delays in the identification of accidental and iatrogenic injuries because of reduced sensation may cause patients to fail to seek care in a timely fashion and increase the risk for infections[64].

As mentioned above, chronic hyperglycemia from DM causes microangiopathic changes. In the case of diabetic neuropathy, hyperglycemia may affect the endoneurial microvasculature by directly reducing perfusion and impairing nerve function[66]. Many of the same cellular and biochemical mechanisms linked to chronic hyperglycemia injure the peripheral nerves, including increased glycolytic processes producing oxidative stress, generation of advanced glycation end-products, increased polyol flux regulated by aldose reductase, PKC activation, and other pro-inflammatory processes from immune dysregulation[67]. Damage to mitochondria also plays an important role in the pathogenesis of diabetic neuropathy and contributes to nerve dysfunction, cell death, and loss of neurotrophic support provided by neurotrophin-3 and NGF[68]. Patients who develop PAD also have more severe diabetic neuropathy (see below)[64].

The cornea is the most densely innervated tissue of the human body and is 100 times more sensitive than skin[69], but this declines with age[70] and is further reduced by DM[71]. The loss of protective sensation of the diabetic cornea impacts various homeostatic functions, such as blinking, aqueous tear production, and the release of growth factors[51,52]. As a result, the incidence of dry eye disease and the need for artificial tears is increased among patients with DM, particularly among those with worse diabetes-related outcomes[72]. A recent meta-analysis estimated that DM conferred 30% increased odds for dry eye syndrome[58]. Dry eye disease and DR are also associated with each other[73]. These changes result in neurotrophic keratopathy marked by persistent epithelial defects and chronic erosions that may develop into corneal ulcers, corneal scarring, and neovascularization, all of which contribute to visual dysfunction[74] and predispose patients to infectious keratitis[75]. The recent application of *in vivo* confocal microscopy has allowed for visualization of diabetes-associated structural changes in the nerves of the corneal epithelium, including nerve thickening[76] and decreased nerve length and density[77]. Anterior segment optical coherence tomography is another emerging diagnostic modality used to evaluate and manage diabetic keratopathy by enabling the direct visualization of the cornea structure and nerves[50,71].

Diabetes-associated hyperglycemia has also been shown to cause direct injury to the neuronal retina, leading to thinning of the nerve fiber layer from the loss of ganglion cells and the death of other retinal neurons, including photoreceptors[78]. This may lead to decreased visual function, impaired contrast sensitivity, and diminished night vision[29,32]. Finally, the eye may also be suddenly and directly affected by diabetic cranial neuropathies, manifesting as double vision from ophthalmoplegia, which is the paralysis of the muscles that move the eye (see below).

Current recommendations for the management of painful diabetic neuropathy include gabapentinoids, serotonin and norepinephrine reuptake inhibitors (SNRIs), and tricyclic antidepressants (TCAs)[79]. Gabapentin is a well-tolerated medication from an ophthalmic standpoint; its most common adverse effect is a reversible nystagmus[80]. SNRIs, such as venlafaxine, have been associated with acute angle closure glaucoma in some case reports[81], along with increased cataract development[82]. Finally, TCAs are associated with blurred vision in up to one third of patients, likely due to the anticholinergic action of these drugs[83]. These side effects further emphasize the importance of communication and collaboration with ophthalmologists when treating diabetes-associated complications of the lower extremity.

Macrovascular complications

Common macrovascular complications of DM that affect the lower extremity include PAD and chronic venous insufficiency (CVI), which may lead to lower extremity amputation (Figure 1)[84]. DM induces and accelerates the development of atherosclerosis *via* multiple mechanisms that include metabolic derangements, smooth muscle dysfunction, oxidative stress, potentiated platelet function, increased coagulability, and chronic inflammation[85]. The availability of the potent vasodilator nitrous oxide, which is produced in the endothelium and is a primary mediator in local vascular endothelial tone, is reduced in hyperglycemic states; DM also promotes the production of endothelin-1, which indirectly increases vasoconstriction and vascular smooth muscle hypertrophy[86]. The result may be an overt occlusion, sometimes acutely when a thrombus forms, or when increasingly stenotic vessels result in reduced perfusion[86]. Patients with co-existing severe PAD are also more likely to have CVI[84], which contributes to poor wound healing by increasing hydrostatic pressure in the lower extremity, thereby promoting wound exudation[87].

While not directly a macrovascular complication, it is important to recognize that DR is strongly associated with lower-extremity PAD. Patients with DR have an approximately two-fold increase in the need for lower-limb revascularization and a five-fold increase in lower-limb amputation[88]. Patients with PAD benefit from additional medical management and risk factor modification for atherosclerotic disease. In addition to optimizing diabetes control, this includes counseling about smoking cessation, antiplatelet and statin therapies, as well as blood pressure control[89]. Exercise also plays a fundamental role in the treatment of PAD, leading to reductions in pain and improvement in functional capacity[89]. The clinical benefit of newer medications on amputation prevention remains uncertain.

In the eye, DM-associated macrovascular disease can manifest as an ocular ischemic syndrome (OIS), a rare, but vision-threatening condition associated with severe carotid artery occlusive disease that leads to ocular hypoperfusion[90]. Like PAD, atherosclerosis affecting the vessels supplying the eye is the main cause of the disease, and most patients with OIS have a diagnosis of DM[91]. Patients typically report dull eye or periorbital pain associated with gradual vision loss as the retina experiences progressive ischemia. Consequently, VEGF levels rise, which may cause neovascular glaucoma in the anterior segment and reduce the final visual potential; neovascularization can also develop in the retina, but it is less prominent than in DR because of reduced retinal perfusion[92]. OIS entails an overall poor visual prognosis, which means that the ophthalmologist's diagnosis is crucial for the systemic health of those patients because OIS may be the presenting sign of impending serious cerebrovascular and ischemic heart disease. Finally, DM can sometimes cause an ischemic optic neuropathy, which is a direct infarct of the optic nerve[52].

Another condition involving a main function of the eye where macrovascular disease in DM manifests is ophthalmoplegia. Ophthalmoplegia is the paralysis of one or more of the extraocular muscles (EOM). It can arise from traumatic, autoimmune, infectious, and vascular etiologies. Usually involving the third (oculomotor), fourth (trochlear), or sixth (abducens) cranial nerves, double vision is the characteristic symptom of ophthalmoplegia[93]. The vascular supply for the EOMs comes from branches of the ophthalmic artery, which is itself a branch of the internal carotid artery. Additionally, the cranial nerves responsible for the EOMs themselves have a complex vascular supply. Focal cranial nerve ischemia due to atherosclerosis within the microvasculature is thought to contribute to the development of ophthalmoplegia in patients with DM[94].

PREVENTION AND MANAGEMENT

Preventing diabetic foot and eye problems is best achieved through regular examinations, diabetes education, and optimal management of underlying DM and its associated metabolic consequences. Tight control of blood glucose, as reflected by HbA1c level, is the most important element for prevention of these two interrelated diabetes-associated complications, closely followed by optimization of blood pressure and lipid levels[1,7,37,38]. This is accomplished through a combination of regulation of diet, lifestyle modification, body mass reduction, and medications, such as insulin and/or oral antidiabetic therapies, as appropriate. Monitoring alterations in serum biomarkers, such as HbA1c, ceruloplasmin, creatinine, uric acid, LDL, and HDL, is also important because these biomarkers are associated with both the onset and severity of DR and DFUs[8,20].

The standard practices in DFU management include cleansing, surgical debridement, application of clean dressings to maintain a moist environment and control exudates, wound off-loading, vascular optimization (including revascularization procedures), treatment and prevention of infection, and glycemic control[88,95]. Proper instruction is also required to prevent accidental or iatrogenic injuries which can result from ordinary hygiene and grooming of the feet and lower extremity[29]. Infection prevention is best achieved through protective footwear, proper hygiene, and offloading interventions[11]. Similarly, preventing complications from diabetic keratopathy focuses on limiting repetitive trauma, neurosensory deformities, exposure, and infections. Injuries may be caused by eye droppers, abnormal eye lashes, cosmetic applicators, fingers, facial towels, and bedding[96]. Infection can occur from overgrowth of the ocular flora or opportunistic infection enhanced by hyperglycemia, or it can

take the form of chronic and recurrent herpes simplex and zoster[97].

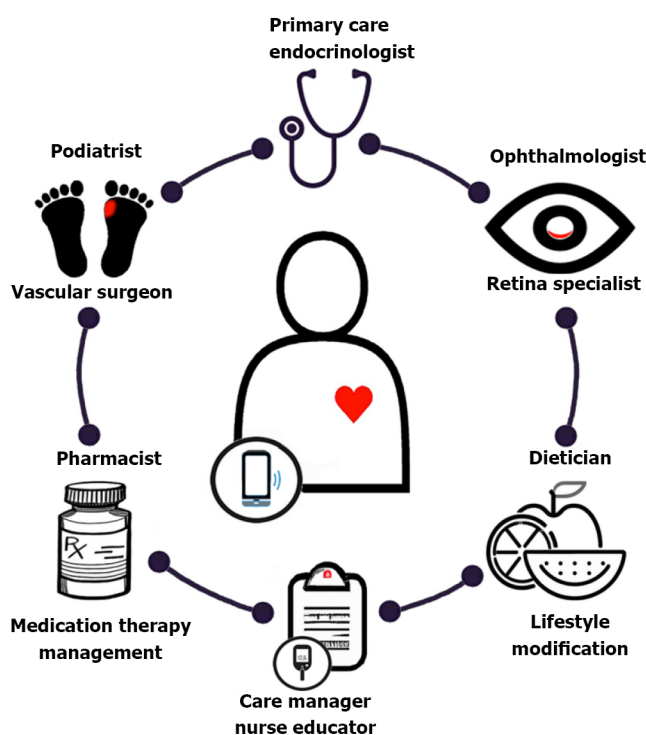
Many parallels exist between management of ulcers in the cornea and those in the lower extremity. Both are treated with clean dressings, antimicrobial ointments, and salves. Wound infections may be polymicrobial, but the bacterial species most associated with DFUs include gram-positive species, *e.g.*, *Staphylococcus aureus* and *Streptococcus* species, but gram-negative infections with *Pseudomonas aeruginosa* and *Enterobacteriaceae* species also occur and are notably more common in ischemic or deep wounds[98]. Infection of corneal ulcers involve many of these same organisms, including *Staphylococcus*, *Pseudomonas aeruginosa*, and *Streptococcus pneumoniae*[70,99]. Special dressing and vacuum-assisted wound closure have been used with good result in the management of DFUs[100]. Non-healing diabetic corneal ulcers are often treated in conjunction with bandage contact lenses, which can lengthen the time antibiotic treatments are in contact with the ocular surface and serve as a reservoir for pharmacologically active compounds to aid wound healing[69]. In contrast to DFU management, patching should generally be avoided in patients with DM and corneal disease because of an increased risk of infection[101]. Amniotic membrane grafts have been studied for their potential of facilitating epithelial migration and healing of corneal ulcers and in very severe cases, corneal transplantation may be necessary[102].

Emerging research has placed an emphasis on developing therapeutic options that offer additional ways of preventing diabetic complications, treating them at earlier stages, or in more effective ways. As discussed earlier, inflammation has been implicated in the pathogenesis of diabetes-associated complications. Cytokines, such as interferon- γ , are being investigated as potential therapeutic targets in attenuating inflammatory cascades given that many of these cytokines contribute to altered vascular permeability and angiogenesis[103]. Given the high metabolic rate of the retina in conjunction with the metabolic stress induced by chronic hyperglycemia, reducing free radical stress may be an effective strategy[104]. Polyphenols, such as epigallocatechin-3-gallate found in green tea, are known for their antioxidant and anti-inflammatory properties and in diabetic animal models, have been shown to attenuate ROS concentrations in the retina[105]. Other polyphenol compounds, carotenoids, thiols, and vitamin supplementation are being investigated to address the several pathways involved in ROS generation and inflammation[104].

Finally, a multidisciplinary care team is essential to care optimally for the diabetic foot and eye, preserving function and quality of life for those with DM (Figure 3). Primary care providers and endocrinologists play a crucial role in coordinating care, including providing a formal assessment of the degree of diabetic control, screening for symptoms related to diabetic complications affecting other organ systems such as diabetic nephropathy, prescribing DM treatment, and involving specialists who manage diabetic complications such as foot or eye problems[1]. A diabetes care team should also include pharmacists who provide medication therapy management, dietitians, psychologists, diabetes care managers, and nurse educators. By working together, a coordinated care team can effectively reduce the healthcare burden associated with DM and its complications through prevention, screening, and management. In the future, the integration of smartphone technology and telehealth may not only streamline care coordination, but also allow for remote diagnosis and long-term monitoring of disease [106].

CONCLUSION

The identification of any ophthalmic or lower extremity complication in a patient with type 1 or type 2 DM should immediately prompt a review of DM management and coordination of diabetes care, including referral for reciprocal comprehensive foot or eye evaluations in patients with either complication[1,37,38]. Although diabetic foot disease is slightly more common among patients with type 1 DM and those who use insulin[6], optimizing diabetes management remains the most important step in preventing diabetes-associated complications no matter what the type of DM[37,38]. While many patients may report symptoms related to diabetic foot disease or observe vision loss in the setting of diabetic eye problems, many others may be asymptomatic or have such mild signs and symptoms that they are easily overlooked, dismissed, or fail to receive clinical attention unless specifically assessed[64, 107]. Primary care providers and endocrinologists should perform regular diabetic foot examinations because they provide insight into the presence and degree of PVD, neuropathy, skin breakdown, and other pre-ulcerative changes. Providers must also screen for signs and symptoms of eye disease, in part because their identification may help triage the urgency of any necessary referrals[37,38]. Because diabetic eye and foot diseases so commonly occur in conjunction, it is essential that clinicians take the necessary steps to reduce the impact of these diseases through regular screening, prompt referral to specialists, and providing a coordinated, team-based approach to management.



DOI: 10.4239/wjd.v13.i12.1035 Copyright © The Author(s) 2022.

Figure 3 Diabetic care team process. Primary care and endocrinology physicians are central to comprehensive diabetes mellitus (DM) evaluation including assessment of the level of glycemic control, prescription of medications, determining level of treatment adherence, and identification of gaps in care and risk of complications. The frequent concurrence of diabetic eye and foot problems mandate that patients affected by either condition should undergo reciprocal comprehensive eye and foot evaluations, in addition to optimizing diabetic control. Specialists are often required to manage diabetic foot problems, including referral to podiatry, lower extremity wound care specialists, or vascular surgery, each engaging treatment algorithms according to their expertise. Eye care is typically provided by ophthalmologists or optometrists, but often requires the expertise of a retinal specialist capable of providing the medical and surgical management of diabetic eye disease. Pharmacists provide medication therapy management and are an important source of diabetes education. Dietitians, lifestyle coaches, and psychologists offer counseling that works toward improving or maintaining glycemic targets through nutrition, achieving weight management and physical activity goals, and implementing behavior changes. Diabetic care managers and nurse educators help individuals with DM establish long-term commitments. They provide instruction on foot and skin care; the use of medications, including the administration of insulin; the monitoring of blood glucose levels; and maintenance of proper diet and exercise. They develop an overall management strategy aimed at reducing risk factors linked to diabetes-associated complications. The integration of smartphone technology and telehealth may streamline the care coordination and communication between the patient and each component of the diabetic care team [106]. Figure 3 was made in ©BioRender-biorender.com. The authors generated parts of the digital images used in Figure 3 by using the Generative Pre-trained Transformer 3 (GPT-3) autoregressive language model that employs deep learning to generate digital images from natural language descriptions (DALL·E, OpenAI, San Francisco, CA, labs.openai.com). The authors reviewed, edited, and revised these images and take ultimate responsibility for the content included in this publication.

ACKNOWLEDGEMENTS

The authors thank Dr. Andrew Popelka Jr., Dr. Shiyong Roh, Dr. Sarkis Soukiasian, Dr. Adam Romeiser III, Dr. Angela Jellison, Rebecca Rick Longo, as well as Carol Spencer, Lahey Hospital Librarian, for research support. D.J. Ramsey is supported by the Harry N. Lee Family Chair in Innovation at the Lahey Hospital and Medical Center, Beth Israel Lahey Health. Study was performed as part of regular employment duties at the Lahey Hospital and Medical Center, Beth Israel Lahey Health. No additional funding was provided.

FOOTNOTES

Author contributions: Ramsey DJ, Kwan JT, and Sharma A contributed equally to this work; All authors have read and approve the final manuscript.

Conflict-of-interest statement: All the authors report no relevant conflicts of interest for this article.

Open-Access: This article is an open-access article that was selected by an in-house editor and fully peer-reviewed by external reviewers. It is distributed in accordance with the Creative Commons Attribution NonCommercial (CC BY-NC 4.0) license, which permits others to distribute, remix, adapt, build upon this work non-commercially, and license their derivative works on different terms, provided the original work is properly cited and the use is non-

commercial. See: <https://creativecommons.org/licenses/by-nc/4.0/>

Country/Territory of origin: United States

ORCID number: David J Ramsey 0000-0002-5504-812X; James T Kwan 0000-0001-8754-3179; Arjun Sharma 0000-0001-9204-856X.

S-Editor: Fan JR

L-Editor: A

P-Editor: Fan JR

REFERENCES

- 1 **International Diabetes Federation.** Clinical practice recommendations on the diabetic foot, 2017. Brussels, Belgium, 2022. [cited 24 August 2022]. Available from: <https://www.idf.org/e-library/guidelines/119-idf-clinical-practice-recommendations-on-diabetic-foot-2017.html>
- 2 **Zhang Y,** Cramb S, McPhail SM, Pacella R, van Netten JJ, Cheng Q, Derhy PH, Kinnear EM, Lazzarini PA; Diabetic Foot Working Group, Queensland Statewide Diabetes Clinical Network, Australia. Factors Associated With Healing of Diabetes-Related Foot Ulcers: Observations From a Large Prospective Real-World Cohort. *Diabetes Care* 2021; **44**: e143-e145 [PMID: 34074651 DOI: 10.2337/dc20-3120]
- 3 **Teo ZL,** Tham YC, Yu M, Chee ML, Rim TH, Cheung N, Bikbov MM, Wang YX, Tang Y, Lu Y, Wong IY, Ting DSW, Tan GSW, Jonas JB, Sabanayagam C, Wong TY, Cheng CY. Global Prevalence of Diabetic Retinopathy and Projection of Burden through 2045: Systematic Review and Meta-analysis. *Ophthalmology* 2021; **128**: 1580-1591 [PMID: 33940045 DOI: 10.1016/j.ophtha.2021.04.027]
- 4 **GBD 2019 Blindness and Vision Impairment Collaborators;** Vision Loss Expert Group of the Global Burden of Disease Study. Causes of blindness and vision impairment in 2020 and trends over 30 years, and prevalence of avoidable blindness in relation to VISION 2020: the Right to Sight: an analysis for the Global Burden of Disease Study. *Lancet Glob Health* 2021; **9**: e144-e160 [PMID: 33275949 DOI: 10.1016/S2214-109X(20)30489-7]
- 5 **Huang ZH,** Li SQ, Kou Y, Huang L, Yu T, Hu A. Risk factors for the recurrence of diabetic foot ulcers among diabetic patients: a meta-analysis. *Int Wound J* 2019; **16**: 1373-1382 [PMID: 31489774 DOI: 10.1111/iwj.13200]
- 6 **Al-Rubeaan K,** Al Derwish M, Ouizi S, Youssef AM, Subhani SN, Ibrahim HM, Alamri BN. Diabetic foot complications and their risk factors from a large retrospective cohort study. *PLoS One* 2015; **10**: e0124446 [PMID: 25946144 DOI: 10.1371/journal.pone.0124446]
- 7 **Klein R,** Knudtson MD, Lee KE, Gangnon R, Klein BE. The Wisconsin Epidemiologic Study of Diabetic Retinopathy: XXII the twenty-five-year progression of retinopathy in persons with type 1 diabetes. *Ophthalmology* 2008; **115**: 1859-1868 [PMID: 19068374 DOI: 10.1016/j.ophtha.2008.08.023]
- 8 **Memişoğlu R,** Bakan E. Levels of ceruloplasmin, transferrin, and lipid peroxidation in the serum of patients with Type 2 diabetes mellitus. *J Diabetes Complications* 2004; **18**: 193-197 [PMID: 15207835 DOI: 10.1016/S1056-8727(03)00032-1]
- 9 **Zubair M,** Ahmad J. Role of growth factors and cytokines in diabetic foot ulcer healing: A detailed review. *Rev Endocr Metab Disord* 2019; **20**: 207-217 [PMID: 30937614 DOI: 10.1007/s11154-019-09492-1]
- 10 **Gohdes DM,** Balamurugan A, Larsen BA, Maylath C. Age-related eye diseases: an emerging challenge for public health professionals. *Prev Chronic Dis* 2005; **2**: A17 [PMID: 15963319]
- 11 **van Deursen R.** Footwear for the neuropathic patient: offloading and stability. *Diabetes Metab Res Rev* 2008; **24** Suppl 1: S96-S100 [PMID: 18357582 DOI: 10.1002/dmrr.827]
- 12 **Lim JZ,** Ng NS, Thomas C. Prevention and treatment of diabetic foot ulcers. *J R Soc Med* 2017; **110**: 104-109 [PMID: 28116957 DOI: 10.1177/0141076816688346]
- 13 **Armstrong DG,** Boulton AJM, Bus SA. Diabetic Foot Ulcers and Their Recurrence. *N Engl J Med* 2017; **376**: 2367-2375 [PMID: 28614678 DOI: 10.1056/NEJMr1615439]
- 14 **Walsh JW,** Hoffstad OJ, Sullivan MO, Margolis DJ. Association of diabetic foot ulcer and death in a population-based cohort from the United Kingdom. *Diabet Med* 2016; **33**: 1493-1498 [PMID: 26666583 DOI: 10.1111/dme.13054]
- 15 **Senneville É,** Lipsky BA, Abbas ZG, Aragón-Sánchez J, Diggle M, Embil JM, Kono S, Lavery LA, Malone M, van Asten SA, Urbančič-Rovan V, Peters EJG. Diagnosis of infection in the foot in diabetes: a systematic review. *Diabetes Metab Res Rev* 2020; **36** Suppl 1: e3281 [PMID: 32176440 DOI: 10.1002/dmrr.3281]
- 16 **Armstrong DG,** Swerdlow MA, Armstrong AA, Conte MS, Padula WV, Bus SA. Five year mortality and direct costs of care for people with diabetic foot complications are comparable to cancer. *J Foot Ankle Res* 2020; **13**: 16 [PMID: 32209136 DOI: 10.1186/s13047-020-00383-2]
- 17 **Jayaprakash P,** Bhansali S, Bhansali A, Dutta P, Anantharaman R. Magnitude of foot problems in diabetes in the developing world: a study of 1044 patients. *Diabet Med* 2009; **26**: 939-942 [PMID: 19719717 DOI: 10.1111/j.1464-5491.2009.02781.x]
- 18 **Karam T,** Kamath YS, Rao LG, Rao KA, Shenoy SB, Bhandary SV. Diabetic retinopathy in patients with diabetic foot syndrome in South India. *Indian J Ophthalmol* 2018; **66**: 547-550 [PMID: 29582817 DOI: 10.4103/ijo.IJO_1000_17]
- 19 **Zafar S,** Rahim K, Khan IU, Yasin M, Dawood M, Saleha S. Prevalence and association of diabetic retinopathy with diabetic foot ulcer: a cross-sectional observational study. In: Ziaei A, editor, *Frontiers in Ophthalmology and Ocular Imaging*. London, UK: IntechOpen Limited, 2019. [cited 24 August 2022]. Available from: <https://www.intechopen.com/chapters/65026>

- 20 **Ye X**, Cao Y, Gao F, Yang Q, Zhang Q, Fu X, Li J, Xue Y. Elevated serum uric acid levels are independent risk factors for diabetic foot ulcer in female Chinese patients with type 2 diabetes. *J Diabetes* 2014; **6**: 42-47 [PMID: [23909978](#) DOI: [10.1111/1753-0407.12079](#)]
- 21 **Banik PC**, Barua L, Moniruzzaman M, Mondal R, Zaman F, Ali L. Risk of diabetic foot ulcer and its associated factors among Bangladeshi subjects: a multicentric cross-sectional study. *BMJ Open* 2020; **10**: e034058 [PMID: [32114471](#) DOI: [10.1136/bmjopen-2019-034058](#)]
- 22 **Hwang DJ**, Lee KM, Park MS, Choi SH, Park JI, Cho JH, Park KH, Woo SJ. Association between diabetic foot ulcer and diabetic retinopathy. *PLoS One* 2017; **12**: e0175270 [PMID: [28388680](#) DOI: [10.1371/journal.pone.0175270](#)]
- 23 **Sellman A**, Katzman P, Andreasson S, Löndahl M. Long-term effects of hyperbaric oxygen therapy on visual acuity and retinopathy. *Undersea Hyperb Med* 2020; **47**: 423-430 [PMID: [32931668](#) DOI: [10.22462/03.07.2020.3](#)]
- 24 **Harris Nwanyanwu K**, Talwar N, Gardner TW, Wrobel JS, Herman WH, Stein JD. Predicting development of proliferative diabetic retinopathy. *Diabetes Care* 2013; **36**: 1562-1568 [PMID: [23275374](#) DOI: [10.2337/dc12-0790](#)]
- 25 **Schultz RO**, Van Horn DL, Peters MA, Klewin KM, Schutten WH. Diabetic keratopathy. *Trans Am Ophthalmol Soc* 1981; **79**: 180-199 [PMID: [7342400](#)]
- 26 **Brownlee M**. Biochemistry and molecular cell biology of diabetic complications. *Nature* 2001; **414**: 813-820 [PMID: [11742414](#) DOI: [10.1038/414813a](#)]
- 27 **Crafts TD**, Jensen AR, Blocher-Smith EC, Markel TA. Vascular endothelial growth factor: therapeutic possibilities and challenges for the treatment of ischemia. *Cytokine* 2015; **71**: 385-393 [PMID: [25240960](#) DOI: [10.1016/j.cyto.2014.08.005](#)]
- 28 **Ahmed AS**, Antonsen EL. Immune and vascular dysfunction in diabetic wound healing. *J Wound Care* 2016; **25**: S35-S46 [PMID: [29027849](#) DOI: [10.12968/jowc.2016.25.Sup7.S35](#)]
- 29 **Ramsey DJ**, Arden GB. Hypoxia and Dark Adaptation in Diabetic Retinopathy: Interactions, Consequences, and Therapy. *Curr Diab Rep* 2015; **15**: 118 [PMID: [26493191](#) DOI: [10.1007/s11892-015-0686-2](#)]
- 30 **Lin X**, Xu Y, Pan X, Xu J, Ding Y, Sun X, Song X, Ren Y, Shan PF. Global, regional, and national burden and trend of diabetes in 195 countries and territories: an analysis from 1990 to 2025. *Sci Rep* 2020; **10**: 14790 [PMID: [32901098](#) DOI: [10.1038/s41598-020-71908-9](#)]
- 31 **Elnahry AG**, Ramsey DJ. Automated Image Alignment for Comparing Microvascular Changes Detected by Fluorescein Angiography and Optical Coherence Tomography Angiography in Diabetic Retinopathy. *Semin Ophthalmol* 2021; **36**: 757-764 [PMID: [33784213](#) DOI: [10.1080/08820538.2021.1901122](#)]
- 32 **Arden GB**, Ramsey DJ. Diabetic retinopathy and a novel treatment based on the biophysics of rod photoreceptors and dark adaptation. 2015 Jul 14. In: Webvision: The Organization of the Retina and Visual System [Internet]. Salt Lake City (UT): University of Utah Health Sciences Center; 1995– [PMID: [26247094](#)]
- 33 **Kim EJ**, Lin WV, Rodriguez SM, Chen A, Loya A, Weng CY. Treatment of Diabetic Macular Edema. *Curr Diab Rep* 2019; **19**: 68 [PMID: [31359157](#) DOI: [10.1007/s11892-019-1188-4](#)]
- 34 **Bressler SB**, Beaulieu WT, Glassman AR, Gross JG, Jampol LM, Melia M, Peters MA, Rauser ME; Diabetic Retinopathy Clinical Research Network. Factors Associated with Worsening Proliferative Diabetic Retinopathy in Eyes Treated with Panretinal Photocoagulation or Ranibizumab. *Ophthalmology* 2017; **124**: 431-439 [PMID: [28161147](#) DOI: [10.1016/j.ophtha.2016.12.005](#)]
- 35 Techniques for scatter and local photocoagulation treatment of diabetic retinopathy: Early Treatment Diabetic Retinopathy Study Report no. 3. The Early Treatment Diabetic Retinopathy Study Research Group. *Int Ophthalmol Clin* 1987; **27**: 254-264 [PMID: [3692707](#) DOI: [10.1097/00004397-198702740-00005](#)]
- 36 **Diabetic Retinopathy Clinical Research Network**, Elman MJ, Aiello LP, Beck RW, Bressler NM, Bressler SB, Edwards AR, Ferris FL 3rd, Friedman SM, Glassman AR, Miller KM, Scott IU, Stockdale CR, Sun JK. Randomized trial evaluating ranibizumab plus prompt or deferred laser or triamcinolone plus prompt laser for diabetic macular edema. *Ophthalmology* 2010; **117**: 1064-1077.e35 [PMID: [20427088](#) DOI: [10.1016/j.ophtha.2010.02.031](#)]
- 37 **Solomon SD**, Chew E, Duh EJ, Sobrin L, Sun JK, VanderBeek BL, Wyckoff CC, Gardner TW. Diabetic Retinopathy: A Position Statement by the American Diabetes Association. *Diabetes Care* 2017; **40**: 412-418 [PMID: [28223445](#) DOI: [10.2337/dc16-2641](#)]
- 38 **Flaxel CJ**, Adelman RA, Bailey ST, Fawzi A, Lim JI, Vemulakonda GA, Ying GS. Diabetic Retinopathy Preferred Practice Pattern®. *Ophthalmology* 2020; **127**: P66-P145 [PMID: [31757498](#) DOI: [10.1016/j.ophtha.2019.09.025](#)]
- 39 **Ramsey DJ**, Haddock LJ, Young LH, Elliott D. Complications of subspecialty ophthalmic care: systemic complications from the intravitreal administration of agents that target the vascular endothelial growth factor pathway. *Semin Ophthalmol* 2014; **29**: 263-275 [PMID: [25325852](#) DOI: [10.3109/08820538.2014.959195](#)]
- 40 **Valverde-Megías A**, Cifuentes-Canorea P, Ruiz-Medrano J, Peña-García P, Megías-Fresno A, Donate-López J, García-Feijoo J. Systemic Effects of Repeated Intraocular Dexamethasone Intravitreal Implant in Diabetic Patients: A Retrospective Study. *Diabetes Ther* 2017; **8**: 1087-1096 [PMID: [28918546](#) DOI: [10.1007/s13300-017-0307-y](#)]
- 41 **Ehlers JP**, Yeh S, Maguire MG, Smith JR, Mruthyunjaya P, Jain N, Kim LA, Weng CY, Flaxel CJ, Schoenberger SD, Kim SJ. Intravitreal Pharmacotherapies for Diabetic Macular Edema: A Report by the American Academy of Ophthalmology. *Ophthalmology* 2022; **129**: 88-99 [PMID: [34446301](#) DOI: [10.1016/j.ophtha.2021.07.009](#)]
- 42 **Feldman-Billard S**, Du Pasquier-Fediaevsky L, Héron E. Hyperglycemia after repeated periocular dexamethasone injections in patients with diabetes. *Ophthalmology* 2006; **113**: 1720-1723 [PMID: [17011953](#) DOI: [10.1016/j.ophtha.2006.05.023](#)]
- 43 **Roters S**, Aspacher F, Diestelhorst M. The influence of dexamethasone 0.1% eye drops on plasma cortisol and ACTH concentrations after cataract surgery. *Ophthalmologica* 1996; **210**: 211-214 [PMID: [8841068](#) DOI: [10.1159/000310711](#)]
- 44 **Yazdanpanah L**, Nasiri M, Adarvishi S. Literature review on the management of diabetic foot ulcer. *World J Diabetes* 2015; **6**: 37-53 [PMID: [25685277](#) DOI: [10.4239/wjd.v6.i1.37](#)]
- 45 **Chen Z**, Fu S, Wu Z, Chen J, Huang Y, Wang Y, Fu M. Relationship between plasma angiogenic growth factors and diabetic foot ulcers. *Clin Chim Acta* 2018; **482**: 95-100 [PMID: [29614308](#) DOI: [10.1016/j.cca.2018.03.035](#)]
- 46 **Brem H**, Tomic-Canic M. Cellular and molecular basis of wound healing in diabetes. *J Clin Invest* 2007; **117**: 1219-1222

- [PMID: [17476353](#) DOI: [10.1172/JCI32169](#)]
- 47 **Burgess JL**, Wyant WA, Abdo Abujamra B, Kirsner RS, Jozic I. Diabetic Wound-Healing Science. *Medicina (Kaunas)* 2021; **57** [PMID: [34684109](#) DOI: [10.3390/medicina57101072](#)]
 - 48 **Busted N**, Olsen T, Schmitz O. Clinical observations on the corneal thickness and the corneal endothelium in diabetes mellitus. *Br J Ophthalmol* 1981; **65**: 687-690 [PMID: [7317320](#) DOI: [10.1136/bjo.65.10.687](#)]
 - 49 **Hyndiuk RA**, Kazarian EL, Schultz RO, Seideman S. Neurotrophic corneal ulcers in diabetes mellitus. *Arch Ophthalmol* 1977; **95**: 2193-2196 [PMID: [588113](#) DOI: [10.1001/archophth.1977.04450120099012](#)]
 - 50 **Ljubimov AV**. Diabetic complications in the cornea. *Vision Res* 2017; **139**: 138-152 [PMID: [28404521](#) DOI: [10.1016/j.visres.2017.03.002](#)]
 - 51 **Zhu L**, Titone R, Robertson DM. The impact of hyperglycemia on the corneal epithelium: Molecular mechanisms and insight. *Ocul Surf* 2019; **17**: 644-654 [PMID: [31238114](#) DOI: [10.1016/j.jtos.2019.06.007](#)]
 - 52 **Skarbez K**, Priestley Y, Hoepf M, Koevary SB. Comprehensive Review of the Effects of Diabetes on Ocular Health. *Expert Rev Ophthalmol* 2010; **5**: 557-577 [PMID: [21760834](#) DOI: [10.1586/eop.10.44](#)]
 - 53 **Kavitha KV**, Tiwari S, Purandare VB, Khedkar S, Bhosale SS, Unnikrishnan AG. Choice of wound care in diabetic foot ulcer: A practical approach. *World J Diabetes* 2014; **5**: 546-556 [PMID: [25126400](#) DOI: [10.4239/wjd.v5.i4.546](#)]
 - 54 **de Smet GHJ**, Kroese LF, Menon AG, Jeekel J, van Pelt AWJ, Kleinrensink GJ, Lange JF. Oxygen therapies and their effects on wound healing. *Wound Repair Regen* 2017; **25**: 591-608 [PMID: [28783878](#) DOI: [10.1111/wrr.12561](#)]
 - 55 **Lipsky BA**, Berendt AR. Hyperbaric oxygen therapy for diabetic foot wounds: has hope hurdled hype? *Diabetes Care* 2010; **33**: 1143-1145 [PMID: [20427686](#) DOI: [10.2337/dc10-0393](#)]
 - 56 **Sheikh AY**, Gibson JJ, Rollins MD, Hopf HW, Hussain Z, Hunt TK. Effect of hyperoxia on vascular endothelial growth factor levels in a wound model. *Arch Surg* 2000; **135**: 1293-1297 [PMID: [11074883](#) DOI: [10.1001/archsurg.135.11.1293](#)]
 - 57 **Kaldırım H**, Yazgan S, Ceylan B, Atalay K. The effect of hyperbaric oxygen therapy on retinal thickness and progression of retinopathy in patients with Type 2 diabetes: a prospective cohort study. *Cutan Ocul Toxicol* 2019; **38**: 233-239 [PMID: [31010336](#) DOI: [10.1080/15569527.2019.1608226](#)]
 - 58 **Yoo TK**, Oh E. Diabetes mellitus is associated with dry eye syndrome: a meta-analysis. *Int Ophthalmol* 2019; **39**: 2611-2620 [PMID: [31065905](#) DOI: [10.1007/s10792-019-01110-y](#)]
 - 59 **Barrientos S**, Stojadinovic O, Golinko MS, Brem H, Tomic-Canic M. Growth factors and cytokines in wound healing. *Wound Repair Regen* 2008; **16**: 585-601 [PMID: [19128254](#) DOI: [10.1111/j.1524-475X.2008.00410.x](#)]
 - 60 **Lou-Bonafonte JM**, Bonafonte-Marquez E, Bonafonte-Royo S, Martínez-Carpio PA. Posology, efficacy, and safety of epidermal growth factor eye drops in 305 patients: logistic regression and group-wise odds of published data. *J Ocul Pharmacol Ther* 2012; **28**: 467-472 [PMID: [22537292](#) DOI: [10.1089/jop.2011.0236](#)]
 - 61 **Sacchetti M**, Lambiase A. Diagnosis and management of neurotrophic keratitis. *Clin Ophthalmol* 2014; **8**: 571-579 [PMID: [24672223](#) DOI: [10.2147/OPTH.S45921](#)]
 - 62 **Winkler MA**, Dib C, Ljubimov AV, Saghizadeh M. Targeting miR-146a to treat delayed wound healing in human diabetic organ-cultured corneas. *PLoS One* 2014; **9**: e114692 [PMID: [25490205](#) DOI: [10.1371/journal.pone.0114692](#)]
 - 63 **Eleftheriadou I**, Samakidou G, Tentolouris A, Papanas N, Tentolouris N. Nonpharmacological Management of Diabetic Foot Ulcers: An Update. *Int J Low Extrem Wounds* 2021; **20**: 188-197 [PMID: [33073653](#) DOI: [10.1177/1534734620963561](#)]
 - 64 **Hicks CW**, Selvin E. Epidemiology of Peripheral Neuropathy and Lower Extremity Disease in Diabetes. *Curr Diab Rep* 2019; **19**: 86 [PMID: [31456118](#) DOI: [10.1007/s11892-019-1212-8](#)]
 - 65 **Sun PC**, Chen CS, Kuo CD, Lin HD, Chan RC, Kao MJ, Wei SH. Impaired microvascular flow motion in subclinical diabetic feet with sudomotor dysfunction. *Microvasc Res* 2012; **83**: 243-248 [PMID: [21722653](#) DOI: [10.1016/j.mvr.2011.06.002](#)]
 - 66 **Malik RA**, Veves A, Masson EA, Sharma AK, Ah-See AK, Schady W, Lye RH, Boulton AJ. Endoneurial capillary abnormalities in mild human diabetic neuropathy. *J Neurol Neurosurg Psychiatry* 1992; **55**: 557-561 [PMID: [1640230](#) DOI: [10.1136/jnnp.55.7.557](#)]
 - 67 **Yagihashi S**, Mizukami H, Sugimoto K. Mechanism of diabetic neuropathy: Where are we now and where to go? *J Diabetes Investig* 2011; **2**: 18-32 [PMID: [24843457](#) DOI: [10.1111/j.2040-1124.2010.00070.x](#)]
 - 68 **Zherebitskaya E**, Akude E, Smith DR, Fernyhough P. Development of selective axonopathy in adult sensory neurons isolated from diabetic rats: role of glucose-induced oxidative stress. *Diabetes* 2009; **58**: 1356-1364 [PMID: [19252136](#) DOI: [10.2337/db09-0034](#)]
 - 69 **Shaheen BS**, Bakir M, Jain S. Corneal nerves in health and disease. *Surv Ophthalmol* 2014; **59**: 263-285 [PMID: [24461367](#) DOI: [10.1016/j.survophthal.2013.09.002](#)]
 - 70 **Millodot M**. The influence of age on the sensitivity of the cornea. *Invest Ophthalmol Vis Sci* 1977; **16**: 240-242 [PMID: [844979](#)]
 - 71 **Al-Aqaba MA**, Dhillon VK, Mohammed I, Said DG, Dua HS. Corneal nerves in health and disease. *Prog Retin Eye Res* 2019; **73**: 100762 [PMID: [31075321](#) DOI: [10.1016/j.preteyeres.2019.05.003](#)]
 - 72 **Kaiserman I**, Kaiserman N, Nakar S, Vinker S. Dry eye in diabetic patients. *Am J Ophthalmol* 2005; **139**: 498-503 [PMID: [15767060](#) DOI: [10.1016/j.ajo.2004.10.022](#)]
 - 73 **Manaviat MR**, Rashidi M, Afkhami-Ardekani M, Shoja MR. Prevalence of dry eye syndrome and diabetic retinopathy in type 2 diabetic patients. *BMC Ophthalmol* 2008; **8**: 10 [PMID: [18513455](#) DOI: [10.1186/1471-2415-8-10](#)]
 - 74 **Priyadarsini S**, Whelchel A, Nicholas S, Sharif R, Riaz K, Karamichos D. Diabetic keratopathy: Insights and challenges. *Surv Ophthalmol* 2020; **65**: 513-529 [PMID: [32092364](#) DOI: [10.1016/j.survophthal.2020.02.005](#)]
 - 75 **Badawi AE**, Moemen D, El-Tantawy NL. Epidemiological, clinical and laboratory findings of infectious keratitis at Mansoura Ophthalmic Center, Egypt. *Int J Ophthalmol* 2017; **10**: 61-67 [PMID: [28149778](#) DOI: [10.18240/ijo.2017.01.10](#)]
 - 76 **Zhao H**, He Y, Ren YR, Chen BH. Corneal alteration and pathogenesis in diabetes mellitus. *Int J Ophthalmol* 2019; **12**: 1939-1950 [PMID: [31850180](#) DOI: [10.18240/ijo.2019.12.17](#)]
 - 77 **Han SB**, Yang HK, Hyon JY. Influence of diabetes mellitus on anterior segment of the eye. *Clin Interv Aging* 2019; **14**:

- 53-63 [PMID: 30643394 DOI: 10.2147/CIA.S190713]
- 78 **Chhablani J**, Sharma A, Goud A, Peguda HK, Rao HL, Begum VU, Barteselli G. Neurodegeneration in Type 2 Diabetes: Evidence From Spectral-Domain Optical Coherence Tomography. *Invest Ophthalmol Vis Sci* 2015; **56**: 6333-6338 [PMID: 26436886 DOI: 10.1167/iops.15-17334]
- 79 **Price R**, Smith D, Franklin G, Gronseth G, Pignone M, David WS, Armon C, Perkins BA, Bril V, Rae-Grant A, Halperin J, Licking N, O'Brien MD, Wessels SR, MacGregor LC, Fink K, Harkless LB, Colbert L, Callaghan BC. Oral and Topical Treatment of Painful Diabetic Polyneuropathy: Practice Guideline Update Summary: Report of the AAN Guideline Subcommittee. *Neurology* 2022; **98**: 31-43 [PMID: 34965987 DOI: 10.1212/WNL.0000000000013038]
- 80 **Jensen TS**. Anticonvulsants in neuropathic pain: rationale and clinical evidence. *Eur J Pain* 2002; **6** Suppl A: 61-68 [PMID: 11888243 DOI: 10.1053/eujp.2001.0324]
- 81 **Wang HY**, Tseng PT, Stubbs B, Carvalho AF, Li DJ, Chen TY, Lin PY, Hsueh YT, Chen YZ, Chen YW, Chu CS. The risk of glaucoma and serotonergic antidepressants: A systematic review and meta-analysis. *J Affect Disord* 2018; **241**: 63-70 [PMID: 30096594 DOI: 10.1016/j.jad.2018.07.079]
- 82 **Fu Y**, Dai Q, Zhu L, Wu S. Antidepressants use and risk of cataract development: a systematic review and meta-analysis. *BMC Ophthalmol* 2018; **18**: 31 [PMID: 29409486 DOI: 10.1186/s12886-018-0699-0]
- 83 **Richa S**, Yazbek JC. Ocular adverse effects of common psychotropic agents: a review. *CNS Drugs* 2010; **24**: 501-526 [PMID: 20443647 DOI: 10.2165/11533180-000000000-00000]
- 84 **Ammermann F**, Meinel FG, Beller E, Busse A, Streckenbach F, Teichert C, Weinrich M, Neumann A, Weber MA, Heller T. Concomitant chronic venous insufficiency in patients with peripheral artery disease: insights from MR angiography. *Eur Radiol* 2020; **30**: 3908-3914 [PMID: 32100090 DOI: 10.1007/s00330-020-06696-x]
- 85 **Poznyak A**, Grechko AV, Poggio P, Myasoedova VA, Alfieri V, Orekhov AN. The Diabetes Mellitus-Atherosclerosis Connection: The Role of Lipid and Glucose Metabolism and Chronic Inflammation. *Int J Mol Sci* 2020; **21** [PMID: 32155866 DOI: 10.3390/ijms21051835]
- 86 **Beckman JA**, Creager MA, Libby P. Diabetes and atherosclerosis: epidemiology, pathophysiology, and management. *JAMA* 2002; **287**: 2570-2581 [PMID: 12020339 DOI: 10.1001/jama.287.19.2570]
- 87 **Everett E**, Mathioudakis N. Update on management of diabetic foot ulcers. *Ann N Y Acad Sci* 2018; **1411**: 153-165 [PMID: 29377202 DOI: 10.1111/nyas.13569]
- 88 **Foussard N**, Saulnier PJ, Potier L, Ragot S, Schneider F, Gand E, Monlun M, Baillet-Blanco L, Velho G, Marre M, Roussel R, Rigalleau V, Mohammedi K, Hadjadj S; SURDIAGENE Study Group. Relationship Between Diabetic Retinopathy Stages and Risk of Major Lower-Extremity Arterial Disease in Patients With Type 2 Diabetes. *Diabetes Care* 2020; **43**: 2751-2759 [PMID: 33055101 DOI: 10.2337/dc20-1085]
- 89 **Ratchford EV**. Medical management of claudication. *J Vasc Surg* 2017; **66**: 275-280 [PMID: 28533077 DOI: 10.1016/j.jvs.2017.02.040]
- 90 **Mizener JB**, Podhajsky P, Hayreh SS. Ocular ischemic syndrome. *Ophthalmology* 1997; **104**: 859-864 [PMID: 9160035 DOI: 10.1016/s0161-6420(97)30221-8]
- 91 **Brown GC**, Magargal LE. The ocular ischemic syndrome. Clinical, fluorescein angiographic and carotid angiographic features. *Int Ophthalmol* 1988; **11**: 239-251 [PMID: 3182177 DOI: 10.1007/BF00131023]
- 92 **Sivalingam A**, Brown GC, Magargal LE. The ocular ischemic syndrome. III. Visual prognosis and the effect of treatment. *Int Ophthalmol* 1991; **15**: 15-20 [PMID: 2010264 DOI: 10.1007/BF00150974]
- 93 **Al Kahtani ES**, Khandekar R, Al-Rubeaan K, Youssef AM, Ibrahim HM, Al-Sharqawi AH. Assessment of the prevalence and risk factors of ophthalmoplegia among diabetic patients in a large national diabetes registry cohort. *BMC Ophthalmol* 2016; **16**: 118 [PMID: 27449153 DOI: 10.1186/s12886-016-0272-7]
- 94 **Smith BE**, Dyck PJ. Subclinical histopathological changes in the oculomotor nerve in diabetes mellitus. *Ann Neurol* 1992; **32**: 376-385 [PMID: 1416807 DOI: 10.1002/ana.410320312]
- 95 **International Working Group on the Diabetic Foot (IWGDF)**. Practical guidelines on the prevention and management of diabetic foot disease. IWGDF, 2019. [cited 24 August 2022]. Available from: <https://iwgdfguidelines.org/wp-content/uploads/2019/05/IWGDF-Guidelines-2019.pdf>
- 96 **Margolis TP**. Neurotrophic Keratopathy: Ophthalmology's Diabetic Foot Problem. *Eye Contact Lens* 2021; **47**: 136-139 [PMID: 33599469 DOI: 10.1097/ICL.0000000000000774]
- 97 **Liesegang TJ**. Corneal complications from herpes zoster ophthalmicus. *Ophthalmology* 1985; **92**: 316-324 [PMID: 3873048 DOI: 10.1016/s0161-6420(85)34034-4]
- 98 **Dörr S**, Freier F, Schlecht M, Lobmann R. Bacterial diversity and inflammatory response at first-time visit in younger and older individuals with diabetic foot infection (DFI). *Acta Diabetol* 2021; **58**: 181-189 [PMID: 32944830 DOI: 10.1007/s00592-020-01587-5]
- 99 **Sand D**, She R, Shulman IA, Chen DS, Schur M, Hsu HY. Microbial keratitis in Los Angeles: the Doheny Eye Institute and the Los Angeles County Hospital experience. *Ophthalmology* 2015; **122**: 918-924 [PMID: 25600200 DOI: 10.1016/j.ophtha.2014.11.027]
- 100 **Lone AM**, Zaroo MI, Laway BA, Pala NA, Bashir SA, Rasool A. Vacuum-assisted closure versus conventional dressings in the management of diabetic foot ulcers: a prospective case-control study. *Diabet Foot Ankle* 2014; **5** [PMID: 24765245 DOI: 10.3402/dfa.v5.23345]
- 101 **Malafa MM**, Coleman JE, Bowman RW, Rohrich RJ. Perioperative Corneal Abrasion: Updated Guidelines for Prevention and Management. *Plast Reconstr Surg* 2016; **137**: 790e-798e [PMID: 27119941 DOI: 10.1097/PRS.0000000000002108]
- 102 **Dua HS**, Gomes JA, King AJ, Maharajan VS. The amniotic membrane in ophthalmology. *Surv Ophthalmol* 2004; **49**: 51-77 [PMID: 14711440 DOI: 10.1016/j.survophthal.2003.10.004]
- 103 **Li BY**, Tan W, Zou JL, He Y, Yoshida S, Jiang B, Zhou YD. Role of interferons in diabetic retinopathy. *World J Diabetes* 2021; **12**: 939-953 [PMID: 34326947 DOI: 10.4239/wjd.v12.i7.939]
- 104 **Kang Q**, Yang C. Oxidative stress and diabetic retinopathy: Molecular mechanisms, pathogenetic role and therapeutic implications. *Redox Biol* 2020; **37**: 101799 [PMID: 33248932 DOI: 10.1016/j.redox.2020.101799]

- 105 **Silva KC**, Rosales MA, Hamassaki DE, Saito KC, Faria AM, Ribeiro PA, Faria JB, Faria JM. Green tea is neuroprotective in diabetic retinopathy. *Invest Ophthalmol Vis Sci* 2013; **54**: 1325-1336 [PMID: [23299475](#) DOI: [10.1167/iovs.12-10647](#)]
- 106 **Varney JE**, Weiland TJ, Inder WJ, Jelinek GA. Effect of hospital-based telephone coaching on glycaemic control and adherence to management guidelines in type 2 diabetes, a randomised controlled trial. *Intern Med J* 2014; **44**: 890-897 [PMID: [24963611](#) DOI: [10.1111/imj.12515](#)]
- 107 **Konstantinidis L**, Carron T, de Ancos E, Chinet L, Hagon-Traub I, Zuercher E, Peytremann-Bridevaux I. Awareness and practices regarding eye diseases among patients with diabetes: a cross sectional analysis of the CoDiab-VD cohort. *BMC Endocr Disord* 2017; **17**: 56 [PMID: [28882117](#) DOI: [10.1186/s12902-017-0206-2](#)]



Published by **Baishideng Publishing Group Inc**
7041 Koll Center Parkway, Suite 160, Pleasanton, CA 94566, USA

Telephone: +1-925-3991568

E-mail: bpgoffice@wjgnet.com

Help Desk: <https://www.f6publishing.com/helpdesk>

<https://www.wjgnet.com>

