

Gas-forming liver abscess associated with rapid hemolysis in a diabetic patient

Miwa Kurasawa, Takashi Nishikido, Junko Koike, Shin-ichi Tominaga, Hiroyuki Tamemoto

Miwa Kurasawa, Takashi Nishikido, Department of Internal Medicine, Nishi-agatsuma Welfare Hospital, Naganohara-machi, Agatsuma-gun, Gunma Prefecture 377-1308, Japan
Junko Koike, Clinical Laboratory, Nishi-agatsuma Welfare Hospital, Naganohara-machi, Agatsuma-gun, Gunma Prefecture 377-1308, Japan

Shin-ichi Tominaga, Hiroyuki Tamemoto, Department of Biochemistry, Jichi Medical University, Shimotsuke City, Tochigi Prefecture 329-0498, Japan

Author contributions: Kurasawa M designed the report; Kurasawa M, Nishikido T and Koike J collected the patient's data; Tominaga S and Tamemoto H analyzed the data and wrote the paper.

Correspondence to: Hiroyuki Tamemoto, MD, PhD, Associate Professor, Department of Biochemistry, Jichi Medical University, Yakushiji 3311-1, Shimotsuke City, Tochigi Prefecture 329-0498, Japan. tamemoto@jichi.ac.jp

Telephone: +81-285-587324 Fax: +81-285-442158

Received: November 28, 2013 Revised: March 10, 2014

Accepted: March 17, 2014

Published online: April 15, 2014

the survival rate is very poor compared with those of *K. pneumoniae* and *E. coli*. Therefore, for every case that presents with a gas-forming liver abscess, the possibility of *CP* should be considered, and immediate aspiration of the abscess and Gram staining are important.

© 2014 Baishideng Publishing Group Co., Limited. All rights reserved.

Key words: Liver abscess; Gas-forming; *Clostridium perfringens*; Hemolysis; Diabetes

Core tip: Gas-forming liver abscess caused by *Clostridium perfringens* can result in massive hemolysis and death within several hours. For survival, urgent surgical intervention and antibiotic administration are necessary.

Kurasawa M, Nishikido T, Koike J, Tominaga S, Tamemoto H. Gas-forming liver abscess associated with rapid hemolysis in a diabetic patient. *World J Diabetes* 2014; 5(2): 224-229 Available from: URL: <http://www.wjgnet.com/1948-9358/full/v5/i2/224.htm> DOI: <http://dx.doi.org/10.4239/wjd.v5.i2.224>

Abstract

We experienced a case of liver abscess due to *Clostridium perfringens* (*CP*) complicated with massive hemolysis and rapid death in an adequately controlled type 2 diabetic patient. The patient died 6 h after his first visit to the hospital. *CP* was later detected in a blood culture. We searched for case reports of *CP* septicemia and found 124 cases. Fifty patients survived, and 74 died. Of the 30 patients with liver abscess, only 3 cases survived following treatment with emergency surgical drainage. For the early detection of *CP* infection, detection of Gram-positive rods in the blood or drainage fluid is important. Spherocytes and ghost cells indicate intravascular hemolysis. The prognosis is very poor once massive hemolysis occurs. The major causative organisms of gas-forming liver abscess in diabetic patients are *Klebsiella pneumoniae* (*K. pneumoniae*) and *Escherichia coli* (*E. coli*). Although *CP* is relatively rare,

INTRODUCTION

Gas-forming infections are an example of a severe type of infection in diabetic patients. Although life threatening, there still remains time for treatment^[1,2]. However, in rare cases of *Clostridium perfringens* (*CP*) infection, the time remaining for the patient is very limited^[3-7]. *CP* is an anaerobic Gram-positive rod that is found in the soil and the human gastrointestinal and urogenital tracts. *CP* causes septicemia in cases of food intoxication, wound-associated soft tissue infections, liver abscess, and lung abscess. *CP* may cause septicemia without any apparent wound through bacterial translocation^[5-8]. Patients typically have an underlying condition such as diabetes, malignancy, liver cirrhosis, or an immunosuppressive state^[4,23].

In some reports, *CP* septicemia occurred after an invasive procedure in the hepatobiliary tract^[24-26] or gastrointestinal tract or following gynecological treatment^[27,28] or line insertion^[29]. Early diagnosis is difficult because only nonspecific inflammation and gas formation in the focus are present. However, once α -toxin triggers hemolysis, it progresses very rapidly and is followed by acidosis and renal failure^[30,31]. According to the literature, the mortality rate ranges from 70% to 100%^[3]. For survival, surgical removal of the focus, appropriate antibiotics, control of hemolysis, and supportive care including hemodialysis are necessary. These treatments should be started before the blood culture result is returned. For early diagnosis, the detection of spherocytes and Gram-positive rods in the blood is important^[5,32,33]. We experienced a case of liver abscess in an adequately controlled diabetic patient without any triggering event. The patient died within hours following massive hemolysis and cardiac arrest. Although the majority of gas-forming infections in diabetics are caused by *Escherichia coli* (*E. coli*) and *Klebsiella pneumoniae* (*K. pneumoniae*)^[34], the possibility of *CP* infection should be considered.

CASE REPORT

The patient was a 65-year-old Brazilian of Japanese origin. He had a 3-day history of fever, appetite loss, nausea, and upper abdominal pain. The patient had type 2 diabetes treated with an oral hypoglycemic agent. He also had hypertension and dyslipidemia. He had a history of coronary stenting but no history of liver cirrhosis or malignancy. On physical examination, consciousness was clear, his blood pressure was 157/90 mmHg, and hyperventilation and coldness of the limbs were noted. Slight scleral jaundice and slight tenderness of the abdomen were noted. Laboratory examinations indicated mild liver dysfunction and elevation of serum bilirubin, C-reactive protein, and the white blood cell count (Table 1). At this time, the serum did not show any sign of intravascular hemolysis (Figure 1A). CT of the abdomen revealed a liver abscess 4 cm in diameter with gas formation in the right lobe (Figure 1C). A blood culture sample was taken, and ceftriaxone injection was started immediately. The patient briefly returned to his dormitory to prepare for admission and was found unconscious by a fellow worker. He was transferred to the hospital, and CPR was performed in vain. The serum color at this time point revealed strong hemolysis (Figure 1B). He died 6 h after his first visit to the hospital. The remarkably high levels of serum potassium (11.8 mEq/L) and lactate dehydrogenase (LDH) (6203 IU/L) during CPR suggested massive intravascular hemolysis. *CP* was later detected in the blood culture. Autopsy was refused, and we were unable to determine whether he had an occult malignancy.

Recently, van Bunderen *et al.*^[3] reported 40 cases of *CP* septicemia and hemolysis between 1990 and 2010. In total, 80% of the patients had died; among the 11 cases with liver abscess, 10 (90.9%) had died. These 10 cases included two cases of microabscess. In one case,

Table 1 Serial laboratory results for a patient with liver abscess and massive hemolysis caused by *Clostridium perfringens*

Parameter	Admission	On CPR	Reference range
White blood count ($\times 10^9$ /L)	24.8	26.0	3.5 to 9.7
Red blood count ($\times 10^9$ /L)	4980	1280	4380 to 5770
Hemoglobin (g/L)	135	81	136 to 183
Hematocrit (%)	40.7	10.8	40.4 to 51.9
Platelet ($\times 10^9$ /L)	243	118.8	140 to 379
Total bilirubin (mg/dL)	6.4	6.96	0.2 to 1.0
Aspartate aminotransferase (IU/L)	140	261	8 to 38
Alanine aminotransferase (IU/L)	102	297	4 to 44
Alkaline phosphatase (IU/L)	178	469	104 to 338
γ -glutamyl transpeptidase (IU/L)	25	6	18 to 66
Lactate dehydrogenase (IU/L)	373	6203	106 to 211
Creatine phosphokinase (IU/L)	220	438	104 to 338
Urea (mg/dL)	24.2	30.5	8 to 20
Creatinine (mg/dL)	1.33	1.12	0.63 to 1.03
Sodium (mEq/L)	134	128	137 to 147
Potassium (mEq/L)	4.6	11.8	3.5 to 5.0
Chloride (mEq/L)	95	84	98 to 108
C-reactive protein (mg/dL)	23.2	16.0	< 0.30
International normalized ratio	1.05	19.4	0.9 to 1.1
APTT (s)	38	122.9	25 to 40
Glucose (mg/dL)	226	129	

APTT: Activated partial thromboplastin time.

the focus of infection was removed, and the patient survived. On the other hand, Fujita *et al.*^[35] studied patients with systemic inflammatory response syndrome (SIRS) with *CP*-positive blood cultures and reported that 5 of 18 cases had died (27.8%). Yang *et al.*^[36] reported the prognosis of *CP* septicemia in a tertiary care hospital. They found 93 cases over 10 years, and the 30-d mortality rate was 26.9%. Therefore, the mortality rate of *CP* septicemia differs considerably. We hypothesized that the complication of liver abscess decreases the survival rate. We searched PubMed for papers published since 2010 and the database of the Japan Medical Abstract Society since 1994 with the keywords “*Clostridium perfringens*” and “septicemia”. We found 20 cases from PubMed and 104 cases from Japan, including our case^[4-33,35,37-39]. Fifty patients survived, and 74 (59.7%) died.

Several possible triggers of septicemia were found, including transarterial embolization of the hepatoma^[24,25], laparoscopic cholecystectomy^[26], amniocentesis^[27], abortion^[28], and intravenous line insertion^[29]. Among the 30 cases with liver abscess, 27 (90%) died. Six cases underwent drainage or laparotomy, and three cases survived^[8,30,38]. Among the cases with liver abscess, 23 were male and 7 were female; the average patient age was 67.2 years old, and 11 patients had diabetes. The median time from the first visit to death was only 6 h. Of the 74 deceased patients, 45 were male, 21 were female, and 8 were not described; the average age was 64.4 years old. Malignancy was the frequent underlying disease. Twenty-one cases had a history of cancer in the liver, stomach, colon, rectum, gall bladder, biliary duct, lung, pancreas, breast, prostate gland, or uterus. Ten cases had a history of leukemia, lymphoma, or multiple myeloma. One patient had

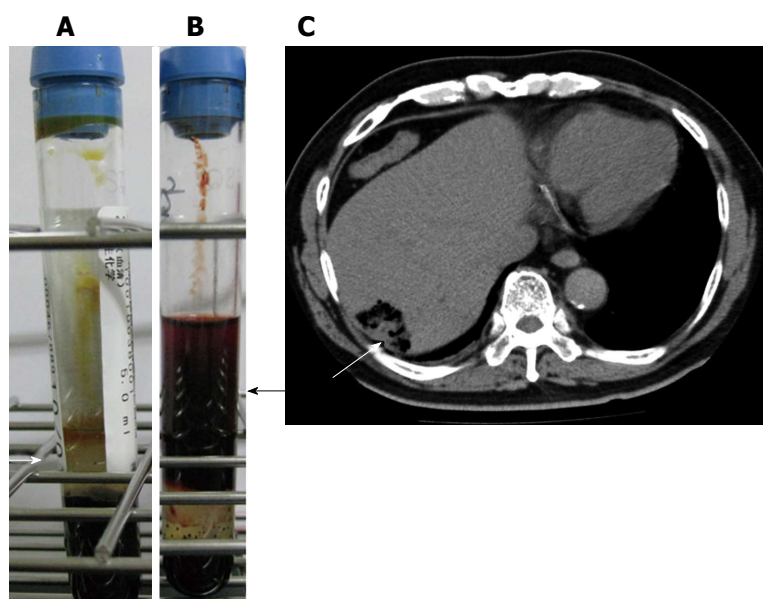


Figure 1 The serum color before and after massive hemolysis and computed tomography imaging results. A: Patient serum color on admission showed no sign of hemolysis (white arrow); B: The dark red color of serum taken during CPR indicated massive hemolysis (black arrow); C: Computed tomography of the abdomen revealed a 4 cm × 2 cm abscess with gas formation in the right lobe (white arrow).

a brain tumor. In total, 30 cases (45.5%) had a history of at least one malignancy. Eighteen cases had diabetes. Four cases had liver cirrhosis. The median time from the first visit to death was 6 h. Only 12 cases (16%) had undergone emergency surgery or drainage. Two patients received hemoperfusion using a polymyxin B-immobilized fiber column (PMX-F), which is used for endotoxin removal in Japan and Italy^[40-43]. Of the 50 surviving patients, 16 were male, 19 were female, and 15 were not described. Females were significantly more prevalent among the survivors, according to a chi-squared test ($P < 0.05$). Three cases involved children younger than 2 years old. The average age, excluding these small children, was 58.1 years. The age difference between the deceased and surviving cases was not significant ($P = 0.06$), according to a two-sided t test. Six cases had leukemia, and 4 cases had cancer or sarcoma in the breast, uterus, or colon. Six cases had diabetes. Twenty (40%) cases underwent surgical removal or drainage of the focus. A significantly greater number of patients who underwent surgical debridement or drainage were among the surviving cases compared with the deceased cases, according to a chi-squared test ($P < 0.01$). PMX-F was used to treat 5 patients who survived. Among the surviving cases, steroid pulse therapy was performed in three cases and hyperbaric oxygen therapy was used in two.

DISCUSSION

Although our case did not show anemia at first presentation and the size of liver abscess was only 4 cm, he developed massive fatal hemolysis within hours, despite prompt treatment with the appropriate antibiotics. Therefore, *CP* septicemia should be considered in diabetic patients with fever and gas-forming lesions before any signs of hemolysis develop. van Bunderen *et al*^[43] reported 40 cases of septicemia caused by *CP* during 1990-2010. Over half of the patients presented elevated bilirubin and LDH as well as anemia, suggesting hemolysis at the

initial presentation. Thirty-two of the patients died, and the median time from admission to death was only 8 h. We searched new cases of *CP* septicemia. We found 124 cases, and the death rate was 59.7%. However, in cases with liver abscess, the death rate reached 90%, and the median time from visit to death was only 6 h. Rapid hemolysis caused by α -toxin is an important complication that makes rescue difficult. The α -toxin of *CP* has two domains plus one loop in between. The N-terminal domain has phospholipase activity, and the C-terminal domain is hydrophobic and inserts into the cell membrane^[44]. The loop between the N- and C-terminal domains contains a GM1 ganglioside-binding motif and specifically binds GM1a. In addition to disrupting membrane phospholipids through phospholipase activity, α -toxin binding to GM1a triggers specific signaling events. The activation of a tyrosine kinase A (TrkA)^[45] and the subsequent signaling cascade results in the release of tumor necrosis factor- α (TNF- α). The catastrophic events induced by α -toxin may in part be mediated by TNF- α signaling. The hemolysis of erythrocytes by α -toxin is reported to depend on Ca^{2+} uptake^[46].

The key for patient rescue is how fast the appropriate treatments are started. At the moment of suspicion of *CP* septicemia, aggressive early management is warranted, including timely debridement or drainage of the focus, initiation of appropriate antibiotics without delay, and support of circulation with a multi-disciplinary team approach. For the early diagnosis of *CP* infection, Gram staining of the blood or drainage sample is important because *CP* is a Gram-positive rod, whereas *K. pneumoniae* and *E. coli* are Gram negative. The early signs of hemolysis are elevated LDH, total or indirect bilirubin, and potassium. Spherocytes or ghost cells may be found in the blood film. A red color of the serum or hemoglobinuria may be observed after substantial hemolysis.

Shah *et al*^[47] reported 25 cases of *CP* septicemia in a tertiary-care hospital from 1995 to 2003 and classified antibiotics into two categories. The antibiotics classified as “appropriate” for *Clostridium* were penicillin G, clinda-

mycin, cefoxitin, metronidazole, ampicillin/sulbactam, piperacillin/tazobactam, and imipenem/cilastatin; other antibiotics were classified as “insufficient”. Patients treated with “insufficient” antibiotics had a significantly higher 2-d mortality rate (75%) compared with patients treated with “appropriate” antibiotics (12.5%). Clindamycin, metronidazole, and rifampicin have been shown to be effective methods to reduce the release of α -toxin^[48]. However, penicillin and cephalosporin do not have such activity. Oda *et al.*^[49] have reported that erythromycin pretreatment reduces the release of TNF- α from activated neutrophils and suppresses hemolysis.

Because α -toxin has enzymatic activity, methods to neutralize or eliminate this toxin are needed. Unfortunately, we were unable to find any established method of doing so. PMX-F is used in septic shock treatment. PMX-F binds endotoxin, monocytes, activated neutrophils, and anandamide, decreasing inflammatory cytokines and other mediators. A review by Cruz *et al.*^[40] analyzed 987 patients treated with PMX-F and 447 patients treated with conventional medical therapies. PMX-F increased the mean arterial pressure by 19 mmHg while reducing the dopamine/dobutamine dose by 1.8 μ g/kg per min. PMX-F therapy was associated with a significantly lower mortality risk (RR = 0.53; 95%CI: 0.43-0.65). However, the number of reported cases is currently too small to discuss the effectiveness of PMX-F in the treatment of CP septicemia. Ochi *et al.*^[46] reported that flunarizine, a T-type Ca^{2+} channel blocker and tetrandrine, an L- and T-type Ca^{2+} channel blocker, inhibited hemolysis by α -toxin. Nagahama *et al.*^[50] reported that the C-terminal recombinant peptide of α -toxin was effective as a vaccine to protect against hemolysis in an animal experiment.

Empirical antibiotic therapy should be started before the culture results are returned. The major causative organisms of gas-forming liver abscesses are *K. pneumoniae* and *E. coli*^[1,2,34]. These organisms can also cause fatal infections, and endophthalmitis or meningitis may occur^[51], but the mortality rate is not as high as that of CP. A review of 46 cases reported death in *K. pneumoniae* liver abscess for 11 of 43 (25.6%) patients^[51]. According to a report from China, 95% of the patients with liver abscess were eventually cured if treated radically^[34]. Fortunately, CP septicemia is rare. Kasai *et al.*^[52] reported that among cases of severe infection in diabetic patients in Japan, 119 cases presented with a gas-forming abscess, and only 8 cases were positive for *Clostridium*. Kurai *et al.*^[53] reported that among 5011 blood samples that were positive for any bacteria, only 41 were positive for *Clostridium*. Of the 41 samples, 16 were confirmed as septicemia, and 9 of the 16 were positive for CP. According to a report from Canada, the incidence of CP septicemia in the community is 0.7 in 100000 per year^[54]. Additionally, in hospital-based studies, CP septicemia is very rare. Zahar reported 45 cases of anaerobic bacteremia among 7989 positive blood cultures in a cancer center during 1993-1998^[55]; seven of them were CP septicemia. Woo *et al.*^[53] reported 38 cases of *Clostridium* septicemia in a large hospital from

1998 to 2001; 79% of them were caused by CP, and the overall mortality was 29%. Younger age and gastrointestinal/hepatobiliary tract disease were associated with mortality. However, considering the very high mortality rate associated with liver abscess, excluding CP infection is important.

In summary, CP septicemia is a rare but well-known cause of massive intravascular hemolysis. Diabetic patients with fever and gas-forming lesions should always be suspected of having CP septicemia.

COMMENTS

Case characteristics

A 65-year-old male with treated diabetes presented with fever and upper abdominal pain.

Clinical diagnosis

Hypertension, hyperventilation, coldness of limbs, scleral jaundice, and tenderness of the abdomen were noted.

Differential diagnosis

Obstructive jaundice complicated with biliary infection and liver abscess.

Laboratory findings

White blood cell $24.8 \times 10^9/\text{L}$, hemoglobin 135 g/L, total bilirubin 6.4 mg/dL, aspartate aminotransferase 140 IU/L, alanine aminotransferase 178 IU/L, creatinine 1.33 mg/dL, C-reactive protein 23.2 mg/dL, and glucose 226 mg/dL.

Imaging diagnosis

Computed tomography imaging showed a gas-forming mass (4 cm \times 2 cm) in the right lobe of the liver.

Pathological diagnosis

Autopsy was not allowed, and blood culture revealed infection by *Clostridium perfringens*.

Treatment

Injection of ceftriaxone was started immediately.

Related reports

The reported mortality rate of *Clostridium perfringens* septicemia varies widely from 26.9% to 80%; however, 90% of patients with liver abscess have been reported to die.

Term explanation

Polymyxin B-immobilized fiber column (PMX-F) is hemoperfusion with a polymyxin B-immobilized fiber column used to remove endotoxin in cases of septic shock.

Experiences and lessons

Although rare, fatal liver abscess patients should be under close observation, and the possibility of *Clostridium perfringens* infection should be considered upon the slightest sign of hemolysis.

Peer review

This is a well written manuscript in which the author gave detailed description of death report associated with CP infection.

REFERENCES

- 1 Tatsuta T, Wada T, Chinda D, Tsushima K, Sasaki Y, Shimoyama T, Fukuda S. A case of gas-forming liver abscess with diabetes mellitus. *Intern Med* 2011; **50**: 2329-2332 [PMID: 22001459]
- 2 Hagiya H, Kuroe Y, Nojima H, Otani S, Sugiyama J, Naito H, Kawanishi S, Hagioka S, Morimoto N. Emphysematous liver abscesses complicated by septic pulmonary emboli in patients with diabetes: two cases. *Intern Med* 2013; **52**: 141-145 [PMID: 23291690 DOI: 10.2169/internalmedicine.52.8737]
- 3 van Bunderen CC, Bomers MK, Wesdorp E, Peerbooms P, Veenstra J. *Clostridium perfringens* septicaemia with massive intravascular haemolysis: a case report and review of the literature. *Neth J Med* 2010; **68**: 343-346 [PMID: 20876913]

- 4 **Smith AM**, Thomas J, Mostert PJ. Fatal case of *Clostridium perfringens* enteritis and bacteraemia in South Africa. *J Infect Dev Ctries* 2011; **5**: 400-402 [PMID: 21628819]
- 5 **McIlwaine K**, Leach MT. *Clostridium perfringens* septicaemia. *Br J Haematol* 2013; **163**: 549 [PMID: 24016137 DOI: 10.1111/bjh.12551]
- 6 Gas Gangrene Caused By *Clostridium Perfringens* Involving the Liver, Spleen, and Heart in a Man 20 Years After an Orthotopic Liver Transplant: A Case Report. *Exp Clin Transplant* 2013; **12**: 165-168 [PMID: 23962047 DOI: 10.6002/ect.2013.0034]
- 7 **Okon E**, Bishburg E, Ugras S, Chan T, Wang H. *Clostridium perfringens* meningitis, *Plesiomonas shigelloides* sepsis: A lethal combination. *Am J Case Rep* 2013; **14**: 70-72 [PMID: 23569567 DOI: 10.12659/AJCR.883830]
- 8 **Rajendran G**, Bothma P, Brodbeck A. Intravascular haemolysis and septicaemia due to *Clostridium perfringens* liver abscess. *Anaesth Intensive Care* 2010; **38**: 942-945 [PMID: 20865884]
- 9 **Atia A**, Raiyani T, Patel P, Patton R, Young M. *Clostridium perfringens* bacteremia caused by choledocholithiasis in the absence of gallbladder stones. *World J Gastroenterol* 2012; **18**: 5632-5634 [PMID: 23112558 DOI: 10.3748/wjg.v18.i39.5632]
- 10 **Mutters NT**, Stoffels S, Eisenbach C, Zimmermann S. Ischaemic intestinal perforation complicated by *Clostridium perfringens* sepsis in a diabetic patient. *Infection* 2013; **41**: 1033-1035 [PMID: 23389817 DOI: 10.1007/s15010-013-0417-z]
- 11 **Hugelshofer M**, Achermann Y, Kovari H, Dent W, Hombach M, Bloemberg G. Meningoencephalitis with subdural empyema caused by toxigenic *Clostridium perfringens* type A. *J Clin Microbiol* 2012; **50**: 3409-3411 [PMID: 22895036 DOI: 10.1128/JCM.00802-12]
- 12 **Lazarescu C**, Kimmoun A, Blatt A, Bastien C, Levy B. *Clostridium perfringens* gangrenous cystitis with septic shock and bone marrow necrosis. *Intensive Care Med* 2012; **38**: 1906-1907 [PMID: 22797355 DOI: 10.1007/s00134-013-2647-4]
- 13 **Salvador C**, Kropshofer G, Niederwanger C, Trieb T, Meister B, Neu N, Müller T. Fulminant *Clostridium perfringens* sepsis during induction chemotherapy in childhood leukemia. *Pediatr Int* 2012; **54**: 424-425 [PMID: 22631574 DOI: 10.1111/j.1442-200X.2011.03436.x]
- 14 **Adams BN**, Lekovic JP, Robinson S. *Clostridium perfringens* sepsis following a molar pregnancy. *Am J Obstet Gynecol* 2014; **210**: e13-e14 [PMID: 24096275 DOI: 10.1016/j.ajog.2013.09.045]
- 15 **Juntermanns B**, Radunz S, Heuer M, Vernadakis S, Reis H, Gallinat A, Treckmann J, Kaiser G, Paul A, Saner F. Fulminant septic shock due to *Clostridium perfringens* skin and soft tissue infection eight years after liver transplantation. *Ann Transplant* 2011; **16**: 143-146 [PMID: 21959524]
- 16 **Watt J**, Amini A, Mosier J, Gustafson M, Wynne JL, Friese R, Gruessner RW, Rhee P, O'Keeffe T. Treatment of severe hemolytic anemia caused by *Clostridium perfringens* sepsis in a liver transplant recipient. *Surg Infect (Larchmt)* 2012; **13**: 60-62 [PMID: 22316146 DOI: 10.1089/sur.2010.092]
- 17 **Ohtani S**, Watanabe N, Kawata M, Harada K, Himeji M, Murakami K. Massive intravascular hemolysis in a patient infected by a *Clostridium perfringens*. *Acta Med Okayama* 2006; **60**: 357-360 [PMID: 17189980]
- 18 **Kuroda S**, Okada Y, Mita M, Okamoto Y, Kato H, Ueyama S, Fujii I, Morita S, Yoshida Y. Fulminant massive gas gangrene caused by *Clostridium perfringens*. *Intern Med* 2005; **44**: 499-502 [PMID: 15942103]
- 19 **Ito M**, Takahashi N, Saitoh H, Shida S, Nagao T, Kume M, Kameoka Y, Tagawa H, Fujishima N, Hirokawa M, Tazawa H, Minato T, Yamada S, Sawada K. Successful treatment of necrotizing fasciitis in an upper extremity caused by *Clostridium perfringens* after bone marrow transplantation. *Intern Med* 2011; **50**: 2213-2217 [PMID: 21963743 DOI: 10.2169/internalmedicine.50.5829]
- 20 **Kurashina R**, Shimada H, Matsushima T, Doi D, Asakura H, Takeshita T. Spontaneous uterine perforation due to clostridial gas gangrene associated with endometrial carcinoma. *J Nippon Med Sch* 2010; **77**: 166-169 [PMID: 20610901]
- 21 **Terada K**, Kawano S, Kataoka N and Morita T. Bacteremia of *Clostridium difficile* and *Clostridium perfringens* with transient eosinophilia in a premature infant. *Kawasaki Medical J* 1990; **16**: 71-74
- 22 **Kimura C**, Miura A, Sato I, Suzuki S. [Acute myelocytic leukemia associated with *Clostridium perfringens* (CP) septicemia: report of 3 cases]. *Nihon Naika Gakkai Zasshi* 1994; **83**: 1351-1352 [PMID: 7983415]
- 23 **Shetty P**, Deans R, Abbott J. A case of *Clostridium perfringens* infection in uterine sarcoma. *Aust N Z J Obstet Gynaecol* 2010; **50**: 495-496 [PMID: 21039388 DOI: 10.1111/j.1479-828X.2010.01215.x]
- 24 **Nakanishi H**, Chuganji Y, Uraushihara K, Yamamoto T, Araki A, Sasaki N, Momoi M, Kawahara Y. An autopsy case of the hepatocellular carcinoma associated with multiple myeloma which developed fatal massive hemolysis due to the *Clostridium perfringens* septicemia following TAE. *Nihon Shokakibyo Gakkai Zasshi* 2003; **100**: 1395-1399 [PMID: 14748326]
- 25 **Kashimura S**, Fujita Y, Imamura S, Shimizu T, Imai J, Tsunoda Y, Ito T, Nagakubo S, Morohoshi Y, Mizukami T and Komatsu H. An autopsy case of hepatocellular carcinoma, which developed a fatal massive hemolysis as a complication of *Clostridium perfringens* infection after transarterial chemoembolization. *Kanzo* 2012; **53**: 175-182
- 26 **Ch'ng JK**, Ng SY, Goh BK. An unusual cause of sepsis after laparoscopic cholecystectomy. *Gastroenterology* 2012; **143**: e1-e2 [PMID: 23089543 DOI: 10.1053/j.gastro.2012.05.040]
- 27 **Hendrix NW**, Mackeen AD, Weiner S. *Clostridium perfringens* Sepsis and Fetal Demise after Genetic Amniocentesis. *AJP Rep* 2011; **1**: 25-28 [PMID: 23705080 DOI: 10.1055/s-0030-1271221]
- 28 **Stroumsa D**, Ben-David E, Hiller N, Hochner-Celnikier D. Severe Clostridial Pyomyoma following an Abortion Does Not Always Require Surgical Intervention. *Case Rep Obstet Gynecol* 2011; **2011**: 364641 [PMID: 22567505 DOI: 10.1155/2011/364641]
- 29 **Determann C**, Walker CA. *Clostridium perfringens* gas gangrene at a wrist intravenous line insertion. *BMJ Case Rep* 2013; **2013**: [PMID: 24108766 DOI: 10.1136/bcr-2013-200242]
- 30 **Ng H**, Lam SM, Shum HP, Yan WW. *Clostridium perfringens* liver abscess with massive haemolysis. *Hong Kong Med J* 2010; **16**: 310-312 [PMID: 20683077]
- 31 **Law ST**, Lee MK. A middle-aged lady with a pyogenic liver abscess caused by *Clostridium perfringens*. *World J Hepatol* 2012; **4**: 252-255 [PMID: 22993668 DOI: 10.4254/wjh.v4.i8.252]
- 32 **Kitamura T**. *Clostridium perfringens* detected by peripheral blood smear. *Intern Med* 2012; **51**: 447 [PMID: 22333387 DOI: 10.2169/internalmedicine.51.6759]
- 33 **Shoda T**, Yoshimura M, Hayata D, Miyazawa Y, Ogata K. Marked spherocytosis in clostridial sepsis. *Int J Hematol* 2006; **83**: 179-180 [PMID: 16513538 DOI: 10.1532/IJH97.05165]
- 34 **Tian LT**, Yao K, Zhang XY, Zhang ZD, Liang YJ, Yin DL, Lee L, Jiang HC, Liu LX. Liver abscesses in adult patients with and without diabetes mellitus: an analysis of the clinical characteristics, features of the causative pathogens, outcomes and predictors of fatality: a report based on a large population, retrospective study in China. *Clin Microbiol Infect* 2012; **18**: E314-E330 [PMID: 22676078 DOI: 10.1111/j.1469-0691.2012.03912.x]
- 35 **Fujita H**, Nishimura S, Kurosawa S, Akiya I, Nakamura-Uchiyama F, Ohnishi K. Clinical and epidemiological features of *Clostridium perfringens* bacteremia: a review of 18 cases over 8 year-period in a tertiary care center in metropolitan Tokyo area in Japan. *Intern Med* 2010; **49**: 2433-2437

- [PMID: 21088344 DOI: 10.2169/internalmedicine.49.4041]
- 36 **Yang CC**, Hsu PC, Chang HJ, Cheng CW, Lee MH. Clinical significance and outcomes of *Clostridium perfringens* bacteremia—a 10-year experience at a tertiary care hospital. *Int J Infect Dis* 2013; **17**: e955-e960 [PMID: 23578849 DOI: 10.1016/j.ijid.2013.03.001]
 - 37 **Nagami H**, Matsui Y. Challenge of acute lumbar pain: clinical experience of four cases of acute pyogenic spondylodiscitis. *Shimane J Med Science* 2012; **28**: 133-141
 - 38 **Sato N**, Kitamura M, Kanno H and Gotoh M. Rupture of a gas-containing liver abscess due to *Clostridium perfringens* treated by laparotomy drainage. *J Jpn Surg Association* 2012; **73**: 2014-2020
 - 39 **Sekino M**, Ichinomiya T, Higashijima U, Yoshitomi O, Nakamura T, Furumoto A, Makita T and Sumikawa K. A case of *Clostridium perfringens* septicemia with massive intravascular hemolysis. *J Jpn Soc Intensive Care Med* 2013; **20**: 38-42
 - 40 **Cruz DN**, Perazella MA, Bellomo R, de Cal M, Polanco N, Corradi V, Lentini P, Nalesso F, Ueno T, Ranieri VM, Ronco C. Effectiveness of polymyxin B-immobilized fiber column in sepsis: a systematic review. *Crit Care* 2007; **11**: R47 [PMID: 17448226 DOI: 10.1186/cc5780]
 - 41 **Zagli G**, Bonizzoli M, Spina R, Cianchi G, Pasquini A, Anichini V, Matano S, Tarantini F, Di Filippo A, Maggi E, Peris A. Effects of hemoperfusion with an immobilized polymyxin-B fiber column on cytokine plasma levels in patients with abdominal sepsis. *Minerva Anestesiol* 2010; **76**: 405-412 [PMID: 20473253]
 - 42 **Berto P**, Ronco C, Cruz D, Melotti RM, Antonelli M. Cost-effectiveness analysis of polymyxin-B immobilized fiber column and conventional medical therapy in the management of abdominal septic shock in Italy. *Blood Purif* 2011; **32**: 331-340 [PMID: 22086346 DOI: 10.1159/000333826]
 - 43 **Qiu XH**, Liu SQ, Guo FM, Yang Y, Qiu HB. [A meta-analysis of the effects of direct hemoperfusion with polymyxin B-immobilized fiber on prognosis in severe sepsis]. *Zhonghua Neike Zazhi* 2011; **50**: 316-321 [PMID: 21600152]
 - 44 **Sakurai J**, Nagahama M, Oda M. *Clostridium perfringens* alpha-toxin: characterization and mode of action. *J Biochem* 2004; **136**: 569-574 [PMID: 15632295 DOI: 10.1093/jb/mvh161]
 - 45 **Oda M**, Kabura M, Takagishi T, Suzue A, Tominaga K, Ura-no S, Nagahama M, Kobayashi K, Furukawa K, Furukawa K, Sakurai J. *Clostridium perfringens* alpha-toxin recognizes the GM1a-TrkA complex. *J Biol Chem* 2012; **287**: 33070-33079 [PMID: 22847002]
 - 46 **Ochi S**, Oda M, Nagahama M, Sakurai J. *Clostridium perfringens* alpha-toxin-induced hemolysis of horse erythrocytes is dependent on Ca²⁺ uptake. *Biochim Biophys Acta* 2003; **1613**: 79-86 [PMID: 12832089 DOI: 10.1016/S0005-2736(03)00140-8]
 - 47 **Shah M**, Bishburg E, Baran DA, Chan T. Epidemiology and outcomes of clostridial bacteremia at a tertiary-care institution. *ScientificWorldJournal* 2009; **9**: 144-148 [PMID: 19252754 DOI: 10.1100/tsw.2009.21]
 - 48 **Stevens DL**, Maier KA, Mitten JE. Effect of antibiotics on toxin production and viability of *Clostridium perfringens*. *Antimicrob Agents Chemother* 1987; **31**: 213-218 [PMID: 2882731 DOI: 10.1128/AAC.31.2.213]
 - 49 **Oda M**, Kihara A, Yoshioka H, Saito Y, Watanabe N, Uoo K, Higashihara M, Nagahama M, Koide N, Yokochi T, Sakurai J. Effect of erythromycin on biological activities induced by *Clostridium perfringens* alpha-toxin. *J Pharmacol Exp Ther* 2008; **327**: 934-940 [PMID: 18794379]
 - 50 **Nagahama M**, Oda M, Kobayashi K, Ochi S, Takagishi T, Shibutani M, Sakurai J. A recombinant carboxy-terminal domain of alpha-toxin protects mice against *Clostridium perfringens*. *Microbiol Immunol* 2013; **57**: 340-345 [PMID: 23668605 DOI: 10.1111/1348-0421.12036]
 - 51 **Han SH**. Review of hepatic abscess from *Klebsiella pneumoniae*. An association with diabetes mellitus and septic endophthalmitis. *West J Med* 1995; **162**: 220-224 [PMID: 7725704]
 - 52 **Kasai K**, Manabe N, Tateishi K, Ichihara N, Ohta Y and Fujimoto C. Severe infections in diabetic patients of reported 568 cases in Japan. *Proceedings Kagawa Prefectural College Health Sciences* 1999; **1**: 1-10
 - 53 **Kurai D**, Araki K, Ishii H, Wada H, Saraya T, Yokoyama T, Watanabe M, Takada S, Koide T, Tamura H, Nagatomo S, Nakamoto K, Nakajima A, Makamura M, Honda K, Inui T, Goto H. Analysis of cases who were positive for *Clostridium* in blood culture. *J Jpn Association Infect Dis* 2011; **85** Suppl 334
 - 54 **Ngo JT**, Parkins MD, Gregson DB, Pitout JD, Ross T, Church DL, Laupland KB. Population-based assessment of the incidence, risk factors, and outcomes of anaerobic bloodstream infections. *Infection* 2013; **41**: 41-48 [PMID: 23292663 DOI: 10.1007/s15010-012-0389-4]
 - 55 **Zahar JR**, Farhat H, Chachaty E, Meshaka P, Antoun S, Nitenberg G. Incidence and clinical significance of anaerobic bacteraemia in cancer patients: a 6-year retrospective study. *Clin Microbiol Infect* 2005; **11**: 724-729 [PMID: 16104987 DOI: 10.1111/j.1469-0691.2005.01214.x]
 - 56 **Woo PC**, Lau SK, Chan KM, Fung AM, Tang BS, Yuen KY. *Clostridium* bacteraemia characterised by 16S ribosomal RNA gene sequencing. *J Clin Pathol* 2005; **58**: 301-307 [PMID: 15735165]

P- Reviewers: Elisaf MS, Ferraioli G, Peng B **S- Editor:** Wen LL
L- Editor: A **E- Editor:** Wu HL





百世登
Baishideng®

Published by **Baishideng Publishing Group Co., Limited**

Flat C, 23/F., Lucky Plaza,

315-321 Lockhart Road, Wan Chai, Hong Kong, China

Fax: +852-65557188

Telephone: +852-31779906

E-mail: bpgoffice@wjgnet.com

<http://www.wjgnet.com>

