

World Journal of *Gastrointestinal Surgery*

World J Gastrointest Surg 2020 August 27; 12(8): 336-376



ORIGINAL ARTICLE**Retrospective Study**

- 336 Influence of postoperative complications on long-term survival in liver transplant patients

Castaneda S, Toledo E, Fernández-Santiago R, Castillo F, Echeverri J, Rodríguez-Sanjuán JC

- 346 Easy fixation effects the prevention of Peterson's hernia and Roux stasis syndrome

Wu JZ, Orita H, Zhang S, Egawa H, Yube Y, Kaji S, Oka S, Fukunaga T

Observational Study

- 355 Drug-eluting beads transarterial chemoembolization sequentially combined with radiofrequency ablation in the treatment of untreated and recurrent hepatocellular carcinoma

Zhang Y, Zhang MW, Fan XX, Mao DF, Ding QH, Zhuang LH, Lv SY

REVIEW

- 369 Gastrointestinal obstruction secondary to enteral nutrition bezoar: A case report

Siddens ED, Al-Habbal Y, Bhandari M

ABOUT COVER

Editor-in-Chief of *World Journal of Gastrointestinal Surgery*, Dr. Varut Lohsiriwat is a Professor of Surgery at the Colorectal Surgery Unit, Department of Surgery, Faculty of Medicine Siriraj Hospital, Mahidol University, Thailand. His research interests include colorectal and anal surgery, perioperative pain, surgical nutrition, surgical infection, and enhanced recovery after surgery (ERAS). He has authored more than 30 book chapters and more than 100 peer-reviewed scientific papers. Collectively, his work has been cited in the medical literature over 1500 times, with H-index of 23. He is an active member of the Royal College of Surgeons Thailand and a general secretary of the Society of Thai Colorectal Surgeons and the Surgical Infection Society of Thailand. (L-Editor: Filipodia)

AIMS AND SCOPE

The primary aim of *World Journal of Gastrointestinal Surgery* (WJGS, *World J Gastrointest Surg*) is to provide scholars and readers from various fields of gastrointestinal surgery with a platform to publish high-quality basic and clinical research articles and communicate their research findings online.

WJGS mainly publishes articles reporting research results and findings obtained in the field of gastrointestinal surgery and covering a wide range of topics including biliary tract surgical procedures, biliopancreatic diversion, colectomy, esophagectomy, esophagostomy, pancreas transplantation, pancreatectomy, pancreaticoduodenectomy, and pancreaticojejunostomy, etc.

INDEXING/ABSTRACTING

The WJGS is now abstracted and indexed in Science Citation Index Expanded (SCIE, also known as SciSearch®), Current Contents/Clinical Medicine, Journal Citation Reports/Science Edition, PubMed, and PubMed Central. The 2020 edition of Journal Citation Reports® cites the 2019 impact factor (IF) for WJGS as 1.863; IF without journal self cites: 1.824; Ranking: 109 among 210 journals in surgery; Quartile category: Q3; Ranking: 77 among 88 journals in gastroenterology and hepatology; and Quartile category: Q4.

RESPONSIBLE EDITORS FOR THIS ISSUE

Production Editor: Yan-Liang Zhang; Production Department Director: Xiang Li; Editorial Office Director: Jia-Ping Yan.

NAME OF JOURNAL

World Journal of Gastrointestinal Surgery

ISSN

ISSN 1948-9366 (online)

LAUNCH DATE

November 30, 2009

FREQUENCY

Monthly

EDITORS-IN-CHIEF

Shu-You Peng, Varut Lohsiriwat

EDITORIAL BOARD MEMBERS

<https://www.wjgnet.com/1948-9366/editorialboard.htm>

PUBLICATION DATE

August 27, 2020

COPYRIGHT

© 2020 Baishideng Publishing Group Inc

INSTRUCTIONS TO AUTHORS

<https://www.wjgnet.com/bpg/gerinfo/204>

GUIDELINES FOR ETHICS DOCUMENTS

<https://www.wjgnet.com/bpg/GerInfo/287>

GUIDELINES FOR NON-NATIVE SPEAKERS OF ENGLISH

<https://www.wjgnet.com/bpg/gerinfo/240>

PUBLICATION ETHICS

<https://www.wjgnet.com/bpg/GerInfo/288>

PUBLICATION MISCONDUCT

<https://www.wjgnet.com/bpg/gerinfo/208>

ARTICLE PROCESSING CHARGE

<https://www.wjgnet.com/bpg/gerinfo/242>

STEPS FOR SUBMITTING MANUSCRIPTS

<https://www.wjgnet.com/bpg/GerInfo/239>

ONLINE SUBMISSION

<https://www.f6publishing.com>

Retrospective Study

Easy fixation effects the prevention of Peterson's hernia and Roux stasis syndrome

Jian-Zhong Wu, Hajime Orita, Shun Zhang, Hiroyuki Egawa, Yukinori Yube, Sanae Kaji, Shinichi Oka, Tetsu Fukunaga

ORCID number: Jian-Zhong Wu 0000-0001-5767-264X; Hajime Orita 0000-0002-8263-7069; Shun Zhang 0000-0002-3493-1247; Hiroyuki Egawa 0000-0003-1934-9918; Yukinori Yube 0000-0002-0289-8892; Sanae Kaji 0000-0002-1372-4468; Shinichi Oka 0000-0002-3820-3394; Tetsu Fukunaga 0000-0003-4802-8945.

Author contributions: Fukunaga T, Wu JZ and Oka S designed the research; Kaji S, Wu JZ, Zhang S and Yube Y collected the clinical data; Yube Y and Egawa H analyzed the data; Wu JZ and Orita H wrote the paper; Fukunaga T corrected and approved the manuscript.

Institutional review board

statement: This study was retrospective, and no interference with patients' treatment was made. Thus, the approval by the Institutional Review Committee of Juntendo University Hospital was waived.

Informed consent statement:

Patients were not required to give informed consent to the study because the analysis used anonymous clinical data that were obtained after each patient agreed to treatment by written consent.

Jian-Zhong Wu, Hajime Orita, Shun Zhang, Hiroyuki Egawa, Yukinori Yube, Sanae Kaji, Shinichi Oka, Tetsu Fukunaga, Department of Gastroenterology and Minimally Invasive Surgery, Juntendo University School of Medicine, Juntendo University, Tokyo 1638001, Japan

Jian-Zhong Wu, Department of Gastroenterology Surgery, Suzhou Ninth People's Hospital, Nantong University, Suzhou 215000, Jiangsu Province, China

Shun Zhang, Department of Surgery, Tongji University, Shanghai 200000, China

Corresponding author: Tetsu Fukunaga, MD, PhD, Professor, Department of Gastroenterology and Minimally Invasive Surgery, Juntendo University Hospital, 3-1-3 Hongo, Bunkyo-ku, Tokyo 1138431, Japan. t2fukunaga@juntendo.ac.jp

Abstract

BACKGROUND

Laparoscopic distal gastrectomy (LDG) for gastric cancer has been progressed and popular in Japan, since it was first described in 1994. Several reconstruction methods can be adopted according to remnant stomach size, and balance of pros and cons. Roux-en-Y (R-Y) reconstruction is a one of standard options after LDG. Its complications include Petersen's hernia and Roux stasis syndrome. Here we report our ingenious attempt, fixation of Roux limb and duodenal stump, for decreasing the development of Petersen's hernia and Roux stasis syndrome.

AIM

To develop a method to decrease the development of Petersen's hernia and Roux stasis syndrome.

METHODS

We performed ante-colic R-Y reconstruction after LDG. After R-Y reconstruction, we fixed Roux limb onto the duodenal stump in a smooth radian. *Via* this small improvement in Roux limb, Roux limb was placed to the right of the ligament of Treitz. This not only changed the anatomy of the Petersen's defect, but it also kept a fluent direction of gastrointestinal anastomosis and avoided a cross-angle after jejunojunostomy. 31 patients with gastric cancer was performed this technique after R-Y reconstruction. Clinical parameters including clinicopathologic characteristics, perioperative outcomes, postoperative complication and follow-up data were evaluated.

Conflict-of-interest statement: The authors declare that they have no conflict of interest.

Data sharing statement: No additional data are available.

Open-Access: This article is an open-access article that was selected by an in-house editor and fully peer-reviewed by external reviewers. It is distributed in accordance with the Creative Commons Attribution NonCommercial (CC BY-NC 4.0) license, which permits others to distribute, remix, adapt, build upon this work non-commercially, and license their derivative works on different terms, provided the original work is properly cited and the use is non-commercial. See: <http://creativecommons.org/licenses/by-nc/4.0/>

Manuscript source: Unsolicited manuscript

Received: May 2, 2020

Peer-review started: May 2, 2020

First decision: May 24, 2020

Revised: May 31, 2020

Accepted: July 26, 2020

Article in press: July 26, 2020

Published online: August 27, 2020

P-Reviewer: Zhe MM

S-Editor: Zhang L

L-Editor: A

P-Editor: Zhang YL



RESULTS

The operative time was (308.0 ± 84.6 min). This improvement method took about 10 min. Two (6.5%) patients experienced pneumonia and pancreatitis, respectively. No patient required reoperation or readmission. All patients were followed up for at least 3 year, and none of the patients developed postoperative complications related to internal hernia or Roux stasis syndrome.

CONCLUSION

This 10 min technique is a very effective method to decrease the development of Petersen's hernia and Roux stasis syndrome in patients who undergo LDG.

Key words: Laparoscopy distal gastrectomy; Roux-en-Y reconstruction; Internal hernia; Roux limb syndrome; Gastric cancer

©The Author(s) 2020. Published by Baishideng Publishing Group Inc. All rights reserved.

Core tip: We developed a method, fixation of Roux limb and duodenal stump. This not only changed the anatomy of the Petersen's defect, but it also kept a fluent direction of gastrointestinal anastomosis and avoided a cross-angle after jejunojejunostomy. None of the patients had complications related to Petersen's hernia and Roux stasis syndrome by at least three years of follow-up in this study. This technique is a simple and effective method to decrease the development of Petersen's hernia and Roux stasis syndrome.

Citation: Wu JZ, Orita H, Zhang S, Egawa H, Yube Y, Kaji S, Oka S, Fukunaga T. Easy fixation effects the prevention of Peterson's hernia and Roux stasis syndrome. *World J Gastrointest Surg* 2020; 12(8): 346-354

URL: <https://www.wjgnet.com/1948-9366/full/v12/i8/346.htm>

DOI: <https://dx.doi.org/10.4240/wjgs.v12.i8.346>

INTRODUCTION

Since the first laparoscopic distal gastrectomy (LDG) for gastric cancer was reported in Japan, it has been progressed and popular due to the benefits for patients^[1]. According to survey from Nationwide Survey of Endoscopic Surgery in Japan, distal gastrectomy was accounted for the most proportion among all the laparoscopic gastrectomy^[1,2].

Evidence-based oncological outcomes of LDG for gastric cancer were obtained from many random clinical trials^[1,3,4]. After that, more and more attention was attracted to improve patients' quality of life. Digestive tract reconstruction is a critical aspect of the procedure in addition to not only the oncologic goals of disease resection but also the quality of life for patients. Reconstruction methods by laparoscopy have been developed during more than 10 year. An optimal technique of digestive tract reconstruction after distal gastrectomy has not been reached definitive consensus. There are several reconstruction methods of digestive tract after laparoscopic distal gastrectomy including Billroth I, Billroth II, and Roux-en-Y anastomosis. Roux-en-Y gastrojejunostomy is now used worldwide for the prevention of alkaline reflux gastritis, esophagitis, dumping syndrome, and carcinogenesis of the gastric remnant.

A gastrojejunostomy in R-Y reconstruction can be performed through either the retrocolic or the antecolic route. The retrocolic reconstruction is conventionally and commonly performed by open surgery. The antecolic route for R-Y reconstruction is favored especially in the laparoscopic procedure with better exposure to the mesenteric defect and lesser mesenteric defects. However, some complications such as internal hernia are closely related with antecolic route for the reason that jejunojejunostomy and Petersen's defect are created during reconstruction^[5].

About 10% to 30% of the patients after R-Y reconstruction suffer from Roux stasis syndrome which consists of abdominal pain, vomiting and post-prandial nausea^[6]. The pathogenic mechanisms of Roux stasis syndrome are not completely identified. It has been proposed that the occurrence of Roux stasis syndrome is related to functional obstruction of the Roux limb or interruption of electrical conduction caused by amputation of the jejunum^[7]. Many improved anastomosis methods were invented, such as uncut R-Y reconstruction or β-shaped R-Y reconstruction^[8,9]. However, some of

them are technically complex elements and time-consuming. Given that surgical technical factors involving the Roux limb play an important role in the development of these two complications, we developed a method of fixation of Roux limb and duodenal stump to narrow the Petersen's defect and decrease the development of Roux stasis syndrome (Figure 1).

In this retrospective study, we describe this simple method and report our experience with 31 successful modified laparoscopic Roux-en-Y gastrojejunostomy with fixation of Roux Limb and duodenal stump evaluate feasibility, safety, and short-term outcomes.

MATERIALS AND METHODS

Patients

Between July 2015 and March 2017, 31 patients with gastric cancer underwent LDG with ante-colic R-Y reconstruction by the same surgeon at the Department of Gastroenterology and Minimally Invasive Surgery at Juntendo University School of Medicine. Clinical parameters included clinicopathologic characteristics, perioperative outcomes, postoperative complication and follow-up data.

Surgical techniques

Patient positioning and placement of the trocars: The patient was placed in the supine position and general anesthesia was induced. A 12 mm trocar was inserted through the umbilical region by the open method, and carbon dioxide pneumoperitoneum was established. The additional four trocars were placed, including two 12 mm trocars in the right and left lower abdomen and two 5mm trocars in the right and left upper abdomen.

Laparoscopic intracorporeal Roux-en-Y gastrojejunostomy after distal gastrectomy: Laparoscopic mobilization of the stomach and lymph node dissection were performed in a conventional manner. The vagus nerve was not preserved. The duodenum was divided distal to the pylorus with an endoscopic linear stapler (Endo-GIA 60-3, Covidien), then the stomach was divided with two endoscopic linear staplers. Usually one-third or one-fifth of the stomach was preserved. The specimen was removed through an extended 4 cm incision in the umbilical port. The jejunum, 20 cm distal to the ligament of Treitz, was prepared for a Roux limb, and the mesentery of this jejunum was divided for a distance of 8 cm. The prepared jejunum then was divided with an endoscopic linear stapler to ensure a tension free-gastrojejunostomy. A side-side jejunojejunostomy was fashioned 30 cm distal to the planed gastrojejunostomy using endoscopic linear staplers under direct vision through the umbilical incision. The jejunojejunostomy defect was closed with nonabsorbable sutures in an intermittent fashion. Pneumoperitoneum was rebuilt and the jejunal limb was brought to the gastric remnant through an ante-colic route. A right-oriented Roux limb was created such that the cut end of the jejunal limb faced the greater curvature of the gastric remnant (Figure 2A). The jejunal limb was anastomosed to the greater curvature of the stomach side-to-side with an endoscopic stapler, then the site of entry for the linear stapler was closed using a running hand sewn suture (Figure 2B).

Surgical technique for fixation of Roux limb and duodenal stump: We summarized the surgical procedures as follows. All the procedures were performed laparoscopically. First, the duodenal stump was laparoscopically buried, with suturing performed by hand. The rows of staples on the duodenal stump may then be reinforced by a continuous absorbable seromuscular barbed suture (*e.g.*, 3-0 V-loc, Covidien), which buries the suture line (Figure 2C). Second, the alimentary was then fixed to the duodenal stump at a location to prevent torsion of the Roux limb (Figure 2D). No intention was made to close the Petersen's defect in any of the patients during the surgery. The final reconstruction is illustrated in Figure 3.

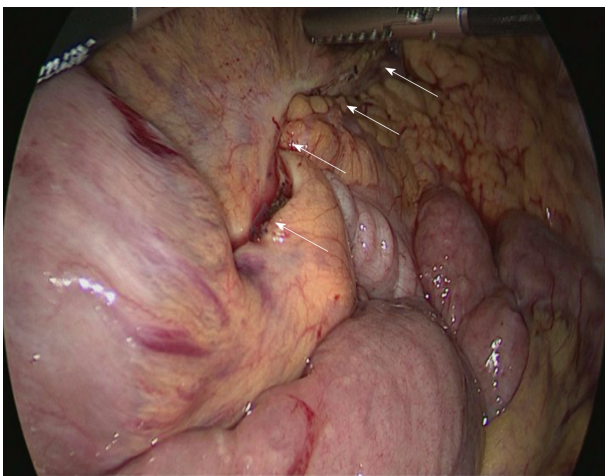
RESULTS

From July 2015 to March 2017, we performed this technique after R-Y reconstruction for gastric cancer in 31 consecutive patients (19 men and 12 women). The characteristics of the patients are shown in Table 1. The mean patient age was 66.2 ± 13.0 years (mean \pm SD), and the mean BMI was 21.5 ± 2.7 kg/m² (mean \pm SD). 2

Table 1 Clinical characteristics of patients

Content	
Sex	
Male	19
Female	12
Age	66.2 ± 13.0
ASA score	
1	29
≥ 2	2
Body mass index (kg/m ²)	21.5 ± 2.7
History of laparotomy	2
Pathological stage	
IA	15 (48.4%)
IB	1 (3.2%)
IIA	2 (6.4%)
IIB	6 (19.4%)
IIIA	6 (19.4%)
IIIB	1 (3.2%)

Number of patients is shown unless otherwise indicated. Values are shown as mean ± SD. Body Mass Index = body weight/height² (kg/m²).

**Figure 1 Petersen's defect (white arrow).**

patients had a history of laparotomy. Most of the patients (48.4%) had stage IA gastric cancer according to the pathological staging of gastric cancer.

The intraoperative data and postoperative outcomes are summarized in [Table 2](#). The operative time was 308.0 ± 84.6 min (mean ± SD). The fixation time was 10 ± 1.6 min (mean ± SD). The blood loss volume was 70.1 ± 76.0 mL (mean ± SD). The number of lymph nodes harvested was 28.9 ± 4.1 (mean ± SD). After LDG, on average, the patients tolerated liquids on the first day and a soft diet on the second postoperative day. The postoperative hospital stay was 13.5 ± 2 d (mean ± SD).

The postoperative complications are summarized in [Table 3](#). There was no conversion to open surgery in any of the patients. Two patients experienced pneumonia and pancreatitis after surgery, respectively. All patients were discharged with satisfactory recovery and were evaluated postoperatively by routine abdominal computed tomography scan and endoscopy as part of follow-up. The median follow-up period was 44.5 mo (range 37-59 mo). None of the patients had complications

Table 2 Intraoperative data and postoperative outcomes

Content	
Operation time (min)	308.0 ± 84.6
Fixation time (min)	10 ± 1.6
Intraoperative blood loss (mL)	70.1 ± 76.0
Conversion to open surgery, <i>n</i> (%)	0 (0)
Extent of lymph node dissection	
≤ D1 ⁺	16
D2	15
Number of lymph nodes harvested	28.9 ± 4.1
Clear liquids initiated, median (d)	1
Soft diet initiated, median (d)	2
Postoperative hospital stay (d)	13.5 ± 2

Number of patients is shown unless otherwise indicated. Values are shown as mean ± SD.

Table 3 Postoperative complications

Content	
Anastomotic leak or stenosis	0 (0%)
Anastomotic bleeding	0 (0%)
Roux stasis syndrome	0 (0%)
Internal hernia	0 (0%)
Pancreatitis	1 (3.2%)
Pneumonia	1 (3.2%)
Reoperation, <i>n</i> (%)	0 (0%)
Readmission, <i>n</i> (%)	0 (0%)

related to internal hernia and Roux stasis syndrome during the follow-up period.

DISCUSSION

Herein we report our method to reduce post-operative Peterson's hernia and Roux stasis syndrome in patients undergoing LDG. There are reports that a laparoscopic approach, non-closure of mesenteric defects, and low BMI are independent risk factors for internal hernia by multivariate analysis^[10-13]. One study reported a higher incidence of internal hernia after single-port surgery compared to multi-port surgery, resulting from the relatively difficult manipulation of laparoscopic instruments in single-port surgery^[13].

The rate of Petersen's hernia which is a type of internal hernia, with the laparoscopic ante-colic R-Y reconstruction approach without closure of Petersen's defect, was reportedly 2.6% to 4.75% and generally was thought to be higher than with open approach^[5,14,15]. One explanation is that laparoscopic surgery is less likely to form adhesions and promotes earlier intestinal peristalsis than laparotomy, which leads to a higher incidence of internal hernia^[16]. Although all defects are closed at the time of the initial surgery, internal hernia still occurs in some cases^[15,17]. Previous studies speculated that the large decrease in mesenteric fat after distal gastrectomy might lead to the reopening of the defect despite an initially complete suture^[18-20]. An early diagnosis of internal hernia is a challenge for most surgeons because of atypical clinical symptoms and lack of sensitive imaging techniques^[17]. Furthermore, the internal hernia may be delayed, so it is necessary to develop an effective technique to

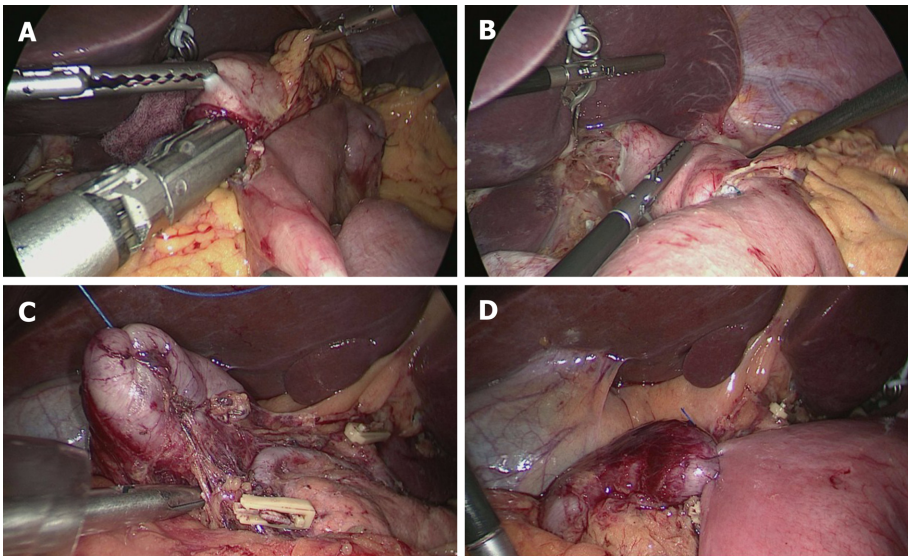


Figure 2 Laparoscopic intracorporeal Roux-en-Y gastrojejunostomy after distal gastrectomy and surgical technique for fixation of Roux limb and duodenal stump. A: The cut end of the jejunal limb faced the greater curvature; B: The site of entry was closed using a running handsewn suture; C: The duodenal stump was embedded with seromuscular suture; and D: Roux limb was fixed on the duodenal stump.

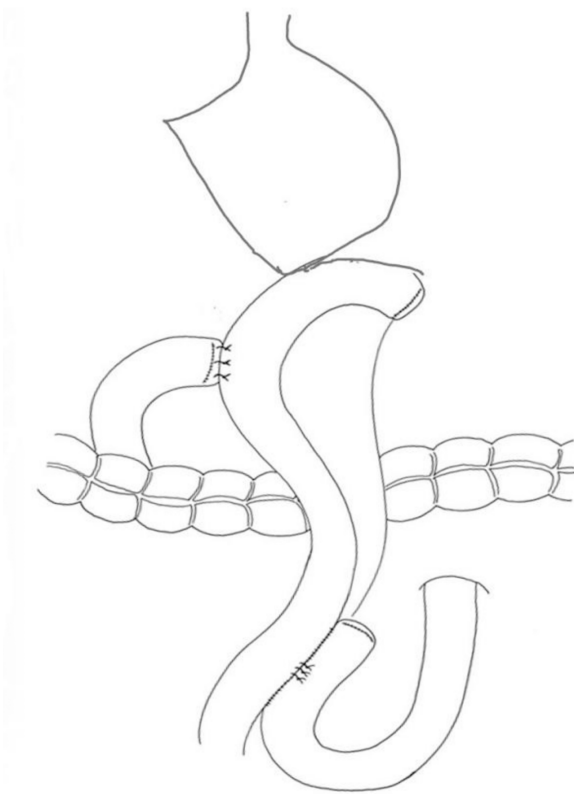


Figure 3 The final reconstruction.

prevent an internal hernia during the surgery.

The boundaries of Petersen's defect are defined as the transverse mesocolon, the mesentery of the Roux limb and the retroperitoneum^[21]. Unlike with laparoscopic gastric bypass, subtotal resection of the stomach with lymph node dissection widens the space behind the Roux limb in the ante-colic Roux-Y reconstruction, which may often result in Petersen's hernia. Closure of all the mesenteric defects with non-absorbable suture in a running fashion was considered the most effective method for preventing internal hernia^[5,16,22], however, a tight closure of the Petersen's defect from the root of the mesentery of the Roux limb and transverse mesocolon to the transverse

colon is difficult with the laparoscopic view. As reported by Hirahara *et al*^[16] one way to minimize the defect is to place the residual greater omentum in the defect between the Roux limb and the transverse mesocolon. Although this technique can prevent Petersen's hernia, it may not be suitable for patients undergoing total resection of the omentum. In our approach to reducing the likelihood of Peterson's hernia, we initially fix Roux limb onto the duodenal stump with a smooth radian and tension, then change the angle of the opening of Petersen's defect and narrow the space behind the Roux limb. This procedure decreases the mobility of Roux limb and makes the mesentery of Roux limb and the transverse mesocolon stick tightly. Thus, this technique eliminates the narrowed Petersen's defect through rapid formation of adhesions behind Roux limb. Compared with the many closure stitches needed to repair Petersen's defect in a relatively poor exposure, our reported procedure does not require mesentery stitches, is time-saving and is simple and effective. Two large retrospective studies of internal hernia reported that the median interval time after gastrectomy for hernia formation was from 15 mo to 20.9 mo^[11,13]. None of the patients developed internal hernias by at least three years of follow-up in this study. To some extent, the follow-up data supports our small change about Roux limb in surgical technique.

In addition, surgical technical factors with Roux limb have been taken into account for the cause of Roux stasis syndrome. Gowen^[23] speculated that one of the causes for Roux stasis syndrome is partial obstruction near or at the gastrointestinal anastomosis, but without stomal stenosis. This author analyzed the types of partial obstruction and found that they were related to postoperative adhesions or a kinked loop around the gastrointestinal anastomosis as a result of non-standard surgical techniques. Masui *et al*^[6] also suggested that the adhesion between Roux limb and the suture of the gastric remnant, which was produced a strong bend of Roux limb to the lesser curvature of gastric remnant, could be a cause of Roux stasis syndrome. To prevent this, we fix Roux limb onto the duodenal stump with appropriate tension, which ensures a fluent direction of the gastrointestinal anastomosis by avoiding the angle after the gastroenterostomy. Moreover, through this technique the alimentary limb lies to the right of the ligament of Treitz and does not cross the proximal jejunum (biliopancreatic limb), which allows digestive juices and food to pass smoothly into the distal small intestine.

In conclusion, here we report a case series of a simple and effective method for decreasing the development of Petersen's hernia and Roux stasis syndrome following R-Y reconstruction. Although Petersen's hernia is a rare complication of R-Y reconstruction, it is difficult to diagnose and may cause serious postoperative complications that require additional surgery and may even result in death^[11,13]. Roux stasis syndrome is also widely reported and results in poor post-operative nutritional status^[24-26]. Furthermore, with our described technique, no patients had complications related to internal hernia and Roux stasis syndrome. This technique is a simple and effective method to decrease the incidence of internal hernia and Roux stasis syndrome. There are some limitations in our study. Its retrospective nature may induce some bias. Because of the length of follow up, our study did not provide enough data to show conclusions about long-term outcomes.

ARTICLE HIGHLIGHTS

Research background

Roux-en-Y reconstruction has been one of the standard options after laparoscopic distal gastrectomy. Its complications include Petersen's hernia and Roux stasis syndrome. Although Petersen's hernia is a rare complication, it is difficult to diagnose and cause serious postoperative complications. Meanwhile, Roux stasis syndrome is widely reported and reduces the post-operative nutritional status of patients.

Research motivation

Many improved methods were invented for decreasing the incidence of Petersen's hernia and Roux stasis syndrome, however, some of them are technically complex elements and time-consuming. We developed an easy and effective method to narrow the Petersen's defect and reduce the development of Roux stasis syndrome using surgical techniques.

Research objectives

The primary objective of the study was to develop an easy and effective method to

decrease the development of Petersen's hernia and Roux stasis syndrome.

Research methods

We fixed Roux limb onto the duodenal stump in a smooth radian after Roux-en-Y reconstruction. *Via* this small improvement in Roux limb, Roux limb was placed to the right of the ligament of Treitz. This not only changed the anatomy of the Petersen's defect, but it also kept a fluent direction of gastrointestinal retrospective analysis review of the data of 31 consecutive patients who was performed this technique between July 2015 and March 2017.

Research results

This improvement method took about 10 min. All patients were followed up for at least 3 year, and none of the patients developed postoperative complications related to internal hernia or Roux stasis syndrome.

Research conclusions

This 10 min technique is a very effective method to decrease the development of Petersen's hernia and Roux stasis syndrome in patients who undergo laparoscopic distal gastrectomy

Research perspectives

In this study, we report a case series of a simple and effective method for decreasing the development of Petersen's hernia and Roux stasis syndrome. Because of the length of follow up, our study did not provide enough data to show conclusions about long-term outcomes. We will continue to perform this technique and collect more data to prove the long-term effect of this technique.

REFERENCES

- Hirao M, Takiguchi S, Imamura H, Yamamoto K, Kurokawa Y, Fujita J, Kobayashi K, Kimura Y, Mori M, Doki Y; Osaka University Clinical Research Group for Gastroenterological Study. Comparison of Billroth I and Roux-en-Y reconstruction after distal gastrectomy for gastric cancer: one-year postoperative effects assessed by a multi-institutional RCT. *Ann Surg Oncol* 2013; **20**: 1591-1597 [PMID: 23104705 DOI: 10.1245/s10434-012-2704-9]
- Osugi H, Fukuhara K, Takada N, Takemura M, Kinoshita H. Reconstructive procedure after distal gastrectomy to prevent remnant gastritis. *Hepatogastroenterology* 2004; **51**: 1215-1218 [PMID: 15239282 DOI: 10.1016/S0014-3057(99)00073-7]
- Inokuchi M, Kojima K, Yamada H, Kato K, Hayashi M, Motoyama K, Sugihara K. Long-term outcomes of Roux-en-Y and Billroth-I reconstruction after laparoscopic distal gastrectomy. *Gastric Cancer* 2013; **16**: 67-73 [PMID: 22467062 DOI: 10.1007/s10120-012-0154-5]
- Kojima K, Yamada H, Inokuchi M, Kawano T, Sugihara K. A comparison of Roux-en-Y and Billroth-I reconstruction after laparoscopy-assisted distal gastrectomy. *Ann Surg* 2008; **247**: 962-967 [PMID: 18520223 DOI: 10.1097/SLA.0b013e31816d9526]
- Kojima K, Inokuchi M, Kato K, Motoyama K, Sugihara K. Petersen's hernia after laparoscopic distal gastrectomy with Roux-en-Y reconstruction for gastric cancer. *Gastric Cancer* 2014; **17**: 146-151 [PMID: 23558458 DOI: 10.1007/s10120-013-0256-8]
- Masui T, Kubota T, Nakanishi Y, Aoki K, Sugimoto S, Takamura M, Takeda H, Hashimoto K, Tokuka A. The flow angle beneath the gastrojejunostomy predicts delayed gastric emptying in Roux-en-Y reconstruction after distal gastrectomy. *Gastric Cancer* 2012; **15**: 281-286 [PMID: 22041869 DOI: 10.1007/s10120-011-0107-4]
- Bar-Natan M, Larson GM, Stephens G, Massey T. Delayed gastric emptying after gastric surgery. *Am J Surg* 1996; **172**: 24-28 [PMID: 8686797 DOI: 10.1016/S0002-9610(96)00048-7]
- Park JY, Kim YJ. Uncut Roux-en-Y Reconstruction after Laparoscopic Distal Gastrectomy Can Be a Favorable Method in Terms of Gastritis, Bile Reflux, and Gastric Residue. *J Gastric Cancer* 2014; **14**: 229-237 [PMID: 25580354 DOI: 10.5230/jgc.2014.14.4.229]
- Motoyama K, Kojima K, Hayashi M, Kato K, Inokuchi M, Sugihara K. β -Shaped intracorporeal Roux-en-Y reconstruction after totally laparoscopic distal gastrectomy. *Gastric Cancer* 2014; **17**: 588-593 [PMID: 24178920 DOI: 10.1007/s10120-013-0311-5]
- Miyagaki H, Takiguchi S, Kurokawa Y, Hirao M, Tamura S, Nishida T, Kimura Y, Fujiwara Y, Mori M, Doki Y. Recent trend of internal hernia occurrence after gastrectomy for gastric cancer. *World J Surg* 2012; **36**: 851-857 [PMID: 22350485 DOI: 10.1007/s00268-012-1479-2]
- Han WH, Eom BW, Yoon HM, Kim YW, Ryu KW. Clinical characteristics and surgical outcomes of internal hernia after gastrectomy in gastric cancer patients: retrospective case control study. *Surg Endosc* 2019; **33**: 2873-2879 [PMID: 30421082 DOI: 10.1007/s00464-018-6584-3]
- Kelly KJ, Allen PJ, Brennan MF, Gollub MJ, Coit DG, Strong VE. Internal hernia after gastrectomy for cancer with Roux-Y reconstruction. *Surgery* 2013; **154**: 305-311 [PMID: 23889956 DOI: 10.1016/j.surg.2013.04.027]
- Kang KM, Cho YS, Min SH, Lee Y, Park KB, Park YS, Ahn SH, Park DJ, Kim HH. Internal hernia after

- gastrectomy for gastric cancer in minimally invasive surgery era. *Gastric Cancer* 2019; **22**: 1009-1015 [PMID: 30758761 DOI: 10.1007/s10120-019-00931-1]
- 14 **Quebbemann BB**, Dallal RM. The orientation of the antecolic Roux limb markedly affects the incidence of internal hernias after laparoscopic gastric bypass. *Obes Surg* 2005; **15**: 766-70; discussion 770 [PMID: 15978143 DOI: 10.1381/0960892054222722]
- 15 **Kimura H**, Ishikawa M, Nabae T, Matsunaga T, Murakami S, Kawamoto M, Kamimura T, Uchiyama A. Internal hernia after laparoscopic gastrectomy with Roux-en-Y reconstruction for gastric cancer. *Asian J Surg* 2017; **40**: 203-209 [PMID: 26589299 DOI: 10.1016/j.asjsur.2015.09.003]
- 16 **Hirahara N**, Matsubara T, Hayashi H, Takai K, Fujii Y, Tajima Y. Easy and secure closure of Petersen's defect after laparoscopic distal gastrectomy with Roux-en-Y reconstruction. *J Laparoendosc Adv Surg Tech A* 2015; **25**: 55-59 [PMID: 25531205 DOI: 10.1089/lap.2014.0402]
- 17 **Steele KE**, Prokopowicz GP, Magnuson T, Lidor A, Schweitzer M. Laparoscopic antecolic Roux-en-Y gastric bypass with closure of internal defects leads to fewer internal hernias than the retrocolic approach. *Surg Endosc* 2008; **22**: 2056-2061 [PMID: 18270773 DOI: 10.1007/s00464-008-9749-7]
- 18 **Hope WW**, Sing RF, Chen AY, Lincourt AE, Gersin KS, Kuwada TS, Heniford BT. Failure of mesenteric defect closure after Roux-en-Y gastric bypass. *JSLs* 2010; **14**: 213-216 [PMID: 20932371 DOI: 10.4293/108680810X12785289144151]
- 19 **Miyato H**, Kitayama J, Hidemura A, Ishigami H, Kaisaki S, Nagawa H. Vagus nerve preservation selectively restores visceral fat volume in patients with early gastric cancer who underwent gastrectomy. *J Surg Res* 2012; **173**: 60-67 [PMID: 21035138 DOI: 10.1016/j.jss.2010.08.040]
- 20 **Papasavas PK**, Caushaj PF, McCormick JT, Quinlin RF, Hayetian FD, Maurer J, Kelly JJ, Gagné DJ. Laparoscopic management of complications following laparoscopic Roux-en-Y gastric bypass for morbid obesity. *Surg Endosc* 2003; **17**: 610-614 [PMID: 12582772 DOI: 10.1007/s00464-002-8826-6]
- 21 **Rogers AM**, Ionescu AM, Pauli EM. When is a Petersen's hernia not a Petersen's hernia. *J Am Coll Surg* 2008; **207**: 121-124 [DOI: 10.1016/S0952-1976(03)00078-2]
- 22 **Higa KD**, Ho T, Boone KB. Internal hernias after laparoscopic Roux-en-Y gastric bypass: incidence, treatment and prevention. *Obes Surg* 2003; **13**: 350-354 [PMID: 12841892 DOI: 10.1381/096089203765887642]
- 23 **Gowen GF**. Delayed gastric emptying after Roux-en-Y due to four types of partial obstruction. *Ann Surg* 1992; **215**: 363-367 [PMID: 1558417 DOI: 10.1097/00000658-199204000-00010]
- 24 **Mathias JR**, Fernandez A, Sninsky CA, Clench MH, Davis RH. Nausea, vomiting, and abdominal pain after Roux-en-Y anastomosis: motility of the jejunal limb. *Gastroenterology* 1985; **88**: 101-107 [PMID: 3964759 DOI: 10.1016/s0016-5085(85)80140-2]
- 25 **Miedema BW**, Kelly KA, Camilleri M, Hanson RB, Zinsmeister AR, O'Connor MK, Brown ML. Human gastric and jejunal transit and motility after Roux gastrojejunostomy. *Gastroenterology* 1992; **103**: 1133-1143 [PMID: 1397870 DOI: 10.1016/0016-5085(92)91496-q]
- 26 **Gustavsson S**, Ilstrup DM, Morrison P, Kelly KA. Roux-Y stasis syndrome after gastrectomy. *Am J Surg* 1988; **155**: 490-494 [PMID: 3344916 DOI: 10.1016/s0002-9610(88)80120-x]



Published by **Baishideng Publishing Group Inc**
7041 Koll Center Parkway, Suite 160, Pleasanton, CA 94566, USA

Telephone: +1-925-3991568

E-mail: bpgoffice@wjgnet.com

Help Desk: <https://www.f6publishing.com/helpdesk>

<https://www.wjgnet.com>

