

World Journal of *Gastrointestinal Surgery*

World J Gastrointest Surg 2021 January 27; 13(1): 1-95



Contents

Monthly Volume 13 Number 1 January 27, 2021

OPINION REVIEW

- 1 Colonic Crohn's disease – decision is more important than incision: A surgical dilemma
Chiarello MM, Cariatì M, Brisinda G

MINIREVIEWS

- 7 Role of artificial intelligence in hepatobiliary and pancreatic surgery
Bari H, Wadhwani S, Dasari BVM

ORIGINAL ARTICLE

Retrospective Cohort Study

- 19 Laparoscopic hepatectomy reduces postoperative complications and hospital stay in overweight and obese patients
Heise D, Bednarsch J, Kroh A, Schipper S, Eickhoff R, Coolsen M, Van Dam R, Lang S, Neumann U, Ulmer F

Retrospective Study

- 30 Pancreas-preserving duodenal resections *vs* pancreatoduodenectomy for groove pancreatitis. Should we revisit treatment algorithm for groove pancreatitis?
Egorov V, Petrov R, Schegolev A, Dubova E, Vankovich A, Kondratyev E, Dobriakov A, Kalinin D, Schvetz N, Poputichikova E
- 50 Evaluation of prognostic factors and clinicopathological patterns of recurrence after curative surgery for colorectal cancer
Melli F, Bartolini I, Risaliti M, Tucci R, Ringressi MN, Muiesan P, Taddei A, Amedei A

SYSTEMATIC REVIEWS

- 76 Xanthogranulomatous appendicitis: A comprehensive literature review
Akbulut S, Demyati K, Koc C, Tuncer A, Sahin E, Ozcan M, Samdanci E

CASE REPORT

- 87 Multidetector computed tomography three-dimensional and multiplanar reconstruction diagnosis of a rare cause of gastrointestinal bleeding: A case report
Cai Y, Chen XB, Mai DH, Wu P, Chen YH, Chen H

ABOUT COVER

Editorial board member of *World Journal of Gastrointestinal Surgery*, Dr. Raphael LC Araujo is a Professor of Liver Surgery at Federal University of São Paulo (UNIFESP -Brazil). After earning his medical degree from University of the State of Rio de Janeiro (2003), he undertook training in Surgical Oncology at AC Camargo Cancer Center. Afterwards, he spent two years (2010-2012) as Research Fellow in Hepatopancreatobiliary Service at Memorial Sloan-Kettering Cancer Center (New York, United States), working on multimodal approaches for hepatopancreatobiliary malignancies, mainly for colorectal liver metastases and pancreas cancer. Subsequently, he performed residency in Hepatopancreatobiliary Service at Hospital Paul Brousse (France; 2012-2013) and then earned both a PhD (2015) and post-doctorate (2017) degree in Gastroenterology from the University of São Paulo. (L-Editor: Filipodia)

AIMS AND SCOPE

The primary aim of *World Journal of Gastrointestinal Surgery* (WJGS, *World J Gastrointest Surg*) is to provide scholars and readers from various fields of gastrointestinal surgery with a platform to publish high-quality basic and clinical research articles and communicate their research findings online.

WJGS mainly publishes articles reporting research results and findings obtained in the field of gastrointestinal surgery and covering a wide range of topics including biliary tract surgical procedures, biliopancreatic diversion, colectomy, esophagectomy, esophagostomy, pancreas transplantation, and pancreatectomy, etc.

INDEXING/ABSTRACTING

The WJGS is now abstracted and indexed in Science Citation Index Expanded (SCIE, also known as SciSearch®), Current Contents/Clinical Medicine, Journal Citation Reports/Science Edition, PubMed, and PubMed Central. The 2020 edition of Journal Citation Reports® cites the 2019 impact factor (IF) for WJGS as 1.863; IF without journal self cites: 1.824; Ranking: 109 among 210 journals in surgery; Quartile category: Q3; Ranking: 77 among 88 journals in gastroenterology and hepatology; and Quartile category: Q4.

RESPONSIBLE EDITORS FOR THIS ISSUE

Production Editor: Jia-Hui Li; Production Department Director: Xiang Li; Editorial Office Director: Ya-Juan Ma.

NAME OF JOURNAL

World Journal of Gastrointestinal Surgery

ISSN

ISSN 1948-9366 (online)

LAUNCH DATE

November 30, 2009

FREQUENCY

Monthly

EDITORS-IN-CHIEF

Shu-You Peng, Varut Lohsiriwat, Jin Gu

EDITORIAL BOARD MEMBERS

<https://www.wjgnet.com/1948-9366/editorialboard.htm>

PUBLICATION DATE

January 27, 2021

COPYRIGHT

© 2021 Baishideng Publishing Group Inc

INSTRUCTIONS TO AUTHORS

<https://www.wjgnet.com/bpg/gerinfo/204>

GUIDELINES FOR ETHICS DOCUMENTS

<https://www.wjgnet.com/bpg/GerInfo/287>

GUIDELINES FOR NON-NATIVE SPEAKERS OF ENGLISH

<https://www.wjgnet.com/bpg/gerinfo/240>

PUBLICATION ETHICS

<https://www.wjgnet.com/bpg/GerInfo/288>

PUBLICATION MISCONDUCT

<https://www.wjgnet.com/bpg/gerinfo/208>

ARTICLE PROCESSING CHARGE

<https://www.wjgnet.com/bpg/gerinfo/242>

STEPS FOR SUBMITTING MANUSCRIPTS

<https://www.wjgnet.com/bpg/GerInfo/239>

ONLINE SUBMISSION

<https://www.f6publishing.com>



Multidetector computed tomography three-dimensional and multiplanar reconstruction diagnosis of a rare cause of gastrointestinal bleeding: A case report

Yong Cai, Xiao-Bo Chen, Da-Hai Mai, Ping Wu, Yong-Hai Chen, Hua Chen

ORCID number: Yong Cai 0000-0001-8387-865X; Xiao-Bo Chen 0000-0003-3752-9509; Da-Hai Mai 0000-0002-3261-060X; Ping Wu 0000-0002-5089-4060; Yong-Hai Chen 0000-0002-4741-0678; Hua Chen 0000-0003-4681-6948.

Author contributions: Chen H and Cai Y analyzed and designed the study; Chen XB, Mai DH, Wu P, and Chen YH worked together to analyze the data; Chen H wrote and edited the manuscript; and all authors read and approved the manuscript.

Supported by Special Fund for Scientific Research for the High-level Hospital Construction Research Project of Maoming People's Hospital, No. zx2020003

Informed consent statement: Informed written consent was obtained from the patient for publication of this report and any accompanying images.

Conflict-of-interest statement: The authors declare that they have no conflict of interest.

CARE Checklist (2016) statement: The authors have read the CARE Checklist (2016), and the manuscript was prepared and revised according to the CARE

Yong Cai, Xiao-Bo Chen, Yong-Hai Chen, Department of Diagnostic Imaging, Maoming People's Hospital, Maoming 525000, Guangdong Province, China

Da-Hai Mai, Hua Chen, Department of Oncology, Maoming People's Hospital, Maoming 525000, Guangdong Province, China

Ping Wu, Department of Gastroenterology, Maoming People's Hospital, Maoming 525000, Guangdong Province, China

Corresponding author: Hua Chen, MBBS, Doctor, Department of Oncology, Maoming People's Hospital, No. 101 Weimin Road, Maoming 525000, Guangdong Province, China. chen1hua@163.com

Abstract

BACKGROUND

Anastomosis of the testicular vein with the superior mesenteric vein rarely causes severe gastrointestinal bleeding. To date, there have been few studies describing its appearance on medical imaging. Here, we present multidetector computed tomography three-dimensional and multiplanar reconstruction (MPR) images of a typical digital subtraction angiography showing proven ectopic bleeding and provide the first review of the image performance.

CASE SUMMARY

A 68-year-old man who had been rushed to the hospital with a four-day history of melena and fainting underwent multiple esophagogastroduodenoscopy procedures that failed to identify the source of bleeding. We used MPR combined with three-dimensional reconstruction images, and found that the testicular vein had anastomosed with the superior mesenteric vein, and they clustered together in the jejunal vessel wall, which caused severe gastrointestinal bleeding. Digital subtraction angiography confirmed the location of bleeding. After transfusion and embolization therapy, the patient's condition improved.

CONCLUSION

Computed tomography-MPR combined with three-dimensional images offers significant value in the localization and qualitative assessment of rare gastrointestinal hemorrhage. The features of multiphase spiral scanning can improve the accuracy of the diagnosis.

Checklist (2016).

Open-Access: This article is an open-access article that was selected by an in-house editor and fully peer-reviewed by external reviewers. It is distributed in accordance with the Creative Commons Attribution NonCommercial (CC BY-NC 4.0) license, which permits others to distribute, remix, adapt, build upon this work non-commercially, and license their derivative works on different terms, provided the original work is properly cited and the use is non-commercial. See: <http://creativecommons.org/licenses/by-nc/4.0/>

Manuscript source: Unsolicited manuscript

Specialty type: Gastroenterology and hepatology

Country/Territory of origin: China

Peer-review report's scientific quality classification

Grade A (Excellent): 0
Grade B (Very good): 0
Grade C (Good): C
Grade D (Fair): 0
Grade E (Poor): 0

Received: September 17, 2020

Peer-review started: September 17, 2020

First decision: November 16, 2020

Revised: November 30, 2020

Accepted: December 10, 2020

Article in press: December 10, 2020

Published online: January 27, 2021

P-Reviewer: Martínez-Pérez A

S-Editor: Zhang L

L-Editor: Webster JR

P-Editor: Wang LYT



Key Words: Testicular vein; Superior mesenteric vein; Gastrointestinal bleeding; Multiplanar reconstruction; Three-dimensional images; Case report

©The Author(s) 2021. Published by Baishideng Publishing Group Inc. All rights reserved.

Core Tip: We report a case of anastomosis of the testicular vein with the superior mesenteric vein that caused severe gastrointestinal bleeding. We used multidetector computed tomography three-dimensional and multiplanar reconstruction, and found that the testicular vein had anastomosed with the superior mesenteric vein, and gathered together in the jejunal vessel wall. Digital subtraction angiography confirmed the location of bleeding. After vascular intervention, the patient's symptoms significantly improved.

Citation: Cai Y, Chen XB, Mai DH, Wu P, Chen YH, Chen H. Multidetector computed tomography three-dimensional and multiplanar reconstruction diagnosis of a rare cause of gastrointestinal bleeding: A case report. *World J Gastrointest Surg* 2021; 13(1): 87-95

URL: <https://www.wjgnet.com/1948-9366/full/v13/i1/87.htm>

DOI: <https://dx.doi.org/10.4240/wjgs.v13.i1.87>

INTRODUCTION

Varices can develop anywhere in the upper or lower gastrointestinal tract. They may develop at any site of portal hypertension, but they are most commonly located in the esophagus and gastric fundus^[1]. In patients with portal hypertension, the absence of hemorrhage from the esophageal and gastric fundal veins does not rule out the presence of varicose veins in other areas, which may lead to gastrointestinal bleeding. Statistically, ectopic varices account for approximately 5% of all variceal bleeding, of which 17% occurs in the duodenum^[2,3]. Colonic varices are extremely rare, and the diagnosis and treatment strategies have not been standardized^[2]. However, traditional endoscopy cannot reach the distal portion of the duodenum, and angiography sometimes fails to show duodenal varicose veins^[4]. Recently, there have been reports of multidetector computed tomography (CT) with multiplanar reconstruction (MPR) for the diagnosis and therapeutic management of duodenal varices^[5,6]. Our case suggests the usefulness of multidetector CT with MPR combined with three-dimensional (3D) images for the diagnosis and therapeutic management of duodenal varices.

CASE PRESENTATION

Chief complaints

A 68-year-old man with liver cancer due to liver cirrhosis was referred to our hospital on March 3, 2020, with persistent melena for 4 d.

History of present illness

The patient's symptoms started a month ago with abdominal pain and weakness.

History of past illness

His significant past history included liver cancer, colon cancer, diabetes, hypertension, and benign prostatic hyperplasia.

Personal and family history

The patient's family had no previous medical history.

Physical examination

The patient's temperature was 36.5°C, heart rate was 92 bpm, respiratory rate was 16 breaths/min, blood pressure was 120/70 mmHg and oxygen saturation in room air

was 98%. No other pathological signs were observed. Physical examination revealed abdominal tenderness. Our clinical consideration was gastrointestinal bleeding.

Laboratory examinations

His hemoglobin level was 56 g/L (normal range 120-160 g/L).

Imaging examinations

He underwent multiple esophagogastroduodenoscopy (EGD) procedures that failed to identify the source of bleeding. For the initial diagnosis, we believed that decompensated cirrhosis led to gastrointestinal bleeding caused by esophageal and gastric varices. However, EGD revealed no bleeding from the esophagus fundus ventricularis varication or duodenal ulcer (Figure 1). To determine the location of bleeding, an abdominal CT examination was conducted using a multidetector row CT. CT (scan and enhancement) revealed numerous enlarged branches of the blood vessels of the jejunum and tortuous irregular vessels relative to the prior physical examination on May 29, 2019 (Figure 2). Imaging of the stomach and the bottom of the pelvis showed varices but no bleeding. Postoperative changes indicated liver cancer and sigmoid colon cancer, liver cirrhosis, splenomegaly, and ascites. Follow-up CT and routine blood reexamination and routine stool examination showed no complications, such as bleeding, between May 2019 and March 2020. The MPR image clearly showed a varicocele on the left side and the venae testicularis as a tangled mass of vessels that formed varicose veins, which anastomosed with the superior mesenteric vein. It also showed local bleeding. On CT, it presented as a high-density hemorrhage and a hematoma (orange arrows in Figure 3). Axial, coronal, and sagittal volume rendering CT images, including maximum intensity projection (MIP), with contrast showed venous anastomosis, varicose veins, and a tortuous collection of irregular vessels (Figure 3). To further confirm the diagnosis, we conducted CT of the arterial-phase, portal-phase, equilibrium-phase, and delayed-phase scanning, and then performed dynamic observation of the changes in jejunal bleeding. The results showed vascular mass enlargement during the delayed phase (Figure 4). Portal angiography indicated that the portal, splenic, and superior mesenteric veins were twisted and dilated. We not only observed spermatic veins but also noted connections with the superior mesenteric vein, and they formed an anastomosis. Contrast media had also leaked into the intestine. An inferior vena digital subtraction angiography (DSA) also showed that the superior mesenteric vein and the spermatic vein had formed a varicose venous anastomosis (Figure 5A and C).

FINAL DIAGNOSIS

The final diagnosis in the present case was chronic portal hypertension leading to the development of collateral circulation, which was manifested as anastomosis of the testicular vein with the superior mesenteric vein that gathered together in the jejunal vessel wall, causing gastrointestinal bleeding.

TREATMENT

The patient was treated conservatively by stopping the bleeding and omeprazole administration during management. After transfusion and infusion with a hemostatic agent, the patient's condition did not improve, and his red blood cell count decreased and hemoglobin decreased to 51 g/L. Finally, we decided that the patient should undergo embolization. Seldinger's technique was used to puncture the femoral vein and percutaneous hepatic portal vein for DSA. A varicocele was observed on the left side and the venae testicularis was a tangled mass of vessels that formed varicose veins, which anastomosed with the superior mesenteric vein. A spring coil was inserted to embolize the communication branch, and imaging was performed again. DSA revealed that the communicating branches had disappeared, and there was no contrast agent extravasation after this treatment (Figure 5B and D).

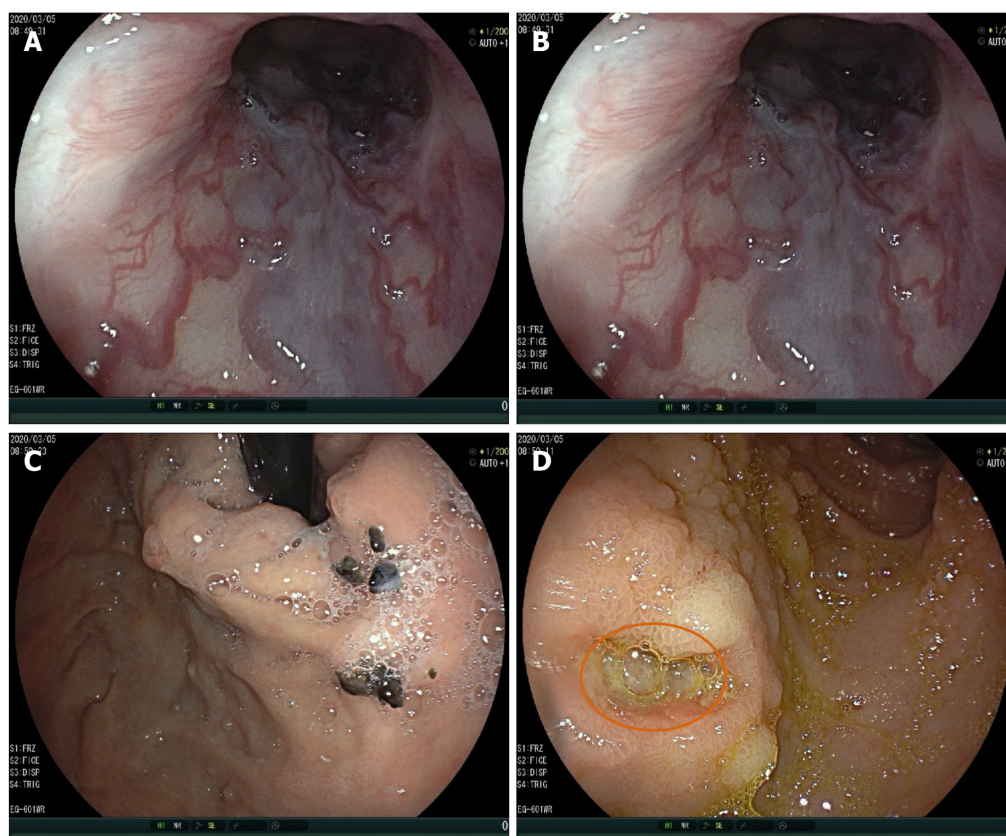


Figure 1 An esophagogastrroduodenoscopy was performed to rule out esophageal and gastric variceal bleeding. A and B: Esophageal varices; C: Gastric varices; and D: No hemorrhage from the superficial ulcer (orange circle).

OUTCOME AND FOLLOW-UP

No gastrointestinal bleeding was observed after embolization. The patient agreed to undergo routine blood examination. After transfusion and embolization therapy, the patient's condition improved, and his hemoglobin level reached 78 g/L; he was then discharged (Figure 6). We performed follow-up CT imaging, blood and stool sample tests, liver function tests, and determination of hemoglobin level, and no bleeding was observed at the embolized site, as indicated by tests at 1, 2, and 3 mo after surgery (Table 1). We suggested the use of a transjugular intrahepatic portosystemic shunt, which not only reduces the recurrence rate of gastrointestinal bleeding due to the high-pressure portal vein but also improves liver function. The patient refused the operation and received conservative treatment only in the internal medicine department. Perhaps the principal reasons why the patient declined to undergo the operation were because the surgery involved a risk of damage to liver function, and involved other risks, his older age, and the considerable financial cost.

DISCUSSION

Gastrointestinal varices are abnormally dilated submucosal veins in the digestive tract. They can be caused by portal hypertension, and they can cause life-threatening bleeding^[7]. Ectopic varices, which are varices other than esophageal and gastric varices, are thought to be relatively rare. Approximately 5% of all varices associated with gastrointestinal bleeding are ectopic varices^[8]. However, the ectopic malformations associated with varices vary greatly in size and location. Rapid, abundant blood flow makes it difficult to diagnose them definitively. In this case, we used multidetector CT with MPR combined with 3D image delineation to localize the bleeding point and provide interventional embolization. Eventually, it was clear that chronic portal hypertension may have led to the development of collateral circulation, which was manifested as anastomosis of the testicular vein with the superior mesenteric vein, and they gathered together in the jejunal vessel wall, causing

Table 1 Hemoglobin changes during hospitalization

Date	Hemoglobin (g/L)	Red blood cells ($10^{12}/L$)	Hematocrit (%)
March 4, 2020	56.0	2.05	17.10
March 5, 2020	51.0	1.99	16.00
March 6, 2020	61.0	2.39	20.00
March 6, 2020	57.0	2.12	17.30
March 7, 2020	70.0	2.63	21.80
March 9, 2020	66.0	2.4	20.70
March 10, 2020	74.0	2.71	23.30

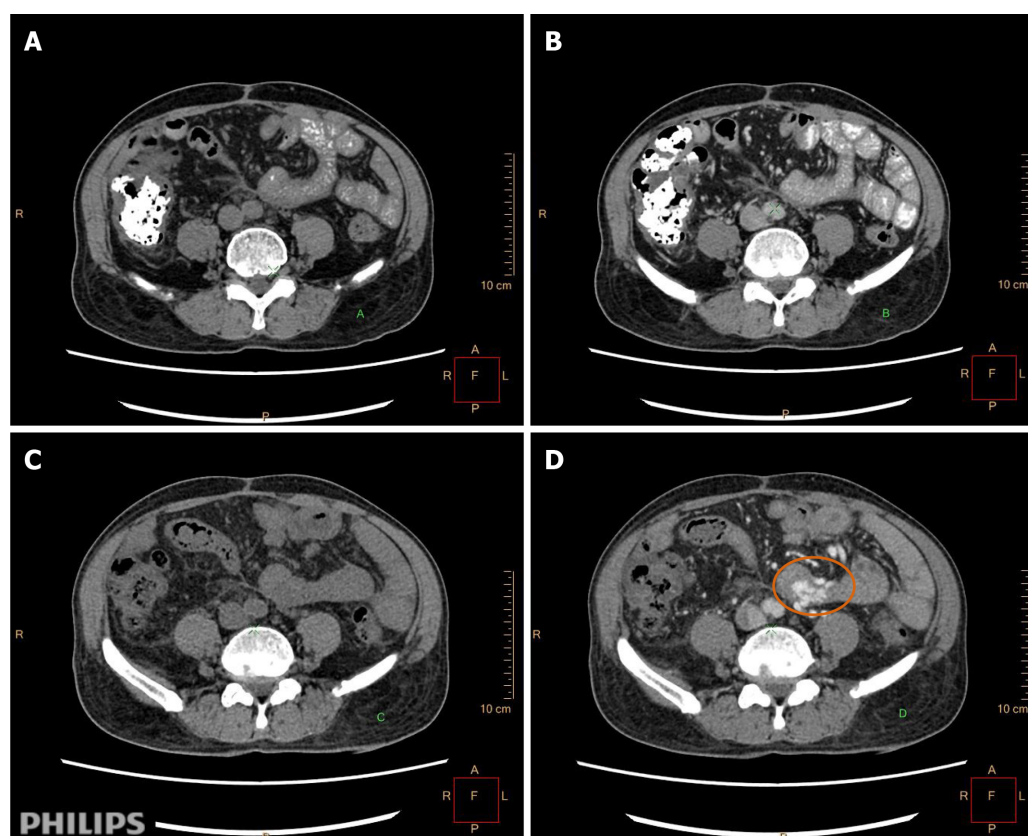


Figure 2 Abdominal computed tomography enhancement scan with intravenous iodixanol-320 administration. A and B: Scans, imaging and physical examination were normal on May 29, 2019; C and D: Enhancement, numerous enlarged branches of the blood vessels of the jejunum and tortuous irregular vessels (orange circle).

gastrointestinal bleeding. According to a recently published report, CT angiography has excellent sensitivity (90%) and specificity (92%) for lower gastrointestinal bleeding^[9].

Globally, the most common etiologies of portal hypertension are cirrhosis due to alcoholic liver disease, nonalcoholic steatohepatitis, and hepatitis C infection^[10]. There are data showing that the prevalence of varicose veins increases with the severity of liver function grade (Child-Pugh class). For classes A, B, and C, the incidence of varicose veins was 42.7%, 70.7%, and 75.5%, respectively^[7,11]. The pathophysiology of portal hypertension is a multifactorial process involving changes in both the portal and systemic circulation. First, hepatocellular injury and expression of pro-inflammatory genes alter the intrahepatic hemodynamics^[12]. Second, there is increased vascular resistance from increased production of vasoconstrictors and a reduction in nitric oxide synthesis^[13]. Extrahepatic hemodynamics are also important. Excessive nitric oxide can reduce splanchnic and systemic vascular resistance^[14]. Activation of the renin-angiotensin mechanism leads to increased cardiac output and hepatic blood

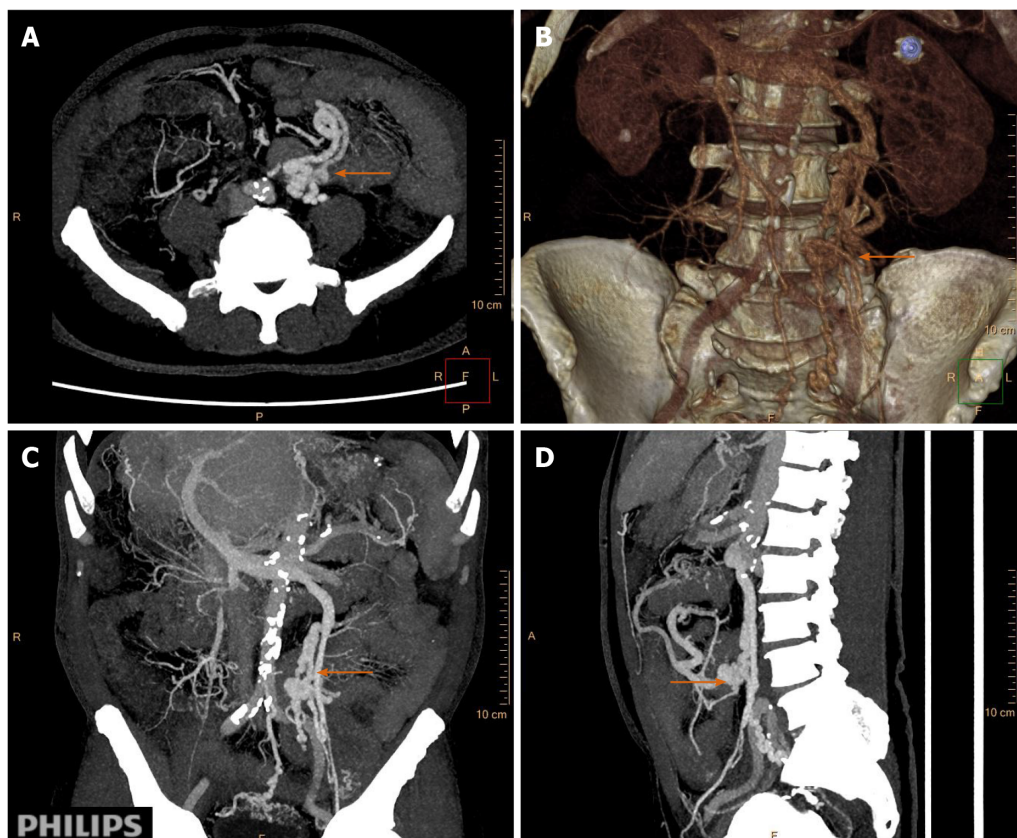


Figure 3 Multiplanar reconstruction showed a varicocele on the left side and venae testicularis as a tangled mass of vessels forming varicose veins, which anastomosed with the superior mesenteric vein (orange arrow). A: Axial plus coronal scanning; B: Sagittal scans; C: Images reconstructed with maximum intensity projection; and D: Images showing volume rendering three-dimensional reconstruction by spiral computed tomography.

flow^[15]. Clear establishment of the mechanism through which varicose veins lead to gastrointestinal bleeding would facilitate the diagnosis and treatment.

Our case shows the effectiveness of multidetector CT with MPR union 3D images for the diagnosis of duodenal varices. The MPR of CT more clearly displays the ectopic duodenal varices at sites that EGD cannot access. Few reports have suggested the importance of MPR in the diagnosis of ectopic varices^[16,17]. The usefulness of multidetector helical CT with multiplanar reconstruction for depicting duodenal varices with multiple collateral shunt vessels has been reported^[6]. CT-MIP is a clinically useful modality to distinguish gastric varices from ectopic varices^[18]. Few papers have also explored MPR union 3D images in the diagnosis of duodenal varices. With the development and application of imaging examination and endoscopic technology, most cases of gastrointestinal bleeding can be definitively diagnosed by gastroscopy. However, the ectopic malformations associated with varices vary greatly in size and location; thus, the results of gastroscopy can be difficult to determine, and it is not exactly clear what causes gastrointestinal bleeding. At this point, CT-MPR, CT-MIP, and CT-volume rendering play a key role in the diagnosis.

There are no management guidelines for this relatively rare condition (Accdon1), and the available literature includes only case reports, with few literature reviews. According to the severity of the disease, treatment can be divided into endoscopy, interventional radiology, and surgery. Although endoscopic ligation and injection sclerotherapy are the first line of treatment^[19,20], they are not always appropriate for gastrointestinal hemorrhage, partly because the site of bleeding cannot be visualized using an endoscope. Embolization must be performed in a specific way to decrease the risk of bowel ischemia^[21]. In our case, endovascular interventional embolization was an appropriate measure because the anastomosis, varicose veins, and tortuous collection of irregular vessels bled profusely during the CT examination, and although conservative medical treatment can better cope with hemorrhage, it did not solve the problem^[9].

We did not conduct multidisciplinary consultation on time as multiple EGD procedures failed to identify the source of bleeding, which was the primary take-away

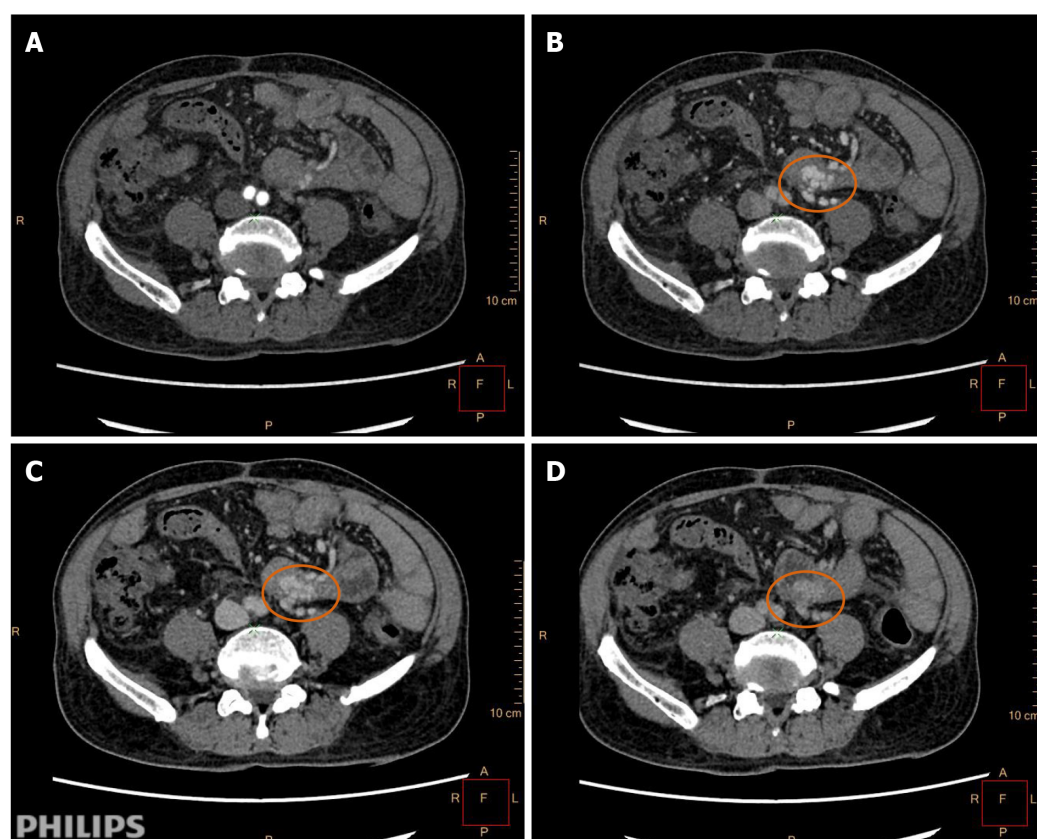


Figure 4 Four-phase dynamic computed tomography features and identifying the bleeding in arterial-phase, portal-phase, equilibrium-phase, and delayed-phase scanning. A: The arterial-phase showed no abnormal signs of the blood vessel on computed tomography images; B: During the portal-phase, the testicular vein and the superior mesenteric vein gathered together with vascular dilatation, tortuosity, and active bleeding (orange circle); C: The equilibrium-phase also showed bleeding; and D: Delayed-phase scanning showed vascular mass enlargement.

lesson of this case report. Blood transfusion was performed during this period, but the symptoms did not improve significantly.

CONCLUSION

In conclusion, we herein report that CT-MPR, CT-MIP, and CT-volume rendering are effective means of locating duodenal varices with complicated varicose veins and tortuous collections of irregular vessels, and all of these methods provide the necessary information for deciding upon the best treatment. CT-MPR was found to be a simple and rapid modality, and it clearly reflected the pathological morphology. CT-MPR is valuable for the early diagnosis of rare variceal bleeding; however, in the present case, the diagnosis was delayed. This method provides reliable diagnostic information for clinical treatment; thus, we expect that it will be widely used in the future.

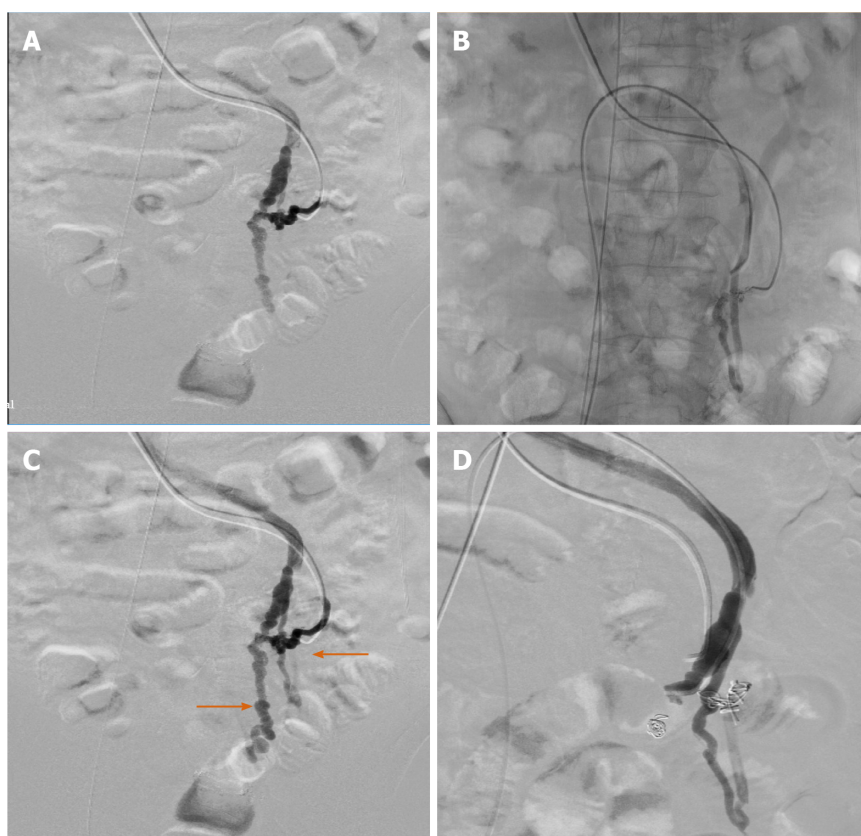


Figure 5 Digital subtraction angiography indicating the bleeding points, which were then embolized to the feeding branches. A and C: Portal angiography, with bleeding points and contrast media extravasating into the intestinal tract; B: Digital subtraction angiography of the inferior vena cava; and D: No contrast agent extravasation after embolization therapy.

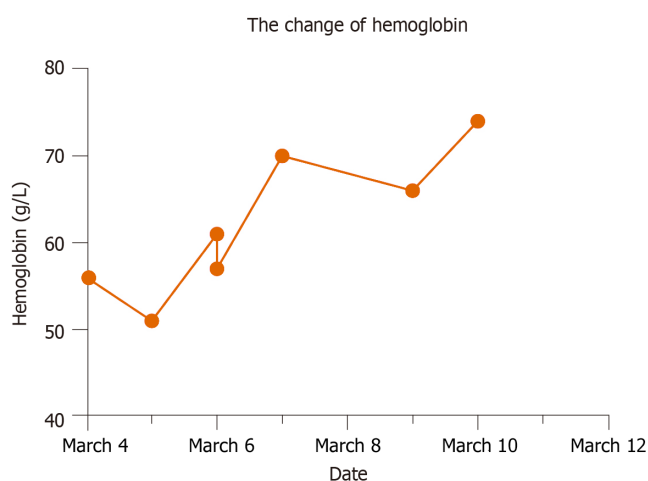


Figure 6 Hemoglobin level changes during hospitalization. After transfusion and embolization therapy, the patient's hemoglobin level reached 78 g/L.

ACKNOWLEDGEMENTS

The authors would like to thank Dr. Lei-Gang Tian and Dr. Ke-Dong Han from Maomin People's Hospital, Maomin, China, for their contributions to image processing; the High-level Hospital Construction Research Project of Maoming People's Hospital for its financial support in conducting the research and preparation of the manuscript. We also would like to thank Dr. Tao-Hsin Tung from Enze Medical Research Center, Affiliated Taizhou Hospital of Wenzhou Medical College, Taizhou, China, for his expert advice and encouragement throughout this study.

REFERENCES

- 1 **Hamlyn AN**, Morris JS, Lunzer MR, Puritz H, Dick R. Portal hypertension with varices in unusual sites. *Lancet* 1974; **2**: 1531-1534 [PMID: [4140979](#) DOI: [10.1016/s0140-6736\(74\)90283-9](#)]
- 2 **Matsumoto K**, Imai Y, Takano M, Nakazawa M, Ando S, Sugawara K, Nakayama N, Tomiya T, Mochida S. A case of colonic varices complicated by alcoholic cirrhosis treated using balloon-occluded retrograde transvenous obliteration. *Clin J Gastroenterol* 2018; **11**: 343-347 [PMID: [29696582](#) DOI: [10.1007/s12328-018-0857-1](#)]
- 3 **Norton ID**, Andrews JC, Kamath PS. Management of ectopic varices. *Hepatology* 1998; **28**: 1154-1158 [PMID: [9755256](#) DOI: [10.1002/hep.510280434](#)]
- 4 **Chang KJ**. Endoscopic foregut surgery and interventions: The future is now. The state-of-the-art and my personal journey. *World J Gastroenterol* 2019; **25**: 1-41 [PMID: [30643356](#) DOI: [10.3748/wjg.v25.i1.1](#)]
- 5 **Haq I-**, Shah AA, Chandramohan S. Distal Duodenal Varices: First Presentation of Upper Gastrointestinal Bleeding. *J Coll Physicians Surg Pak* 2017; **27**: S11-S12 [PMID: [28302230](#)]
- 6 **Yoshida S**, Watabe H, Akahane M, Kyoden Y, Ishikawa H, Yamada A, Sugimoto T, Ohta M, Ogura K, Yamaji Y, Ohtomo K, Kokudo N, Koike K, Omata M. Usefulness of multi-detector helical CT with multiplanar reconstruction for depicting the duodenal varices with multiple collateral shunt vessels. *Hepatol Int* 2010; **4**: 775-778 [PMID: [21286350](#) DOI: [10.1007/s12072-010-9191-5](#)]
- 7 **Boregowda U**, Umapathy C, Halim N, Desai M, Nanjappa A, Arekapudi S, Theethira T, Wong H, Roytman M, Saligram S. Update on the management of gastrointestinal varices. *World J Gastrointest Pharmacol Ther* 2019; **10**: 1-21 [PMID: [30697445](#) DOI: [10.4292/wjgpt.v10.i1.1](#)]
- 8 **Watanabe N**, Toyonaga A, Kojima S, Takashimizu S, Oho K, Kokubu S, Nakamura K, Hasumi A, Murashima N, Tajiri T. Current status of ectopic varices in Japan: Results of a survey by the Japan Society for Portal Hypertension. *Hepatol Res* 2010; **40**: 763-776 [PMID: [20649816](#) DOI: [10.1111/j.1872-034X.2010.00690.x](#)]
- 9 **Pannatier M**, Duran R, Denys A, Meuli R, Zingg T, Schmidt S. Characteristics of patients treated for active lower gastrointestinal bleeding detected by CT angiography: Interventional radiology vs surgery. *Eur J Radiol* 2019; **120**: 108691 [PMID: [31589996](#) DOI: [10.1016/j.ejrad.2019.108691](#)]
- 10 **Kovalak M**, Lake J, Mattek N, Eisen G, Lieberman D, Zaman A. Endoscopic screening for varices in cirrhotic patients: data from a national endoscopic database. *Gastrointest Endosc* 2007; **65**: 82-88 [PMID: [17185084](#) DOI: [10.1016/j.gie.2006.08.023](#)]
- 11 **Grace ND**. Diagnosis and treatment of gastrointestinal bleeding secondary to portal hypertension. American College of Gastroenterology Practice Parameters Committee. *Am J Gastroenterol* 1997; **92**: 1081-1091 [PMID: [9219775](#)]
- 12 **Thabut D**, Shah V. Intrahepatic angiogenesis and sinusoidal remodeling in chronic liver disease: new targets for the treatment of portal hypertension? *J Hepatol* 2010; **53**: 976-980 [PMID: [20800926](#) DOI: [10.1016/j.jhep.2010.07.004](#)]
- 13 **Chinese Society of Spleen and Portal Hypertension Surgery**, Chinese Society of Surgery, Chinese Medical Association. [Expert consensus on diagnosis and treatment of esophagogastric variceal bleeding in cirrhotic portal hypertension (2019 edition)]. *Zhonghua Wai Ke Za Zhi* 2019; **57**: 885-892 [PMID: [31826590](#) DOI: [10.3760/cma.j.issn.0529-5815.2019.12.002](#)]
- 14 **Abrales JG**, Iwakiri Y, Loureiro-Silva M, Haq O, Sessa WC, Groszmann RJ. Mild increases in portal pressure upregulate vascular endothelial growth factor and endothelial nitric oxide synthase in the intestinal microcirculatory bed, leading to a hyperdynamic state. *Am J Physiol Gastrointest Liver Physiol* 2006; **290**: G980-G987 [PMID: [16603731](#) DOI: [10.1152/ajpgi.00336.2005](#)]
- 15 **Huang HC**, Haq O, Utsumi T, Sethasine S, Abrales JG, Groszmann RJ, Iwakiri Y. Intestinal and plasma VEGF levels in cirrhosis: the role of portal pressure. *J Cell Mol Med* 2012; **16**: 1125-1133 [PMID: [21801303](#) DOI: [10.1111/j.1582-4934.2011.01399.x](#)]
- 16 **Li CY**, Gao BL, Song B, Fan QY, Zhou LX, Feng PY, Zhang XJ, Zhu QF, Xiang C, Peng S, Huang YF, Yang HQ. Evaluation of left gastric vein in Chinese healthy adults with multi-detector computed tomography. *Postgrad Med* 2016; **128**: 701-705 [PMID: [27336836](#) DOI: [10.1080/00325481.2016.1205455](#)]
- 17 **Seo YS**, Kwon YD, Park S, Keum B, Park BJ, Kim YS, Jeon YT, Chun HJ, Kim CD, Ryu HS, Um SH. Complete eradication of duodenal varices after endoscopic injection sclerotherapy with ethanolamine oleate: a case report. *Gastrointest Endosc* 2008; **67**: 759-762 [PMID: [18206152](#) DOI: [10.1016/j.gie.2007.08.027](#)]
- 18 **Ishikawa T**, Ushiki T, Mizuno K, Togashi T, Watanabe K, Seki K, Ohta H, Yoshida T, Takeda K, Kamimura T. CT-maximum intensity projection is a clinically useful modality for the detection of gastric varices. *World J Gastroenterol* 2005; **11**: 7515-7519 [PMID: [16437726](#) DOI: [10.3748/wjg.v11.i47.7515](#)]
- 19 **Malik A**, Junglee N, Khan A, Sutton J, Gasem J, Ahmed W. Duodenal varices successfully treated with cyanoacrylate injection therapy. *BMJ Case Rep* 2011; **2011** [PMID: [22694885](#) DOI: [10.1136/bcr.02.2011.3913](#)]
- 20 **Kang HY**, Lee WK, Kim YH, Kwon BW, Kang MS, Kim SB, Song IH. Ruptured duodenal varices arising from the main portal vein successfully treated with endoscopic injection sclerotherapy: a case report. *Korean J Hepatol* 2011; **17**: 152-156 [PMID: [21757987](#) DOI: [10.3350/kjhep.2011.17.2.152](#)]
- 21 **Funaki B**. Gastrointestinal Bleeding on Call: Questions and Answers and One Person's Opinions. *Semin Intervent Radiol* 2020; **37**: 31-34 [PMID: [32139968](#) DOI: [10.1055/s-0039-3402018](#)]



Published by **Baishideng Publishing Group Inc**
7041 Koll Center Parkway, Suite 160, Pleasanton, CA 94566, USA

Telephone: +1-925-3991568

E-mail: bpgoffice@wjgnet.com

Help Desk: <https://www.f6publishing.com/helpdesk>

<https://www.wjgnet.com>

