

World Journal of *Gastrointestinal Surgery*

World J Gastrointest Surg 2021 October 27; 13(10): 1110-1292



Contents

Monthly Volume 13 Number 10 October 27, 2021

FRONTIER

- 1110 Long-term survival outcome of laparoscopic liver resection for hepatocellular carcinoma
Lam S, Cheng KC

OPINION REVIEW

- 1122 Review of minimally invasive pancreas surgery and opinion on its incorporation into low volume and resource poor centres
Cawich SO, Kluger MD, Francis W, Deshpande RR, Mohammed F, Bonadie KO, Thomas DA, Pearce NW, Schrope BA

MINIREVIEWS

- 1136 Research progress regarding programmed cell death 1/programmed cell death ligand 1 inhibitors combined with targeted therapy for treating hepatocellular carcinoma
Zheng LL, Tao CC, Tao ZG, Zhang K, Wu AK, Wu JX, Rong WQ
- 1149 Transanal minimally invasive surgery using laparoscopic instruments of the rectum: A review
Kim MJ, Lee TG
- 1166 Current surgical management of duodenal gastrointestinal stromal tumors
Lim KT
- 1180 Gastric endoscopic submucosal dissection in Western countries: Indications, applications, efficacy and training perspective
De Luca L, Di Berardino M, Mangiavillano B, Repici A

ORIGINAL ARTICLE

Case Control Study

- 1190 Laparoscopy for Crohn's disease: A comprehensive exploration of minimally invasive surgical techniques
Wan J, Liu C, Yuan XQ, Yang MQ, Wu XC, Gao RY, Yin L, Chen CQ

Retrospective Study

- 1202 Onodera's Prognostic Nutritional Index is a novel and useful prognostic marker for gastrointestinal stromal tumors
Wang H, Xu YY, You J, Hu WQ, Wang SF, Chen P, Yang F, Shi L, Zhao W, Zong L
- 1216 Utility of preoperative systemic inflammatory biomarkers in predicting postoperative complications after pancreaticoduodenectomy: Literature review and single center experience
Coppola A, La Vaccara V, Caggiati L, Carbone L, Spoto S, Ciccozzi M, Angeletti S, Coppola R, Caputo D

- 1226** Low serum albumin may predict poor efficacy in patients with perforated peptic ulcer treated nonoperatively
Liang TS, Zhang BL, Zhao BB, Yang DG
- 1235** Oesophageal adenocarcinoma: In the era of extended lymphadenectomy, is the value of neoadjuvant therapy being attenuated?
Park JS, Van der Wall H, Kennedy C, Falk GL
- 1245** Outcomes of reduction hepatectomy combined with postoperative multidisciplinary therapy for advanced hepatocellular carcinoma
Asahi Y, Kamiyama T, Kakisaka T, Orimo T, Shimada S, Nagatsu A, Aiyama T, Sakamoto Y, Kamachi H, Taketomi A
- 1258** Development and validation of a prediction model for deep vein thrombosis in older non-mild acute pancreatitis patients
Yang DJ, Li M, Yue C, Hu WM, Lu HM

SCIENTOMETRICS

- 1267** Immunotherapy after liver transplantation: Where are we now?
Au KP, Chok KSH

CASE REPORT

- 1279** Hodgkin lymphoma masquerading as perforated gallbladder adenocarcinoma: A case report
Manesh M, Henry R, Gallagher S, Greas M, Sheikh MR, Zielsdorf S
- 1285** Whole circumferential endoscopic submucosal dissection of superficial adenocarcinoma in long-segment Barrett's esophagus: A case report
Abe K, Goda K, Kanamori A, Suzuki T, Yamamiya A, Takimoto Y, Arisaka T, Hoshi K, Sugaya T, Majima Y, Tominaga K, Iijima M, Hirooka S, Yamagishi H, Irisawa A

ABOUT COVER

Editorial Board Member of World Journal of *Gastrointestinal Surgery*, Ramón Cantero, MD, PhD, Associate Professor, Surgeon, Department of Surgery, La Paz University Hospital, Pozuelo de Alarcón 28223, Madrid, Spain. ramon.cantero@salud.madrid.org

AIMS AND SCOPE

The primary aim of *World Journal of Gastrointestinal Surgery* (WJGS, *World J Gastrointest Surg*) is to provide scholars and readers from various fields of gastrointestinal surgery with a platform to publish high-quality basic and clinical research articles and communicate their research findings online.

WJGS mainly publishes articles reporting research results and findings obtained in the field of gastrointestinal surgery and covering a wide range of topics including biliary tract surgical procedures, biliopancreatic diversion, colectomy, esophagectomy, esophagostomy, pancreas transplantation, and pancreatectomy, etc.

INDEXING/ABSTRACTING

The WJGS is now abstracted and indexed in Science Citation Index Expanded (SCIE, also known as SciSearch®), Current Contents/Clinical Medicine, Journal Citation Reports/Science Edition, PubMed, and PubMed Central. The 2021 edition of Journal Citation Reports® cites the 2020 impact factor (IF) for WJGS as 2.582; IF without journal self cites: 2.564; 5-year IF: 3.378; Journal Citation Indicator: 0.53; Ranking: 97 among 212 journals in surgery; Quartile category: Q2; Ranking: 73 among 92 journals in gastroenterology and hepatology; and Quartile category: Q4.

RESPONSIBLE EDITORS FOR THIS ISSUE

Production Editor: Rui-Rui Wu, Production Department Director: Xiang Li, Editorial Office Director: Ya-Juan Ma.

NAME OF JOURNAL

World Journal of Gastrointestinal Surgery

ISSN

ISSN 1948-9366 (online)

LAUNCH DATE

November 30, 2009

FREQUENCY

Monthly

EDITORS-IN-CHIEF

Shu-You Peng, Varut Lohsiriwat, Jin Gu

EDITORIAL BOARD MEMBERS

<https://www.wjgnet.com/1948-9366/editorialboard.htm>

PUBLICATION DATE

October 27, 2021

COPYRIGHT

© 2021 Baishideng Publishing Group Inc

INSTRUCTIONS TO AUTHORS

<https://www.wjgnet.com/bpg/gerinfo/204>

GUIDELINES FOR ETHICS DOCUMENTS

<https://www.wjgnet.com/bpg/gerinfo/287>

GUIDELINES FOR NON-NATIVE SPEAKERS OF ENGLISH

<https://www.wjgnet.com/bpg/gerinfo/240>

PUBLICATION ETHICS

<https://www.wjgnet.com/bpg/gerinfo/288>

PUBLICATION MISCONDUCT

<https://www.wjgnet.com/bpg/gerinfo/208>

ARTICLE PROCESSING CHARGE

<https://www.wjgnet.com/bpg/gerinfo/242>

STEPS FOR SUBMITTING MANUSCRIPTS

<https://www.wjgnet.com/bpg/gerinfo/239>

ONLINE SUBMISSION

<https://www.f6publishing.com>



Review of minimally invasive pancreas surgery and opinion on its incorporation into low volume and resource poor centres

Shamir O Cawich, Michael D Kluger, Wesley Francis, Rahul R Deshpande, Fawwaz Mohammed, Kimon O Bonadie, Dexter A Thomas, Neil W Pearce, Beth A Schrope

ORCID number: Shamir O Cawich 0000-0003-3377-0303; Michael D Kluger 0000-0003-4311-078X; Wesley Francis 0000-0003-3174-1015; Rahul R Deshpande 0000-0002-1368-4144; Fawwaz Mohammed 0000-0002-1346-8628; Kimon O Bonadie 0000-0001-9387-6121; Dexter A Thomas 0000-0003-3744-744X; Neil W Pearce 0000-0002-3182-7268; Beth A Schrope 0000-0003-0313-8120.

Author contributions: Cawich SO, Schrope BA and Kluger MD designed and coordinated the study; Pearce NW, Bonadie KO, Deshpande R, Francis W and Mohammed F performed experiments, acquired and analyzed data; Cawich SO, Schrope BA, Kluger MD, Pearce NW, Bonadie KO, Deshpande R, Francis W and Mohammed F interpreted the data; Cawich SO and Kluger MD wrote the manuscript; all authors approved the final version of the article.

Conflict-of-interest statement: There are no conflicts of interest reported for any of the authors.

Open-Access: This article is an open-access article that was selected by an in-house editor and fully peer-reviewed by external reviewers. It is distributed in accordance with the Creative

Shamir O Cawich, Clinical Surgical Sciences, University of the West Indies, Tunapuna 331333, Trinidad and Tobago

Michael D Kluger, Department of Surgery, New York Presbyterian Hospital/Columbia University Medical Center, New York, NY 10032, United States

Wesley Francis, Department of Surgery, University of the West Indies, Nassau N-1184, Bahamas

Rahul R Deshpande, Department of Surgery, Manchester Royal Infirmary, Manchester M13 9WL, United Kingdom

Fawwaz Mohammed, Dexter A Thomas, Department of Clinical Surgical Sciences, University of the West Indies, Tunapuna 331333, Trinidad and Tobago

Kimon O Bonadie, Department of Surgery, Health Service Authority, Georgetown 915 GT, Cayman Islands

Neil W Pearce, Department of Surgery, Southampton General Hospital, Southampton SO16 6YD, United Kingdom

Beth A Schrope, Department of Surgery, Columbia University College of Physicians and Surgeons, New York, NY 10032, United States

Corresponding author: Shamir O Cawich, FACS, Professor, Department of Clinical Surgical Sciences, University of the West Indies, St Augustine Campus, Tunapuna 331333, Trinidad and Tobago. socawich@hotmail.com

Abstract

Pancreatic surgery has been one of the last areas for the application of minimally invasive surgery (MIS) because there are many factors that make laparoscopic pancreas resections difficult. The concept of service centralization has also limited expertise to a small cadre of high-volume centres in resource rich countries. However, this is not the environment that many surgeons in developing countries work in. These patients often do not have the opportunity to travel to high volume centres for care. Therefore, we sought to review the existing data on MIS for the pancreas and to discuss. In this paper, we review the evolution of MIS on the pancreas and discuss the incorporation of this service into low-volume and

Commons Attribution NonCommercial (CC BY-NC 4.0) license, which permits others to distribute, remix, adapt, build upon this work non-commercially, and license their derivative works on different terms, provided the original work is properly cited and the use is non-commercial. See: <http://creativecommons.org/licenses/by-nc/4.0/>

Manuscript source: Invited manuscript

Specialty type: Surgery

Country/Territory of origin: Trinidad and Tobago

Peer-review report's scientific quality classification

Grade A (Excellent): 0
Grade B (Very good): B
Grade C (Good): C, C
Grade D (Fair): 0
Grade E (Poor): 0

Received: February 9, 2021

Peer-review started: February 9, 2021

First decision: May 13, 2021

Revised: May 19, 2021

Accepted: September 22, 2021

Article in press: September 22, 2021

Published online: October 27, 2021

P-Reviewer: Samiullah S, Wang Z

S-Editor: Zhang H

L-Editor: A

P-Editor: Li X



resource-poor countries, such as those in the Caribbean. This paper has two parts. First, we performed a literature review evaluating all studies published on laparoscopic and robotic surgery of the pancreas. The data in the Caribbean is examined and we discuss tips for incorporating this operation into resource poor hospital practice. Low pancreatic case volume in the Caribbean, and financial barriers to MIS in general, laparoscopic distal pancreatectomy, enucleation and cystogastrostomy are feasible operations to integrate in to a resource-limited healthcare environment. This is because they can be performed with minimal to no consumables and require an intermediate MIS skillset to complement an open pancreatic surgeon's peri-operative experience.

Key Words: Pancreas; Surgery; Laparoscopic; Minimally invasive; Pancreatectomy; Whipple's; Pancreaticoduodenectomy

©The Author(s) 2021. Published by Baishideng Publishing Group Inc. All rights reserved.

Core Tip: The published data generally support the use of the minimally invasive approach for surgery on the pancreas. However, it has been under-utilized in the Caribbean because both minimally invasive surgery and service centralization for pancreatic surgery are in their infancy in the Caribbean. Only 3.25 Laparoscopic distal pancreatectomies are performed per annum across the entire region. In this paper we explore the obstacles to incorporating a minimally invasive service for pancreatic surgery.

Citation: Cawich SO, Kluger MD, Francis W, Deshpande RR, Mohammed F, Bonadie KO, Thomas DA, Pearce NW, Schroepe BA. Review of minimally invasive pancreas surgery and opinion on its incorporation into low volume and resource poor centres. *World J Gastrointest Surg* 2021; 13(10): 1122-1135

URL: <https://www.wjgnet.com/1948-9366/full/v13/i10/1122.htm>

DOI: <https://dx.doi.org/10.4240/wjgs.v13.i10.1122>

INTRODUCTION

Surgeons across the globe embraced minimally invasive surgery (MIS) by the end of the 20th century, but pancreatic surgery was one of the last frontiers for its application. Many factors make laparoscopic pancreatic surgery difficult: The organ is deep in the retroperitoneum, attached to the duodenum, intimately related to large mesenteric vessels and draped by viscera. In addition, its soft glandular consistency and its ability to fibrose surrounding tissues in the setting of pathology make it a treacherous contender for laparoscopy.

An additional consideration is the fact that multiple studies demonstrated that patient safety and outcomes are better when pancreatic operations are performed in high volume centers by specialized surgical teams[1,2]. This limits the experience with laparoscopic pancreatic surgery to a small cadre of institutions, mostly in high-income, resource-rich countries. In this paper, we review the evolution of minimally invasive pancreatic surgery and discuss our experience incorporating this into low-volume, resource-poor countries such as those in the Caribbean.

LITERATURE REVIEW

The first report of a laparoscopic operation on the pancreas was published by Gagner *et al*[3] who completed a pancreaticoduodenectomy (PD) in 1994. Their operation was complicated by a jejunal ulcer, delayed gastric emptying and a prolonged 30-d post-operative hospitalization, forcing the authors to conclude that "although technically feasible, the laparoscopic Whipple procedure did not improve the postoperative outcome or shorten the postoperative recovery"[1]. It was interesting that Gagner and Pomp chose this operation for their initial attempt at laparoscopic pancreatic surgery, considering that a

PD is longer and technically more complex than left-sided resections.

Most of the subsequent reports in the 1990's focused on laparoscopic distal pancreatectomies (LDP), demonstrating that it was feasible for benign endocrine lesions and chronic pancreatitis[4-11]. By the end of the 20th century, it appeared that laparoscopy was being seriously entertained for benign pancreatic diseases. In 1998, Cuschieri *et al* [11] wrote "*laparoscopic distal pancreatic resections have been entirely favorable, with benefit to the patient in terms of postoperative recovery, minimal morbidity and short hospital stay*". And in 1999, Park *et al*[10] stated that "*patients appear to benefit from laparoscopic distal pancreatic resections.*"

MINIMALLY INVASIVE DISTAL PANCREATECTOMY

In the first decade of the 21st century, more robust publications began to appear proving that LDP was feasible, technically reproducible and accompanied by encouraging short-term outcomes[12-18]. One decade later, sufficient data had accumulated to allow large meta-analyses[19-21].

Venkat *et al*[19] published a meta-analysis in 2012 that compared LDP and open distal pancreatectomy (ODP) in 1814 patients across 18 studies. They demonstrated that both techniques had similar operative times, margin positivity, postoperative pancreatic fistula and mortality, but LDP brought statistically significant reductions in blood loss, hospital stay, overall morbidity and surgical site infection. Venkat *et al*[19] wrote that the "*improved complication profile of LDP, taken together with the lack of compromise of margin status, suggests that this technique is a reasonable approach in selected cancer patients.*"

In 2013 Nakamura *et al*[20] published a meta-analysis of 2904 distal pancreatectomies across 24 studies. Compared with ODP, LDP showed statistically significant reductions in blood loss, transfusion requirements, wound infection rates, morbidity rates and hospitalization. Based on this, Nakamura *et al*[20] wrote "*LDP showed significantly better perioperative outcomes and is a reasonable operative method for benign tumors and some ductal carcinomas in the pancreas*".

Riviere *et al*[21] then published a 2016 Cochrane Database Systematic Review that compared ODP and LDP in 1576 patients. They noted that hospital stay was 2.43 d shorter in the laparoscopic group, but lamented that existing data were from observational and case-control studies with confounders that did not allow definitive conclusions. Riviere *et al*[21] called for prospective randomized trials to evaluate this further. The Dutch Pancreatic Cancer Group responded and published results of the LEOPARD trial in 2019 that randomized patients to LDP or ODP, blinding patients with a large abdominal dressing[22]. In this trial, patients who had LDP had statistically significant reductions in the time to functional recovery (4 d *vs* 6 d), operative blood loss (150 mL *vs* 400 mL) and incidence of delayed gastric emptying (6% *vs* 20%). They also had better quality of life after LDP. Although the time to complete LDP was significantly longer (217 min *vs* 179 min), it did not increase the overall cost of care.

The data in support of LDP continued to accrue, but as laparoscopic surgeons pushed the boundaries of pancreatic surgery another development occurred simultaneously. The approval of Intuitive's DaVinci surgical robot by the United States Food and Drug Administration (FDA) in the year 2000[23] ushered in the robotic surgical revolution. In 2003, Melvin *et al*[24] published a report of the first robotic distal pancreatectomy (RDP) and this was followed by a publication from Guilianotti *et al*[25] in 2003 documenting 13 robotic pancreatic operations (among a series of 193 varied robotic operations) that included 5 RDPs and 8 robotic-assisted pancreaticoduodenectomy (RPDs). They reported good outcomes with RDP, with 270 min operating time, 20% overall morbidity and no mortality. Within a few years, the robotic approach became popular in resource-rich countries and small RDP series with good results were published[26-29].

Within a decade, sufficient data were accrued to allow meta-analyses to be performed[30-35]. The first was published by Gavrilidis *et al*[30] in 2016 and compared RDP *vs* LDP in 637 patients across 9 studies. They found no significant difference in operative time, conversions, grade B-C pancreatic fistula, morbidity, spleen preservation, perioperative mortality or R0 surgical margins. There was a reduction in hospitalization by one day when patients underwent RDP, but this was countered by significantly increased readmission rates. Therefore, Gavrilidis *et al*[30] concluded that both were reasonable techniques with similar feasibility, safety and oncological adequacy.

In 2017, Huang *et al*[31] compared LDP and RDP in more than 1100 patients across 9 studies and found no difference in operating time, conversions, pancreatic fistulae, spleen preservation, transfusion rates or post-operative hospitalization between the two approaches. Huang *et al*[31] also concluded that RDP was a “safe and effective alternative”.

In 2017, Guerrini *et al*[32] compared RDP and LDP in a metaanalysis of 813 patients across 10 studies. They were able to show definite advantages for RDP, with significantly greater spleen preservation, less conversions and shorter hospitalization. Although there was greater higher cost associated with RDP, Guerrini *et al*[32] concluded that RDP was “safe and comparable to LDP” and suggested that the increase in cost was balanced by the improved peri-operative profile.

In 2019, Gavriilidis *et al*[33] published an updated metaanalysis comparing the oncological adequacy and efficacy between RDP, LDP and ODP in 6796 patients across 36 studies. Both RDP and LDP brought significantly less blood loss, shorter length of stay and better R0 margins compared to open surgery. When they compared LDP and RDP directly, RDP had lower conversion rates, reduced blood loss and shorter hospital stay. In their conclusion, however, they acknowledged that the data were “underpowered and did not permit conclusions about oncological safety for pancreatic adenocarcinoma.”

Hu *et al*[34] published another metaanalysis comparing RDP and LDP across 22 studies in 2020. In this study, robotic surgery significantly increased spleen preservation, reduced conversions and shortened hospitalization, at the expense of increased cost. There were no differences in blood loss, overall morbidity, node harvest, transfusions, grade B-C pancreatic fistula, margin positivity or mortality. Hu *et al*[34] concluded that “both RDP and LDP are safe and feasible alternatives” and suggested that the advantages of RDP balanced the increase in cost.

Finally, in 2020 Zhou *et al*[35] compared RDP and ODP in 2264 patients in a metaanalysis of 7 studies. They demonstrated that RDP significantly reduced blood loss, transfusion rates, postoperative mortality and length of hospital stay. There was no difference in operating time, node harvest, margin positivity, spleen preservation, severe morbidity or grade B-C pancreatic fistula between the groups. They concluded that RDP was a “safe and feasible alternative in centers with expertise in robotic surgery.”

It appears that within the first two decades of the 21st century, there was a rapid swing of the pendulum, moving from open to laparoscopic to robotic distal pancreatectomy. Indeed, the conclusions of early authors seem to have been dismissed and many now propound LDP as standard of care, and RDP as a safe and feasible alternative. While the qualities of a surgical robot (better 3-dimensional visualization, tremor filtration, motion scaling, improved ergonomics and better freedom of motion) appear attractive compared to conventional laparoscopy, the exorbitant cost is prohibitive even in the health care systems of high-income economies. Many developing countries are not able to afford the high cost, and in the English-speaking Caribbean there are no surgical robots available for use.

MINIMALLY INVASIVE WHIPPLE'S PD

Although LDP gained footing in the late 1990s, there was reluctance to embrace laparoscopy for PD. In 1998 Cuschieri *et al*[11] wrote “the experience with laparoscopic PD has been unfavorable. With the current technology, the laparoscopic approach for this procedure is too prolonged and does not seem to offer any benefit to the patient.” Similarly, in 1999 Parks *et al*[10] wrote that “patients benefit from laparoscopic distal pancreatic resection but not from laparoscopic PD”. And in 2001, Gentileschi *et al*[12] wrote that laparoscopic PD “is not associated with patient benefit and may be accompanied by increased morbidity.” The general theme during the late 1990s was to dissuade the surgical community in its pursuit of minimally invasive PD.

The turn of the 21st century saw publication of small series demonstrating that LPD was technically feasible and associated with reasonable short-term outcomes[36,37]. And by the second decade of the 21st century there were increasing numbers of larger, more robust studies comparing LPD and open pancreaticoduodenectomy (OPD) being published[38-49]. Most publications reported significantly longer operating time[20,42,43] and increased cost[20,39,41-43]. But the data supported LPD by showing benefit with significantly reduced post-operative pain[42], quicker return of bowel function[42], reduced overall morbidity[43], shorter high dependency unit or intensive care unit (HDU/ICU) stay[38,40], shorter hospitalization[38,39,42,43] and lower blood loss[20,38,39,43]. It is clear that within 2 decades most authors adopted conclusions that

were opposite to those in the late 1990s[42-49].

Although there now seemed to be a general embrace of the minimally invasive approach, the Dutch LEOPARD trials[50] mounted a challenge. The Dutch LEOPARD trial was a multi-centre randomized blinded trial that randomized 99 patients to OPD or LPD[50]. The surgeons in this trial were highly skilled pancreatic surgeons who had to complete at least 20 LPDs in an approved training programme before they participated in the study. Patients who underwent LPD had a trend toward greater 90-d mortality (10% *vs* 2%; $P = 0.02$; RR 4.9; 95%CI: 0.59-40.4), but no difference in median time to functional recovery (10 d *vs* 8 d; 95%CI: 7-9), no difference in major morbidity (50% *vs* 39%; RR 1.29; 95%CI: 0.82-2.02; $P = 0.26$) and no difference in grade B/C pancreatic fistula (28% *vs* 24%; RR 1.14; 95%CI: 0.59-2.22; $P = 0.69$). Although there was no statistically significant difference between the two groups, the study was concluded early based on the rationale that the findings were “unexpected and worrisome, especially in the setting of trained surgeons working in centres performing 20 or more pancreatoduodenectomies annually.”

But before consensus was achieved, the direction again shifted soon after the FDA approval of Intuitive’s DaVinci surgical robot[23]. Guilianotti *et al*[25] in 2003 published the first series of 193 robotic operations that included 8 RPDs. Within a few years, RPD gained traction in resource-rich countries and their outcomes data were published[30,47,48,51]. Four authors attempted to collectively evaluate the existing data in meta-analyses to compare the robotic approach with OPD[52-55].

Peng *et al*[52] reported on a meta-analysis of 435 patients undergoing OPD *vs* 245 undergoing RPD across 9 non-randomized studies. Patients in the RPD group had significantly lower overall morbidity, significantly better R0 margin clearance, lower surgical site infections and a shorter duration of post-operative hospital stay. This was achieved without any difference in operation time, node harvest, pancreatic fistulae or mortality. Peng *et al*[52] concluded that RPD was safe and efficient, but noted that multi-centre randomized, controlled trials were lacking.

Zhao *et al*[53] published a meta-analysis that compared RPD (assisted) and OPD across 11 non-randomized controlled trials. The robotic approach had longer operative times, but was accompanied by statistically significant reductions in blood loss, surgical site infections, R1 margin involvement, overall morbidity and time to return of post-operative activity. Compared to OPD, there was equivalent lymph node harvest, post-operative pancreatic fistula, hospitalization and mortality rates. Zhao *et al*[53] concluded that RPD is a “safe and feasible alternative to OPD with regard to perioperative outcomes. However, due to the lack of high-quality randomized controlled trials, the evidence is still limited”.

Shin *et al*[54] published a systematic review comparing RPD or LPD and OPD. Both techniques had similar oncologic outcomes, but the robotic approach had significantly longer operative times, less intraoperative blood loss and shorter hospital stay. Shin *et al*[54] concluded that RPD was “feasible and oncologically safe”, but lamented the paucity of robust data.

Podda *et al*[55] published the most recent metanalysis to date compared 1593 patients who underwent RPD to 12046 patients who underwent OPD across 18 non-randomized studies. They found that both techniques had similar outcomes in mortality, overall morbidity, post-operative pancreatic fistula rates, haemorrhage, bile leaks, nodal harvest and positive margin status. While RPD did require significantly longer operating time (461 min *vs* 384 min), it did have the advantage of significantly lower operative blood loss (174 mL *vs* 352 mL). Based on this, Podda *et al*[55] concluded that RPD was a “safe and feasible alternative” to open surgery.

Simultaneously, two meta-analyses evaluated the existing data to compare the robotic and laparoscopic approaches to PD[47,56]. In 2014 Boggi *et al*[47] published a systematic review of 746 LPDs done across 25 published articles. These included pure laparoscopic (386), robot assisted (243), laparoscopic assisted (121) and hand-assisted (5) cases. Interestingly, they were able to show that pure LPD was associated with a significant reduction in operative time, blood loss and pancreatic fistulae *vs* cases completed with laparoscopic assistance and robotic assistance.

Kamarajah *et al*[56] published a metanalysis comparing outcomes in 2437 patients undergoing LPD and 1025 patients undergoing RPD across 44 studies. They noted that RPD was associated with significantly less conversions, lower transfusion requirements and shorter post-operative hospitalization (11 d *vs* 12 d). But there was no difference in blood loss, (220 mL *vs* 287 mL), operating time (405 min *vs* 418 min), overall morbidity, pancreatic fistula or margin involvement. Kamarajah *et al*[56] noted that RPD did have advantages, but the data was limited and so had to be considered to “offerequivalent clinical outcomes.”

In summary, it appears that there was a similar swing of the pendulum for PD from open to laparoscopic and robotic approaches, although the movement took longer to gain momentum. Although some authors have documented good outcome data in select patients at experienced centres, most agree that minimally invasive PD, whether purely laparoscopic, hybrid (laparoscopic dissection with open or robotic reconstruction) or wholly robotic, remain in the hands of experienced pancreatic surgeons in high-volume centers.

CARIBBEAN EXPERIENCE

Although the first reports of laparoscopy in the Anglophone Caribbean date back to 1991 with a cholecystectomy in Trinidad & Tobago, MIS remained relatively dormant and did not gain traction in the Caribbean until 2005[57]. As it relates to service centralization, regional referral centers for pancreatic diseases in the Caribbean were only established in 2010 under the auspices of the Caribbean Chapter of the Americas Hepatopancreaticobiliary Association (AHPBA)[58]. Therefore, a situation exists where both centralization for pancreatic surgery and the minimally invasive surgical revolution are in their infancy in the Caribbean.

The surgeons attached to the pancreatic referral centers all completed formal fellowship training at high-volume hospitals in Canada (4), the United Kingdom (1) and India (1). In these centers they gained sufficient experience to overcome learning curves for the full range of open pancreatic operations and select minimally invasive operations[58]. It is important to appreciate that these training centers all ran accredited fellowships in hepatopancreaticobiliary surgery, but they were high-volume hospitals that operated in different healthcare environments. Although the local surgeons generally surpassed their learning curves, they repatriated to the resource-poor settings with many challenges: scarce blood products, high competition for ICU/HDU beds, an undersupply of consumables and referral bias. Consequently, pancreatic operations are still performed at low volumes in the region. To illustrate this point, consider data from the largest Caribbean hepatopancreatobiliary referral center in Trinidad & Tobago, where only 12.8 pancreaticoduodenectomies were performed annually[58]. This falls short of the “high-volume” mark of 15-20 procedures generally quoted in the medical literature[1,2]. Pancreatic operations outside of these centers are performed in very small volumes by general surgeons with even less experience in pancreatic surgery and with varied MIS exposure.

Although the surgeons in regional referral centers received sufficient exposure during fellowship training to overcome the learning curve for LDP, LPD was not performed regularly during their training[58]. Consequently, LPD is not popular in the region. To date there have only been one published case report of totally LPD[59] and three (un-published) laparoscopic-assisted PDs performed in Trinidad & Tobago. Otherwise, the reports of minimally invasive pancreatic surgery in the Anglophone Caribbean have been limited to three small series of laparoscopic distal pancreatectomies[57,60,61] and two reports of laparoscopic cysto-gastrostomy[62,63]. Up to the year 2021, there were no surgical robots in any English-speaking Caribbean country.

Unpublished data from the registry maintained by the Caribbean Chapter of the AHPBA revealed that only 13 LDPs were performed over the four-year period between January 1, 2014 and December 30, 2017 for trauma (2), adenocarcinoma (2), neuroendocrine tumours (3) and Frantz tumours (3). Generally, the small numbers (3.25 distal pancreatectomies annually) are reflective of low case volumes in the Caribbean. It is hoped that the volumes will increase once the centralization concept is embraced and there is continued progress in MIS in the region. In the region, we experience obstacles that are similar to other developing countries that wish to commence minimally invasive pancreatic surgery: (1) scarce consumables for MIS surgery; (2) lack of universal health insurance for Caribbean populations; (3) paucity of operating list time; (4) limited ICU/HDU space; and (5) poor attitudes toward MIS[58].

Despite the existing challenges, we believe that LDP is an operation that can be done with minimal consumables and in similar time to the open approach. It is attractive to healthcare administrators because it can prevent lengthy hospitalizations, thereby saving limited resources. An intermediate MIS surgeon should have safe dissection skills (since there are no anastomoses) and sufficient familiarity with the instrumentation to make this a feasible operation to integrate in to a resource-limited environment.

Therefore, for the remainder of this paper, we focus on LDP, cystogastrostomy and enucleations because we believe these are realistic operations to be learned and

practiced in developing countries. The authors advocate these as the initial operations to be introduced in expanding MIS programs because it does not require specialized instruments, does not require a keen grasp of intracorporeal suturing and treats that part of the pancreas that is most maneuverable and easiest to control if hemorrhage were to occur.

TECHNICAL ASPECTS

Surgeons seeking to incorporate minimally invasive pancreatic surgery into their practice should be intimately familiar with pancreatic anatomy as well as common anatomic variants. Facility with laparoscopic foregut surgery is an advantage when beginning, including appreciation of optimal patient positioning, port placement, intracorporeal suturing skills and proficiency with laparoscopic ultrasonography. We advocate for a team-based approach, where an advanced laparoscopic surgeon is paired with an experienced pancreatic surgeon. The authors also suggest mastery of the operations in a step-wise fashion, starting with completing the simpler dissections initially and gradually rising to the most difficult step (Figure 1). Initial un-proctored exposure should aim for the most straightforward anatomy possible, and as the learning curve levels off, more challenging cases can be attempted. Finally, there should be no shame or bruised ego when conversion to an open procedure is required as patient welfare and oncologic principles must come first.

Patient selection

Because the pancreas is a retroperitoneal organ, patients with lower body mass index, less visceral fat and no previous abdominal operations are more straightforward laparoscopic candidates. At the same time, thin or short patients may present the surgeon with diminished working space. As skill and comfort develops, less ideal patients can be considered. Of course, a patient with compromised pulmonary mechanics or severe acid-base disorders may not be the best choice for a prolonged laparoscopic procedure, where CO₂ retention can be considerable.

Favorable lesions include those located toward the pancreatic tail, requiring less retroperitoneal dissection and laying comfortably away from major vascular structures (celiac trunk, superior mesenteric artery, inferior mesenteric vein, superior mesenteric and portal veins). Benign diseases tend to result in easier dissection planes, as do small neuroendocrine lesions. In contrast, “benign” acute or chronic pancreatitis may present obscure tissue planes and rock-hard fibrosis making dissection exceedingly challenging. Malignant lesions also can range in the spectrum from small tumors with minimal desmoplastic reaction to large immobile tumors which obscure a laparoscopic camera view.

Distal pancreatectomies are the most straightforward cases to integrate, especially where instrumentation, personnel and operative time may be limited. When the surgeon is prepared to tackle more complex cases, patient selection is again paramount. Even many experienced laparoscopic or robotic surgeons will not plan a minimally invasive approach for lesions that abut or invade major vascular structures.

Patient positioning and trocar placement

Careful patient positioning is a critical step for successful minimally invasive pancreatectomy. The first consideration is where the operating surgeon will stand. To perform a distal (left-sided) pancreatectomy, the surgeon may either stand to the patient’s right side or between the legs in a modified lithotomy position. A surgeon performing midline (central) pancreatectomy or pancreaticoduodenectomy may be better served standing between split legs or on the patient’s left side. Steep reverse Trendelenberg position is useful to allow viscera to fall, facilitating exposure of the lesser sac. To ensure patient safety, footboards should be in place and safety straps should be used to prevent slipping. An electric operating table is useful (but not essential) to provide lateral tilt for gravity-assisted retraction of viscera.

Optimal trocar placement relies on the principle of triangulation, where the visual access, operator and assistant are arranged in a triangle centered on the target pathology; the pathology should be considered the apex of a diamond with the instruments as the remaining three points. Thus, in a left upper quadrant procedure, one or two working trocars should be midline/right abdomen, the viewing port left mid-abdomen, and a retraction port left lateral abdomen. However, a large pannus often distorts anatomy, with the umbilicus far more caudad, so the trocars may be better positioned more cephalad than external landmarks indicate. Handedness of the

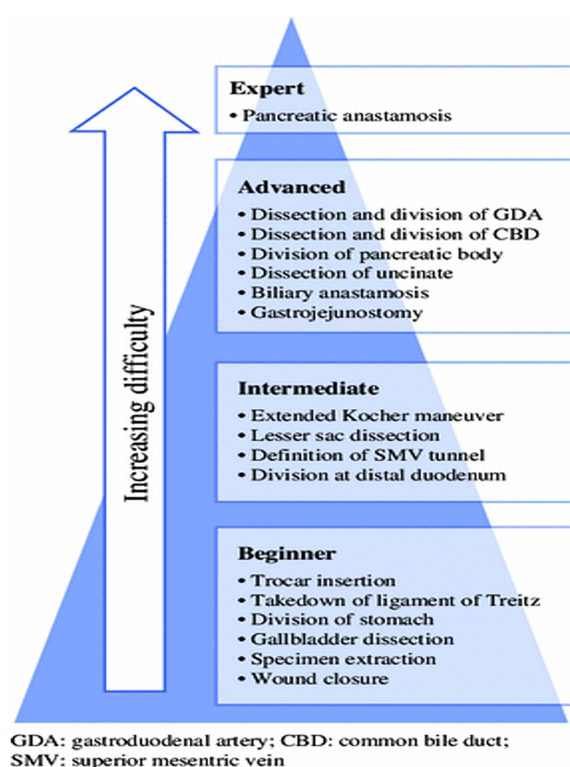


Figure 1 Learning curve pyramid illustrating the suggested mastery of pancreatic operations in a step-wise fashion, starting with simpler dissections initially and gradually rising to the most difficult operations. Citation: Speicher PJ, Nussbaum DP, White RR, Zani S, Mosca PJ, Blazer DG 3rd, Clary BM, Pappas TN, Tyler DS, Perez A. Defining the learning curve for team-based laparoscopic pancreaticoduodenectomy. *Ann Surg Oncol* 2014; 21(12): 4014-4019. Copyright © Speicher PJ *et al* 2014. Published by Springer Nature[74].

operating surgeon may also play a role in trocar position and size. The size of the trocars depends on the instruments used; often the authors will start with all 5 mm trocars and upsize when it is clear where the stapler, suturing device or extraction site will be best positioned. Most of the dissection can be done with 5 mm instruments and energy devices. All trocars are typically placed off midline for these cases; the umbilical trocar used for appendectomy or cholecystectomy is rarely needed.

Technical aspects of dissection including instrumentation

There are many types of laparoscopic instruments available, and surgeons should accumulate a representative selection for the task at hand. We typically use 30 angled laparoscopes and pneumoperitoneum pressures ranging from 12-15 mmHg, depending on body habitus and respiratory physiology.

Atraumatic graspers should be used to grasping bowel and stomach. Note that most pancreata are fragile and should not be grasped, but rather nudged or held by surrounding fatty tissue. Finer dissectors, either needle-nosed, round-nosed or curved, can be used for blunt dissection and one might consider a few bariatric length instruments for use on the proximal short gastric vascular bundles and around the spleen. Fine electrocautery tips or hooks are handy tools for rendering hemostasis on raw surfaces. Energy instruments are useful for hemostatic peripancreatic dissection and the surgeon should ultimately choose ones they are comfortable with, remaining aware of the capabilities and precautions of each.

As with the energy devices, the surgeon should choose the stapling device they wish to use based on: what is available in their setting, one that they are comfortable with, that is easy for them to handle and fire, and reasonable for the operating room staff to load. One prerequisite is that the stapler should be able to articulate and rotate, as the retroperitoneal space does not offer much flexibility for stapler positioning. Prolonged compression before slow firing may aid in hemostasis and has even been proposed as a maneuver to decrease the incidence of pancreatic leaks[64,65]. Buttress materials for staplers are also available, and there is data suggesting that they decrease the incidence of pancreatic fistula[66]. We advocate using different staple heights based on the types of tissues and texture of the pancreas, though we acknowledge that there is no data to guide this. For very thick pancreata, we prefer to transect with energy devices and suture the duct because a stapled closure may not be robust. In

fact, in some cases the stapler may not even close over the organ or it may fracture the gland[67,68]. This technique may be feasible for low resource centres where staplers are not readily available.

Intracorporeal suturing is one of the more challenging minimally invasive skills to acquire. Therefore, laparoscopically assisted dissection and resection can be considered followed by a mini-laparotomy for the reconstruction. Alternatively, there are several enabling devices available to facilitate suturing such as Endo360 (Endoevolution, LLC, Raynam, MA, United States) or EndoStitch (Covidien Ltd, Minneapolis, MN, United States) devices. As a note, it also takes practice to master these instruments so the surgeon should make an individualized decision on their use, weighing the instrument capabilities and cost with free hand suturing.

Exposure of the pancreas

We were being by using an energy device to open the gastrocolic ligament in an avascular plane, preserving the gastroepiploic vessels along the greater curvature of stomach. If there is an option to preserve the spleen, the short gastric vascular bundles should be preserved as long as possible to allow a Warshaw-type spleen preservation if the main splenic artery and vein need to be sacrificed[69]. If splenectomy is planned or visualization is poor, the short gastric vascular bundles can be divided early. There are often adhesions between the pancreas and the posterior stomach to the pancreas that can be safely divided with energy. The stomach will then need to be retracted to expose the pancreas and this can be achieved either with laparoscopic self-retaining retractors or using a marionette technique to suspending it with sutures placed along the posterior gastric body and exiting through the abdominal wall[70]. This allows the surgeon and assistant to use both hands for the operation.

Dissection of the body and tail of the gland from the retroperitoneum

As the pancreas is often a soft and fragile organ, grasping it should be kept to a minimum, if at all. One may consider placing a small gauze sponge inside the abdomen, for quick access in case unexpected bleeding is encountered or as a gentle retractor held by another instrument. We usually start the pancreatic dissection 2 cm proximal to the intended resection margin, or at the superior mesenteric vein for formal distal pancreatectomy, by lifting the inferior edge using gentle, blunt dissection aided by energy devices as needed. The objective is to make a tunnel behind the pancreas from caudad to cephalad direction. The surgeon must heed the splenic vein, especially during the initial exposure, taking care to avoid direct application of energy to this large vein. The splenic artery is usually easy to separate from the gland, but the splenic vein is not and it is laden with many tiny branches all along the pancreas. Proper identification of the origin of the splenic artery as well as the common hepatic and left gastric branches is critical for dissections near the neck of the gland. We find an articulating instrument such as an esophageal dissector to be useful when creating the retro-pancreatic tunnel and then we routinely pass an umbilical tape through the tunnel to allow retraction and facilitate further dissection.

Division of the pancreas

There is no reconstruction required in LDP so the surgeon aims to divide with an intention to seal. This can be achieved by linear stapling, with or without buttress material, or by dividing with an energy device followed by suturing the cut edge. In a recent multi-institutional retrospective study of fistula after distal pancreatectomy, none of the following operative techniques independently affected the occurrence of fistulae: method of pancreas transection, suture ligation of the pancreatic duct, staple size, the use of staple line reinforcement, tissue patches, biologic sealants, or prophylactic octreotide[71]. Although the study was primarily (70%) comprised of open cases, there is no reason to expect differences for a minimally invasive approach.

Suturing

This is generally more straightforward when suturing mobile organs on mesenteries (stomach, bowel), but becomes increasingly difficult when mobility is limited. And that is compounded when suturing small, fragile pancreatic and bile ducts. To add an extra layer of complexity, many of the previously mentioned suture-assist devices are not well-suited for these anastomoses. The small, straight needles used in these devices are inappropriate for securing a thick pancreas margin, or for passing through fragile pancreatic tissue for a pancreatic anastomosis. Similarly, barbed sutures are generally too traumatic for soft pancreata. Realistically, minimally invasive surgeons intending to perform a pancreatic anastomosis must be practiced in intracorporeal

suturing and knot-tying with conventional curved needles. The choice of suture (monofilament *vs* braided, absorbable *vs* nonabsorbable) and technique (running *vs* interrupted) can mirror the surgeon's choice in open surgery.

PROCEDURES

Pancreatic tumor enucleation

Well-chosen tumor enucleations may be excellent cases to start with during the initial minimally invasive experience. Generally, these are small (< 2 cm), tumors with well-defined borders, in the body and tail of the pancreas. In addition, a reasonable distance from the pancreatic duct (at least 2 mm) is suggested to avoid duct disruption, either directly during dissection or postoperatively due to duct ischemia. The pancreas may not need to be mobilized much, if at all for anterior lesions. Visible lesions are simpler to extract; those requiring ultrasound guidance require a slightly greater degree of sophistication and comfort with the technology. After the tumor is removed the magnification afforded by laparoscopy is excellent to survey the pancreatic bed for evidence of ductal disruption and for hemostasis. In the absence of intra-operative ultrasound, these procedures should be avoided because determination of distance from the main pancreatic duct cannot be determined increasing the risk of pancreatic leak and complications, as in general, enucleations have the highest risk of fistula.

Distal pancreatectomy

Much of the technique for distal pancreatectomy without reconstruction has been reviewed in the previous sections. Splenic preservation should always be considered for benign lesions by either technique: splenic artery and vein preservation (Kimura technique) or maintenance of the short gastric vessels and transection of the splenic artery and vein (Warshaw technique)[69,72,73].

Drainage of symptomatic pancreatic pseudocysts—cystogastrostomy, cystenterostomy

Acute pancreatitis is common, and endoscopic drainage through a transoral route is rarely possible outside of dedicated centers. Large, well-formed pancreatic pseudocysts can interfere in recovery from acute pancreatitis, causing pain and poor oral intake. In these delicate patients, an open operation can cause considerable physiologic stress and delayed healing. A cyst posterior to the stomach can be an excellent opportunity to enlist laparoscopy. The abdomen is explored laparoscopically and an anterior gastrostomy created with diathermy, attending to hemostasis as varices may be present if the splenic vein is thrombosed. If ultrasonography is available, an optimal location for cystogastrostomy can be determined by placing the probe on the posterior gastric wall anterior to the cyst. Otherwise, the cyst is punctured at a point of bulging through the posterior gastric wall to confirm cyst location. Again, attending to hemostasis as varices may be present, the posterior gastric wall is incised with diathermy approximately 2-4 cm until the inside of the cyst can be visualized. Then using endovascular staplers with staple height depending on wall thickness, a stapled, hemostatic anastomosis is created between the posterior gastric and anterior cyst walls. Any debris should be aspirated. The anterior wall of the stomach is stapled closed. In the absence of staplers, the cysto-gastrostomy anastomosis and anterior gastrotomy can be sewn. For large symptomatic cysts not aligned with the stomach, a Roux-en-Y cyst-enterostomy can be created by anastomosing the drainage limb to the pseudocyst. This can be done with staplers or suture, but clearly requires more advanced laparoscopic skills than that for cysto-gastrostomy.

Drainage procedures for chronic pancreatitis—Frey, Puestow

Similarly, the drainage procedures involve a pancreatic anastomosis to a Roux limb of jejunum. The conditions necessitating such procedures often render the gland very firm and fibrotic—delightful to manipulate, but challenging for suture placement with the laparoscopic needle drivers. The length of the instrument is mechanically not favorable to grab on to the needle if too much force is required to pass it through tissue. Little experience is reported on these cases.

CONCLUSION

With minimally invasive pancreatic surgery, one should aim for a better operation that results in less morbidity and improved survival with lesser importance to the abdominal access method or shortening the hospital stay. That being said, more and broader experience with minimally invasive techniques in pancreatic surgery will determine the future of this modality. Despite low pancreatic case volume in the Caribbean, and financial barriers to MIS in general, laparoscopic distal pancreatectomy, enucleation and cystogastrostomy are feasible operations to integrate in to a resource-limited healthcare environment. This is because they can be performed with minimal to no consumables and require an intermediate MIS skillset to complement an open pancreatic surgeon's peri-operative experience.

REFERENCES

- Schmidt CM, Turrini O, Parikh P, House MG, Zyromski NJ, Nakeeb A, Howard TJ, Pitt HA, Lillemoe KD. Effect of hospital volume, surgeon experience, and surgeon volume on patient outcomes after pancreaticoduodenectomy: a single-institution experience. *Arch Surg* 2010; **145**: 634-640 [PMID: 20644125 DOI: 10.1001/archsurg.2010.118]
- Ahola R, Sand J, Laukkarinen J. Centralization of Pancreatic Surgery Improves Results: Review. *Scand J Surg* 2020; **109**: 4-10 [PMID: 31969066 DOI: 10.1177/1457496919900411]
- Gagner M, Pomp A. Laparoscopic pylorus-preserving pancreatoduodenectomy. *Surg Endosc* 1994; **8**: 408-410 [PMID: 7915434 DOI: 10.1007/BF00642443]
- Cuschieri A. Laparoscopic Pancreatic Resections. *Semin Laparosc Surg* 1996; **3**: 15-20 [PMID: 10401098 DOI: 10.1053/SLAS00300015]
- Sussman LA, Christie R, Whittle DE. Laparoscopic excision of distal pancreas including insulinoma. *Aust N Z J Surg* 1996; **66**: 414-416 [PMID: 8678863 DOI: 10.1111/j.1445-2197.1996.tb01222.x]
- Gagner M, Pomp A, Herrera MF. Early experience with laparoscopic resections of islet cell tumors. *Surgery* 1996; **120**: 1051-1054 [PMID: 8957494 DOI: 10.1016/s0039-6060(96)80054-7]
- Tihanyi TF, Morvay K, Nehéz L, Wintemitz T, Rusz Z, Flautner LE. Laparoscopic distal resection of the pancreas with the preservation of the spleen. *Acta Chir Hung* 1997; **36**: 359-361 [PMID: 9408401]
- Vezakis A, Davides D, Larvin M, McMahon MJ. Laparoscopic surgery combined with preservation of the spleen for distal pancreatic tumors. *Surg Endosc* 1999; **13**: 26-29 [PMID: 9869683 DOI: 10.1007/s004649900891]
- Matsumoto T, Kitano S, Yoshida T, Bandoh T, Kakisako K, Ninomiya K, Tsuboi S, Baatar D. Laparoscopic resection of a pancreatic mucinous cystadenoma using laparoscopic coagulating shears. *Surg Endosc* 1999; **13**: 172-173 [PMID: 9918625 DOI: 10.1007/s004649900933]
- Park A, Schwartz R, Tandan V, Anvari M. Laparoscopic pancreatic surgery. *Am J Surg* 1999; **177**: 158-163 [PMID: 10204562 DOI: 10.1016/s0002-9610(98)00325-0]
- Cuschieri SA, Jakimowicz JJ. Laparoscopic pancreatic resections. *Semin Laparosc Surg* 1998; **5**: 168-179 [PMID: 9787203 DOI: 10.1177/155335069800500303]
- Gentileschi P, Gagner M. Laparoscopic pancreatic resection. *Chir Ital* 2001; **53**: 279-289 [PMID: 11452812]
- Patterson EJ, Gagner M, Salky B, Inabnet WB, Brower S, Edye M, Gurland B, Reiner M, Pertsemlides D. Laparoscopic pancreatic resection: single-institution experience of 19 patients. *J Am Coll Surg* 2001; **193**: 281-287 [PMID: 11548798 DOI: 10.1016/s1072-7515(01)01018-3]
- Fabre JM, Dulucq JL, Vacher C, Lemoine MC, Wintringer P, Nocca D, Burgel JS, Domergue J. Is laparoscopic left pancreatic resection justified? *Surg Endosc* 2002; **16**: 1358-1361 [PMID: 11984672 DOI: 10.1007/s00464-001-9206-3]
- Shimizu S, Tanaka M, Konomi H, Mizumoto K, Yamaguchi K. Laparoscopic pancreatic surgery: current indications and surgical results. *Surg Endosc* 2004; **18**: 402-406 [PMID: 14735345 DOI: 10.1007/s00464-003-8164-3]
- Lebedev A, Zmora O, Kuriansky J, Rosin D, Khaikin M, Shabtai M, Ayalon A. Laparoscopic distal pancreatectomy. *Surg Endosc* 2004; **18**: 1427-1430 [PMID: 15791363 DOI: 10.1007/s00464-003-8221-y]
- Root J, Nguyen N, Jones B, McCloud S, Lee J, Nguyen P, Chang K, Lin P, Imagawa D. Laparoscopic distal pancreatic resection. *Am Surg* 2005; **71**: 744-749 [PMID: 16468510]
- Mabrut JY, Fernandez-Cruz L, Azagra JS, Bassi C, Delvaux G, Weerts J, Fabre JM, Boulez J, Baulieux J, Peix JL, Gigot JF; Hepatobiliary and Pancreatic Section (HBPS) of the Royal Belgian Society of Surgery; Belgian Group for Endoscopic Surgery (BGES); Club Coelio. Laparoscopic pancreatic resection: results of a multicenter European study of 127 patients. *Surgery* 2005; **137**: 597-605 [PMID: 15962401 DOI: 10.1016/j.surg.2005.02.002]
- Venkat R, Edil BH, Schulick RD, Lidor AO, Makary MA, Wolfgang CL. Laparoscopic distal pancreatectomy is associated with significantly less overall morbidity compared to the open technique: a systematic review and meta-analysis. *Ann Surg* 2012; **255**: 1048-1059 [PMID: 22511003 DOI: 10.1097/SLA.0b013e318251ee09]

- 20 **Nakamura M**, Nakashima H. Laparoscopic distal pancreatectomy and pancreaticoduodenectomy: is it worthwhile? *J Hepatobiliary Pancreat Sci* 2013; **20**: 421-428 [PMID: [23224732](#) DOI: [10.1007/s00534-012-0578-7](#)]
- 21 **Riviere D**, Gurusamy KS, Kooby DA, Vollmer CM, Besselink MG, Davidson BR, van Laarhoven CJ. Laparoscopic versus open distal pancreatectomy for pancreatic cancer. *Cochrane Database Syst Rev* 2016; **4**: CD011391 [PMID: [27043078](#) DOI: [10.1002/14651858.CD011391.pub2](#)]
- 22 **de Rooij T**, van Hilst J, van Santvoort H, Boerma D, van den Boezem P, Daams F, van Dam R, Dejong C, van Duyn E, Dijkgraaf M, van Eijck C, Festen S, Gerhards M, Groot Koerkamp B, de Hingh I, Kazemier G, Klaase J, de Kleine R, van Laarhoven C, Luyer M, Patijn G, Steenvoorde P, Suker M, Abu Hilal M, Busch O, Besselink M; Dutch Pancreatic Cancer Group. Minimally Invasive Versus Open Distal Pancreatectomy (LEOPARD): A Multicenter Patient-blinded Randomized Controlled Trial. *Ann Surg* 2019; **269**: 2-9 [PMID: [30080726](#) DOI: [10.1097/SLA.0000000000002979](#)]
- 23 **Shah J**, Vyas A, Vyas D. The History of Robotics in Surgical Specialties. *Am J Robot Surg* 2014; **1**: 12-20 [PMID: [26677459](#) DOI: [10.1166/ajrs.2014.1006](#)]
- 24 **Melvin WS**, Needleman BJ, Krause KR, Ellison EC. Robotic resection of pancreatic neuroendocrine tumor. *J Laparoendosc Adv Surg Tech A* 2003; **13**: 33-36 [PMID: [12676019](#) DOI: [10.1089/109264203321235449](#)]
- 25 **Giulianotti PC**, Coratti A, Angelini M, Sbrana F, Cecconi S, Balestracci T, Caravaglios G. Robotics in general surgery: personal experience in a large community hospital. *Arch Surg* 2003; **138**: 777-784 [PMID: [12860761](#) DOI: [10.1001/archsurg.138.7.777](#)]
- 26 **Suman P**, Rutledge J, Yiengpruksawan A. Robotic distal pancreatectomy. *JSLs* 2013; **17**: 627-635 [PMID: [24398207](#) DOI: [10.4293/108680813X13794522667409](#)]
- 27 **Giulianotti PC**, Sbrana F, Bianco FM, Elli EF, Shah G, Addeo P, Caravaglios G, Coratti A. Robot-assisted laparoscopic pancreatic surgery: single-surgeon experience. *Surg Endosc* 2010; **24**: 1646-1657 [PMID: [20063016](#) DOI: [10.1007/s00464-009-0825-4](#)]
- 28 **Goh BK**, Chan CY, Soh HL, Lee SY, Cheow PC, Chow PK, Ooi LL, Chung AY. A comparison between robotic-assisted laparoscopic distal pancreatectomy versus laparoscopic distal pancreatectomy. *Int J Med Robot* 2017; **13** [PMID: [26813478](#) DOI: [10.1002/rcs.1733](#)]
- 29 **Waters JA**, Canal DF, Wiebke EA, Dumas RP, Beane JD, Aguilar-Saavedra JR, Ball CG, House MG, Zyromski NJ, Nakeeb A, Pitt HA, Lillemoe KD, Schmidt CM. Robotic distal pancreatectomy: cost effective? *Surgery* 2010; **148**: 814-823 [PMID: [20797748](#) DOI: [10.1016/j.surg.2010.07.027](#)]
- 30 **Gavriliadis P**, Lim C, Menahem B, Lahat E, Salloum C, Azoulay D. Robotic versus laparoscopic distal pancreatectomy - The first meta-analysis. *HPB (Oxford)* 2016; **18**: 567-574 [PMID: [27346136](#) DOI: [10.1016/j.hpb.2016.04.008](#)]
- 31 **Huang B**, Feng L, Zhao J. Systematic review and meta-analysis of robotic versus laparoscopic distal pancreatectomy for benign and malignant pancreatic lesions. *Surg Endosc* 2016; **30**: 4078-4085 [PMID: [26743110](#) DOI: [10.1007/s00464-015-4723-7](#)]
- 32 **Guerrini GP**, Lauretta A, Belluco C, Olivieri M, Forlin M, Basso S, Breda B, Bertola G, Di Benedetto F. Robotic versus laparoscopic distal pancreatectomy: an up-to-date meta-analysis. *BMC Surg* 2017; **17**: 105 [PMID: [29121885](#) DOI: [10.1186/s12893-017-0301-3](#)]
- 33 **Gavriliadis P**, Roberts KJ, Sutcliffe RP. Comparison of robotic vs laparoscopic vs open distal pancreatectomy. A systematic review and network meta-analysis. *HPB (Oxford)* 2019; **21**: 1268-1276 [PMID: [31080086](#) DOI: [10.1016/j.hpb.2019.04.010](#)]
- 34 **Hu YH**, Qin YF, Yu DD, Li X, Zhao YM, Kong DJ, Jin W, Wang H. Meta-analysis of short-term outcomes comparing robot-assisted and laparoscopic distal pancreatectomy. *J Comp Eff Res* 2020; **9**: 201-218 [PMID: [31975614](#) DOI: [10.2217/cer-2019-0124](#)]
- 35 **Zhou J**, Lv Z, Zou H, Xiong L, Liu Z, Chen W, Wen Y. Up-to-date comparison of robotic-assisted versus open distal pancreatectomy: A PRISMA-compliant meta-analysis. *Medicine (Baltimore)* 2020; **99**: e20435 [PMID: [32501990](#) DOI: [10.1097/MD.00000000000020435](#)]
- 36 **Staudacher C**, Orsenigo E, Baccari P, Di Palo S, Crippa S. Laparoscopic assisted duodenopancreatectomy. *Surg Endosc* 2005; **19**: 352-356 [PMID: [15627172](#) DOI: [10.1007/s00464-004-9055-y](#)]
- 37 **Dulucq JL**, Wintringer P, Mahajna A. Laparoscopic pancreaticoduodenectomy for benign and malignant diseases. *Surg Endosc* 2006; **20**: 1045-1050 [PMID: [16736311](#) DOI: [10.1007/s00464-005-0474-1](#)]
- 38 **Khaled YS**, Fatania K, Barrie J, De Liguori N, Deshpande R, O'Reilly DA, Ammori BJ. Matched Case-Control Comparative Study of Laparoscopic Versus Open Pancreaticoduodenectomy for Malignant Lesions. *Surg Laparosc Endosc Percutan Tech* 2018; **28**: 47-51 [PMID: [28212257](#) DOI: [10.1097/SLE.0000000000000381](#)]
- 39 **Croome KP**, Farnell MB, Que FG, Reid-Lombardo KM, Truty MJ, Nagorney DM, Kendrick ML. Total laparoscopic pancreaticoduodenectomy for pancreatic ductal adenocarcinoma: oncologic advantages over open approaches? *Ann Surg* 2014; **260**: 633-8; discussion 638 [PMID: [25203880](#) DOI: [10.1097/SLA.0000000000000937](#)]
- 40 **Hakeem AR**, Verbeke CS, Cairns A, Aldouri A, Smith AM, Menon KV. A matched-pair analysis of laparoscopic versus open pancreaticoduodenectomy: oncological outcomes using Leeds Pathology Protocol. *Hepatobiliary Pancreat Dis Int* 2014; **13**: 435-441 [PMID: [25100130](#) DOI: [10.1016/s1499-3872\(14\)60048-5](#)]
- 41 **Croome KP**, Farnell MB, Que FG, Reid-Lombardo KM, Truty MJ, Nagorney DM, Kendrick ML.

- Pancreaticoduodenectomy with major vascular resection: a comparison of laparoscopic versus open approaches. *J Gastrointest Surg* 2015; **19**: 189-94; discussion 194 [PMID: [25274069](#) DOI: [10.1007/s11605-014-2644-8](#)]
- 42 **Tan CL**, Zhang H, Peng B, Li KZ. Outcome and costs of laparoscopic pancreaticoduodenectomy during the initial learning curve vs laparotomy. *World J Gastroenterol* 2015; **21**: 5311-5319 [PMID: [25954105](#) DOI: [10.3748/wjg.v21.i17.5311](#)]
 - 43 **Chen S**, Chen JZ, Zhan Q, Deng XX, Shen BY, Peng CH, Li HW. Robot-assisted laparoscopic versus open pancreaticoduodenectomy: a prospective, matched, mid-term follow-up study. *Surg Endosc* 2015; **29**: 3698-3711 [PMID: [25761559](#) DOI: [10.1007/s00464-015-4140-y](#)]
 - 44 **Wang M**, Zhang H, Wu Z, Zhang Z, Peng B. Laparoscopic pancreaticoduodenectomy: single-surgeon experience. *Surg Endosc* 2015; **29**: 3783-3794 [PMID: [25783837](#) DOI: [10.1007/s00464-015-4154-5](#)]
 - 45 **Paniccia A**, Schulick RD, Edil BH. Total Laparoscopic Pancreaticoduodenectomy: A Single-Institutional Experience. *Ann Surg Oncol* 2015; **22**: 4380-4381 [PMID: [25893407](#) DOI: [10.1245/s10434-015-4450-2](#)]
 - 46 **Gumbs AA**, Rodriguez Rivera AM, Milone L, Hoffman JP. Laparoscopic pancreatoduodenectomy: a review of 285 published cases. *Ann Surg Oncol* 2011; **18**: 1335-1341 [PMID: [21207166](#) DOI: [10.1245/s10434-010-1503-4](#)]
 - 47 **Boggi U**, Amorese G, Vistoli F, Caniglia F, De Lio N, Perrone V, Barbarello L, Belluomini M, Signori S, Mosca F. Laparoscopic pancreaticoduodenectomy: a systematic literature review. *Surg Endosc* 2015; **29**: 9-23 [PMID: [25125092](#) DOI: [10.1007/s00464-014-3670-z](#)]
 - 48 **Liao CH**, Wu YT, Liu YY, Wang SY, Kang SC, Yeh CN, Yeh TS. Systemic Review of the Feasibility and Advantage of Minimally Invasive Pancreaticoduodenectomy. *World J Surg* 2016; **40**: 1218-1225 [PMID: [26830906](#) DOI: [10.1007/s00268-016-3433-1](#)]
 - 49 **Chen K**, Liu XL, Pan Y, Maher H, Wang XF. Expanding laparoscopic pancreaticoduodenectomy to pancreatic-head and periampullary malignancy: major findings based on systematic review and meta-analysis. *BMC Gastroenterol* 2018; **18**: 102 [PMID: [29969999](#) DOI: [10.1186/s12876-018-0830-y](#)]
 - 50 **van Hilst J**, de Rooij T, Bosscha K, Brinkman DJ, van Dieren S, Dijkgraaf MG, Gerhards MF, de Hingh IH, Karsten TM, Lips DJ, Luyer MD, Busch OR, Festen S, Besselink MG; Dutch Pancreatic Cancer Group. Laparoscopic versus open pancreatoduodenectomy for pancreatic or periampullary tumours (LEOPARD-2): a multicentre, patient-blinded, randomised controlled phase 2/3 trial. *Lancet Gastroenterol Hepatol* 2019; **4**: 199-207 [PMID: [30685489](#) DOI: [10.1016/S2468-1253\(19\)30004-4](#)]
 - 51 **Zhao Z**, Yin Z, Hang Z, Ji G, Feng Q, Zhao Q. A systemic review and an updated meta-analysis: minimally invasive vs open pancreaticoduodenectomy. *Sci Rep* 2017; **7**: 2220 [PMID: [28533536](#) DOI: [10.1038/s41598-017-02488-4](#)]
 - 52 **Peng L**, Lin S, Li Y, Xiao W. Systematic review and meta-analysis of robotic versus open pancreaticoduodenectomy. *Surg Endosc* 2017; **31**: 3085-3097 [PMID: [27928665](#) DOI: [10.1007/s00464-016-5371-2](#)]
 - 53 **Zhao W**, Liu C, Li S, Geng D, Feng Y, Sun M. Safety and efficacy for robot-assisted versus open pancreaticoduodenectomy and distal pancreatectomy: A systematic review and meta-analysis. *Surg Oncol* 2018; **27**: 468-478 [PMID: [30217304](#) DOI: [10.1016/j.suronc.2018.06.001](#)]
 - 54 **Shin SH**, Kim YJ, Song KB, Kim SR, Hwang DW, Lee JH, Park KM, Lee YJ, Jun E, Kim SC. Totally laparoscopic or robot-assisted pancreaticoduodenectomy versus open surgery for periampullary neoplasms: separate systematic reviews and meta-analyses. *Surg Endosc* 2017; **31**: 3459-3474 [PMID: [28039645](#) DOI: [10.1007/s00464-016-5395-7](#)]
 - 55 **Podda M**, Gerardi C, Di Saverio S, Marino MV, Davies RJ, Pellino G, Pisanu A. Robotic-assisted versus open pancreaticoduodenectomy for patients with benign and malignant periampullary disease: a systematic review and meta-analysis of short-term outcomes. *Surg Endosc* 2020; **34**: 2390-2409 [PMID: [32072286](#) DOI: [10.1007/s00464-020-07460-4](#)]
 - 56 **Kamarajah SK**, Bundred J, Marc OS, Jiao LR, Manas D, Abu Hilal M, White SA. Robotic versus conventional laparoscopic pancreaticoduodenectomy a systematic review and meta-analysis. *Eur J Surg Oncol* 2020; **46**: 6-14 [PMID: [31409513](#) DOI: [10.1016/j.ejso.2019.08.007](#)]
 - 57 **Cawich SO**, Pooran S, Amow B, Ali E, Mohammed F, Mencia M, Ramsewak S, Hariharan S, Naraynsingh V. Impact of a medical university on laparoscopic surgery in a service-oriented public hospital in the Caribbean. *Risk Manag Healthc Policy* 2016; **9**: 253-260 [PMID: [27895521](#) DOI: [10.2147/RMHP.S89724](#)]
 - 58 **Francis W**, Arra A, Bonadie KO, Cawich SO. Evolution of Liver and Pancreas Surgical Sub-Specialty in the Caribbean: Caribbean Chapter of the Americans Hepatopancreatobiliary Association. *J Carib Coll Surg* 2021; **1**: 51-54
 - 59 **Singh Y**, Cawich SO, Mohammed S, Kuruvilla T, Naraynsingh V. Totally Laparoscopic Whipple's Operation: Initial Report from the Caribbean. *Cureus* 2020; **12**: e7401 [PMID: [32337127](#) DOI: [10.7759/cureus.7401](#)]
 - 60 **Dan D**, Rambally R, Cawich SO, Maharaj R, Naraynsingh V. Solid pseudopapillary neoplasms of the pancreas: a report of two cases. *Case Rep Med* 2014; **2014**: 356379 [PMID: [24982677](#) DOI: [10.1155/2014/356379](#)]
 - 61 **Cawich SO**, Ledesma Z, Sampath L, Sandy S. Clinicopathologic features of solid pseudopapillary pancreatic neoplasms in an Eastern Caribbean population. *Trop Doct* 2018; **48**: 224-227 [PMID: [29198177](#) DOI: [10.1177/0049475517744961](#)]
 - 62 **Cawich SO**, Murphy T, Shah S, Barrow P, Arthurs M, Ramdass MJ, Johnson PB. Endoscopic transmural drainage of pancreatic pseudocysts: technical challenges in the resource poor setting. *Case*

- Rep Gastrointest Med* 2013; **2013**: 942832 [PMID: [24377052](#) DOI: [10.1155/2013/942832](#)]
- 63 **Singh Y**, Cawich SO, Olivier L, Kuruvilla T, Mohammed F, Naraysingh V. Pancreatic pseudocyst: combined single incision laparoscopic cystogastrostomy and cholecystectomy in a resource poor setting. *J Surg Case Rep* 2016; **2016** [PMID: [27803243](#) DOI: [10.1093/jscr/rjw176](#)]
- 64 **Ariyaratnam AV**, Bunting D, Aroori S. Laparoscopic Distal Pancreatectomy Using the Modified Prolonged Prefiring Compression Technique Reduces Pancreatic Fistula. *J Laparoendosc Adv Surg Tech A* 2015; **25**: 821-825 [PMID: [26394027](#) DOI: [10.1089/lap.2015.0200](#)]
- 65 **Nakamura M**, Ueda J, Kohno H, Aly MY, Takahata S, Shimizu S, Tanaka M. Prolonged peri-firing compression with a linear stapler prevents pancreatic fistula in laparoscopic distal pancreatectomy. *Surg Endosc* 2011; **25**: 867-871 [PMID: [20730447](#) DOI: [10.1007/s00464-010-1285-6](#)]
- 66 **Kurahara H**, Maemura K, Mataka Y, Sakoda M, Iino S, Hiwatashi K, Ishigami S, Ueno S, Shinchi H, Natsugoe S. Closure of the pancreas in distal pancreatectomy: comparison between bare stapler and reinforced stapler. *Hepatogastroenterology* 2014; **61**: 2367-2370 [PMID: [25699384](#)]
- 67 **Sugimoto M**, Gotohda N, Kato Y, Takahashi S, Kinoshita T, Shibasaki H, Nomura S, Konishi M, Kaneko H. Risk factor analysis and prevention of postoperative pancreatic fistula after distal pancreatectomy with stapler use. *J Hepatobiliary Pancreat Sci* 2013; **20**: 538-544 [PMID: [23430057](#) DOI: [10.1007/s00534-013-0596-0](#)]
- 68 **Kawai M**, Tani M, Okada K, Hirono S, Miyazawa M, Shimizu A, Kitahata Y, Yamaue H. Stump closure of a thick pancreas using stapler closure increases pancreatic fistula after distal pancreatectomy. *Am J Surg* 2013; **206**: 352-359 [PMID: [23806829](#) DOI: [10.1016/j.amjsurg.2012.11.023](#)]
- 69 **Warshaw AL**. Conservation of the spleen with distal pancreatectomy. *Arch Surg* 1988; **123**: 550-553 [PMID: [3358679](#) DOI: [10.1001/archsurg.1988.01400290032004](#)]
- 70 **Hsu KF**, Liu TP, Yu JC, Chen TW, Shih ML, Ou KL, Chen CJ, Chan DC, Hsieh CB. Application of marionette technique for 3-port laparoscopic liver resection. *Surg Laparosc Endosc Percutan Tech* 2012; **22**: e186-e189 [PMID: [22874696](#) DOI: [10.1097/SLE.0b013e318256b6e4](#)]
- 71 **Ecker BL**, McMillan MT, Allegrini V, Bassi C, Beane JD, Beckman RM, Behrman SW, Dickson EJ, Callery MP, Christein JD, Drebin JA, Hollis RH, House MG, Jamieson NB, Javed AA, Kent TS, Kluger MD, Kowalsky SJ, Maggino L, Malleo G, Valero V 3rd, Velu LKP, Watkins AA, Wolfgang CL, Zureikat AH, Vollmer CM Jr. Risk Factors and Mitigation Strategies for Pancreatic Fistula After Distal Pancreatectomy: Analysis of 2026 Resections From the International, Multi-institutional Distal Pancreatectomy Study Group. *Ann Surg* 2019; **269**: 143-149 [PMID: [28857813](#) DOI: [10.1097/SLA.0000000000002491](#)]
- 72 **Kimura W**, Inoue T, Futakawa N, Shinkai H, Han I, Muto T. Spleen-preserving distal pancreatectomy with conservation of the splenic artery and vein. *Surgery* 1996; **120**: 885-890 [PMID: [8909526](#) DOI: [10.1016/s0039-6060\(96\)80099-7](#)]
- 73 **Nakata K**, Shikata S, Ohtsuka T, Ukai T, Miyasaka Y, Mori Y, Velasquez VVDM, Gotoh Y, Ban D, Nakamura Y, Nagakawa Y, Tanabe M, Sahara Y, Takaori K, Honda G, Misawa T, Kawai M, Yamaue H, Morikawa T, Kuroki T, Mou Y, Lee WJ, Shrikhande SV, Tang CN, Conrad C, Han HS, Chinnusamy P, Asbun HJ, Kooby DA, Wakabayashi G, Takada T, Yamamoto M, Nakamura M. Minimally invasive preservation versus splenectomy during distal pancreatectomy: a systematic review and meta-analysis. *J Hepatobiliary Pancreat Sci* 2018; **25**: 476-488 [PMID: [29943909](#) DOI: [10.1002/jhbp.569](#)]
- 74 **Speicher PJ**, Nussbaum DP, White RR, Zani S, Mosca PJ, Blazer DG 3rd, Clary BM, Pappas TN, Tyler DS, Perez A. Defining the learning curve for team-based laparoscopic pancreaticoduodenectomy. *Ann Surg Oncol* 2014; **21**: 4014-4019 [PMID: [24923222](#) DOI: [10.1245/s10434-014-3839-7](#)]



Published by **Baishideng Publishing Group Inc**
7041 Koll Center Parkway, Suite 160, Pleasanton, CA 94566, USA

Telephone: +1-925-3991568

E-mail: bpgoffice@wjgnet.com

Help Desk: <https://www.f6publishing.com/helpdesk>

<https://www.wjgnet.com>

