


# World Journal of *Gastrointestinal Surgery*

*World J Gastrointest Surg* 2021 November 27; 13(11): 1293-1522



## Contents

Monthly Volume 13 Number 11 November 27, 2021

## REVIEW

- 1293 Acute appendicitis—advances and controversies  
*Teng TZJ, Thong XR, Lau KY, Balasubramaniam S, Shelat VG*

## MINIREVIEWS

- 1315 Application and progress of medical imaging in total mesopancreas excision for pancreatic head carcinoma  
*Feng P, Cheng B, Wang ZD, Liu JG, Fan W, Liu H, Qi CY, Pan JJ*
- 1327 Retrorectal tumors: A challenge for the surgeons  
*Balci B, Yildiz A, Leventoglu S, Montes B*
- 1338 Surgical ampullectomy: A comprehensive review  
*Scroggie DL, Mavroeidis VK*
- 1351 Is surgery the best treatment for elderly gastric cancer patients?  
*Kawaguchi Y, Akaike H, Shoda K, Furuya S, Hosomura N, Amemiya H, Kawaida H, Kono H, Ichikawa D*

## ORIGINAL ARTICLE

## Case Control Study

- 1361 Nomogram for predicting chylous ascites after right colectomy  
*Zheng HD, Liu YR, Chen ZZ, Sun YF, Xu CH, Xu JH*
- 1372 Comparison of safety, efficacy, and long-term follow-up between “one-step” and “step-up” approaches for infected pancreatic necrosis  
*Zheng Z, Lu JD, Ding YX, Guo YL, Mei WT, Qu YX, Cao F, Li F*

## Retrospective Study

- 1390 Risk of station 12a lymph node metastasis in patients with lower-third gastric cancer  
*Dong YP, Cai FL, Wu ZZ, Wang PL, Yang Y, Guo SW, Zhao ZZ, Zhao FC, Liang H, Deng JY*
- 1405 Choice of operative method for pancreaticojejunostomy and a multivariable study of pancreatic leakage in pancreaticoduodenectomy  
*Liang H, Wu JG, Wang F, Chen BX, Zou ST, Wang C, Luo SW*
- 1414 Laparoscopic vs open surgery in ileostomy reversal in Crohn's disease: A retrospective study  
*Wan J, Yuan XQ, Wu TQ, Yang MQ, Wu XC, Gao RY, Yin L, Chen CQ*

- 1423** Preoperative serum carbohydrate antigen 19-9 levels predict early recurrence after the resection of early-stage pancreatic ductal adenocarcinoma

*Hong S, Song KB, Hwang DW, Lee JH, Lee W, Jun E, Kwon J, Park Y, Park SY, Kim N, Shin D, Kim H, Sung M, Ryu Y, Kim SC*

- 1436** Patients with *Clostridium difficile* infection and prior appendectomy may be prone to worse outcomes

*Shaikh DH, Patel H, Munshi R, Sun H, Meher Shahi S, Baiomi A, Alemam A, Pirzada U, Nawaz I, Naher K, Hanumanthu S, Nayudu S*

### Observational Study

- 1448** Novel roles of lipopolysaccharide and TLR4/NF- $\kappa$ B signaling pathway in inflammatory response to liver injury in Budd-Chiari syndrome

*Li J, Chen XM, Zhou CZ, Fang WW, Lv WF, Cheng DL*

- 1463** Long-term survival of patients with stage II and III gastric cancer who underwent gastrectomy with inadequate nodal assessment

*Desiderio J, Sagnotta A, Terrenato I, Garofoli E, Mosillo C, Trastulli S, Arteritano F, Tozzi F, D'Andrea V, Fong Y, Woo Y, Bracarda S, Parisi A*

- 1484** Defecation disorders are crucial sequelae that impairs the quality of life of patients after conventional gastrectomy

*Nakada K, Ikeda M, Takahashi M, Kinami S, Yoshida M, Uenosono Y, Terashima M, Oshio A, Kodera Y*

### SYSTEMATIC REVIEWS

- 1497** Is omentectomy necessary in the treatment of benign or malignant abdominal pathologies? A systematic review

*Atay A, Dilek ON*

### SCIENTOMETRICS

- 1509** Global trends in research related to sleeve gastrectomy: A bibliometric and visualized study

*Barqawi A, Abushamma FA, Akkawi M, Al-Jabi SW, Shahwan MJ, Jairoun AA, Zyoud SH*

**ABOUT COVER**

Editorial Board Member of *World Journal of Gastrointestinal Surgery*, Ali Coskun, MD, Associate Professor, Doctor, Department of General Surgery, Izmir Bozyaka Training and Research Hospital, Izmir 35380, Turkey. dralicoskun3564@hotmail.com

**AIMS AND SCOPE**

The primary aim of *World Journal of Gastrointestinal Surgery* (WJGS, *World J Gastrointest Surg*) is to provide scholars and readers from various fields of gastrointestinal surgery with a platform to publish high-quality basic and clinical research articles and communicate their research findings online.

WJGS mainly publishes articles reporting research results and findings obtained in the field of gastrointestinal surgery and covering a wide range of topics including biliary tract surgical procedures, biliopancreatic diversion, colectomy, esophagectomy, esophagostomy, pancreas transplantation, and pancreatectomy, etc.

**INDEXING/ABSTRACTING**

The WJGS is now abstracted and indexed in Science Citation Index Expanded (SCIE, also known as SciSearch®), Current Contents/Clinical Medicine, Journal Citation Reports/Science Edition, PubMed, and PubMed Central. The 2021 edition of Journal Citation Reports® cites the 2020 impact factor (IF) for WJGS as 2.582; IF without journal self cites: 2.564; 5-year IF: 3.378; Journal Citation Indicator: 0.53; Ranking: 97 among 212 journals in surgery; Quartile category: Q2; Ranking: 73 among 92 journals in gastroenterology and hepatology; and Quartile category: Q4.

**RESPONSIBLE EDITORS FOR THIS ISSUE**

Production Editor: Rui-Rui Wu, Production Department Director: Xiang Li, Editorial Office Director: Ya-Juan Ma.

**NAME OF JOURNAL**

*World Journal of Gastrointestinal Surgery*

**ISSN**

ISSN 1948-9366 (online)

**LAUNCH DATE**

November 30, 2009

**FREQUENCY**

Monthly

**EDITORS-IN-CHIEF**

Shu-You Peng, Varut Lohsiriwat, Jin Gu

**EDITORIAL BOARD MEMBERS**

<https://www.wjgnet.com/1948-9366/editorialboard.htm>

**PUBLICATION DATE**

November 27, 2021

**COPYRIGHT**

© 2021 Baishideng Publishing Group Inc

**INSTRUCTIONS TO AUTHORS**

<https://www.wjgnet.com/bpg/gerinfo/204>

**GUIDELINES FOR ETHICS DOCUMENTS**

<https://www.wjgnet.com/bpg/gerinfo/287>

**GUIDELINES FOR NON-NATIVE SPEAKERS OF ENGLISH**

<https://www.wjgnet.com/bpg/gerinfo/240>

**PUBLICATION ETHICS**

<https://www.wjgnet.com/bpg/gerinfo/288>

**PUBLICATION MISCONDUCT**

<https://www.wjgnet.com/bpg/gerinfo/208>

**ARTICLE PROCESSING CHARGE**

<https://www.wjgnet.com/bpg/gerinfo/242>

**STEPS FOR SUBMITTING MANUSCRIPTS**

<https://www.wjgnet.com/bpg/gerinfo/239>

**ONLINE SUBMISSION**

<https://www.f6publishing.com>





## Retrorectal tumors: A challenge for the surgeons

Bengi Balci, Alp Yildiz, Sezai Leventoğlu, Bulent Mentec

**ORCID number:** Bengi Balci 0000-0002-0630-5097; Alp Yildiz 0000-0002-6800-138X; Sezai Leventoğlu 0000-0003-0680-0589; Bulent Mentec 0000-0001-6417-8949.

**Author contributions:** Balci B and Yildiz A reviewed the literature; Balci B wrote the manuscript; Yildiz A arranged the figures; Mentec B and Leventoğlu S reviewed and edited the manuscript; all authors read and agreed to the published version of the manuscript.

**Conflict-of-interest statement:** All authors declare having no conflict of interests for this article.

**Country/Territory of origin:** Turkey

**Specialty type:** Gastroenterology and hepatology

**Provenance and peer review:** Invited article; Externally peer reviewed.

**Open-Access:** This article is an open-access article that was selected by an in-house editor and fully peer-reviewed by external reviewers. It is distributed in accordance with the Creative Commons Attribution NonCommercial (CC BY-NC 4.0) license, which permits others to distribute, remix, adapt, build upon this work non-commercially, and license their derivative works on different terms, provided the

**Bengi Balci,** Department of General Surgery, Ankara Oncology Training and Research Hospital, Ankara 06060, Turkey

**Alp Yildiz,** Department of General Surgery, Ankara Yenimahalle Training and Research Hospital, Ankara 06370, Turkey

**Sezai Leventoğlu,** Department of Surgery, Gazi University Medical School, Ankara 06530, Turkey

**Bulent Mentec,** Department of General Surgery, Memorial Ankara Hospital, Ankara 06060, Turkey

**Corresponding author:** Sezai Leventoğlu, MD, Professor, Surgeon, Department of Surgery, Gazi University Medical School, 22 Sokak 26-2 Emek, Ankara 06530, Turkey.

[sezaileventoglu@hotmail.com](mailto:sezaileventoglu@hotmail.com)

### Abstract

Retrorectal or presacral tumors are rare lesions located in the presacral area and considered as being derived from multiple embryological remnants. These tumors are classified as congenital, neurogenic, osseous, inflammatory, or miscellaneous. The most common among these are congenital benign lesions that present with non-specific symptoms, such as lower back pain and change in bowel habit. Although congenital and developmental tumors occur in younger patients, the median age of presentation is reported to be 45 years. Magnetic resonance imaging plays a crucial role in treatment management through accurate diagnosis of the lesion, the evaluation of invasion to adjacent structures, and the decision of appropriate surgical approach. The usefulness of preoperative biopsy is still debated; currently, it is only indicated for solid or heterogeneous tumors if it will alter the treatment management. Surgical resection with clear margins is considered the optimal treatment; described approaches are transabdominal, perineal, combined abdominoperineal, and minimally invasive. Benign retrorectal tumors have favorable long-term outcomes with a low incidence of recurrence, whereas malignant tumors have a potential for distant organ metastasis in addition to local recurrence.

**Key Words:** Retrorectal tumors; Congenital cystic lesions; Teratomas; Perineal approach; Transabdominal approach; Combined abdominoperineal approach

©The Author(s) 2021. Published by Baishideng Publishing Group Inc. All rights reserved.

original work is properly cited and the use is non-commercial. See: <http://creativecommons.org/licenses/by-nc/4.0/>

**Received:** February 21, 2021

**Peer-review started:** February 21, 2021

**First decision:** July 16, 2021

**Revised:** July 26, 2021

**Accepted:** September 22, 2021

**Article in press:** September 22, 2021

**Published online:** November 27, 2021

**P-Reviewer:** Bogach J, Bustamante-Lopez LA, Piozzi GN, Sano W

**S-Editor:** Fan JR

**L-Editor:** A

**P-Editor:** Wu RR



**Core Tip:** With advances in imaging modalities and increased clinicians' awareness, the diagnosis of a retrorectal tumor has been improving over the years. This review article discusses the epidemiology, classification and suggested diagnostic methods, with current treatment options mostly focusing on surgical approaches and follow-up recommendations, for patients with retrorectal tumors.

**Citation:** Balci B, Yildiz A, Leventoglu S, Montes B. Retrorectal tumors: A challenge for the surgeons. *World J Gastrointest Surg* 2021; 13(11): 1327-1337

**URL:** <https://www.wjgnet.com/1948-9366/full/v13/i11/1327.htm>

**DOI:** <https://dx.doi.org/10.4240/wjgs.v13.i11.1327>

## INTRODUCTION

Retrorectal or presacral tumors are extremely rare. Although their true incidence in the general population is unknown, it has been reported that the number of patients diagnosed yearly with retrorectal tumor is approximately 1-6 in tertiary referral centers and the estimated incidence is 1 in 40,000 hospital admissions[1]. Most of the retrorectal tumors are benign, but malignant cases account for 21%-50% of patients[1, 2].

The retrorectal space is an anatomic area formed by the rectum's posterior wall anteriorly and the sacrum posteriorly. It extends to the peritoneal reflection superiorly and to Waldeyer's fascia inferiorly[3]. The histopathological varieties of retrorectal tumors result from the multiple embryological remnants located in this potential space [4]. Due to their unusual localization and mimicry of symptoms caused by other joint diseases, the diagnosis and treatment of retrorectal tumors are challenging for clinicians[5]. As well, different surgical approaches and procedures are described for these tumors, to provide optimal exposure to the lesional field and decrease postoperative morbidity[6-8].

Herein, we present a comprehensive review of surgical management and share our clinical experiences for retrorectal tumors.

## CLINICAL PRESENTATION AND CLASSIFICATION

Retrorectal tumors are usually asymptomatic lesions (26%-50% of cases), being discovered incidentally on routine digital rectal examination. Symptoms such as sacral pain, constipation, incontinence, and pencil-thin stools usually indicate tumor invasion to adjacent structures[1]. Patients may present with lower back pain that worsens with sitting and is alleviated by walking and standing[4]. Patients who present with recurrent anal fistula and perirectal abscesses should be suspected of retrorectal tumor and subjected to additional imaging studies[9].

Retrorectal tumors are classified based on their origin, namely congenital, neurogenic, osseous, inflammatory, or miscellaneous. Moreover, these tumors can be divided according to the lesions' histopathology, as benign congenital, malignant congenital, benign acquired, and malignant acquired (Table 1)[10,11].

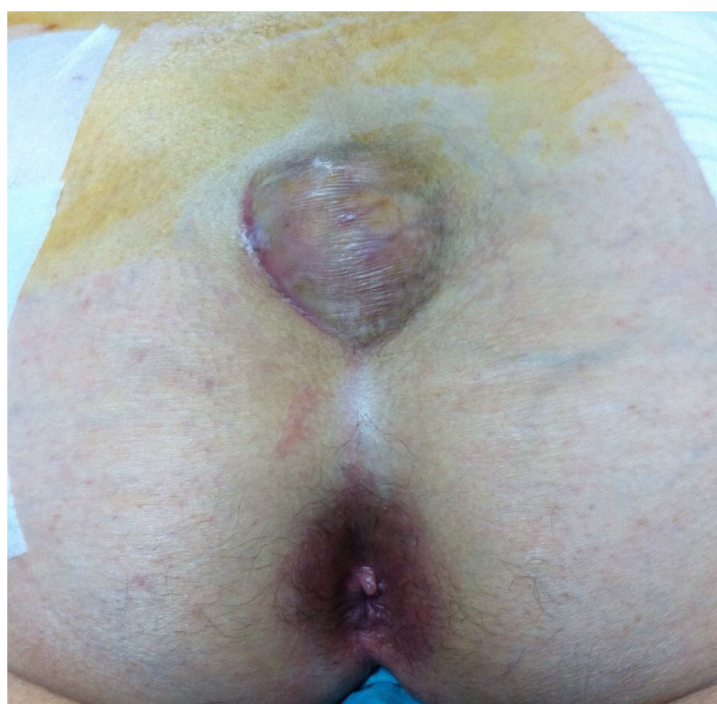### Congenital lesions

The most common type of retrorectal tumor is congenital, of which two-thirds are cystic lesions, such as tail-gut, epidermoid and dermoid cysts[1,4,10]. The incidence of those developmental cysts tends to be higher in females. Although many of them are benign lesions, malignant transformation of tail-gut cysts has also been reported by tertiary centers[12,13]. Epidermoid and dermoid cysts can communicate with skin and present as postanal dimple or sinus, which can be easily misdiagnosed as pilonidal sinus or perirectal abscess (Figures 1 and 2)[14,15].

The risk of malignancy is higher for solid retrorectal tumors, the most common of which are the chordomas[16]. These slow-growing tumors arise from the fetal notochord's vestiges, usually from within the vertebral bodies. Unlike developmental cysts, chordomas are more common in males. Patients with chordomas usually present with urinary or gas incontinence and intensive sacral or perineal pain due to invasion of the adjacent structures. Radical resection is usually required because of the

**Table 1** The classification of retrorectal tumors[10,11]

	Benign	Malignant
Congenital	Developmental cysts (Tail-gut, epidermoid, dermoid, teratoma)	Chordoma
	Anterior sacral meningocele	Teratocarcinoma
	Adrenal rest tumor	
Neurogenic	Schwannoma	Neuroblastoma
	Neurofibroma	Malignant nerve sheath tumors
	Ganglioneuroma	Ganglioneuroblastoma Ependymoma
Osseous	Giant-cell tumor	Osteogenic sarcoma
	Osteoblastoma	Ewing sarcoma
	Aneurysmal bone cyst	Chondrosarcoma
		Myeloma
Inflammatory	Abscess/hematoma	
Miscellaneous	Lipoma	Liposarcoma
	Fibroma	Fibrosarcoma
	Hemangioma	Hemangiopericytoma
	Endothelioma	Leiomyosarcoma
	Leiomyoma	Metastatic carcinoma

**Figure 1** A patient presented with complaints of recurrent fistula, which was ultimately diagnosed as epidermoid cyst.

relatively higher recurrence rates of this type of congenital lesion[17,18].

Teratomas are true neoplasms, that include all three germ layers. They can be solid or cystic, and often contain both components. They are also more common in females and associated with a 40%-50% risk of malignant degeneration in the adult population [19]. In the absence of malignancy, they rarely adhere to the rectum or other adjacent viscera[4].

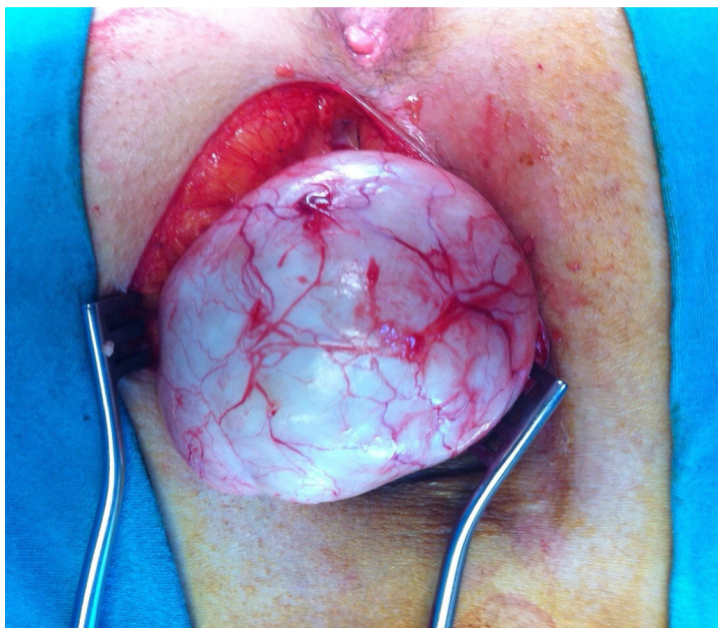


Figure 2 Intraoperative image of the epidermoid cyst.

### **Neurogenic lesions**

Neurogenic tumors are the second most common retrorectal tumors, after congenital lesions. These are slow-growing tumors that typically arise from peripheral nerves, and 85% of them are benign, consisting of neurofibromas and schwannomas[20].

### **Osseous lesions**

Osseous tumors account for 10% of retrorectal tumors and have a high risk of recurrence. These include benign tumors (*i.e.* osteoblastoma, giant-cell tumor) and malignant tumors (*i.e.* Ewing sarcoma, chondrosarcoma, osteogenic sarcoma), which arise from bone, cartilage, fibrous tissue, and marrow[4,21].

### **Inflammatory lesions**

Inflammatory tumors are less common than congenital lesions and are considered secondary reactions to foreign substances left in the body from previous surgeries[22]. It has been reported that they can also result from an extension of infection from either the perirectal space or abdomen[2,6].

### **Miscellaneous lesions**

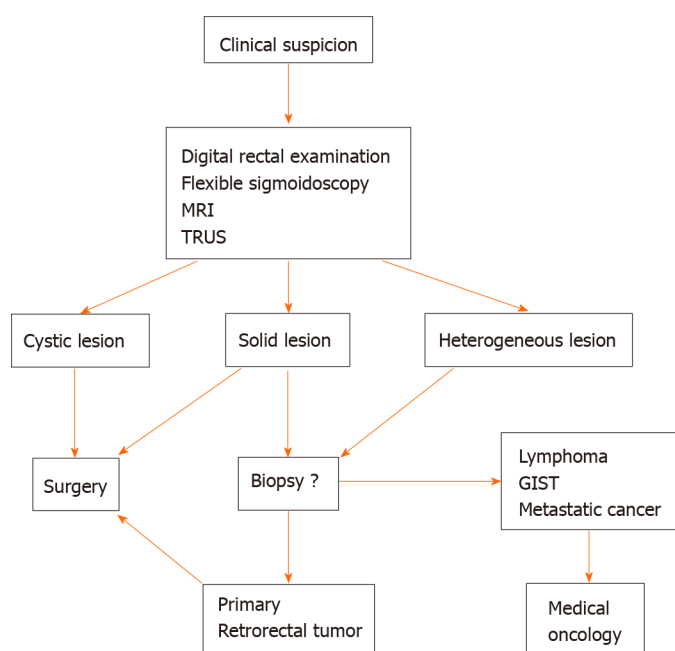
Miscellaneous tumors account for 10%-25% of all retrorectal tumors, including lipoma, fibroma, hemangioma, leiomyoma, and liposarcoma[21]. These lesions can also be a metastasis from primary rectal cancer.

---

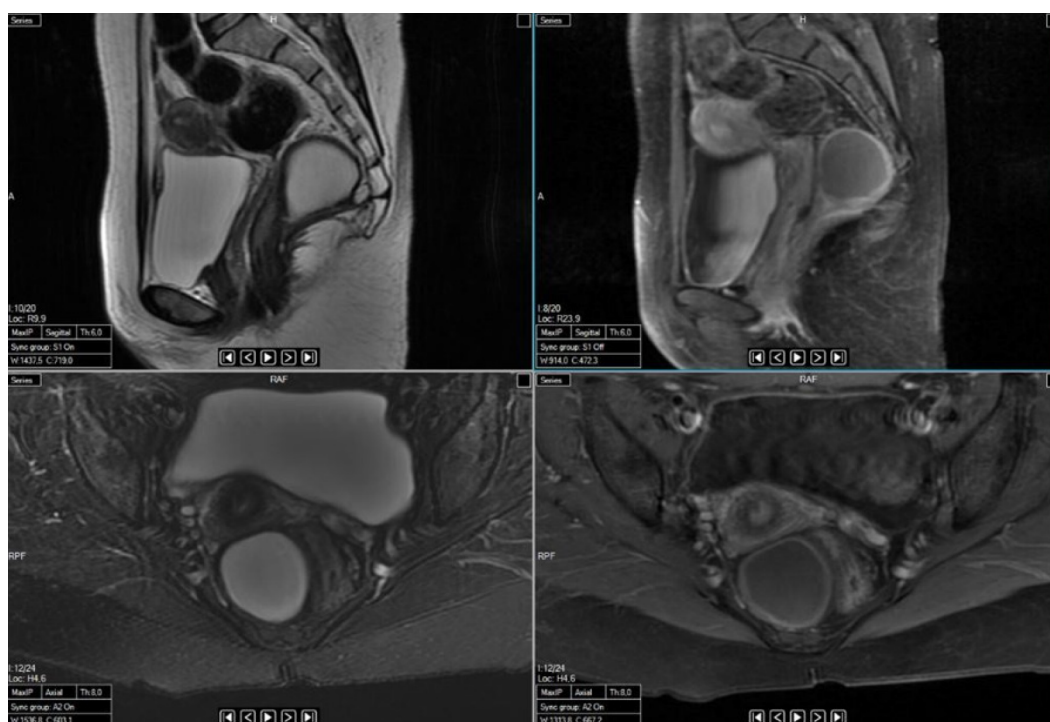
## **DIAGNOSIS**

A careful rectal examination carries the utmost importance for making a diagnosis, accounting for diagnosis in 90% of cases. Unfortunately, unless the physician has a high index of suspicion, these soft and compressible lesions can easily be missed[4]. As such, magnetic resonance imaging (MRI) in conjunction with computed tomography (CT) has emerged as the diagnostic tool of choice (Figure 3)[5]. CT is useful for demonstrating the nature of the lesion (cystic-solid) and bone destruction, whereas MRI is more advanced in evaluating soft tissue and adjacent structures' involvement (Figures 4 and 5)[23]. On MRI, based on the lesion's internal signal characteristics, the lesion is diagnosed as a cystic tumor when it displays cystic elements comprising greater than 80% of the lesion and a solid tumor when the lesion shows solid elements in greater than 80%; the remainder are classified as heterogeneous[6]. Radiological features that indicate malignant lesions are heterogeneous signal intensity, irregular infiltrative margin, sacral destruction or remodeling, and enhancement[24]. MRI also enables the surgical care team to plan for extent of resection (local *vs en bloc*) and





**Figure 3** Flow diagram for the management of retrorectal tumors. MRI: Magnetic resonance imaging; GIST: Gastrointestinal stromal tumor; TRUS: Transrectal ultrasonography.



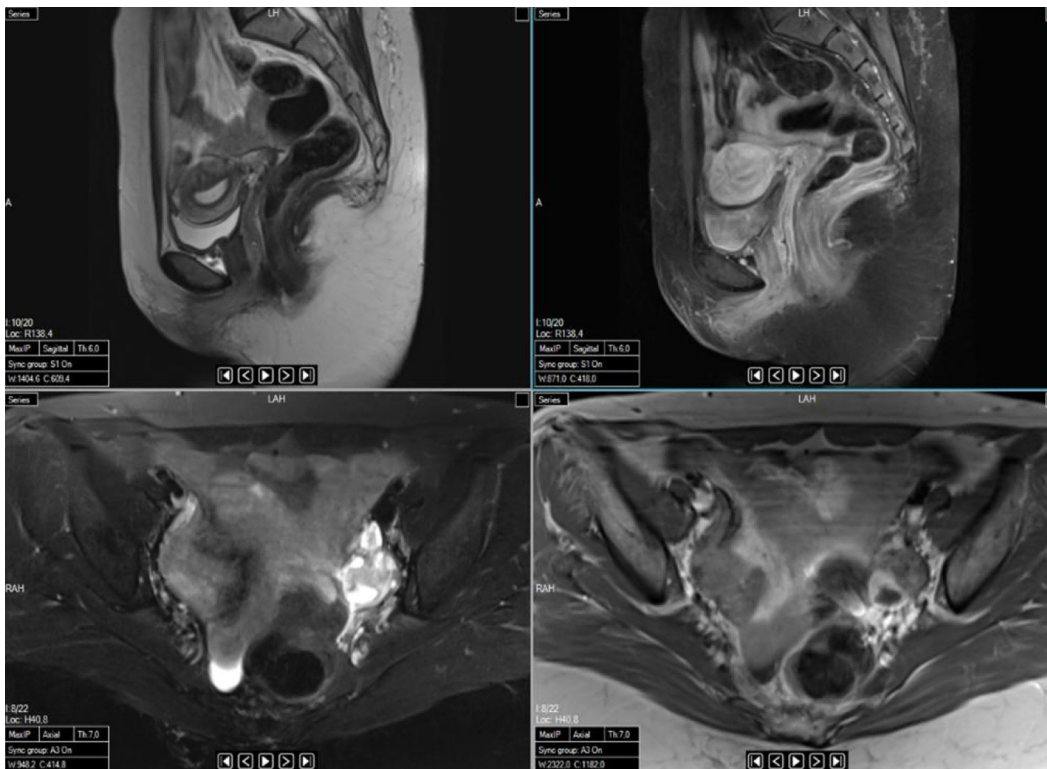
**Figure 4** Sagittal and axial magnetic resonance images showing a cystic teratoma localized in the retrorectal area.

surgical approach (anterior *vs* posterior *vs* combined) in a preoperative setting[22].

Other applicable imaging modalities are flexible sigmoidoscopy, transrectal ultrasonography (TRUS), and fistulograms. The flexible sigmoidoscopy is a newly established option to demonstrate rectal mucosa involvement or exclude a primary rectal cancer, whereas TRUS provides detailed information on the size, consistency of the tumor, and evidence of local invasion[2,5]. Fistulograms can be preferred in patients with a chronically draining sinus, to evaluate underlying pathology such as developmental cyst[21].

Preoperative biopsy has been controversial for retrorectal tumors, according to the potential risk of secondary infection and seeding of the tumor[1,8,21]. With the





**Figure 5** Sagittal and axial magnetic resonance images taken after resectioning the cystic teratoma shown in Figure 4.

advances in imaging modalities and improved neoadjuvant therapy options that have become available in recent years, it has become a feasible technique[25]. On the other hand, a preoperative biopsy may lead to misdiagnosis, with a reported rate of incorrect diagnosis as high as 44% [8]. Nevertheless, studies have demonstrated preoperative biopsy to have better diagnostic accuracy in solid or heterogeneous tumors and to affect treatment management[26,27]. Neoadjuvant chemotherapy is essential for some retrorectal tumors, such as Ewing sarcoma and osteogenic sarcoma, or metastatic chordoma, and tyrosine kinase inhibitors have been shown effective in progression-free survival[28-30].

In our clinical practice, if preoperative imaging modalities provide sufficient information regarding the nature of the lesion and if the treatment management will not change according to additional findings, we do not advocate performing a preoperative biopsy. It should be emphasized that if it is indicated, performing biopsies by an experienced radiologist and choosing the appropriate transperineal or parasacral approach have been recommended. However, transperitoneal, transretroperitoneal, transvaginal, and transrectal biopsies should be avoided, and the biopsy tract must be removed *en bloc*[21].

## SURGICAL APPROACH

The optimal management of retrorectal tumors is surgical resection, including of benign tumors, given the potential for developing symptoms and malignancy[2,31,32]. The morphology of tumor determines the level of extension of surgery. Complete gross resection is recommended for benign tumors, whereas radical resection or *en bloc* resection of involved adjacent organs is required for malignant tumors[21]. Surgical approaches include those from the anterior (transabdominal), the combined abdominoperineal, and the posterior (perineal). A general consideration is that an anterior or combined approach is preferred for tumors above the level of S3 and a posterior approach for lesions below the level of S3.

### **Anterior (transabdominal) approach**

The anterior approach is recommended for tumors located above S3 or which show sign(s) of pelvic wall involvement in the preoperative investigation. If the tumor cells have invaded into adjacent structures or an *en bloc* resection for malignant lesions

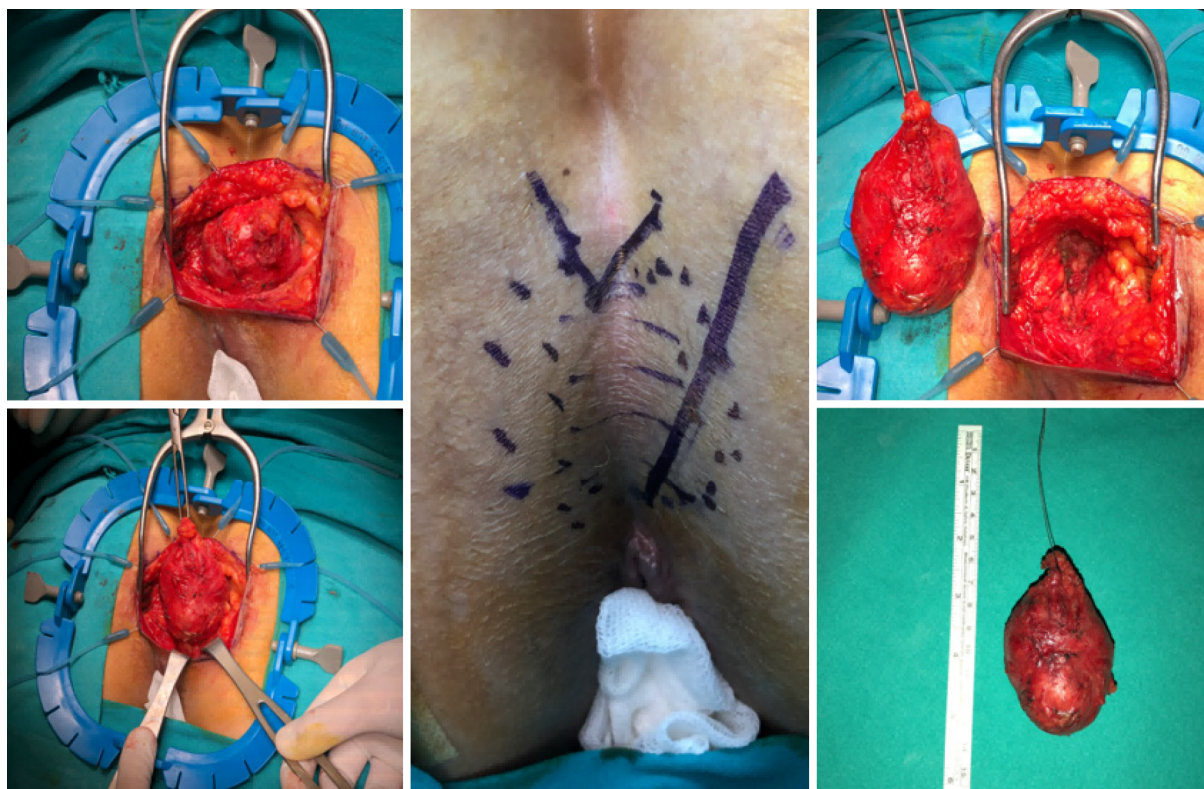


Figure 6 Perineal approach via parasagittal incision in a patient with a tail-gut cyst.

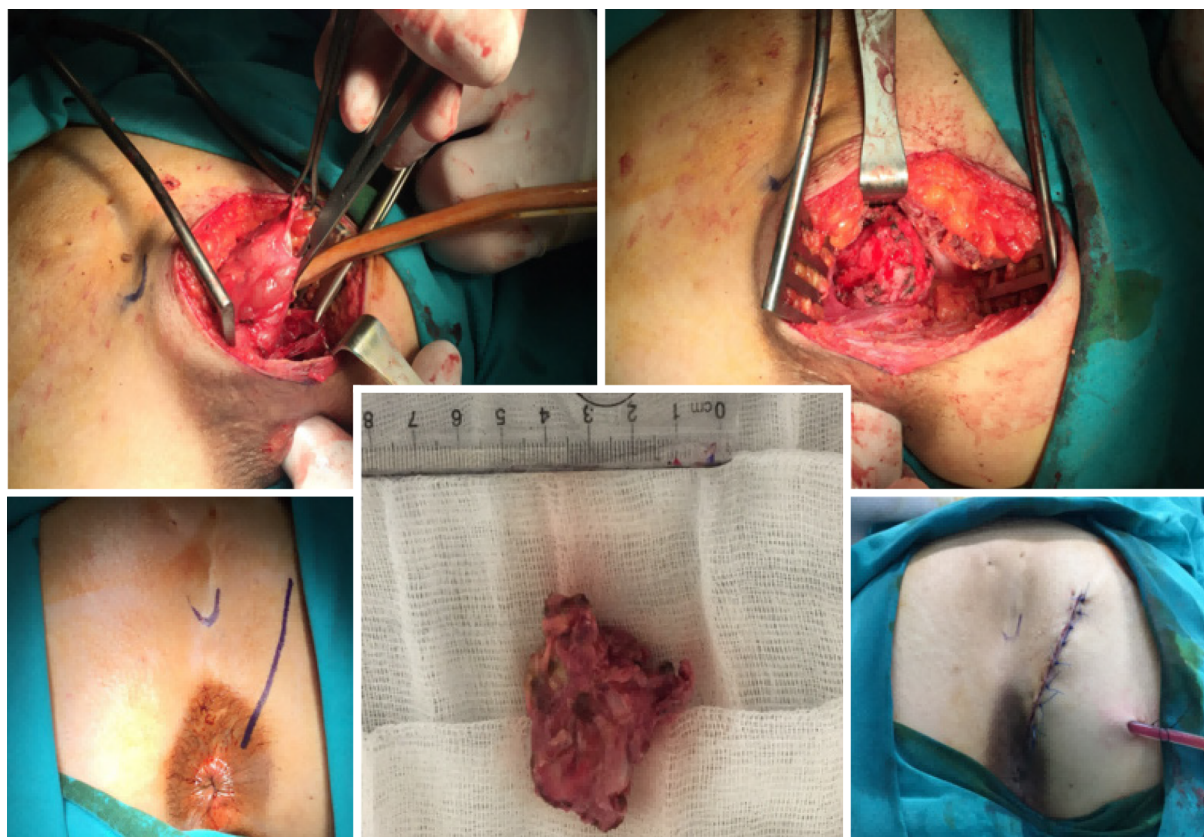


Figure 7 Perineal approach via parasagittal incision in a patient with an epidermoid cyst.



(such as sacrectomy) is required, this approach is more feasible[33,34]. For such, the patient is placed in the modified Lloyd-Davis position. The dissection starts with the opening of the pelvic peritoneum and continues to the posterior of the rectum. After the anterior margins of the tumor are dissected from the mesorectum, it is separated from the presacral fascia. Since the arterial supply of the tumor can originate from the middle sacral artery, it is crucial to identify and ligate the tumor's vascular structures first[25,35].

### **Posterior (perineal) approach**

The posterior approach is indicated for tumors below S3 without any involvement of the sacrum and other pelvic organs (Figures 6-8). The patient is placed in the prone jack-knife position, and a midline or parasagittal incision is performed. Excision or elevation of the coccyx can be necessary for better exposure to the retrorectal space [23]. The division of the levator muscles follows, to enable access into the retrorectal space. Abdominoperineal resection may be required in patients with malignant tumors, as part of the *en bloc* resection. It has been reported that the posterior approach is preferred over the combined abdominoperineal approach, due to its lower morbidity rate than the latter, which has the highest recurrence and complication rate of all approaches[8,36-38].

### **Combined abdominoperineal approach**

The combined abdominoperineal approach is recommended for malignant lesions, invading adjacent structures and obscuring normal surgical planes. The patient is placed in a modified Lloyd-Davies position, in order to access both areas[23]. If an extended soft tissue resection is required to achieve clear surgical margins, simultaneous or staged pedicle or free flap transfers can be used to prevent chronic sinus formation and fistulation[39,40]. Permacol mesh can also be applied for the reconstruction of the pelvic wall.

### **Minimally invasive surgery**

Although it has not been reported whether laparotomy or laparoscopy has better long-term results, it is known that the laparoscopic approach provides an enhanced visualization of pelvic structures and facilitates precise dissection of the tumor from adjacent structures[8]. The laparoscopic approach has been demonstrated as a safe and feasible technique for treating retrorectal tumors[41,42]. There have also been case series reporting that the robotic approach can be chosen for large tumors, offering the benefits of shorter operation time and shorter length of hospitalization compared to laparotomy[43,44].

Transanal endoscopic microsurgery (TEMS) is also newly being applied to retrorectal tumors; however, with this approach, following oncological principles for malignant tumors is difficult[45,46]. Thus, it is recommended that malignancy should be excluded before TEMS is performed[23].

---

## **FOLLOW-UP AND SURVEILLANCE**

---

Long-term results depend on the type of tumor and the successful surgical resection with clear margins achieved in the first operation. Although many authors have reported that benign retrorectal tumors have 100% overall survival rates with no recurrences[2,11], the patients should be followed-up for potential risk of local recurrence. Benign local recurrences' have been shown to have a good prognosis, even after repeated resection[47]. In contrast, malignant tumors can metastasize to the liver, lung, and brain, which are all associated with significantly worse prognosis[48-50].

---

## **CONCLUSION**

---

Retrorectal tumors are uncommon lesions occurring in the retrorectal space. The most common retrorectal tumors are congenital benign tumors. The diagnostic algorithm starts with suspicion by a physician who carries out a thorough physical examination. MRI is the chosen imaging modality, with or without CT and TRUS. The preoperative biopsy is highly recommended for solid or heterogeneous tumors, although it is contraindicated for pure cystic lesions. The posterior approach is the preferred surgical method for most retrorectal tumors, producing lower morbidity rates. A multidiscip-

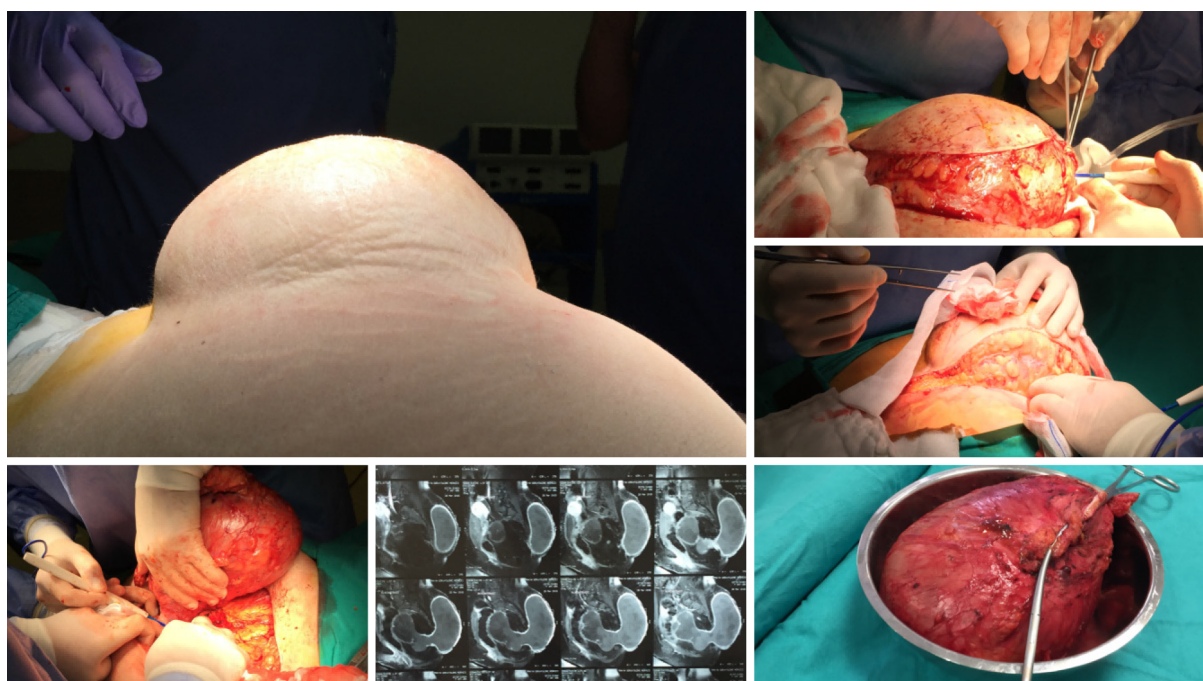


Figure 8 Perineal approach via parasagittal incision in a patient with a teratoma.

linary team is usually required, since these complex tumors have a potential risk of invading adjacent structures and necessitating an *en bloc* resection.

## ACKNOWLEDGEMENTS

The authors extend a special thanks to Dr. Murat Ucar, Department of Radiology, Gazi University Hospital, and Dr. Mehmet Yorubulut, Department of Radiology, Acibadem Ankara Hospital, for their contributions to the preparation of this review article.

## REFERENCES

- 1 **Jao SW**, Beart RW Jr, Spencer RJ, Reiman HM, Ilstrup DM. Retrorectal tumors. Mayo Clinic experience, 1960-1979. *Dis Colon Rectum* 1985; **28**: 644-652 [PMID: [2996861](#) DOI: [10.1007/BF02553440](#)]
- 2 **Wolpert A**, Beer-Gabel M, Lifschitz O, Zbar AP. The management of presacral masses in the adult. *Tech Coloproctol* 2002; **6**: 43-49 [PMID: [12077641](#) DOI: [10.1007/s101510200008](#)]
- 3 **Mirilas P**, Skandalakis JE. Surgical anatomy of the retroperitoneal spaces part II: the architecture of the retroperitoneal space. *Am Surg* 2010; **76**: 33-42 [PMID: [20135937](#)]
- 4 **Hobson KG**, Ghaemmaghami V, Roe JP, Goodnight JE, Khatri VP. Tumors of the retrorectal space. *Dis Colon Rectum* 2005; **48**: 1964-1974 [PMID: [15981068](#) DOI: [10.1007/s10350-005-0122-9](#)]
- 5 **Carpelan-Holmström M**, Koskenvuo L, Haapamäki C, Renkonen-Sinisalo L, Lepistö A. Clinical management of 52 consecutive retro-rectal tumours treated at a tertiary referral centre. *Colorectal Dis* 2020; **22**: 1279-1285 [PMID: [32336000](#) DOI: [10.1111/codi.15080](#)]
- 6 **Woodfield JC**, Chalmers AG, Phillips N, Sagar PM. Algorithms for the surgical management of retrorectal tumours. *Br J Surg* 2008; **95**: 214-221 [PMID: [17933000](#) DOI: [10.1002/bjs.5931](#)]
- 7 **Brown KGM**, Lee PJ. Algorithms for the surgical management of benign and malignant presacral tumors. *Semi Colon Rec Surg* 2020; **31**: 3 [DOI: [10.1016/j.scrs.2020.100762](#)]
- 8 **Baek SK**, Hwang GS, Vinci A, Jafari MD, Jafari F, Moghadamyeghaneh Z, Pigazzi A. Retrorectal Tumors: A Comprehensive Literature Review. *World J Surg* 2016; **40**: 2001-2015 [PMID: [27083451](#) DOI: [10.1007/s00268-016-3501-6](#)]
- 9 **Menteş BB**, Kurukahvecioğlu O, Ege B, Karamercan A, Leventoglu S, Yazicioğlu O, Oğuz M. Retrorectal tumors: a case series. *Turk J Gastroenterol* 2008; **19**: 40-44 [PMID: [18386239](#)]
- 10 **Uhlig BE**, Johnson RL. Presacral tumors and cysts in adults. *Dis Colon Rectum* 1975; **18**: 581-589 [PMID: [1181162](#) DOI: [10.1007/BF02587141](#)]
- 11 **Lev-Chelouche D**, Gutman M, Goldman G, Even-Sapir E, Meller I, Issakov J, Klausner JM, Rabau M. Presacral tumors: a practical classification and treatment of a unique and heterogeneous group of

- diseases. *Surgery* 2003; **133**: 473-478 [PMID: [12773974](#) DOI: [10.1067/msy.2003.118](#)]
- 12 **Li W**, Li J, Yu K, Zhang K. Retrorectal adenocarcinoma arising from tailgut cysts: a rare case report. *BMC Surg* 2019; **19**: 180 [PMID: [31775691](#) DOI: [10.1186/s12893-019-0639-9](#)]
  - 13 **Lee A**, Suhardja TS, Nguyen TC, Teoh WM. Neuroendocrine tumour developing within a long-standing tailgut cyst: case report and review of the literature. *Clin J Gastroenterol* 2019; **12**: 539-551 [PMID: [31147970](#) DOI: [10.1007/s12328-019-00998-4](#)]
  - 14 **Stewart RJ**, Humphreys WG, Parks TG. The presentation and management of presacral tumours. *Br J Surg* 1986; **73**: 153-155 [PMID: [3947908](#) DOI: [10.1002/bjs.1800730227](#)]
  - 15 **Li Z**, Lu M. Presacral Tumor: Insights From a Decade's Experience of This Rare and Diverse Disease. *Front Oncol* 2021; **11**: 639028 [PMID: [33796466](#) DOI: [10.3389/fonc.2021.639028](#)]
  - 16 **Farsad K**, Kattapuram SV, Sacknoff R, Ono J, Nielsen GP. Sacral chordoma. *Radiographics* 2009; **29**: 1525-1530 [PMID: [19755609](#) DOI: [10.1148/rg.295085215](#)]
  - 17 **Gray SW**, Singhabhandhu B, Smith RA, Skandalakis JE. Sacrococcygeal chordoma: Report of a case and review of the literature. *Surgery* 1975; **78**: 573-582 [PMID: [1188599](#)]
  - 18 **Bergh P**, Kindblom LG, Gunterberg B, Remotti F, Ryd W, Meis-Kindblom JM. Prognostic factors in chordoma of the sacrum and mobile spine: a study of 39 patients. *Cancer* 2000; **88**: 2122-2134 [PMID: [10813725](#) DOI: [10.1002/\(sici\)1097-0142\(20000501\)88:9<2122::aid-cnecr19>3.0.co;2-1](#)]
  - 19 **Waldhausen JA**, Kolman JW, Vellos F, Battersby JS. Sacrococcygeal Teratoma. *Surgery* 1963; **54**: 933-949 [PMID: [14087131](#)]
  - 20 **Gordon PH**. Retrorectal tumors. In: Gordon PH, Nivatvongs S, eds. *Principles and Practice of Surgery for the Colon, Rectum and Anus*. St. Louis, MO: Quality Medical Publishing, 1999: 427-445
  - 21 **Dozois EJ**, Jacofsky DJ, Dozois RR. Presacral tumors. In: Wolff BG, Fleshman JW, Beck DE, *et al*, eds. *The ASCRS Textbook of Colon and Rectal Surgery*. New York: Springer, 2007: 501-514
  - 22 **Freier DT**, Stanley JC, Thompson NW. Retrorectal tumors in adults. *Surg Gynecol Obstet* 1971; **132**: 681-686 [PMID: [4995717](#)]
  - 23 **Toh JW**, Morgan M. Management approach and surgical strategies for retrorectal tumours: a systematic review. *Colorectal Dis* 2016; **18**: 337-350 [PMID: [26663419](#) DOI: [10.1111/codi.13232](#)]
  - 24 **Murphy A**, O'Sullivan H, Stirling A, Fenlon H, Cronin C. Integrated multimodality and multi-disciplinary team approach to pre-sacral lesions. *Clin Imaging* 2020; **67**: 255-263 [PMID: [32890910](#) DOI: [10.1016/j.clinimag.2020.08.011](#)]
  - 25 **Neale JA**. Retrorectal tumors. *Clin Colon Rectal Surg* 2011; **24**: 149-160 [PMID: [22942797](#) DOI: [10.1055/s-0031-1285999](#)]
  - 26 **Merchea A**. Role of preoperative biopsy in the management of presacral tumors. *Seminars in Colon and Rectal Surgery* 2020; **31**: 3 [DOI: [10.1016/j.scrs.2020.100761](#)]
  - 27 **Paradies G**, Zullino F, Orofino A, Leggio S. Unusual presentation of sacrococcygeal teratomas and associated malformations in children: clinical experience and review of the literature. *Ann Ital Chir* 2013; **84**: 333-346 [PMID: [23160138](#)]
  - 28 **Casali PG**, Messina A, Stacchiotti S, Tamborini E, Crippa F, Gronchi A, Orlandi R, Ripamonti C, Spreafico C, Bertieri R, Bertulli R, Colecchia M, Fumagalli E, Greco A, Grosso F, Olmi P, Pierotti MA, Pilotti S. Imatinib mesylate in chordoma. *Cancer* 2004; **101**: 2086-2097 [PMID: [15372471](#) DOI: [10.1002/cncr.20618](#)]
  - 29 **Varga PP**, Bors I, Lazary A. Sacral tumors and management. *Orthop Clin North Am* 2009; **40**: 105-123, vii [PMID: [19064059](#) DOI: [10.1016/j.ocl.2008.09.010](#)]
  - 30 **Hof H**, Welzel T, Debus J. Effectiveness of cetuximab/ gefitinib in the therapy of a sacral chordoma. *Onkologie* 2006; **29**: 572-574 [PMID: [17202828](#) DOI: [10.1159/000096283](#)]
  - 31 **Glasgow SC**, Dietz DW. Retrorectal tumors. *Clin Colon Rectal Surg* 2006; **19**: 61-68 [PMID: [20011312](#) DOI: [10.1055/s-2006-942346](#)]
  - 32 **Bullard Dunn K**. Retrorectal tumors. *Surg Clin North Am* 2010; **90**: 163-171, Table of Contents [PMID: [20109640](#) DOI: [10.1016/j.suc.2009.09.009](#)]
  - 33 **Sagar AJ**, Tan WS, Codd R, Fong SS, Sagar PM. Surgical strategies in the management of recurrent retrorectal tumours. *Tech Coloproctol* 2014; **18**: 1023-1027 [PMID: [24925354](#) DOI: [10.1007/s10151-014-1172-6](#)]
  - 34 **Localio SA**, Eng K, Ranson JH. Abdominosacral approach for retrorectal tumors. *Ann Surg* 1980; **191**: 555-560 [PMID: [6929181](#) DOI: [10.1097/00000658-198005000-00006](#)]
  - 35 **Young-Fadok TM**, Dozois EJ. Retrorectal tumors. In: Yeo CJ, ed. *Shackelford's Surgery of the Alimentary Tract*. Philadelphia: Saunders, 2007: 2299-2311
  - 36 **Chéreau N**, Lefevre JH, Meurette G, Mourra N, Shields C, Parc Y, Tiret E. Surgical resection of retrorectal tumours in adults: long-term results in 47 patients. *Colorectal Dis* 2013; **15**: e476-e482 [PMID: [23601092](#) DOI: [10.1111/codi.12255](#)]
  - 37 **Alsofyani TM**, Aldossary MY, AlQahtani FF, Sabr K, Balhareth A. Successful excision of a retrorectal cyst through trans-sacral approach: A case report. *Int J Surg Case Rep* 2020; **71**: 307-310 [PMID: [32485636](#) DOI: [10.1016/j.ijscr.2020.05.023](#)]
  - 38 **Buchs N**, Taylor S, Roche B. The posterior approach for low retrorectal tumors in adults. *Int J Colorectal Dis* 2007; **22**: 381-385 [PMID: [16909248](#) DOI: [10.1007/s00384-006-0183-9](#)]
  - 39 **Yalav O**, Topal U, Eray İC, Deveci MA, Gencel E, Rencuzogullari A. Retrorectal tumor: a single-center 10-years' experience. *Ann Surg Treat Res* 2020; **99**: 110-117 [PMID: [32802816](#) DOI: [10.4174/astr.2020.99.2.110](#)]
  - 40 **Beier JP**, Croner RS, Lang W, Arkudas A, Schmitz M, Göhl J, Hohenberger W, Horch RE.



- [Avoidance of complications in oncological surgery of the pelvic region : combined oncosurgical and plastic reconstruction measures]. *Chirurg* 2015; **86**: 242-250 [PMID: [25620285](#) DOI: [10.1007/s00104-014-2835-6](#)]
- 41 **Duclos J**, Maggiori L, Zappa M, Ferron M, Panis Y. Laparoscopic resection of retrorectal tumors: a feasibility study in 12 consecutive patients. *Surg Endosc* 2014; **28**: 1223-1229 [PMID: [24263459](#) DOI: [10.1007/s00464-013-3312-x](#)]
  - 42 **Mullaney TG**, Lightner AL, Johnston M, Kelley SR, Larson DW, Dozois EJ. A systematic review of minimally invasive surgery for retrorectal tumors. *Tech Coloproctol* 2018; **22**: 255-263 [PMID: [29679245](#) DOI: [10.1007/s10151-018-1781-6](#)]
  - 43 **Oh JK**, Yang MS, Yoon DH, Rha KH, Kim KN, Yi S, Ha Y. Robotic resection of huge presacral tumors: case series and comparison with an open resection. *J Spinal Disord Tech* 2014; **27**: E151-E154 [PMID: [23698108](#) DOI: [10.1097/BSD.0b013e318299c5fd](#)]
  - 44 **Morelli L**, Tassinari D, Rosati CM, Palmeri M, Boggi U, Mosca F. Robot-assisted excision of a huge pararectal dermoid cyst via a totally transabdominal route. *J Minim Invasive Gynecol* 2012; **19**: 772-774 [PMID: [23084685](#) DOI: [10.1016/j.jmig.2012.06.008](#)]
  - 45 **Duek SD**, Gilshtein H, Khoury W. Transanal endoscopic microsurgery: also for the treatment of retrorectal tumors. *Minim Invasive Ther Allied Technol* 2014; **23**: 28-31 [PMID: [24329013](#) DOI: [10.3109/13645706.2013.872663](#)]
  - 46 **Raestrup H**, Manncke K, Mentges B, Buess G, Becker HD. Indications and technique for TEM (transanal endoscopic microsurgery). *Endosc Surg Allied Technol* 1994; **2**: 241-246 [PMID: [7866754](#)]
  - 47 **Messick CA**, Hull T, Rosselli G, Kiran RP. Lesions originating within the retrorectal space: a diverse group requiring individualized evaluation and surgery. *J Gastrointest Surg* 2013; **17**: 2143-2152 [PMID: [24146338](#) DOI: [10.1007/s11605-013-2350-y](#)]
  - 48 **Spada F**, Pelosi G, Squadroni M, Lorizzo K, Farris A, de Braud F, Fazio N. Neuroendocrine tumour arising inside a retro-rectal tailgut cyst: report of two cases and a review of the literature. *Ecancermedicalscience* 2011; **5**: 201 [PMID: [22276050](#) DOI: [10.3332/ecancer.2011.201](#)]
  - 49 **Li GD**, Chen K, Fu D, Ma XJ, Sun MX, Sun W, Cai ZD. Surgical strategy for presacral tumors: analysis of 33 cases. *Chin Med J (Engl)* 2011; **124**: 4086-4091 [PMID: [22340347](#)]
  - 50 **Yoshida A**, Maoate K, Blakelock R, Robertson S, Beasley S. Long-term functional outcomes in children with Currarino syndrome. *Pediatr Surg Int* 2010; **26**: 677-681 [PMID: [20473613](#) DOI: [10.1007/s00383-010-2615-4](#)]



Published by **Baishideng Publishing Group Inc**  
7041 Koll Center Parkway, Suite 160, Pleasanton, CA 94566, USA

**Telephone:** +1-925-3991568

**E-mail:** [bpgoffice@wjgnet.com](mailto:bpgoffice@wjgnet.com)

**Help Desk:** <https://www.f6publishing.com/helpdesk>

<https://www.wjgnet.com>

