

# World Journal of *Gastrointestinal Surgery*

*World J Gastrointest Surg* 2021 March 27; 13(3): 222-329



## Contents

Monthly Volume 13 Number 3 March 27, 2021

### OPINION REVIEW

- 222 Paraesophageal hernia and iron deficiency anemia: Mechanisms, diagnostics and therapy  
*Dietrich CG, Hübner D, Heise JW*

### REVIEW

- 231 Gastroenteropancreatic neuroendocrine neoplasms: A clinical snapshot  
*Fernandez CJ, Agarwal M, Pottakkat B, Haroon NN, George AS, Pappachan JM*

### ORIGINAL ARTICLE

#### Retrospective Study

- 256 Prognostic predictors in patients with sepsis after gastrointestinal tumor surgery: A retrospective study  
*Chen RX, Wu ZQ, Li ZY, Wang HZ, Ji JF*
- 267 Retrospective research of neoadjuvant therapy on tumor-downstaging, post-operative complications, and prognosis in locally advanced rectal cancer  
*Li WC, Zhao JK, Feng WQ, Miao YM, Xu ZF, Xu ZQ, Gao H, Sun J, Zheng MH, Zong YP, Lu AG*
- 279 Combination of preoperative fibrinogen and D-dimer as a prognostic indicator in pancreatic ductal adenocarcinoma patients undergoing R0 resection  
*Zhang LP, Ren H, Du YX, Zheng XH, Zhang ZM, Wang CF*
- 303 Colonic pouch confers better bowel function and similar postoperative outcomes compared to straight anastomosis for low rectal cancer  
*Chen ZZ, Li YD, Huang W, Chai NH, Wei ZQ*

### CASE REPORT

- 315 Giant hepatic extra-gastrointestinal stromal tumor treated with cytoreductive surgery and adjuvant systemic therapy: A case report and review of literature  
*Fernandes MR, Ghezzi CLA, Grezzana-Filho TJM, Feier FH, Leipnitz I, Chedid AD, Cerski CTS, Chedid MF, Krueel CRP*
- 323 Functional anatomical hepatectomy guided by indocyanine green fluorescence imaging in patients with localized cholestasis: Report of four cases  
*Han HW, Shi N, Zou YP, Zhang YP, Lin Y, Yin Z, Jian ZX, Jin HS*

**ABOUT COVER**

Editorial Board Member, Vasile Virgil Bintintan, MD, PhD, Doctor, Senior Lecturer, Senior Researcher, Surgeon, Department of Surgery, "Tuliu Hatieganu" University of Medicine and Pharmacy Cluj-Napoca, Cluj Napoca 400006, Romania. [vasile.bintintan@umfcluj.ro](mailto:vasile.bintintan@umfcluj.ro)

**AIMS AND SCOPE**

The primary aim of *World Journal of Gastrointestinal Surgery* (WJGS, *World J Gastrointest Surg*) is to provide scholars and readers from various fields of gastrointestinal surgery with a platform to publish high-quality basic and clinical research articles and communicate their research findings online.

WJGS mainly publishes articles reporting research results and findings obtained in the field of gastrointestinal surgery and covering a wide range of topics including biliary tract surgical procedures, biliopancreatic diversion, colectomy, esophagectomy, esophagostomy, pancreas transplantation, and pancreatectomy, etc.

**INDEXING/ABSTRACTING**

The WJGS is now abstracted and indexed in Science Citation Index Expanded (SCIE, also known as SciSearch®), Current Contents/Clinical Medicine, Journal Citation Reports/Science Edition, PubMed, and PubMed Central. The 2020 edition of Journal Citation Reports® cites the 2019 impact factor (IF) for WJGS as 1.863; IF without journal self cites: 1.824; Ranking: 109 among 210 journals in surgery; Quartile category: Q3; Ranking: 77 among 88 journals in gastroenterology and hepatology; and Quartile category: Q4.

**RESPONSIBLE EDITORS FOR THIS ISSUE**

Production Editor: Jia-Hui Li; Production Department Director: Xiang Li; Editorial Office Director: Ya-Juan Ma.

**NAME OF JOURNAL**

*World Journal of Gastrointestinal Surgery*

**ISSN**

ISSN 1948-9366 (online)

**LAUNCH DATE**

November 30, 2009

**FREQUENCY**

Monthly

**EDITORS-IN-CHIEF**

Shu-You Peng, Varut Lohsiriwat, Jin Gu

**EDITORIAL BOARD MEMBERS**

<https://www.wjgnet.com/1948-9366/editorialboard.htm>

**PUBLICATION DATE**

March 27, 2021

**COPYRIGHT**

© 2021 Baishideng Publishing Group Inc

**INSTRUCTIONS TO AUTHORS**

<https://www.wjgnet.com/bpg/gerinfo/204>

**GUIDELINES FOR ETHICS DOCUMENTS**

<https://www.wjgnet.com/bpg/gerinfo/287>

**GUIDELINES FOR NON-NATIVE SPEAKERS OF ENGLISH**

<https://www.wjgnet.com/bpg/gerinfo/240>

**PUBLICATION ETHICS**

<https://www.wjgnet.com/bpg/gerinfo/288>

**PUBLICATION MISCONDUCT**

<https://www.wjgnet.com/bpg/gerinfo/208>

**ARTICLE PROCESSING CHARGE**

<https://www.wjgnet.com/bpg/gerinfo/242>

**STEPS FOR SUBMITTING MANUSCRIPTS**

<https://www.wjgnet.com/bpg/gerinfo/239>

**ONLINE SUBMISSION**

<https://www.f6publishing.com>



## Gastroenteropancreatic neuroendocrine neoplasms: A clinical snapshot

Cornelius J Fernandez, Mayuri Agarwal, Biju Pottakkat, Nisha Nigil Haroon, Annu Susan George, Joseph M Pappachan

**ORCID number:** Cornelius J Fernandez 0000-0002-1171-5525; Mayuri Agarwal 0000-0003-0824-5255; Biju Pottakkat 0000-0002-8474-0270; Nisha Nigil Haroon 0000-0002-6695-315X; Annu Susan George 0000-0003-2806-958X; Joseph M Pappachan 0000-0003-0886-5255.

**Author contributions:** Fernandez CJ and Agarwal M performed majority of the initial drafting and prepared the figures and tables, and share the first authorship; Pottakkat B made critical revisions in the surgical aspects of the write up; Haroon NN provided substantial additional contributions to the endocrine aspects of the work; George AS contributed to the conception and design of the study and made critical revisions especially the oncological aspects; Pappachan JM conceived the study, made critical revisions and provided final approval of the final version of the manuscript to be published

**Conflict-of-interest statement:** Authors declare no conflict of interests for this article.

**Open-Access:** This article is an open-access article that was selected by an in-house editor and fully peer-reviewed by external reviewers. It is distributed in accordance with the Creative

**Cornelius J Fernandez, Mayuri Agarwal,** Department of Endocrinology and Metabolism, Pilgrim Hospital, United Lincolnshire Hospitals NHS Trust, Boston PE21 9QS, United Kingdom

**Biju Pottakkat,** Department of Surgical Gastroenterology, Jawaharlal Institute of Post Graduate Medical Education and Research (JIPMER), Puducherry 605006, India

**Nisha Nigil Haroon,** Department of Endocrinology and Internal Medicine, Northern Ontario School of Medicine, Sudbury P3E 2C6, Ontario, Canada

**Annu Susan George,** Department of Medical Oncology, VPS Lakeshore Hospital, Cochin 682040, Kerala, India

**Joseph M Pappachan,** Department of Endocrinology and Metabolism, Lancashire Teaching Hospitals NHS Trust, PR2 9HT, Preston, The University of Manchester, Oxford Road M13 9PL, Manchester Metropolitan University, All Saints Building M15 6BH, Manchester, United Kingdom.

**Corresponding author:** Joseph M Pappachan, MD, MRCP, FRCP; Consultant, Senior Researcher, Department of Endocrinology and Metabolism, Lancashire Teaching Hospitals NHS Trust, PR2 9HT, Preston, The University of Manchester, Oxford Road M13 9PL, Manchester Metropolitan University, All Saints Building M15 6BH, Manchester, United Kingdom. [drpappachan@yahoo.co.in](mailto:drpappachan@yahoo.co.in)

### Abstract

Our understanding about the epidemiological aspects, pathogenesis, molecular diagnosis, and targeted therapies of neuroendocrine neoplasms (NENs) have drastically advanced in the past decade. Gastroenteropancreatic (GEP) NENs originate from the enteroendocrine cells of the embryonic gut which share common endocrine and neural differentiation factors. Most NENs are well-differentiated, and slow growing. Specific neuroendocrine biomarkers that are used in the diagnosis of functional NENs include insulin, glucagon, vasoactive intestinal polypeptide, gastrin, somatostatin, adrenocorticotropin, growth hormone releasing hormone, parathyroid hormone-related peptide, serotonin, histamine, and 5-hydroxy indole acetic acid (5-HIAA). Biomarkers such as pancreatic polypeptide, human chorionic gonadotrophin subunits, neurotensin, ghrelin, and calcitonin are used in the diagnosis of non-functional NENs. 5-HIAA levels correlate with tumour burden, prognosis and development of carcinoid heart disease and mesenteric fibrosis, however several diseases, medications and



Commons Attribution NonCommercial (CC BY-NC 4.0) license, which permits others to distribute, remix, adapt, build upon this work non-commercially, and license their derivative works on different terms, provided the original work is properly cited and the use is non-commercial. See: <http://creativecommons.org/licenses/by-nc/4.0/>

**Manuscript source:** Invited manuscript

**Specialty type:** Gastroenterology and hepatology

**Country/Territory of origin:** United Kingdom

**Peer-review report's scientific quality classification**

Grade A (Excellent): 0  
Grade B (Very good): 0  
Grade C (Good): C  
Grade D (Fair): 0  
Grade E (Poor): 0

**Received:** December 11, 2020

**Peer-review started:** December 11, 2020

**First decision:** January 11, 2021

**Revised:** January 17, 2021

**Accepted:** March 2, 2021

**Article in press:** March 2, 2021

**Published online:** March 27, 2021

**P-Reviewer:** Wang WQ

**S-Editor:** Fan JR

**L-Editor:** A

**P-Editor:** Li JH



edible products can falsely elevate the 5-HIAA levels. Organ-specific transcription factors are useful in the differential diagnosis of metastasis from an unknown primary of well-differentiated NENs. Emerging novel biomarkers include circulating tumour cells, circulating tumour DNA, circulating micro-RNAs, and neuroendocrine neoplasms test (NETest) (simultaneous measurement of 51 neuroendocrine-specific marker genes in the peripheral blood). NETest has high sensitivity (85%-98%) and specificity (93%-97%) for the detection of gastrointestinal NENs, and is useful for monitoring treatment response, recurrence, and prognosis. In terms of management, surgery, radiofrequency ablation, symptom control with medications, chemotherapy and molecular targeted therapies are all considered as options. Surgery is the mainstay of treatment, but depends on factors including age of the individual, location, stage, grade, functional status, and the heredity of the tumour (sporadic *vs* inherited). Medical management is helpful to alleviate the symptoms, manage inoperable lesions, suppress postoperative tumour growth, and manage recurrences. Several molecular-targeted therapies are considered second line to somatostatin analogues. This review is a clinical update on the pathophysiological aspects, diagnostic algorithm, and management of GEP NENs.

**Key Words:** Gastroenteropancreatic neuroendocrine neoplasms; Neuroendocrine tumours; Neuroendocrine carcinoma; Targeted molecular therapy; Octreoscan; Chemotherapy

©The Author(s) 2021. Published by Baishideng Publishing Group Inc. All rights reserved.

**Core Tip:** Gut, the largest endocrine organ of the body, secretes several hormones through its specialised neuroendocrine cells. Neuroendocrine neoplasms (NENs) originating from these cells are collectively known as gastroenteropancreatic (GEP) NENs that pose significant challenges to clinicians in the diagnostic work up, prognostication and management. Rapid advancements in the molecular diagnostic and therapeutic strategies in the recent years revolutionised the options for clinical investigations and management of patients with these uncommon neoplasms. This review updates the pathophysiological aspects, diagnostic strategies, and management algorithms of GEP NENs with the best evidence currently available in the global scientific literature to enable clinicians to optimally manage these unusual disease entities.

**Citation:** Fernandez CJ, Agarwal M, Pottakkat B, Haroon NN, George AS, Pappachan JM. Gastroenteropancreatic neuroendocrine neoplasms: A clinical snapshot. *World J Gastrointest Surg* 2021; 13(3): 231-255

**URL:** <https://www.wjgnet.com/1948-9366/full/v13/i3/231.htm>

**DOI:** <https://dx.doi.org/10.4240/wjgs.v13.i3.231>

## INTRODUCTION

Gut, the largest endocrine organ of the body, is involved in the synthesis of many hormones such as glucagon-like peptide-1 (GLP-1), glucose-dependent insulinotropic polypeptide (GIP), motilin, leptin, ghrelin, somatostatin, gastrin, secretin, cholecystokinin, serotonin, histamine, and neurotensin<sup>[1]</sup>. These hormones are secreted by the neuroendocrine cells, which are also known as amine precursor uptake and decarboxylation (APUD) cells or enteroendocrine cells (EECs). There are various types of EECs, the most important being enterochromaffin cells, L-cells, and D-cells. The enterochromaffin cells (ECs) are the most abundant of EECs and are widely distributed along the gut and are named so because of their affinity to bind chromium salts. The enterochromaffin-like cells (ECLs) are also present in the gastric mucosa<sup>[2]</sup>. The types of enteroendocrine cells, the hormones secreted from these cells and their functions are depicted in [Table 1](#).

Neuroendocrine neoplasms (NENs) originating from the EECs of the embryonic gut are a diverse group of epithelial neoplasms that share a common characteristic feature

**Table 1 The enteroendocrine cells, secretory products, and their physiological functions<sup>[3,4]</sup>**

EECs	Amine/peptide hormones	Physiological functions of the hormones
ECs	Serotonin	Regulation of appetite and gut motility
ECLs	Histamine	Regulation of gastric acidity
L-cells	GLP-1, GLP-2, peptide YY, glicentin and oxyntomodulin	Regulation of appetite, gut motility, and insulin kinetics
K-cells	GIP	Insulin kinetics
D-cells	Somatostatin	Regulation of gastric acidity, and insulin secretion
A-cells	Ghrelin and nesfatin-1	Regulation of appetite and growth hormone
G-cells	Gastrin	Regulation of gastric acidity
P-cells	Leptin	Regulation of appetite
S-cells	Secretin	Regulation of gastric acidity
I-cells	CCK	Modulation of appetite, gall bladder motility, and bile release
M-cells	Motilin	Regulation of gut motility
N-cells	Neurotensin	Regulation of gut motility

CCK: Cholecystokinin; EECs: Enteroendocrine cells; ECs: Enterochromaffin cells; ECLs: Enterochromaffin-like cells; GLP: Glucagon-like peptide; GIP: Glucose-dependent insulintropic polypeptide.

of endocrine and neural differentiation including the presence of secretory granules, potential for peptide/amine hormone synthesis, and presence of synaptic-like vesicles<sup>[3]</sup>. The NENs were previously known as carcinoid tumors or APUDomas<sup>[4]</sup>. A majority of NENs are well-differentiated, slow growing, but potentially malignant lesions and are known as neuroendocrine tumors (NETs). Only a minority of NENs are poorly differentiated, and highly aggressive lesions. These are known as neuroendocrine carcinomas (NECs).

Well-differentiated NENs (NETs) are composed of cells that retain their ability to secrete hormones. NETs are frequently diagnosed when they present with symptoms related to hormone hypersecretion, often after they have metastasized to the liver. On the other hand, poorly differentiated NENs (NECs) are less likely to secrete hormones and are more likely to be diagnosed after development of widespread metastasis. NENs comprise of NETs and NECs with entirely different natural histories and prognoses<sup>[5]</sup>. Thus, significant variations exist in the functional status (functional *vs* non-functional), secretory products (for functional NENs), histology (well *vs* poorly differentiated), findings on immunohistochemistry, potential for metastasis and thereby prognosis.

NENs were historically classified into foregut, midgut, and hindgut NENs based on their site of origin from the embryonic gut. The foregut NENs include bronchopulmonary, thymic, oesophageal, gastric, duodenal, and pancreatic NENs. The midgut NENs are small intestinal, appendiceal, and caecal NENs, and the hindgut NENs are distal colonic, and rectal NENs<sup>[6]</sup>. However, as the above classification is less accurate in adults, the currently used classification divide NENs into gastroenteropancreatic and lung NENs (GEP-NENs and lung-NENs). GEP-NENs constitute pancreatic NENs (pNENs), and gastrointestinal NENs (GI-NENs), the latter is again subdivided into gastric, small intestinal (Jejuno-ileal), appendiceal, colonic, and rectal NENs<sup>[7]</sup>.

The biological behaviour of NENs can change significantly based on the site of origin. The hypergastrinaemia related gastric NENs (type I and II gastric NENs), duodenal, appendiceal, and rectal NENs are less aggressive in comparison to rest of the GI-NENs and pNENs<sup>[8]</sup>. A majority of gastric and appendiceal NENs remain well localized, whereas majority of small intestinal and pNENs would have developed metastasis at the time of diagnosis<sup>[9]</sup>. Whereas small intestinal and pNENs are predominantly NETs, the lung and colonic NENs are predominantly NECs<sup>[10]</sup>. We would like to critically review the available literature pertaining to the GEP-NENs, with special emphasis on their management.

## THE EPIDEMIOLOGICAL PERSPECTIVE

The incidence of NENs have increased in the last four decades. As *per* the Surveillance, Epidemiology and End Results (SEER) database from the United States, the overall annual age-adjusted incidence of NENS in the year 2014 was 6.98, whereas that in the year 1973 was 1.09 *per* 100000 population indicating an increase in incidence by 6.4-fold in 4 decades<sup>[11]</sup>. The increase is presumably due to an increase in detection of early stage NENs that are localized and regional. The incidence of various types of NENs in the descending order were lung (1.49), small intestine (1.05), rectum (1.04), unknown primary (0.8), pancreas (0.48), stomach (0.4), appendix (0.3), colon (0.2) and caecum (0.1) *per* 100000. NENs of unknown primary was nearly 0.8 *per* 100000. The distribution of NENs based on the primary site of the tumor is given in **Figure 1**. The 20-year limited-duration prevalence was 48 *per* 100000 and the projected prevalence of NENs in the United States in 2014 was 171321. **Figure 1** shows the incidence of NENs in the year 2014.

The increased incidence is attributed to increased rate of imaging, higher awareness about NENs, improved availability of biomarkers and better methods in immuno-histochemistry. Higher frequency of NENs and worse outcomes with the disease are seen in men. NENs are mostly sporadic in origin but nearly 5% can be hereditary cases associated with conditions such as Multiple Endocrine Neoplasia type 1 (MEN1), von Hippel-Lindau (VHL) disease, tuberous sclerosis (Bourneville's disease), and neurofibromatosis type 1 or NF1 (Von Recklinghausen's Disease). The hereditary NENs are characteristically multifocal, appear 1-2 decades earlier than sporadic NENs, and are diagnosed in the early stages of illness. Genetic testing for hereditary aetiologies should be done in patients with age < 40 years, family history of NENs, clinical features of hereditary disease, or multiple endocrine glandular involvement. Nearly 80%-90% of NENs are contributed by NETs and the rest 10%-20% of NENs are NECs<sup>[12]</sup>.

## CLINICAL PROFILES OF GEP-NENS BASED ON THE LOCATION OF TUMOR

Among GEP-NENs, nearly 50% are intestinal and 30% pancreatic. Among intestinal NENs only 20% are hormone secreting. Among pancreatic NENs only 10%-30% are functional<sup>[12]</sup>. Thus a majority of the NENs are non-functional indicating lack of symptoms of hormonal hypersecretion<sup>[13]</sup>.

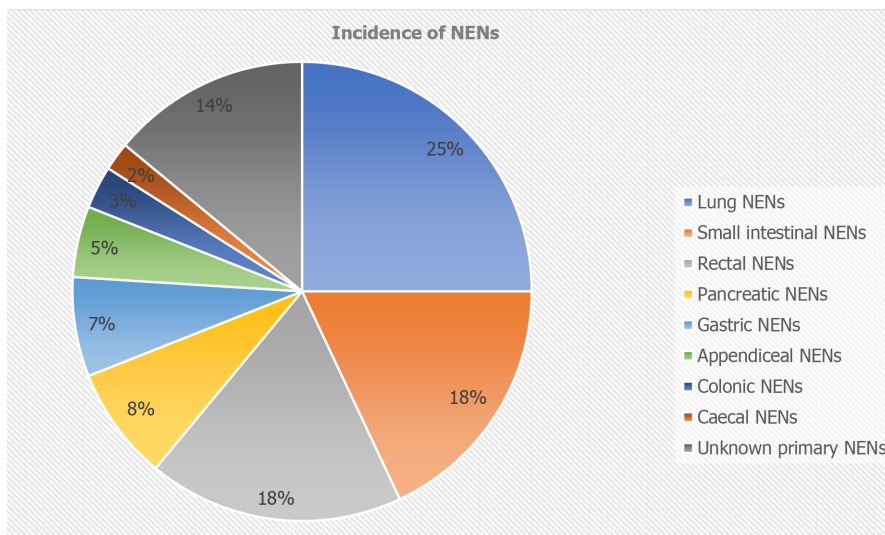
### Gastric-NENs

Gastric-NENS arise from the ECL cells of gastric mucosa that normally secrete histamine. There are four types of gastric-NENS. The type 1 constitutes 70%-80% of all gastric NENs and they occur in patients with chronic atrophic gastritis having autoimmune destruction of acid secreting gastric parietal cells by anti-parietal antibodies and intrinsic factor antibodies. The resulting achlorhydria stimulate the G cells of gastric antrum (hypergastrinaemia), which in turn stimulates hyperplasia of ECL cells and development of multifocal polypoid NENs of 1-2 cm size. Parietal cell antibodies are present in 80%. This type is less aggressive, and the prognosis is excellent<sup>[14]</sup>.

The type 2 constitutes 5%-10% of all gastric NENs and are associated with gastrinomas and gastric acid hypersecretion [Zollinger-Ellison syndrome (ZES)]. Hypergastrinaemia results in hyperplasia and hypertrophy of ECL cells resulting in multiple, small (approximately 1 cm) NENs that are less aggressive with good prognosis. The gastric pH will be low and abdominal pain and diarrhoea will be present<sup>[14]</sup>. Patients with type 2 gastric NENs should be investigated for pituitary and parathyroid disease in view of the frequent association with MEN1.

The type 3 constitutes 10%-15% of all gastric NENs, and these are not associated with hypergastrinaemia and abnormal (low or high) gastric acid production. They NENs are solitary, sporadic, and well-differentiated lesions originating from ECL cells without any atrophy or hypertrophy of the underlying gastric mucosa. These are large (> 2 cm) neoplasms that are aggressive, and more than 50% of patients develop hepatic metastasis at the time of diagnosis. They may present with features of atypical carcinoid syndrome due to the release of both histamine and serotonin. The prognosis is similar to gastric adenocarcinoma<sup>[15]</sup>.

The type 4 has similar characteristics as that of type 3 gastric NENs. However, they are either poorly differentiated NECs or variably differentiated mixed neuroendoc-



**Figure 1** The distribution of neuroendocrine neoplasms based on the primary site of the neuroendocrine tumors<sup>[11]</sup>. NENs: Neuroendocrine neoplasms.

rine-non-neuroendocrine neoplasms (MiNEN), with more aggressive behavior and worse prognosis compared to type 3 gastric NENs<sup>[16]</sup>. Thus, the type 1 and 2 NENs manifest as gastric ulcers or bleeding gastric polyps. On the other hand, type 3 and 4 NENs manifest with weight loss, anaemia, metastasis to liver or lymph nodes, such as gastric adenocarcinoma<sup>[17]</sup>.

### **Jejuno-ileal NENs**

These NENs originate from the EC cells at the base of the intestinal crypts in the submucosa of jejunum and ileum. Most common site is the distal ileum up to 60 cm proximal to ileocecal valve followed by jejunum. The primary lesions are usually less than 1 cm in size and multifocal primary lesions are found in nearly 50% of patients. Though these tumors are characteristically of lower grades (G1 or G2), they are often diagnosed in advanced stages<sup>[18]</sup>. Hepatic metastasis is seen in nearly 80%-90% of cases at the time of diagnosis<sup>[19]</sup>. Similarly, metastasis to mesenteric nodes and development of mesenteric fibrosis with encasement of superior mesenteric artery would be present in nearly 50% at the time of diagnosis. Nearly 20% of small intestinal NENs are associated with release of amines and peptides to induce carcinoid syndrome. Moreover, they are associated with fibrotic complications such as mesenteric fibrosis and carcinoid heart disease (CaHD)<sup>[20]</sup>.

The pathogenesis of mesenteric fibrosis is thought to be mediated by a complex network of autocrine and paracrine interactions between serotonin and certain growth factors triggered by the tumor deposits in the mesentery. These growth factors include transforming growth factor (TGF)- $\beta$ , connective tissue growth factor, platelet-derived growth factor (PDGF), insulin-like growth factor 1, epidermal growth factor (EGF), and TGF- $\alpha$ . The mesenteric fibrosis can present as acute intestinal obstruction, acute mesenteric ischaemia or with chronic symptoms including prandial abdominal pain, venous stasis, malabsorption, and malnutrition<sup>[20]</sup>. The pathogenesis of CaHD, characterized by right heart involvement that occurs in nearly 60% of carcinoid syndrome<sup>[21]</sup>, is mediated by high circulating serotonin levels<sup>[20]</sup>.

### **Duodenal NENs**

Duodenal NENs originating from the proximal duodenum could be gastrinomas, non-functional duodenal-NETs and duodenal NECs, whereas those originating from the ampullary or periampullary region could be somatostatinomas and gangliocytic paragangliomas. Duodenal gastrinomas, originating from G cells in the submucosal layer of proximal duodenum, can be associated with MEN1 in 20%-30% of cases or can be sporadic in 70%-80%. Duodenal gastrinomas constitute about 70% of all gastrinomas and is the most common cause of ZES. The non-functional duodenal-NETs that constitutes 90% of all duodenal NENs are often detected incidentally during endoscopy<sup>[19]</sup>. However, they can sometimes present with bowel obstruction. The duodenal NECs are rare aggressive neoplasms with invasion into lymphovascular structures or duodenal wall and can present with distant metastasis<sup>[20]</sup>. Somatostati-



nomas, originating from D cells of the duodenum near the ampulla, can be mostly sporadic or can be rarely associated with MEN1 or NF1<sup>[22,23]</sup>. Somatostatinomas can, very rarely, present as somatostatinoma syndrome consisting of triad of diabetes mellitus, cholelithiasis and steatorrhea. However, most often they remain clinically silent without hormonal overactivity or can cause biliary or pancreatic duct obstruction. Gangliocytic paragangliomas has 3 components (epithelioid, spindle-shaped, and ganglion-like cells) and they originate from the second part of duodenum near the ampulla of Vater. They are usually benign, though they can metastasize to regional lymph nodes, and can cause nonspecific abdominal symptoms such as pain, nausea, vomiting and recurrent mucosal ulcerations<sup>[24]</sup>.

### **Appendiceal NENs**

The appendiceal NENs are the third most common type of gastrointestinal NENs after the rectal and small intestinal NENs<sup>[16]</sup>. Appendiceal NENs are usually an incidental diagnosis, detected in 0.3%-0.9% of patients undergoing appendicectomy<sup>[25]</sup>. Appendiceal NENs account for 30%-80% of all appendiceal neoplasms. They were diagnosed at a much younger age of 32-42 years compared to other gastrointestinal NENs and are seen more commonly in women than men. Appendiceal NENs originate from the neuroendocrine cells of the lamina propria and submucosa of appendix. Appendiceal NENs can be histologically classified into EC cell type NENs, L-cell type NENs, and MiNEN. The local and distant spread depends on size of the neoplasm and its histology. Large NENs (more than 2 cm), NECs and MiNEN have high risk of metastasis<sup>[26]</sup>. Though considered indolent, 50% would have developed nodal spread and 10% distant spread at the time of diagnosis<sup>[19]</sup>. 60%-80% of appendiceal NENs are located at the tip, 5%-21% in the body, and 7%-10% at the base, with the latter at higher risk of local recurrence after appendicectomy<sup>[26]</sup>.

### **Rectal NENs**

Rectal NENs originating from the L-cells secreting GLP-1 and PYY are one of the commonest NENs and are of low grades (G1 or G2) and low stages (75%-85% are localized) at the time of diagnosis<sup>[27,28]</sup>. Rectal NENs < 1 cm has a metastasis risk of < 3%, whereas those > 2 cm has a risk of 60%-80%. The rectal NENs of the size 1-2 cm has a metastasis risk of 10%-15%<sup>[19]</sup>. Rectal NENs are diagnosed incidentally during sigmoidoscopy/colonoscopy in nearly 40% of cases. They may also present with altered bowel habit, rectal bleeding, abdominal pain, tenesmus, and weight loss. Though bowel obstruction is rare with rectal NENs, it can occur in rectosigmoid NENs. Since the rectal NENs are not serotonin producing, associated carcinoid syndrome is rare<sup>[28]</sup>.

### **Colonic NENs**

Colonic NENs originate from the EC cells that secrete serotonin. However, carcinoid syndrome is extremely rare. These neoplasms are aggressive and poorly differentiated (high-grade)<sup>[27]</sup>. Due to the delayed presentation, these are often large (> 2 cm) with widespread metastases at the time of diagnosis. Symptoms and signs include abdominal discomfort, diarrhoea, bleeding, bowel obstruction, weight loss, palpable abdominal mass, or hepatomegaly mimicking those of colonic adenocarcinoma<sup>[28]</sup>.

### **pNENs**

pNENs are the second most common pancreatic neoplasms, representing 1%-2% of all pancreatic neoplasms<sup>[29]</sup>. Most pNENs are non-functional, whereas very few are functional, the commonest functional pNENs being insulinomas, and gastrinomas. Rare functional pNENs include Vasoactive intestinal peptide (VIP)omas, glucagonomas, somatostatinomas, growth hormone releasing hormone (GHRH) secreting pNENs (GRHomas), adrenocorticotropin (ACTH)omas, parathyroid hormone related peptide (PTHrP)omas, pNEN-related carcinoid syndrome, and very rarely cholecystokinin (CCK)omas<sup>[30]</sup>. Non-functional pNENs are diagnosed incidentally at an advanced stage with evidence of metastasis. While functional pNENs are small (1-2 cm), well-defined, and hyper-vascular, the non-functional pNENs are large (4 cm), well-defined, encapsulated and heterogeneously enhancing lesions<sup>[31]</sup>.

Most pNENs are sporadic, whereas a minority are inherited. MEN1 is associated with non-functional pNENs in 80%-100%, gastrinomas in 20%-61%, insulinomas in 7%-31%, glucagonomas in 1%-6%, VIPomas in 1%-12%, and somatostatinomas in 1%<sup>[32]</sup>. All these pNENs, except gastrinomas and somatostatinomas, exclusively occur in the pancreas. NF1 is associated with duodenal somatostatinomas in 0%-10%, with

NF1 accounting for nearly 50% of somatostatinomas in that location. NF1 is rarely associated with pNENs such as somatostatinoma, insulinoma, gastrinoma, or non-functional pNENs. VHL is associated with pNENs in 10%-17%, which are invariably non-functional. Tuberous sclerosis is associated with both functional and non-functional pNENs, and the functional NENs being gastrinomas and insulinomas<sup>[32]</sup>. Clinical features, incidence, cancer risk, MEN1 association, and treatment of various functional pNENs are summarised in **Table 2**, with references taken from<sup>[29-32]</sup>.

## CLINICAL FEATURES OF GEP-NENS WITH HORMONE HYPERSECRETION

### *Insulinoma*

This is the commonest functional pNEN. Peak incidence is 40-45 years with a female preponderance (approximately 60%). 95%-100% of these lesions can be cured surgically. Patients with malignant insulinomas having liver metastasis at the time of presentation have a median survival of < 2 years. Around 10% the insulinomas are multifocal in origin. Patients with large insulinomas (> 2 cm) have high metastasis risk and poor survival<sup>[33]</sup>. The suspected patients should satisfy the Whipple's triad characterized by symptoms of hypoglycaemia, plasma glucose levels < 2.2 mmol/L (< 40 mg/dL), and relief of symptoms with glucose administration for diagnosis. Gold standard test for the diagnosis of insulinoma is the 72 h fast test, with the diagnosis established with the following criteria: Glucose  $\leq$  2.2 mmol/L, concomitant insulin  $\geq$  6  $\mu$ U/mL ( $\geq$  36 pmol/L); C-peptide  $\geq$  0.2 nmol/L; proinsulin  $\geq$  5 pmol/L;  $\beta$ -hydroxybutyrate levels  $\leq$  2.7 mmol/L, and no sulfonylurea metabolites in the plasma and/or urine<sup>[33]</sup>. Nearly 18% of patients with insulinoma develop only postprandial hypoglycaemia, meaning that the 72 h fast test can be falsely negative, and these patients can be diagnosed based on altered insulin pattern during an oral glucose tolerance test induced hypoglycaemia<sup>[34]</sup>.

### *Gastrinoma*

Gastrinoma or Zollinger Ellison syndrome is the second most common functional pNEN. Nearly 70% of gastrinomas occur in duodenum and 70%-85% of which occur in the Passaro's gastrinoma triangle. Nearly 25% of gastrinomas occur in pancreas and only 5% occur in various organs such as stomach, liver, bile duct, ovary, heart, and lung<sup>[33]</sup>. Compared to duodenal gastrinomas, pancreatic gastrinomas are lesser in frequency, larger in size with higher rates of liver metastasis. Gastrinomas are usually > 1 cm in size and exhibit signs of local invasion and lymph node metastasis. Though gastrinomas are the commonest functional malignant pNENs, they are well-differentiated NENs with the WHO grading of G1 and G2<sup>[35]</sup>.

Age at presentation of sporadic ZES is 48-55 years, whereas the corresponding figure of MEN1 associated ZES is 32-35 years. Among patients with sporadic ZES, duodenal gastrinomas account for 55%-88% of cases, whereas among patients with MEN1 associated ZES, duodenal gastrinomas account for 70%-100% of cases and they are always multiple. In up to 45% of MEN1 associated ZES patients, the ZES symptoms precede the hyperparathyroidism symptoms. However, almost all will have diagnosis of hyperparathyroidism before ZES diagnosis. Family history of endocrinopathies is present only in 60%-75% of MEN1 associated ZES<sup>[36]</sup>. As 20%-30% of ZES is associated with MEN1 and family history can be negative in 25%-40% of patients, all patients with ZES should be tested for MEN1 with albumin corrected calcium, parathyroid hormone (PTH) and prolactin. Diagnosis of ZES can be difficult in post-parathyroidectomy patients, as an effective parathyroidectomy can suppress the acid output and masks the ZES<sup>[37]</sup>.

Symptoms of ZES include longstanding abdominal pain due to chronic/recurrent/refractory peptic ulcer disease (PUD), heartburn due to gastro-oesophageal reflux disease (GORD), chronic diarrhoea, gastrointestinal bleeding, and weight loss. Multiple ulcers or ulcers in unusual locations are less frequently observed as classical ZES symptoms due to widespread proton pump inhibitor (PPI) use. Suspect ZES in patients with severe, recurrent, familial PUD; PUD not associated with *Helicobacter Pylori* or non-steroidal anti-inflammatory drugs; PUD with GORD; PUD resistant to therapy/causing complications; PUD with diarrhoea, especially if the diarrhoea shows improvement with PPI; PUD with endocrinopathies (hypercalcaemia or hypergastrinaemia); or PUD with prominent gastric folds on endoscopy<sup>[33]</sup>.

The diagnostic features include high fasting serum gastrin level or FSG (10-fold of

**Table 2 Clinical features, incidence, cancer risk, multiple endocrine neoplasia 1 association, and treatment of various functional pancreatic neuroendocrine neoplasms<sup>[29-32]</sup>**

Name of f-pNENs	Proportion of f-NENs	Incidence million/year	Biomarker	Location of the NENs	Malignancy (proportion)	MEN1 association	Symptoms, signs, and laboratory testing features	Surgery: Indication and procedure
Insulinoma	30%-40%	1-32	Insulin	Pancreas: > 99%	< 10%	4%-5%	Hypoglycemia symptoms Whipple's triad, weight gain. ↑Insulin, ↑proinsulin levels. ↑C-peptide on 72 h fast test	Always. Parenchymal sparing pancreatectomy
Gastrinoma ZES	16%-30%	0.5-21.5	Gastrin	Duodenum: 70%. Pancreas: 25%. Others: 5%	60%-90%	20%-25%	Complicated or difficult to treat PUD, GORD, profuse diarrhoea. ↑Gastrin levels, ↓Gastric pH. Secretin stimulation test	Yes, except < 2 cm MEN1/ZES. Standard pancreatectomy
VIPoma or WDHA Verner-Morrison syndrome. Pancreatic cholera	< 10%	0.05-0.2	VIP	Pancreas: 90% Neural, adrenal, preganglionic: 10%	40%-70%	6%	Profuse watery diarrhoea, hypokalaemia, metabolic acidosis, achlorhydria, and dehydration; ↑VIP levels	Yes. Standard pancreatectomy
Glucagonoma	< 10%	0.01-0.1	Glucagon	Pancreas: 100%	50%-80%	1%-20%	Rash (necrolytic migratory erythema), weight loss, new onset diabetes mellitus and thromboembolic events. ↑Glucagon levels	Yes. Standard pancreatectomy
Somatostatinoma	< 5%	Rare	Somatostatin	Pancreas 55% Duodenum-jejunum: 44%	> 70%	45%	New onset diabetes, gallstones, weight loss, diarrhoea, steatorrhoea, ↑Somatostatin	Yes. Standard pancreatectomy
GRHoma	Rare	Unknown	GHRH	Pancreas: 30%, Lung 54%, Jejunum: 7%, and Others: 13%	> 60%	16%	Acromegaly with/without peptic ulcer, wheeze, flushing, renal stone, ↑GHRH levels	Yes. Standard pancreatectomy
ACTHoma	Rare	Rare	ACTH	Pancreas	> 95%	Rare	Ectopic Cushing's syndrome. 4%-16% of all ectopic Cushing	Yes. Standard pancreatectomy
PTHrP-oma	Rare	Rare	PTHrP	Pancreas	84%	Rare	Rare cause of hypercalcemia. Pain abdomen: Liver metastasis	Yes. Standard pancreatectomy
Carcinoid syndrome arising from pNEN	Rare	Rare	Serotonin Tachykinin?	Pancreas: < 1% of all carcinoid syndrome	60%-88%	Rare	Flushing, diarrhoea, broncho-spasm, carcinoid heart disease↑ urinary 5-HIAA levels	Yes. Standard pancreatectomy

NENs: Neuroendocrine neoplasms; pNENs: Pancreatic NENs; f-pNENs: Functional-pNENs; MEN1: Multiple endocrine neoplasia 1; 5-HIAA: 5-hydroxy indole acetic acid; ZES: Zollinger Ellison syndrome; PVD: Peripheral vascular disease; GORD: Gastro-oesophageal reflux disease; WDHA: Watery diarrhea, hypokalemia, and hypochlorhydria or achlorhydria; VIP: Vasoactive intestinal peptide; GHRH: Growth hormone releasing hormone; PTHrP: Parathyroid hormone-related peptide; GRHomias: GHRH secreting pNENs; ACTH: Gastrin, somatostatin, adrenocorticotropin.

upper limit of normal), gastric acid hypersecretion (basal acid output or BAO > 15 mEq/h), and gastric acid pH of < 2. FSG and gastric pH should be measured after stopping the PPI therapy for at least 1 wk, as PPI use results in increased gastrin levels and a false positive test for ZES. PPI should be stopped cautiously to avoid rapid development of PUD complications<sup>[38]</sup>. The ZES can be easily diagnosed in 40% of cases if the FSG is > 10 fold and gastric pH is < 2. In the remaining 60% of cases with

the FSG is < 10 fold, but with pH < 2, additional provocative testing using secretin test (rapid infusion of secretin 2 Units/kg) and the measurement of BAO is indicated. After the secretin test, if the BAO reaches > 15 mEq/h or the serum gastrin levels increases by > 120 pg/mL above the basal FSG level, ZES can be diagnosed (sensitivity 94% and specificity 100%)<sup>[39]</sup>. A small number of patients with clinical features of ZES with acid hypersecretion, but with normal FSG levels and negative secretin test, might be having a CCKoma. Thus, plasma CCK levels should be checked in such patients. The CCKoma patients may present with nonwatery diarrhoea, cholelithiasis, peptic ulcer disease, and significant weight loss<sup>[40]</sup>.

### Glucagonoma

Glucagonomas are one of the rare functional pNENs that are exclusively pancreatic in location. Age at diagnosis is 50-55 years and nearly 40%-90% of patients will have hepatic metastasis at the time of diagnosis. The 5-year survival in the advanced stages is only 29%-45%<sup>[33]</sup>. Patients with glucagonomas typically present with necrolytic migratory erythema, significant weight loss (catabolic effect of glucagon), new onset or worsening diabetes mellitus, and may have cheilosis, glossitis, stomatitis, anaemia, thromboembolic events, and neuropsychiatric disturbances. Diagnosis requires documentation of plasma glucagon level of > 500 pg/mL, and documentation of a pancreatic tumor, usually large (> 4 cm) due to the delay in diagnosis<sup>[41-44]</sup>.

### Somatostatinoma

Somatostatinomas are an extremely rare functional NENs that occur in the pancreas, duodenum, and jejunum. 93.1% are sporadic and only 6.9% are associated with inherited conditions such as MEN1, NF1, VHL, or tuberous sclerosis<sup>[45]</sup>. Nearly 45% of pancreatic somatostatinomas are associated with MEN1 and nearly 50% of duodenal somatostatinomas are associated with NF1. Recently a new inherited condition caused by a gain in function mutation of hypoxia-inducible factor 2 alpha (*HIF-2α*) gene has been recognized which is characterized by duodenal somatostatinoma, multiple paragangliomas, and polycythemia<sup>[46]</sup>. Age at diagnosis is 50-55 years and nearly 40%-90% will have hepatic metastasis at the time of diagnosis. Most appear as well-differentiated tumors.

Most symptoms are nonspecific which include dyspepsia, hypochlorhydria, weight loss, and anaemia. However, few patients especially those with pancreatic somatostatinomas present with somatostatinoma syndrome characterized by diabetes mellitus, diarrhoea/steatorrhoea and cholelithiasis. The effect of somatostatin to inhibit release of multiple hormones such as insulin, glucagon, GLP-1, GIP, gastrin, secretin, cholecystokinin, growth hormone, VIP, and pancreatic polypeptide could explain the multiple non-specific symptoms<sup>[46]</sup>. The real existence of somatostatinoma syndrome has been questioned recently<sup>[47]</sup>. Fasting plasma somatostatin level > 30 pg/mL establishes the diagnosis. Survival rates are high for metastatic duodenal somatostatinomas in comparison to metastatic pancreatic somatostatinomas<sup>[48]</sup>.

### VIPoma

VIPomas are rare functional pNENs, also known by various names including Verner-Morrison Syndrome, pancreatic cholera, or watery diarrhoea, hypokalaemia, and achlorhydria syndrome as these patients suffer from profuse large volume watery diarrhoea, metabolic acidosis (bicarbonate loss in stools), hypokalaemia, and reduced gastric acid secretion, with or without facial flushing. Age at diagnosis is 50-55 years and nearly 40%-90% will have hepatic metastasis at the time of diagnosis. Five-year survival is 60% in patients with metastatic disease and 94% in those without<sup>[49,50]</sup>. Diagnosis is characterised by raised VIP levels in a patient with typical watery diarrhoea (specificity 100%).

### Other rare functional NENs

Nearly 16% of ectopic Cushing's syndrome are contributed by a pancreatic ACTHoma. In addition to these pNENs bronchial carcinoids contribute to 21%, thymic carcinoids to 10%, and small cell cancer of lung to 27% of all ectopic Cushing's syndromes<sup>[51,52]</sup>. GRHomas are known to present as acromegaly. Whereas patients with pituitary acromegaly have normal or low GHRH, patients with GRHomas have elevated GHRH levels. Suspect GRHomas in acromegaly patients exhibiting unique features such as wheezing, flushing, peptic ulcer disease, or renal stone<sup>[53]</sup>.

PTHrPomas are pNENs that secrete PTHrP causing hypercalcaemia<sup>[54]</sup>. The pNENs are an extremely rare (< 1%) cause of carcinoid syndrome<sup>[33]</sup>. Metachronous hormonal syndromes (MHSs) refers to new symptoms of secondary hormonal hypersecretion



that have developed later during the follow-up period of a functional or non-functional NENs. The secondary hormonal hypersecretion is usually associated with disease progression, increased morbidity, and mortality especially in those with insulin related MHSs. Secondary hormone hypersecretion is seen in nearly 9.3% of pNENs whereas it is extremely rare with small intestinal NENs (1 in 603 cases)<sup>[55,56]</sup>.

### **Carcinoid syndrome**

Carcinoid syndrome is a paraneoplastic syndrome characterized by combination of symptoms which occurs due to various vasoactive substances secreted by the NENs into the systemic circulation<sup>[57,58]</sup>. Various vasoactive substances include serotonin, histamine, kallikrein, prostaglandins E and F, norepinephrine, motilin, and tachykinins such as substance P. Carcinoid syndrome usually occur in the setting of extensive liver metastasis, where these vasoactive substances cannot be metabolized and enter the systemic circulation through the hepatic veins. However, bronchial, ovarian, or gastrointestinal NENs with extensive retroperitoneal nodal spread can cause carcinoid syndrome even without hepatic metastasis<sup>[22]</sup>.

Carcinoid syndrome account for 20% of all NENs and 25% of all GEP-NENs<sup>[59,60]</sup>. As per the SEER database from the United States, the frequency of carcinoid syndrome in the descending order of their occurrence were from small intestine (40%), lung (13%), colon/rectum (10%), and caecum/appendix (2%-5%)<sup>[61]</sup>. Thymus and appendiceal NENs were underrepresented in the SEER database. Other studies have shown that carcinoid syndrome occur predominantly with midgut NENs, followed by thymic and lung NENs, and very rarely from pancreatic NENs (< 1%), as well as other gastrointestinal-NENs<sup>[16]</sup>. The foregut NENs lack the aromatic amino acid decarboxylase that converts 5-hydroxytryptophan to serotonin. However, they produce histamine in addition to 5-hydroxy tryptophan leading to the development of atypical carcinoid syndrome. The hindgut NENs very rarely produce serotonin and other vasoactive substances, making carcinoid syndrome less likely even in the setting of hepatic metastasis<sup>[58]</sup>.

Typical symptoms of carcinoid syndrome include episodic flushing and diarrhoea. However, atypical symptoms in the form of wheezing, palpitations, breathlessness, abdominal pain; and symptoms arising from complications (CaHD, pellagra, neuropsychiatric manifestations, and carcinoid crisis) also constitute important manifestations<sup>[62]</sup>. Flushing and diarrhoea are provoked by excessive 5HT levels, though other metabolites including prostaglandin, catecholamines, histamines and substance P also play an important role. CaHD which is also known as Hedinger syndrome occurs in about 40%-50% of patients with carcinoid syndrome. The underlying mechanism is serotonin driven deposition of fibrotic plaque in endocardial surfaces of valvular/subvalvular apparatus, cardiac chambers and rarely within intima of pulmonary arteries and aorta. Left side of the heart is spared due to the inactivation of vasoactive substances in the lungs<sup>[63-65]</sup>.

Diversion of tryptophan to the process of making serotonin leads to depletion of tryptophan store, depriving generation of niacin. Therefore, patients with carcinoid syndrome are prone to develop niacin deficiency causing pellagra. Neuropsychiatric manifestations in the form of cognitive impairment is noted in carcinoid syndrome secondary to depletion of serotonin synthesis within the brain due to deprivation of tryptophan stores<sup>[66]</sup>. Anaesthesia, surgery, or even abdominal palpation may cause sudden massive release of catecholamines from the tumor leading to hypotension, prolonged/excessive flushing, hyperthermia, and palpitations, which is known as carcinoid crisis. The predictors for the crisis are presence of CaHD and high urinary 5-HIAA levels<sup>[15]</sup>.

### **Clinical features of GEP-NENs without hormone hypersecretion**

Most of the non-functional GEP NENs are detected as incidentalomas. However, some may present with gastrointestinal bleeding, iron deficiency anaemia, bowel perforation, bowel obstruction (due to primary tumor or mesenteric fibrosis), mesenteric ischaemia, unexplained weight loss/fever/night sweats, bone pain/hepatomegaly (metastasis) or renal dysfunction (retroperitoneal fibrosis). Nearly 70% of non-functional pNENs secrete various peptides (pancreatic polypeptide, neurotensin, ghrelin, calcitonin), human chorionic gonadotrophin subunits, neuron-specific enolase, and chromogranins. As these are not known to cause any hormonal excess symptoms, they are considered as non-functional pNENs<sup>[67]</sup>.

## DIAGNOSIS OF GEP-NENS

### ***Serum biomarkers in the diagnosis and follow-up of NENs***

General neuroendocrine biomarkers that are commonly present in neuroendocrine cells of neuroendocrine neoplasms include chromogranin A (CgA) (present in secretory granules), synaptophysin (present in synaptic-like vesicles), neuron-specific enolase (NSE) (present in the cytoplasm of neuroendocrine cells), protein gene product 9.5 (PGP9.5), and cluster of differentiation 56 or CD56 (neural cell adhesion molecule). Well-differentiated GEP-NETs express both synaptophysin and CgA. On the other hand, poorly differentiated NENs can be negative for CgA, but positive for synaptophysin and NSE. Thus, CgA is a general biomarker for well-differentiated NENs and NSE is a specific general biomarker for poorly differentiated NENs<sup>[68,69]</sup>. Although these biomarkers are insufficient for diagnosis, they are good for assessing the prognosis and therapeutic response.

Though it can be positive in all NENs, the CgA lacks the specificity for the new diagnosis of NENs. It can be elevated in inflammatory bowel disease, chronic gastritis, pancreatitis, renal failure, liver failure, other neoplasms, and treatment with PPI, steroids, and somatostatin analogues (SSAs). Moreover, there is no relationship between CgA levels and the tumor burden. However, it has good sensitivity and specificity to monitor the disease progression, response to treatment and to detect recurrence of the disease<sup>[16]</sup>. Pancreastatin, a breakdown product of CgA, has the advantage that it is less affected by PPI use, but has the disadvantage that there is no relationship with the tumor burden, and the test is not widely available<sup>[70]</sup>.

Specific neuroendocrine biomarkers that are used in the diagnosis of functional NENs include peptide hormones and bioamines like insulin, glucagon, VIP, gastrin, somatostatin, ACTH, GHRH, PTHrP, serotonin, histamine and 5-HIAA. Biomarkers such as pancreatic polypeptide, human chorionic gonadotrophin subunits, neurotensin, ghrelin, and calcitonin are used in the diagnosis of non-functional NENs. The urinary breakdown product of serotonin, 5-HIAA, is used in the diagnosis and follow-up of patients with carcinoid syndrome. The 5-HIAA levels are correlated with the tumor burden, development of CaHD, development of mesenteric fibrosis, overall prognosis, and survival, even though several diseases, drugs and foods can falsely elevate the 5-HIAA levels<sup>[71]</sup>.

Novel biomarkers that are under development for NENs include circulating tumor cells, circulating tumor DNA, circulating micro-RNAs, and NETest (simultaneous measurement of 51 neuroendocrine-specific marker genes in the peripheral blood). NETest has high sensitivity (85%-98%) and specificity (93%-97%) for the detection of GI-NENs, irrespective of stage and grade of the disease and the use of PPIs and SSAs. It has 93% accuracy in establishing the diagnosis. It can be used for monitoring the response to therapy, to detect recurrence and for assessing the prognosis. But the test is not widely available, and it needs further validation<sup>[7,69]</sup>.

### ***Immuno-histochemical markers***

Organ-specific transcription factors are useful in the differential diagnosis of metastasis from an unknown primary from well-differentiated NENs. The thyroid transcription factor 1 is specific to lung; caudal type homeobox transcription factor 2 is specific to midgut; insulin gene enhancer protein 1 and paired box protein 8 are specific for pancreas and rectum; special AT-rich sequence binding protein homeobox 2 is specific to rectum, and neuroendocrine secretory protein 55 is specific to pancreas<sup>[7,72,73]</sup>.

### ***Imaging modalities for the diagnosis of NENs***

High resolution multidetector computed tomography (CT) of the chest, abdomen, and pelvis pre and post administration of intravenous contrast can be used in the diagnosis, with the late arterial phase aids in detection of NENs in liver and pancreas, and the venous phase aids in detection of NENs in the remaining organs and tissues<sup>[74]</sup>. Small intestinal NENs with mesenteric metastases result in intense desmoplastic reaction appearing as soft tissue masses with areas of calcification surrounded by fibrotic streaks radiating to the mesentery<sup>[75]</sup>. Advantage of CT include is a high detection rate for hepatic and pancreatic NENs. Disadvantages are low detection rate for bone metastases, sub-centimetre sized lymph node metastasis and small intestinal NENs and high dose of radiation.

Magnetic resonance imaging (MRI) is superior to CT for diagnosis of pancreatic (sensitivity 79%, specificity 100%) and hepatic (sensitivity 75%, specificity 98%) NENs. Typical NENs exhibit low signal intensity on T1 and high signal intensity on T2-

weighted images<sup>[16]</sup>. Diffusion weighted MRI and contrast enhanced MRI help in visualisation of small hepatic metastases, and in the assessment of the margin between the tumor and the pancreatic duct. <sup>18</sup>F-fluorodeoxyglucose positron emission tomography (<sup>18</sup>F-FDG PET) can be hybridised with CT and MRI. Even though advantageous due to higher resolution, the disadvantages are limited tracer uptake and lower sensitivity for low grade NENs<sup>[16]</sup>. However, GLP-1 receptor PET/CT for the diagnosis and localisation of insulinomas are in development.

Contrast enhanced ultrasound has an increasing role in the detection and follow up of patients with NENs. Early enhancement after microbubble injection is characteristic. The effect is more pronounced in metastatic liver lesions. Early enhancement can differentiate NENs from metastasis from other types of malignancies.

Upper and lower gastrointestinal endoscopic examinations have significant role in the detection of NENs. Many incidental lesions in the gastrointestinal tract detected on endoscopic examinations can be NENs. Depending on the site of the lesion, upper GI scopy, side viewing endoscopy, colonoscopy, or small bowel enteroscopy can be used to evaluate lesions. Endoscopic ultrasound (EUS) can be used to improve the detection of pancreatic NENs (except for those in the tail of the pancreas), duodenal NENs and gastric NENs. EUS will facilitate assessment of depth of extension and allow access to tissue sampling with fine needle aspiration or EUS-guided punch biopsy<sup>[76]</sup>. Endorectal ultrasound can be used in rectal NENs. Small lesions can be excised for biopsy by mucosal or submucosal endoscopic resections.

Nearly 70%-90% of gastrointestinal and 50%-80% of pancreatic NENs express the somatostatin receptors, especially somatostatin receptor (SSTR) 2 and SSTR5. The somatostatin receptor imaging (SRI) is useful to establish the diagnosis of NENs, to assess the burden and distribution of the disease (staging), to assess the response to therapy with SSAs or peptide receptor radionuclide therapy (PRRT), and to provide information about prognosis, as SSTR expression is a characteristic feature of well-differentiated NENs. The SRI can reveal evidence of additional metastases in comparison to conventional CT and MRI<sup>[74]</sup>.

Two available SRIs are OctreoScan (octreotide SPECT/CT or <sup>111</sup>In-pentetreotide with SPECT), and <sup>68</sup>Gallium-DOTA-somatostatin analogs with PET/CT. The somatostatin analogs that bind to <sup>68</sup>Gallium-DOTA exist in three different forms including tyrosine octreotide (TOC), TATE (octreotate), and 1-Nal3-octreotide (NOC), thus forming <sup>68</sup>Gallium-DOTATOC, <sup>68</sup>Gallium-DOTATATE, and <sup>68</sup>Gallium-DOTANOC, where DOTA is a linker and TOC/TATE/NOC are somatostatin analogs. ALL the three compounds bind avidly with the SSTR2 and the tumor will light up in the PET scan. There is no special advantage for selecting one over the other<sup>[77]</sup>.

PET/CT used in <sup>68</sup>Gallium-DOTATATE provides better resolution and faster scanning compared to SPECT/CT used in OctreoScan. Moreover, the <sup>68</sup>Gallium-DOTATATE has improved sensitivity for occult primary tumors compared to OctreoScan. However, the <sup>68</sup>Gallium-DOTATATE can be false negative in NENs < 7 mm and can be false positive in inflammatory bowel disease. Uptake can occur in normal tissues such as adrenal, pituitary and uncinate process of pancreas due to presence of SSTR in these tissues. Once the NENs are found to have somatostatin receptors using <sup>68</sup>Gallium-DOTATATE PET/CT, the <sup>68</sup>Gallium-DOTATATE can be replaced by <sup>177</sup>lutetium or <sup>90</sup>yttrium. When given intravenously in 4 cycles that are 8 wk apart, the <sup>177</sup>lutetium-DOTATATE will target the tumor cells by emitting  $\beta$  and  $\gamma$  radiations, forming the basis for the novel treatment known as peptide receptor radionuclide therapy or PRRT<sup>[78]</sup>.

### Grading of NENs

World Health Organization grading of NENs<sup>[79]</sup> is given in Table 3. The mitotic rate is the number of mitoses/2 mm<sup>2</sup>. Though NECs are not formally graded, they are considered high-grade.

### Staging of NENs

Tumor-node-metastasis (TNM) staging of pancreatic NENs based on the American Joint Committee on Cancer (AJCC) and the European Neuroendocrine Tumor Society ENETS (modified ENETS staging)<sup>[80]</sup> and TNM staging of the small intestinal NENs based on AJCC<sup>[81]</sup> is given in Table 4.

### Surgical management of GEP-NENs

The North American Neuroendocrine Tumor Society consensus paper on the surgical management of pancreatic neuroendocrine tumors (2020) has suggested the following surgical options<sup>[82]</sup>. Surgery is indicated for non-functional pNENs that are

**Table 3 World Health Organization grading of neuroendocrine neoplasms<sup>[79]</sup>**

Grade	Terminology	Differentiation	Mitotic rate	Ki-67 index
Low	NET, G1	Well	< 2	< 3
Intermediate	NET, G2	Well	2-20	3-20
High	NET, G3	Well	> 20	> 20
High	NEC, small cell type	Poor	> 20	> 20
High	NEC, large cell type	Poor	> 20	> 20
Variable	MinEN	Well or Poor	Variable	Variable

NEC: Neuroendocrine carcinoma; NET: Neuroendocrine tumours; G1: Grade 1; G2: Grade 2; G3: Grade 3.

**Table 4 Tumor-node-metastasis staging of pancreatic neuroendocrine neoplasms based on the American Joint Committee on Cancer and the European Neuroendocrine Tumor Society (modified European Neuroendocrine Tumor Society staging)<sup>[80]</sup> and tumor-node-metastasis staging of the small intestinal neuroendocrine neoplasms based on American Joint Committee on Cancer<sup>[81]</sup>**

TNM staging of pancreatic neuroendocrine tumours						TNM staging of small intestinal neuroendocrine tumours					
T0						No documented evidence of a primary tumour					
T1	Tumour limited to pancreas, ≤ 2 cm					Tumour invading lamina propria/submucosa, and size ≤ 1 cm					
T2	Tumour limited to pancreas, 2-4 cm					Tumour invading muscularis propria or size ≥ 1 cm					
T3	Tumour limited to pancreas, > 4 cm, or invading duodenum/bile duct					Tumour invading sub-serosa (without penetrating the serosa)					
T4	Tumour invades adjacent structures					Tumour invading peritoneum/other organs/adjacent structures					
N0	Absence of regional lymph node metastasis					Absence of regional lymph node metastasis					
N1	Presence of regional lymph node metastasis					Presence of regional lymph node metastasis in < 12 nodes					
N2	Absence of distant metastasis					Presence of large mesenteric masses (> 2 cm) or ≥ 12 nodes					
M0	Presence of distant metastasis					Absence of distant metastasis					
M1	Metastasis confined to hepatic tissue					Presence of distant metastasis					
M1a	Metastasis in at least one extrahepatic tissue					Metastasis confined to hepatic tissue					
M1b	Both hepatic and extrahepatic metastatic involvement					Metastasis in at least one extrahepatic tissue					
M1c	Tumour limited to pancreas, ≤ 2 cm					Both hepatic and extrahepatic metastatic involvement					
Stage IA	Stage IB	Stage IIA	Stage IIB	Stage III	Stage IV	Stage I	STAGE IIA	Stage IIB	Stage IIIA	Stage IIIB	Stage IV
T1N0M0	T2N0M0	T3N0M0	T1-3N1M0	T4NanyM0	TanyNanyM1	T1N0M0	T2N0M0	T3N0M0	T4N0M0	TanyN0M0	TanyNanyM1

TNM: Tumor-node-metastasis.

symptomatic or ≥ 2 cm in size and for all functional pNENs regardless of their size, except MEN1 associated gastrinomas that are small (< 2 cm). Surveillance is advised for sporadic or MEN1 associated non-functional pNENs that are asymptomatic, small (< 2 cm), and without biliary/pancreatic duct dilatation. Surveillance is also advised for MEN1 associated small (< 2 cm) gastrinomas without metastasis. Standard pancreatic resections are advised for large lesions. Surgery is advised as the treatment of choice for MEN1 associated insulinomas, regardless of their size. Contraindications for surgery include poor general health, extrahepatic metastatic disease, technical issues such as cavernomas, and pancreatic NEC. For G1 and G2 pNETs, the surgery is done with an intention to cure even in the presence of metastasis to lymph nodes or liver, whereas for G3 pNETs the decision (curative *vs* debulking) is still unclear<sup>[83]</sup>.

The surgical management of pNENs depend on multiple factors including age of the individual, location, stage, grade, functional status, and the heredity of the tumor (sporadic *vs* inherited). Two strategies are used in the management of pNENs.



Parenchymal sparing pancreatic resections such as enucleation or central pancreatectomy with lymph node picking are considered for insulinomas and small (< 2 cm) asymptomatic non-functional pNENs, whereas standard pancreatic resections such as pancreaticoduodenectomy, distal pancreatectomy, or total pancreatectomy with regional lymphadenectomy are considered for functional pNENs other than insulinomas and for > 2 cm non-functional pNENs<sup>[83,84]</sup>.

Extensive pancreatic resections are associated with morbidity, exocrine dysfunction (9%-60%) and endocrine dysfunction (7%-35%). For appropriately selected patients (low grade, small NENs), the parenchymal sparing pancreatic resections provide acceptable survival benefits with minimal (< 5%) exocrine and endocrine dysfunction. The enucleation is considered for superficial pNENs that are located 2-3 mm away from main pancreatic duct (confirmed by MRI, EUS, and intraoperative ultrasound). On the contrary, central pancreatectomy is used for low grade pNENs of the neck and first part of the body of the pancreas without involvement of the gastroduodenal artery and common bile duct. Though central pancreatectomy preserves the pancreatic function, the disadvantage is a high rate of pancreatic fistula with resultant rise in postoperative-morbidity and mortality<sup>[85,86]</sup>. Large lesion located in the head of the pancreas may necessitate a pancreaticoduodenectomy. Duodenum preserving pancreatic head resections and pancreas preserving duodenal resections also have roles in highly selected patients.

The pancreatic resections can be open, minimally invasive (laparoscopic) or robot assisted. For operations not requiring reconstructions such as enucleation and distal pancreatectomy, the laparoscopic pancreatectomies provide equivalent short and long-term post-operative outcomes. For patients who are poor candidates for surgery (old age, poor general health) or for whom extensive surgical resections are not desired, radiofrequency ablation can be performed *via* percutaneous, intra-operative, and more commonly endoscopic approaches, with a small risk of pancreatitis in the post-procedure period possibly due to heat that is generated<sup>[87]</sup>.

While considering liver resections for liver metastasis from NENs, the disease burden in the liver, presence of chronic liver disease and volume of the functional liver remnant are important considerations. Patients with G1/G2 pancreatic/small intestinal NETs with type 1 hepatic metastatic burden (corresponding to single metastatic lesion) or selected patients with type 2 hepatic metastatic burden (corresponding to isolated metastatic bulk with accompanying smaller deposits) are suitable for partial hepatectomy. Those who are traditionally not candidates for hepatectomy may be considered for staged liver resections. Non-anatomical liver resections or a combination of anatomical and non-anatomical resections can be considered depending on the location of lesions. Some patients may benefit from total hepatectomy and liver transplantation. Several ablative therapies are used in the treatment of liver metastasis from NENs, as an adjunct to partial hepatectomy or for rapid symptom control or sometimes as the sole feasible therapy for the lesion. Ablative therapies include radiofrequency, microwave, laser or cryoablation. Transarterial interventional procedures include trans-arterial embolisation, trans-arterial chemoembolization and selective internal radiotherapy with Yttrium-90 particles (radioembolization). Best results are obtained for liver metastases that are of < 5 cm with ablation margins of > 1 cm<sup>[88]</sup>.

All patients with small intestinal NETs of grade G1-G3 that is localized to small intestine with or without regional metastasis to mesentery should be considered for curative small intestinal resection after precise intra-operative exploration of small bowel to identify sub-centimetre sized multifocal lesions which are often not detectable even on a gold-standard imaging in up to 70% of cases<sup>[89]</sup>. While focus is on preserving the small bowel, curative small intestinal resections should incorporate excision of the involved lymph nodes and the peritoneal carcinomatosis, as missing the skipped lymph node metastases can cause locoregional recurrence and the peritoneal carcinomatosis may cause intestinal obstruction. Even in the setting of unresectable hepatic metastases, resection of primary tumor is advisable to avoid ileus, intestinal obstruction, and desmoplastic reaction. Selected patients with small intestinal NENs with mesenteric node metastasis that are beyond the scope of the limit of small intestinal resection might benefit from intestinal transplantation to avoid development of short bowel syndrome. Surgical resections have impact in local recurrence and recurrence at distant sites in patients with good performance status. Moreover, surgical resections act as adjuvant to other therapies<sup>[89]</sup>.

### Medical management of GEP-NENs

Indications for medical management in pNETs are to alleviate the symptoms from functional NETs, to manage unresectable/incompletely resected pNETs, to suppress

postoperative tumor growth and to manage recurrent pNETs. Symptomatic therapy for GEP-NENs include proton pump inhibitors for gastrinoma related hyperacidity, diazoxide and frequent small meals for insulinoma related hypoglycaemia, hydration for VIPomas and somatostatinomas, SSAs for carcinoid syndrome related flushing and diarrhoea (by virtue of anti-secretory effect), and pancreatic enzyme supplementation for patients with exocrine pancreatic insufficiency<sup>[90]</sup>.

SSAs, by virtue of anti-proliferative effect, are considered the first line agents for the medical management of patients with high burden of well-differentiated, locally advanced, metastatic, unresectable GEP-NETs<sup>[91]</sup>. Octreotide and lanreotide are SSAs with high affinity to SSTR2, and moderate affinity to SSTR3 and SSTR5. Pasireotide has affinity for all SSTRs except SSTR4. Even though the antiproliferative effect is a class effect, lanreotide Autogel is preferred over octreotide long-acting release (LAR) in the management of pNENs based on the CLARINET study where lanreotide significantly prolonged the progression-free survival among metastatic enteropancreatic G1/2 NETs with Ki-67 < 10% from 33% with placebo to 65.1%<sup>[92]</sup>.

In patients with carcinoid syndrome 74.2% of cases on octreotide LAR and 67% of cases on lanreotide Autogel showed improvement in diarrhoea and flushing<sup>[93]</sup>. Moreover, in the PROMID study, those patients with well differentiated locally advanced/metastatic intestinal NENs treated with octreotide LAR showed a significantly prolonged time to progression (hazard ratio 0.34; 95% confidence interval (95% CI), 0.20-0.59;  $P = 0.000072$ ), indicating that SSAs can stabilize the tumor growth<sup>[94]</sup>. In some NENs including gastric NENs, the SSAs can even cause tumor regression<sup>[95]</sup>. Long acting SSAs are the standard therapy, whereas short acting agents are used as rescue drugs. Some patients showing signs of clinical, biochemical, or radiological progression while on therapy with SSAs can be treated by increasing the frequency of SSAs.

The PI3K-AKT-mTOR pathway, which has a physiological role in protein synthesis, cell growth and cell metabolism, is dysregulated in various tumours including GEP NENs. This pathway has a central role in the initiation and progression of various GEP NENs. Moreover, it is involved in the development of chemoresistance<sup>[96]</sup>. The molecular-targeted therapies are agents that targets the PI3K-AKT-mTOR pathway. The vascular EGF (VEGF) and PDGF are drivers of angiogenesis contributing to the development of GEP NENs. Therefore, mTOR inhibitors and angiogenesis inhibitors are developed in the medical management of GEP NENs<sup>[97]</sup>.

Molecular-targeted therapies including everolimus and sunitinib are considered as the second line medical agents that can be used in locally advanced, unresectable, or metastatic disease following failure of somatostatin analogue. Everolimus and temsirolimus are mTOR inhibitors (mammalian target of rapamycin inhibitor). Sunitinib is a dual VEGF/PDGF receptor inhibitor and it belong to the family multitargeted tyrosine kinase inhibitors, as receptors for VEGF and PDGF are tyrosine kinases<sup>[98]</sup>. Treatment of advanced well-differentiated pNENs and intestinal NENs with everolimus was associated with significant prolongation in progression free survival in the RADIANT trial program<sup>[99]</sup>. Therapy of patients with advanced well differentiated pancreatic NETs with sunitinib is associated with significant prolongation in progression free survival and overall survival, though there is insufficient data about gastrointestinal NETs<sup>[100]</sup>. Hence everolimus or sunitinib can be considered as first-line in patients with advanced pancreatic G1/2 NENs and reduced SSTR expression, or as second-line in patients with normal SSTR expression (OctreoScan or <sup>68</sup>Ga-PET/CT). Everolimus is considered as second-line agent in patients with advanced non-functional gastrointestinal G1/G2 NENs that are refractory to SSAs or PRRT. Sunitinib and bevacizumab have no proven data in this group. Moreover, everolimus is better than sunitinib for initiating molecular targeted therapy in patients with progressive NENs<sup>[101]</sup>.

Other multi-targeted tyrosine kinase inhibitors such as pazopanib, sorafenib, axitinib, surufatinib, lenvatinib, and cabozantinib have shown promising response in patients with advanced pancreatic NETs<sup>[98]</sup>. The combination of temsirolimus with bevacizumab, a monoclonal anti-VEGF antibody, has shown substantial response in 41% of locally advanced, or metastatic, well-differentiated to moderately differentiated progressive pancreatic NETs<sup>[102]</sup>. Bevacizumab is undergoing trials with atezolizumab, a monoclonal antibody against PDL-1 or ligand 1 of programmed cell death immune check point, in advanced or progressive NETs (ClinicalTrials.gov Identifier: NCT03074513)<sup>[103]</sup>.

Before the advent of molecular targeted therapy, well differentiated advanced pancreatic NENs with high tumor load and rapid growth were treated with streptozotocin in combination with 5-fluorouracil or doxorubicin with a response rate of 69%. The first line treatment for pancreatic and small intestinal NEC was platinum-

based therapy, whereas the second line treatments were folinic acid, 5-fluorouracil, oxaliplatin (FOLFOX) or folinic acid, fluorouracil, and irinotecan (FOLFIRI)<sup>[104]</sup>. Capecitabine and temozolomide combination has become more popular with better response rates in patients with advanced G1/G2 pancreatic NETs with high tumor load, significant clinical, biochemical, or radiological progression, advanced G3 pancreatic NETs and even in NEC. Systemic chemotherapy is not efficacious in small intestinal NENs (they are not as chemo sensitive as pNENs) and is not recommended, with the only exception of capecitabine and temozolomide combination therapy that can be used in carefully selected well differentiated NETs with rapid progression, and high tumor burden<sup>[105]</sup>.

The ERASMUS study which evaluated the effect of <sup>177</sup>Lutetium on various SSTR positive tumor types including pancreas, foregut, midgut, hindgut and bronchial NENs, observed a consistent prolongation of progression free survival and overall survival across various tumor types with PRRT<sup>[106]</sup>. In NETTER trial, where patients with advanced SSTR positive well differentiated metastatic midgut NETs received either <sup>177</sup>Lu-DOTATATE plus low dose octreotide LAR (30 mg) or high dose octreotide LAR (60mg), the patients on <sup>177</sup>Lu-DOTATATE arm were associated with prolongation in progression free survival from 8.5 mo to 28.5 mo with significant symptomatic improvement and superior quality of life compared to high dose SSA therapy<sup>[107]</sup>. Though PRRT is not indicated for metastatic, inoperable, well differentiated pancreatic NETs, it is recommended in these patients when all other treatments fail<sup>[108]</sup>. The prerequisite for PRRT is SSTR positivity. The SSTR positive FDG-PET/CT negative patients respond superiorly to PRRT compared to FDG-PET/CT positive patients. FDG-PET/CT positive patients might benefit from a combination of PRRT and capecitabine, which is a radiosensitizer<sup>[109]</sup>. Telotristat etiprate is an oral inhibitor of tryptophan hydroxylase enzyme, the rate-limiting step in the conversion of tryptophan to serotonin. In the TELESTAR study where patients with metastatic NETs and carcinoid syndrome were randomized to receive telotristat or placebo, the drug resulted in sustained improvement in bowel frequency with improvement in quality of life<sup>[110]</sup>.

A recent systematic review and network meta-analysis of 30 randomized controlled trials<sup>[111]</sup> observed seven efficient treatment options for pNENs including everolimus with hazard ratio of 0.35 (95%CI: 0.28-0.45), everolimus plus SSA 0.35 (95%CI: 0.25-0.51), everolimus plus bevacizumab plus SSA 0.44 (95%CI: 0.26-0.75), interferon 0.37 (95%CI: 0.16-0.83), interferon plus SSA 0.31 (95%CI: 0.13-0.71), sunitinib 0.42 (95%CI: 0.26-0.67), and SSA alone 0.46 (95%CI: 0.33-0.66). Similarly, five efficient treatment options were observed for GEP-NENs including bevacizumab plus SSA 0.22 (95%CI: 0.05-0.99), everolimus plus SSA 0.31 (95%CI: 0.11-0.90), interferon plus SSA 0.27 (95%CI: 0.07-0.96), PRRT plus SSA 0.08 (95%CI: 0.03-0.26), and SSA alone 0.40 (95%CI: 0.21-0.78). Thus, combination therapy is appropriate for NENs.

A summary of surgical and medical management of the pancreatic and small intestinal NENs is given in [Figure 2](#). An insight into the endoscopic and surgical managements for other GEP-NENs<sup>[112,113]</sup> based on the location, grade, and size of the tumor is given in the [Table 5](#).

## CONCLUSION

Surgery remains the cornerstone for the curative treatment of well-differentiated GEP-NENs of G1/G2 grade and for selected patients of G3 grade. Pancreatectomies are indicated for functional pNENs and asymptomatic non-functional pNENs > 2 cm. Small intestinal NENs of G1-G3 grade that is localized to small intestine with or without metastasis to mesentery should be considered for curative small intestinal resection, and selected patients who are not amenable for that might benefit from intestinal transplantation. Patients with resectable hepatic metastasis should be treated with partial hepatectomy, and those with unresectable hepatic metastasis should be treated with ablative procedures or liver transplantation. For GEP-NENs with SSTR expression, the SSAs are considered as the 1<sup>st</sup> line and the molecular targeted therapies with everolimus is considered as the 2<sup>nd</sup> line. PRRT is increasingly used in advanced NENs when all other therapies fail. The pNENs respond to streptozotocin based regimen, whereas small-intestinal NENs do not. The 1<sup>st</sup> line therapy for GEP-NEC is platinum-based regimen, whereas FOLFIRI and FOLFOX have shown promise as 2<sup>nd</sup> line therapies.

The last decade has witnessed a significant improvement in our understanding regarding the complex molecular pathways involved in the development of GEP-

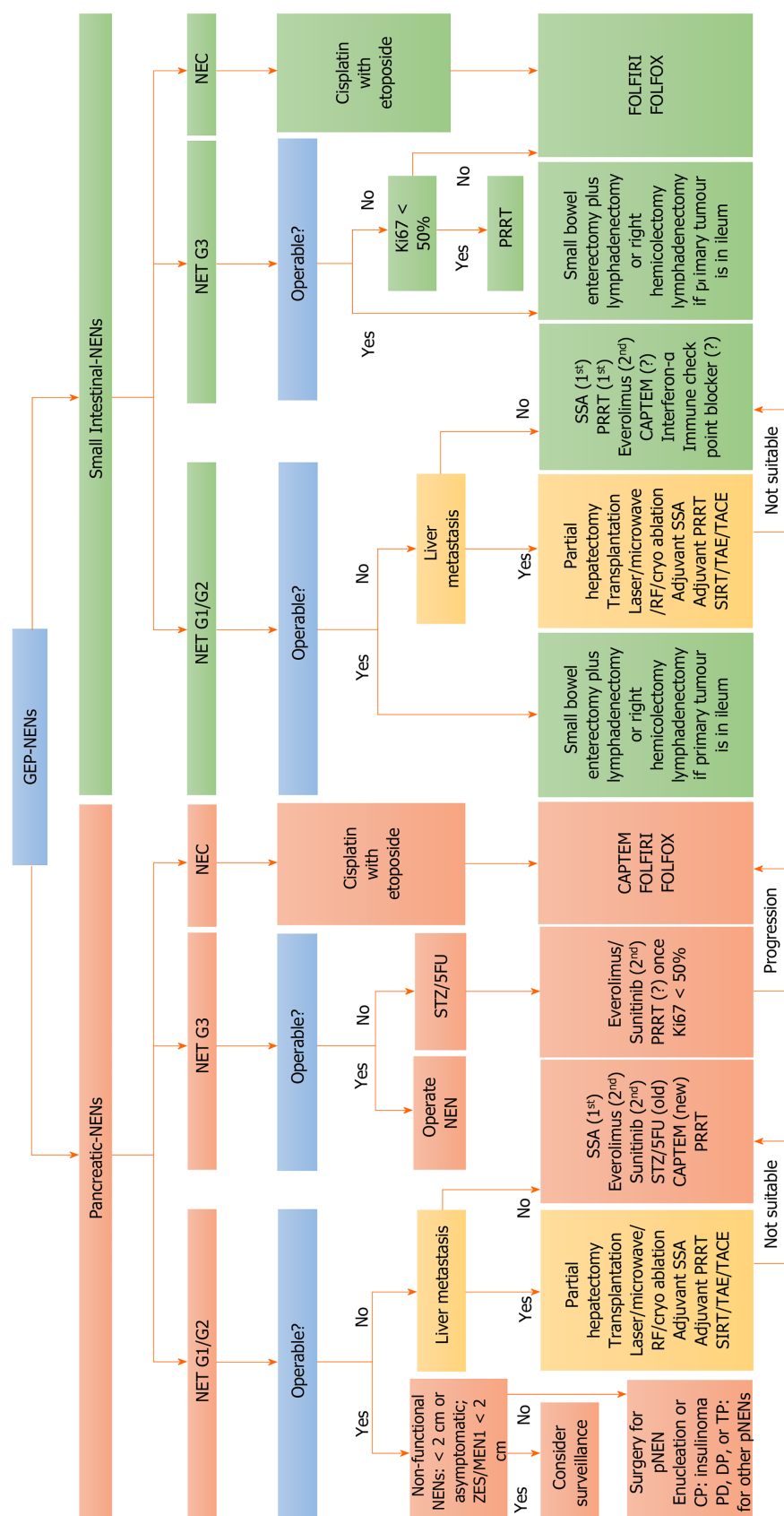
**Table 5 Endoscopic and surgical management of gastroenteropancreatic-neuroendocrine neoplasms based on the location, grade, and size of the tumor<sup>[12,113]</sup>**

Site of NENs	Type of NENs	Laboratory tests required	Abnormal results expected	Surveillance	Endoscopy (EMR/ESD)	Operation
Gastric NEN	Type 1 and type 2	CgA and gastrin	Raised CgA and gastrin	< 1 cm	1-2 cm: EMR or ESD	> 2 cm; local wedge resection
	Type 3 and type 4	CgA and gastrin	Raised CgA, normal gastrin	-	< 1 cm G1/2 type 3	> 1 cm; treat as adenocarcinoma
Duodenal NENs	1 <sup>st</sup> part duodenum	CgA, gastrin, PP, 5-HIAA	Raised CgA, consider MEN1	-	< 1 cm G1 (EMR, not ESD; ESD increase perforation)	< 1 cm any other grade; > 1 cm any grade; gastrinoma and NEC any size
	Ampullary	CgA, somatostatin	Consider MEN1/NF1/VHL/TSC	-	< 2 cm G1: Papillectomy	> 2 cm or < 2 cm with G2/3: Surgery
Jejunioileal NENs	-	CgA, 5-HIAA, NKA	Raised CgA, 5-HIAA and NKA	-	-	Preoperative SSAs, look for CaHD, peroperative palpation-multifocal
Appendiceal NENs	-	CgA, 5-HIAA, NKA, PP	Not raised unless metastatic	-	-	< 2 cm: Appendectomy; > 2 cm: Right hemicolectomy
Colonic NENs	-	CgA, 5-HIAA, NKA, PP	Raised CgA, 5-HIAA and NKA	-	< 1 cm for G1, lack of submucosa infiltration	< 1 cm for G2/G3, muscle infiltrate or angioinvasion; > 1 cm any grade: Treat as adenocarcinoma with segmental colectomy and wide regional lymphadenectomy
Rectal NENs	-	CgA, PP, enteroglucagon, $\beta$ -hCG	Raised CgA, PP, $\beta$ -hCG and enteroglucagon	-	< 1 cm G1/2 (EMR/ESD)	1-2 cm G1/2, no nodal metastasis: Transanal resection; > 2 cm G1/2 with nodal spread, any size G3: Treat as adenocarcinoma
Pancreatic NENs	Functional pNEN, Non-functional pNEN, pNEN with MEN1 and inherited conditions	CgA, insulin, gastrin, VIP, glucagon, somatostatin, glucose, calcium, PTH, PP, prolactin, MEN1 genetics	Raised CgA: Metastatic NENs Raised hormones: F-pNENs Raised calcium, prolactin, PTH: Consider MEN1	Sporadic or MEN1 related NF-pNENs asymptomatic and < 2 cm; MEN1 related ZES < 2 cm	Sporadic or MEN1 related asymptomatic NF-pNEN and < 2 cm; insulinoma (pNENs with very low cancer risk)	NF-pNENs symptomatic or $\geq$ 2 cm; functional pNEN of any size except insulinoma. Open or robot assisted surgery. Robot assisted surgery: For precise reconstruction

NENs: Neuroendocrine neoplasms; pNENs: Pancreatic NENs; F-pNENs: Functional pNENs; NF-pNENs: Non-functional pNENs; CgA: Chromogranin A; 5-HIAA: 5-hydroxy indole acetic acid; NKA: Neurokinin A; PTH: Parathyroid hormone; PP: Pancreatic polypeptide; VIP: Vasoactive intestinal peptide; hCG: Human chorionic gonadotrophin; MEN1: Multiple endocrine neoplasia 1; NF1: Type 1 neurofibromatosis; VHL: Von Hippel-Lindau; TSC: Tuberous sclerosis; ZES: Zollinger Ellison syndrome; NEC: Neuroendocrine carcinoma; SSAs: Somatostatin analogues; CaHD: Carcinoid heart disease; EMR: Endoscopic mucosal resection; ESD: Endoscopic submucosal dissection; G1: Grade 1; G2: Grade 2; G3: Grade 3.

NENs. Newer biomarkers have been developed to facilitate the diagnosis, and to predict the prognosis. Newer treatment modalities with enhanced tumor control and symptom control are made available. However, the biggest challenge is the uncertainty regarding the most appropriate treatment algorithm. Patient characteristics, preferences, and the availability of treatment modalities in the local area would determine the appropriate algorithm. A multidisciplinary team approach with inputs from experts from various fields is needed to tailor an individualized diagnostic and therapeutic strategy that would improve the patient's long-term prognosis.





**Figure 2 Surgical and medical management of pancreatic and small intestinal neuroendocrine neoplasms<sup>[80-91]</sup>.** GEP: Gastroenteropancreatic; NENs: Neuroendocrine neoplasms; pNENs: Pancreatic NENs; NET: Neuroendocrine tumor; NEC: Neuroendocrine carcinoma; ZES/MEN1: Zollinger Ellison Syndrome with multiple endocrine neoplasia 1; STZ/5FU: Streptozotocin/5-fluorouracil; PRRT: Peptide receptor radionuclide therapy; SSA: Somatostatin analogues; SIRT: Selective internal radiotherapy; TAE: Transarterial embolisation; TACE: Transarterial chemoembolization; CAPTEM: Capecitabine and temozolomide; FOLFOX: Folinic acid, 5-fluorouracil and oxaliplatin; FOLFIRI: Folinic acid, fluorouracil, and irinotecan; CP: Central pancreatectomy; DP: Distal pancreatectomy; PD: Pancreaticoduodenectomy; TP: Total pancreatectomy; G1: Grade 1; G2: Grade 2; G3: Grade 3.

## REFERENCES

- 1 **Ahlman H**, Nilsson. The gut as the largest endocrine organ in the body. *Ann Oncol* 2001; **12** Suppl 2: S63-S68 [PMID: [11762354](#) DOI: [10.1093/annonc/12.suppl\\_2.s63](#)]
- 2 **Worthington JJ**, Reimann F, Gribble FM. Enteroendocrine cells-sensory sentinels of the intestinal environment and orchestrators of mucosal immunity. *Mucosal Immunol* 2018; **11**: 3-20 [PMID: [28853441](#) DOI: [10.1038/mi.2017.73](#)]
- 3 **Pearse AG**. The APUD concept and hormone production. *Clin Endocrinol Metab* 1980; **9**: 211-222 [PMID: [6105028](#) DOI: [10.1016/s0300-595x\(80\)80030-2](#)]
- 4 **Zandee WT**, Kamp K, van Adrichem RC, Feelders RA, de Herder WW. Effect of hormone secretory syndromes on neuroendocrine tumor prognosis. *Endocr Relat Cancer* 2017; **24**: R261-R274 [PMID: [28483790](#) DOI: [10.1530/ERC-16-0538](#)]
- 5 **Perren A**, Couvelard A, Scoazec JY, Costa F, Borbath I, Delle Fave G, Gorbounova V, Gross D, Grossma A, Jense RT, Kulke M, Oeberg K, Rindi G, Sorbye H, Welin S; Antibes Consensus Conference participants. ENETS Consensus Guidelines for the Standards of Care in Neuroendocrine Tumors: Pathology: Diagnosis and Prognostic Stratification. *Neuroendocrinology* 2017; **105**: 196-200 [PMID: [28190015](#) DOI: [10.1159/000457956](#)]
- 6 **Klimstra DS**, Modlin IR, Coppola D, Lloyd RV, Suster S. The pathologic classification of neuroendocrine tumors: a review of nomenclature, grading, and staging systems. *Pancreas* 2010; **39**: 707-712 [PMID: [20664470](#) DOI: [10.1097/MPA.0b013e3181ec124e](#)]
- 7 **Kyriakopoulos G**, Mavroei V, Chatzellis E, Kaltsas GA, Alexandraki KI. Histopathological, immunohistochemical, genetic and molecular markers of neuroendocrine neoplasms. *Ann Transl Med* 2018; **6**: 252 [PMID: [30069454](#) DOI: [10.21037/atm.2018.06.27](#)]
- 8 **Klöppel G**, Rindi G, Perren A, Komminoth P, Klimstra DS. The ENETS and AJCC/UICC TNM classifications of the neuroendocrine tumors of the gastrointestinal tract and the pancreas: a statement. *Virchows Arch* 2010; **456**: 595-597 [PMID: [20422210](#) DOI: [10.1007/s00428-010-0924-6](#)]
- 9 **Niederle MB**, Hackl M, Kaserer K, Niederle B. Gastroenteropancreatic neuroendocrine tumours: the current incidence and staging based on the WHO and European Neuroendocrine Tumour Society classification: an analysis based on prospectively collected parameters. *Endocr Relat Cancer* 2010; **17**: 909-918 [PMID: [20702725](#) DOI: [10.1677/ERC-10-0152](#)]
- 10 **Rindi G**, Klersy C, Albarello L, Baudin E, Bianchi A, Buchler MW, Caplin M, Couvelard A, Cros J, de Herder WW, Delle Fave G, Doglioni C, Federspiel B, Fischer L, Fusai G, Gavazzi F, Hansen CP, Inzani F, Jann H, Komminoth P, Knigge UP, Landoni L, La Rosa S, Lawlor RT, Luong TV, Marinoni I, Panzuto F, Pape UF, Partelli S, Perren A, Rinzivillo M, Rubini C, Ruszniewski P, Scarpa A, Schmitt A, Schinzari G, Scoazec JY, Sessa F, Solcia E, Spaggiari P, Toumpanakis C, Vanoli A, Wiedenmann B, Zamboni G, Zandee WT, Zerbi A, Falconi M. Competitive Testing of the WHO 2010 versus the WHO 2017 Grading of Pancreatic Neuroendocrine Neoplasms: Data from a Large International Cohort Study. *Neuroendocrinology* 2018; **107**: 375-386 [PMID: [30300897](#) DOI: [10.1159/000494355](#)]
- 11 **Dasari A**, Shen C, Halperin D, Zhao B, Zhou S, Xu Y, Shih T, Yao JC. Trends in the Incidence, Prevalence, and Survival Outcomes in Patients With Neuroendocrine Tumors in the United States. *JAMA Oncol* 2017; **3**: 1335-1342 [PMID: [28448665](#) DOI: [10.1001/jamaoncol.2017.0589](#)]
- 12 **Pavel M**, Öberg K, Falconi M, Krenning EP, Sundin A, Perren A, Berruti A; ESMO Guidelines Committee. Electronic address: [clinicalguidelines@esmo.org](mailto:clinicalguidelines@esmo.org). Gastroenteropancreatic neuroendocrine neoplasms: ESMO Clinical Practice Guidelines for diagnosis, treatment and follow-up. *Ann Oncol* 2020; **31**: 844-860 [PMID: [32272208](#) DOI: [10.1016/j.annonc.2020.03.304](#)]
- 13 **Rindi G**, Inzani F. Neuroendocrine neoplasm update: toward universal nomenclature. *Endocr Relat Cancer* 2020; **27**: R211-R218 [PMID: [32276263](#) DOI: [10.1530/ERC-20-0036](#)]
- 14 **Roberto GA**, Rodrigues CMB, Peixoto RD, Younes RN. Gastric neuroendocrine tumor: A practical literature review. *World J Gastrointest Oncol* 2020; **12**: 850-856 [PMID: [32879663](#) DOI: [10.4251/wjgo.v12.i8.850](#)]
- 15 **Kaltsas G**, Caplin M, Davies P, Ferone D, Garcia-Carbonero R, Grozinsky-Glasberg S, Hörsch D, Tiensuu Janson E, Kianmanesh R, Kos-Kudla B, Pavel M, Rinke A, Falconi M, de Herder WW; Antibes Consensus Conference participants. ENETS Consensus Guidelines for the Standards of Care in Neuroendocrine Tumors: Pre- and Perioperative Therapy in Patients with Neuroendocrine Tumors. *Neuroendocrinology* 2017; **105**: 245-254 [PMID: [28253514](#) DOI: [10.1159/000461583](#)]
- 16 **Hofland J**, Kaltsas G, de Herder WW. Advances in the Diagnosis and Management of Well-Differentiated Neuroendocrine Neoplasms. *Endocr Rev* 2020; **41** [PMID: [31555796](#) DOI: [10.1210/endrev/bnz004](#)]
- 17 **Wang R**, Zheng-Pywell R, Chen HA, Bibb JA, Chen H, Rose JB. Management of Gastrointestinal Neuroendocrine Tumors. *Clin Med Insights Endocrinol Diabetes* 2019; **12**: 1179551419884058 [PMID: [31695546](#) DOI: [10.1177/1179551419884058](#)]
- 18 **Niederle B**, Pape UF, Costa F, Gross D, Kelestimur F, Knigge U, Öberg K, Pavel M, Perren A, Toumpanakis C, O'Connor J, O'Toole D, Krenning E, Reed N, Kianmanesh R; Vienna Consensus Conference participants. ENETS Consensus Guidelines Update for Neuroendocrine Neoplasms of the Jejunum and Ileum. *Neuroendocrinology* 2016; **103**: 125-138 [PMID: [26758972](#) DOI: [10.1159/000443170](#)]
- 19 **Tsoli M**, Chatzellis E, Koumariou A, Kolomodi D, Kaltsas G. Current best practice in the management of neuroendocrine tumors. *Ther Adv Endocrinol Metab* 2019; **10**: 2042018818804698

- [PMID: 30800264 DOI: 10.1177/2042018818804698]
- 20 **Koumariannou A**, Alexandraki KI, Wallin G, Kaltsas G, Daskalakis K. Pathogenesis and Clinical Management of Mesenteric Fibrosis in Small Intestinal Neuroendocrine Neoplasms: A Systematic Review. *J Clin Med* 2020; **9** [PMID: 32521677 DOI: 10.3390/jcm9061777]
  - 21 **Fox DJ**, Khattar RS. Carcinoid heart disease: presentation, diagnosis, and management. *Heart* 2004; **90**: 1224-1228 [PMID: 15367531 DOI: 10.1136/hrt.2004.040329]
  - 22 **Ahmed M**. Gastrointestinal neuroendocrine tumors in 2020. *World J Gastrointest Oncol* 2020; **12**: 791-807 [PMID: 32879660 DOI: 10.4251/wjgo.v12.i8.791]
  - 23 **Vanoli A**, La Rosa S, Klersy C, Grillo F, Albarello L, Inzani F, Maragliano R, Manca R, Luinetti O, Milione M, Doglioni C, Rindi G, Capella C, Solcia E. Four Neuroendocrine Tumor Types and Neuroendocrine Carcinoma of the Duodenum: Analysis of 203 Cases. *Neuroendocrinology* 2017; **104**: 112-125 [PMID: 26910321 DOI: 10.1159/000444803]
  - 24 **Okubo Y**. Gangliocytic paraganglioma: An overview and future perspective. *World J Clin Oncol* 2019; **10**: 300-302 [PMID: 31572665 DOI: 10.5306/wjco.v10.i9.300]
  - 25 **Pape UF**, Niederle B, Costa F, Gross D, Kelestimur F, Kianmanesh R, Knigge U, Öberg K, Pavel M, Perren A, Toumpanakis C, O'Connor J, Krenning E, Reed N, O'Toole D; Vienna Consensus Conference participants. ENETS Consensus Guidelines for Neuroendocrine Neoplasms of the Appendix (Excluding Goblet Cell Carcinomas). *Neuroendocrinology* 2016; **103**: 144-152 [PMID: 26730583 DOI: 10.1159/000443165]
  - 26 **Alexandraki KI**, Kaltsas GA, Grozinsky-Glasberg S, Chatzellis E, Grossman AB. Appendiceal neuroendocrine neoplasms: diagnosis and management. *Endocr Relat Cancer* 2016; **23**: R27-R41 [PMID: 26483424 DOI: 10.1530/ERC-15-0310]
  - 27 **Ramage JK**, De Herder WW, Delle Fave G, Ferolla P, Ferone D, Ito T, Ruzsiewicz P, Sundin A, Weber W, Zheng-Pei Z, Taal B, Pascher A; Vienna Consensus Conference participants. ENETS Consensus Guidelines Update for Colorectal Neuroendocrine Neoplasms. *Neuroendocrinology* 2016; **103**: 139-143 [PMID: 26730835 DOI: 10.1159/000443166]
  - 28 **Caplin M**, Sundin A, Nillson O, Baum RP, Klose KJ, Kelestimur F, Plöckinger U, Papotti M, Salazar R, Pascher A; Barcelona Consensus Conference participants. ENETS Consensus Guidelines for the management of patients with digestive neuroendocrine neoplasms: colorectal neuroendocrine neoplasms. *Neuroendocrinology* 2012; **95**: 88-97 [PMID: 22261972 DOI: 10.1159/000335594]
  - 29 **Dromain C**, Déandréis D, Scoazec JY, Goere D, Ducreux M, Baudin E, Tselikas L. Imaging of neuroendocrine tumors of the pancreas. *Diagn Interv Imaging* 2016; **97**: 1241-1257 [PMID: 27876341 DOI: 10.1016/j.diii.2016.07.012]
  - 30 **Falconi M**, Eriksson B, Kaltsas G, Bartsch DK, Capdevila J, Caplin M, Kos-Kudla B, Kwekkeboom D, Rindi G, Klöppel G, Reed N, Kianmanesh R, Jensen RT; Vienna Consensus Conference participants. ENETS Consensus Guidelines Update for the Management of Patients with Functional Pancreatic Neuroendocrine Tumors and Non-Functional Pancreatic Neuroendocrine Tumors. *Neuroendocrinology* 2016; **103**: 153-171 [PMID: 26742109 DOI: 10.1159/000443171]
  - 31 **Granata V**, Fusco R, Setola SV, Castelfidone ELD, Camera L, Tafuto S, Avallone A, Belli A, Incollingo P, Palaia R, Izzo F, Petrillo A. The multidisciplinary team for gastroenteropancreatic neuroendocrine tumours: the radiologist's challenge. *Radiol Oncol* 2019; **53**: 373-387 [PMID: 31652122 DOI: 10.2478/raon-2019-0040]
  - 32 **Jensen RT**, Berna MJ, Bingham DB, Norton JA. Inherited pancreatic endocrine tumor syndromes: advances in molecular pathogenesis, diagnosis, management, and controversies. *Cancer* 2008; **113**: 1807-1843 [PMID: 18798544 DOI: 10.1002/cncr.23648]
  - 33 **Jensen RT**, Cadiot G, Brandi ML, de Herder WW, Kaltsas G, Komminoth P, Scoazec JY, Salazar R, Sauvanet A, Kianmanesh R; Barcelona Consensus Conference participants. ENETS Consensus Guidelines for the management of patients with digestive neuroendocrine neoplasms: functional pancreatic endocrine tumor syndromes. *Neuroendocrinology* 2012; **95**: 98-119 [PMID: 22261919 DOI: 10.1159/000335591]
  - 34 **Toiari M**, Davi MV, Dalle Carbonare L, Boninsegna L, Castellani C, Falconi M, Francia G. Presentation, diagnostic features and glucose handling in a monocentric series of insulinomas. *J Endocrinol Invest* 2013; **36**: 753-758 [PMID: 23608735 DOI: 10.3275/8942]
  - 35 **Anlauf M**, Garbrecht N, Henopp T, Schmitt A, Schlenger R, Raffel A, Krausch M, Gimm O, Eisenberger CF, Knoefel WT, Dralle H, Komminoth P, Heitz PU, Perren A, Klöppel G. Sporadic versus hereditary gastrinomas of the duodenum and pancreas: distinct clinico-pathological and epidemiological features. *World J Gastroenterol* 2006; **12**: 5440-5446 [PMID: 17006979 DOI: 10.3748/wjg.v12.i34.5440]
  - 36 **Anlauf M**, Perren A, Meyer CL, Schmid S, Saremaslani P, Kruse ML, Weihe E, Komminoth P, Heitz PU, Klöppel G. Precursor lesions in patients with multiple endocrine neoplasia type 1-associated duodenal gastrinomas. *Gastroenterology* 2005; **128**: 1187-1198 [PMID: 15887103 DOI: 10.1053/j.gastro.2005.01.058]
  - 37 **Shao QQ**, Zhao BB, Dong LB, Cao HT, Wang WB. Surgical management of Zollinger-Ellison syndrome: Classical considerations and current controversies. *World J Gastroenterol* 2019; **25**: 4673-4681 [PMID: 31528093 DOI: 10.3748/wjg.v25.i32.4673]
  - 38 **Jensen RT**. Consequences of long-term proton pump blockade: insights from studies of patients with gastrinomas. *Basic Clin Pharmacol Toxicol* 2006; **98**: 4-19 [PMID: 16433886 DOI: 10.1111/j.1742-7843.2006.pto\_378.x]
  - 39 **Berna MJ**, Hoffmann KM, Long SH, Serrano J, Gibril F, Jensen RT. Serum gastrin in Zollinger-

- Ellison syndrome: II. Prospective study of gastrin provocative testing in 293 patients from the National Institutes of Health and comparison with 537 cases from the literature. evaluation of diagnostic criteria, proposal of new criteria, and correlations with clinical and tumoral features. *Medicine (Baltimore)* 2006; **85**: 331-364 [PMID: [17108779](#) DOI: [10.1097/MD.0b013e31802b518c](#)]
- 40 **Rehfeld JF**, Federspiel B, Bardram L. A neuroendocrine tumor syndrome from cholecystokinin secretion. *N Engl J Med* 2013; **368**: 1165-1166 [PMID: [23514309](#) DOI: [10.1056/NEJMc1215137](#)]
  - 41 **Castro PG**, de León AM, Trancón JG, Martínez PA, Alvarez Pérez JA, Fernández Fernández JC, García Bernardo CM, Serra LB, González González JJ. Glucagonoma syndrome: a case report. *J Med Case Rep* 2011; **5**: 402 [PMID: [21859461](#) DOI: [10.1186/1752-1947-5-402](#)]
  - 42 **Tseng HC**, Liu CT, Ho JC, Lin SH. Necrolytic migratory erythema and glucagonoma rising from pancreatic head. *Pancreatol* 2013; **13**: 455-457 [PMID: [23890147](#) DOI: [10.1016/j.pan.2013.03.011](#)]
  - 43 **Halvorson SA**, Gilbert E, Hopkins RS, Liu H, Lopez C, Chu M, Martin M, Sheppard B. Putting the pieces together: necrolytic migratory erythema and the glucagonoma syndrome. *J Gen Intern Med* 2013; **28**: 1525-1529 [PMID: [23681843](#) DOI: [10.1007/s11606-013-2490-5](#)]
  - 44 **Tolliver S**, Graham J, Kaffenberger BH. A review of cutaneous manifestations within glucagonoma syndrome: necrolytic migratory erythema. *Int J Dermatol* 2018; **57**: 642-645 [PMID: [29450880](#) DOI: [10.1111/ijd.13947](#)]
  - 45 **Vianna PM**, Ferreira CR, de Campos FPF. Somatostatinoma syndrome: a challenging differential diagnosis among pancreatic tumors. *Autops Case Rep* 2013; **3**: 29-37 [PMID: [31528595](#) DOI: [10.4322/acr.2013.005](#)]
  - 46 **Pacak K**, Jochmanova I, Prodanov T, Yang C, Merino MJ, Fojo T, Prchal JT, Tischler AS, Lechan RM, Zhuang Z. New syndrome of paraganglioma and somatostatinoma associated with polycythemia. *J Clin Oncol* 2013; **31**: 1690-1698 [PMID: [23509317](#) DOI: [10.1200/JCO.2012.47.1912](#)]
  - 47 **Garbrecht N**, Anlauf M, Schmitt A, Henopp T, Sipos B, Raffel A, Eisenberger CF, Knoefel WT, Pavel M, Fottner C, Musholt TJ, Rinke A, Arnold R, Berndt U, Plöckinger U, Wiedenmann B, Moch H, Heitz PU, Komminoth P, Perren A, Klöppel G. Somatostatin-producing neuroendocrine tumors of the duodenum and pancreas: incidence, types, biological behavior, association with inherited syndromes, and functional activity. *Endocr Relat Cancer* 2008; **15**: 229-241 [PMID: [18310290](#) DOI: [10.1677/ERC-07-0157](#)]
  - 48 **Martin S**, Fica S, Parfeni O, Popa L, Manuc T, Rizea O, Lupescu I, Gherghie M, Becheanu G, Croitoru A. Somatostatinoma and Neurofibromatosis Type 1-A Case Report and Review of the Literature. *Diagnostics (Basel)* 2020; **10** [PMID: [32825782](#) DOI: [10.3390/diagnostics10090620](#)]
  - 49 **Peng SY**, Li JT, Liu YB, Fang HQ, Wu YL, Peng CH, Wang XB, Qian HR. Diagnosis and treatment of VIPoma in China: (case report and 31 cases review) diagnosis and treatment of VIPoma. *Pancreas* 2004; **28**: 93-97 [PMID: [14707737](#) DOI: [10.1097/00006676-200401000-00015](#)]
  - 50 **Shankar N**, Linzay C, Rowe K. Vasoactive intestinal peptide-oma causing refractory diarrhea in a young woman. *Proc (Bayl Univ Med Cent)* 2020; **33**: 641-643 [PMID: [33100555](#) DOI: [10.1080/08998280.2020.1778963](#)]
  - 51 **Kamp K**, Alwani RA, Korpershoek E, Franssen GJ, de Herder WW, Feelders RA. Prevalence and clinical features of the ectopic ACTH syndrome in patients with gastroenteropancreatic and thoracic neuroendocrine tumors. *Eur J Endocrinol* 2016; **174**: 271-280 [PMID: [26643855](#) DOI: [10.1530/EJE-15-0968](#)]
  - 52 **Han SY**, Kim BH, Jang HR, Kim WJ, Jeon YK, Kim SS, Kim IJ. Ectopic ACTH syndrome caused by pulmonary carcinoid tumor mimicking long-standing sclerosing hemangioma. *Korean J Intern Med* 2016; **31**: 794-797 [PMID: [26828249](#) DOI: [10.3904/kjim.2014.320](#)]
  - 53 **Gola M**, Doga M, Bonadonna S, Mazziotti G, Vescovi PP, Giustina A. Neuroendocrine tumors secreting growth hormone-releasing hormone: Pathophysiological and clinical aspects. *Pituitary* 2006; **9**: 221-229 [PMID: [17036195](#) DOI: [10.1007/s11102-006-0267-0](#)]
  - 54 **Kamp K**, Feelders RA, van Adrichem RC, de Rijke YB, van Nederveen FH, Kwekkeboom DJ, de Herder WW. Parathyroid hormone-related peptide (PTHrP) secretion by gastroenteropancreatic neuroendocrine tumors (GEP-NETs): clinical features, diagnosis, management, and follow-up. *J Clin Endocrinol Metab* 2014; **99**: 3060-3069 [PMID: [24905065](#) DOI: [10.1210/jc.2014-1315](#)]
  - 55 **de Mestier L**, Hentic O, Cros J, Walter T, Roquin G, Brixi H, Lombard-Bohas C, Hammel P, Diebold MD, Couvelard A, Ruszniewski P, Cadiot G. Metachronous hormonal syndromes in patients with pancreatic neuroendocrine tumors: a case-series study. *Ann Intern Med* 2015; **162**: 682-689 [PMID: [25984844](#) DOI: [10.7326/M14-2132](#)]
  - 56 **Crona J**, Norlén O, Antonodimitrakis P, Welin S, Ståhlberg P, Eriksson B. Multiple and Secondary Hormone Secretion in Patients With Metastatic Pancreatic Neuroendocrine Tumours. *J Clin Endocrinol Metab* 2016; **101**: 445-452 [PMID: [26672633](#) DOI: [10.1210/jc.2015-2436](#)]
  - 57 **Clement D**, Ramage J, Srirajaskanthan R. Update on Pathophysiology, Treatment, and Complications of Carcinoid Syndrome. *J Oncol* 2020; **2020**: 8341426 [PMID: [32322270](#) DOI: [10.1155/2020/8341426](#)]
  - 58 **Gade AK**, Olariu E, Douthit NT. Carcinoid Syndrome: A Review. *Cureus* 2020; **12**: e7186 [PMID: [32257725](#) DOI: [10.7759/cureus.7186](#)]
  - 59 **Ploekinger U**, Kloepfel G, Wiedenmann B, Lohmann R; representatives of 21 German NET Centers. The German NET-registry: an audit on the diagnosis and therapy of neuroendocrine tumors. *Neuroendocrinology* 2009; **90**: 349-363 [PMID: [19776553](#) DOI: [10.1159/000242109](#)]



- 60 **Garcia-Carbonero R**, Capdevila J, Crespo-Herrero G, Díaz-Pérez JA, Martínez Del Prado MP, Alonso Orduña V, Sevilla-García I, Villabona-Artero C, Beguiristain-Gómez A, Llanos-Muñoz M, Marazuela M, Alvarez-Escola C, Castellano D, Vilar E, Jiménez-Fonseca P, Teulé A, Sastre-Valera J, Benavent-Viñuelas M, Monleon A, Salazar R. Incidence, patterns of care and prognostic factors for outcome of gastroenteropancreatic neuroendocrine tumors (GEP-NETs): results from the National Cancer Registry of Spain (RGETNE). *Ann Oncol* 2010; **21**: 1794-1803 [PMID: [20139156](#) DOI: [10.1093/annonc/mdq022](#)]
- 61 **Halperin DM**, Shen C, Dasari A, Xu Y, Chu Y, Zhou S, Shih YT, Yao JC. Frequency of carcinoid syndrome at neuroendocrine tumour diagnosis: a population-based study. *Lancet Oncol* 2017; **18**: 525-534 [PMID: [28238592](#) DOI: [10.1016/S1470-2045\(17\)30110-9](#)]
- 62 **Rubin de Celis Ferrari AC**, Glasberg J, Riechelmann RP. Carcinoid syndrome: update on the pathophysiology and treatment. *Clinics (Sao Paulo)* 2018; **73**: e490s [PMID: [30133565](#) DOI: [10.6061/clinics/2018/e490s](#)]
- 63 **Bertin N**, Favretto S, Pelizzo F, Mos L, Pertoldi F, Vrizz O. Carcinoid Heart Disease: Starting From Heart Failure. *J Investig Med High Impact Case Rep* 2017; **5**: 2324709617713511 [PMID: [28634593](#) DOI: [10.1177/2324709617713511](#)]
- 64 **Grozinsky-Glasberg S**, Grossman AB, Gross DJ. Carcinoid Heart Disease: From Pathophysiology to Treatment--'Something in the Way It Moves'. *Neuroendocrinology* 2015; **101**: 263-273 [PMID: [25871411](#) DOI: [10.1159/000381930](#)]
- 65 **Ram P**, Penalver JL, Lo KBU, Rangaswami J, Pressman GS. Carcinoid Heart Disease: Review of Current Knowledge. *Tex Heart Inst J* 2019; **46**: 21-27 [PMID: [30833833](#) DOI: [10.14503/THIJ-17-6562](#)]
- 66 **Mota JM**, Sousa LG, Riechelmann RP. Complications from carcinoid syndrome: review of the current evidence. *Ecancermedicalscience* 2016; **10**: 662 [PMID: [27594907](#) DOI: [10.3332/ecancer.2016.662](#)]
- 67 **Metz DC**, Jensen RT. Gastrointestinal neuroendocrine tumors: pancreatic endocrine tumors. *Gastroenterology* 2008; **135**: 1469-1492 [PMID: [18703061](#) DOI: [10.1053/j.gastro.2008.05.047](#)]
- 68 **Cives M**, Strosberg JR. Gastroenteropancreatic Neuroendocrine Tumors. *CA Cancer J Clin* 2018; **68**: 471-487 [PMID: [30295930](#) DOI: [10.3322/caac.21493](#)]
- 69 **Ma ZY**, Gong YF, Zhuang HK, Zhou ZX, Huang SZ, Zou YP, Huang BW, Sun ZH, Zhang CZ, Tang YQ, Hou BH. Pancreatic neuroendocrine tumors: A review of serum biomarkers, staging, and management. *World J Gastroenterol* 2020; **26**: 2305-2322 [PMID: [32476795](#) DOI: [10.3748/wjg.v26.i19.2305](#)]
- 70 **Modlin IM**, Oberg K, Taylor A, Drozdov I, Bodei L, Kidd M. Neuroendocrine tumor biomarkers: current status and perspectives. *Neuroendocrinology* 2014; **100**: 265-277 [PMID: [25300695](#) DOI: [10.1159/000368363](#)]
- 71 **Kanakis G**, Kaltsas G. Biochemical markers for gastroenteropancreatic neuroendocrine tumours (GEP-NETs). *Best Pract Res Clin Gastroenterol* 2012; **26**: 791-802 [PMID: [23582919](#) DOI: [10.1016/j.bpg.2012.12.006](#)]
- 72 **Yang Z**, Klimstra DS, Hruban RH, Tang LH. Immunohistochemical Characterization of the Origins of Metastatic Well-differentiated Neuroendocrine Tumors to the Liver. *Am J Surg Pathol* 2017; **41**: 915-922 [PMID: [28498280](#) DOI: [10.1097/PAS.0000000000000876](#)]
- 73 **Zhao LH**, Chen C, Mao CY, Xiao H, Fu P, Xiao HL, Wang G. Value of SATB2, ISL1, and TTF1 to differentiate rectal from other gastrointestinal and lung well-differentiated neuroendocrine tumors. *Pathol Res Pract* 2019; **215**: 152448 [PMID: [31133441](#) DOI: [10.1016/j.prp.2019.152448](#)]
- 74 **Sundin A**, Arnold R, Baudin E, Cwikla JB, Eriksson B, Fanti S, Fazio N, Giammarile F, Hicks RJ, Kjaer A, Krenning E, Kwekkeboom D, Lombard-Bohas C, O'Connor JM, O'Toole D, Rockall A, Wiedenmann B, Valle JW, Vullierme MP; Antibes Consensus Conference participants. ENETS Consensus Guidelines for the Standards of Care in Neuroendocrine Tumors: Radiological, Nuclear Medicine & Hybrid Imaging. *Neuroendocrinology* 2017; **105**: 212-244 [PMID: [28355596](#) DOI: [10.1159/000471879](#)]
- 75 **Laskaratos FM**, Walker M, Wilkins D, Tuck A, Ramakrishnan S, Phillips E, Gertner J, Megapanou M, Papantoniou D, Shah R, Banks J, Vlachou E, Garcia-Hernandez J, Woodbridge L, Papadopolou A, Grant L, Theocharidou E, Watkins J, Luong TV, Mandair D, Caplin M, Toumpanakis C. Evaluation of Clinical Prognostic Factors and Further Delineation of the Effect of Mesenteric Fibrosis on Survival in Advanced Midgut Neuroendocrine Tumours. *Neuroendocrinology* 2018; **107**: 292-304 [PMID: [30153671](#) DOI: [10.1159/000493317](#)]
- 76 **Boutsen L**, Jouret-Mourin A, Borbath I, van Maanen A, Weynand B. Accuracy of Pancreatic Neuroendocrine Tumour Grading by Endoscopic Ultrasound-Guided Fine Needle Aspiration: Analysis of a Large Cohort and Perspectives for Improvement. *Neuroendocrinology* 2018; **106**: 158-166 [PMID: [28494461](#) DOI: [10.1159/000477213](#)]
- 77 **Gabriel S**, Garrigue P, Dahan L, Castinetti F, Sebag F, Baumstark K, Archange C, Jha A, Pacak K, Guillet B, Taïeb D. Prospective evaluation of <sup>68</sup>Ga-DOTATATE PET/CT in limited disease neuroendocrine tumours and/or elevated serum neuroendocrine biomarkers. *Clin Endocrinol (Oxf)* 2018; **89**: 155-163 [PMID: [29788534](#) DOI: [10.1111/cen.13745](#)]
- 78 **Baum RP**, Kulkarni HR, Singh A, Kaemmerer D, Mueller D, Prasad V, Hommann M, Robiller FC, Niepsch K, Franz H, Jochems A, Lambin P, Hörsch D. Results and adverse events of personalized peptide receptor radionuclide therapy with <sup>90</sup>Yttrium and <sup>177</sup>Lutetium in 1048 patients with neuroendocrine neoplasms. *Oncotarget* 2018; **9**: 16932-16950 [PMID: [29682195](#) DOI: [10.18653/oncotarget.2018.09.16932-16950](#)]

- 10.18632/oncotarget.24524]
- 79 **WHO Classification of Tumours Editorial Board.** WHO classification of tumours of the digestive system (5th edition). Lyon, France: International Agency for Research on Cancer, 2019
  - 80 **Luo G,** Javed A, Strosberg JR, Jin K, Zhang Y, Liu C, Xu J, Soares K, Weiss MJ, Zheng L, Wolfgang CL, Cives M, Wong J, Wang W, Sun J, Shao C, Tan H, Li J, Ni Q, Shen L, Chen M, He J, Chen J, Yu X. Modified Staging Classification for Pancreatic Neuroendocrine Tumors on the Basis of the American Joint Committee on Cancer and European Neuroendocrine Tumor Society Systems. *J Clin Oncol* 2017; **35**: 274-280 [PMID: 27646952 DOI: 10.1200/JCO.2016.67.8193]
  - 81 **Clift AK,** Kidd M, Bodei L, Toumpanakis C, Baum RP, Oberg K, Modlin IM, Frilling A. Neuroendocrine Neoplasms of the Small Bowel and Pancreas. *Neuroendocrinology* 2020; **110**: 444-476 [PMID: 31557758 DOI: 10.1159/000503721]
  - 82 **Souche R,** Hobeika C, Hain E, Gaujoux S. Surgical Management of Neuroendocrine Tumours of the Pancreas. *J Clin Med* 2020; **9** [PMID: 32947997 DOI: 10.3390/jcm9092993]
  - 83 **Howe JR,** Merchant NB, Conrad C, Keutgen XM, Hallet J, Drebin JA, Minter RM, Lairmore TC, Tseng JF, Zeh HJ, Libutti SK, Singh G, Lee JE, Hope TA, Kim MK, Menda Y, Halfdanarson TR, Chan JA, Pommier RF. The North American Neuroendocrine Tumor Society Consensus Paper on the Surgical Management of Pancreatic Neuroendocrine Tumors. *Pancreas* 2020; **49**: 1-33 [PMID: 31856076 DOI: 10.1097/MPA.0000000000001454]
  - 84 **Jeune F,** Taibi A, Gaujoux S. Update on the Surgical Treatment of Pancreatic Neuroendocrine Tumors. *Scand J Surg* 2020; **109**: 42-52 [PMID: 31975647 DOI: 10.1177/1457496919900417]
  - 85 **Ammori BJ,** Ayiomamitis GD. Laparoscopic pancreaticoduodenectomy and distal pancreatectomy: a UK experience and a systematic review of the literature. *Surg Endosc* 2011; **25**: 2084-2099 [PMID: 21298539 DOI: 10.1007/s00464-010-1538-4]
  - 86 **Wakabayashi T,** Felli E, Cherkaoui Z, Mutter D, Marescaux J, Pessaux P. Robotic Central Pancreatectomy for Well-Differentiated Neuroendocrine Tumor: Parenchymal-Sparing Procedure. *Ann Surg Oncol* 2019; **26**: 2121 [PMID: 31020502 DOI: 10.1245/s10434-019-07387-8]
  - 87 **Barthet M,** Giovannini M, Lesavre N, Boustiere C, Napoleon B, Koch S, Gasmi M, Vanbiervliet G, Gonzalez JM. Endoscopic ultrasound-guided radiofrequency ablation for pancreatic neuroendocrine tumors and pancreatic cystic neoplasms: a prospective multicenter study. *Endoscopy* 2019; **51**: 836-842 [PMID: 30669161 DOI: 10.1055/a-0824-7067]
  - 88 **Pavel M,** Baudin E, Couvelard A, Krenning E, Öberg K, Steinmüller T, Anlauf M, Wiedenmann B, Salazar R; Barcelona Consensus Conference participants. ENETS Consensus Guidelines for the management of patients with liver and other distant metastases from neuroendocrine neoplasms of foregut, midgut, hindgut, and unknown primary. *Neuroendocrinology* 2012; **95**: 157-176 [PMID: 22262022 DOI: 10.1159/000335597]
  - 89 **Deguelte S,** Perrier M, Hammoutene C, Cadiot G, Kianmanesh R. Surgery and Perioperative Management in Small Intestinal Neuroendocrine Tumors. *J Clin Med* 2020; **9** [PMID: 32708330 DOI: 10.3390/jcm9072319]
  - 90 **Garcia-Carbonero R,** Sorbye H, Baudin E, Raymond E, Wiedenmann B, Niederle B, Sedlackova E, Toumpanakis C, Anlauf M, Cwikla JB, Caplin M, O'Toole D, Perren A; Vienna Consensus Conference participants. ENETS Consensus Guidelines for High-Grade Gastroenteropancreatic Neuroendocrine Tumors and Neuroendocrine Carcinomas. *Neuroendocrinology* 2016; **103**: 186-194 [PMID: 26731334 DOI: 10.1159/000443172]
  - 91 **Luley K,** Gebauer J, Gebauer N, Tharun L, Buchmann I, Barkhausen J, von Bubnoff N, Lindner K, Keck T, Lehnert H, Schmid SM. [Gastroenteropancreatic neuroendocrine neoplasms-Heterogeneity, management and perspectives of treatment and research]. *Internist (Berl)* 2020; **61**: 875-890 [PMID: 32676723 DOI: 10.1007/s00108-020-00832-x]
  - 92 **Caplin ME,** Pavel M, Cwikla JB, Phan AT, Raderer M, Sedláčková E, Cadiot G, Wolin EM, Capdevila J, Wall L, Rindi G, Langley A, Martinez S, Blumberg J, Ruzsiewicz P; CLARINET Investigators. Lanreotide in metastatic enteropancreatic neuroendocrine tumors. *N Engl J Med* 2014; **371**: 224-233 [PMID: 25014687 DOI: 10.1056/NEJMoa1316158]
  - 93 **Modlin IM,** Pavel M, Kidd M, Gustafsson BI. Review article: somatostatin analogues in the treatment of gastroenteropancreatic neuroendocrine (carcinoid) tumours. *Aliment Pharmacol Ther* 2010; **31**: 169-188 [PMID: 19845567 DOI: 10.1111/j.1365-2036.2009.04174.x]
  - 94 **Rinke A,** Müller HH, Schade-Brittinger C, Klose KJ, Barth P, Wied M, Mayer C, Aminossadati B, Pape UF, Bläker M, Harder J, Arnold C, Gress T, Arnold R; PROMID Study Group. Placebo-controlled, double-blind, prospective, randomized study on the effect of octreotide LAR in the control of tumor growth in patients with metastatic neuroendocrine midgut tumors: a report from the PROMID Study Group. *J Clin Oncol* 2009; **27**: 4656-4663 [PMID: 19704057 DOI: 10.1200/JCO.2009.22.8510]
  - 95 **Mazziotti G,** Mosca A, Frara S, Vitale G, Giustina A. Somatostatin analogs in the treatment of neuroendocrine tumors: current and emerging aspects. *Expert Opin Pharmacother* 2017; **18**: 1679-1689 [PMID: 29067877 DOI: 10.1080/14656566.2017.1391217]
  - 96 **Zanini S,** Renzi S, Giovannazzo F, Bermano G. mTOR Pathway in Gastroenteropancreatic Neuroendocrine Tumor (GEP-NETs). *Front Endocrinol (Lausanne)* 2020; **11**: 562505 [PMID: 33304317 DOI: 10.3389/fendo.2020.562505]
  - 97 **Beyens M,** Vandamme T, Peeters M, Van Camp G, Op de Beeck K. Resistance to targeted treatment of gastroenteropancreatic neuroendocrine tumors. *Endocr Relat Cancer* 2019; **26**: R109-R130 [PMID: 32022503 DOI: 10.1530/ERC-18-0420]

- 98 **Fazio N**, Cella CA, Del Re M, Laffi A, Rubino M, Zagami P, Spada F. Pharmacodynamics, clinical findings and approval status of current and emerging tyrosine-kinase inhibitors for pancreatic neuroendocrine tumors. *Expert Opin Drug Metab Toxicol* 2019; **15**: 993-1004 [PMID: [31794273](#) DOI: [10.1080/17425255.2019.1700951](#)]
- 99 **Chan DL**, Segelov E, Singh S. Everolimus in the management of metastatic neuroendocrine tumours. *Therap Adv Gastroenterol* 2017; **10**: 132-141 [PMID: [28286565](#) DOI: [10.1177/1756283X16674660](#)]
- 100 **Raymond E**, Dahan L, Raoul JL, Bang YJ, Borbath I, Lombard-Bohas C, Valle J, Metrakos P, Smith D, Vinik A, Chen JS, Hörsch D, Hammel P, Wiedenmann B, Van Cutsem E, Patyna S, Lu DR, Blanckmeister C, Chao R, Ruzniewski P. Sunitinib malate for the treatment of pancreatic neuroendocrine tumors. *N Engl J Med* 2011; **364**: 501-513 [PMID: [21306237](#) DOI: [10.1056/NEJMoa1003825](#)]
- 101 **Daskalakis K**, Tsoli M, Angelousi A, Kassi E, Alexandraki KI, Kolomodi D, Kaltsas G, Koumariou A. Anti-tumour activity of everolimus and sunitinib in neuroendocrine neoplasms. *Endocr Connect* 2019; **8**: 641-653 [PMID: [31026812](#) DOI: [10.1530/EC-19-0134](#)]
- 102 **Hobday TJ**, Qin R, Reidy-Lagunes D, Moore MJ, Strosberg J, Kaubisch A, Shah M, Kindler HL, Lenz HJ, Chen H, Erlichman C. Multicenter Phase II Trial of Temsirolimus and Bevacizumab in Pancreatic Neuroendocrine Tumors. *J Clin Oncol* 2015; **33**: 1551-1556 [PMID: [25488966](#) DOI: [10.1200/JCO.2014.56.2082](#)]
- 103 **Kenmotsu H**, Niho S, Tsuboi M, Wakabayashi M, Ishii G, Nakagawa K, Daga H, Tanaka H, Saito H, Aokage K, Takahashi T, Menju T, Kasai T, Yoshino I, Minato K, Okada M, Eba J, Asamura H, Ohe Y, Watanabe SI. Randomized Phase III Study of Irinotecan Plus Cisplatin Versus Etoposide Plus Cisplatin for Completely Resected High-Grade Neuroendocrine Carcinoma of the Lung: JCOG1205/1206. *J Clin Oncol* 2020; **38**: 4292-4301 [PMID: [33136471](#) DOI: [10.1200/JCO.20.01806](#)]
- 104 **Tsoli M**, Alexandraki K, Xanthopoulos C, Kassi E, Kaltsas G. Medical Treatment of Gastrointestinal Neuroendocrine Neoplasms. *Horm Metab Res* 2020; **52**: 614-620 [PMID: [32108932](#) DOI: [10.1055/a-1110-7251](#)]
- 105 **Chatzellis E**, Angelousi A, Daskalakis K, Tsoli M, Alexandraki KI, Wachula E, Meirovitz A, Maimon O, Grozinsky-Glasberg S, Gross D, Kos-Kudla B, Koumariou A, Kaltsas G. Activity and Safety of Standard and Prolonged Capecitabine/Temozolomide Administration in Patients with Advanced Neuroendocrine Neoplasms. *Neuroendocrinology* 2019; **109**: 333-345 [PMID: [31167197](#) DOI: [10.1159/000500135](#)]
- 106 **Brabander T**, Teunissen JJ, Van Eijck CH, Franssen GJ, Feelders RA, de Herder WW, Kwekkeboom DJ. Peptide receptor radionuclide therapy of neuroendocrine tumours. *Best Pract Res Clin Endocrinol Metab* 2016; **30**: 103-114 [PMID: [26971847](#) DOI: [10.1016/j.beem.2015.10.005](#)]
- 107 **Strosberg J**, El-Haddad G, Wolin E, Hendifar A, Yao J, Chasen B, Mittra E, Kunz PL, Kulke MH, Jacene H, Bushnell D, O'Dorisio TM, Baum RP, Kulkarni HR, Caplin M, Lebthahi R, Hobday T, Delpassand E, Van Cutsem E, Benson A, Srirajaskanthan R, Pavel M, Mora J, Berlin J, Grande E, Reed N, Seregini E, Öberg K, Lopera Sierra M, Santoro P, Thevenet T, Erion JL, Ruzniewski P, Kwekkeboom D, Krenning E; NETTER-1 Trial Investigators. Phase 3 Trial of <sup>177</sup>Lu-Dotatate for Midgut Neuroendocrine Tumors. *N Engl J Med* 2017; **376**: 125-135 [PMID: [28076709](#) DOI: [10.1056/NEJMoa1607427](#)]
- 108 **Starr JS**, Sonbol MB, Hobday TJ, Sharma A, Kendi AT, Halfdanarson TR. Peptide Receptor Radionuclide Therapy for the Treatment of Pancreatic Neuroendocrine Tumors: Recent Insights. *Onco Targets Ther* 2020; **13**: 3545-3555 [PMID: [32431509](#) DOI: [10.2147/OTT.S202867](#)]
- 109 **Sansovini M**, Severi S, Ianniello A, Nicolini S, Fantini L, Mezzenga E, Ferroni F, Scarpi E, Monti M, Bongiovanni A, Cingarlini S, Grana CM, Bodei L, Paganelli G. Long-term follow-up and role of FDG PET in advanced pancreatic neuroendocrine patients treated with <sup>177</sup>Lu-D OTATATE. *Eur J Nucl Med Mol Imaging* 2017; **44**: 490-499 [PMID: [27704193](#) DOI: [10.1007/s00259-016-3533-z](#)]
- 110 **Cella D**, Beaumont JL, Hudgens S, Marteau F, Feuilly M, Houchard A, Lapuerta P, Ramage J, Pavel M, Hörsch D, Kulke MH. Relationship Between Symptoms and Health-related Quality-of-life Benefits in Patients With Carcinoid Syndrome: Post Hoc Analyses From TELESTAR. *Clin Ther* 2018; **40**: 2006-2020. e2 [PMID: [30477789](#) DOI: [10.1016/j.clinthera.2018.10.008](#)]
- 111 **Kaderli RM**, Spanjol M, Kollár A, Bütikofer L, Gloy V, Dumont RA, Seiler CA, Christ ER, Radojewski P, Briel M, Walter MA. Therapeutic Options for Neuroendocrine Tumors: A Systematic Review and Network Meta-analysis. *JAMA Oncol* 2019; **5**: 480-489 [PMID: [30763436](#) DOI: [10.1001/jamaoncol.2018.6720](#)]
- 112 **Ramage JK**, Ahmed A, Ardill J, Bax N, Breen DJ, Caplin ME, Corrie P, Davar J, Davies AH, Lewington V, Meyer T, Newell-Price J, Poston G, Reed N, Rockall A, Steward W, Thakker RV, Toubanakis C, Valle J, Verbeke C, Grossman AB; UK and Ireland Neuroendocrine Tumour Society. Guidelines for the management of gastroenteropancreatic neuroendocrine (including carcinoid) tumours (NETs). *Gut* 2012; **61**: 6-32 [PMID: [22052063](#) DOI: [10.1136/gutjnl-2011-300831](#)]
- 113 **Deutsche Gesellschaft für Gastroenterologie**, Verdauungs- und Stoffwechselkrankheiten (DGVS); Netzwerk Neuroendokrine Tumoren (NeT) e. V. (Patientenvertretung); Bundesorganisation Selbsthilfe NeuroEndokrine Tumoren e.V. (NET-sgh) (Patientenvertretung); Deutsche Gesellschaft für Hämatologie und Medizinische Onkologie e.V. (DGHO), und Arbeitsgemeinschaft Internistische Onkologie (AIO) der Deutschen Krebsgesellschaft e.V.; Deutsche Gesellschaft für Allgemein- und

Viszeralchirurgie e.V. (DGAV); Deutsche Gesellschaft für Chirurgie (DGCH); Deutsche Gesellschaft für Endoskopie und Bildgebende Verfahren (DGEbV); Deutsche Gesellschaft für Nuklearmedizin e.V. (DGNM); Deutsche Gesellschaft für Innere Medizin (DGIM); Deutsche Gesellschaft für Endokrinologie (DGE); Deutsche Gesellschaft für Palliativmedizin e.V. (DGP); Deutsche Röntgengesellschaft e.V. (DRG); Deutsche Gesellschaft für Pathologie e.V./Bundesverband Deutscher Pathologen (DGP/BDP); Deutsche Gesellschaft für interventionelle Radiologie (DGiR); Authors; Collaborators. [Practice guideline neuroendocrine tumors - AWMF-Reg. 021-27]. *Z Gastroenterol* 2018; **56**: 583-681 [PMID: 29890561 DOI: 10.1055/a-0604-2924]



Published by **Baishideng Publishing Group Inc**  
7041 Koll Center Parkway, Suite 160, Pleasanton, CA 94566, USA

**Telephone:** +1-925-3991568

**E-mail:** [bpgoffice@wjgnet.com](mailto:bpgoffice@wjgnet.com)

**Help Desk:** <https://www.f6publishing.com/helpdesk>

<https://www.wjgnet.com>

