

World Journal of *Gastrointestinal Surgery*

World J Gastrointest Surg 2022 December 27; 14(12): 1320-1437



Contents

Monthly Volume 14 Number 12 December 27, 2022

MINIREVIEWS

- 1320 Timing of individualized surgical intervention in Crohn's disease
Xia K, Gao RY, Wu XC, Yin L, Chen CQ

ORIGINAL ARTICLE

Basic Study

- 1329 Hydrogen gas and preservation of intestinal stem cells in mesenteric ischemia and reperfusion
Yamamoto R, Suzuki S, Homma K, Yamaguchi S, Sujino T, Sasaki J

Retrospective Study

- 1340 Microbial spectrum and drug resistance of pathogens cultured from gallbladder bile specimens of patients with cholelithiasis: A single-center retrospective study
Huang XM, Zhang ZJ, Zhang NR, Yu JD, Qian XJ, Zhuo XH, Huang JY, Pan WD, Wan YL
- 1350 Low preoperative skeletal muscle index increases the risk of mortality among resectable pancreatic cancer patients: A retrospective study
Cai ZW, Li JL, Liu M, Wang HW, Jiang CY

Observational Study

- 1363 Development of a prediction model for enteral feeding intolerance in intensive care unit patients: A prospective cohort study
Lu XM, Jia DS, Wang R, Yang Q, Jin SS, Chen L

Prospective Study

- 1375 Real-time *in vivo* distal margin selection using confocal laser endomicroscopy in transanal total mesorectal excision for rectal cancer
Tan J, Ji HL, Hu YW, Li ZM, Zhuang BX, Deng HJ, Wang YN, Zheng JX, Jiang W, Yan J

META-ANALYSIS

- 1387 Short- and long-term outcomes of laparoscopic *vs* open surgery for T2 gallbladder cancer: A systematic review and meta-analysis
Zhang W, Ouyang DL, Che X
- 1397 Meta-analysis of transanal *vs* laparoscopic total mesorectal excision of low rectal cancer: Importance of appropriate patient selection
Bhattacharya P, Patel I, Fazili N, Hajibandeh S, Hajibandeh S

CASE REPORT

- 1411 Secondary sclerosing cholangitis in a young COVID-19 patient resulting in death: A case report
Steiner J, Kaufmann-Bühler AK, Fuchsjäger M, Schemmer P, Talakić E

- 1418** Rectal tubular adenoma with submucosal pseudoinvasion misdiagnosed as adenocarcinoma: A case report
Chen D, Zhong DF, Zhang HY, Nie Y, Liu D
- 1425** Malignant transformation of perianal tailgut cyst: A case report
Fang Y, Zhu Y, Liu WZ, Zhang XQ, Zhang Y, Wang K
- 1432** Acute appendicitis in the short term following radical total gastrectomy misdiagnosed as duodenal stump leakage: A case report
Ma J, Zha ZP, Zhou CP, Miao X, Duan SQ, Zhang YM

ABOUT COVER

Peer Reviewer of *World Journal of Gastrointestinal Surgery*, Giuseppe Currò, MD, Professor, Surgeon, Department of Health Science, University Magna Graecia of Catanzaro, Catanzaro 88100, Calabria, Italy. currog@unicz.it

AIMS AND SCOPE

The primary aim of *World Journal of Gastrointestinal Surgery* (WJGS, *World J Gastrointest Surg*) is to provide scholars and readers from various fields of gastrointestinal surgery with a platform to publish high-quality basic and clinical research articles and communicate their research findings online.

WJGS mainly publishes articles reporting research results and findings obtained in the field of gastrointestinal surgery and covering a wide range of topics including biliary tract surgical procedures, biliopancreatic diversion, colectomy, esophagectomy, esophagostomy, pancreas transplantation, and pancreatectomy, etc.

INDEXING/ABSTRACTING

The WJGS is now abstracted and indexed in Science Citation Index Expanded (SCIE, also known as SciSearch®), Current Contents/Clinical Medicine, Journal Citation Reports/Science Edition, PubMed, PubMed Central, Reference Citation Analysis, China National Knowledge Infrastructure, China Science and Technology Journal Database, and Superstar Journals Database. The 2022 Edition of Journal Citation Reports® cites the 2021 impact factor (IF) for WJGS as 2.505; IF without journal self cites: 2.473; 5-year IF: 3.099; Journal Citation Indicator: 0.49; Ranking: 104 among 211 journals in surgery; Quartile category: Q2; Ranking: 81 among 93 journals in gastroenterology and hepatology; and Quartile category: Q4.

RESPONSIBLE EDITORS FOR THIS ISSUE

Production Editor: Rui-Rui Wu, Production Department Director: Xiang Li, Editorial Office Director: Jia-Ru Fan.

NAME OF JOURNAL

World Journal of Gastrointestinal Surgery

ISSN

ISSN 1948-9366 (online)

LAUNCH DATE

November 30, 2009

FREQUENCY

Monthly

EDITORS-IN-CHIEF

Peter Schemmer

EDITORIAL BOARD MEMBERS

<https://www.wjgnet.com/1948-9366/editorialboard.htm>

PUBLICATION DATE

December 27, 2022

COPYRIGHT

© 2022 Baishideng Publishing Group Inc

INSTRUCTIONS TO AUTHORS

<https://www.wjgnet.com/bpg/gerinfo/204>

GUIDELINES FOR ETHICS DOCUMENTS

<https://www.wjgnet.com/bpg/GerInfo/287>

GUIDELINES FOR NON-NATIVE SPEAKERS OF ENGLISH

<https://www.wjgnet.com/bpg/gerinfo/240>

PUBLICATION ETHICS

<https://www.wjgnet.com/bpg/GerInfo/288>

PUBLICATION MISCONDUCT

<https://www.wjgnet.com/bpg/gerinfo/208>

ARTICLE PROCESSING CHARGE

<https://www.wjgnet.com/bpg/gerinfo/242>

STEPS FOR SUBMITTING MANUSCRIPTS

<https://www.wjgnet.com/bpg/GerInfo/239>

ONLINE SUBMISSION

<https://www.f6publishing.com>



Timing of individualized surgical intervention in Crohn's disease

Kai Xia, Ren-Yuan Gao, Xiao-Cai Wu, Lu Yin, Chun-Qiu Chen

Specialty type: Gastroenterology and hepatology

Provenance and peer review: Invited article; Externally peer reviewed.

Peer-review model: Single blind

Peer-review report's scientific quality classification

Grade A (Excellent): 0
Grade B (Very good): B
Grade C (Good): C
Grade D (Fair): D
Grade E (Poor): 0

P-Reviewer: Jha P, United States; Zha B, China

Received: September 1, 2022

Peer-review started: September 1, 2022

First decision: October 20, 2022

Revised: October 24, 2022

Accepted: December 1, 2022

Article in press: December 1, 2022

Published online: December 27, 2022



Kai Xia, Ren-Yuan Gao, Xiao-Cai Wu, Lu Yin, Chun-Qiu Chen, Diagnostic and Treatment Center for Refractory Diseases of Abdomen Surgery, Shanghai Tenth People's Hospital, Tongji University School of Medicine, Shanghai 200072, China

Corresponding author: Chun-Qiu Chen, Doctor, Chief Doctor, Professor, Diagnostic and Treatment Center for Refractory Diseases of Abdomen Surgery, Shanghai Tenth People's Hospital, Tongji University School of Medicine, No. 301 Yanchang Middle Road, Shanghai 200072, China. chenchunqiu6@126.com

Abstract

Crohn's disease (CD) is a chronic inflammatory disorder of the gastrointestinal tract with an increasing incidence worldwide. Comprehensive therapy for CD focuses on symptom control and healing the intestinal mucosa to improve the quality of life and prevent complications. Surgical intervention plays a vital role in comprehensive therapy. However, deciding the optimal timing for surgical intervention has long been a focus of controversy. This review provides insights into the timing of surgery for CD and guides clinicians in daily treatment.

Key Words: Crohn's disease; Surgical intervention; Timing of surgery; Individualization; Therapy

©The Author(s) 2022. Published by Baishideng Publishing Group Inc. All rights reserved.

Core Tip: Surgical intervention plays an important role in the comprehensive treatment of Crohn's disease (CD). However, the timing of surgery has always been a major controversial point. This review focuses on the main surgical indications for CD and the clinical factors that may influence surgical timing decisions. We also emphasize the value of early surgery in treating CD.

Citation: Xia K, Gao RY, Wu XC, Yin L, Chen CQ. Timing of individualized surgical intervention in Crohn's disease. *World J Gastrointest Surg* 2022; 14(12): 1320-1328

URL: <https://www.wjgnet.com/1948-9366/full/v14/i12/1320.htm>

DOI: <https://dx.doi.org/10.4240/wjgs.v14.i12.1320>

INTRODUCTION

Crohn's disease (CD) is a chronic inflammatory bowel disease that can affect the entire digestive tract, especially the terminal ileum and proximal colon[1,2]. The course of CD is protracted, characterized by alternating active and remission stages. The epidemiologic patterns of CD depict that the prevalence and hospitalization rates are currently rising gradually worldwide, contributing to an increasing burden on healthcare systems[3-6]. The underlying cause of CD is still unknown but includes a variety of factors, including genetic susceptibility, environmental triggers, immune regulation, and gut microbial imbalance[7-9]. CD is prone to various complications due to penetrating and chronic intestinal inflammatory response, including intestinal obstruction, bowel perforation, fistula, or intra-abdominal abscess [10,11]. After diagnosis, approximately 50% and 70% of CD patients develop complications within 5 or 10 years, respectively[12,13].

Recently, the launch of new biological agents has breathed new life into the clinical treatment of CD, while surgical intervention still plays an indispensable role[14-16]. The cumulative surgery rate for CD patients is 16.6%, 35.4%, 53%, and 94.5% for 1, 5, 10, and 30 years, respectively, after the onset of the disease[17]. The choice of optimal timing for surgical intervention has always been a focus of controversy. Some scholars advocate for early surgical intervention if drugs fail to achieve good results. Nevertheless, the recurrence after surgery is almost inevitable, and approximately 40% of CD patients require reoperation[18]. Other scholars prefer to avoid early surgery only if it is necessary to resect the intestinal segments that cause complications following the principle of intestinal conservation. However, postoperative complications significantly increase due to poor nutritional status and severe abdominal infection[19]. This review mainly focuses on the choice of individualized surgical intervention timing for CD patients.

SURGICAL INDICATIONS FOR CD

According to the relevant literature and clinical experience, we summarize the main surgical indications for CD, which involve serious complications of CD (Figure 1), failure of medical therapy, and growth retardation in children.

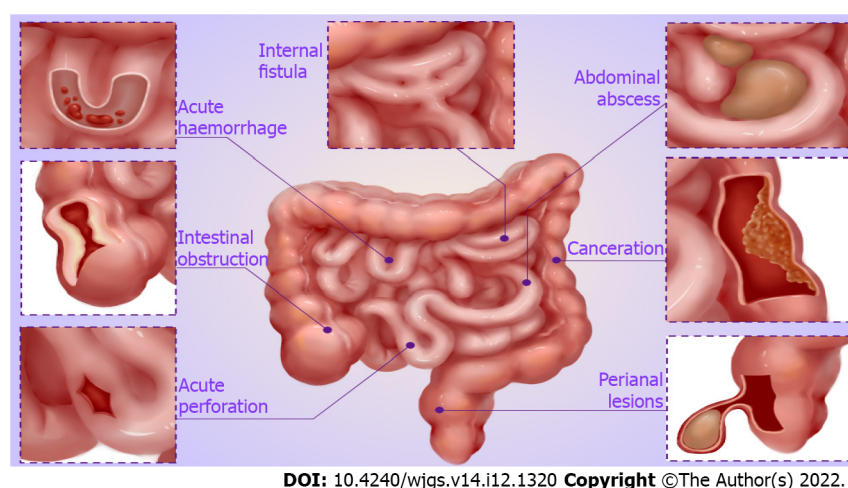
Serious complications of CD

Intestinal obstruction: Intestinal obstruction is a common and serious complication of CD, especially fibrosis-associated intestinal stricture[20]. Lin *et al*[21] revealed that approximately 70% of CD patients inevitably develop fibrosis-associated intestinal stricture a decade following diagnosis. Medical treatment is frequently ineffective in patients who develop intestinal obstruction, and surgical resection is primarily required in that case[22,23]. Certainly, with the development of endoscopic technology, endoscopic balloon dilation is also an appropriate treatment option when the length of strictures is ≤ 5 cm, non-angulated, and with a sizeable intestinal cavity large enough to allow balloon dilators in the absence of contraindications such as the presence of fistula, abscess, or malignancy[24,25]. Furthermore, acute inflammatory obstruction can be frequently relieved by medical therapy. If conservative therapy is ineffective, surgical intervention should be considered to relieve the obstruction.

Intra-abdominal abscess: Intra-abdominal abscess is an important clinical complication of CD, the cause of which may be spontaneous or secondary to surgery[26,27]. The current first-line therapy for CD complicated by intra-abdominal abscess, is percutaneous abscess drainage with systemic antibiotics[28, 29]. However, surgical intervention should be considered actively if the symptoms of sepsis do not improve after drainage, abscess ruptures with severe peritonitis, or multiple abscesses cannot be drained. Intestine resection appears to be inevitable in most CD patients presenting intra-abdominal abscess[30,31].

Fistula: Therapy for fistula has always been a complex clinical challenge. Simple enteral fistula without infection and clinical symptoms can be healed by a medical treatment such as enteral nutrition or biological agents[32,33]. For other complex enteral fistulae, including spontaneous enteroenteral or enteroexternal fistula formed after abscess drainage, the possibility of self-healing is low, and surgery should be adopted[34,35]. CD patients with severe fistula are often accompanied by loss of digestive fluid, resulting in disturbance of internal environmental balance, secondary infection, and malnutrition. Therefore, the infection should be readily controlled, and adequate nutritional support provided before elective surgery[36,37]. Yzet *et al*[38] recently reported successful cases of endoscopic treatment for enteroexternal fistula, which was feasible with short-term effectiveness.

Perianal lesions: Perianal lesions are common complications of CD, with perianal fistula and abscess being one of the most common[39,40]. The management of symptomatic simple perianal fistula and complex perianal fistula employs a multidisciplinary approach, which includes antibiotics, biological therapies, and surgery[41,42]. Furthermore, stem cell therapy is also an effective option for complex perianal fistula in CD patients[43,44]. As for the treatment of perianal abscess, surgical drainage and



DOI: 10.4240/wjgs.v14.i12.1320 Copyright ©The Author(s) 2022.

Figure 1 Major categories of Crohn's disease complications, including intestinal obstruction, fistula, intra-abdominal abscess, perianal lesions, massive bleeding, perforation, and canceration.

antibiotic therapy are preferred.

Perforation, massive bleeding, or canceration: The incidence of CD complicated by acute perforation is low. However, emergency surgical intervention is often required if it occurs[45]. When complicated by massive bleeding, the location of bleeding should be identified, and treatments such as drug, endoscopic, or interventional hemostasis should be actively adopted. Emergency surgery is required if the above treatments fail and massive bleeding continues[46,47]. In addition, CD complicated by canceration is an absolute indication for surgery[48].

Failure of medical therapy: Surgical intervention may be considered when drug therapy fails, and symptoms such as intolerance to severe side effects and ineffectiveness to various biological agents are difficult to control.

Growth retardation in children: Pediatric CD often presents as a triad of abdominal pain, diarrhea, and weight loss, characterized by growth retardation[49,50]. Therefore, the pediatric treatment of CD induces and maintains clinical remission of the disease and optimizes nutrition and growth as soon as possible[51]. Surgery should be performed before puberty for prepubertal or early pubertal patients with severe malnutrition resulting in growth arrest[52]. Since the rate of postoperative recurrence is still high, drug therapy is required to maintain remission after surgery[53].

CLINICAL FACTORS AFFECTING TIMING OF SURGERY

Surgical intervention for CD aims to deal with complications and improve the quality of life of patients, as they tend to be in poor general conditions. Therefore, except for emergencies such as massive bleeding and acute perforation, adequate preoperative preparation should be completed to improve the efficacy of surgery. As a clinician, more attention should be paid to following the clinical factors to minimize perioperative complications.

Nutritional support

Malnutrition is one of the prominent clinical manifestations of CD. Our team recently published a study indicating that CD patients were at higher nutritional risk than healthy people[54]. It can hinder wound healing and increase the risk of incision infection, hernia, and anastomotic leak[55]. Therefore, nutritional status is recognized as an independent risk factor for postoperative complications. Yamamoto *et al*[56] revealed that patients with preoperative low albumin levels (< 30 g/L) had a 2.6-fold increased incidence of postoperative complications, similar to that reported by Shah *et al*[57]. Another study indicated that preoperative optimization with nutritional support reduced the overall rate of postoperative complications of CD[58]. Thus, perioperative nutritional support is vital for CD patients, while enteral nutrition should be adopted when the intestinal state permits. Appropriate enteral nutrition can improve the nutritional status, protect the intestinal mucosal barrier, and induce clinical remission[59,60]. It is a well-established and recommended first-line induction therapy in pediatric CD with remission rates of up to 80%[61].

Table 1 Correlations between drug factors and surgical complications of Crohn's disease

Ref.	Drugs	Type of study	Number of patients	Observations	Conclusion
Cohen <i>et al</i> [68], 2022	TNFis	Prospective study	947	Postoperative infection rate	No correlation
Uchino <i>et al</i> [69], 2022	TNFis	Retrospective study	305	Surgical mortality	No correlation
Abd El Aziz <i>et al</i> [70], 2022	TNFis	Prospective study	274	Intra-abdominal septic complications	No correlation
Azzam <i>et al</i> [71], 2022	Azathioprine	Retrospective study	105	Endoscopic recurrence rate	Negative correlation
Cosnes <i>et al</i> [72], 2005	Azathioprine	Retrospective study	2573	Intestinal complications	No correlation
Nguyen <i>et al</i> [73], 2014	Steroids	Retrospective study	15495	Postoperative sepsis and VTE	Positive correlation

TNFis: Tumor necrosis factor inhibitors; VTE: Venous thromboembolism.

Infection control

A recent study by Bachour *et al*[62] revealed that abdominal infection was associated with an increased risk of surgical postoperative recurrence of CD. Tzivanakis *et al*[63] indicated that the presence of preoperative abdominal abscess formation was identified as an independent predictor of anastomotic-associated complications. If the risk factor is present before surgery, the risk of anastomotic complications can be increased to 14%. Therefore, CD patients with abdominal abscesses can often be first managed with antibiotics and percutaneous drainage, while definitive surgical intervention should be performed after the infection has been controlled[64].

Effects of drugs

Whether preoperative CD treatment with tumor necrosis factor inhibitors (TNFis) increases the risk of postoperative complications remains controversial. TNFis may compromise immunity, collagen production, and angiogenesis, resulting in postoperative infective complications and altered wound healing[65,66]. In addition, TNF- α is a key cytokine in collagen production and angiogenesis, with animal studies confirming its role in wound healing[67]. However, previous studies have confirmed that preoperative TNFis exposure was not correlated with postoperative infectious complications[68-70] (Table 1).

Azathioprine is commonly used as an immunosuppressant for treating CD and may not increase the risk of postoperative complications. Although azathioprine has demonstrated efficacy in preventing postoperative recurrence, there is no significant decrease in the need for surgery or intestinal complications from CD[71,72] (Table 1). Furthermore, CD patients are frequently treated with steroids before surgery. Nguyen *et al*[73] indicated that preoperative steroids were correlated with a higher risk of postoperative sepsis (Table 1). Therefore, steroids should be minimized or discontinued 6 mo before surgery.

VALUE OF EARLY SURGICAL INTERVENTION IN TREATMENT OF CD

Early surgery for CD is commonly performed within a short time after diagnosis, while the time frame is still inconclusive[74,75]. An *et al*[76] defined early surgery as patients who had undergone upfront surgery for CD due to an acute complication and those who underwent surgery within 6 mo of diagnosis. Interestingly, this study revealed that patients with ileocolonic CD may have a better prognosis if undergoing early surgical intervention, with fewer admissions to the hospital and reduced overall operation rates. Aratari *et al*[77] also defined early surgery when performed at the time of CD diagnosis, when these patients underwent surgery for the acute or subacute presentation of CD. Meanwhile, late surgery was defined as patients with an established diagnosis of CD who underwent surgery during the course of the disease on account of intestinal complications or refractoriness to medical therapy. Early surgery may significantly prolong the time of clinical recurrence of CD compared to late surgery. Considering the lack of evidence from these retrospective studies, the conclusions warrant further verification.

Early surgical intervention may benefit patients with localized CD, which refers to intestinal CD affecting < 30 cm in extent. This usually applies to an ileocaecal location but also isolated colonic disease, or conceivably to proximal small intestinal disease[78]. Ponsioen *et al*[79] indicated that early laparoscopic surgery for localized CD could improve the overall quality of life of patients and reduce the rate of recurrence and reoperation. A long-term follow-up study by Stevens *et al*[80] during the LIR! C-trial revealed that most patients with localized CD who underwent early surgery were free of anti-TNF treatment, and none required a second surgery. Conversely, almost half of the patients who underwent anti-TNF treatment moved on to a Crohn-related resection. Furthermore, de Groof *et al*[81]

revealed that mean CD total direct healthcare costs per patient at 1 year were lower in the group who underwent early surgery compared with the anti-TNF group. Early surgical intervention is a reasonable and cost-effective treatment option for patients with localized CD.

China has a high incidence of hepatitis and tuberculosis. However, anti-TNF treatment may increase the risk of opportunistic infections[82,83]. Early surgery instead of anti-TNF treatment can reduce opportunistic infections. Additionally, early surgical resection of localized lesions may improve the response to postoperative anti-TNF treatment, the curative effect of which is better than that of the initial therapy[84,85].

CONCLUSION

CD is a refractory disease with a high misdiagnosis rate, a tendency for lifelong recurrence, and a high rate of operation and reoperation. Surgical intervention is a key part of the comprehensive treatment of CD. Inappropriate timing of surgery may lead to catastrophic postoperative complications, increasing the risk of surgery and prolonging hospital stays. Therefore, clinicians need to evaluate the severity and type of CD as well as the effectiveness of medical therapy and choose the timing of surgical intervention based on individual circumstances to ensure the maximum benefit for CD patients. Maybe in the future, with the deepening of multi-omics researches such as radiomics, metabolomics, and microbiomics, it will provide a more favorable basis for individualized timing of CD surgery and identify the early changes of CD related acute lesions.

ACKNOWLEDGEMENTS

We thank the medical teams of Diagnostic and Treatment Center for Refractory Diseases of Abdomen Surgery, Shanghai Tenth People's Hospital, for their support for this subject.

FOOTNOTES

Author contributions: Xia K drafted the manuscript, and collected and organized the literature; Gao RY, Wu XC, Yin L, and Chen CQ contributed to manuscript modification.

Conflict-of-interest statement: All the authors report no relevant conflicts of interest for this article.

Open-Access: This article is an open-access article that was selected by an in-house editor and fully peer-reviewed by external reviewers. It is distributed in accordance with the Creative Commons Attribution NonCommercial (CC BY-NC 4.0) license, which permits others to distribute, remix, adapt, build upon this work non-commercially, and license their derivative works on different terms, provided the original work is properly cited and the use is non-commercial. See: <https://creativecommons.org/licenses/by-nc/4.0/>

Country/Territory of origin: China

ORCID number: Kai Xia 0000-0001-6690-0341; Ren-Yuan Gao 0000-0002-7602-0601; Xiao-Cai Wu 0000-0001-7546-6882; Lu Yin 0000-0002-9060-0178; Chun-Qiu Chen 0000-0002-4248-7414.

S-Editor: Wang JJ

L-Editor: Wang TQ

P-Editor: Wang JJ

REFERENCES

- 1 **Cohen NA**, Micic DM, Sakuraba A. Factors associated with poor compliance amongst hospitalized, predominantly adolescent pediatric Crohn's disease patients. *Ann Med* 2022; **54**: 886-892 [PMID: [35352625](#) DOI: [10.1080/07853890.2022.2057582](#)]
- 2 **Narula N**, Wong ECL, Dulai PS, Sengupta NK, Marshall JK, Colombel JF, Reinisch W. Comparative Efficacy and Rapidity of Action for Infliximab vs Ustekinumab in Biologic Naïve Crohn's Disease. *Clin Gastroenterol Hepatol* 2022; **20**: 1579-1587.e2 [PMID: [33838348](#) DOI: [10.1016/j.cgh.2021.04.006](#)]
- 3 **Buie MJ**, Quan J, Windsor JW, Coward S, Hansen TM, King JA, Kotze PG, Gearry RB, Ng SC, Mak JWY, Abreu MT, Rubin DT, Bernstein CN, Banerjee R, Yamamoto-Furusho JK, Panaccione R, Seow CH, Ma C, Underwood FE, Ahuja V, Panaccione N, Shaheen AA, Holroyd-Leduc J, Kaplan GG; Global IBD Visualization of Epidemiology Studies in the 21st Century (GIVES-21) Research Group, Balderramo D, Chong VH, Juliao-Baños F, Dutta U, Simadibrata M, Kaibullayeva J,

- Sun Y, Hilmi I, Raja Ali RA, Paudel MS, Altuwaijri M, Hartono JL, Wei SC, Limsrivilai J, El Ouali S, Vergara BI, Dao VH, Kelly P, Hodges P, Miao Y, Li M. Global Hospitalization Trends for Crohn's Disease and Ulcerative Colitis in the 21st Century: A Systematic Review With Temporal Analyses. *Clin Gastroenterol Hepatol* 2022 [PMID: 35863682 DOI: 10.1016/j.cgh.2022.06.030]
- 4 **Kuenzig ME**, Fung SG, Marderfeld L, Mak JWY, Kaplan GG, Ng SC, Wilson DC, Cameron F, Henderson P, Kotze PG, Bharti J, Fang V, Gerber S, Guay E, Kotteduwa Jayawarden S, Kadota L, Maldonado D F, Osei JA, Sandarage R, Stanton A, Wan M; InsightScope Pediatric IBD Epidemiology Group, Benchimol EI. Twenty-first Century Trends in the Global Epidemiology of Pediatric-Onset Inflammatory Bowel Disease: Systematic Review. *Gastroenterology* 2022; **162**: 1147-1159.e4 [PMID: 34995526 DOI: 10.1053/j.gastro.2021.12.282]
- 5 **Cosnes J**, Gower-Rousseau C, Seksik P, Cortot A. Epidemiology and natural history of inflammatory bowel diseases. *Gastroenterology* 2011; **140**: 1785-1794 [PMID: 21530745 DOI: 10.1053/j.gastro.2011.01.055]
- 6 **Stöss C**, Berlet M, Reischl S, Nitsche U, Weber MC, Friess H, Wilhelm D, Neumann PA. Crohn's disease: a population-based study of surgery in the age of biological therapy. *Int J Colorectal Dis* 2021; **36**: 2419-2426 [PMID: 33876296 DOI: 10.1007/s00384-021-03930-w]
- 7 **Michaud E**, Waeckel L, Gayet R, Goguyer-Deschaumes R, Chanut B, Jospin F, Bathany K, Monnoye M, Genet C, Prier A, Tokarski C, Gérard P, Roblin X, Rochereau N, Paul S. Alteration of microbiota antibody-mediated immune selection contributes to dysbiosis in inflammatory bowel diseases. *EMBO Mol Med* 2022; **14**: e15386 [PMID: 35785473 DOI: 10.15252/emmm.202115386]
- 8 **Ananthakrishnan AN**, Kaplan GG, Bernstein CN, Burke KE, Lochhead PJ, Sasson AN, Agrawal M, Tiong JHT, Steinberg J, Kruis W, Steinwurz F, Ahuja V, Ng SC, Rubin DT, Colombel JF, Geary R; International Organization for Study of Inflammatory Bowel Diseases. Lifestyle, behaviour, and environmental modification for the management of patients with inflammatory bowel diseases: an International Organization for Study of Inflammatory Bowel Diseases consensus. *Lancet Gastroenterol Hepatol* 2022; **7**: 666-678 [PMID: 35487235 DOI: 10.1016/S2468-1253(22)00021-8]
- 9 **Kong C**, Yan X, Liu Y, Huang L, Zhu Y, He J, Gao R, Kalady MF, Goel A, Qin H, Ma Y. Ketogenic diet alleviates colitis by reduction of colonic group 3 innate lymphoid cells through altering gut microbiome. *Signal Transduct Target Ther* 2021; **6**: 154 [PMID: 33888680 DOI: 10.1038/s41392-021-00549-9]
- 10 **Xia K**, Gao R, Wu X, Ruan Y, Wan J, Wu T, Wang F, Lin Y, Yin L, Chen C. Crohn's Disease Complicated by Rare Types of Intestinal Obstruction: Two Case Reports. *Front Med (Lausanne)* 2022; **9**: 895202 [PMID: 35572975 DOI: 10.3389/fmed.2022.895202]
- 11 **Yao J**, Jiang Y, Ke J, Lu Y, Hu J, Zhi M. A Validated Prognostic Model and Nomogram to Predict Early-Onset Complications Leading to Surgery in Patients With Crohn's Disease. *Dis Colon Rectum* 2021; **64**: 697-705 [PMID: 33315712 DOI: 10.1097/DCR.0000000000001881]
- 12 **Rieder F**, Zimmermann EM, Remzi FH, Sandborn WJ. Crohn's disease complicated by strictures: a systematic review. *Gut* 2013; **62**: 1072-1084 [PMID: 23626373 DOI: 10.1136/gutjnl-2012-304353]
- 13 **Louis E**, Collard A, Oger AF, Degroote E, Aboul Nasr El Yafi FA, Belaiche J. Behaviour of Crohn's disease according to the Vienna classification: changing pattern over the course of the disease. *Gut* 2001; **49**: 777-782 [PMID: 11709511 DOI: 10.1136/gut.49.6.777]
- 14 **Sands BE**, Irving PM, Hoops T, Izanec JL, Gao LL, Gasink C, Greenspan A, Allez M, Danese S, Hanauer SB, Jairath V, Kuehbach T, Lewis JD, Loftus EV Jr, Mihaly E, Panaccione R, Scherl E, Shchukina OB, Sandborn WJ; SEAVUE Study Group. Ustekinumab versus adalimumab for induction and maintenance therapy in biologic-naïve patients with moderately to severely active Crohn's disease: a multicentre, randomised, double-blind, parallel-group, phase 3b trial. *Lancet* 2022; **399**: 2200-2211 [PMID: 35691323 DOI: 10.1016/S0140-6736(22)00688-2]
- 15 **Hindson J**. First-line infliximab for children with Crohn's disease. *Nat Rev Gastroenterol Hepatol* 2021; **18**: 150 [PMID: 33594271 DOI: 10.1038/s41575-021-00429-1]
- 16 **Bouhnik Y**, Carbonnel F, Laharie D, Stefanescu C, Hébuterne X, Abitbol V, Nachury M, Brixi H, Bourreille A, Picon L, Bourrier A, Allez M, Peyrin-Biroulet L, Moreau J, Savoye G, Fumery M, Nancey S, Roblin X, Altwegg R, Bouguen G, Bommelaer G, Danese S, Louis E, Zappa M, Mary JY; GETAID CREOLE Study Group. Efficacy of adalimumab in patients with Crohn's disease and symptomatic small bowel stricture: a multicentre, prospective, observational cohort (CREOLE) study. *Gut* 2018; **67**: 53-60 [PMID: 28119352 DOI: 10.1136/gutjnl-2016-312581]
- 17 **Gao X**, Yang RP, Chen MH, Xiao YL, He Y, Chen BL, Hu PJ. Risk factors for surgery and postoperative recurrence: analysis of a south China cohort with Crohn's disease. *Scand J Gastroenterol* 2012; **47**: 1181-1191 [PMID: 22845663 DOI: 10.3109/00365521.2012.668931]
- 18 **Bernell O**, Lapidus A, HELLERS G. Risk factors for surgery and postoperative recurrence in Crohn's disease. *Ann Surg* 2000; **231**: 38-45 [PMID: 10636100 DOI: 10.1097/0000658-200001000-00006]
- 19 **Brouquet A**, Blanc B, Bretagnol F, Valleur P, Bouhnik Y, Panis Y. Surgery for intestinal Crohn's disease recurrence. *Surgery* 2010; **148**: 936-946 [PMID: 20363010 DOI: 10.1016/j.surg.2010.02.001]
- 20 **Ou W**, Xu W, Liu F, Guo Y, Huang Z, Feng T, Liu CY, Du P. Increased expression of yes-associated protein/YAP and transcriptional coactivator with PDZ-binding motif/TAZ activates intestinal fibroblasts to promote intestinal obstruction in Crohn's disease. *EBioMedicine* 2021; **69**: 103452 [PMID: 34186485 DOI: 10.1016/j.ebiom.2021.103452]
- 21 **Lin XX**, Qiu Y, Zhuang XJ, Liu F, Wu XM, Chen MH, Mao R. Intestinal stricture in Crohn's disease: A 2020 update. *J Dig Dis* 2021; **22**: 390-398 [PMID: 34014617 DOI: 10.1111/1751-2980.13022]
- 22 **Schulberg JD**, Wright EK, Holt BA, Hamilton AL, Sutherland TR, Ross AL, Vogrin S, Miller AM, Connell WC, Lust M, Ding NS, Moore GT, Bell SJ, Shelton E, Christensen B, De Cruz P, Rong YJ, Kamm MA. Intensive drug therapy versus standard drug therapy for symptomatic intestinal Crohn's disease strictures (STRIDENT): an open-label, single-centre, randomised controlled trial. *Lancet Gastroenterol Hepatol* 2022; **7**: 318-331 [PMID: 34890567 DOI: 10.1016/S2468-1253(21)00393-9]
- 23 **Hayashi Y**, Nakase H. The Molecular Mechanisms of Intestinal Inflammation and Fibrosis in Crohn's Disease. *Front Physiol* 2022; **13**: 845078 [PMID: 35222098 DOI: 10.3389/fphys.2022.845078]
- 24 **Bettenworth D**, Gustavsson A, Atreja A, Lopez R, Tysk C, van Assche G, Rieder F. A Pooled Analysis of Efficacy,

- Safety, and Long-term Outcome of Endoscopic Balloon Dilation Therapy for Patients with Stricturing Crohn's Disease. *Inflamm Bowel Dis* 2017; **23**: 133-142 [PMID: 28002130 DOI: 10.1097/MIB.0000000000000988]
- 25 **Chen M**, Shen B. Endoscopic Therapy in Crohn's Disease: Principle, Preparation, and Technique. *Inflamm Bowel Dis* 2015; **21**: 2222-2240 [PMID: 26284298 DOI: 10.1097/MIB.0000000000000433]
 - 26 **Levartovsky A**, Barash Y, Ben-Horin S, Ungar B, Soffer S, Amitai MM, Klang E, Kopylov U. Machine learning for prediction of intra-abdominal abscesses in patients with Crohn's disease visiting the emergency department. *Therap Adv Gastroenterol* 2021; **14**: 17562848211053114 [PMID: 34707689 DOI: 10.1177/17562848211053114]
 - 27 **Clancy C**, Boland T, Deasy J, McNamara D, Burke JP. A Meta-analysis of Percutaneous Drainage Versus Surgery as the Initial Treatment of Crohn's Disease-related Intra-abdominal Abscess. *J Crohns Colitis* 2016; **10**: 202-208 [PMID: 26512133 DOI: 10.1093/ecco-jcc/jjv198]
 - 28 **Celentano V**, Giglio MC, Pellino G, Rottoli M, Sampietro G, Spinelli A, Selvaggi F; Italian Society of Colorectal Surgery SICCR. High complication rate in Crohn's disease surgery following percutaneous drainage of intra-abdominal abscess: a multicentre study. *Int J Colorectal Dis* 2022; **37**: 1421-1428 [PMID: 35599268 DOI: 10.1007/s00384-022-04183-x]
 - 29 **Collard MK**, Benoist S, Maggiori L, Zerbib P, Lefevre JH, Denost Q, Germain A, Cotte E, Beyer-Berjot L, Corté H, Desfourneaux V, Rahili A, Duffas JP, Pautrat K, Denet C, Bridoux V, Meurette G, Faucheron JL, Loriau J, Souche R, Vicaut E, Panis Y, Brouquet A. A Reappraisal of Outcome of Elective Surgery After Successful Non-Operative Management of an Intra-Abdominal Abscess Complicating Ileocolonic Crohn's Disease: A Subgroup Analysis of a Nationwide Prospective Cohort. *J Crohns Colitis* 2021; **15**: 409-418 [PMID: 33090205 DOI: 10.1093/ecco-jcc/jjaa217]
 - 30 **Waked B**, Holvoet T, Geldof J, Baert F, Pattyn P, Lobatón T, Hindryckx P. Conservative management of spontaneous intra-abdominal abscess in Crohn's disease: Outcome and prognostic factors. *J Dig Dis* 2021; **22**: 263-270 [PMID: 33742782 DOI: 10.1111/1751-2980.12984]
 - 31 **Buisson A**, Cannon L, Umanskiy K, Hurst RD, Hyman NH, Sakuraba A, Pekow J, Dalal S, Cohen RD, Pereira B, Rubin DT. Factors associated with anti-tumor necrosis factor effectiveness to prevent postoperative recurrence in Crohn's disease. *Intest Res* 2022; **20**: 303-312 [PMID: 34333909 DOI: 10.5217/ir.2021.00018]
 - 32 **Klek S**, Sierzega M, Turczynowski L, Szybinski P, Szczepanek K, Kulig J. Enteral and parenteral nutrition in the conservative treatment of pancreatic fistula: a randomized clinical trial. *Gastroenterology* 2011; **141**: 157-163, 163.e1 [PMID: 21439962 DOI: 10.1053/j.gastro.2011.03.040]
 - 33 **Kucharski MA**, Wierzbicka A, Tsiulski A, Sotiri E, Dobrowolska A, Mańkowska-Wierzbicka D. Parenteral and Enteral Nutrition: A Bridge to Healing and Biological Therapy in a Patient With Enterocutaneous Fistula and Sepsis Complicated Crohn's Disease. *JPEN J Parenter Enteral Nutr* 2021; **45**: 430-433 [PMID: 32386252 DOI: 10.1002/jpen.1875]
 - 34 **Gong J**, Wei Y, Gu L, Li Y, Guo Z, Sun J, Ding C, Zhu W, Li N, Li J. Outcome of Surgery for Coloduodenal Fistula in Crohn's Disease. *J Gastrointest Surg* 2016; **20**: 976-984 [PMID: 26718702 DOI: 10.1007/s11605-015-3065-z]
 - 35 **Ghimire P**. Management of Enterocutaneous Fistula: A Review. *JNMA J Nepal Med Assoc* 2022; **60**: 93-100 [PMID: 35199684 DOI: 10.31729/jnma.5780]
 - 36 **Papa A**, Lopetuso LR, Minordi LM, Di Veronica A, Neri M, Rapaccini G, Gasbarrini A, Papa V. A modern multidisciplinary approach to the treatment of enterocutaneous fistulas in Crohn's disease patients. *Expert Rev Gastroenterol Hepatol* 2020; **14**: 857-865 [PMID: 32673498 DOI: 10.1080/17474124.2020.1797484]
 - 37 **Abdalla S**, Benoist S, Maggiori L, Zerbib P, Lefevre JH, Denost Q, Germain A, Cotte E, Beyer-Berjot L, Corte H, Desfourneaux V, Rahili A, Duffas JP, Pautrat K, Denet C, Bridoux V, Meurette G, Faucheron JL, Loriau J, Guillon F, Vicaut E, Panis Y, Brouquet A; GETAID Chirurgie group. Impact of preoperative enteral nutritional support on postoperative outcome in patients with Crohn's disease complicated by malnutrition: Results of a subgroup analysis of the nationwide cohort registry from the GETAID Chirurgie group. *Colorectal Dis* 2021; **23**: 1451-1462 [PMID: 33624371 DOI: 10.1111/codi.15600]
 - 38 **Yzet C**, Brazier F, Sabbagh C, Le Mouel JP, Hakim S, Nguyen-Khac E, Fumery M. Endoscopic Treatment of Enterocutaneous Fistulas in Crohn's Disease. *Dis Colon Rectum* 2022; **65**: 721-726 [PMID: 33990501 DOI: 10.1097/DCR.0000000000001995]
 - 39 **Flacs M**, Collard M, Doblas S, Zappa M, Cazals-Hatem D, Maggiori L, Panis Y, Treton X, Ogier-Denis E. Preclinical Model of Perianal Fistulizing Crohn's Disease. *Inflamm Bowel Dis* 2020; **26**: 687-696 [PMID: 31774918 DOI: 10.1093/ibd/izz288]
 - 40 **Mak WY**, Mak OS, Lee CK, Tang W, Leung WK, Wong MTL, Sze ASF, Li M, Leung CM, Lo FH, Lam BCY, Chan KH, Shan EHS, Tsang SWC, Hui AJ, Chow WH, Chan FKL, Sung JY, Ng SC. Significant Medical and Surgical Morbidity in Perianal Crohn's Disease: Results from a Territory-Wide Study. *J Crohns Colitis* 2018; **12**: 1392-1398 [PMID: 30165543 DOI: 10.1093/ecco-jcc/jjy120]
 - 41 **de Las Casas SG**, Alvarez-Gallego M, Martínez JAG, Alcolea NG, Serrano CB, Jiménez AU, Arranz MDM, Martín JLM, Migueláñez IP. Management of perianal fistula in inflammatory bowel disease: identification of prognostic factors associated with surgery. *Langenbecks Arch Surg* 2021; **406**: 1181-1188 [PMID: 33515317 DOI: 10.1007/s00423-021-02100-4]
 - 42 **Biemans VBC**, van der Meulen-de Jong AE, van der Woude CJ, Löwenberg M, Dijkstra G, Oldenburg B, de Boer NKH, van der Marel S, Bodelier AGL, Jansen JM, Haans JLL, Theeuwens R, de Jong D, Pierik MJ, Hoentjen F. Ustekinumab for Crohn's Disease: Results of the ICC Registry, a Nationwide Prospective Observational Cohort Study. *J Crohns Colitis* 2020; **14**: 33-45 [PMID: 31219157 DOI: 10.1093/ecco-jcc/jjz119]
 - 43 **Panés J**, García-Olmo D, Van Assche G, Colombel JF, Reinisch W, Baumgart DC, Dignass A, Nachury M, Ferrante M, Kazemi-Shirazi L, Grimaud JC, de la Portilla F, Goldin E, Richard MP, Diez MC, Tagarro I, Leselbaum A, Danese S; ADMIRE CD Study Group Collaborators. Long-term Efficacy and Safety of Stem Cell Therapy (Cx601) for Complex Perianal Fistulas in Patients With Crohn's Disease. *Gastroenterology* 2018; **154**: 1334-1342.e4 [PMID: 29277560 DOI: 10.1053/j.gastro.2017.12.020]
 - 44 **Schwandner O**. Stem cell injection for complex anal fistula in Crohn's disease: A single-center experience. *World J Gastroenterol* 2021; **27**: 3643-3653 [PMID: 34239275 DOI: 10.3748/wjg.v27.i24.3643]
 - 45 **Chiarello MM**, Pepe G, Fico V, Bianchi V, Tropeano G, Altieri G, Brisinda G. Therapeutic strategies in Crohn's disease in

- an emergency surgical setting. *World J Gastroenterol* 2022; **28**: 1902-1921 [PMID: [35664965](#) DOI: [10.3748/wjg.v28.i18.1902](#)]
- 46 **Goldstone RN**, Steinhagen RM. Abdominal Emergencies in Inflammatory Bowel Disease. *Surg Clin North Am* 2019; **99**: 1141-1150 [PMID: [31676053](#) DOI: [10.1016/j.suc.2019.08.007](#)]
 - 47 **De Simone B**, Davies J, Chouillard E, Di Saverio S, Hoentjen F, Tarasconi A, Sartelli M, Biffi WL, Ansaloni L, Coccolini F, Chiarugi M, De'Angelis N, Moore EE, Kluger Y, Abu-Zidan F, Sakakushev B, Coimbra R, Celentano V, Wani I, Pintar T, Sganga G, Di Carlo I, Tartaglia D, Pikoulis M, Cardi M, De Moya MA, Leppaniemi A, Kirkpatrick A, Agnoletti V, Poggioni G, Carcoforo P, Baiocchi GL, Catena F. WSES-AAST guidelines: management of inflammatory bowel disease in the emergency setting. *World J Emerg Surg* 2021; **16**: 23 [PMID: [33971899](#) DOI: [10.1186/s13017-021-00362-3](#)]
 - 48 **Porter RJ**, Arends MJ, Churchhouse AMD, Din S. Inflammatory Bowel Disease-Associated Colorectal Cancer: Translational Risks from Mechanisms to Medicines. *J Crohns Colitis* 2021; **15**: 2131-2141 [PMID: [34111282](#) DOI: [10.1093/ecco-jcc/ijab102](#)]
 - 49 **Agrawal M**, Spencer EA, Colombel JF, Ungaro RC. Approach to the Management of Recently Diagnosed Inflammatory Bowel Disease Patients: A User's Guide for Adult and Pediatric Gastroenterologists. *Gastroenterology* 2021; **161**: 47-65 [PMID: [33940007](#) DOI: [10.1053/j.gastro.2021.04.063](#)]
 - 50 **Heuschkel R**, Salvestrini C, Beattie RM, Hildebrand H, Walters T, Griffiths A. Guidelines for the management of growth failure in childhood inflammatory bowel disease. *Inflamm Bowel Dis* 2008; **14**: 839-849 [PMID: [18266237](#) DOI: [10.1002/ibd.20378](#)]
 - 51 **Zimmerman L**, Bousvaros A. The pharmacotherapeutic management of pediatric Crohn's disease. *Expert Opin Pharmacother* 2019; **20**: 2161-2168 [PMID: [31574236](#) DOI: [10.1080/14656566.2019.1659778](#)]
 - 52 **Fehmel E**, Teague WJ, Simpson D, McLeod E, Hutson JM, Rosenbaum J, Oliver M, Alex G, King SK. The burden of surgery and postoperative complications in children with inflammatory bowel disease. *J Pediatr Surg* 2018; **53**: 2440-2443 [PMID: [30244938](#) DOI: [10.1016/j.jpedsurg.2018.08.030](#)]
 - 53 **Yerushalmy-Feler A**, Assa A. Pharmacological Prevention and Management of Postoperative Relapse in Pediatric Crohn's Disease. *Paediatr Drugs* 2019; **21**: 451-460 [PMID: [31628665](#) DOI: [10.1007/s40272-019-00361-7](#)]
 - 54 **Xia K**, Gao R, Wu X, Sun J, Wan J, Wu T, Fichna J, Yin L, Chen C. Characterization of Specific Signatures of the Oral Cavity, Sputum, and Ileum Microbiota in Patients With Crohn's Disease. *Front Cell Infect Microbiol* 2022; **12**: 864944 [PMID: [35493739](#) DOI: [10.3389/fcimb.2022.864944](#)]
 - 55 **Yamamoto T**, Shimoyama T, Umegae S, Kotze PG. Impact of Preoperative Nutritional Status on the Incidence Rate of Surgical Complications in Patients With Inflammatory Bowel Disease With Vs Without Preoperative Biologic Therapy: A Case-Control Study. *Clin Transl Gastroenterol* 2019; **10**: e00050 [PMID: [31136361](#) DOI: [10.14309/ctg.0000000000000050](#)]
 - 56 **Yamamoto T**, Allan RN, Keighley MR. Risk factors for intra-abdominal sepsis after surgery in Crohn's disease. *Dis Colon Rectum* 2000; **43**: 1141-1145 [PMID: [10950014](#) DOI: [10.1007/BF02236563](#)]
 - 57 **Shah RS**, Bachour S, Jia X, Holubar SD, Hull TL, Achkar JP, Philpott J, Qazi T, Rieder F, Cohen BL, Regueiro MD, Lightner AL, Click BH. Hypoalbuminaemia, Not Biologic Exposure, Is Associated with Postoperative Complications in Crohn's Disease Patients Undergoing Ileocolic Resection. *J Crohns Colitis* 2021; **15**: 1142-1151 [PMID: [33388775](#) DOI: [10.1093/ecco-jcc/ijaa268](#)]
 - 58 **Yamamoto T**, Nakahigashi M, Shimoyama T, Umegae S. Does preoperative enteral nutrition reduce the incidence of surgical complications in patients with Crohn's disease? *Colorectal Dis* 2020; **22**: 554-561 [PMID: [31782874](#) DOI: [10.1111/codi.14922](#)]
 - 59 **Svolos V**, Hansen R, Nichols B, Quince C, Ijaz UZ, Papadopoulou RT, Edwards CA, Watson D, Alghamdi A, Brejnrod A, Ansaloni C, Duncan H, Gervais L, Tayler R, Salmond J, Bolognini D, Klopfeisch R, Gaya DR, Milling S, Russell RK, Gerasimidis K. Treatment of Active Crohn's Disease With an Ordinary Food-based Diet That Replicates Exclusive Enteral Nutrition. *Gastroenterology* 2019; **156**: 1354-1367.e6 [PMID: [30550821](#) DOI: [10.1053/j.gastro.2018.12.002](#)]
 - 60 **Sohouli MH**, Fatahi S, Farahmand F, Alimadadi H, Seraj SS, Rohani P. Meta-analysis: efficacy of exclusive enteral nutrition as induction therapy on disease activity index, inflammation and growth factors in paediatric Crohn's disease. *Aliment Pharmacol Ther* 2022; **56**: 384-395 [PMID: [35748390](#) DOI: [10.1111/apt.17109](#)]
 - 61 **Di Caro S**, Fragkos KC, Keetart K, Koo HF, Sebeos-Rogers G, Saravanapavan H, Barragry J, Rogers J, Mehta SJ, Rahman F. Enteral Nutrition in Adult Crohn's Disease: Toward a Paradigm Shift. *Nutrients* 2019; **11** [PMID: [31540038](#) DOI: [10.3390/nu11092222](#)]
 - 62 **Bachour SP**, Shah RS, Rieder F, Qazi T, Achkar JP, Philpott J, Lashner B, Holubar SD, Lightner AL, Barnes EL, Axelrad J, Regueiro M, Click B, Cohen BL. Intra-abdominal septic complications after ileocolic resection increases risk for endoscopic and surgical postoperative Crohn's disease recurrence. *J Crohns Colitis* 2022; **16**: 1696-1705 [PMID: [35705188](#) DOI: [10.1093/ecco-jcc/ijac078](#)]
 - 63 **Tzivanakis A**, Singh JC, Guy RJ, Travis SP, Mortensen NJ, George BD. Influence of risk factors on the safety of ileocolic anastomosis in Crohn's disease surgery. *Dis Colon Rectum* 2012; **55**: 558-562 [PMID: [22513434](#) DOI: [10.1097/DCR.0b013e318247c433](#)]
 - 64 **Feagins LA**, Holubar SD, Kane SV, Speechler SJ. Current strategies in the management of intra-abdominal abscesses in Crohn's disease. *Clin Gastroenterol Hepatol* 2011; **9**: 842-850 [PMID: [21679776](#) DOI: [10.1016/j.cgh.2011.04.023](#)]
 - 65 **Byrne LW**, McKay D. Does perioperative biological therapy increase 30-day post-operative complication rates in inflammatory bowel disease patients undergoing intra-abdominal surgery? *Surgeon* 2021; **19**: e153-e167 [PMID: [34581275](#) DOI: [10.1016/j.surge.2020.09.001](#)]
 - 66 **de Buck van Overstraeten A**, Wolthuis A, D'Hoore A. Surgery for Crohn's disease in the era of biologicals: a reduced need or delayed verdict? *World J Gastroenterol* 2012; **18**: 3828-3832 [PMID: [22876034](#) DOI: [10.3748/wjg.v18.i29.3828](#)]
 - 67 **Jensen JS**, Petersen NB, Biagini M, Bollen P, Qvist N. Infliximab treatment reduces tensile strength in intestinal anastomosis. *J Surg Res* 2015; **193**: 145-152 [PMID: [25156230](#) DOI: [10.1016/j.jss.2014.07.022](#)]
 - 68 **Cohen BL**, Fleshner P, Kane SV, Herfarth HH, Palekar N, Farraye FA, Leighton JA, Katz JA, Cohen RD, Gerich ME, Cross RK, Higgins PDR, Tinsley A, Glover S, Siegel CA, Bohl JL, Iskandar H, Ji J, Hu L, Sands BE. Prospective Cohort

- Study to Investigate the Safety of Preoperative Tumor Necrosis Factor Inhibitor Exposure in Patients With Inflammatory Bowel Disease Undergoing Intra-abdominal Surgery. *Gastroenterology* 2022; **163**: 204-221 [PMID: [35413359](#) DOI: [10.1053/j.gastro.2022.03.057](#)]
- 69 **Uchino M**, Ikeuchi H, Horio Y, Kuwahara R, Minagawa T, Kusunoki K, Goto Y, Beppu N, Ichiki K, Ueda T, Nakajima K, Ikeda M. Association between preoperative biologic use and surgical morbidity in patients with Crohn's disease. *Int J Colorectal Dis* 2022; **37**: 999-1010 [PMID: [35384495](#) DOI: [10.1007/s00384-022-04140-8](#)]
 - 70 **Abd El Aziz MA**, Abdalla S, Calini G, Saeed H, Stocchi L, Merchea A, Colibaseanu DT, Shawki S, Larson DW. Postoperative Safety Profile of Minimally Invasive Ileocolonic Resections for Crohn's Disease in the Era of Biologic Therapy. *J Crohns Colitis* 2022; **16**: 1079-1088 [PMID: [35045164](#) DOI: [10.1093/ecco-jcc/jjac012](#)]
 - 71 **Azzam N**, AlRuthia Y, Al Thaher A, Almadi M, Alharbi O, Altuwaijri M, Alshankiti S, Alanazi M, Alanazi A, Aljebreen A, Regueiro M. Rate and risk factors of postoperative endoscopic recurrence of moderate- to high-risk Crohn's disease patients - A real-world experience from a Middle Eastern cohort. *Saudi J Gastroenterol* 2022; **28**: 201-208 [PMID: [35042320](#) DOI: [10.4103/sjg.sjg_499_21](#)]
 - 72 **Cosnes J**, Nion-Larmurier I, Beaugerie L, Afchain P, Tiret E, Gendre JP. Impact of the increasing use of immunosuppressants in Crohn's disease on the need for intestinal surgery. *Gut* 2005; **54**: 237-241 [PMID: [15647188](#) DOI: [10.1136/gut.2004.045294](#)]
 - 73 **Nguyen GC**, Elnahas A, Jackson TD. The impact of preoperative steroid use on short-term outcomes following surgery for inflammatory bowel disease. *J Crohns Colitis* 2014; **8**: 1661-1667 [PMID: [25107847](#) DOI: [10.1016/j.crohns.2014.07.007](#)]
 - 74 **Maruyama BY**, Ma C, Panaccione R, Kotze PG. Early Laparoscopic Ileal Resection for Localized Ileocecal Crohn's Disease: Hard Sell or a Revolutionary New Norm? *Inflamm Intest Dis* 2022; **7**: 13-20 [PMID: [35224013](#) DOI: [10.1159/000515959](#)]
 - 75 **Luglio G**, Kono T. Surgical Techniques and Risk of Postoperative Recurrence in CD: A Game Changer? *Inflamm Intest Dis* 2022; **7**: 21-27 [PMID: [35224014](#) DOI: [10.1159/000515372](#)]
 - 76 **An V**, Cohen L, Lawrence M, Thomas M, Andrews J, Moore J. Early surgery in Crohn's disease a benefit in selected cases. *World J Gastrointest Surg* 2016; **8**: 492-500 [PMID: [27462391](#) DOI: [10.4240/wjgs.v8.i7.492](#)]
 - 77 **Aratari A**, Papi C, Leandro G, Viscido A, Capurso L, Caprilli R. Early versus late surgery for ileo-caecal Crohn's disease. *Aliment Pharmacol Ther* 2007; **26**: 1303-1312 [PMID: [17848181](#) DOI: [10.1111/j.1365-2036.2007.03515.x](#)]
 - 78 **Gomollón F**, Dignass A, Annese V, Tilg H, Van Assche G, Lindsay JO, Peyrin-Biroulet L, Cullen GJ, Daperno M, Kucharzik T, Rieder F, Almer S, Armuzzi A, Harbord M, Langhorst J, Sans M, Chowers Y, Fiorino G, Juillerat P, Mantzaris GJ, Rizzello F, Vavricka S, Gionchetti P; ECCO. 3rd European Evidence-based Consensus on the Diagnosis and Management of Crohn's Disease 2016: Part 1: Diagnosis and Medical Management. *J Crohns Colitis* 2017; **11**: 3-25 [PMID: [27660341](#) DOI: [10.1093/ecco-jcc/jjw168](#)]
 - 79 **Ponsioen CY**, de Groof EJ, Eshuis EJ, Gardenbroek TJ, Bossuyt PMM, Hart A, Warusavitarne J, Buskens CJ, van Bodegraven AA, Brink MA, Consten ECJ, van Wagensveld BA, Rijk MCM, Crolla RMPH, Noomen CG, Houdijk APJ, Mallant RC, Boom M, Marsman WA, Stockmann HB, Mol B, de Groof AJ, Stokkers PC, D'Haens GR, Bemelman WA; LIR!C study group. Laparoscopic ileocaecal resection versus infliximab for terminal ileitis in Crohn's disease: a randomised controlled, open-label, multicentre trial. *Lancet Gastroenterol Hepatol* 2017; **2**: 785-792 [PMID: [28838644](#) DOI: [10.1016/S2468-1253\(17\)30248-0](#)]
 - 80 **Stevens TW**, Haasnoot L, D'Haens GR, Buskens C, de Groof EJ, Eshuis EJ, Gardenbroek TJ, Mol B, Stokkers PCF, Bemelman WA, Ponsioen CY. OP03 Reduced need for surgery and medical therapy after early ileocaecal resection for Crohn's disease: Long-term follow-up of the LIR! *J Crohns Colitis* 2020; **14**: S003-S004 [DOI: [10.1093/ecco-jcc/jjz203.002](#)]
 - 81 **de Groof EJ**, Stevens TW, Eshuis EJ, Gardenbroek TJ, Bosmans JE, van Dongen JM, Mol B, Buskens CJ, Stokkers PCF, Hart A, D'Haens GR, Bemelman WA, Ponsioen CY; LIR!C study group. Cost-effectiveness of laparoscopic ileocaecal resection versus infliximab treatment of terminal ileitis in Crohn's disease: the LIR! *Gut* 2019; **68**: 1774-1780 [PMID: [31233395](#) DOI: [10.1136/gutjnl-2018-317539](#)]
 - 82 **Su X**, Zheng L, Zhang H, Shen T, Liu Y, Hu X. Secular Trends of Acute Viral Hepatitis Incidence and Mortality in China, 1990 to 2019 and Its Prediction to 2030: The Global Burden of Disease Study 2019. *Front Med (Lausanne)* 2022; **9**: 842088 [PMID: [35360747](#) DOI: [10.3389/fmed.2022.842088](#)]
 - 83 **Dong Z**, Wang QQ, Yu SC, Huang F, Liu JJ, Yao HY, Zhao YL. Age-period-cohort analysis of pulmonary tuberculosis reported incidence, China, 2006-2020. *Infect Dis Poverty* 2022; **11**: 85 [PMID: [35902982](#) DOI: [10.1186/s40249-022-01009-4](#)]
 - 84 **Van Assche G**, Lewis JD, Lichtenstein GR, Loftus EV, Ouyang Q, Panes J, Siegel CA, Sandborn WJ, Travis SP, Colombel JF. The London position statement of the World Congress of Gastroenterology on Biological Therapy for IBD with the European Crohn's and Colitis Organisation: safety. *Am J Gastroenterol* 2011; **106**: 1594-602; quiz 1593, 1603 [PMID: [21844919](#) DOI: [10.1038/ajg.2011.211](#)]
 - 85 **Bemelman WA**, Warusavitarne J, Sampietro GM, Serclova Z, Zmora O, Luglio G, de Buck van Overstraeten A, Burke JP, Buskens CJ, Colombo F, Dias JA, Eliakim R, Elosua T, Gecim IE, Kolacek S, Kierkus J, Kolho KL, Lefevre JH, Millan M, Panis Y, Pinkney T, Russell RK, Shwaartz C, Vaizey C, Yassin N, D'Hoore A. ECCO-ESCP Consensus on Surgery for Crohn's Disease. *J Crohns Colitis* 2018; **12**: 1-16 [PMID: [28498901](#) DOI: [10.1093/ecco-jcc/jjx061](#)]



Published by **Baishideng Publishing Group Inc**
7041 Koll Center Parkway, Suite 160, Pleasanton, CA 94566, USA

Telephone: +1-925-3991568

E-mail: bpgoffice@wjgnet.com

Help Desk: <https://www.f6publishing.com/helpdesk>

<https://www.wjgnet.com>

