


World Journal of *Gastrointestinal Surgery*

World J Gastrointest Surg 2022 September 27; 14(9): 877-1088



MINIREVIEWS

- 877** Oncologic aspects of the decision-making process for surgical approach for colorectal liver metastases progressing during chemotherapy
Araujo RLC, Carvalho CGCY, Maeda CT, Milani JM, Bugano DG, de Moraes PHZ, Linhares MM
- 887** Research progress on the immune microenvironment of the gallbladder in patients with cholesterol gallstones
Jiao JY, Zhu XJ, Zhou C, Wang P

ORIGINAL ARTICLE

Retrospective Study

- 896** Central pancreatectomy for benign or low-grade malignant pancreatic tumors in the neck and body of the pancreas
Chen YW, Xu J, Li X, Chen W, Gao SL, Shen Y, Zhang M, Wu J, Que RS, Yu J, Liang TB, Bai XL
- 904** Irinotecan- vs oxaliplatin-based regimens for neoadjuvant chemotherapy in colorectal liver metastasis patients: A retrospective study
Liu W, Chen FL, Wang K, Bao Q, Wang HW, Jin KM, Xing BC
- 918** Predictors of difficult endoscopic resection of submucosal tumors originating from the muscularis propria layer at the esophagogastric junction
Wang YP, Xu H, Shen JX, Liu WM, Chu Y, Duan BS, Lian JJ, Zhang HB, Zhang L, Xu MD, Cao J
- 930** Liver transplantation with simultaneous splenectomy increases risk of cancer development and mortality in hepatocellular carcinoma patients
Fan HL, Hsieh CB, Kuo SM, Chen TW
- 940** Development of an innovative nomogram of risk factors to predict postoperative recurrence of gastrointestinal stromal tumors
Guan SH, Wang Q, Ma XM, Qiao WJ, Li MZ, Lai MG, Wang C
- 950** Comparison of short-term efficacy between totally laparoscopic gastrectomy and laparoscopic assisted gastrectomy for elderly patients with gastric cancer
Zhao RY, Li HH, Zhang KC, Cui H, Deng H, Gao JW, Wei B
- 963** Personal predictive model based on systemic inflammation markers for estimation of postoperative pancreatic fistula following pancreaticoduodenectomy
Long ZD, Lu C, Xia XG, Chen B, Xing ZX, Bie L, Zhou P, Ma ZL, Wang R
- 976** Feasible management of median arcuate ligament syndrome in orthotopic liver transplantation recipients
Li SX, Fan YH, Tian GY, Lv GY

- 986** Study of preoperative diagnostic modalities in Chinese patients with superficial esophageal squamous cell carcinoma

Zeng YT, Sun YY, Tan WC, Luo SA, Zou BH, Luo GY, Huang CY

Observational Study

- 997** Oesophageal cancer metastases: An observational study of a more aggressive approach

Pickett L, Dunne M, Monaghan O, Grogan L, Breathnach O, Walsh TN

- 1008** Change of tumor-infiltrating lymphocyte of associating liver partition and portal vein ligation for staged hepatectomy for hepatocellular carcinoma

Wang W, Deng ZF, Wang JL, Zhang L, Bao L, Xu BH, Zhu H, Guo Y, Wen Z

- 1026** Blood index panel for gastric cancer detection

Guo GH, Xie YB, Zhang PJ, Jiang T

Randomized Controlled Trial

- 1037** Effect of cardiac output - guided hemodynamic management on acute lung injury in pediatric living donor liver transplantation

Dou XJ, Wang QP, Liu WH, Weng YQ, Sun Y, Yu WL

SYSTEMATIC REVIEWS

- 1049** Minimally invasive endoscopic repair of rectovaginal fistula

Zeng YX, He YH, Jiang Y, Jia F, Zhao ZT, Wang XF

META-ANALYSIS

- 1060** Laparoscopic appendectomy, stump closure and endoloops: A meta-analysis

Zorzetti N, Lauro A, Bellini MI, Vaccari S, Dalla Via B, Cervellera M, Cirocchi R, Sorrenti S, D'Andrea V, Tonini V

CASE REPORT

- 1072** Retrorectal mucinous adenocarcinoma arising from a tailgut cyst: A case report and review of literature

Wang YS, Guo QY, Zheng FH, Huang ZW, Yan JL, Fan FX, Liu T, Ji SX, Zhao XF, Zheng YX

LETTER TO THE EDITOR

- 1082** Successful treatment of acute symptomatic extensive portal venous system thrombosis by 7-day systemic thrombolysis

Gao FB, Wang L, Zhang WX, Shao XD, Guo XZ, Qi XS

- 1086** Prediction factors for ischemia of closed-loop small intestinal obstruction

Pavlidis ET, Pavlidis TE

ABOUT COVER

Editorial Board Member of *World Journal of Gastrointestinal Surgery*, Shu-You Peng, FACS, FRCP (Hon), MD, Full Professor, Department of Surgery, Medical School of Zhejiang University, Hangzhou 310009, Zhejiang Province, China. zrwkpsy@zju.edu.cn

AIMS AND SCOPE

The primary aim of *World Journal of Gastrointestinal Surgery* (WJGS, *World J Gastrointest Surg*) is to provide scholars and readers from various fields of gastrointestinal surgery with a platform to publish high-quality basic and clinical research articles and communicate their research findings online.

WJGS mainly publishes articles reporting research results and findings obtained in the field of gastrointestinal surgery and covering a wide range of topics including biliary tract surgical procedures, biliopancreatic diversion, colectomy, esophagectomy, esophagostomy, pancreas transplantation, and pancreatectomy, etc.

INDEXING/ABSTRACTING

The WJGS is now abstracted and indexed in Science Citation Index Expanded (SCIE, also known as SciSearch®), Current Contents/Clinical Medicine, Journal Citation Reports/Science Edition, PubMed, PubMed Central, Reference Citation Analysis, China National Knowledge Infrastructure, China Science and Technology Journal Database, and Superstar Journals Database. The 2022 Edition of Journal Citation Reports® cites the 2021 impact factor (IF) for WJGS as 2.505; IF without journal self cites: 2.473; 5-year IF: 3.099; Journal Citation Indicator: 0.49; Ranking: 104 among 211 journals in surgery; Quartile category: Q2; Ranking: 81 among 93 journals in gastroenterology and hepatology; and Quartile category: Q4.

RESPONSIBLE EDITORS FOR THIS ISSUE

Production Editor: Rui-Rui Wu, Production Department Director: Xiang Li, Editorial Office Director: Jia-Ru Fan.

NAME OF JOURNAL

World Journal of Gastrointestinal Surgery

ISSN

ISSN 1948-9366 (online)

LAUNCH DATE

November 30, 2009

FREQUENCY

Monthly

EDITORS-IN-CHIEF

Peter Schemmer

EDITORIAL BOARD MEMBERS

<https://www.wjgnet.com/1948-9366/editorialboard.htm>

PUBLICATION DATE

September 27, 2022

COPYRIGHT

© 2022 Baishideng Publishing Group Inc

INSTRUCTIONS TO AUTHORS

<https://www.wjgnet.com/bpg/gerinfo/204>

GUIDELINES FOR ETHICS DOCUMENTS

<https://www.wjgnet.com/bpg/GerInfo/287>

GUIDELINES FOR NON-NATIVE SPEAKERS OF ENGLISH

<https://www.wjgnet.com/bpg/gerinfo/240>

PUBLICATION ETHICS

<https://www.wjgnet.com/bpg/GerInfo/288>

PUBLICATION MISCONDUCT

<https://www.wjgnet.com/bpg/gerinfo/208>

ARTICLE PROCESSING CHARGE

<https://www.wjgnet.com/bpg/gerinfo/242>

STEPS FOR SUBMITTING MANUSCRIPTS

<https://www.wjgnet.com/bpg/GerInfo/239>

ONLINE SUBMISSION

<https://www.f6publishing.com>



Minimally invasive endoscopic repair of rectovaginal fistula

Yi-Xian Zeng, Ying-Hua He, Yun Jiang, Fei Jia, Zi-Ting Zhao, Xiao-Feng Wang

Specialty type: Surgery

Provenance and peer review:

Unsolicited article; Externally peer reviewed.

Peer-review model: Single blind

Peer-review report's scientific quality classification

Grade A (Excellent): 0

Grade B (Very good): 0

Grade C (Good): C, C

Grade D (Fair): 0

Grade E (Poor): 0

P-Reviewer: Fiori E, Italy; Ohta H, Japan

Received: May 28, 2022

Peer-review started: May 28, 2022

First decision: June 19, 2022

Revised: June 30, 2022

Accepted: September 2, 2022

Article in press: September 2, 2022

Published online: September 27, 2022



Yi-Xian Zeng, Ying-Hua He, Yun Jiang, Fei Jia, Zi-Ting Zhao, Xiao-Feng Wang, Department of Proctology, Guang'anmen Hospital, China Academy of Chinese Medical Sciences, Beijing 100053, China

Corresponding author: Xiao-Feng Wang, MD, Doctor, Surgeon, Department of Proctology, Guang'anmen Hospital, China Academy of Chinese Medical Sciences, No. 5 North Line Pavilion, Xicheng District, Beijing 100053, China. wangxiaofeng74@hotmail.com

Abstract

BACKGROUND

Surgical techniques for repair of rectovaginal fistula (RVF) have been continually developed, but the ideal procedure remains unclear. Endoscopic repair is a novel and minimally invasive technique for RVF repair with increasing reporting.

AIM

To review the current applications and preliminary outcomes of this technique for RVF repair, aiming to give surgeons an alternative in clinical practice.

METHODS

Available articles were searched according to the search strategy. And the sample size, fistula etiology, fistula type, endoscopic repair approaches, operative time and hospital stay, follow-up period, complication and life quality assessment were selected for recording and further analysis.

RESULTS

A total of 11 articles were eventually identified, involving 71 patients with RVFs who had undergone endoscopic repair. The principal causes of RVFs were surgery ($n = 51$, 71.8%), followed by obstetrics ($n = 7$, 9.8%), inflammatory bowel disease ($n = 5$, 7.0%), congenital ($n = 3$, 4.2%), trauma ($n = 2$, 2.8%), radiation ($n = 1$, 1.4%), and in two patients, the cause was unclear. Most fistulas were in a mid or low position. Several endoscopic repair methods were included, namely transanal endoscopic microsurgery, endoscopic clipping, and endoscopic stenting. Most patients underwent > 1-year follow-up, and the success rate was 40%-93%, and all cases reported successful closure. Few complications were mentioned, while postoperative quality of life assessment was only mentioned in one study.

CONCLUSION

In conclusion, endoscopic repair of RVF is novel, minimally invasive and promising with acceptable preliminary effectiveness. Given its unique advantages, endoscopic repair can be an alternative technique for surgeons.

Key Words: Endoscopic repair; Minimal-invasive technique; Rectovaginal fistula

©The Author(s) 2022. Published by Baishideng Publishing Group Inc. All rights reserved.

Core Tip: The current status of minimally invasive endoscopic repair for rectovaginal fistulas (RVFs) was reviewed. This is the first review to explore the current application status and evaluate the preliminary outcomes. Endoscopic repair is recommended as a novel and promising technique for RVF and warrants consideration by surgeons. The disappointing quality of published studies on surgical treatment of RVF is discussed, along with the possible role of endoscopic repair in improving the situation.

Citation: Zeng YX, He YH, Jiang Y, Jia F, Zhao ZT, Wang XF. Minimally invasive endoscopic repair of rectovaginal fistula. *World J Gastrointest Surg* 2022; 14(9): 1049-1059

URL: <https://www.wjgnet.com/1948-9366/full/v14/i9/1049.htm>

DOI: <https://dx.doi.org/10.4240/wjgs.v14.i9.1049>

INTRODUCTION

Rectovaginal fistula (RVF), a type of chronic gastrointestinal fistula, refers to an abnormal epithelialized-lined connection between the rectum and the vagina, presenting with symptoms including uncontrollable passage of gas and/or fecal discharge from the vagina[1]. Even though it is benign, the distressing and persistent symptoms interfere with daily activities and sexual life, and have a long-term potential detrimental impact on psychological health[2,3]. Obstetric trauma is the primary etiological factor for RVF, but it can also be acquired from local abscess, pelvic floor or rectal surgery, trauma, or radiotherapy[3-5]. Chronic inflammatory bowel disease (most commonly Crohn's disease) is the second most common etiology with rates varying between 6% and 23%[6]. It is reported that RVF occurs in up to 10% of women diagnosed with Crohn's disease[7,8]. Congenital RVF is rare, usually coexists with anal malformation, and can be treated by anal reconstruction at a young age[9].

Standard classification of RVF will benefit to the choice of treatment approach and the comparison of treatment outcomes between studies, and help develop an algorithm for repair. However, there is no generally accepted classification of RVF. Currently, the classification of "simple/complex" or "low/middle/high" according to location, size, and etiology of RVF is most used[10,11]. With the development of diagnostic and therapeutic techniques, the imaging results, endoscopic exploration and gradually defined local anatomical structure will promote a classification consensus[12,13]. The anatomical features are always the principle of classification, which makes it necessary to achieve a more detailed and precise anatomical recognition[14].

Various medical and surgical treatments have been applied for RVF, but treatment is still a challenge for doctors due to the high recurrence rate. Nonoperative methods are recommended for the treatment of fresh and slight symptomatic fistula. Surgical repair is essential, once it occurs and persists[15]. There is still no standard surgical repair technique worldwide for RVF and no evidence can suggest one surgical technique over another since the release of the procedural guidelines in Europe.

Multiple surgical repair techniques, including fistulectomy, advancement flap, muscle transposition, closure with biomaterials, endoscopic repair and transabdominal approaches[16], have been gradually reported in the literature. Fistulectomy is not technically demanding, whose main step is to remove the fistula tract, together with the surrounding scarred and sclerotic tissue. It may fail due to incomplete removal and excessive tissue tension of tissue suture for large excision, and is therefore, mostly used to repair small and simple RVFs[17,18]. Advancement flaps are performed by raising either the rectal mucosa (transrectal) or vaginal mucosa (transvaginal) to cover the fistula tract. Transrectal advancement flap is more commonly adopted compared to the transvaginal approach, and the repair is performed from the high pressure of the rectum side, and has an actual success rate of 50%-70%[1,4]. Even though some studies have recommended transrectal advancement flap as the first-line treatment for low RVFs, it is not as effective as expected if the periorificial tissue is chronically inflamed, or when the fistula is large in diameter and causes anal stenosis[19]. Reconstruction by Martius flap, gracilis muscle flap or bulbocavernosus muscle transposition can be used to introduce healthy vascularized tissues, which has achieved a certain effect for recurrent, Crohn's-disease-related and radiation-related RVFs, with reported overall success rates ranging from 25% to 100%[20,21]. However, given the aggressive incision, tissue damage, prolonged hospital stay and protective stoma diversion routinely required, this technique is demanding and not easily accepted by patients[22,23]. Biomaterials and endoscopic repair are novel and less invasive techniques and constant attempts have been made to apply them for RVF repair. However, given the limited number of publications available, there are currently no relevant recommendations. Transabdominal approaches are recommended for high RVFs resulting from

complications of colorectal anastomosis, and laparoscopic repair has been frequently adopted[15,24]. In clinical practice, protective stoma diversion is generally applied for the treatment of RVF, whereas absence of any reliable efficacy assessment for RVF makes it remain controversial. Theoretically, diversion stoma may help control the symptoms by fecal diversion and support healing of the fistula and surgical success[25]. Corte *et al*[26] claimed that a temporary diversion stoma could significantly improve the success rate of repair. However, Lambert *et al*[27] found no connection between diversion stoma creation and rate of recurrence, which was supported by other authors[28,29]. Some studies have shown that radiation- and Chron's-disease-related RVFs are indications for diversion stoma[30,31], and stating that once the diversion stoma is made, large invasion, distressing conditions and potential complications can occur[32]. Although the techniques for RVF repair have been developing, the etiology, classification, surrounding tissue condition, prior treatment procedures and the surgeon's preference are always the basis for determining the approach. In addition, individualized, precise, and less-invasive surgical techniques for RVFs repair are gradually being recommended[13,33].

All the surgical interventions performed *via* an endoscope or in the endoscopy unit can be classified as endoscopic repair, which is a novel and minimally invasive surgical technique for RVF. Several endoscopic repair approaches have been applied and reported for RVF surgical treatment. Transanal endoscopic microsurgery (TEMS) is an endoscopic technique performed entirely through the anus and rectum, which was originally developed in the 1980s to treat lower rectal adenomas[34] (Figure 1). Vávra *et al*[35] reported the first case of RVF treatment using TEMS in 2006, which is one of the most reported endoscopic approaches for RVF. Several minimally invasive endoscopic approaches such as the through-the-scope clip (TTSC), over-the-scope clip proctology system (OTSC) and endoscopic stenting have successively proven their role in RVF repair. After more than a decade of development, endoscopic repair for RVF has been continuously advanced and more advantages have been unveiled. Endoscopic repair for RVF is novel but limited by the information available. Therefore, a review of studies on minimally invasive endoscopic repair for RVF was carried out to assess the preliminary outcomes and introduce several endoscopic approaches for RVF surgical repair to surgeons, thereby contributing to developing a more individualized, precise, and less-invasive treatment plan appropriate for each patient.

MATERIALS AND METHODS

A search was performed to identify the existing literature available in PubMed and EMBASE databases in December 2021, without timeframe limitations (Figure 2). The following keywords, including "rectovaginal fistula," "rectovaginal," "fistula," "endoscope", "endoscopic," and "endoscopy", were used for searching. Given that there were only around 184 articles available, every single article was reviewed at the beginning. Exclusion criteria included irrelevancy, not English language, guidelines, or reviews. Articles published by the same author were found a duplication in the inclusion of patients, and the study with the longest follow-up was included. Three independent reviewers extracted and summarized data from the included articles and conducted qualitative assessment in accordance with the Oxford Centre for Evidence-Based Medicine 2011 Level of evidence[36]. All disagreements were settled by consensus. In addition, we conducted a research using Reference Citation Analysis (<https://www.referencecitationanalysis.com/>) and cited the relevant references.

RESULTS

A total of 11 articles were eventually identified according to the search strategy. Data were extracted by the reviewers and eventually reported using summary statistics, as shown in Table 1. The limited number of available articles and the low evidence of all studies made the primary outcome not sufficiently satisfactory. Besides, there were not enough eligible articles to perform a meta-analysis. In terms of the type of study, case reports seemed to be preferred for this novel technique, and the number of patients in each retrospective study was limited. The etiology was classified as: related to surgery ($n = 51$) such as rectal surgery, pelvic surgery and the colorectal anastomosis, *etc.*, with 22 patients undergoing rectal surgery with a history of radiotherapy; and directly caused by radiotherapy ($n = 1$), inflammatory bowel diseases ($n = 5$) including Crohn's disease and ulcerative colitis; congenital ($n = 3$), obstetric injury ($n = 7$), trauma ($n = 2$), with the etiology unclear in two patients. Most fistulas were situated in the middle or low. Most of the patients had undergone previous repairs, even on multiple occasions. Fecal diversion was chosen as part of surgical treatment in some patients. Psychological components regarded as important as the success rate were rarely reported[19,37], with improved sexual function after repair mentioned in only one paper.

Table 2 summarized the details and preliminary outcomes of endoscopic repair of RVFs. A total of 38 patients underwent the conventional surgical procedure with a transrectal endoscopic device, when the layered suture was closed for 24, and mucosal advancement flap was for 14 patients. Endoscopic clip was another commonly used approach for RVF repair, and 18 patients who were treated using this

Table 1 Extract data of studies included

Number	Ref.	Type of study and evidence level	No. of patient(s)	Age of patients (yr)	Fistula etiology	Fistula type	No. of patients with previous repair	Diversion stoma	Life quality assessment (yes or no)
1	D'Ambrosio <i>et al</i> [41], 2012	Retrospective, level IV	13	44 (range, 25-70)	Surgery (<i>n</i> = 12); Radiation (<i>n</i> = 1)	Mid-low	13	Yes, 13 patients	No
2	Lamazza <i>et al</i> [54], 2016	Retrospective, level IV	15	58 (rang, 36-77)	Surgery with radiation (<i>n</i> = 15)	Mid-low	4	Yes, 4 patients	No
3	van Vledder <i>et al</i> [56], 2016	Retrospective, level IV	5	40 (range, 35-73)	Surgery (<i>n</i> = 5)	Mid-low	0	Yes, 3 patients	No
4	Yuan <i>et al</i> [42], 2019	Retrospective, level IV	17	46 (range, 10-76)	Surgery (<i>n</i> = 11); Congenital (<i>n</i> = 3); Obstetric (<i>n</i> = 2); IBDs (<i>n</i> = 1)	Mid-low	6	Yes, 9 patients	No
5	Tong <i>et al</i> [50], 2019	Prospective, level IV	16	40.1 (range, 27-56)	Surgery with radiation (<i>n</i> = 6); Obstetric (<i>n</i> = 5); IBDs (<i>n</i> = 3); Unclear (<i>n</i> = 2)	Mid-low	13	Yes, 11 patients	No
6	Shibata <i>et al</i> [57], 1999	Case report, level IV	1	71	Surgery	Low	0	No	No
7	Darwood <i>et al</i> [58], 2008	Case report, level IV	1	71	Surgery with radiation (<i>n</i> = 1)	Unclear	0	Yes	No
8	John <i>et al</i> [45], 2008	Case report, level IV	1	77	Infection (<i>n</i> = 1)	Mid	0	No	No
9	Vavra <i>et al</i> [59], 2009	Case report, level IV	1	53	Trauma (<i>n</i> = 1)	Mid	0	Yes	Yes
10	Chen <i>et al</i> [43], 2016	Case report, level IV	1	22	Trauma (<i>n</i> = 1)	Mid	2	Yes	No
11	Matano <i>et al</i> [48], 2019	Case report, level IV	1	71	Surgery (<i>n</i> = 1)	Mid	Multiple times	Yes	No

technique benefited from TTSC (*n* = 2) and OTSC (*n* = 16). One retrospective study reported endoscopic repair with placement of a self-expandable metal stent (*n* = 15). Several other endoscopic repair approaches for RVF such as endoscopic plugs, endoscopic injection and endoscopic-laparoscopic combined approach were noted, which were removed due to no complete references. Operating time and hospital stay were the desired outcomes, but not frequently reported. Most patients underwent > 1 year of follow-up. All case reports reported successful outcomes, but the success rates were different (40%-93%) in retrospective case series. More than half the studies reported no severe complications, and a few reported some minor postoperative complications, such as hematoma or abscess of rectovaginal septum (*n* = 2), moderate sphincter hypotonia (*n* = 1), pain (*n* = 5), minimal vaginal flatus (*n* = 1).

Minimally invasive endoscopic repair

TEMS: Minimally invasive techniques have been one of the major advancements in surgery in the last few decades, and are also one of the future trends. Such a technique has been almost routinely performed in colorectal resection irrespective of underlying diseases[38]. With the development of surgical instruments, endoscopic surgery is considered a feasible and minimally invasive approach that can facilitate better exposure, direct visualization and precise operation, with an increasing number of surgeons choosing it[39]. TEMS, as a platform for natural orifice transluminal endoscopic surgery, has developed into a well-established method of accurate resection of specimens from the rectum under binocular vision after the initial application for rectal cancer, and has also been adopted as an operative intervention in an extended setting for RVF[40]. After the first case of TEMS for RVF repair reported in 2006[35], the first retrospective review with 13 patients who had undergone layered sutures *via* this repair technique was published in 2012, with a closure rate of 93%[41]. In the present review, more than half of patients (*n* = 38) underwent conventional surgical repair procedures with transanal endoscopic devices, with a success rate of 40%-93%. The latest study reported a closure rate of 82% of mid-low RVF TEMS with layered sutures and mucosal advancement flaps[42]. Another three cases all reported successful closure. The superior 3D exposure and direct vision were the greatest advantages of TEMS. Under good visualization, comprehensive procedures exploring the anatomical structural relationship

Table 2 Details and results of the endoscopic repair approaches for rectovaginal fistulas

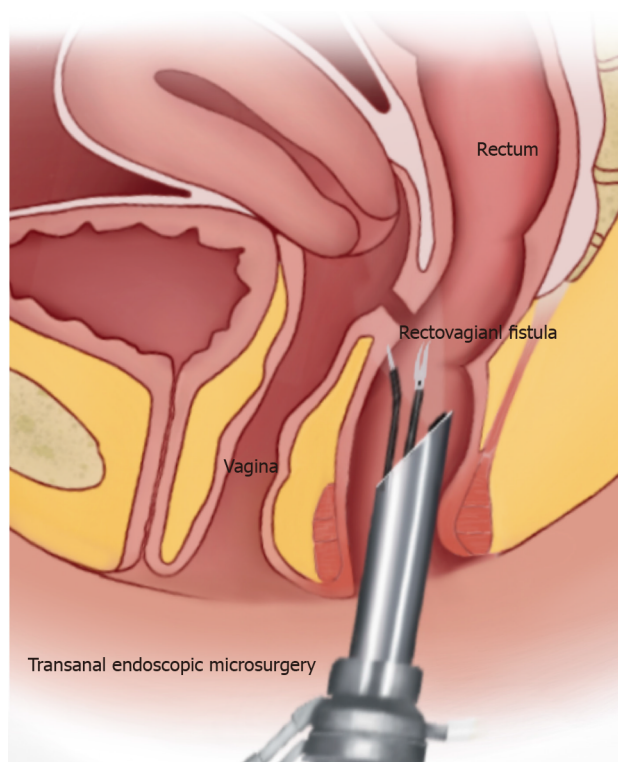
Number	Endoscopic repair	Operative time (min) and hospital-stay (d)	Follow-up (mo)	Results ^a	Complication
1	TEMS + fistulectomy + suturing (<i>n</i> = 13)	130 min (range, 90-150 min); 5 d (range, 3-8 d)	25	93% closed	Hematoma of the septum (<i>n</i> = 1); Abscess of the septum (<i>n</i> = 1); Moderate sphincter hypotonia (<i>n</i> = 1)
2	Endoscopic stenting (<i>n</i> = 15)	Unclear; Unclear	22 (range, 4-39)	80% closed	Pain (<i>n</i> = 1); Too uncomfortable to tolerate the stent (<i>n</i> = 1)
3	TEMS + fistulectomy + suturing (<i>n</i> = 4); TEMS + RAF (<i>n</i> = 1)	Unclear; Unclear	5 (range, 1-68)	40% closed	No complication
4	TEMS + VAF (<i>n</i> = 6); TEMS exploration + VAF (<i>n</i> = 6); TEMS + transvaginal suturing (<i>n</i> = 3); TES exploration + transvaginal suturing (<i>n</i> = 2)	75 min (range, 60-120 min); 8.29 d (range, 2-24 d)	8 (range, 2-24)	82.4% closed	No complication
5	OTSCs (<i>n</i> = 16)	Unclear; Unclear	10.2 (range, 8-36)	43.7% closed	Pain (<i>n</i> = 4); Spontaneous clip detachment (<i>n</i> = 1)
6	Endoscopic injection of fibrin glue (<i>n</i> = 1)	Few min; 0 d	12	Closed successfully	No complication
7	TEMS + RAF (<i>n</i> = 1)	Unclear; 2 d	6	Closed successfully	No complication
8	TTSCs (<i>n</i> = 1)	Unclear; Unclear	12	Closed successfully	Minimal flatus from vaginal (<i>n</i> = 1)
9	TEMS + suturing (<i>n</i> = 1)	125 min; 7d	12	Closed successfully	No complication
10	TEMS + stratified suturing (<i>n</i> = 1)	40 min; 2 d	12	Closed successfully	No complication
11	TTSCs (<i>n</i> = 1)	Unclear; Unclear	13	Closed successfully	No complication

^aSuccess rate (%) for retrospective or prospective studies, closed successfully or unsuccessfully for case reports.

TEMS: Transanal endoscopic microsurgery; OTSC: Over-the-scope clip; TTSC: Through-the-scope clip; RAF: Rectal advancement flap; VAF: Vaginal advancement flap.

could be provided preoperatively and intraoperatively. The conventional invasive procedure could be performed more accurately with TEMS equipment, and ensure complete removal of the surrounding scarred or granulomatous tissues, but without significant loss of normal tissue. Therefore, there was a greater certainty of adequate blood supply to the tissue overlaps and/or flaps owing to the fresh tissue with the healthy margins[42]. In addition, the smaller tissue defect and good control of suture tightness enable free-tension repair[43], and make up for the shortcomings of conventional local repair that cannot completely remove surrounding tissue and is subject to insufficient blood supply and prompt healing. Using a natural endoluminal approach with endoscopy, precise operation and visualization can greatly reduce the invasiveness of conventional surgery with less intraoperative bleeding, shorter operating time and hospital stay, and fewer postoperative complications.

Endoscopic clipping: Endoscopic clipping is another technology using endoclips to completely close gastrointestinal leaks and fistulas, initially applied for iatrogenic gastric perforation in 1993[44]. John *et al*[45] reported the first successful closure of an RVF with TTSCs, which was also applied for repair of refractory RVF[33]; Ortiz-Moyano *et al*[46] described a combined approach using TTSCs and tissue adhesive that improved the rate of technical success in the endoscopic clips treatment of RVFs, since clips not only worked in opposing the margins, but acted as a scaffold for the glue. OTSCs for the gastrointestinal tract had greater force and a consistently high mean rate of procedural success of 80%-100%, and a durable clinical success rate of 57%-100%, and was preferred over TTSCs for closure of gastrointestinal fistulas[47]. Regarding colon perforation, small perforations (< 10 mm) could be successfully closed with TTSCs, whereas larger perforations could be successfully closed with OTSCs [48]. The first RVF closure using the OTSC proctology system was performed by Probst *et al*[49] in 2015. One prospective study in 2019[50] presented the first evaluation of the therapeutic effects and safety of the application of OTSCs in complex RVFs, with a success rate of 43.7%, which was as high as that for gastrointestinal fistulas and convincing for complicated ones. Endoscopic clipping is a minimally invasive technique that involves transrectal placement of endoclips for RVF closure to avoid tissue incision, sphincter damage and intraoperative bleeding[49]. It is considered suitable for small fistulas,



DOI: 10.4240/wjgs.v14.i9.1049 Copyright ©The Author(s) 2022.

Figure 1 Transanal endoscopic microsurgery for rectovaginal fistula repair.

and is even recommended to repair high-level fistulas[45,48]. Given limited data and obtained evidence, the role of endoscopic clips in RVF repair remains to be further investigated.

Endoscopic stenting: Endoscopic stenting involves placement of a self-expandable metal stent into the gastrointestinal tract to treat the defects, especially anastomotic leaks or perforation of the upper gastrointestinal tract[51]. Endoscopic placement of the self-expandable metal stent to treat RVFs after colorectal resection for cancer was a useful alternative to divert colostomy for the palliation of malignant rectal obstruction[52]. The team presented the two series outcomes with a success rate of 83% (5 of 6 patients)[53] and 80% (12 of 15 patients)[54], and the fistula size decreased significantly in all remaining patients, indicating that endoscopic placement of self-expandable metal stents may be a valid adjunctive treatment of RVF after colorectal resection for cancer. However, the favorable results may have been due to the low number of patients and selection bias. In the selected cases, the endoscopic placement of the self-expandable metal stent for RVF repair showed that the endoscopic stenting allowed a fast and proper closure of the fistula in a minimally invasive endoscopic way, with minor discomfort for patients and early discharge. A clear indication and results are still required for further in-depth study.

DISCUSSION

Surgical outcomes of RVF repair are mostly measured by the rates of closure and reoperation[37]. The successful closure rates for RVF surgical repair vary in the literature[55]. A similar variation in success rate (20%-93%) was found in this study using different etiologies and endoscopic approaches. We acknowledge that the varying rate of successful closure, limited number of publications available on this novel technique, and the low quality of included studies were limitations of the present review. In addition, the indications for endoscopic repair for RVF are not clear due to the lack of high-quality clinical studies. From a review of the included literature, endoscopic repair for RVF seems to be more commonly used in the treatment of low- and mid-level fistulas. However, it is also used for high-level fistulas with small openings, because transabdominal surgery is an invasive approach for small fistulas; therefore, endoscopic repair is considered a viable minimally invasive approach[48]. Moreover, endoscopic repair is a promising option for primary repair of RVF, and can be recommended for treatment of recurrent fistulas as well[50]. Regarding endoscopic repair is performed locally, it is not suitable for refractory RVFs with large openings and excessive tissue defects. Nevertheless, the minimally invasive endoscopic approach for RVF repair is a promising choice, and more surgical methods could be developed based on the endoscopic technique. As the research progresses, more

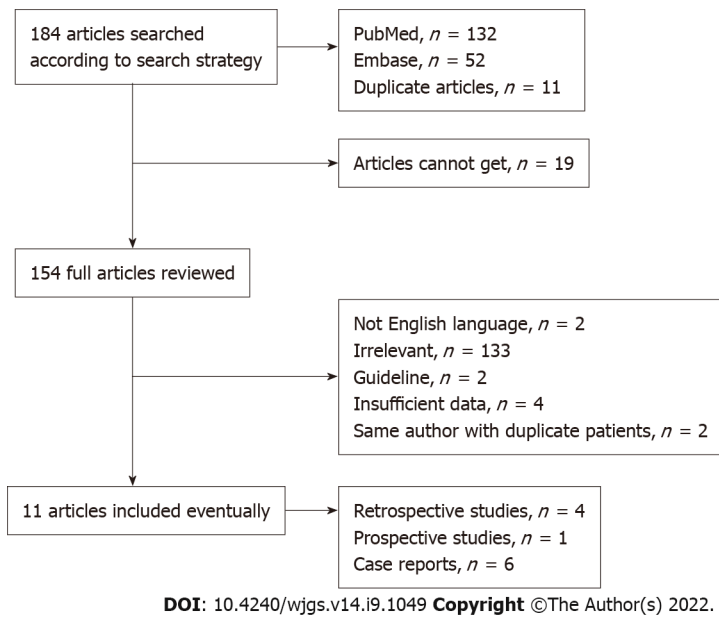


Figure 2 The search strategy.

indications should be unveiled as well.

A 2014 systematic review claimed that the reason for difficulties in formulating a conclusion about the best surgical technique for RVF repair was the disappointing quality of existing literature surrounding different surgical techniques and outcomes for RVF repair[16]. Such a result not only persisted in the present review, but also in some related to single surgical approaches[8,20]. On the one hand, the limited number of samples and the heterogeneity of etiologies and local conditions made it hard to design large studies. RVF is a benign and chronic disease without a high incidence, but subject to variable and complex causes. There is no doubt that compared to the sample iatrogenic etiologies, IBDs-or radiation-related RVF would make difference in the local condition and the selection of surgical techniques. Therefore, retrospective studies were reviewed carefully to ensure the study sample size and homogeneity. With the continuous advancement of endoscopic techniques, different surgical procedures can be applied and standardized, which may improve the homogeneity of the surgical devices and contribute to designing large studies. On the other hand, in terms of the precise anatomical relationship of the fistula defect and the surrounding tissue, the lack of consensus on classification of RVFs makes it difficult to compare different surgical techniques. It is therefore proposed that further revisions are needed to guide the choice of newly developed treatment approaches[19]. Additionally, some authors claimed that a precise preoperative anatomical relationship assessment allowed better classification of fistulas and comparisons among different techniques[14]. It is believed that diagnostic imaging and endoscopic exploration could play a role in clarifying and developing anatomical relationship standards.

CONCLUSION

Endoscopic repair for RVFs is novel, effective and promising. A precise operation under good visualization through a natural lumen can reduce the invasiveness of conventional procedures. Some endoscopic surgical modes such as clipping and stenting mentioned in this review could even close the fistula without incision, less intraoperative bleeding, fewer complications, and shorter operating time and hospital stay. Surgeons could clarify the anatomical relationship of the fistula and surrounding tissue by endoscopic preoperative exploration and provide patients with a more appropriate treatment approach. However, endoscopic surgical repair for RVFs is technically demanding with a long learning curve and requires sufficient professional experience. Therefore, it is advocated to be performed by professional colorectal surgeons in highly specialized centers. Besides, larger high-quality studies and longer follow-up studies are necessary to unveil the clear indication and advantages of this novel minimally invasive endoscopic technique for RVF repair.

ARTICLE HIGHLIGHTS

Research background

Rectovaginal fistula (RVF) is abnormal connection between the rectum and vagina. Surgical repair is essential, once it occurs and persists. Surgical techniques for repair of rectovaginal fistula have been continually developed, but the ideal procedure remains unclear. Endoscopic repair is a novel and minimally invasive technique for RVF repair with increasing reporting.

Research motivation

To review the current literature of endoscopic repair of RVF and highlight the novel and minimally invasive technique for RVF repair to surgeons.

Research objectives

To evaluate the preliminary outcomes of this technique for RVF repair and analyze the indication and technical superiority.

Research methods

We searched PubMed and EMBASE databases for available studies. Data were extracted and qualitative assessment was conducted.

Research results

The endoscopic repair of RVF is in constant development, including several available approaches. The preliminary effectiveness of endoscopic technique for RVF repair is acceptable.

Research conclusions

Endoscopic repair for RVF is novel, effective and promising with acceptable preliminary effectiveness. In this manuscript, we have provided a detailed review of literatures, summarized its indications and unique technical advantages and made suggestions for its application and future development.

Research perspectives

Endoscopic repair for RVF is effective and safe according to preliminary outcomes. It is a promising technique for the treatment of rectovaginal fistulas and provides a minimally invasive technique selection for surgeons to treat rectovaginal fistulas.

FOOTNOTES

Author contributions: All authors contributed to this manuscript; Zeng YX, Wang XF and He YH designed the outline of this review; Zeng YX performed most of the writing, and prepared the figures and tables; Wang XF and He YH made critical revision of the manuscript for important intellectual content; Jiang Y, Jia F and Zhao ZT performed data acquisition, and writing; All authors read and approved the final version.

Conflict-of-interest statement: No benefits in any form have been received or will be received from a commercial party related directly or indirectly to the subject of this article.

PRISMA 2009 Checklist statement: The authors have read the PRISMA 2009 Checklist, and the manuscript was prepared and revised according to the PRISMA 2009 Checklist.

Open-Access: This article is an open-access article that was selected by an in-house editor and fully peer-reviewed by external reviewers. It is distributed in accordance with the Creative Commons Attribution NonCommercial (CC BY-NC 4.0) license, which permits others to distribute, remix, adapt, build upon this work non-commercially, and license their derivative works on different terms, provided the original work is properly cited and the use is non-commercial. See: <https://creativecommons.org/licenses/by-nc/4.0/>

Country/Territory of origin: China

ORCID number: Yi-Xian Zeng 0000-0002-9219-9103; Ying-Hua He 0000-0002-8970-4519; Yun Jiang 0000-0002-4449-2137; Fei Jia 0000-0002-4114-492X; Zi-Ting Zhao 0000-0003-4023-0006; Xiao-Feng Wang 0000-0001-6053-8177.

S-Editor: Zhang H

L-Editor: A

P-Editor: Zhang H

REFERENCES

- 1 **Kniery KR**, Johnson EK, Steele SR. Operative considerations for rectovaginal fistulas. *World J Gastrointest Surg* 2015; **7**: 133-137 [PMID: [26328032](#) DOI: [10.4240/wjgs.v7.i8.133](#)]
- 2 **Baig MK**, Zhao RH, Yuen CH, Nogueras JJ, Singh JJ, Weiss EG, Wexner SD. Simple rectovaginal fistulas. *Int J Colorectal Dis* 2000; **15**: 323-327 [PMID: [11151438](#) DOI: [10.1007/s003840000253](#)]
- 3 **Byrnes JN**, Schmitt JJ, Faustich BM, Mara KC, Weaver AL, Chua HK, Occhino JA. Outcomes of Rectovaginal Fistula Repair. *Female Pelvic Med Reconstr Surg* 2017; **23**: 124-130 [PMID: [28106653](#) DOI: [10.1097/SPV.0000000000000373](#)]
- 4 **Ommer A**, Herold A, Berg E, Fürst A, Schiedeck T, Sailer M. German S3-Guideline: rectovaginal fistula. *Ger Med Sci* 2012; **10**: Doc15 [PMID: [23255878](#) DOI: [10.3205/000166](#)]
- 5 **Rahman MS**, Al-Suleiman SA, El-Yahia AR, Rahman J. Surgical treatment of rectovaginal fistula of obstetric origin: a review of 15 years' experience in a teaching hospital. *J Obstet Gynaecol* 2003; **23**: 607-610 [PMID: [14617459](#) DOI: [10.1080/01443610310001604349](#)]
- 6 **Pinto RA**, Peterson TV, Shawki S, Davila GW, Wexner SD. Are there predictors of outcome following rectovaginal fistula repair? *Dis Colon Rectum* 2010; **53**: 1240-1247 [PMID: [20706066](#) DOI: [10.1007/DCR.0b013e3181e536cb](#)]
- 7 **Valente MA**, Hull TL. Contemporary surgical management of rectovaginal fistula in Crohn's disease. *World J Gastrointest Pathophysiol* 2014; **5**: 487-495 [PMID: [25400993](#) DOI: [10.4291/wjgp.v5.i4.487](#)]
- 8 **Kaimakliotis P**, Simillis C, Harbord M, Kontovounisios C, Rasheed S, Tekkis PP. A Systematic Review Assessing Medical Treatment for Rectovaginal and Enterovesical Fistulae in Crohn's Disease. *J Clin Gastroenterol* 2016; **50**: 714-721 [PMID: [27466166](#) DOI: [10.1097/MCG.0000000000000607](#)]
- 9 **Oh C**, Youn JK, Han JW, Yang HB, Kim HY, Jung SE, Park KW. Experiences of Rectovaginal Fistula in Anorectal Malformation. *J Pediatr Surg* 2020; **55**: 1495-1498 [PMID: [31416593](#) DOI: [10.1016/j.jpedsurg.2019.06.021](#)]
- 10 **Rothenberger DA**, Goldberg SM. The management of rectovaginal fistulae. *Surg Clin North Am* 1983; **63**: 61-79 [PMID: [6338609](#) DOI: [10.1016/s0039-6109\(16\)42930-0](#)]
- 11 **Abu Gazala M**, Wexner SD. Management of rectovaginal fistulas and patient outcome. *Expert Rev Gastroenterol Hepatol* 2017; **11**: 461-471 [PMID: [28276809](#) DOI: [10.1080/17474124.2017.1296355](#)]
- 12 **Rociu E**, Stoker J, Zwamborn AW, Laméris JS. Endoanal MR imaging of the anal sphincter in fecal incontinence. *Radiographics* 1999; **19** Spec No: S171-S177 [PMID: [10517453](#) DOI: [10.1148/radiographics.19.suppl_1.g99oc02s171](#)]
- 13 **Komori K**, Kinoshita T, Oshiro T, Ouchi A, Ito S, Abe T, Senda Y, Misawa K, Ito Y, Natsume S, Higaki E, Okuno M, Hosoi T, Nagao T, Kunitomo A, Oki S, Takano J, Suenaga Y, Maeda S, Dei H, Numata Y, Shimizu Y. Surgical Strategy for Rectovaginal Fistula After Colorectal Anastomosis at a High-volume Cancer Center According to Image Type and Colonoscopy Findings. *Anticancer Res* 2019; **39**: 5097-5103 [PMID: [31519621](#) DOI: [10.21873/anticancer.13704](#)]
- 14 **Hauch A**, Ramamoorthy S, Zelhart M, Dobke M. Refining Approaches to Surgical Repair of Rectovaginal Fistulas. *Ann Plast Surg* 2020; **84**: S250-S256 [PMID: [31923012](#) DOI: [10.1097/SAP.00000000000002207](#)]
- 15 **Vogel JD**, Johnson EK, Morris AM, Paquette IM, Saclarides TJ, Feingold DL, Steele SR. Clinical Practice Guideline for the Management of Anorectal Abscess, Fistula-in-Ano, and Rectovaginal Fistula. *Dis Colon Rectum* 2016; **59**: 1117-1133 [PMID: [27824697](#) DOI: [10.1097/DCR.0000000000000733](#)]
- 16 **Göttgens KW**, Smeets RR, Stassen LP, Beets G, Breukink SO. The disappointing quality of published studies on operative techniques for rectovaginal fistulas: a blueprint for a prospective multi-institutional study. *Dis Colon Rectum* 2014; **57**: 888-898 [PMID: [24901691](#) DOI: [10.1097/DCR.0000000000000147](#)]
- 17 **Beksac K**, Tanacan A, Ozgul N, Beksac MS. Treatment of Rectovaginal Fistula Using Sphincteroplasty and Fistulectomy. *Obstet Gynecol Int* 2018; **2018**: 5298214 [PMID: [29853904](#) DOI: [10.1155/2018/5298214](#)]
- 18 **Fu J**, Liang Z, Zhu Y, Cui L, Chen W. Surgical repair of rectovaginal fistulas: predictors of fistula closure. *Int Urogynecol J* 2019; **30**: 1659-1665 [PMID: [31468097](#) DOI: [10.1007/s00192-019-04082-w](#)]
- 19 **Trompetto M**, Realis Luc A, Novelli E, Tutino R, Clerico G, Gallo G. Use of the Martius advancement flap for low rectovaginal fistulas. *Colorectal Dis* 2019; **21**: 1421-1428 [PMID: [31260184](#) DOI: [10.1111/codi.14748](#)]
- 20 **Hotouras A**, Ribas Y, Zakeri S, Murphy J, Bhan C, Chan CL. Gracilis muscle interposition for rectovaginal and anovaginal fistula repair: a systematic literature review. *Colorectal Dis* 2015; **17**: 104-110 [PMID: [25284745](#) DOI: [10.1111/codi.12791](#)]
- 21 **Lowry AC**. Management of rectovaginal fistula. *Semin Colon Rectal Surg* 2016; **27**: 64-68 [DOI: [10.1053/J.SCRS.2015.12.010](#)]
- 22 **Lee RC**, Rotmensch J. Rectovaginal radiation fistula repair using an obturator fasciocutaneous thigh flap. *Gynecol Oncol* 2004; **94**: 277-282 [PMID: [15297162](#) DOI: [10.1016/j.ygyno.2004.03.049](#)]
- 23 **Lefèvre JH**, Bretagnol F, Maggiori L, Alves A, Ferron M, Panis Y. Operative results and quality of life after gracilis muscle transposition for recurrent rectovaginal fistula. *Dis Colon Rectum* 2009; **52**: 1290-1295 [PMID: [19571707](#) DOI: [10.1007/DCR.0b013e3181a74700](#)]
- 24 **Mukwege D**, Mukanire N, Himpens J, Cadière GB. Minimally invasive treatment of traumatic high rectovaginal fistulas. *Surg Endosc* 2016; **30**: 379-387 [PMID: [25847136](#) DOI: [10.1007/s00464-015-4192-z](#)]
- 25 **Fu W**, Yi S, An M, Tang Y, Tang L, Wang Y, Yuan Y, Zhou Q, Hu Y, Wen Y. Effect of diverting stoma for rectovaginal fistula: A protocol of systematic review and meta-analysis. *Medicine (Baltimore)* 2020; **99**: e23202 [PMID: [33285694](#) DOI: [10.1097/MD.00000000000023202](#)]
- 26 **Corte H**, Maggiori L, Treton X, Lefevre JH, Ferron M, Panis Y. Rectovaginal Fistula: What Is the Optimal Strategy? *Ann Surg* 2015; **262**: 855-60; discussion 860 [PMID: [26583676](#) DOI: [10.1097/SLA.0000000000001461](#)]
- 27 **Lambertz A**, Lüken B, Ulmer TF, Böhm G, Neumann UP, Klink CD, Krones CJ. Influence of diversion stoma on surgical outcome and recurrence rates in patients with rectovaginal fistula - A retrospective cohort study. *Int J Surg* 2016; **25**: 114-117 [PMID: [26700197](#) DOI: [10.1016/j.ijsu.2015.12.005](#)]
- 28 **Barugola G**, Bertocchi E, Leonardi A, Almoudaris AM, Ruffo G. Post surgical rectovaginal fistula: who really benefits from stoma diversion? *Updates Surg* 2021; **73**: 165-171 [PMID: [32449033](#) DOI: [10.1007/s13304-020-00810-w](#)]

- 29 **Tozer PJ**, Balmforth D, Kayani B, Rahbour G, Hart AL, Phillips RK. Surgical management of rectovaginal fistula in a tertiary referral centre: many techniques are needed. *Colorectal Dis* 2013; **15**: 871-877 [PMID: [23331635](#) DOI: [10.1111/codi.12114](#)]
- 30 **Piekarski JH**, Jereczek-Fossa BA, Nejc D, Pluta P, Szymczak W, Sek P, Bilski A, Gottwald L, Jeziorski A. Does fecal diversion offer any chance for spontaneous closure of the radiation-induced rectovaginal fistula? *Int J Gynecol Cancer* 2008; **18**: 66-70 [PMID: [17466039](#) DOI: [10.1111/j.1525-1438.2007.00954.x](#)]
- 31 **Hannaway CD**, Hull TL. Current considerations in the management of rectovaginal fistula from Crohn's disease. *Colorectal Dis* 2008; **10**: 747-55; discussion 755 [PMID: [18462243](#) DOI: [10.1111/j.1463-1318.2008.01552.x](#)]
- 32 **Klink CD**, Lioupis K, Binnebösel M, Kaemmer D, Kozubek I, Grommes J, Neumann UP, Jansen M, Willis S. Diversion stoma after colorectal surgery: loop colostomy or ileostomy? *Int J Colorectal Dis* 2011; **26**: 431-436 [PMID: [21221605](#) DOI: [10.1007/s00384-010-1123-2](#)]
- 33 **Shen B**. Exploring endoscopic therapy for the treatment of Crohn's disease-related fistula and abscess. *Gastrointest Endosc* 2017; **85**: 1133-1143 [PMID: [28153572](#) DOI: [10.1016/j.gie.2017.01.025](#)]
- 34 **Buess G**, Theiss R, Hutterer F, Pichlmaier H, Pelz C, Holfeld T, Said S, Isselhard W. [Transanal endoscopic surgery of the rectum - testing a new method in animal experiments]. *Leber Magen Darm* 1983; **13**: 73-77 [PMID: [6621245](#)]
- 35 **Vávra P**, Anđel P, Dostalík J, Gunková P, Pelikán A, Gunka I, Martínek L, Vávrová M, Spurný P, Curík R, Koliba P. [The first case of management of the rectovaginal fistula using transanal endoscopic microsurgery]. *Rozhl Chir* 2006; **85**: 82-85 [PMID: [16626017](#)]
- 36 University of Oxford. OCEBM Levels of Evidence Working Group. "The Oxford Levels of Evidence 2". Centre for Evidence-Based Medicine. [cited 28 May 2022]. Available from: <https://www.cebm.ox.ac.uk/resources/Levels-of-evidence/ocebm-levels-of-evidence>
- 37 **Hauch A**, McKee RM, Li WY, Crowley JS, Ramamoorthy S, Dobke M. Rectovaginal Fistula Repair 1 Year Later: Lessons Learned. *Ann Plast Surg* 2021; **87**: 187-193 [PMID: [33346534](#) DOI: [10.1097/SAP.0000000000002626](#)]
- 38 **Neumann PA**, Rijcken E. Minimally invasive surgery for inflammatory bowel disease: Review of current developments and future perspectives. *World J Gastrointest Pharmacol Ther* 2016; **7**: 217-226 [PMID: [27158537](#) DOI: [10.4292/wjgpt.v7.i2.217](#)]
- 39 **Reavis KM**, Melvin WS. Advanced endoscopic technologies. *Surg Endosc* 2008; **22**: 1533-1546 [PMID: [18401657](#) DOI: [10.1007/s00464-008-9831-1](#)]
- 40 **Saclarides TJ**. Transanal Endoscopic Microsurgery. *Clin Colon Rectal Surg* 2015; **28**: 165-175 [PMID: [26491409](#) DOI: [10.1055/s-0035-1562889](#)]
- 41 **D'Ambrosio G**, Paganini AM, Guerrieri M, Barchetti L, Lezoche G, Fabiani B, Lezoche E. Minimally invasive treatment of rectovaginal fistula. *Surg Endosc* 2012; **26**: 546-550 [PMID: [22083318](#) DOI: [10.1007/s00464-011-1917-5](#)]
- 42 **Yuan X**, Chen H, Chen C, Yang M, Li Q, Gao R, Wu X, Xu W, Sun J, Yin L. Minimally invasive treatment of mid-low rectovaginal fistula: a transanal endoscopic surgery study. *Surg Endosc* 2020; **34**: 3971-3977 [PMID: [31728753](#) DOI: [10.1007/s00464-019-07174-2](#)]
- 43 **Chen W**, Chen X, Lin G, Qiu H. Successful repair of recurrent rectovaginal fistula by stratified suture using transanal endoscopic microsurgery: A CARE-compliant case report. *Medicine (Baltimore)* 2016; **95**: e4600 [PMID: [27603349](#) DOI: [10.1097/MD.00000000000004600](#)]
- 44 **Binmoeller KF**, Grimm H, Soehendra N. Endoscopic closure of a perforation using metallic clips after snare excision of a gastric leiomyoma. *Gastrointest Endosc* 1993; **39**: 172-174 [PMID: [8495838](#) DOI: [10.1016/s0016-5107\(93\)70060-7](#)]
- 45 **John BK**, Cortes RA, Feinerman A, Somnay K. Successful closure of a rectovaginal fistula by using an endoscopically placed Resolution clip. *Gastrointest Endosc* 2008; **67**: 1192-1195 [PMID: [18402957](#) DOI: [10.1016/j.gie.2007.12.057](#)]
- 46 **Ortiz-Moyano C**, Guerrero-Jiménez P, Romero-Gómez M. Endoscopic closure of a rectovaginal fistula combining N-2-butyl-cyanoacrylate (Histoacryl) and Resolution clips. *Endoscopy* 2011; **43** Suppl 2 UCTN: E133-E134 [PMID: [21425012](#) DOI: [10.1055/s-0030-1256166](#)]
- 47 **Weiland T**, Fehlker M, Gottwald T, Schurr MO. Performance of the OTSC System in the endoscopic closure of iatrogenic gastrointestinal perforations: a systematic review. *Surg Endosc* 2013; **27**: 2258-2274 [PMID: [23340813](#) DOI: [10.1007/s00464-012-2754-x](#)]
- 48 **Matano Y**, Zianne M, Omura H, Hayashi N, Miwa K. Successful endoscopic closure of a refractory postoperative rectovaginal fistula. *Endosc Int Open* 2019; **7**: E796-E799 [PMID: [31198842](#) DOI: [10.1055/a-0895-5573](#)]
- 49 **Prosst RL**, Joos AK, Ehni W, Bussen D, Herold A. Prospective pilot study of anorectal fistula closure with the OTSC Proctology. *Colorectal Dis* 2015; **17**: 81-86 [PMID: [25175824](#) DOI: [10.1111/codi.12762](#)]
- 50 **Tong Y**, Trilling B, Sage PY, Girard E, Faucheron JL. Short-term outcomes of the over-the-scope clip proctology system for rectovaginal fistula repair: a prospective study. *Tech Coloproctol* 2019; **23**: 245-249 [PMID: [30937645](#) DOI: [10.1007/s10151-019-01948-5](#)]
- 51 **El Hajj II**, Imperiale TF, Rex DK, Ballard D, Kesler KA, Birdas TJ, Fatima H, Kessler WR, DeWitt JM. Treatment of esophageal leaks, fistulae, and perforations with temporary stents: evaluation of efficacy, adverse events, and factors associated with successful outcomes. *Gastrointest Endosc* 2014; **79**: 589-598 [PMID: [24125513](#) DOI: [10.1016/j.gie.2013.08.039](#)]
- 52 **Baron TH**. Indications and results of endoscopic rectal stenting. *J Gastrointest Surg* 2004; **8**: 266-269 [PMID: [15019920](#) DOI: [10.1016/j.gassur.2003.11.018](#)]
- 53 **Lamazza A**, Fiori E, Sterpetti AV. Endoscopic placement of self-expandable metal stents for treatment of rectovaginal fistulas after colorectal resection for cancer. *Gastrointest Endosc* 2014; **79**: 1025-1027 [PMID: [24565070](#) DOI: [10.1016/j.gie.2014.01.010](#)]
- 54 **Lamazza A**, Fiori E, Sterpetti AV, Schillaci A, De Cesare A, Lezoche E. Endoscopic placement of self-expandable metallic stents for rectovaginal fistula after colorectal resection: a comparison with proximal diverting ileostomy alone. *Surg Endosc* 2016; **30**: 797-801 [PMID: [26017913](#) DOI: [10.1007/s00464-015-4246-2](#)]
- 55 **Zhu YF**, Tao GQ, Zhou N, Xiang C. Current treatment of rectovaginal fistula in Crohn's disease. *World J Gastroenterol* 2011; **17**: 963-967 [PMID: [21448347](#) DOI: [10.3748/wjg.v17.i8.963](#)]

- 56 **van Vledder MG**, Doornebosch PG, de Graaf EJ. Transanal endoscopic surgery for complications of prior rectal surgery. *Surg Endosc* 2016; **30**: 5356-5363 [PMID: [27059974](#) DOI: [10.1007/s00464-016-4888-8](#)]
- 57 **Shibata**, Mizuguchi, Takeda, Miyashita. Successful closure of a rectovaginal fistula following low anterior resection by endoscopic fibrin glue application. *Colorectal Dis* 1999; **1**: 42-44 [PMID: [23577683](#) DOI: [10.1046/j.1463-1318.1999.00009.x](#)]
- 58 **Darwood RJ**, Borley NR. TEMS: an alternative method for the repair of benign recto-vaginal fistulae. *Colorectal Dis* 2008; **10**: 619-620 [PMID: [18294273](#) DOI: [10.1111/j.1463-1318.2008.01478.x](#)]
- 59 **Vavra P**, Dostalík J, Vavrova M, Gunkova P, Pai M, El-Gendi A, Habib N, Papaevangelou A. Transanal endoscopic microsurgery: a novel technique for the repair of benign rectovaginal fistula. *Surgeon* 2009; **7**: 126-127 [PMID: [19408806](#) DOI: [10.1016/s1479-666x\(09\)80031-0](#)]



Published by **Baishideng Publishing Group Inc**
7041 Koll Center Parkway, Suite 160, Pleasanton, CA 94566, USA

Telephone: +1-925-3991568

E-mail: bpgoffice@wjgnet.com

Help Desk: <https://www.f6publishing.com/helpdesk>

<https://www.wjgnet.com>

