


World Journal of *Gastrointestinal Surgery*

World J Gastrointest Surg 2022 September 27; 14(9): 877-1088



MINIREVIEWS

- 877** Oncologic aspects of the decision-making process for surgical approach for colorectal liver metastases progressing during chemotherapy
Araujo RLC, Carvalho CGCY, Maeda CT, Milani JM, Bugano DG, de Moraes PHZ, Linhares MM
- 887** Research progress on the immune microenvironment of the gallbladder in patients with cholesterol gallstones
Jiao JY, Zhu XJ, Zhou C, Wang P

ORIGINAL ARTICLE

Retrospective Study

- 896** Central pancreatectomy for benign or low-grade malignant pancreatic tumors in the neck and body of the pancreas
Chen YW, Xu J, Li X, Chen W, Gao SL, Shen Y, Zhang M, Wu J, Que RS, Yu J, Liang TB, Bai XL
- 904** Irinotecan- vs oxaliplatin-based regimens for neoadjuvant chemotherapy in colorectal liver metastasis patients: A retrospective study
Liu W, Chen FL, Wang K, Bao Q, Wang HW, Jin KM, Xing BC
- 918** Predictors of difficult endoscopic resection of submucosal tumors originating from the muscularis propria layer at the esophagogastric junction
Wang YP, Xu H, Shen JX, Liu WM, Chu Y, Duan BS, Lian JJ, Zhang HB, Zhang L, Xu MD, Cao J
- 930** Liver transplantation with simultaneous splenectomy increases risk of cancer development and mortality in hepatocellular carcinoma patients
Fan HL, Hsieh CB, Kuo SM, Chen TW
- 940** Development of an innovative nomogram of risk factors to predict postoperative recurrence of gastrointestinal stromal tumors
Guan SH, Wang Q, Ma XM, Qiao WJ, Li MZ, Lai MG, Wang C
- 950** Comparison of short-term efficacy between totally laparoscopic gastrectomy and laparoscopic assisted gastrectomy for elderly patients with gastric cancer
Zhao RY, Li HH, Zhang KC, Cui H, Deng H, Gao JW, Wei B
- 963** Personal predictive model based on systemic inflammation markers for estimation of postoperative pancreatic fistula following pancreaticoduodenectomy
Long ZD, Lu C, Xia XG, Chen B, Xing ZX, Bie L, Zhou P, Ma ZL, Wang R
- 976** Feasible management of median arcuate ligament syndrome in orthotopic liver transplantation recipients
Li SX, Fan YH, Tian GY, Lv GY

- 986** Study of preoperative diagnostic modalities in Chinese patients with superficial esophageal squamous cell carcinoma

Zeng YT, Sun YY, Tan WC, Luo SA, Zou BH, Luo GY, Huang CY

Observational Study

- 997** Oesophageal cancer metastases: An observational study of a more aggressive approach

Pickett L, Dunne M, Monaghan O, Grogan L, Breathnach O, Walsh TN

- 1008** Change of tumor-infiltrating lymphocyte of associating liver partition and portal vein ligation for staged hepatectomy for hepatocellular carcinoma

Wang W, Deng ZF, Wang JL, Zhang L, Bao L, Xu BH, Zhu H, Guo Y, Wen Z

- 1026** Blood index panel for gastric cancer detection

Guo GH, Xie YB, Zhang PJ, Jiang T

Randomized Controlled Trial

- 1037** Effect of cardiac output - guided hemodynamic management on acute lung injury in pediatric living donor liver transplantation

Dou XJ, Wang QP, Liu WH, Weng YQ, Sun Y, Yu WL

SYSTEMATIC REVIEWS

- 1049** Minimally invasive endoscopic repair of rectovaginal fistula

Zeng YX, He YH, Jiang Y, Jia F, Zhao ZT, Wang XF

META-ANALYSIS

- 1060** Laparoscopic appendectomy, stump closure and endoloops: A meta-analysis

Zorzetti N, Lauro A, Bellini MI, Vaccari S, Dalla Via B, Cervellera M, Cirocchi R, Sorrenti S, D'Andrea V, Tonini V

CASE REPORT

- 1072** Retrorectal mucinous adenocarcinoma arising from a tailgut cyst: A case report and review of literature

Wang YS, Guo QY, Zheng FH, Huang ZW, Yan JL, Fan FX, Liu T, Ji SX, Zhao XF, Zheng YX

LETTER TO THE EDITOR

- 1082** Successful treatment of acute symptomatic extensive portal venous system thrombosis by 7-day systemic thrombolysis

Gao FB, Wang L, Zhang WX, Shao XD, Guo XZ, Qi XS

- 1086** Prediction factors for ischemia of closed-loop small intestinal obstruction

Pavlidis ET, Pavlidis TE

ABOUT COVER

Editorial Board Member of *World Journal of Gastrointestinal Surgery*, Shu-You Peng, FACS, FRCP (Hon), MD, Full Professor, Department of Surgery, Medical School of Zhejiang University, Hangzhou 310009, Zhejiang Province, China. zrwkpsy@zju.edu.cn

AIMS AND SCOPE

The primary aim of *World Journal of Gastrointestinal Surgery* (WJGS, *World J Gastrointest Surg*) is to provide scholars and readers from various fields of gastrointestinal surgery with a platform to publish high-quality basic and clinical research articles and communicate their research findings online.

WJGS mainly publishes articles reporting research results and findings obtained in the field of gastrointestinal surgery and covering a wide range of topics including biliary tract surgical procedures, biliopancreatic diversion, colectomy, esophagectomy, esophagostomy, pancreas transplantation, and pancreatectomy, etc.

INDEXING/ABSTRACTING

The WJGS is now abstracted and indexed in Science Citation Index Expanded (SCIE, also known as SciSearch®), Current Contents/Clinical Medicine, Journal Citation Reports/Science Edition, PubMed, PubMed Central, Reference Citation Analysis, China National Knowledge Infrastructure, China Science and Technology Journal Database, and Superstar Journals Database. The 2022 Edition of Journal Citation Reports® cites the 2021 impact factor (IF) for WJGS as 2.505; IF without journal self cites: 2.473; 5-year IF: 3.099; Journal Citation Indicator: 0.49; Ranking: 104 among 211 journals in surgery; Quartile category: Q2; Ranking: 81 among 93 journals in gastroenterology and hepatology; and Quartile category: Q4.

RESPONSIBLE EDITORS FOR THIS ISSUE

Production Editor: Rui-Rui Wu, Production Department Director: Xiang Li, Editorial Office Director: Jia-Ru Fan.

NAME OF JOURNAL

World Journal of Gastrointestinal Surgery

ISSN

ISSN 1948-9366 (online)

LAUNCH DATE

November 30, 2009

FREQUENCY

Monthly

EDITORS-IN-CHIEF

Peter Schemmer

EDITORIAL BOARD MEMBERS

<https://www.wjgnet.com/1948-9366/editorialboard.htm>

PUBLICATION DATE

September 27, 2022

COPYRIGHT

© 2022 Baishideng Publishing Group Inc

INSTRUCTIONS TO AUTHORS

<https://www.wjgnet.com/bpg/gerinfo/204>

GUIDELINES FOR ETHICS DOCUMENTS

<https://www.wjgnet.com/bpg/GerInfo/287>

GUIDELINES FOR NON-NATIVE SPEAKERS OF ENGLISH

<https://www.wjgnet.com/bpg/gerinfo/240>

PUBLICATION ETHICS

<https://www.wjgnet.com/bpg/GerInfo/288>

PUBLICATION MISCONDUCT

<https://www.wjgnet.com/bpg/gerinfo/208>

ARTICLE PROCESSING CHARGE

<https://www.wjgnet.com/bpg/gerinfo/242>

STEPS FOR SUBMITTING MANUSCRIPTS

<https://www.wjgnet.com/bpg/GerInfo/239>

ONLINE SUBMISSION

<https://www.f6publishing.com>



Retrorectal mucinous adenocarcinoma arising from a tailgut cyst: A case report and review of literature

Yan-Shuai Wang, Qing-Yun Guo, Fang-Hong Zheng, Zi-Wei Huang, Jia-Lang Yan, Fu-Xiang Fan, Tian Liu, Shun-Xian Ji, Xiao-Feng Zhao, Yi-Xiong Zheng

Specialty type: Surgery

Provenance and peer review:

Unsolicited article; Externally peer reviewed.

Peer-review model: Single blind

Peer-review report's scientific quality classification

Grade A (Excellent): A, A

Grade B (Very good): 0

Grade C (Good): C, C, C

Grade D (Fair): D

Grade E (Poor): 0

P-Reviewer: Bairwa DBL, India; Haddadi S, Algeria; Kawabata H, Japan; Nakaji K, Japan; Yap RVC, Philippines

Received: April 23, 2022

Peer-review started: April 23, 2022

First decision: June 19, 2022

Revised: June 30, 2022

Accepted: August 21, 2022

Article in press: August 21, 2022

Published online: September 27, 2022



Yan-Shuai Wang, Fang-Hong Zheng, Zi-Wei Huang, Jia-Lang Yan, Fu-Xiang Fan, Yi-Xiong Zheng, Department of General Surgery, The Fourth Affiliated Hospital, School of Medicine, Zhejiang University, Yiwu 322000, Zhejiang Province, China

Qing-Yun Guo, Xiao-Feng Zhao, Department of Gynecology, Women's Hospital, School of Medicine, Zhejiang University, Hangzhou 310006, Zhejiang Province, China

Tian Liu, Department of Intensive Care Unit, The Fourth Affiliated Hospital, School of Medicine, Zhejiang University, Yiwu 322000, Zhejiang Province, China

Shun-Xian Ji, Department of Pathology, The Fourth Affiliated Hospital, School of Medicine, Zhejiang University, Yiwu 322000, Zhejiang Province, China

Corresponding author: Yi-Xiong Zheng, MD, Attending Doctor, Professor, Department of General Surgery, The Fourth Affiliated Hospital, School of Medicine, Zhejiang University, No. 1 Shangcheng Road, Yiwu 322000, Zhejiang Province, China. 2100011@zju.edu.cn

Abstract

BACKGROUND

Tailgut cysts are defined as congenital cysts that develop in the rectosacral space from the residue of the primitive tail. As a congenital disease, caudal cysts are very rare, and their canceration is even rarer, which makes the disease prone to misdiagnosis and delayed treatment. We describe a case of caudal cyst with adenocarcinogenesis and summarize in detail the characteristics of cases with analytical value reported since 1990.

CASE SUMMARY

A 35-year-old woman found a mass in her lower abdomen 2 mo ago. She was asymptomatic at that time and was not treated because of the coronavirus disease 2019 pandemic. Two weeks ago, the patient developed abdominal distension and right waist discomfort and came to our hospital. Except for the high level of serum carcinoembryonic antigen, the medical history and laboratory tests were not remarkable. Magnetic resonance imaging showed a well-defined, slightly lobulated cystic-solid mass with a straight diameter of approximately 10 cm × 9 cm in the presacral space, slightly high signal intensity on T2-weighted imaging, and moderate signal intensity on T1-weighted imaging. The mass was completely removed by laparoscopic surgery. Histopathological examination showed that the lesion was an intestinal mucinous adenocarcinoma, and the multidisciplinary

team decided to implement postoperative chemotherapy. The patient recovered well, the tumor marker levels returned to normal, and tumor-free survival has been achieved thus far.

CONCLUSION

The case and literature summary can help clinicians and researchers develop appropriate examination and therapeutic methods for diagnosis and treatment of this rare disease.

Key Words: Tailgut cysts; Adenocarcinoma; Magnetic resonance imaging; Retrorectal disease; Preoperative biopsy; Case report

©The Author(s) 2022. Published by Baishideng Publishing Group Inc. All rights reserved.

Core Tip: Tailgut cysts (TGCs) are rare congenital cysts of the retrorectal space. We report a case of TGC with adenocarcinogenesis and review the literature on caudal cyst adenocarcinogenesis. Magnetic resonance imaging is the most valuable tool for diagnosis and differential diagnosis, and preoperative biopsy is not worth advocating. Early MDT plays an important role in the accurate diagnosis and selection of the most appropriate personalized treatment. Complete resection of TGCs is the key to avoiding postoperative recurrence. We recommend MDT with complete surgical resection as the core and discuss the advantages and disadvantages of various diagnostic and treatment strategies.

Citation: Wang YS, Guo QY, Zheng FH, Huang ZW, Yan JL, Fan FX, Liu T, Ji SX, Zhao XF, Zheng YX. Retrorectal mucinous adenocarcinoma arising from a tailgut cyst: A case report and review of literature. *World J Gastrointest Surg* 2022; 14(9): 1072-1081

URL: <https://www.wjgnet.com/1948-9366/full/v14/i9/1072.htm>

DOI: <https://dx.doi.org/10.4240/wjgs.v14.i9.1072>

INTRODUCTION

Tailgut cysts (TGCs) are congenital cysts that develop in the retrorectal-presacral space from the remnants of the primitive embryonic hindgut[1,2]. These rare cysts are more common in women. Patients may present with lower abdominal pain and perianal lesions. Due to the risk of complications, such as recurrent perianal suppuration and malignant changes, surgical treatment is necessary. TGCs with malignant transformation are extremely rare[3]. The types of malignant transformation include adenocarcinoma, neuroendocrine tumor, and carcinoid. Most of these tumors are more inert than other epithelial malignant tumors; however, a small number of them are aggressive and resistant to treatment. Adenocarcinoma caused by TGCs is very rare, with only 28 cases with clinical details having been reported in the medical literature since 1990. In this paper, we report a new case and summarize the clinical and pathological features of adenocarcinoma from TGCs with a literature review. The reported cases were retrieved from the PubMed and Reference Citation Analysis (<https://www.referencecitation-analysis.com/>) database, and case summary information was carefully extracted from each article searched by PubMed (Table 1). To the best of our knowledge, a summary of adenocarcinogenesis of TGCs has not been reported before. Here, we focus on the regular characteristics of malignant transformation of TGCs to facilitate clinical diagnosis and treatment.

CASE PRESENTATION

Chief complaints

A 35-year-old Chinese woman complained of a lower abdominal mass for 2 mo and abdominal distension for 2 wk.

History of present illness

The patient accidentally found a mass in her lower abdomen in May 2020 with no related clinical symptoms. She delayed hospitalization for 2 mo due to the coronavirus disease 2019 pandemic. Two months later, due to abdominal distension and right waist discomfort, the patient went to the gynecology clinic to seek medical help. Since the onset of the disease, the patient has had no dysuria or menstrual changes.

Table 1 Summary of disease information on adenocarcinogenesis of tailgut cysts published from 1990-2021

Case	Ref.	Sex	Age	Clinical symptoms	Duration	Size (mm)	MRI/CT	Biopsy	Invasion	Position S4+/S3-	CEA/CA199	Surgery planning
1	Baverez <i>et al</i> [19], 2021	F	57	Perianal suppuration	5 yr	55	+/+	+	Anal canal and perianal skin	-	30/UN	Abdominoperineal resection
2	Wang <i>et al</i> [3], 2020	F	50	Irregular defecation	2 wk	90 × 80	+/+	-	-	-	79.89/57.60	Trans-sacroccygeal approach
3	Rachel <i>et al</i> [20], 2019	F	73	Anal abscess and associated fistula	40 yr	56 × 46	+/+	+	Anal canal and perianal skin	-	UN	Trans-sacroccygeal approach
4	Martins <i>et al</i> [4], 2020	F	54	Pelvic and perineal pain	1-2 mo	50 × 35	+/+	+	Sacrum	-	UN	Trans-sacroccygeal approach
5	Li <i>et al</i> [21], 2019	M	33	-	-	80 × 59	+/-	-	-	-	26.97/106.50	Trans-sacroccygeal approach
6	Şahin <i>et al</i> [22], 2020	F	55	Swelling of the buttocks	6 mo	21 × 16	+/-	-	-	-	-/204	Trans-sacroccygeal approach
7	Almeida Costa and Rio [23], 2018	F	53	Defecation and lower abdominal pain	UN	UN	+/+	-	Sacrum	+	UN	Trans-sacroccygeal approach
8	Zhao <i>et al</i> [11], 2015	F	44	Pelvic and perineal pain	6 mo	100	-/+	+	Rectum and surrounding	+	+ / UN	Partial resection and drainage of the pelvic tumor
9	Chhabra <i>et al</i> [8], 2013	F	56	Hematuria	1 yr	46 × 37	-/+	+	-	-	-/UN	Trans-sacroccygeal approach
10	Jarboui <i>et al</i> [24], 2008	F	49	Pelvic and perineal pain	6 mo	150	-/+	-	-	+	UN	Laparotomy
11	Tampi <i>et al</i> [2], 2007	F	57	Low backache	6 mo	120 × 100 × 80	-/+	-	Liver	+	-/-	Laparotomy
12	Andea and Klimstra[25], 2005	F	47	Gluteal pain	3 mo	40 × 40	UN/UN	-	-	UN	-/UN	UN
13	Cho <i>et al</i> [26], 2005	F	40	Perianal pain	1 mo	100 × 80 × 70	+/	+	Sacrum	-	159/2270	Abdominoperineal resection and partial sacrectomy
14	Kanthan <i>et al</i> [12], 2004	F	76	Perianal pain	UN	65 × 45 × 35	-/+	+	-	-	UN	Trans-sacroccygeal approach
15	Moreira <i>et al</i> [13], 2001 (case-1)	F	64	Constipation and frequent urination	2 mo	120 × 100	+/UN	-	-	UN	UN	UN
16	Moreira <i>et al</i> [13], 2001 (case-2)	F	68	Rectal “fullness”	2 yr	180 × 40	+/+	-	-	UN	UN	UN
17	Schwarz <i>et al</i> [14], 2000	M	47	Bilateral flank pain, constipation	3 mo	160	-/+	-	-	-	46/-	Abdominoperineal resection and partial sacrectomy
18	Prasad <i>et al</i> [27], 2000	F	36	-	UN	95 × 92 × 88	+/+	UN	-	UN	UN	UN
19	Sauer <i>et al</i> [28], 2000	F	58	Recurrent perianal fistulas	17	55 × 40 × 35	+/+	-	-	+	6.7/42	Laparotomy
20	Graadt van Roggen <i>et al</i>	F	43	-	-	130	+/-	-	UN	+	+ / UN	UN

	[7], 1999											
21	Maruyama <i>et al</i> [29], 1998	F	66	Perianal pain	6 mo	100 × 90	+/+	-	-		3.8/-	Trans-sacrococcygeal approach
22	Lim <i>et al</i> [10], 1998	F	40	Urinary frequency and constipation	8 mo	250 × 100 × 100	+/-	-	-	UN	-/-	Laparotomy
23	Yamaguchi <i>et al</i> [30], 2001	M	32	Anal fistula	4 yr	UN	+/+	-	Rectum	UN	UN	Pelvic evisceration
24	Liessi <i>et al</i> [31], 1995	M	50	UN	UN	UN	+/+	UN	Sacrum	UN	UN	Trans-sacrococcygeal approach

CT: Computed tomography; MRI: Magnetic resonance imaging; F: Female; M: Male; CEA: Carcinoembryonic antigen.

History of past illness

The patient's past medical history included a loop electrosurgical excision procedure for cervical erosion 10 years ago.

Personal and family history

No family history was identified.

Physical examination

Physical examination showed that the patient's abdomen was flat and soft, with no abnormal bulge, tenderness, or rebound pain. A cystic-solid mass of approximately 10 cm, which was painless and could not be pushed, was palpated slightly higher than the pubic bone. Gynecological bimanual examination showed no abnormalities of the vagina, cervix, or uterus.

Laboratory examinations

Laboratory studies were normal except for an elevation in serum carcinoembryonic antigen (CEA) to 132.69 ng/mL.

Imaging examinations

Gynecological B-mode ultrasonography examination showed that there was a cystic-solid mass close to the surface of the right ovary, mainly cystic, and the sound difference of the internal diaphragm was noisy. The appearance of thick and intense light spots followed by sound shadows, as well as a small blood flow signal in the solid part, allowed us to calculate a resistance index of 0.55. Computed tomography (CT) showed a cystic mass in the posterior rectal pelvis, extending to the level of the sacral promontory but not reaching the bony components of the sacrum or coccyx. The size of the mass was approximately 10 cm × 9 cm, and it showed polycystic changes with a septum and calcification. Contrast-enhanced CT indicated that the septum of the mass could be enhanced. Magnetic resonance imaging (MRI) showed a mass of abnormal signal on the right side of the pelvis measuring approximately 10 cm × 7 cm. Its borders were clear, with mixed high signal on T2-weighted imaging (T2WI) and localized lamellar low signal within. The right adnexal region was a cystic abnormal signal focus with a moderate signal on T1-weighted imaging (T1WI) and a slightly high signal on T2WI, with

nodular ring reinforcement on an enhanced scan. No enlarged lymph nodes or abnormal masses were seen in the pelvis. There was also no abnormal signal in the pelvic wall tissue (Figure 1).

FINAL DIAGNOSIS

Histopathology revealed that the lesion was an intestinal mucinous adenocarcinoma, and the malignant transformation of an embryonic residual enterogenous cyst was considered. The results of pathological sections showed fibrous tissue with a cystic lining; the lesion was rich in cellular mucus and infiltrating the columnar epithelium, and it also showed high-grade atypical cell hyperplasia and mitotic activity. Morphologically, this was consistent with mucinous adenocarcinoma, intestinal type. Immunopathology showed that cytokeratin 20 (CK) 20, CK7, CDX2, and STATB2 were positive (Figure 2). After joint consultation with the Department of Pathology of University of California, Los Angeles, we diagnosed the patient with a TGC with adenocarcinogenesis.

TREATMENT

After a multidisciplinary consultation and evaluation, laparoscopic surgery was performed under general anesthesia on July 14, 2020. During the operation, there was no obvious free fluid in the pelvis and no obvious abnormalities in the uterus, fallopian tubes, or ovaries.

An enlarged cyst, swollen and measuring approximately 10 cm × 9 cm, was found behind the peritoneum in front of the sacrum near the right iliac vessel. Hyperplastic vessels were visible on the smooth surface of the swelling, the ureter was observed to pass through the surface, and the iliac vessels were visible below it, with no adhesion to the surrounding tissues of S2-S4.

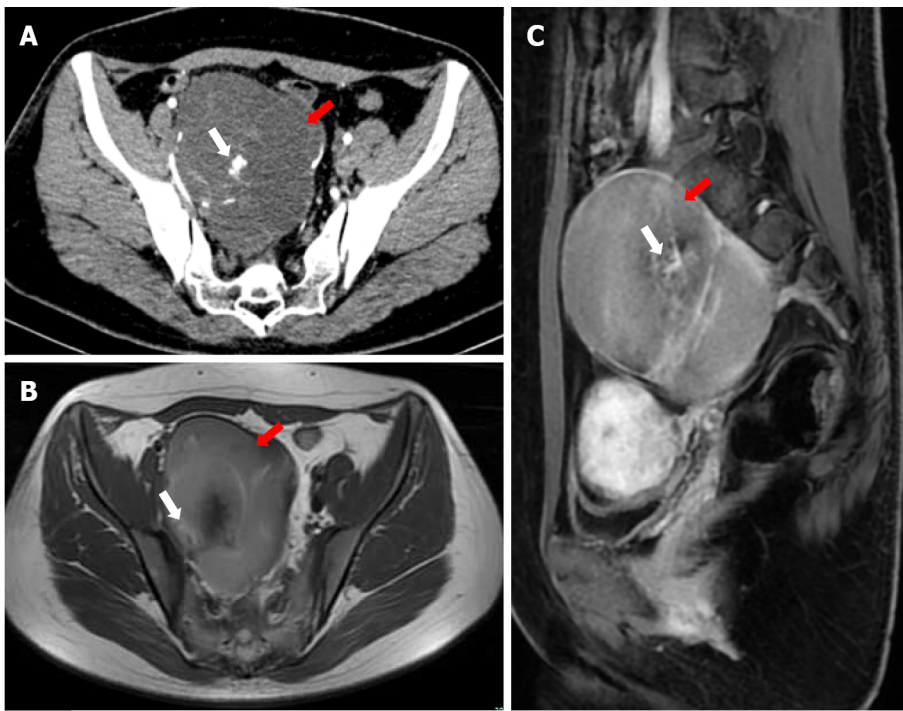
The operation was performed by an experienced general surgeon and a gynecologist. With the help of laparoscopy, we successfully removed the cyst completely. After the cyst was removed from the abdominal cavity, we opened the cyst and found that its inner wall was rough; moreover, we found multiple tissue calcifications. The intraoperative frozen pathological results showed a retroperitoneal benign cyst and cyst wall fibrosis and calcification. After flushing the abdominal cavity and retroperitoneal space with distilled water, no residual cysts or enlarged lymph nodes were found, and the peritoneum was closed by suture (Figure 3).

OUTCOME AND FOLLOW-UP

The patient received six cycles of capecitabine and oxaliplatin (CapeOX) chemotherapy, and there were no grade 3-4 side effects during this treatment. After treatment, her CEA level decreased progressively and ultimately fell within the normal range, and no metastatic focus was found on CT. The patient received therapy with high compliance, expressed satisfaction with her recovery, and has been tumor-free for more than 18 mo.

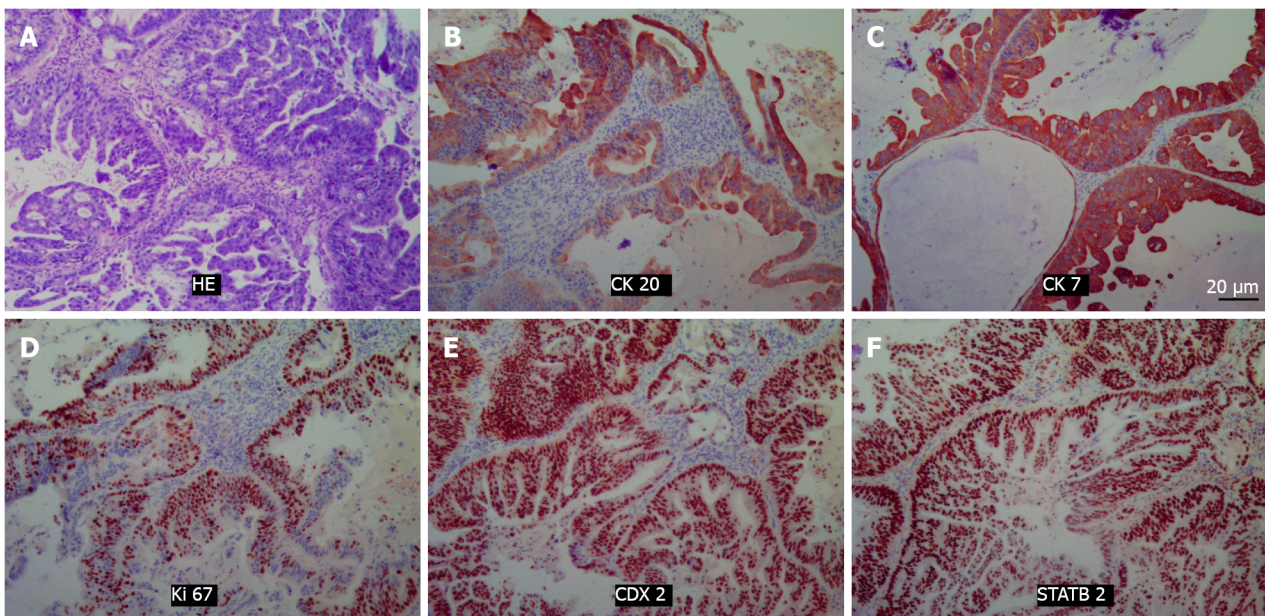
DISCUSSION

TGCs are considered to be congenital cysts that develop in the rectosacral space from the residue of the primitive tail[1,2]. This incomplete degeneration of the extension of the tail from the posterior intestine of the embryo usually occurs at the 8th week of the embryonic stage[4]. The rectosacral space is a potential space located in the deep part of the pelvis, with the posterior rectal fascia in the front and the presacral fascia (Waldeyer fascia) in the back; this space extends upward to the peritoneum and downward to the level of the rectosacral fascia and perineal muscle[5]. The boundaries on both sides are roughly outlined by the ureter, iliac vessels, and sacral nerve roots[6]. This area includes the confluence of the embryonic hindgut, pelvis, and neuroectoderm, and consequently, there are many different tissue types that can lead to retrorectal tumors. Retrorectal tumors can be divided into congenital, inflammatory, neurogenic, and osteogenic tumors. Cystic congenital lesions consist of epidermoid cysts, dermoid cysts, TGCs, enterogenous cysts, teratomas, and teratocarcinomas[7]. Such lesions affect people of all ages from birth to adulthood and are more common in women. Sometimes, patients may have space-occupying symptoms due to the enlargement of deep pelvic masses[1,3]. Clinical manifestations are usually nonspecific, with half of the patients experiencing pain, perianal lesions, changes in defecation habits, dysuria, and neurological symptoms of the lower extremities and perineum[8]. Among congenital cystic lesions, the incidence of TGCs is relatively high, but the incidence of canceration is very rare.



DOI: 10.4240/wjgs.v14.i9.1072 Copyright ©The Author(s) 2022.

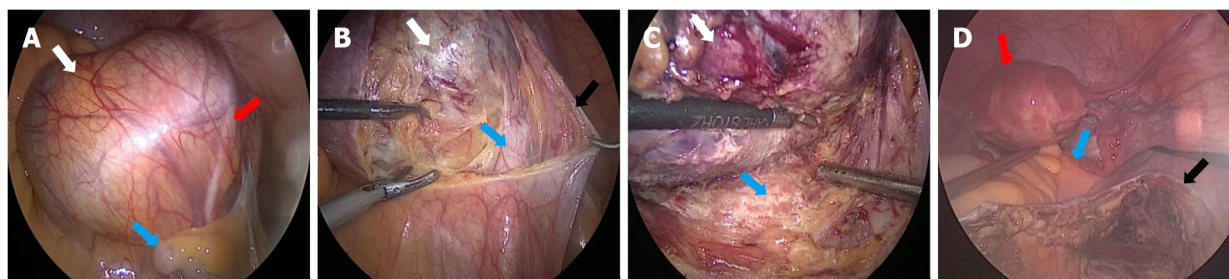
Figure 1 Imaging examination. A: Computed tomography showed a low-density mass (red arrow) of approximately 10 cm × 9 cm in the pelvis, with cordlike separation and unclear boundaries with the posterior wall and lateral wall. Inhomogeneous enhancement and high-density areas (white arrow) were seen; B and C: Magnetic resonance imaging showed a mass (red arrow) of abnormal signal intensity on the right side of the pelvic cavity, whereas the boundary was still clear. T1-weighted imaging showed a slightly high signal intensity, T2-weighted imaging showed a mixed high signal intensity, and the septal changes in the enhanced scan showed obvious enhancement (white arrow).



DOI: 10.4240/wjgs.v14.i9.1072 Copyright ©The Author(s) 2022.

Figure 2 Hematoxylin-eosin staining and immunohistochemical pictures. Positivity for cytokeratin 20, cytokeratin 7, Ki67, CDX2, and STATB2 was noted. A: Hematoxylin-eosin staining; B: CK20; C: CK7; D: Ki67; E: CDX2; F: STATB2. HE: Hematoxylin-eosin; CK20: Cytokeratin 20; CK7: Cytokeratin 7.

The malignant transformation of TGCs into reported tumors includes adenocarcinoma, carcinoid, neuroendocrine carcinoma, endometrioid carcinoma, adenosquamous carcinoma, squamous cell carcinoma, and sarcoma[2]. Most of them are endocrine tumors and adenocarcinomas, while others, such as carcinoids, are rare. At present, approximately 28 cases of TGC adenocarcinoma have been reported, of which 24 with relatively complete data were retrieved. We describe a new case of TGC with



DOI: 10.4240/wjgs.v14.i9.1072 Copyright ©The Author(s) 2022.

Figure 3 Surgical pictures. A: Gross view of the mass (white arrow) under laparoscopy. The sigmoid colon (blue arrow) and ureter (red arrow) can be seen; B: Opening of the retroperitoneum (black arrow) and exposure of the mass (white arrow) and external iliac artery (blue arrow); C: Careful separation of the mass (white arrow) from the presacral tissue (blue arrow); D: The operative field after the tumor was removed, and the uterus (red arrow), rectum (blue arrow), and retroperitoneum (black arrow) can be seen.

mucinous cystadenocarcinoma and review the literature reports of TGCs with adenocarcinogenesis to provide a reference for diagnosis and treatment.

We summarize cases of TGC adenocarcinoma reported from 1990 to 2021, as the diagnostic and therapeutic approach is of limited interest due to the low prevalence and accuracy of diagnostic tools such as MRI and CT prior to 1990.

First, we sorted out the historical process of a complete understanding of TGCs. Cancerous TGC was first reported in 1932, and Ballantyne reported the first case of adenocarcinoma with TGCs. That patient developed local recurrence, lung metastasis, and inguinal lymph node metastasis and died 8 mo after cyst resection. Subsequently, doctors began to pay attention to and share the diagnosis and treatment of this rare disease. Through the review of articles related to TGCs, we found that there were two related landmark systematic retrospective studies. The first one was conducted in 1987 when Hjerstad and Helwig[1] evaluated all the pathological specimens of posterior rectal cysts diagnosed by the Institute of Pathology of the Armed Forces of the United States during a period of 35 years, and 53 cases of "tailgut cysts" were selected[1]. Their screening criteria were that the cysts must be partially covered by a columnar or transitional epithelium, but there must be no myenteric plexus or serosa, nor can there be a complete muscular layer. Hjerstad and Helwig's study defined the pathological criteria for the diagnosis of TGCs, allowing doctors to unify the definition of the disease[1]. The second was a retrospective analysis of the clinical and pathological data of patients who underwent colectomy at Mayo Clinic in 2008, conducted by Mathis *et al*[9]. A total of 31 patients were diagnosed, including 28 females, with an average age of 52 years. The median diameter of the cyst was 4.4 cm. There were four patients with malignant transformation, comprising three cases of adenocarcinoma and one case of carcinoid, and the 5-year survival rate was 83%. The work of Mathis *et al*[9] provides a single-center clinical experiential basis for the treatment and prognosis of TGCs. At present, with the progress of medical technology, the surgical methods and chemotherapy schemes have changed, but their principle of complete resection of the tumor remains unaddressed.

The summary of cases of TGCs with adenocarcinogenesis showed that most of the patients were middle-aged adults with a female-male ratio of 10:1, which was much higher than the ratio of 3-4:1 in previous articles on caudal cysts. The clinical manifestations of TGCs are varied and nonspecific. However, by summarizing the cases of caudal cysts with adenocarcinoma, we found that half of the patients complained of an abdominal mass and pain, perianal disease, and changes in stool habits and stool characteristics, while other patients did not have any symptoms. TGC is a rare congenital retrorectal disease in which the residue of the fetal retroanal intestine grows in the retrorectal space. It should be noted that this gap is a potential space, and the mass has considerable room for growth. This can explain the late onset of the disease, and TGC canceration occurs during this process. It is suggested that TGCs should be regarded as a precancerous lesion to explain this phenomenon. More than half of the patients were diagnosed with TGCs within 1 year after the onset of symptoms, and most of them exhibited retrorectal masses by imaging examinations such as CT and MRI. Compared with CT, MRI has the ability of multiplanar imaging and better tissue contrast in presacral masses[10]. MR has more advantages in differential diagnosis. Regarding the differential diagnosis of presacral masses, anal gland cysts, repeated cysts, teratomas, epidermoid cyst chordomas, abscesses, metastatic tumors, and neurofibromas should be considered. Fat content on fat-saturated images indicates dermoid cysts[1]. In presacral cystic masses, epidermoid cysts, dermoid cysts, rectal repeated cysts, and meningoceles are usually monocystic. Rectal repetitive cysts, which are located in front of the rectum, often communicate with the rectal cavity. In contrast, TGCs are usually polycystic and can be characterized by large cysts with small peripheral cysts. This polycystic change is very important. Regarding the MRI features of TGCs, low signal intensity is usually shown on T1WI, and high signal intensity is shown on T2WI. However, the internal signal intensity of T1WI and T2WI indicates the protein concentration in the lesion, which increases with age, and the cysts show high signal intensity on T1WI. However, the

consistent feature is that most of the dominant cysts on T2-weighted sequences are hyperintense relative to the pelvic muscles. In addition, we are more concerned about the accuracy of MRI in predicting the nature of tumors. Cystic tumors with smooth, well-defined boundaries and no infiltrative or gadolinium enhancement are generally considered to be benign, whereas cysts with thickened and irregularly enhancing cyst wall boundaries, which may even be surrounded by inflammatory changes, are usually malignant.

MRI is the most valuable tool to meet the needs of diagnosis and differential diagnosis, to help improve preoperative assessments, to estimate the extent of the disease and malignant risk, and to determine the most appropriate treatment strategy. The effect of CT is not as accurate as that of MRI[3]. By pooling the literature, it was found that half of the cases had calcification and that the presence or absence of calcification was not of significant value in the diagnosis of benign or malignant lesions. Enhanced MRI and PET may be good examination methods for the diagnosis of malignant transformation and metastasis of TGCs, which is worth exploring in the future.

Preoperative biopsy of TGCs is considered unnecessary because it cannot confirm or even misconfirm the diagnosis of adenocarcinogenesis or tumor differentiation of TGCs[8]. Some authors believe that in the case of heterogeneous masses with elevated CEA, direct surgery should be performed without biopsy. However, in our statistical table, we can see that among three patients with benign lesions diagnosed by preoperative biopsy, one had a high CEA level (case 8)[11], one had a normal CEA level (case 9)[8], and one had an unknown CEA level (case 14)[12], but postoperative pathology confirmed adenocarcinoma. Therefore, biopsy can provide very limited help in diagnosing heterogeneous masses with normal CEA. Preoperative biopsies may pose major risks, such as malignant cell spillage or needle implantation. After such a biopsy, it is necessary to consider removing the tissue around the needle track during the operation, but in many cases, this is not easy to do. When we make the surgical plan, regardless of the biopsy results, we need to assume that this is a malignant lesion and adhere to the principle of complete resection. The accuracy of preoperative biopsy is in doubt, and this procedure may bring the risk of metastasis and increase the difficulty of operation. However, for patients who are unable or difficult to surgically remove the tumor, it is indeed a good method to determine the nature of the tumor through the pathological results of the biopsy and then perform surgical treatment after neoadjuvant chemotherapy.

Because cases of adenocarcinogenesis of TGCs are very rare, there are no guidelines to follow in the treatment of retrorectal tumors. In view of the strong positive expression of p53 and Ki-67 and the negative expression of p21 in the dysplastic epithelium of tailgut adenocarcinoma, it is speculated that the occurrence order of dysplasia and carcinoma is similar to that of colonic adenocarcinoma[13]. At present, the treatment mainly draws lessons from the clinical treatment guidelines for rectal adenocarcinoma, including European ESMO guidelines and American NCCN guidelines. It is suggested that multidisciplinary treatment should be adopted. Considering the postoperative pathological report and high CEA level, the present patient chose surgery and chemotherapy. The key to such operations is to remove the cyst wall completely. There are three common surgical approaches, namely, the anterior approach (abdomen), posterior approach (perineal approach), and combined abdominal perineal approach[4,14]. MRI will help to determine the margin of resection and identify the relationship between the tumor and the sacral level. For instance, if the tumor is below the middle of S3, the perineal approach can be considered[15]. All tumors extending above S4 usually require an abdominal or combined approach. For small lesions, the surgeon can also use a transvaginal approach. If malignant lesions are confirmed or suspected, the tumor tissue can be cleared more thoroughly *via* the combined abdominal perineal approach. Minimally invasive surgery has great advantages in the fine separation of anatomical hierarchy and reduction of complications[16,17]. In view of the leakage of the cancer and the large mass, it is recommended to use an endobag in the extraction of the specimen through a small incision in the abdominal wall. If there is no R0 resection or residual cyst wall and invasion of the tissue around the tumor leads to postoperative recurrence, comprehensive treatment schemes such as cytoreductive surgery, radiotherapy, chemotherapy, interventional therapy, and molecular targeted drug therapy are recommended. Considering that a small amount of leakage of TGC fluid during the operation might occur and that the postoperative pathology showed mucinous adenocarcinoma with high CEA, we chose to use CapeOX treatment to prevent recurrence. The reason for choosing CapeOX treatment is that it is feasible and widely used in malignant tumors of the digestive tract; the other reason is that the incidence of serious side effects of this regimen is low. In summary, complete resection of TGC masses during surgery is the key to avoiding postoperative recurrence and obtaining long-term survival for patients without metastasis[18].

CONCLUSION

Adenocarcinoma of TGCs is a very rare disease, and complete resection is still the gold standard. We do not recommend preoperative biopsies. Early MDT plays a significant role in the accurate diagnosis and selection of the most appropriate personalized treatment.

FOOTNOTES

Author contributions: Wang YS and Guo QY contributed to the conceptualization; Zheng FH, Huang ZW, and Yan JL contributed to the literature search and data analysis; Wang YS wrote the original draft; Fan FX, Liu T, and Ji SX reviewed and edited the manuscript; Zheng YX and Zhao XF supervised the manuscript.

Informed consent statement: Informed written consent was obtained from the patient for publication of this report and any accompanying images.

Conflict-of-interest statement: All the authors report no relevant conflicts of interest for this article.

CARE Checklist (2016) statement: The authors have read the CARE Checklist (2016), and the manuscript was prepared and revised according to the CARE Checklist (2016).

Open-Access: This article is an open-access article that was selected by an in-house editor and fully peer-reviewed by external reviewers. It is distributed in accordance with the Creative Commons Attribution NonCommercial (CC BY-NC 4.0) license, which permits others to distribute, remix, adapt, build upon this work non-commercially, and license their derivative works on different terms, provided the original work is properly cited and the use is non-commercial. See: <https://creativecommons.org/licenses/by-nc/4.0/>

Country/Territory of origin: China

ORCID number: Yan-Shuai Wang 0000-0002-2692-2244; Qing-Yun Guo 0000-0003-1465-6185; Fang-Hong Zheng 0000-0001-7524-9511; Zi-Wei Huang 0000-0001-9038-958X; Jia-Lang Yan 0000-0003-0275-049X; Fu-Xiang Fan 0000-0001-6321-1057; Tian Liu 0000-0002-1349-2177; Shun-Xian Ji 0000-0001-9652-2070; Xiao-Feng Zhao 0000-0002-8579-6997; Yi-Xiong Zheng 0000-0002-2729-6417.

S-Editor: Fan JR

L-Editor: Wang TQ

P-Editor: Fan JR

REFERENCES

- Hjermstad BM, Helwig EB. Tailgut cysts. Report of 53 cases. *Am J Clin Pathol* 1988; **89**: 139-147 [PMID: 3277378 DOI: 10.1093/ajcp/89.2.139]
- Tampi C, Lotwala V, Lakdawala M, Coelho K. Retrorectal cyst hamartoma (tailgut cyst) with malignant transformation. *Gynecol Oncol* 2007; **105**: 266-268 [PMID: 17303225 DOI: 10.1016/j.ygyno.2007.01.008]
- Wang M, Liu G, Mu Y, He H, Wang S, Li J. Tailgut cyst with adenocarcinoma transition: A rare case report. *Medicine (Baltimore)* 2020; **99**: e20941 [PMID: 32629697 DOI: 10.1097/MD.00000000000020941]
- Martins P, Canotilho R, Peyroteo M, Afonso M, Moreira A, de Sousa A. Tailgut cyst adenocarcinoma. *Autops Case Rep* 2020; **10**: e2019115 [PMID: 32039057 DOI: 10.4322/acr.2019.115]
- Satyadas T, Davies M, Nasir N, Halligan S, Akle CA. Tailgut cyst associated with a pilonidal sinus: an unusual case and a review. *Colorectal Dis* 2002; **4**: 201-204 [PMID: 12780617 DOI: 10.1046/j.1463-1318.2002.00345.x]
- Kildušis E, Samalavičius NE. Surgical management of a retro-rectal cystic hamartoma (tailgut cyst) using a trans-rectal approach: a case report and review of the literature. *J Med Case Rep* 2014; **8**: 11 [PMID: 24393234 DOI: 10.1186/1752-1947-8-11]
- Graadt van Roggen JF, Welvaart K, de Roos A, Offerhaus GJ, Hogendoorn PC. Adenocarcinoma arising within a tailgut cyst: clinicopathological description and follow up of an unusual case. *J Clin Pathol* 1999; **52**: 310-312 [PMID: 10474528 DOI: 10.1136/jcp.52.4.310]
- Chhabra S, Wise S, Maloney-Patel N, Rezac C, Poplin E. Adenocarcinoma associated with tail gut cyst. *J Gastrointest Oncol* 2013; **4**: 97-100 [PMID: 23450681 DOI: 10.3978/j.issn.2078-6891.2012.043]
- Mathis KL, Dozois EJ, Grewal MS, Metzger P, Larson DW, Devine RM. Malignant risk and surgical outcomes of presacral tailgut cysts. *Br J Surg* 2010; **97**: 575-579 [PMID: 20169572 DOI: 10.1002/bjs.6915]
- Lim KE, Hsu WC, Wang CR. Tailgut cyst with malignancy: MR imaging findings. *AJR Am J Roentgenol* 1998; **170**: 1488-1490 [PMID: 9609159 DOI: 10.2214/ajr.170.6.9609159]
- Zhao XR, Gao C, Zhang Y, Yu YH. The Malignant Transformation of Retrorectal Cystic Hamartomas With Blood Irregular Antibodies Positive: A Case Report. *Medicine (Baltimore)* 2015; **94**: e2253 [PMID: 26656372 DOI: 10.1097/MD.0000000000002253]
- Kanthan SC, Kanthan R. Unusual retrorectal lesion. *Asian J Surg* 2004; **27**: 144-146 [PMID: 15140669 DOI: 10.1016/S1015-9584(09)60330-4]
- Moreira AL, Scholes JV, Boppana S, Melamed J. p53 Mutation in adenocarcinoma arising in retrorectal cyst hamartoma (tailgut cyst): report of 2 cases--an immunohistochemistry/immunoperoxidase study. *Arch Pathol Lab Med* 2001; **125**: 1361-1364 [PMID: 11570917 DOI: 10.5858/2001-125-1361-PMIAAI]
- Schwarz RE, Lyda M, Lew M, Paz IB. A carcinoembryonic antigen-secreting adenocarcinoma arising within a retrorectal tailgut cyst: clinicopathological considerations. *Am J Gastroenterol* 2000; **95**: 1344-1347 [PMID: 10811351 DOI: 10.1111/j.1572-0241.2000.02023.x]
- Alsofyani TM, Aldossary MY, AlQahtani FF, Sabr K, Balhareth A. Successful excision of a retrorectal cyst through trans-

- sacral approach: A case report. *Int J Surg Case Rep* 2020; **71**: 307-310 [PMID: [32485636](#) DOI: [10.1016/j.ijscr.2020.05.023](#)]
- 16 **Rompen IF**, Scheiwiller A, Winiger A, Metzger J, Gass JM. Robotic-Assisted Laparoscopic Resection of Tailgut Cysts. *JSLs* 2021; **25** [PMID: [34354334](#) DOI: [10.4293/JSLs.2021.00035](#)]
 - 17 **Inada R**, Watanabe A, Toshima T, Katsura Y, Sato T, Sui K, Oishi K, Okabayashi T, Ozaki K, Shibuya Y, Matsumoto M, Iwata J. Laparoscopic Synchronous Resection for Descending Colon Cancer and Tailgut Cyst. *Acta Med Okayama* 2021; **75**: 529-532 [PMID: [34511622](#) DOI: [10.18926/AMO/62407](#)]
 - 18 **Baek SK**, Hwang GS, Vinci A, Jafari MD, Jafari F, Moghadamyeghaneh Z, Pigazzi A. Retrorectal Tumors: A Comprehensive Literature Review. *World J Surg* 2016; **40**: 2001-2015 [PMID: [27083451](#) DOI: [10.1007/s00268-016-3501-6](#)]
 - 19 **Baverez M**, Thibaudeau E, Libois V, Kerdraon O, Senellart H, Raoul JL. Retrorectal Mucinous Adenocarcinoma Arising from a Tailgut Cyst: A Case Report. *Case Rep Oncol* 2021; **14**: 147-151 [PMID: [33776696](#) DOI: [10.1159/000513028](#)]
 - 20 **Rachel F**, Guzik A, Szczerba D, Kozieł K, Gutterch K. Tailgut cyst and a very rare case of a tailgut cyst with mucinous adenocarcinoma in a 73 year old woman treated for buttock abscess with fistula. *Pol Przegl Chir* 2019; **91**: 38-42 [PMID: [31243172](#) DOI: [10.5604/01.3001.0013.0810](#)]
 - 21 **Li W**, Li J, Yu K, Zhang K. Retrorectal adenocarcinoma arising from tailgut cysts: a rare case report. *BMC Surg* 2019; **19**: 180 [PMID: [31775691](#) DOI: [10.1186/s12893-019-0639-9](#)]
 - 22 **Şahin S**, Kepil N, Batur Ş, Çetin SE. Adenocarcinoma in a Tailgut Cyst: A Rare Case Report. *Türk Patoloji Derg* 2020; **36**: 169-172 [PMID: [31026045](#) DOI: [10.5146/tjpath.2018.01459](#)]
 - 23 **Almeida Costa NA**, Rio G. Adenocarcinoma within a tailgut cyst. *BMJ Case Rep* 2018; **2018** [PMID: [30108121](#) DOI: [10.1136/bcr-2018-226107](#)]
 - 24 **Jarbouli S**, Jarraya H, Mihoub MB, Abdesselem MM, Zaouche A. Retrorectal cystic hamartoma associated with malignant disease. *Can J Surg* 2008; **51**: E115-E116 [PMID: [19057717](#)]
 - 25 **Andea AA**, Klimstra DS. Adenocarcinoma arising in a tailgut cyst with prominent meningotheelial proliferation and thyroid tissue: case report and review of the literature. *Virchows Arch* 2005; **446**: 316-321 [PMID: [15731926](#) DOI: [10.1007/s00428-004-1178-y](#)]
 - 26 **Cho BC**, Kim NK, Lim BJ, Kang SO, Sohn JH, Roh JK, Choi ST, Kim SA, Park SE. A carcinoembryonic antigen-secreting adenocarcinoma arising in tailgut cyst: clinical implications of carcinoembryonic antigen. *Yonsei Med J* 2005; **46**: 555-561 [PMID: [16127782](#) DOI: [10.3349/ymj.2005.46.4.555](#)]
 - 27 **Prasad AR**, Amin MB, Randolph TL, Lee CS, Ma CK. Retrorectal cystic hamartoma: report of 5 cases with malignancy arising in 2. *Arch Pathol Lab Med* 2000; **124**: 725-729 [PMID: [10782156](#) DOI: [10.5858/2000-124-0725-RCH](#)]
 - 28 **Sauer J**, Wolf HK, Junginger T. [Adenocarcinoma in a tail-gut cyst: a rare cause of recurrent perianal fistula]. *Chirurg* 2000; **71**: 712-716 [PMID: [10948740](#) DOI: [10.1007/s001040051125](#)]
 - 29 **Maruyama A**, Murabayashi K, Hayashi M, Nakano H, Isaji S, Uehara S, Kusuda T, Miyahara S, Kondo A, Yabana T. Adenocarcinoma arising in a tailgut cyst: report of a case. *Surg Today* 1998; **28**: 1319-1322 [PMID: [9872560](#) DOI: [10.1007/BF02482826](#)]
 - 30 **Yamaguchi K**, Okushiba S, Katoh H, Shimizu M, Taneichi H. Tailgut cyst invaded by rectal cancer through an anal fistula: report of a case. *Dis Colon Rectum* 2001; **44**: 447 [PMID: [11289294](#) DOI: [10.1007/BF02234747](#)]
 - 31 **Liessi G**, Cesari S, Pavanello M, Butini R. Tailgut cysts: CT and MR findings. *Abdom Imaging* 1995; **20**: 256-258 [PMID: [7620420](#) DOI: [10.1007/BF00200409](#)]



Published by **Baishideng Publishing Group Inc**
7041 Koll Center Parkway, Suite 160, Pleasanton, CA 94566, USA

Telephone: +1-925-3991568

E-mail: bpgoffice@wjgnet.com

Help Desk: <https://www.f6publishing.com/helpdesk>

<https://www.wjgnet.com>

