


World Journal of *Gastrointestinal Surgery*

World J Gastrointest Surg 2022 September 27; 14(9): 877-1088



Contents

Monthly Volume 14 Number 9 September 27, 2022

MINIREVIEWS

- 877 Oncologic aspects of the decision-making process for surgical approach for colorectal liver metastases progressing during chemotherapy
Araujo RLC, Carvalho CGCY, Maeda CT, Milani JM, Bugano DG, de Moraes PHZ, Linhares MM
- 887 Research progress on the immune microenvironment of the gallbladder in patients with cholesterol gallstones
Jiao JY, Zhu XJ, Zhou C, Wang P

ORIGINAL ARTICLE

Retrospective Study

- 896 Central pancreatectomy for benign or low-grade malignant pancreatic tumors in the neck and body of the pancreas
Chen YW, Xu J, Li X, Chen W, Gao SL, Shen Y, Zhang M, Wu J, Que RS, Yu J, Liang TB, Bai XL
- 904 Irinotecan- vs oxaliplatin-based regimens for neoadjuvant chemotherapy in colorectal liver metastasis patients: A retrospective study
Liu W, Chen FL, Wang K, Bao Q, Wang HW, Jin KM, Xing BC
- 918 Predictors of difficult endoscopic resection of submucosal tumors originating from the muscularis propria layer at the esophagogastric junction
Wang YP, Xu H, Shen JX, Liu WM, Chu Y, Duan BS, Lian JJ, Zhang HB, Zhang L, Xu MD, Cao J
- 930 Liver transplantation with simultaneous splenectomy increases risk of cancer development and mortality in hepatocellular carcinoma patients
Fan HL, Hsieh CB, Kuo SM, Chen TW
- 940 Development of an innovative nomogram of risk factors to predict postoperative recurrence of gastrointestinal stromal tumors
Guan SH, Wang Q, Ma XM, Qiao WJ, Li MZ, Lai MG, Wang C
- 950 Comparison of short-term efficacy between totally laparoscopic gastrectomy and laparoscopic assisted gastrectomy for elderly patients with gastric cancer
Zhao RY, Li HH, Zhang KC, Cui H, Deng H, Gao JW, Wei B
- 963 Personal predictive model based on systemic inflammation markers for estimation of postoperative pancreatic fistula following pancreaticoduodenectomy
Long ZD, Lu C, Xia XG, Chen B, Xing ZX, Bie L, Zhou P, Ma ZL, Wang R
- 976 Feasible management of median arcuate ligament syndrome in orthotopic liver transplantation recipients
Li SX, Fan YH, Tian GY, Lv GY

- 986** Study of preoperative diagnostic modalities in Chinese patients with superficial esophageal squamous cell carcinoma

Zeng YT, Sun YY, Tan WC, Luo SA, Zou BH, Luo GY, Huang CY

Observational Study

- 997** Oesophageal cancer metastases: An observational study of a more aggressive approach

Pickett L, Dunne M, Monaghan O, Grogan L, Breathnach O, Walsh TN

- 1008** Change of tumor-infiltrating lymphocyte of associating liver partition and portal vein ligation for staged hepatectomy for hepatocellular carcinoma

Wang W, Deng ZF, Wang JL, Zhang L, Bao L, Xu BH, Zhu H, Guo Y, Wen Z

- 1026** Blood index panel for gastric cancer detection

Guo GH, Xie YB, Zhang PJ, Jiang T

Randomized Controlled Trial

- 1037** Effect of cardiac output - guided hemodynamic management on acute lung injury in pediatric living donor liver transplantation

Dou XJ, Wang QP, Liu WH, Weng YQ, Sun Y, Yu WL

SYSTEMATIC REVIEWS

- 1049** Minimally invasive endoscopic repair of rectovaginal fistula

Zeng YX, He YH, Jiang Y, Jia F, Zhao ZT, Wang XF

META-ANALYSIS

- 1060** Laparoscopic appendectomy, stump closure and endoloops: A meta-analysis

Zorzetti N, Lauro A, Bellini MI, Vaccari S, Dalla Via B, Cervellera M, Cirocchi R, Sorrenti S, D'Andrea V, Tonini V

CASE REPORT

- 1072** Retrorectal mucinous adenocarcinoma arising from a tailgut cyst: A case report and review of literature

Wang YS, Guo QY, Zheng FH, Huang ZW, Yan JL, Fan FX, Liu T, Ji SX, Zhao XF, Zheng YX

LETTER TO THE EDITOR

- 1082** Successful treatment of acute symptomatic extensive portal venous system thrombosis by 7-day systemic thrombolysis

Gao FB, Wang L, Zhang WX, Shao XD, Guo XZ, Qi XS

- 1086** Prediction factors for ischemia of closed-loop small intestinal obstruction

Pavlidis ET, Pavlidis TE

ABOUT COVER

Editorial Board Member of *World Journal of Gastrointestinal Surgery*, Shu-You Peng, FACS, FRCP (Hon), MD, Full Professor, Department of Surgery, Medical School of Zhejiang University, Hangzhou 310009, Zhejiang Province, China. zrwkpsy@zju.edu.cn

AIMS AND SCOPE

The primary aim of *World Journal of Gastrointestinal Surgery* (WJGS, *World J Gastrointest Surg*) is to provide scholars and readers from various fields of gastrointestinal surgery with a platform to publish high-quality basic and clinical research articles and communicate their research findings online.

WJGS mainly publishes articles reporting research results and findings obtained in the field of gastrointestinal surgery and covering a wide range of topics including biliary tract surgical procedures, biliopancreatic diversion, colectomy, esophagectomy, esophagostomy, pancreas transplantation, and pancreatectomy, etc.

INDEXING/ABSTRACTING

The WJGS is now abstracted and indexed in Science Citation Index Expanded (SCIE, also known as SciSearch®), Current Contents/Clinical Medicine, Journal Citation Reports/Science Edition, PubMed, PubMed Central, Reference Citation Analysis, China National Knowledge Infrastructure, China Science and Technology Journal Database, and Superstar Journals Database. The 2022 Edition of Journal Citation Reports® cites the 2021 impact factor (IF) for WJGS as 2.505; IF without journal self cites: 2.473; 5-year IF: 3.099; Journal Citation Indicator: 0.49; Ranking: 104 among 211 journals in surgery; Quartile category: Q2; Ranking: 81 among 93 journals in gastroenterology and hepatology; and Quartile category: Q4.

RESPONSIBLE EDITORS FOR THIS ISSUE

Production Editor: Rui-Rui Wu, Production Department Director: Xiang Li, Editorial Office Director: Jia-Ru Fan.

NAME OF JOURNAL

World Journal of Gastrointestinal Surgery

ISSN

ISSN 1948-9366 (online)

LAUNCH DATE

November 30, 2009

FREQUENCY

Monthly

EDITORS-IN-CHIEF

Peter Schemmer

EDITORIAL BOARD MEMBERS

<https://www.wjgnet.com/1948-9366/editorialboard.htm>

PUBLICATION DATE

September 27, 2022

COPYRIGHT

© 2022 Baishideng Publishing Group Inc

INSTRUCTIONS TO AUTHORS

<https://www.wjgnet.com/bpg/gerinfo/204>

GUIDELINES FOR ETHICS DOCUMENTS

<https://www.wjgnet.com/bpg/GerInfo/287>

GUIDELINES FOR NON-NATIVE SPEAKERS OF ENGLISH

<https://www.wjgnet.com/bpg/gerinfo/240>

PUBLICATION ETHICS

<https://www.wjgnet.com/bpg/GerInfo/288>

PUBLICATION MISCONDUCT

<https://www.wjgnet.com/bpg/gerinfo/208>

ARTICLE PROCESSING CHARGE

<https://www.wjgnet.com/bpg/gerinfo/242>

STEPS FOR SUBMITTING MANUSCRIPTS

<https://www.wjgnet.com/bpg/GerInfo/239>

ONLINE SUBMISSION

<https://www.f6publishing.com>



Observational Study

Oesophageal cancer metastases: An observational study of a more aggressive approach

Lianne Pickett, Mary Dunne, Orla Monaghan, Liam Grogan, Oscar Breathnach, Thomas N Walsh

Specialty type: Surgery

Provenance and peer review:

Unsolicited article; Externally peer reviewed.

Peer-review model: Single blind

Peer-review report's scientific quality classification

Grade A (Excellent): 0

Grade B (Very good): B, B

Grade C (Good): 0

Grade D (Fair): 0

Grade E (Poor): 0

P-Reviewer: Sachdeva S, India; Serban ED, Romania

Received: December 18, 2021

Peer-review started: December 18, 2021

First decision: April 19, 2022

Revised: May 4, 2022

Accepted: August 30, 2022

Article in press: August 30, 2022

Published online: September 27, 2022



Lianne Pickett, Department of Surgery, Connolly Hospital, Blanchardstown, Dublin D15 X40D, Ireland

Mary Dunne, Clinical Trials Resource Unit, St Luke's Radiation Oncology Network, Dublin D06 HH36, Ireland

Orla Monaghan, Department of Radiation Oncology, St Luke's Radiation Oncology Network, Dublin D06 HH36, Ireland

Liam Grogan, Oscar Breathnach, Department of Medical Oncology, Beaumont Hospital, Dublin D09 V2N0, Ireland

Thomas N Walsh, Department of Surgery, RCSI Bahrain, Adliya 15503, Bahrain

Corresponding author: Lianne Pickett, MB, ChB, MCh, Doctor, Department of Surgery, Connolly Hospital, Blanchardstown, Mill Road, Abbots Town, Dublin D15 X40D, Ireland. lianne.pickett@ucdconnect.ie

Abstract

BACKGROUND

The prognosis for oesophageal carcinoma is poor, but once distant metastases emerge the prognosis is considered hopeless. There is no consistent protocol for the early identification and aggressive management of metastases.

AIM

To examine the outcome of a policy of active postoperative surveillance with aggressive treatment of confirmed metastases.

METHODS

A prospectively maintained database of 205 patients diagnosed with oesophageal carcinoma between 1998 and 2019 and treated with curative intent was interrogated for patients with metastases, either at diagnosis or on follow-up surveillance and treated for cure. This cohort was compared with incomplete clinical responders to neoadjuvant chemoradiotherapy (nCRT) who subsequently underwent surgery on their primary tumour. Overall survival was estimated using the Kaplan-Meier method, and the log-rank test was used to compare survival differences between groups.

RESULTS

Of 205 patients, 11 (5.4%) had metastases treated for cure (82% male; median age 60 years; 9 adenocarcinoma and 2 squamous cell carcinomas). All had undergone neoadjuvant chemotherapy or chemoradiotherapy, followed by surgery in all but 1 case. Of the 11 patients, 4 had metastatic disease at diagnosis, of whom 3 were successfully downstaged with nCRT before definitive surgery; 2 of these 4 also developed oligometastatic recurrence and were treated with curative intent. Following definitive treatment, 7 had treatment for metachronous oligometastatic disease; 5 of whom underwent metastasectomy (adrenal \times 2; lung \times 2; liver \times 1). The median overall survival was 10.9 years [95% confidence interval (CI): 0.7-21.0 years], which was statistically significantly longer than incomplete clinical responders undergoing surgery on the primary tumour without metastatic intervention [n = 62; median overall survival = 1.9 (95%CI: 1.1-2.7; P = 0.012]. The cumulative proportion surviving 1, 3, and 5 years was 100%, 91%, and 61%, respectively compared to 71%, 36%, and 25% for incomplete clinical responders undergoing surgery on the primary tumour who did not undergo treatment for metastatic disease.

CONCLUSION

Metastatic oesophageal cancer represents a unique challenge, but aggressive treatment can be rewarded with impressive survival data. In view of recent advances in targeted therapies, intensive follow-up may yield a greater number of patients with curative potential and thus improved long-term survival.

Key Words: Oesophageal metastases; Oligometastases; Active surveillance; Treatment for cure; Metastasectomy; Survival

©The Author(s) 2022. Published by Baishideng Publishing Group Inc. All rights reserved.

Core Tip: Modern imaging technologies can detect oligometastatic oesophageal cancer earlier than ever before, and targeted multimodal therapies, combined with innovative surgery, increases the potential for cure. Unfortunately, current guidelines do not reflect these advances and all too often consign patients to palliation. This approach is incongruous with other oligometastatic cancers such as colorectal cancer. Based on the survival outcomes of patients with oligometastatic disease treated for cure at our institution we advocate for more intensive surveillance strategies for earlier identification of patients with curative potential to improve overall long-term survival.

Citation: Pickett L, Dunne M, Monaghan O, Grogan L, Breathnach O, Walsh TN. Oesophageal cancer metastases: An observational study of a more aggressive approach. *World J Gastrointest Surg* 2022; 14(9): 997-1007

URL: <https://www.wjgnet.com/1948-9366/full/v14/i9/997.htm>

DOI: <https://dx.doi.org/10.4240/wjgs.v14.i9.997>

INTRODUCTION

Oesophageal cancer is an aggressive disease that presents insidiously, disseminates early, and spreads rapidly in most patients. It remains a leading cause of death from cancer worldwide and fewer than 5%-12% will survive 5 years[1,2]. At least 40% of patients present with distant metastasis at initial diagnosis [3], and only 5% of these patients will be alive at 5 years[4]. Even when presenting with early disease, 29%-54% of patients undergoing surgical resection with curative intent will develop locoregional or distant recurrence[5-7]. Of patients with a ypT0N0M0 tumour at resection following neoadjuvant chemoradiotherapy (nCRT), up to 17% will succumb to distant metastases[8-10]. Because of these poor survival outcomes, the role of intensive surveillance post-oesophagectomy and treatment of metastatic disease remains controversial.

The management of oesophageal cancer has undergone major advances over the past 30 years. Specifically, both neoadjuvant chemotherapy and nCRT have been shown to increase survival over surgery alone[11-13]. While neoadjuvant chemotherapy has achieved this increase by targeting occult micrometastases[14], combined CRT has increased survival by both targeting micrometastases and sterilizing locoregional disease, thus up to 50% of patients with squamous cell carcinoma (SCC) and up to 25% of patients with adenocarcinoma (AC) undergoing CRT have a complete pathological response in the resected specimen, depending on the regimen and the disease stage[11,12].

Nevertheless, metastatic oesophageal cancer remains a challenge. Oligometastases are defined as a state of limited metastatic disease characterized by fewer than five metastases[5,15]. Synchronous oligometastases may be detected at the time of diagnosis of the primary cancer, while metachronous

oligometastases are those detected during follow-up[5,16]. Metastasectomy is well-established in the treatment of certain oligometastatic cancers, such as colorectal cancer, where partial hepatectomy and pulmonary resection are well established[5]. Both the United Kingdom's National Institute for Health and Clinical Excellence and the United States' National Comprehensive Cancer Network recommend surveillance strategies to identify recurrence as well as liver and pulmonary metastasectomy where possible[17,18]. In contrast, the National Institute for Health and Clinical Excellence recommends neither routine clinical follow-up nor radiological follow-up be offered to patients who have no symptoms or evidence of residual disease after treatment for oesophagogastric cancer with curative intent for the detection of recurrent disease[19]. The National Comprehensive Cancer Network recommends clinical follow-up alone for asymptomatic patients and palliation alone for patients who develop metastatic recurrence[20].

Over the past decades, efforts have focused on the molecular and biological alterations that lead to oesophageal cancer, specifically the influence of angiogenesis on micrometastatic tumour growth[21, 22]. This has resulted in the development of novel molecularly targeted agents that target a variety of relevant pathways, such as vascular endothelial growth factor, cyclooxygenase-2, epidermal growth factor receptor, and mammalian target of rapamycin[23] as well as targeted radiotherapy in the form of stereotactic radiotherapy[24]. Leading the way are HER-2 inhibitors for the treatment of HER-2 expressing metastatic ACs[23]. It is intuitive that aggressive treatment of oligometastatic disease would improve disease control and provide a survival benefit for patients with recurrent cancer detected at its earliest stage. The purpose of this study was to examine survival outcomes in patients who underwent active surveillance and targeted therapy at our institution for their oligometastatic disease.

MATERIALS AND METHODS

Study design and patients

We conducted a retrospective review of a prospectively maintained database of all patients diagnosed with oesophageal carcinoma and treated with curative intent between 1998 and 2019 at Connolly Hospital Blanchardstown, Dublin, Ireland. Patients were treated with either CRT alone, or CRT followed by surgery, or surgery alone.

Patient management and follow-up

Over a 21-year period, 205 patients with oesophageal carcinoma underwent curative management. Following discharge, patients were followed up in the clinic every 3 mo for the first 3 years with esophagogastroduodenoscopy performed every 3 mo and computed tomography (CT) performed every 6 mo. Between 3 years and 5 years they were followed up in the clinic every 6 mo with esophagogastroduodenoscopy every 6 mo and CT scanning performed annually. After 5 years patients were followed up annually with endoscopy and a clinic visit (which was on the same day for patients who had to travel from a distance). In addition, patients had access to their oncology coordinator and were encouraged to call at any time with any concern. On receipt of a call, the coordinator would offer them a clinic visit or an esophagogastroduodenoscopy (or other imaging) depending on their symptoms or concerns.

Patient database

A patient database was maintained over the study period, both by nursing and clinical staff. This was scrutinized for patients with synchronous and metachronous oligometastases. Only patients who underwent curative treatment of oligometastatic disease were included in this study. A second group of patients (with non-metastatic disease) who had an incomplete clinical response to nCRT and subsequently underwent surgery on the primary tumour were identified for comparison of survival outcomes.

Of 205 patients treated with curative intent, 62 had an incomplete response to nCRT for non-metastatic oesophageal cancer and subsequently underwent surgery, and 11 had oligometastases treated for cure. The medical and electronic records of the oligometastatic cohort treated for cure were reviewed for demographic, clinical, and histopathologic variables. Notably, staging of the primary oesophageal cancer was prospectively assigned according to the TNM classification of the American Joint Committee for Cancer Staging, initially the 6th edition and then the 7th following its publication. Each case was assessed with respect to the use of neoadjuvant therapy, history of oesophagectomy, and timing of metastasis. Further details regarding the site and treatment of metastasis were included. Survival data was included for analysis and comparison.

Ethical approval

As this was a retrospective audit ethical approval was not required, but audit approval was sought and granted by the Connolly Hospital Ethics Committee.

Statistical analysis

The statistical analysis of this study was performed by biostatistician Mary Dunne from St Luke's Radiation Oncology Network, Dublin D06 HH36, Ireland. Overall survival was estimated using the Kaplan-Meier method and was defined as the duration from the date of diagnosis until death from any cause or last follow-up at study endpoint on February 26, 2020. The log-rank test was used to compare survival differences between groups (assessed for significance at the 0.05 level). Statistical analysis was performed using IBM SPSS Statistics 25 (Chicago, IL, United States).

RESULTS

Clinical characteristics of patients

Of the 205 patients, 11 (5.4%) patients diagnosed with oesophageal carcinoma [146 (71.0%) male; 135 (65.9%) AC; 68 (33.2%) SCC; 2 adenosquamous] between 1998 and 2019 and treated with curative intent had metastases treated for cure. Of these, 4 had synchronous oligometastatic oesophageal cancer, 2 of which also had treatment for cure for oligometastatic recurrence. A further 7 had metachronous oligometastatic oesophageal cancer only. The median age of patients with synchronous metastasis was 65 years (range: 53-71 years; AC 75%) and in patients with metachronous carcinoma was 57 years (range: 36-72 years; AC 86%) (Table 1). The majority of both cohorts were male (75% and 86%, respectively).

Treatment of synchronous oligometastatic oesophageal cancer

The 4 patients that had metastatic disease at presentation were treated with nCRT, 3 of whom underwent subsequent oesophagectomy and achieved a margin free R0 resection and 1 of whom declined surgery following a clinical complete response to nCRT (Table 1). Two of these patients subsequently presented with metachronous metastases, which were also treated for cure (Table 2).

Patient 1 had locally advanced SCC at diagnosis (T4N1M1). Despite a complete clinical response to definitive CRT, routine surveillance positron emission tomography-CT (PET-CT) almost 12 mo later (11.5 mo) revealed fluorodeoxyglucose (FDG) avid lung lesions bilaterally. These were subsequently treated with stereotactic radiotherapy. The patient survived for 3 years post metastatic recurrence (36.4 mo). Patient 2 had a 12 mm short-axis FDG-positive lymph node lying immediately to the right of the coeliac axis on staging PET-CT (AC, T3N2M1). The patient was treated with nCRT and radical oesophagogastric resection for a poorly differentiated junctional/cardia AC (ypT2bN1Mx). Almost 18 mo later (17.9 mo) a radiological work-up for a pulmonary embolus revealed a 1.9 cm left para-aortic node with FDG uptake on PET-CT, which was subsequently treated with chemotherapy (Table 2). Follow-up CT showed a reduction in tumour size and subsequent surveillance with endoscopy and CT revealed stable disease with no evidence of recurrence. The patient was alive and well at the conclusion of this study, 83.3 mo after his initial diagnosis (65.4 mo post-recurrence).

Two further patients (Patient 3 and Patient 4) had treatment for cure of synchronous oligometastatic disease only (Tables 1 and 2). Patient 3 had liver metastasis on staging PET-CT (AC, T3N1M1). Restaging CT post nCRT was negative for liver metastasis, and the patient subsequently underwent oesophagectomy (ypT3N0M0). Patient 4 had a 1 cm FDG avid right supraclavicular node on staging PET-CT (AC, T3N2M0) and underwent nCRT and subsequent oesophagectomy for a moderate to poorly differentiated AC at the oesophagogastric junction (ypT2N0Mx). The patient was alive and well at the conclusion of this study, 8.5 years after his initial diagnosis (102.8 mo).

Treatment of metachronous oligometastatic oesophageal cancer

The remaining 7 patients did not have clinical evidence of metastatic oesophageal cancer at diagnosis. These patients had mostly T3 disease with or without nodal involvement (Table 1; Patient 5-11). All underwent nCRT or neoadjuvant chemotherapy followed by surgery for their primary cancer. Of this cohort ($n = 7$), 3 developed pulmonary recurrence, 2 adrenal, 1 liver, and 1 patient had biopsy proven retroperitoneal nodal recurrence. All 7 patients underwent targeted treatment for metastatic recurrence with intent to cure, the details of which are summarized in Table 2. The median time from diagnosis to recurrence was 19.2 mo (range: 15.7-33.0 mo), and the median survival post recurrence was 97.4 mo [95% confidence interval (CI): 0-204 mo]. The median overall survival (MOS) was 130 mo (95%CI: 3-258 mo), or the MOS was 10.9 years (95%CI: 0.2-21.5 years).

Survival outcomes

The MOS of the 11 patients who underwent curative treatment for synchronous or metachronous metastatic disease or both was 10.9 years (95%CI: 0.7-21) which was statistically significantly longer than patients with an incomplete clinical response following nCRT undergoing surgery [$n = 62$; MOS = 1.9 years (95%CI: 1.1-2.7); $P = 0.012$] (Figure 1). Of note, the latter did not undergo curative treatment for any future proven or probable metastatic recurrence. The cumulative proportion of patients with metastatic disease treated for cure surviving 1, 3, and 5 years was 100%, 91%, and 61%, respectively,

Table 1 Clinical characteristics of patients

Patient	Age in yr	Sex	Primary tumour location	Histologic type of tumour	Differentiation	Clinical stage of primary tumour	Neoadjuvant therapy	Oesophagectomy	ypTNM
Synchronous and Metachronous Oligometastatic Disease									
1 ¹	62	Female	Upper third	SCC	Moderate	T4N1M1	Walsh Regimen ¹⁷	No	NA
2 ²	53	Male	OGJ	AC	Poor	T3N2M1	Walsh Regimen + CROSS	Yes	T2bN1Mx
Synchronous Oligometastatic Disease Only									
3	71	Male	Lower third/OGJ	AC	Poor	T3N1M1	Carbo5FU; 60Gy	Yes	T3N0M0
4	68	Male	OGJ	AC	Moderate-poor	T3N2M0	Walsh Regimen	Yes	T2N0Mx
Metachronous Oligometastatic Disease Only									
5	56	Male	Middle/lower third	SCC	Moderate	T3N2M0	Walsh Regimen	Yes	T2N1Mx
6	36	Male	Lower	AC	Moderate	T3N1M0	CROSS	Yes	T3N0Mx
7 ³	72	Female	OGJ	AC	Moderate	T3N0M0	CROSS	Yes	T2N0
8	70	Male	OGJ	AC	Poor	Nodal disease/Stage IIIA	MAGIC	Yes	T2N1Mx
9	48	Male	Lower third	AC	Poor	Stage IIB	Walsh Regimen	Yes	T1N0Mx
10 ⁴	57	Male	Lower third	AC	Poor	T3N0M0	CROSS	Yes	T2N0M0
11	60	Male	OGJ	AC	Poor	T3N0M0	CROSS	Yes	T0N0Mx

¹Patient 1 had a complete clinical response.

²Patient 2 received six cycles of cisplatin and fluorouracil, followed by six cycles of paclitaxel and carboplatin.

³Patient 7 underwent salvage surgery after surveillance Positron-emission tomography suggested residual disease despite initial complete clinical response to neoadjuvant chemoradiotherapy.

⁴Patient 10 was diagnosed with a synchronous primary renal cell carcinoma, which was discovered incidentally during staging for his oesophageal cancer. He was referred to a urology service in another hospital and treated with radiofrequency ablation.

ypTNM: Pathologic staging after neoadjuvant therapy; Walsh Regimen¹⁷: Cisplatin/5-fluorouracil, 40 Gy concurrent radiotherapy; CROSS: The Dutch Chemoradiotherapy for Oesophageal Cancer Followed by Surgery study-weekly carboplatin and paclitaxel with concurrent radiotherapy; Carbo5FU: Carboplatin/5-fluorouracil; MAGIC: Epirubicin, cisplatin, and fluorouracil; NA: Not applicable; OGJ: Oesophagogastric junction; AC: Adenocarcinoma; SCC: Squamous cell carcinoma.

with 6 patients still alive at the end of the study period, compared to 71%, 36%, and 25% for incomplete clinical responders without metastatic disease undergoing surgery on the primary tumour.

Patients that underwent surgical resection for their recurrence ($n = 5$) had a MOS of 10.9 years (95%CI: 0.6-21.2) from date of diagnosis, 8.1 years (95%CI: 0-16.8 years) post recurrence, and a 5-year survival of 80% from the date of diagnosis.

DISCUSSION

Patients with metastatic oesophageal cancer present a unique challenge. Although solitary metastases of oesophageal cancer are uncommon[25], the evolution of imaging will ensure ever-earlier detection, which challenges oncologists and surgeons to detect and deal with them. Treatment of oligometastatic oesophageal cancer is controversial, and to date formal guidelines are lacking. There are no large randomized multicenter trials, and thus case series, such as ours, remain an important source of information for clinicians managing these challenging patients.

Those patients treated surgically for recurrence in our study had a MOS of 10.9 years, or 130.3 mo and a 5-year survival of 80%. Depypere *et al*[26] conducted a large retrospective study comparing different treatment options for different subtypes of recurrence following curative resection, including single solid organ metastasis and single metastasis at another location. Of 1754 patients that had curative resection, 43.7% had recurrence, 14.4% of whom had clinical solitary solid organ recurrence (liver, lung, brain, or adrenal)[26]. Only 20 patients (1.14%) had their recurrence resected with or without systemic

Table 2 Treatment of synchronous and metachronous oligometastatic oesophageal carcinoma

Patient	Synchronous metastases	Type	Treatment	Metachronous metastases	Type	Time to recurrence in mo	Treatment	Survival post recurrence in mo	Alive at study endpoint	Overall survival in mo
1	Yes	Locally advanced ¹	Walsh regimen	Yes	Lung	11.5	Stereotactic radiotherapy	36.4	No	47.9
2	Yes	Coeliac axis	Walsh regimen + CROSS + radial gastrectomy	Yes	Left para-aortic nodes	17.9	Chemotherapy (Epirubicin, Oxaliplatin + Capecitabine)	65.4	Yes	83.3
3	Yes	Liver	Carbo5FU; 60 Gy + oesophagectomy	No	NA	NA	NA	NA	No	23.6
4	Yes	Locally advanced ²	Walsh regimen + oesophagectomy	No	NA	NA	NA	NA	Yes	102.8
5	No	NA	NA	Yes	Lung	32.9	Left upper lobectomy (VATS)	97.4	No	130.3
6	No	NA	NA	Yes	Lung	16.7	Chemotherapy (carbo/taxol + FOLFOX)	21.9	No	38.6
7	No	NA	NA	Yes	Lung	19.2	Wedge resection (VATS)	26.1	No	45.3
8	No	NA	NA	Yes	Adrenal	29.7	Adrenalectomy	62.1	Yes	91.8
9	No	NA	NA	Yes	Adrenal	15.9	Adrenalectomy + chemotherapy (irinotecan)	118.9	Yes	134.8
10	No	NA	NA	Yes	Liver	33.0	Resection + chemotherapy	51.9	Yes	84.9
11	No	NA	NA	Yes	Para-aortic + Retroperitoneal	15.7	Chemotherapy (FOLFOX)	14.9	Yes	30.6

¹Right innominate artery and pars membrane of the trachea with a right 1 cm subcarinal adenopathy and left 5 mm paratracheal node on staging whole-body positron emission tomography-computed tomography (squamous cell carcinoma, T4N1M1).

²1 cm fluorodeoxyglucose avid right supraclavicular node on staging positron emission tomography-computed tomography.

NA: Not applicable; VATS: Video-assisted thoracoscopic surgery; FOLFOX: Folinic acid, fluorouracil, oxaliplatin; CROSS: The Dutch Chemoradiotherapy for Oesophageal Cancer Followed by Surgery study-weekly carboplatin and paclitaxel with concurrent radiotherapy; Carbo5FU: Carboplatin/5-fluorouracil.

therapy and had a significantly better median and 5-year survival than 63 non-surgically treated patients [54.8 mo (5-year survival 43.9%) *vs* 11.6 mo (5-year survival 4.6%)] [25,26]. Arguably, those suitable for resection self-select, but the survival statistics for metastatic resection in a disease as aggressive as oesophageal cancer are impressive.

The patients in our study who underwent adrenalectomy were alive at 62.1 and 118.9 mo post recurrence. The oesophagus is the third most frequent site of origin of adrenal metastasis [27], and there are only a few reports of adrenalectomy for recurrence with survival ranging from 28 mo to over 5 years [27–30]. These findings confirm that adrenalectomy for isolated adrenal metastases from oesophageal carcinoma is worthwhile. A disease-free interval of over 6 mo and an AC subtype are reported as predictors of improved survival and should be considered in patient selection [31,32]. As adrenal metastases are clinically silent, intensive surveillance imaging is indicated if they are to be identified early enough for curative resection.

The remaining patients who underwent metastasectomy in our case series had either lung or liver metastases. All had metachronous oligometastases, had received nCRT, and had undergone resection of their primary tumour. Those who underwent pulmonary metastasectomy lived for 26.1 and 97.4 mo post recurrence, while the patient who underwent liver metastasectomy was alive and disease-free at 51.9 mo post recurrence. While hepatectomy and pulmonary resection are universally recommended for colorectal cancer metastases [17,18], they are not recommended for oesophageal cancer [19,20]. A nationwide study by Seising *et al* [33] of the Dutch national registry for histopathology and cyto-

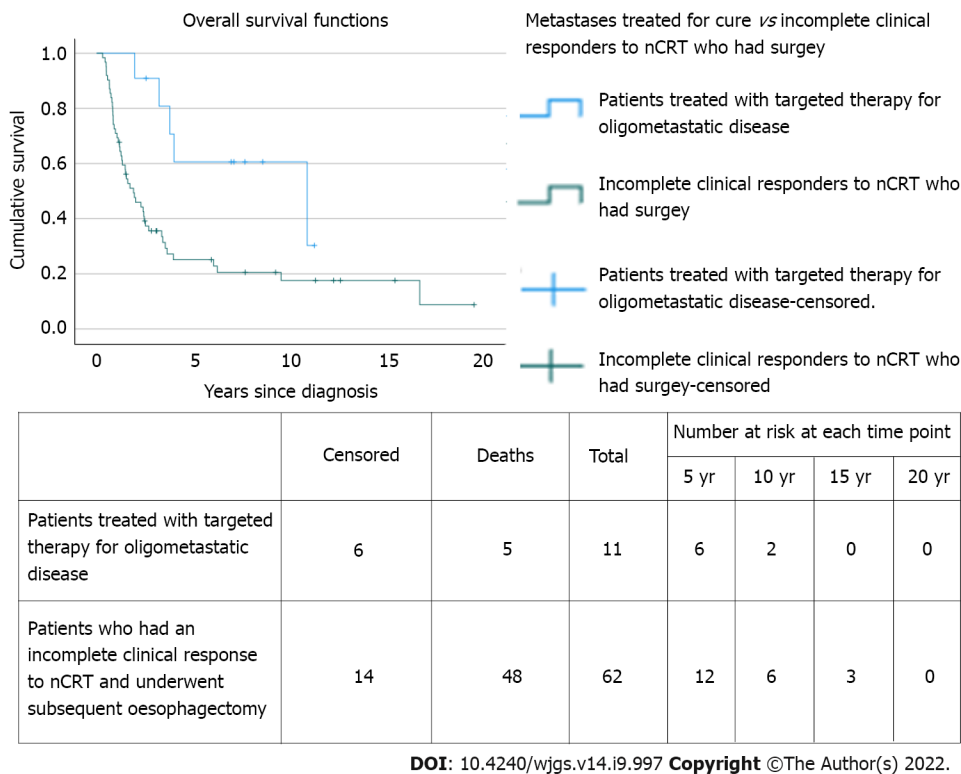


Figure 1 Survival plots for patients undergoing treatment of oligometastatic disease for cure vs patients with an incomplete clinical response to neoadjuvant chemoradiotherapy who underwent subsequent oesophagectomy. nCRT: Neoadjuvant chemoradiotherapy.

pathology identified 32057 patients who underwent resection for gastro-oesophageal cancer between 1991 and 2016 and reported that 34 (0.11%) underwent resection for pulmonary ($n = 15$) or hepatic ($n = 19$) metastases across 21 hospitals and had an overall 5-year survival of 53% and 31%, respectively[33]. Liu *et al*[34] reported that 26 SCC patients with solitary hepatic metastasis, who underwent liver resection, had 1- and 2-year survival rates of 50.8% and 21.2%, respectively, which was significantly higher than the 31.0% and 7.1% survival rates for the 43 non-surgically treated patients[34].

Oesophageal cancer patients very frequently present with metastases, which almost inevitably consigns them to palliative management. Until recently primary cancer resection in these circumstances was rarely considered. Of the 4 patients who presented with metastatic oesophageal cancer in our case series, 3 underwent surgery to the primary cancer. All 3 had nCRT and all achieved an R0 resection, with a cumulative proportion surviving 2 years of 67%. Zhang *et al*[35] analysed a large population-based cohort of 4367 metastatic oesophageal cancer patients (M1b-stage) from the SEER database[35] and found a significant survival benefit for surgery for the primary tumour with a median survival for the surgery group of 14 mo compared with 9 mo for the no surgery AC group, and a similar significant survival advantage for surgery (11 mo) compared with the no surgery SCC group (7 mo)[35]. Of note, patients who had not received neoadjuvant chemotherapy failed to benefit from resection for either tumour subtype[35]. Thus, when combined with neoadjuvant chemotherapy, surgery for the primary tumour is associated with improved survival in a select group of patients with metastatic oesophageal cancer[35].

Three of the patients in our series received chemotherapy alone for recurrent oligometastatic oesophageal cancer (patients 2, 6, and 11). Although chemotherapy is commonly considered as merely palliative in recurrent metastatic cancer, it also has the potential to cure[36]. Taxanes as single agents have a slightly higher response rate in patients with AC (34%) than in patients with SCC (28%), resulting in an overall survival rate of 13.2 mo[37]. Parry *et al*[38] reported complete tumour regression in 2 patients after chemotherapy alone, with both patients alive at last follow-up (35 and 112 mo)[38]. Developments in proton beam therapy and stereotactic ablative radiation increases its conformality and reduces radiation toxicity[39]. Sachdeva *et al*[40] recently reported on the use of external beam radiotherapy for the treatment of oligometastatic sacral metastases in a 46-year-old male with a rare case of primary oesophageal lymphoma[40]. Moreover, 1-year and 2-year progression-free survival and overall survival rates have been reported at 62% and 48% and 90% and 72%, respectively, following stereotactic ablative therapy for pulmonary metastases[41].

With few predictive factors for survival of metastatic oesophageal cancer in the literature[42], it is unclear which patients or which tumour characteristics predict the best survival outcomes. The current approach to metastatic disease all too often consigns the patient to palliative care and a dismal outcome.

We have previously reported that bone marrow positivity for micrometastases at the time of oesophagectomy is a predictor of increased risk of cancer-related death and can identify patients requiring intensive surveillance for early detection of metastases with intent to treat[43]. Our current findings suggest that a more optimistic approach can be rewarded with impressive survival data. It is intuitive that aggressive treatment can improve survival, but it implies a need for more intensive surveillance strategies, especially in the first 3 years post-resection, to identify salvageable patients and consider curative intent. In an era of molecularly targeted agents, the identification of such patients is more important than ever as identified by the CheckMate 557 trial where the addition of nivolumab for patients with residual disease following CRT provided a median disease-free survival of 22.4 mo *vs* 11.0 mo in the placebo arm, which was significant[44].

The obvious limitation of our study is the small sample size of patients with metastatic oesophageal cancer treated for cure. Moreover, the survival data reported in our study reflects a policy of aggressive treatment of confirmed limited metastases only. Such patients self-select, and our survival data cannot be applied to all patients with metastatic oesophageal cancer.

CONCLUSION

In conclusion, as advances in imaging facilitate earlier metastatic disease detection and advances in multimodal and targeted treatments improve survival outcomes, surveillance strategies must be intensified to diagnose metastatic disease earlier in the recurrence process to institute medical or surgical measures with a greater possibility of success. Future studies are needed to prospectively identify the rate of oligometastatic recurrence in oesophageal carcinoma in the context of today's imaging technologies to update surveillance and treatment guidelines in line with those for cancers of the lower gastrointestinal tract.

ARTICLE HIGHLIGHTS

Research background

The prognosis of metastatic oesophageal cancer is poor. The rate of oligometastatic oesophageal cancer is not well established nor is the survival benefit of intervention. As a result, current guidelines advocate against a proactive approach, which is incongruent with other oligometastatic cancers such as colorectal cancer. Based on a policy of active postoperative surveillance and survival outcomes of patients with oligometastatic disease treated with curative intent at our institution, we advocate for more intensive surveillance strategies to identify patients with curative potential early and thus improve long-term survival.

Research motivation

To evaluate the impact of a policy of active surveillance and aggressive management of confirmed metastases on long-term survival.

Research objectives

To examine survival outcomes in patients who underwent active surveillance and targeted therapy of their oligometastatic disease, either at diagnosis or on follow-up surveillance, at our institution. When compared to incomplete clinical responders to neoadjuvant chemoradiotherapy (nCRT) for non-metastatic oesophageal cancer who underwent surgery on their primary tumour, the median overall survival of the oligometastatic cohort was statistically significantly longer. These findings suggest that aggressive treatment of confirmed metastases can be rewarded with impressive survival data and that a more proactive approach to oesophageal oligometastases should be considered.

Research methods

A prospectively maintained database of patients diagnosed with oesophageal carcinoma and treated with curative intent in a single institution was interrogated for patients with metastases, either at diagnosis or on follow-up surveillance, and treated for cure. This cohort was compared with incomplete clinical responders to nCRT who subsequently underwent surgery on their primary tumour. Overall survival was estimated using the Kaplan-Meier method, and the log-rank test was used to compare survival differences between groups.

Research results

The overall survival of patients with oligometastatic disease who were treated for cure at our institution is impressive and statistically significantly longer than incomplete clinical responders without metastatic disease who subsequently underwent surgery on their primary tumour. These results suggest

that intensive follow-up and aggressive management of confirmed metastases may improve long-term survival. Further studies are needed to prospectively identify the rate of oligometastatic recurrence in oesophageal carcinoma and evaluate the cost-benefit ratio of a policy of active surveillance and aggressive management of confirmed oligometastatic disease.

Research conclusions

In view of recent diagnostic and therapeutic advances, intensive follow-up and aggressive treatment of confirmed metastases may improve long-term survival in patients with oligometastatic oesophageal carcinoma.

Research perspectives

Further research should prospectively establish the rate of oligometastatic recurrence in oesophageal carcinoma to evaluate the cost-benefit ratio of active surveillance and aggressive management and inform future clinical guidelines.

FOOTNOTES

Author contributions: Walsh TN was the guarantor, designed the study, participated in the acquisition of data, and revised and edited the article critically; Pickett L acquired, analysed, and interpreted the data and drafted the initial manuscript; Dunne M statistically analysed the data and edited the manuscript; Monaghan O, Grogan L, and Breathnach O reviewed the article and made critical revisions related to important intellectual content.

Institutional review board statement: The study was reviewed and approved by the Connolly Hospital Institutional Review Board.

Informed consent statement: As this was a retrospective audit and many patients were not alive at the commencement of this study, written informed consent was not feasible/obtained. This was an observational study, and no patient received treatment as part of the study. Furthermore, we have not included any identifiable patient information in our manuscript. Verbal consent, although not required, was obtained where appropriate/feasible.

Conflict-of-interest statement: All the authors report no relevant conflicts of interest for this article.

Data sharing statement: The statistical analysis and dataset are available from the corresponding author at lianne.pickett@ucdconnect.ie. As this was a retrospective audit consent was not routinely obtained but the presented data are anonymized, and risk of identification is low.

STROBE statement: The authors have read the STROBE Statement – checklist of items, and the manuscript was prepared and revised according to the STROBE Statement – checklist of items.

Open-Access: This article is an open-access article that was selected by an in-house editor and fully peer-reviewed by external reviewers. It is distributed in accordance with the Creative Commons Attribution NonCommercial (CC BY-NC 4.0) license, which permits others to distribute, remix, adapt, build upon this work non-commercially, and license their derivative works on different terms, provided the original work is properly cited and the use is non-commercial. See: <https://creativecommons.org/licenses/by-nc/4.0/>

Country/Territory of origin: Ireland

ORCID number: Lianne Pickett 0000-0001-5156-0612; Mary Dunne 0000-0002-3723-6311; Orla Monaghan 0000-0003-2902-528X; Oscar Breathnach 0000-0003-4852-0358; Thomas N Walsh 0000-0002-1600-8029.

S-Editor: Fan JR

L-Editor: Filipodia

P-Editor: Fan JR

REFERENCES

- 1 Verhoef C, van de Weyer R, Schaapveld M, Bastiaannet E, Plukker JT. Better survival in patients with esophageal cancer after surgical treatment in university hospitals: a plea for performance by surgical oncologists. *Ann Surg Oncol* 2007; **14**: 1678-1687 [PMID: 17294070 DOI: 10.1245/s10434-006-9333-0]
- 2 Anderson LA, Tavilla A, Brenner H, Luttman S, Navarro C, Gavin AT, Holleczeck B, Johnston BT, Cook MB, Bannon F, Sant M; EUROCARE-5 Working Group. Survival for oesophageal, stomach and small intestine cancers in Europe 1999-2007: Results from EUROCARE-5. *Eur J Cancer* 2015; **51**: 2144-2157 [PMID: 26421818 DOI: 10.1016/j.ejca.2015.07.026]

- 3 **Rustgi AK**, El-Serag HB. Esophageal carcinoma. *N Engl J Med* 2014; **371**: 2499-2509 [PMID: [25539106](#) DOI: [10.1056/NEJMra1314530](#)]
- 4 **American Cancer Society [Internet]**. Cancer Facts and Statistics. [cited 22 June 2020]. Available from: <https://www.cancer.org/research/cancer-facts-statistics/all-cancer-facts-figures/cancer-facts-figures-2020.html>
- 5 **Jamel S**, Tukanova K, Markar S. Detection and management of oligometastatic disease in oesophageal cancer and identification of prognostic factors: A systematic review. *World J Gastrointest Oncol* 2019; **11**: 741-749 [PMID: [31558978](#) DOI: [10.4251/wjgo.v11.i9.741](#)]
- 6 **Sugiyama M**, Morita M, Yoshida R, Ando K, Egashira A, Takefumi O, Saeki H, Oki E, Kakeji Y, Sakaguchi Y, Maehara Y. Patterns and time of recurrence after complete resection of esophageal cancer. *Surg Today* 2012; **42**: 752-758 [PMID: [22370963](#) DOI: [10.1007/s00595-012-0133-9](#)]
- 7 **Mariette C**, Balon JM, Piessen G, Fabre S, Van Seuning I, Triboulet JP. Pattern of recurrence following complete resection of esophageal carcinoma and factors predictive of recurrent disease. *Cancer* 2003; **97**: 1616-1623 [PMID: [12655517](#) DOI: [10.1002/cncr.11228](#)]
- 8 **Knight WRC**, Zylstra J, Van Hemelrijck M, Griffin N, Jacques AET, Maisiey N, Baker CR, Gossage JA, Lagergren J, Davies AR. Patterns of recurrence in oesophageal cancer following oesophagectomy in the era of neoadjuvant chemotherapy. *BJS Open* 2017; **1**: 182-190 [PMID: [29951621](#) DOI: [10.1002/bjs.5.30](#)]
- 9 **Oppedijk V**, van der Gaast A, van Lanschot JJ, van Hagen P, van Os R, van Rij CM, van der Sangen MJ, Beukema JC, Rütten H, Spruit PH, Reinders JG, Richel DJ, van Berge Henegouwen MI, Hulshof MC. Patterns of recurrence after surgery alone versus preoperative chemoradiotherapy and surgery in the CROSS trials. *J Clin Oncol* 2014; **32**: 385-391 [PMID: [24419108](#) DOI: [10.1200/JCO.2013.51.2186](#)]
- 10 **Meguid RA**, Hooker CM, Taylor JT, Kleinberg LR, Cattaneo SM 2nd, Sussman MS, Yang SC, Heitmiller RF, Forastiere AA, Brock MV. Recurrence after neoadjuvant chemoradiation and surgery for esophageal cancer: does the pattern of recurrence differ for patients with complete response and those with partial or no response? *J Thorac Cardiovasc Surg* 2009; **138**: 1309-1317 [PMID: [19931663](#) DOI: [10.1016/j.jtcvs.2009.07.069](#)]
- 11 **van Hagen P**, Hulshof MC, van Lanschot JJ, Steyerberg EW, van Berge Henegouwen MI, Wijnhoven BP, Richel DJ, Nieuwenhuijzen GA, Hospers GA, Bonenkamp JJ, Cuesta MA, Blaisse RJ, Busch OR, ten Kate FJ, Creemers GJ, Punt CJ, Plukker JT, Verheul HM, Spillenaar Bilgen EJ, van Dekken H, van der Sangen MJ, Rozema T, Biermann K, Beukema JC, Piet AH, van Rij CM, Reinders JG, Tilanus HW, van der Gaast A; CROSS Group. Preoperative chemoradiotherapy for esophageal or junctional cancer. *N Engl J Med* 2012; **366**: 2074-2084 [PMID: [22646630](#) DOI: [10.1056/NEJMoa1112088](#)]
- 12 **Bass GA**, Furlong H, O'Sullivan KE, Hennessy TP, Walsh TN. Chemoradiotherapy, with adjuvant surgery for local control, confers a durable survival advantage in adenocarcinoma and squamous cell carcinoma of the oesophagus. *Eur J Cancer* 2014; **50**: 1065-1075 [PMID: [24480403](#) DOI: [10.1016/j.ejca.2013.12.022](#)]
- 13 **Shapiro J**, van Lanschot JJB, Hulshof MCCM, van Hagen P, van Berge Henegouwen MI, Wijnhoven BPL, van Laarhoven HWM, Nieuwenhuijzen GAP, Hospers GAP, Bonenkamp JJ, Cuesta MA, Blaisse RJB, Busch ORC, Ten Kate FJW, Creemers GM, Punt CJA, Plukker JTM, Verheul HMW, Bilgen EJS, van Dekken H, van der Sangen MJC, Rozema T, Biermann K, Beukema JC, Piet AHM, van Rij CM, Reinders JG, Tilanus HW, Steyerberg EW, van der Gaast A; CROSS study group. Neoadjuvant chemoradiotherapy plus surgery versus surgery alone for oesophageal or junctional cancer (CROSS): long-term results of a randomised controlled trial. *Lancet Oncol* 2015; **16**: 1090-1098 [PMID: [26254683](#) DOI: [10.1016/S1470-2045\(15\)00040-6](#)]
- 14 **Eguchi T**, Koda Y, Nakanishi H, Yokoyama H, Ohashi N, Ito Y, Nakayama G, Koike M, Fujiwara M, Nakao A. The effect of chemotherapy against micrometastases and isolated tumor cells in lymph nodes: an in vivo study. *In Vivo* 2008; **22**: 707-712 [PMID: [19180995](#) DOI: [10.1158/1078-0432.ccr-05-1963](#)]
- 15 **Weichselbaum RR**, Hellman S. Oligometastases revisited. *Nat Rev Clin Oncol* 2011; **8**: 378-382 [PMID: [21423255](#) DOI: [10.1038/nrclinonc.2011.44](#)]
- 16 **Niibe Y**, Chang JY. Novel insights of oligometastases and oligo-recurrence and review of the literature. *Pulm Med* 2012; **2012**: 261096 [PMID: [22966429](#) DOI: [10.1155/2012/261096](#)]
- 17 **National Institute for Health and Care Excellence [Internet]**. Colorectal Cancer. NICE Guideline [NG151]. Jan 2020. Updated Dec 2021. [cited 29 May 2022]. Available from: <https://www.nice.org.uk/guidance/ng151>
- 18 **National Comprehensive Cancer Network [Internet]**. NCCN Clinical Practice Guidelines in Oncology. Colon Cancer. Feb 2022. [cited 29 May 2022]. Available from: https://www.nccn.org/professionals/physician_gls/pdf/colon.pdf
- 19 **National Institute for Health and Care Excellence [Internet]**. Oesophago-gastric cancer: assessment and management in adults. NICE Guideline [NG83]. Jan 2018. [cited 29 May 2022]. Available from: <https://www.nice.org.uk/guidance/ng83/chapter/Recommendations#follow-up>
- 20 **Ajani JA**, D'Amico TA, Bentrem DJ, Chao J, Corvera C, Das P, Denlinger CS, Enzinger PC, Fanta P, Farjah F, Gerdes H, Gibson M, Glasgow RE, Hayman JA, Hochwald S, Hofstetter WL, Ilson DH, Jaroszewski D, Johung KL, Keswani RN, Kleinberg LR, Leong S, Ly QP, Matkowskyj KA, McNamara M, Mulcahy MF, Paluri RK, Park H, Perry KA, Pimiento J, Poultsides GA, Roses R, Strong VE, Wiesner G, Willett CG, Wright CD, McMillian NR, Pluchino LA. Esophageal and Esophagogastric Junction Cancers, Version 2.2019, NCCN Clinical Practice Guidelines in Oncology. *J Natl Compr Canc Netw* 2019; **17**: 855-883 [PMID: [31319389](#) DOI: [10.6004/jncn.2019.0033](#)]
- 21 **O'sullivan GC**, Sheehan D, Clarke A, Stuart R, Kelly J, Kiely MD, Walsh T, Collins JK, Shanahan F. Micrometastases in esophagogastric cancer: high detection rate in resected rib segments. *Gastroenterology* 1999; **116**: 543-548 [PMID: [10029612](#) DOI: [10.1016/s0016-5085\(99\)70175-7](#)]
- 22 **McDonnell CO**, Hill AD, McNamara DA, Walsh TN, Bouchier-Hayes DJ. Tumour micrometastases: the influence of angiogenesis. *Eur J Surg Oncol* 2000; **26**: 105-115 [PMID: [10744927](#) DOI: [10.1053/ejso.1999.0753](#)]
- 23 **Yang YM**, Hong P, Xu WW, He QY, Li B. Advances in targeted therapy for esophageal cancer. *Signal Transduct Target Ther* 2020; **5**: 229 [PMID: [33028804](#) DOI: [10.1038/s41392-020-00323-3](#)]
- 24 **Milano MT**, Katz AW, Schell MC, Philip A, Okunieff P. Descriptive analysis of oligometastatic lesions treated with curative-intent stereotactic body radiotherapy. *Int J Radiat Oncol Biol Phys* 2008; **72**: 1516-1522 [PMID: [18495378](#) DOI: [10.1016/j.ijrobp.2008.03.044](#)]

- 25 **Schizas D**, Lazaridis II, Moris D, Mastoraki A, Lazaridis LD, Tsilimigras DI, Charalampakis N, Liakakos T. The role of surgical treatment in isolated organ recurrence of esophageal cancer-a systematic review of the literature. *World J Surg Oncol* 2018; **16**: 55 [PMID: [29540179](#) DOI: [10.1186/s12957-018-1357-y](#)]
- 26 **Depypere L**, Lerut T, Moons J, Coosemans W, Decker G, Van Veer H, De Leyn P, Naftoux P. Isolated local recurrence or solitary solid organ metastasis after esophagectomy for cancer is not the end of the road. *Dis Esophagus* 2017; **30**: 1-8 [PMID: [27704661](#) DOI: [10.1111/dote.12508](#)]
- 27 **Fumagalli U**, de Carli S, de Pascale S, Rimassa L, Bignardi M, Rosati R. Adrenal metastases from adenocarcinoma of the esophagogastric junction: adrenalectomy and long-term survival. *Updates Surg* 2010; **62**: 63-67 [PMID: [20845103](#) DOI: [10.1007/s13304-010-0012-0](#)]
- 28 **Saito H**, Shuto K, Ota T, Toma T, Ohira G, Natsume T, Uesato M, Akutsu Y, Kono T, Matsubara H. [A case of long-term survival after resection for postoperative solitary adrenal metastasis from esophageal adenocarcinoma]. *Gan To Kagaku Ryoho* 2010; **37**: 2406-2408 [PMID: [21224588](#)]
- 29 **O'Sullivan KE**, Moriarty AR, Larkin JO, Reynolds JV. Curative surgical management of isolated adrenal recurrence of oesophageal adenocarcinoma. *BMJ Case Rep* 2013; **2013** [PMID: [23632191](#) DOI: [10.1136/bcr-2013-009657](#)]
- 30 **Kanaya N**, Noma K, Okada T, Maeda N, Tanabe S, Sakurama K, Shirakawa Y, Fujiwara T. A case of long-term survival after surgical resection for solitary adrenal recurrence of esophageal squamous carcinoma. *Surg Case Rep* 2017; **3**: 61 [PMID: [28477332](#) DOI: [10.1186/s40792-017-0337-8](#)]
- 31 **Hess KR**, Varadhachary GR, Taylor SH, Wei W, Raber MN, Lenzi R, Abbruzzese JL. Metastatic patterns in adenocarcinoma. *Cancer* 2006; **106**: 1624-1633 [PMID: [16518827](#) DOI: [10.1002/cncr.21778](#)]
- 32 **Howell GM**, Carty SE, Armstrong MJ, Stang MT, McCoy KL, Bartlett DL, Yip L. Outcome and prognostic factors after adrenalectomy for patients with distant adrenal metastasis. *Ann Surg Oncol* 2013; **20**: 3491-3496 [PMID: [23793361](#) DOI: [10.1245/s10434-013-3050-2](#)]
- 33 **Seesing MFJ**, van der Veen A, Brenkman HJF, Stockmann HBAC, Nieuwenhuijzen GAP, Rosman C, van den Wildenberg FJH, van Berge Henegouwen MI, van Duijvendijk P, Wijnhoven BPL, Stoot JHMB, Lacle M, Ruurda JP, van Hillegersberg R; Gastroesophageal Metastasectomy Group. Resection of hepatic and pulmonary metastasis from metastatic esophageal and gastric cancer: a nationwide study. *Dis Esophagus* 2019; **32** [PMID: [31220859](#) DOI: [10.1093/dote/doz034](#)]
- 34 **Liu J**, Wei Z, Wang Y, Xia Z, Zhao G. Hepatic resection for post-operative solitary liver metastasis from oesophageal squamous cell carcinoma. *ANZ J Surg* 2018; **88**: E252-E256 [PMID: [27764891](#) DOI: [10.1111/ans.13810](#)]
- 35 **Zhang R**, Zou J, Li P, Li Q, Qiao Y, Han J, Huang K, Ruan P, Lin H, Song Q, Fu Z. Surgery to the primary tumor is associated with improved survival of patients with metastatic esophageal cancer: propensity score-matched analyses of a large retrospective cohort. *Dis Esophagus* 2020; **33** [PMID: [31175353](#) DOI: [10.1093/dote/doz051](#)]
- 36 **Mohamed A**, El-Rayes B, Khuri FR, Saba NF. Targeted therapies in metastatic esophageal cancer: advances over the past decade. *Crit Rev Oncol Hematol* 2014; **91**: 186-196 [PMID: [24582516](#) DOI: [10.1016/j.critrevonc.2014.01.010](#)]
- 37 **Ajani JA**, Ilson DH, Daugherty K, Pazdur R, Lynch PM, Kelsen DP. Activity of taxol in patients with squamous cell carcinoma and adenocarcinoma of the esophagus. *J Natl Cancer Inst* 1994; **86**: 1086-1091 [PMID: [7912736](#) DOI: [10.1093/jnci/86.14.1086](#)]
- 38 **Parry K**, Visser E, van Rossum PS, Mohammad NH, Ruurda JP, van Hillegersberg R. Prognosis and Treatment After Diagnosis of Recurrent Esophageal Carcinoma Following Esophagectomy with Curative Intent. *Ann Surg Oncol* 2015; **22** Suppl 3: S1292-S1300 [PMID: [26334295](#) DOI: [10.1245/s10434-015-4840-5](#)]
- 39 **Welsh J**, Amini A, Likhacheva A, Erasmus J J, Gomez D, Davila M, Mehran RJ, Komaki R, Liao Z, Hofstetter WL, Lee H J, Bhutani MS, Ajani JA. Update: modern approaches to the treatment of localized esophageal cancer. *Curr Oncol Rep* 2011; **13**: 157-167 [PMID: [21365188](#) DOI: [10.1007/s11912-011-0158-z](#)]
- 40 **Sachdeva S**, Jain A, Dalal A, Puri AS. Primary Esophageal Lymphoma: A Rare Entity. *GE Port J Gastroenterol* 2021 [DOI: [10.1159/000515840](#)]
- 41 **Jang BS**, Kim HJ, Kim BH, Kim DW, Kim YT, Kim YW, Jang MJ, Wu HG. Clinical outcomes of stereotactic ablative radiotherapy in patients with pulmonary metastasis. *Jpn J Clin Oncol* 2017; **47**: 61-66 [PMID: [28122893](#) DOI: [10.1093/jcco/hyw147](#)]
- 42 **Li B**, Wang R, Zhang T, Sun X, Jiang C, Li W, Zou B, Xie P, Meng X, Wang L, Yu J. Development and validation of a nomogram prognostic model for esophageal cancer patients with oligometastases. *Sci Rep* 2020; **10**: 11259 [PMID: [32647289](#) DOI: [10.1038/s41598-020-68160-6](#)]
- 43 **Ryan P**, Furlong H, Murphy CG, O'Sullivan F, Walsh TN, Shanahan F, O'Sullivan GC. Prognostic significance of prospectively detected bone marrow micrometastases in esophagogastric cancer: 10-year follow-up confirms prognostic significance. *Cancer Med* 2015; **4**: 1281-1288 [PMID: [25914238](#) DOI: [10.1002/cam4.470](#)]
- 44 **Kelly RJ**, Ajani JA, Kuzdzal J, Zander T, Van Cutsem E, Piessen G, Mendez G, Feliciano J, Motoyama S, Lièvre A, Uronis H, Elimova E, Grootscholten C, Geboes K, Zafar S, Snow S, Ko AH, Feeney K, Schenker M, Kocon P, Zhang J, Zhu L, Lei M, Singh P, Kondo K, Cleary JM, Moehler M; CheckMate 577 Investigators. Adjuvant Nivolumab in Resected Esophageal or Gastroesophageal Junction Cancer. *N Engl J Med* 2021; **384**: 1191-1203 [PMID: [33789008](#) DOI: [10.1056/NEJMoa2032125](#)]



Published by **Baishideng Publishing Group Inc**
7041 Koll Center Parkway, Suite 160, Pleasanton, CA 94566, USA

Telephone: +1-925-3991568

E-mail: bpgoffice@wjgnet.com

Help Desk: <https://www.f6publishing.com/helpdesk>

<https://www.wjgnet.com>

