

World Journal of *Gastrointestinal Surgery*

World J Gastrointest Surg 2023 January 27; 15(1): 1-120



Contents

Monthly Volume 15 Number 1 January 27, 2023

OPINION REVIEW

- 1 Hereditary polyposis syndromes remain a challenging disease entity: Old dilemmas and new insights
Pachler FR, Byrjalsen A, Karstensen JG, Jelsig AM

MINIREVIEWS

- 9 Application of ablative therapy for intrahepatic recurrent hepatocellular carcinoma following hepatectomy
Cong R, Ma XH, Wang S, Feng B, Cai W, Chen ZW, Zhao XM
- 19 Postoperative adjuvant therapy for hepatocellular carcinoma with microvascular invasion
Li J, Yang F, Li J, Huang ZY, Cheng Q, Zhang EL

ORIGINAL ARTICLE

Retrospective Cohort Study

- 32 Prognostic effect of excessive chemotherapy cycles for stage II and III gastric cancer patients after D2 + gastrectomy
Li YF, Zhang WB, Gao YY

Retrospective Study

- 49 Development and validation of a novel nomogram for predicting overall survival in gastric cancer based on inflammatory markers
Luo PQ, Song ED, Liu F, Rankine AN, Zhang LX, Wei ZJ, Han WX, Xu AM
- 60 New perspectives on robotic pancreaticoduodenectomy: An analysis of the National Cancer Database
Kalabin A, Mani VR, Kruse RL, Schlesselman C, Li KY, Staveley-O'Carroll KF, Kimchi ET
- 72 Impact of body mass index in elderly patients treated with laparoscopic liver resection for hepatocellular carcinoma
Conticchio M, Inchingolo R, Delvecchio A, Ratti F, Gelli M, Anelli MF, Laurent A, Vitali GC, Magistri P, Assirati G, Felli E, Wakabayashi T, Pessaux P, Piardi T, di Benedetto F, de'Angelis N, Briceño J, Rampoldi A, Adam R, Cherqui D, Aldrighetti LA, Memeo R
- 82 Effects of postoperative use of proton pump inhibitors on gastrointestinal bleeding after endoscopic variceal treatment during hospitalization
Zhang YY, Wang L, Shao XD, Zhang YG, Ma SZ, Peng MY, Xu SX, Yin Y, Guo XZ, Qi XS
- 94 Associate factors for endoscopic submucosal dissection operation time and postoperative delayed hemorrhage of early gastric cancer
Cai RS, Yang WZ, Cui GR

Clinical Trials Study

- 105** Short-term efficacy assessment of transarterial chemoembolization combined with radioactive iodine therapy in primary hepatocellular carcinoma

Wang L, Huang K, Zhang Y, Wu YF, Yue ZD, Fan ZH, Liu FQ, Li YW, Dong J

CASE REPORT

- 114** Intestinal erosion caused by meshoma displacement: A case report

Wu JF, Chen J, Hong F

ABOUT COVER

Editorial Board Member of *World Journal of Gastrointestinal Surgery*, Abdul-Wahed Meshikhes, MBChB (Dublin), FRCS (Gen Surg), Senior Consultant Surgeon, Department of Surgery, Alzahra General Hospital, Qatif 31911, Saudi Arabia. meshikhes@gmail.com

AIMS AND SCOPE

The primary aim of *World Journal of Gastrointestinal Surgery* (WJGS, *World J Gastrointest Surg*) is to provide scholars and readers from various fields of gastrointestinal surgery with a platform to publish high-quality basic and clinical research articles and communicate their research findings online.

WJGS mainly publishes articles reporting research results and findings obtained in the field of gastrointestinal surgery and covering a wide range of topics including biliary tract surgical procedures, biliopancreatic diversion, colectomy, esophagectomy, esophagostomy, pancreas transplantation, and pancreatectomy, etc.

INDEXING/ABSTRACTING

The WJGS is now abstracted and indexed in Science Citation Index Expanded (SCIE, also known as SciSearch®), Current Contents/Clinical Medicine, Journal Citation Reports/Science Edition, PubMed, PubMed Central, Reference Citation Analysis, China National Knowledge Infrastructure, China Science and Technology Journal Database, and Superstar Journals Database. The 2022 Edition of Journal Citation Reports® cites the 2021 impact factor (IF) for WJGS as 2.505; IF without journal self cites: 2.473; 5-year IF: 3.099; Journal Citation Indicator: 0.49; Ranking: 104 among 211 journals in surgery; Quartile category: Q2; Ranking: 81 among 93 journals in gastroenterology and hepatology; and Quartile category: Q4.

RESPONSIBLE EDITORS FOR THIS ISSUE

Production Editor: Rui-Rui Wu; Production Department Director: Xiang Li; Editorial Office Director: Jia-Ru Fan.

NAME OF JOURNAL

World Journal of Gastrointestinal Surgery

ISSN

ISSN 1948-9366 (online)

LAUNCH DATE

November 30, 2009

FREQUENCY

Monthly

EDITORS-IN-CHIEF

Peter Schemmer

EDITORIAL BOARD MEMBERS

<https://www.wjgnet.com/1948-9366/editorialboard.htm>

PUBLICATION DATE

January 27, 2023

COPYRIGHT

© 2023 Baishideng Publishing Group Inc

INSTRUCTIONS TO AUTHORS

<https://www.wjgnet.com/bpg/gerinfo/204>

GUIDELINES FOR ETHICS DOCUMENTS

<https://www.wjgnet.com/bpg/GerInfo/287>

GUIDELINES FOR NON-NATIVE SPEAKERS OF ENGLISH

<https://www.wjgnet.com/bpg/gerinfo/240>

PUBLICATION ETHICS

<https://www.wjgnet.com/bpg/GerInfo/288>

PUBLICATION MISCONDUCT

<https://www.wjgnet.com/bpg/gerinfo/208>

ARTICLE PROCESSING CHARGE

<https://www.wjgnet.com/bpg/gerinfo/242>

STEPS FOR SUBMITTING MANUSCRIPTS

<https://www.wjgnet.com/bpg/GerInfo/239>

ONLINE SUBMISSION

<https://www.f6publishing.com>



Hereditary polyposis syndromes remain a challenging disease entity: Old dilemmas and new insights

Frederik Rønne Pachler, Anna Byrjalsen, John Gásdal Karstensen, Anne Marie Jelsig

Specialty type: Gastroenterology and hepatology

Provenance and peer review: Invited article; Externally peer reviewed

Peer-review model: Single blind

Peer-review report's scientific quality classification

Grade A (Excellent): 0
Grade B (Very good): 0
Grade C (Good): C
Grade D (Fair): D
Grade E (Poor): 0

P-Reviewer: Vietri MT, Italy; Yuan Y, China

Received: October 9, 2022

Peer-review started: October 9, 2022

First decision: November 3, 2022

Revised: November 18, 2022

Accepted: January 3, 2023

Article in press: January 3, 2023

Published online: January 27, 2023



Frederik Rønne Pachler, John Gásdal Karstensen, Danish Polyposis Registry, Gastrounit, Copenhagen University Hospital - Amager and Hvidovre Hospital, Hvidovre 2650, Denmark

Anna Byrjalsen, Anne Marie Jelsig, Department of Clinical Genetics, University Hospital of Copenhagen, Rigshospitalet, Copenhagen 2100, Denmark

John Gásdal Karstensen, Department of Clinical Medicine, University of Copenhagen, Hvidovre 2650, Denmark

Corresponding author: Frederik Rønne Pachler, MD, PhD, Surgeon, Danish Polyposis Registry, Gastrounit, Copenhagen University Hospital - Amager and Hvidovre Hospital, Kettegård Allé 30, Hvidovre 2650, Denmark. frederik.roenne.pachler.01@regionh.dk

Abstract

In this editorial we present an overview and insights of the management of hereditary polyposis syndromes. The primary focus was on familial adenomatous polyposis, juvenile polyposis syndrome and Peutz-Jegher syndrome. Genetic testing has become increasingly available and is easier than ever to integrate into clinical practice. Furthermore, several genes have been added to the expanding list of genes associated with hereditary polyposis syndromes, allowing for precise diagnostics and tailored follow-up. Endoscopic evaluation of patients with hereditary polyposis syndromes is paramount in the surveillance strategies. Current endoscopic procedures include both diagnostic procedures and surveillance as well as therapeutic interventions. Recommendations for endoscopic procedures in the upper and lower gastrointestinal canal were described. Surgery is still a key component in the management of patients with hereditary polyposis syndromes. The increased cancer risk in these patients often render prophylactic procedures or intended curative procedures in the case of cancer development. Surgical interventions in the upper and lower gastrointestinal canal were described with relevant considerations. Development of chemopreventive medications is ongoing. Few drugs have been investigated, including nonsteroidal anti-inflammatory drugs. It has been demonstrated that cyclooxygenase-2 inhibitors may lower the number of polyps. Other medications are currently under investigation, but none have, to date, consistently been able to prevent development of disease.

Key Words: Hereditary polyposis; Familial adenomatous polyposis; Juvenile polyposis syndrome; Peutz-Jegher syndrome

Core Tip: Genetic technologies and testing have evolved immensely over the past decades allowing for tailored surveillance of patients with hereditary polyposis syndromes. These include endoscopic follow-up and surgery when endoscopic management is no longer possible. Chemopreventive drugs may serve as a cornerstone in future management, but it has yet to show consistent prevention of disease progression.

Citation: Pachler FR, Byrjalsen A, Karstensen JG, Jelsig AM. Hereditary polyposis syndromes remain a challenging disease entity: Old dilemmas and new insights. *World J Gastrointest Surg* 2023; 15(1): 1-8

URL: <https://www.wjgnet.com/1948-9366/full/v15/i1/1.htm>

DOI: <https://dx.doi.org/10.4240/wjgs.v15.i1.1>

INTRODUCTION

It is estimated that gastrointestinal (GI) polyps develop in 40%-50% of the population, and risk factors include increasing age, male sex, smoking, and meat consumption[1-4]. The management of one or a few polyps is in many cases straight forward. The polyp is removed, and the histopathology, localization, number, and size guide the need for endoscopic follow-up. However, when multiple or rare types of polyps are detected or when a polyp is detected in young patients, the clinical work-up is less straightforward. In those cases, it may be relevant to consider whether the patient has a hereditary polyposis syndrome. It is important to distinguish polyposis syndromes from spontaneous polyps, as individuals with polyposis syndromes often have a considerable risk of GI cancer. Further, these patients may also have an increased risk of extraintestinal cancer and sometimes other manifestations that may contribute to increased morbidity and mortality[5-7]. Furthermore, first degree relatives may be at risk, as many syndromes are inherited through an autosomal dominant or recessive inheritance pattern.

Clear recommendations for suspecting a polyposis syndrome are difficult to decide upon. The syndromes present with considerable intra- and interfamilial variability, and many patients only have a few polyps and a negative family history. In this paper familial adenomatous polyposis (FAP), juvenile polyposis syndrome (JPS) and Peutz-Jegher syndrome (PJS) were described, as these are the most common.

GENETIC REVOLUTION

Some of the polyposis syndromes have been known for over a century as clinical and hereditary entities (Figure 1). Knowledge of the underlying genetic cause of the syndromes increased when it became possible to investigate variants in the human genome. The first generation of sequencing methods, Sanger sequencing, was developed and commercialized in the 1970s and 1980s. This technique represented a revolution in genetic technology and made it possible to integrate genetic testing in clinical diagnostics[8,9]. Some genes associated with polyposis were discovered in the 1990s and early 2000s, including adenomatous polyposis coli (APC) associated with FAP, *mutY* homologue, *STK11*, type 1A bone morphogenetic protein receptor (*BMPRIA*) and axis inhibition protein 2 (Figure 1). However, Sanger sequencing is time-consuming and expensive, and it was not until the second (next) generation sequencing methods were developed that further polyposis genes were detected. Next generation sequencing is a form of parallel sequencing that was integrated in clinical practice around 2010. It facilitated fast and cheap sequencing of several genes simultaneously. Thus, genes such as polymerase-epsilon (*POLE*), polymerase delta 1 (*POLD1*), and *NTHL1* have been added as causative of hereditary polyposis[10,11] (Figure 1).

EXPANDING THE PHENOTYPE

The increased knowledge of genetic causes has revealed that several polyposis syndromes have a phenotypic overlap and that at least in the GI tract they mimic each other. Thus, patients with adenomatous polyposis do not always have FAP but may have other rarer syndromes including a polymerase proofreading-associated syndrome where pathogenic variants are detected in the exonuclease domain of *POLE* and *POLD1* or *NTHL1*-related polyposis[12,13]. Concerning hamartomatous polyposis syndrome, JPS is sometimes misdiagnosed because juvenile polyps are mistaken for

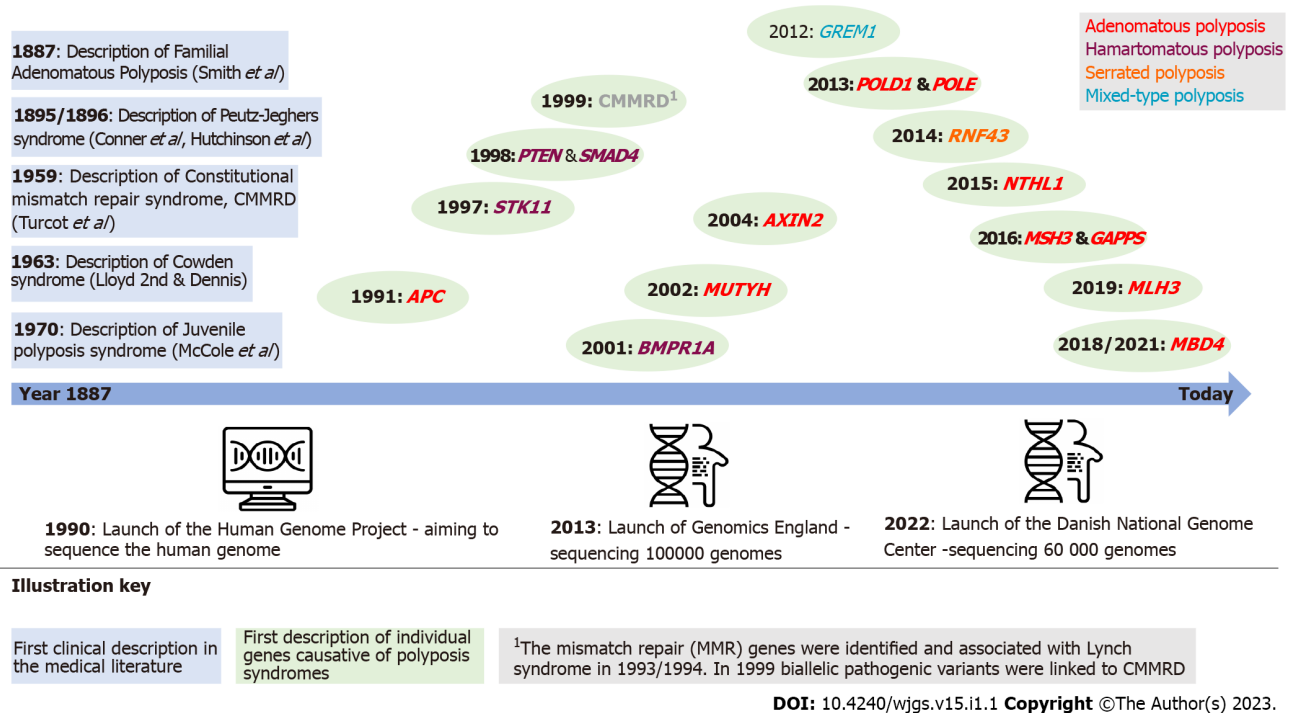


Figure 1 Timeline of hereditary polyposis syndromes and identification of causative gene. *APC*: Adenomatous polyposis coli; *AXIN2*: Axis inhibition protein 2; *BMPR1A*: Type IA bone morphogenetic protein receptor; *CMMRD*: Constitutional mismatch repair deficiency; *POLD1*: Polymerase delta 1; *POLE*: Polymerase-epsilon; *MLH3*: MutL homolog; *MUTYH*: MutY homologue; *RNF43*: Ring finger 43.

inflammatory polyps[14]. Furthermore, a mixture of polyps with different histopathology sometimes blurs the clinical picture, *e.g.*, in *PTEN*-hamartoma tumor syndrome (Cowden syndrome, Figure 2) where adenomas and inflammatory, hyperplastic and juvenile polyps can be present[15]. Purely based on clinical manifestations it is often impossible to tell one polyposis syndrome from the other.

It is important to know the genetic subtype, as the risk profile of the patient is different from syndrome to syndrome. The risk of extraintestinal cancer differs with the subtype, *e.g.*, a patient with *NTHL1*-related polyposis has in addition to the risk of colorectal cancer an increased risk of breast and uterine cancer (Table 1). Accordingly, the surveillance strategies should be tailored. Genetic analysis should be integrated in the diagnostic work-up and should comprise a gene panel with polyposis-associated genes as seen in Table 1. Genetic analysis should be carefully interpreted, and if a pathogenic variant is detected, genetic counseling is recommended.

Some efforts have been made to clarify a possible genotype-phenotype correlation especially in the most well-known syndromes like FAP and PJS[16,17]. However, these studies are limited by the small number of patients. Furthermore, the underlying mechanisms that drive cancer development in several of the polyposis syndromes are largely unknown, especially in the hamartomatous polyposis syndromes. A hamartoma-adenoma-carcinoma sequence has been proposed but has yet to be confirmed [18]. It is believed that cancer development in FAP follows the adenoma-carcinoma sequence caused by dysregulation of the Wnt/ β -catenin pathway[19]. However, more knowledge on the details of the pathophysiology is necessary to understand the background for polyposis and (extra)intestinal cancer.

SURGICAL MANAGEMENT OF HEREDITARY POLYPOSIS

When a patient is diagnosed or suspected of having a hereditary polyposis syndrome, the primary management include an endoscopic baseline examination with histopathological evaluation of polyps as well as a physical examination with focus on extraintestinal manifestations as seen in the polyposis syndrome[20] (Table 1). There is a phenotypic overlap, as polyposis for most of the syndromes (PJS excluded) is primarily located in the large intestine. *SMAD4*-related JPS and FAP often have polyposis in the upper GI tract (gastric and duodenal polyps, respectively). It is common for all syndromes that when endoscopic management is no longer sufficient then surgical resection is the treatment of choice. Several guidelines have been published on recommended surveillance. However, the evidence level is often low due to a limited number of patients and lack of long-term follow-up studies evaluating different surveillance protocols[20-24].

Table 1 Hereditary polyposis syndromes

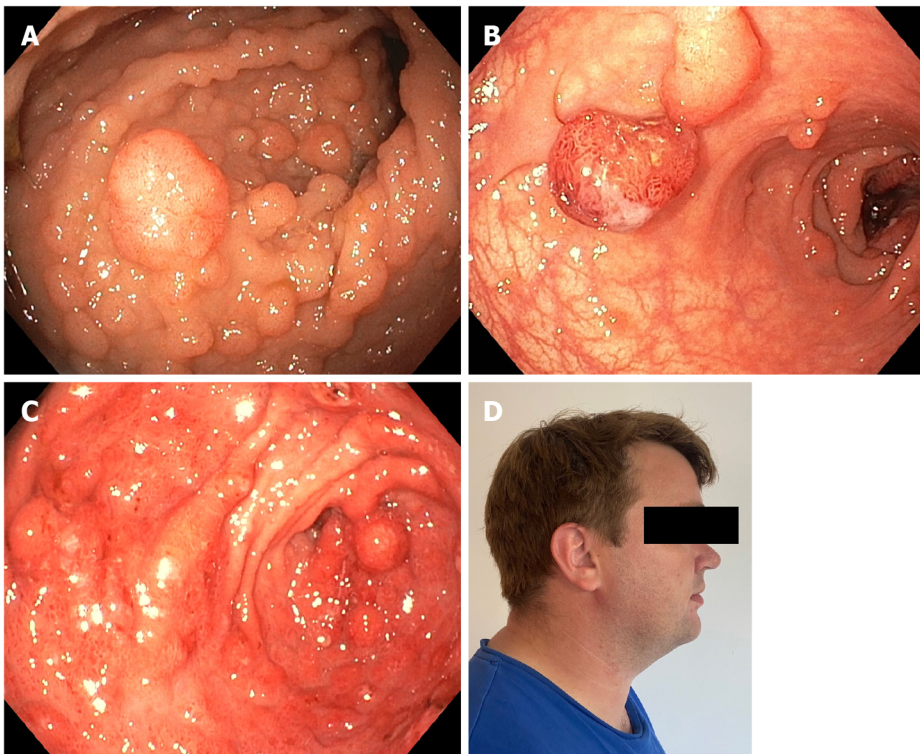
Gene (clinical entity)	Inheritance	Cancer risk	Extraintestinal manifestations
Adenomatous polyposis			
<i>APC</i> (familial adenomatous polyposis)	Autosomal dominant	Colon, rectum, thyroid, gastric, hepato-blastoma	Osteomas, dental anomalies, desmoid tumors, epidermoid cysts, CHRPE
<i>AXIN2</i> (oligodontia-colorectal cancer syndrome)	-	Colon, rectum	Tooth agenesis
<i>POLD1</i> (polymerase proofreading-associated polyposis)	-	Colon, rectum, uterus, breast, bladder, brain	
<i>POLE</i> (polymerase proofreading-associated polyposis)	-	Colon, rectum, uterus, duodenal, ovary	
<i>MBD4</i> (<i>MBD4</i> -associated neoplasia syndrome)	Autosomal recessive	Colon, rectum, myelodysplastic syndrome, acute myeloid leukemia	
<i>MLH1</i> , <i>MSH2</i> , <i>MSH6</i> , <i>PMS2</i> (constitutional mismatch repair syndrome)	-	Colon, rectum, hematologic, brain	Café-au-lait spots, neurofibromas
<i>MLH3</i> (<i>MLH3</i> -related polyposis)	-	Uncertain; potentially colon, rectum, gastric, brain, breast	
<i>MSH3</i> (<i>MSH3</i> -related polyposis)	-	Uncertain; potentially colon, rectum, gastric, brain, breast	
<i>MUTYH</i> (<i>MUTYH</i> -associated polyposis)	-	Colon, rectum, ovary, bladder, breast, uterus, gastric, pancreas, skin	
<i>NTHL1</i> (<i>NTHL1</i> tumor syndrome)	-	Colon, rectum, breast, duodenum, uterus	
Hamartomatous polyposis			
<i>BMPRI1A</i> (juvenile polyposis syndrome)	Autosomal dominant	Colon, rectum	
<i>PTEN</i> (<i>PTEN</i> hamartoma tumor syndrome)	-	Colon, rectum, thyroid, breast, kidney, uterus	Macrocephaly, trichilemmomas, autism, hemangiomas, arteriovenous malformations
<i>SMAD4</i> (juvenile polyposis syndrome)	-	Colon, rectum, gastric	HHT, thoracic aneurysm
<i>STK11</i> (Peutz-Jeghers syndrome)	-	Colon, rectum, duodenum, breast, ovary, pancreas, gastric, cervical	Mucocutaneous pigmentation
Serrated polyposis			
<i>RNF43</i> (serrated polyposis syndrome) ¹	Autosomal dominant	Colon, rectum	
Mixed-type polyposis			
<i>GREM1</i> (hereditary mixed polyposis syndrome)	Autosomal dominant	Colon, rectum	

¹Ring finger 43 only accounts for a fraction of serrated polyposis syndromes.*APC*: Adenomatous polyposis coli; *AXIN2*: Axis inhibition protein 2; *BMPRI1A*: Type IA bone morphogenetic protein receptor; CHRPE: Multifocal/bilateral congenital hypertrophy of the retinal pigment epithelium; HHT: Hereditary hemorrhagic telangiectasia; *MLH*: MutL homolog; *MSH*: MutS homolog; *MUTYH*: MutY homologue; *POLD1*: Polymerase delta 1; *POLE*: Polymerase-epsilon; *RNF43*: Ring finger 43.

LOWER GI ENDOSCOPY AND SURGERY

Virtually all patients with polyposis syndromes undergo colonoscopy surveillance. The appropriate intervals and recommended age to initiate surveillance are debated. It is widely recommended that individuals with FAP are examined annually or biannually from the early teenage years[20,24]. Development of cancer in patients with FAP is extremely rare before the age of 15[20,24-26], and it could be argued that endoscopic examinations should not start earlier than this.

During colonoscopy investigation, the use of chromoendoscopy, either direct or virtual with narrow band imaging, is often used. Narrow band imaging has not been shown to increase detection of neoplastic polyps, but it is a helpful tool in skilled hands[27]. In patients with FAP a prophylactic colectomy is often indicated as most FAP patients will develop adenomatous lesions (Figure 2), and endoscopic surveillance is insufficient[20,24,26]. However, it is now clear that patients who have a pathogenic variant in *APC* have a very variable phenotype. Some may develop polyps at a later age, and thus family history should always be considered when recommending surveillance and deciding on surgery. Subtotal colectomy with ileorectal anastomosis (IRA) or proctocolectomy, often with the intent



DOI: 10.4240/wjgs.v15.i1.1 Copyright ©The Author(s) 2023.

Figure 2 Polyps and extraintestinal manifestations in patients with hereditary polyposis syndromes. A: Severe colonic adenomatosis in a patient with familial adenomatous polyposis; B: Colonic polyposis in patient with Peutz-Jegher syndrome; C: Severe gastric polyposis in patient with SMAD4-related juvenile polyposis syndrome; D: Patient with Cowden syndrome and macrocephaly.

of restorative proctocolectomy with ileal-pouch anal anastomosis (IPAA), are recommended for patients with FAP[20,23,24,26,28]. Surgery for patients who are known to have FAP from childhood often occur in their late teenage years but may be sooner or later if endoscopic findings dictate it. Surgery before the age of 15 years is not recommended[20,23,24,26,28].

After colectomy endoscopic surveillance annually or biannually is recommended[20,24]. However, it is heavily debated whether patients with IRA and patients with restorative proctocolectomy with IPAA should follow the same intervals. If polyposis progresses during surveillance in patients with IRA, proctectomy, possibly with IPAA, should be considered. This may be the appropriate choice, especially in patients with FAP, in the presence of numerous rectal polyps since excessive resection may lead to functional problems and technical difficulty in future proctectomy[20-22,28,29].

In all cases of colectomy, proctocolectomy with terminal ileostomy is also an appropriate solution. However, most patients undergoing resection are relatively young, and a permanent stoma may impact their quality of life[30]. Hence, it is often desirable to attempt anastomosis with preserved continence, but this should be a subject for discussion and individualization.

In patients with JPS and PJS the initial colonoscopy is usually recommended around the age of 12 years for JPS[20,22,31] and 8-10 years for PJS[22,29,31] and repeated every 2-3 years, although recommendations differ. Patients with JPS or PJS should be offered colectomy, either segmental or subtotal with IRA or restorative proctocolectomy with IPAA if the colorectal polyp burden is too high for endoscopic management or if cancer develops[21,22,29]. A further indication for resection in this population may be severe bleeding from colonic neoplasia[21,22,29] (Figure 2).

UPPER GI ENDOSCOPY AND SURGERY

For some polyposis syndromes, upper GI surveillance is recommended due to a high risk of polyposis and/or cancer. In patients with a pathogenic variant in *APC* associated with FAP, esophagogastroduodenoscopy (EGD) is recommended from 25 years of age. It may be initiated earlier if colonic polyposis is present in the teenage years[20,24]. In recent years, it has become more frequent to perform EGD with a cap-assisted forward viewing endoscope, which has been shown to be safe and visualize the papilla in most patients[32].

It is widely recommended to alter surveillance according to the Spigelman staging of polyps[33,34]. Depending on the EGD findings and histopathological evaluation, total duodenectomy may be relevant in patients with FAP. As a guidance to the timing of duodenectomy, the Spigelman classification may

used[20,24]. Duodenectomy is recommended in patients with stage IV or evidence of cancer[20,24].

In some cases, it is recommended to perform a pancreas preserving total duodenectomy, which facilitates an easier endoscopic surveillance compared to post-Whipple procedure. It is proposed that EGD screening in patients with JPS should start in the early teenage years and be repeated every 2-3 years[20,22]. Several upper GI resections may be relevant in patients with JPS, especially those who have a pathogenic variant in *SMAD4* since they have a higher risk of gastric polyposis and gastric cancer compared to JPS and pathogenic variants in *BMPR1A*[14]. In the case of development of numerous and/or very large gastric polyps, partial or total gastrectomy is advised[21,22,29].

In patients with PJS, initial EGD is recommended at the same time as the initial colonoscopy, usually at age 8-10[20-22,29]. The repeat interval should be based on endoscopic findings, but due to the increasing risk of polyposis with age, the interval should at minimum be every 2-3 years[20-22,29] (Figure 2). Upper GI resections in patients with PJS should in general be segmental, although indications should be made with some restraint[21,22,29]. It is recommended to perform the smallest possible, oncologically safe resection to prevent the risk of short bowel syndrome. Indications include suspicious lesions, repeated symptomatic bleeding and obstruction or intussusception caused by polyps[21,22,29]. Small bowel resection in patients with JPS follow the same recommendations. It is advised to perform intraoperative enteroscopy when performing small bowel resections to evaluate the extent of polyposis.

OTHER ENDOSCOPIC PROCEDURES

In PJS, polyps mainly develop in the in the small bowel, and invagination is a frequent first symptom [21,22,29]. It is usually recommended that patients with PJS undergo a baseline video capsule endoscopy at the beginning of endoscopic screening[21,22,29]. Intervals for video capsule endoscopy should depend on the endoscopic findings.

CONCLUSION

As more and more families are identified and genetic testing is becoming more sophisticated, research into preventing symptomatic disease has increased. In patients with FAP, the primary focus has been on nonsteroidal anti-inflammatory drugs, which have been shown to decrease the number of adenomas. Two agents in particular have been studied: Sulindac and celecoxib. Both have demonstrated a decrease in the amount of colorectal adenomas, but celecoxib also decreases the number of duodenal adenomas [28]. Treatment with nonsteroidal anti-inflammatory drugs inherently has a risk of GI complications, most of which can be managed with protein-protein interaction. Celecoxib, a selective cyclooxygenase-2 inhibitor, has the disadvantage of an increased risk of cardiovascular side effects. Treatment with celecoxib has shown similar results in patients with PJS. Polyps in PJS overexpress cyclooxygenase-2, and the decrease in polyp burden is thought to be due to inhibition of this expression[20]. In addition, some older studies have shown that rapamycin (sirolimus) affects the polyp burden and size in mouse models[35,36]. Further therapeutics are under ongoing investigation and aim to target the involved pathway. In JPS, both *BMPR1A* and *SMAD4* encode proteins working in the transforming growth factor-beta pathway, and as it is also frequently involved in sporadic cancer several attempts have been made to target this[37]. Recommendations as to which patients should use chemoprevention differs, but since no agents have been shown to prevent development of disease, the endoscopic and surgical measures, as described above, should be the primary focus.

FOOTNOTES

Author contributions: Pachler FR and Jelsig AM drafted the manuscript; Pachler FR, Byrjalsen A, Karstensen JG and Jelsig AM provided revisions within their expert fields; Byrjalsen A drew up figures and tables.

Conflict-of-interest statement: Karstensen JG is a consultant for Snipr Biome. Pachler FR, Byrjalsen A and Jelsig AM have no conflicts of interest to declare.

Open-Access: This article is an open-access article that was selected by an in-house editor and fully peer-reviewed by external reviewers. It is distributed in accordance with the Creative Commons Attribution NonCommercial (CC BY-NC 4.0) license, which permits others to distribute, remix, adapt, build upon this work non-commercially, and license their derivative works on different terms, provided the original work is properly cited and the use is non-commercial. See: <https://creativecommons.org/licenses/by-nc/4.0/>

Country/Territory of origin: Denmark

ORCID number: Frederik Rønne Pachler 0000-0001-6941-9617; Anna Byrjalsen 0000-0002-3470-5995; John Gásdal

Karstensen 0000-0001-9333-0399; Anne Marie Jelsig 0000-0002-0916-4517.

S-Editor: Wang JJ

L-Editor: Filipodia

P-Editor: Wang JJ

REFERENCES

- 1 **Bekyarova G**, Apostolova M, Kotzev I. Melatonin protection against burn-induced hepatic injury by down-regulation of nuclear factor kappa B activation. *Int J Immunopathol Pharmacol* 2012; **25**: 591-596 [PMID: 23058009 DOI: 10.5772/30891]
- 2 **McCashland TM**, Brand R, Lyden E, de Garmo P; CORI Research Project. Gender differences in colorectal polyps and tumors. *Am J Gastroenterol* 2001; **96**: 882-886 [PMID: 11280569 DOI: 10.1111/j.1572-0241.2001.03638.x]
- 3 **Vatn MH**, Stalsberg H. The prevalence of polyps of the large intestine in Oslo: an autopsy study. *Cancer* 1982; **49**: 819-825 [PMID: 7055790 DOI: 10.1002/1097-0142(19820215)49:4<819::AID-CNCR2820490435>3.0.CO;2-D]
- 4 **Peipins LA**, Sandler RS. Epidemiology of colorectal adenomas. *Epidemiol Rev* 1994; **16**: 273-297 [PMID: 7713180 DOI: 10.1093/oxfordjournals.epirev.a036154]
- 5 **Valle L**, de Voer RM, Goldberg Y, Sjursen W, Försti A, Ruiz-Ponte C, Caldés T, Garré P, Olsen MF, Nordling M, Castellvi-Bel S, Hemminki K. Update on genetic predisposition to colorectal cancer and polyposis. *Mol Aspects Med* 2019; **69**: 10-26 [PMID: 30862463 DOI: 10.1016/j.mam.2019.03.001]
- 6 **Jelsig AM**, Kjeldsen A, Christensen LL, Bertelsen B, Karstensen JG, Brusgaard K, Tørring PM. Hereditary haemorrhagic telangiectasia in Danish patients with pathogenic variants in SMAD4: a nationwide study. *J Med Genet* 2022 [PMID: 36038259 DOI: 10.1136/jmg-2022-108766]
- 7 **Kidambi TD**, Kohli DR, Samadder NJ, Singh A. Hereditary Polyposis Syndromes. *Curr Treat Options Gastroenterol* 2019; **17**: 650-665 [PMID: 31705372 DOI: 10.1007/s11938-019-00251-4]
- 8 **Sanger F**, Nicklen S, Coulson AR. DNA sequencing with chain-terminating inhibitors. *Proc Natl Acad Sci U S A* 1977; **74**: 5463-5467 [PMID: 271968 DOI: 10.1073/pnas.74.12.5463]
- 9 **Hood LE**, Hunkapiller MW, Smith LM. Automated DNA sequencing and analysis of the human genome. *Genomics* 1987; **1**: 201-212 [PMID: 3328736 DOI: 10.1016/0888-7543(87)90046-2]
- 10 **Bellido F**, Pineda M, Aiza G, Valdés-Mas R, Navarro M, Puente DA, Pons T, González S, Iglesias S, Darder E, Piñol V, Soto JL, Valencia A, Blanco I, Urioste M, Brunet J, Lázaro C, Capellá G, Puente XS, Valle L. POLE and POLD1 mutations in 529 kindred with familial colorectal cancer and/or polyposis: review of reported cases and recommendations for genetic testing and surveillance. *Genet Med* 2016; **18**: 325-332 [PMID: 26133394 DOI: 10.1038/gim.2015.75]
- 11 **Magrin L**, Fanale D, Brando C, Fiorino A, Corsini LR, Sciacchitano R, Filorizzo C, Dimino A, Russo A, Bazan V. POLE, POLD1, and NTHL1: the last but not the least hereditary cancer-predisposing genes. *Oncogene* 2021; **40**: 5893-5901 [PMID: 34363023 DOI: 10.1038/s41388-021-01984-2]
- 12 **Mur P**, García-Mulero S, Del Valle J, Magraner-Pardo L, Vidal A, Pineda M, Cinnirella G, Martín-Ramos E, Pons T, López-Doriga A, Belhadj S, Feliubadaló L, Muñoz-Torres PM, Navarro M, Grau E, Darder E, Llort G, Sanz J, Ramón Y Cajal T, Balmana J, Brunet J, Moreno V, Piulats JM, Matías-Guiu X, Sanz-Pamplona R, Aligué R, Capellá G, Lázaro C, Valle L. Role of POLE and POLD1 in familial cancer. *Genet Med* 2020; **22**: 2089-2100 [PMID: 32792570 DOI: 10.1038/s41436-020-0922-2]
- 13 **Beck SH**, Jelsig AM, Yassin HM, Lindberg LJ, Wadt KAW, Karstensen JG. Intestinal and extraintestinal neoplasms in patients with NTHL1 tumor syndrome: a systematic review. *Fam Cancer* 2022; **21**: 453-462 [PMID: 35292903 DOI: 10.1007/s10689-022-00291-3]
- 14 **Blatter R**, Tschupp B, Aretz S, Bernstein I, Colas C, Evans DG, Genuardi M, Hes FJ, Hüneburg R, Järvinen H, Lalloo F, Moeslein G, Renkonen-Sinisalo L, Resta N, Spier I, Varvara D, Vasen H, Latchford AR, Heinemann K. Disease expression in juvenile polyposis syndrome: a retrospective survey on a cohort of 221 European patients and comparison with a literature-derived cohort of 473 SMAD4/BMPRI1A pathogenic variant carriers. *Genet Med* 2020; **22**: 1524-1532 [PMID: 32398773 DOI: 10.1038/s41436-020-0826-1]
- 15 **Stanich PP**, Owens VL, Sweetser S, Khambatta S, Smyrk TC, Richardson RL, Goetz MP, Patnaik MM. Colonic polyposis and neoplasia in Cowden syndrome. *Mayo Clin Proc* 2011; **86**: 489-492 [PMID: 21628613 DOI: 10.4065/mcp.2010.0816]
- 16 **D'Elia G**, Caliendo G, Casamassimi A, Cioffi M, Molinari AM, Vietri MT. APC and MUTYH Analysis in FAP Patients: A Novel Mutation in APC Gene and Genotype-Phenotype Correlation. *Genes (Basel)* 2018; **9** [PMID: 29954149 DOI: 10.3390/genes9070322]
- 17 **Hearle N**, Schumacher V, Menko FH, Olschwang S, Boardman LA, Gille JJ, Keller JJ, Westerman AM, Scott RJ, Lim W, Trimboth JD, Giardiello FM, Gruber SB, Offerhaus GJ, Rooij FW, Wilson JH, Hansmann A, Möslin G, Royer-Pokora B, Vogel T, Phillips RK, Spigelman AD, Houlston RS. STK11 status and intussusception risk in Peutz-Jeghers syndrome. *J Med Genet* 2006; **43**: e41 [PMID: 16882735 DOI: 10.1136/jmg.2005.040535]
- 18 **Bosman FT**. The hamartoma-adenoma-carcinoma sequence. *J Pathol* 1999; **188**: 1-2 [PMID: 10398131 DOI: 10.1002/(SICI)1096-9896(199905)188:1<1::AID-PATH327>3.0.CO;2-J]
- 19 **Shenoy S**. Genetic risks and familial associations of small bowel carcinoma. *World J Gastrointest Oncol* 2016; **8**: 509-519 [PMID: 27326320 DOI: 10.4251/wjgo.v8.i6.509]
- 20 **Syngal S**, Brand RE, Church JM, Giardiello FM, Hampel HL, Burt RW; American College of Gastroenterology. ACG clinical guideline: Genetic testing and management of hereditary gastrointestinal cancer syndromes. *Am J Gastroenterol* 2015; **110**: 223-62; quiz 263 [PMID: 25645574 DOI: 10.1038/ajg.2014.435]
- 21 **Wagner A**, Aretz S, Auranen A, Bruno MJ, Cavestro GM, Crosbie EJ, Goverde A, Jelsig AM, Latchford A, Leerdam

- MEV, Lepisto A, Puzzono M, Winship I, Zuber V, Möslin G. The Management of Peutz-Jeghers Syndrome: European Hereditary Tumour Group (EHTG) Guideline. *J Clin Med* 2021; **10** [PMID: 33513864 DOI: 10.3390/jcm10030473]
- 22 **Boland CR**, Idos GE, Durno C, Giardiello FM, Anderson JC, Burke CA, Dominitz JA, Gross S, Gupta S, Jacobson BC, Patel SG, Shaikat A, Syngal S, Robertson DJ. Diagnosis and Management of Cancer Risk in the Gastrointestinal Hamartomatous Polyposis Syndromes: Recommendations From the US Multi-Society Task Force on Colorectal Cancer. *Gastroenterology* 2022; **162**: 2063-2085 [PMID: 35487791 DOI: 10.1053/j.gastro.2022.02.021]
- 23 **Kanth P**, Grimmer J, Champine M, Burt R, Samadder NJ. Hereditary Colorectal Polyposis and Cancer Syndromes: A Primer on Diagnosis and Management. *Am J Gastroenterol* 2017; **112**: 1509-1525 [PMID: 28786406 DOI: 10.1038/ajg.2017.212]
- 24 **Herzig D**, Hardiman K, Weiser M, You N, Paquette I, Feingold DL, Steele SR. The American Society of Colon and Rectal Surgeons Clinical Practice Guidelines for the Management of Inherited Polyposis Syndromes. *Dis Colon Rectum* 2017; **60**: 881-894 [PMID: 28796726 DOI: 10.1097/DCR.0000000000000912]
- 25 **Church JM**, McGannon E, Burke C, Clark B. Teenagers with familial adenomatous polyposis: what is their risk for colorectal cancer? *Dis Colon Rectum* 2002; **45**: 887-889 [PMID: 12130875 DOI: 10.1007/s10350-004-6322-x]
- 26 **Karstensen JG**, Burisch J, Pommergaard HC, Aalling L, Højén H, Jespersen N, Schmidt PN, Bülow S. Colorectal Cancer in Individuals With Familial Adenomatous Polyposis, Based on Analysis of the Danish Polyposis Registry. *Clin Gastroenterol Hepatol* 2019; **17**: 2294-2300.e1 [PMID: 30743005 DOI: 10.1016/j.cgh.2019.02.008]
- 27 **Barbeiro S**, Libanio D, Castro R, Dinis-Ribeiro M, Pimentel-Nunes P. Narrow-Band Imaging: Clinical Application in Gastrointestinal Endoscopy. *GE Port J Gastroenterol* 2018; **26**: 40-53 [PMID: 30675503 DOI: 10.1159/000487470]
- 28 **Vasen HF**, Möslin G, Alonso A, Aretz S, Bernstein I, Bertario L, Blanco I, Bülow S, Burn J, Capella G, Colas C, Engel C, Frayling I, Friedl W, Hes FJ, Hodgson S, Järvinen H, Mecklin JP, Möller P, Myrthøi T, Nagengast FM, Parc Y, Phillips R, Clark SK, de Leon MP, Renkonen-Sinisalo L, Sampson JR, Stormorken A, Tejpar S, Thomas HJ, Wijnen J. Guidelines for the clinical management of familial adenomatous polyposis (FAP). *Gut* 2008; **57**: 704-713 [PMID: 18194984 DOI: 10.1136/gut.2007.136127]
- 29 **Beggs AD**, Latchford AR, Vasen HF, Moslein G, Alonso A, Aretz S, Bertario L, Blanco I, Bülow S, Burn J, Capella G, Colas C, Friedl W, Möller P, Hes FJ, Järvinen H, Mecklin JP, Nagengast FM, Parc Y, Phillips RK, Hyer W, Ponz de Leon M, Renkonen-Sinisalo L, Sampson JR, Stormorken A, Tejpar S, Thomas HJ, Wijnen JT, Clark SK, Hodgson SV. Peutz-Jeghers syndrome: a systematic review and recommendations for management. *Gut* 2010; **59**: 975-986 [PMID: 20581245 DOI: 10.1136/gut.2009.198499]
- 30 **Nugent KP**, Daniels P, Stewart B, Patankar R, Johnson CD. Quality of life in stoma patients. *Dis Colon Rectum* 1999; **42**: 1569-1574 [PMID: 10613475 DOI: 10.1007/BF02236209]
- 31 **Jelsig AM**, Karstensen JG, Jespersen N, Ketabi Z, Lautrup C, Rønland K, Sunde L, Wadt K, Thorlacius-Ussing O, Qvist N. Danish guidelines for management of non-APC-associated hereditary polyposis syndromes. *Hered Cancer Clin Pract* 2021; **19**: 41 [PMID: 34620187 DOI: 10.1186/s13053-021-00197-8]
- 32 **Kallenberg FGJ**, Bastiaansen BAJ, Dekker E. Cap-assisted forward-viewing endoscopy to visualize the ampulla of Vater and the duodenum in patients with familial adenomatous polyposis. *Endoscopy* 2017; **49**: 181-185 [PMID: 27760435 DOI: 10.1055/s-0042-118311]
- 33 **Karstensen JG**, Bülow S, Burisch J, Ellebæk MB, Ostapiuk M, Pommergaard HC, Schmidt PN. Validation of the Endoscopic Part of the Spigelman Classification for Evaluating Duodenal Adenomatosis in Familial Adenomatous Polyposis: A Prospective Study of Interrater and Intrarater Reliability. *Am J Gastroenterol* 2022; **117**: 343-345 [PMID: 34913876 DOI: 10.14309/ajg.0000000000001582]
- 34 **Spigelman AD**, Williams CB, Talbot IC, Domizio P, Phillips RK. Upper gastrointestinal cancer in patients with familial adenomatous polyposis. *Lancet* 1989; **2**: 783-785 [PMID: 2571019 DOI: 10.1016/s0140-6736(89)90840-4]
- 35 **Robinson J**, Lai C, Martin A, Nye E, Tomlinson I, Silver A. Oral rapamycin reduces tumour burden and vascularization in Lkb1(+/-) mice. *J Pathol* 2009; **219**: 35-40 [PMID: 19434632 DOI: 10.1002/path.2562]
- 36 **Wei C**, Amos CI, Zhang N, Zhu J, Wang X, Frazier ML. Chemopreventive efficacy of rapamycin on Peutz-Jeghers syndrome in a mouse model. *Cancer Lett* 2009; **277**: 149-154 [PMID: 19147279 DOI: 10.1016/j.canlet.2008.11.036]
- 37 **Gotovac JR**, Fujihara KM, Phillips WA, Clemons NJ. TGF-beta signaling and its targeted therapy in gastrointestinal cancers. *Discov Med* 2018; **26**: 103-112 [PMID: 30399328]



Published by **Baishideng Publishing Group Inc**
7041 Koll Center Parkway, Suite 160, Pleasanton, CA 94566, USA

Telephone: +1-925-3991568

E-mail: bpgoffice@wjgnet.com

Help Desk: <https://www.f6publishing.com/helpdesk>

<https://www.wjgnet.com>

