

World Journal of *Gastrointestinal Surgery*

World J Gastrointest Surg 2023 December 27; 15(12): 2674-2961



Contents

Monthly Volume 15 Number 12 December 27, 2023

REVIEW

- 2674 Antimicrobial approach of abdominal post-surgical infections
Fiore M, Corrente A, Di Franco S, Alfieri A, Pace MC, Martora F, Petrou S, Mauriello C, Leone S

MINIREVIEWS

- 2693 Indocyanine green fluorescence in gastrointestinal surgery: Appraisal of current evidence
Kalayarasan R, Chandrasekar M, Sai Krishna P, Shanmugam D
- 2709 Post-cholecystectomy iatrogenic bile duct injuries: Emerging role for endoscopic management
Emara MH, Ahmed MH, Radwan MI, Emara EH, Basheer M, Ali A, Elfert AA

ORIGINAL ARTICLE

Case Control Study

- 2719 Multidisciplinary diagnosis and treatment nutritional support intervention for gastrointestinal tumor radiotherapy: Impact on nutrition and quality of life
Hui L, Zhang YY, Hu XD

Retrospective Cohort Study

- 2727 Association between the early high level of serum tacrolimus and recurrence of hepatocellular carcinoma in ABO-incompatible liver transplantation
Han JW, Choi JY, Jung ES, Kim JH, Cho HS, Yoo JS, Sung PS, Jang JW, Yoon SK, Choi HJ, You YK
- 2739 Determining the need for a thoracoscopic approach to treat a giant hiatal hernia when abdominal access is poor
Pérez Lara FJ, Zubizarreta Jimenez R, Prieto-Puga Arjona T, Gutierrez Delgado P, Hernández Carmona JM, Hernández Gonzalez JM, Pitarch Martinez M
- 2747 Predictive value of Hajibandeh index in determining peritoneal contamination in acute abdomen: A cohort study and meta-analysis
Hajibandeh S, Hajibandeh S, Evans L, Miller B, Waterman J, Ahmad SJ, Hale J, Higgi A, Johnson B, Pearce D, Helmy AH, Naguib N, Maw A

Retrospective Study

- 2757 Efficacy of pantoprazole plus perforation repair for peptic ulcer and its effect on the stress response
Leng ZY, Wang JH, Gao L, Shi K, Hua HB
- 2765 Application of electroacupuncture in the prevention of low anterior resection syndrome after rectal cancer surgery
Xu LL, Xiang NJ, Cheng TC, Li YX, Chen P, Jiang ZW, Liu XX

- 2774** Effects of remifentanyl combined with propofol on hemodynamics and oxidative stress in patients undergoing resection of rectal carcinoma
Huang J, Tian WJ
- 2783** Percutaneous microwave ablation and transcatheter arterial chemoembolization for serum tumor markers and prognostics of middle-late primary hepatic carcinoma
Lin ZP, Huang DB, Zou XG, Chen Y, Li XQ, Zhang J
- 2792** Novel invagination procedure for pancreaticojejunostomy using double purse string sutures: A technical note
Li J, Niu HY, Meng XK
- 2799** Laparoscopic resection and endoscopic submucosal dissection for treating gastric ectopic pancreas
Zheng HD, Huang QY, Hu YH, Ye K, Xu JH
- 2809** Prediction of the lymphatic, microvascular, and perineural invasion of pancreatic neuroendocrine tumors using preoperative magnetic resonance imaging
Liu YL, Zhu HB, Chen ML, Sun W, Li XT, Sun YS
- 2820** Impact of hepatectomy and postoperative adjuvant transarterial chemoembolization on serum tumor markers and prognosis in intermediate-stage hepatocellular carcinoma
Hu YD, Zhang H, Tan W, Li ZK

Observational Study

- 2831** Analysis of nutritional risk, skeletal muscle depletion, and lipid metabolism phenotype in acute radiation enteritis
Ma CY, Zhao J, Qian KY, Xu Z, Xu XT, Zhou JY

Randomized Controlled Trial

- 2844** Holistic conditions after colon cancer: A randomized controlled trial of systematic holistic care *vs* primary care
Wang J, Qiao JH

Basic Study

- 2855** Mutational separation and clinical outcomes of *TP53* and *CDH1* in gastric cancer
Liu HL, Peng H, Huang CH, Zhou HY, Ge J
- 2866** Hepatic vagotomy blunts liver regeneration after hepatectomy by downregulating the expression of interleukin-22
Zhou H, Xu JL, Huang SX, He Y, He XW, Lu S, Yao B

META-ANALYSIS

- 2879** Recent evidence for subcutaneous drains to prevent surgical site infections after abdominal surgery: A systematic review and meta-analysis
Ishinuki T, Shinkawa H, Kouzu K, Shinji S, Goda E, Ohyanagi T, Kobayashi M, Kobayashi M, Suzuki K, Kitagawa Y, Yamashita C, Mohri Y, Shimizu J, Uchino M, Haji S, Yoshida M, Ohge H, Mayumi T, Mizuguchi T

- 2890** Prognostic role of serum carcinoembryonic antigen in patients receiving liver resection for colorectal cancer liver metastasis: A meta-analysis

Tang F, Huang CW, Tang ZH, Lu SL, Bai T, Huang Q, Li XZ, Zhang B, Wu FX

- 2907** Significance of carcinoembryonic antigen detection in the early diagnosis of colorectal cancer: A systematic review and meta-analysis

Wang R, Wang Q, Li P

CASE REPORT

- 2919** Primary repair of esophageal atresia gross type C *via* thoracoscopic magnetic compression anastomosis: A case report

Zhang HK, Li XQ, Song HX, Liu SQ, Wang FH, Wen J, Xiao M, Yang AP, Duan XF, Gao ZZ, Hu KL, Zhang W, Lv Y, Zhou XH, Cao ZJ

- 2926** Portal vein embolization for closure of marked arteriportal shunt of hepatocellular carcinoma to enable radioembolization: A case report

Wang XD, Ge NJ, Yang YF

- 2932** Removal of a large rectal polyp with endoscopic submucosal dissection-trans-anal rectoscopic assisted minimally invasive surgery hybrid technique: A case report

Polese L

- 2938** Successful treatment of invasive liver abscess syndrome caused by *Klebsiella variicola* with intracranial infection and septic shock: A case report

Zhang PJ, Lu ZH, Cao LJ, Chen H, Sun Y

- 2945** Duodenojejunostomy treatment of groove pancreatitis-induced stenosis and obstruction of the horizontal duodenum: A case report

Zhang Y, Cheng HH, Fan WJ

- 2954** Awake robotic liver surgery: A case report

Delvecchio A, Pavone G, Conticchio M, Piacente C, Varvara M, Ferraro V, Stasi M, Casella A, Filippo R, Tedeschi M, Pullano C, Inchingolo R, Delmonte V, Memeo R

ABOUT COVER

Editorial Board Member of *World Journal of Gastrointestinal Surgery*, Lapo Bencini, PhD, General Surgery Unit, AOUC, Department of Oncology and Robotics, Careggi University Hospital, Florence 350134, Italy. lapbenc@tin.it

AIMS AND SCOPE

The primary aim of *World Journal of Gastrointestinal Surgery* (WJGS, *World J Gastrointest Surg*) is to provide scholars and readers from various fields of gastrointestinal surgery with a platform to publish high-quality basic and clinical research articles and communicate their research findings online.

WJGS mainly publishes articles reporting research results and findings obtained in the field of gastrointestinal surgery and covering a wide range of topics including biliary tract surgical procedures, biliopancreatic diversion, colectomy, esophagectomy, esophagostomy, pancreas transplantation, and pancreatectomy, etc.

INDEXING/ABSTRACTING

The WJGS is now abstracted and indexed in Science Citation Index Expanded (SCIE, also known as SciSearch®), Current Contents/Clinical Medicine, Journal Citation Reports/Science Edition, PubMed, PubMed Central, Reference Citation Analysis, China Science and Technology Journal Database, and Superstar Journals Database. The 2023 Edition of Journal Citation Reports® cites the 2022 impact factor (IF) for WJGS as 2.0; IF without journal self cites: 1.9; 5-year IF: 2.2; Journal Citation Indicator: 0.52; Ranking: 113 among 212 journals in surgery; Quartile category: Q3; Ranking: 81 among 93 journals in gastroenterology and hepatology; and Quartile category: Q4.

RESPONSIBLE EDITORS FOR THIS ISSUE

Production Editor: Rui-Rui Wu, Production Department Director: Xu Guo, Editorial Office Director: Jia-Ru Fan.

NAME OF JOURNAL

World Journal of Gastrointestinal Surgery

ISSN

ISSN 1948-9366 (online)

LAUNCH DATE

November 30, 2009

FREQUENCY

Monthly

EDITORS-IN-CHIEF

Peter Schemmer

EDITORIAL BOARD MEMBERS

<https://www.wjgnet.com/1948-9366/editorialboard.htm>

PUBLICATION DATE

December 27, 2023

COPYRIGHT

© 2023 Baishideng Publishing Group Inc

INSTRUCTIONS TO AUTHORS

<https://www.wjgnet.com/bpg/gerinfo/204>

GUIDELINES FOR ETHICS DOCUMENTS

<https://www.wjgnet.com/bpg/GerInfo/287>

GUIDELINES FOR NON-NATIVE SPEAKERS OF ENGLISH

<https://www.wjgnet.com/bpg/gerinfo/240>

PUBLICATION ETHICS

<https://www.wjgnet.com/bpg/GerInfo/288>

PUBLICATION MISCONDUCT

<https://www.wjgnet.com/bpg/gerinfo/208>

ARTICLE PROCESSING CHARGE

<https://www.wjgnet.com/bpg/gerinfo/242>

STEPS FOR SUBMITTING MANUSCRIPTS

<https://www.wjgnet.com/bpg/GerInfo/239>

ONLINE SUBMISSION

<https://www.f6publishing.com>



Retrospective Study

Efficacy of pantoprazole plus perforation repair for peptic ulcer and its effect on the stress response

Zi-Yan Leng, Jia-Hao Wang, Lei Gao, Ke Shi, Hai-Bing Hua

Specialty type: Gastroenterology and hepatology

Provenance and peer review:

Unsolicited article; Externally peer reviewed.

Peer-review model: Single blind

Peer-review report's scientific quality classification

Grade A (Excellent): 0
Grade B (Very good): B, B
Grade C (Good): C
Grade D (Fair): 0
Grade E (Poor): 0

P-Reviewer: Ermolao A, Italy; Ren-Fielding CJ, United States; Brisinda G, Italy

Received: September 14, 2023

Peer-review started: September 14, 2023

First decision: October 8, 2023

Revised: October 23, 2023

Accepted: November 25, 2023

Article in press: November 25, 2023

Published online: December 27, 2023



Zi-Yan Leng, The Second Hospital of Traditional Chinese Medicine of Jiangsu Province, Affiliated to Nanjing University of Chinese Medicine, Nanjing 210023, Jiangsu Province, China

Jia-Hao Wang, Institute of Literature in Chinese Medicine, Nanjing University of Chinese Medicine, Nanjing 210023, Jiangsu Province, China

Lei Gao, School of Chinese Medicine & School of Integrated, Chinese and Western Medicine, Nanjing University of Chinese Medicine, Nanjing 210023, Jiangsu Province, China

Ke Shi, Hai-Bing Hua, Department of Spleen and Gastroenterology, Jiangyin Hospital Affiliated to Nanjing University of Chinese Medicine, Jiangyin 214400, Jiangsu Province, China

Corresponding author: Hai-Bing Hua, Doctor, Chief Physician, Department of Spleen and Gastroenterology, Jiangyin Hospital Affiliated to Nanjing University of Chinese Medicine, No. 130 Renmin Middle Road, Jiangyin 214400, Jiangsu Province, China. jyhb75@163.com

Abstract

BACKGROUND

Peptic ulcer (PU) is an abnormal phenomenon in which there is rupture of the mucosa of the digestive tract, which not only affects patients' normal life but also causes an economic burden due to its high medical costs.

AIM

To investigate the efficacy of pantoprazole (PPZ) plus perforation repair in patients with PU and its effect on the stress response.

METHODS

The study subjects were 108 PU patients admitted between July 2018 and July 2022, including 58 patients receiving PPZ plus perforation repair [research group (RG)] and 50 patients given simple perforation repair [control group (CG)]. The efficacy, somatostatin (SS) concentration, stress reaction [malondialdehyde (MDA), lipid peroxide (LPO)], inflammatory indices [tumor necrosis factor (TNF)- α , C-reactive protein (CRP), interleukin (IL)-1 β], recurrence, and complications (perforation, hemorrhage, and pyloric obstruction) were compared.

RESULTS

The overall response rate was higher in the RG than in the CG. Patients in the RG

had markedly elevated SS after treatment, which was higher than that of the CG, while MDA, LPO, TNF-, CRP, and IL-1 β were significantly reduced to lower levels than those in the CG. Lower recurrence and complication rates were identified in the RG group.

CONCLUSION

Therefore, PPZ plus perforation repair is conducive to enhancing treatment outcomes in PU patients, reducing oxidative stress injury and excessive inflammatory reactions, and contributing to low recurrence and complication rates.

Key Words: Pantoprazole; Perforation repair; Peptic ulcer; Efficacy; Etreess response

©The Author(s) 2023. Published by Baishideng Publishing Group Inc. All rights reserved.

Core Tip: Peptic ulcer (PU), as a chronic disease, may cause complications such as perforation, upper gastrointestinal bleeding, and rarely gastric outlet obstruction. Risk factors such as advanced age, a history of PU, *Helicobacter pylori* infection, and the use of nonsteroidal anti-inflammatory drugs further increase the risk of developing the disease. To further reduce the associated negative effects of the disease, this study aims to explore and seek new therapeutic models to improve the management of the disease.

Citation: Leng ZY, Wang JH, Gao L, Shi K, Hua HB. Efficacy of pantoprazole plus perforation repair for peptic ulcer and its effect on the stress response. *World J Gastrointest Surg* 2023; 15(12): 2757-2764

URL: <https://www.wjgnet.com/1948-9366/full/v15/i12/2757.htm>

DOI: <https://dx.doi.org/10.4240/wjgs.v15.i12.2757>

INTRODUCTION

Peptic ulcer (PU), as a disease of the digestive system, is essentially a phenomenon of digestive tract mucosal rupture, which mainly appears in the stomach and duodenum[1,2]. The disease may cause complications such as perforation, upper gastrointestinal bleeding, and rarely gastric outlet obstruction, which poses a threat to the health of patients[3,4]. Risk factors for PU include advanced age, history of PU, *Helicobacter pylori* infection, and use of nonsteroidal anti-inflammatory drugs[5]. The disease may lead to gastrointestinal symptoms such as epigastric pain, burping, vomiting and heartburn, hindering the patient's normal life activities and lowering the quality of life[6]. According to statistics, the lifetime risk of PU can be as high as 10%, with at least 4 million people affected by the disease every year, which causes these patients to have high medical costs[7,8]. To reduce the negative effects of PU, this study seeks new modalities of treatment to improve the management of the disease.

Perforation repair, a surgical procedure used to prevent the recurrence of ulcers in PU, has the advantages of minimal invasiveness, low surgical difficulty, low surgical risk and little influence on patients' abdominal organs[9,10]. In the study by Varcus *et al*[11], perforation repair was more effective than open repair in accelerating the recovery of patients with PU perforation and was associated with a lower risk of morbidity and mortality, suggesting that the former has a clinical advantage over the latter in the treatment of PU. Kim *et al*[12] also reported that perforation repair is more beneficial to digestive tract function recovery and can play a therapeutic role in hemodynamically unstable patients while ensuring a good level of safety. Pantoprazole (PPZ), on the other hand, is a proton pump inhibitor that can affect the structure and function of the gastric mucosa and reduce the acid secretion of gastric parietal cells, helping alleviate diseases such as heartburn, gastroesophageal reflux disease and PU[13,14]. In the research of Moayyedi *et al*[15], PPZ had a preventive effect on gastroduodenal bleeding in patients with stable cardiovascular disease and peripheral arterial disease. PPZ, although long-acting, is less available when taken orally than when intravenously injected, so it is often administered intravenously[16].

This study proposes that PPZ plus perforation repair has a better therapeutic effect and clinical application value than perforation repair alone in PU patients, and the results validated this hypothesis.

MATERIALS AND METHODS

Patient data

The eligibility criteria were as follows: A diagnosis of PU[17], first-time treatment for PU, no contraindications to the study medication plans, and complete case data. The exclusion criteria were as follows: Abnormal coagulation function; other gastrointestinal diseases; malignant tumor or severe organ dysfunction; psychiatric disorders or serious infectious diseases; cardiac and renal insufficiency; and pregnancy or lactation. According to the above eligibility and exclusion criteria, 108 PU patients were deemed eligible, whose treatment time was from July 2018 to July 2022. As detailed in

Table 1, the general data, such as sex and age, of the two groups were clinically comparable ($P > 0.05$).

Treatment methods

Perforation repair: Each patient underwent endotracheal intubation for general anesthesia, and pneumoperitoneum was established using the three-hole technique, followed by placement of the remaining sheath catheters. Abdominal exploration was performed to further rule out gastric cancer after drainage of the abdominal fluid and food debris. After feeding 0-3 absorbable surgical sutures through the main operation hole with a needle, the Scanlan needle holder was used to tie a knot in the cavity according to the conventional upper digestive tract perforation repair method. After 2-4 stitches, the fixed part of the omentum was covered at the perforation suture. The epiploic foramen was drained following irrigation of the abdominal cavity, and the abdomen was closed.

Regarding the administration of PPZ, 40 mg of PPZ in 0.9% normal saline was injected as an intravenous drip during postoperative fasting once daily for 3-5 d. PPZ (40 mg) was given twice a day after the initiation of postoperative oral food intake, which was supplemented by colloidal bismuth pectin capsules (100 mg) three times a day, for 6-8 wk.

The research group (RG) received PPZ plus perforation repair, while the control group (CG) received perforation repair alone.

Outcome measures

Efficacy: If the patient's ulcer surface was basically healed with no inflammation around it, it was considered to be cured. A marked response was indicated by the disappearance of the ulcer surface and some inflammation around it. An improvement referred to an ulcer area reduction of less than 50.0%. Nonresponse referred to no change or even worsening of the ulcer surface.

Somatostatin (SS) and stress response: Five milliliters of fasting venous blood was collected in the early morning before and after treatment, and the serum was separated by centrifugation to determine stress-related indices such as SS, malondialdehyde (MDA) and lipid peroxide (LPO) using immunoturbidimetry.

Inflammation indices: Enzyme-linked immunosorbent assays were carried out to measure tumor necrosis factor (TNF)- α , C-reactive protein (CRP) and interleukin (IL)-1 β levels in strict accordance with the kit instructions.

Recurrence: Recurrent cases were counted, from which the recurrence rate was calculated.

Occurrence of complications: We observed and counted the number of patients with complications, such as perforation, bleeding, and pyloric obstruction, and calculated the overall incidence.

Statistical analyses

In this study, both continuous (represented by mean \pm SEM) and categorical variables [denoted by n (%)] were imported into GraphPad Prism 7.0 for statistical analysis and graph drawing. To identify intergroup differences, the t test and the χ^2 test were used for continuous and categorical variables, respectively. All analyses relied upon a $P < 0.05$ statistical significance criterion.

RESULTS

General information

The RG and CG had similar general data, such as sex, age, lesion site, alcohol abuse history, and smoking history ($P > 0.05$, **Table 1**).

Efficacy

The overall response rates of the RG and CG were 89.66% (37 cases) and 74.00% (52 cases), respectively. The above data revealed a markedly higher overall response rate in the RG than in the CG ($P < 0.05$, **Table 2**).

SS, MDA, and LPO

The effects of the two treatment schemes on the stress response of PU patients were evaluated by measuring stress response indices such as SS, MDA and LPO. The above indices were similar between the groups prior to treatment ($P > 0.05$). In both groups, SS was elevated and MDA and LPO were reduced after treatment, but SS was even higher and MDA and LPO were even lower in the RG ($P < 0.05$) (**Figure 1**).

TNF- α , CRP, and IL-1 β

The inflammatory indicators TNF- α , CRP, and IL-1 β were measured to evaluate the effects of the two treatment schemes on inflammation in PU patients. As above, these indices were similar between the groups prior to treatment ($P > 0.05$). An evident reduction was observed in TNF-, CRP, and IL-1 β in both groups after treatment ($P < 0.05$), which were more extreme in the RG *vs* CG ($P < 0.05$, **Figure 2**).

Recurrence

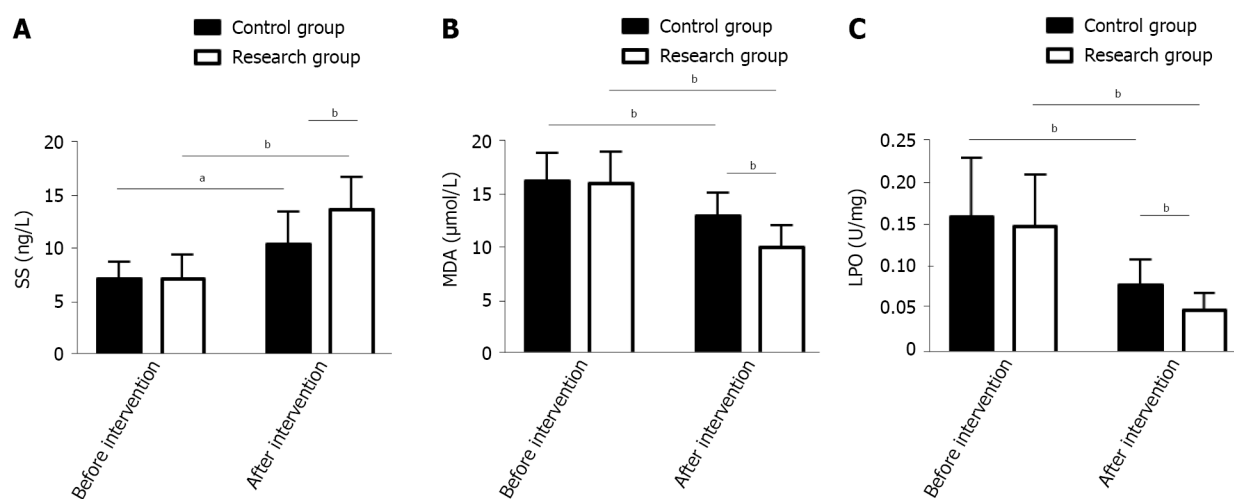
The number of recurrent cases in the RG and CG was 11 (18.97%) and 18 (36.00%), respectively, which was a lower recurrence rate in the RG than in the CG ($P < 0.05$, **Figure 3**).

Table 1 General information of patients with peptic ulcer in the two groups

Indicators	Control group (n = 50)	Research group (n = 58)	χ^2/t	P value
Sex (male/female)	29/21	35/23	0.061	0.805
Age (yr)	49.10 ± 8.08	48.50 ± 7.21		
Perforation site (stomach/duodenum/mixed)	22/20/8	20/27/11	1.025	0.599
History of alcoholism (with/without)	16/34	20/38	0.074	0.785
History of smoking (yes/no)	13/37	13/45	0.189	0.664

Table 2 Therapeutic effects in the two groups of patients with peptic ulcer

Indicators	Control group (n = 50)	Research group (n = 58)	χ^2	P value
Marked response	22 (44.00)	30 (51.72)		
Response	15 (30.00)	22 (37.93)		
Nonresponse	13 (26.00)	6 (10.34)		
Overall response	37 (74.00)	52 (89.66)	4.539	0.033



DOI: 10.4240/wjgs.v15.i12.2757 Copyright ©The Author(s) 2023.

Figure 1 Somatostatin, malondialdehyde and lipid peroxide of patients with peptic ulcer in the two groups. A: Pre- and posttreatment somatostatin levels in the two groups; b: Pre- and posttreatment malondialdehyde levels in the two groups; C: Pre- and posttreatment lipid peroxide levels in the two groups. ^a*P* < 0.05, ^b*P* < 0.01. SS: Somatostatin; MDA: Malondialdehyde; LPO: Lipid peroxide.

Occurrence of complications

Both groups of patients suffered from perforation, bleeding, and pyloric obstruction, with overall incidences of 12.00% and 0.00% in the CG and RG, respectively. When comparing the groups, the overall complication rate was markedly lower in the RG than in the CG (*P* < 0.05, Table 3).

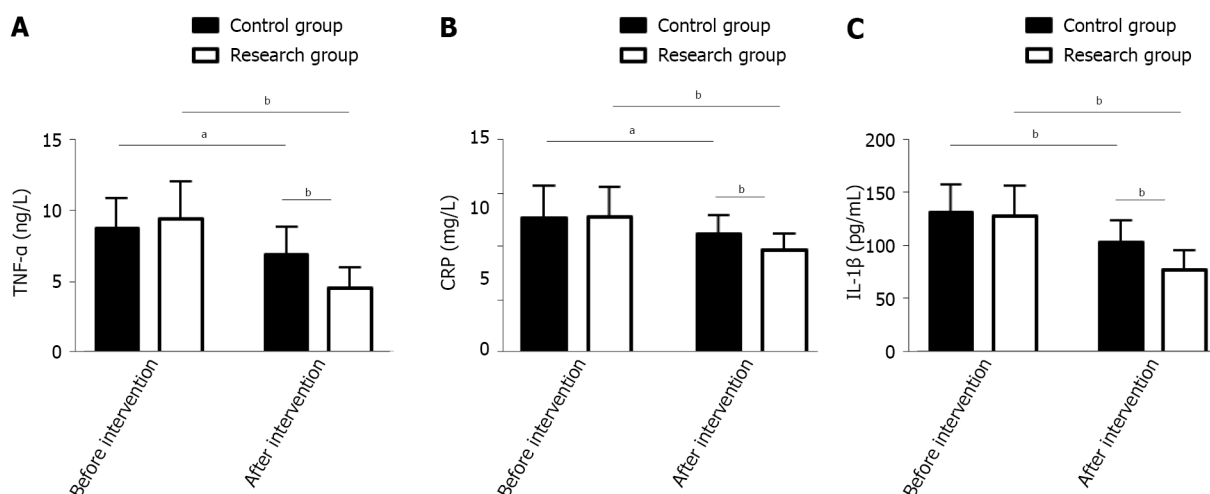
DISCUSSION

PU is a chronic disease. Although its etiology remains unclear, PU is known to be pathogenically associated with the weakening of the gastric mucosal protection mechanism and with excessive gastric acid[18]. The risk of perforation in patients with this disease can be as high as 14%. PU perforation generally manifests as diffuse peritonitis and systemic septicemia, which may endanger patients' lives[19,20]. This study proposes a therapeutic regimen to treat patients with PU perforation in the search for effective treatment options and in the interest of providing a new clinical reference.

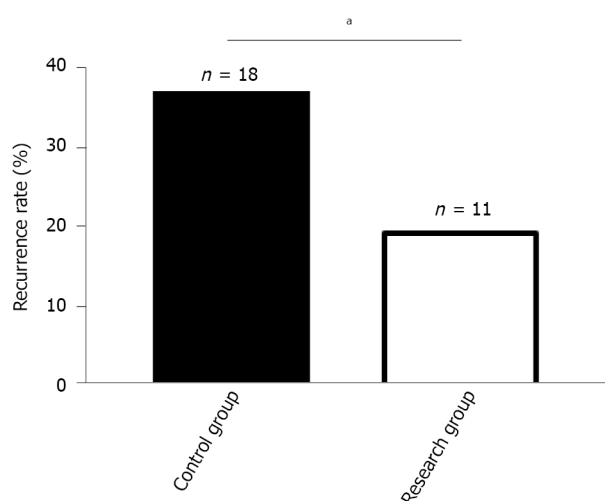
This study included 108 PU patients and grouped them by treatment scheme: Those receiving PPZ plus perforation repair and those treated by perforation repair alone were assigned to the RG and CG, respectively. In our study, the overall response rate of the RG was significantly higher than that of the CG (89.66% vs 74.00%), indicating that PPZ plus

Table 3 Complications of patients with peptic ulcer in the two groups

Indicators	Control group (n = 50)	Research group (n = 58)	χ^2	P value
Perforation	0 (0.00)	0 (0.00)		
Hemorrhage	3 (6.00)	0 (0.00)		
Pyloric obstruction	3 (6.00)	0 (0.00)		
Total	6 (12.00)	0 (0.00)	7.369	0.007



DOI: 10.4240/wjgs.v15.i12.2757 Copyright ©The Author(s) 2023.

Figure 2 Tumor necrosis factor-α, C-reactive protein, and interleukin-1β of patients with peptic ulcer in the two groups. A: Pre- and posttreatment tumor necrosis factor-α levels in the two groups; B: Pre- and posttreatment C-reactive protein levels in the two groups; C: Pre- and posttreatment IL-1β levels in the two groups. ^a*P* < 0.05, ^b*P* < 0.01. TNF-α: Tumor necrosis factor-α; CRP: C-reactive protein; IL-1β: Interleukin-1β.

DOI: 10.4240/wjgs.v15.i12.2757 Copyright ©The Author(s) 2023.

Figure 3 Recurrence rate of patients with peptic ulcer in the two groups. ^a*P* < 0.05.

perforation repair for PUs can help improve efficacy, with better efficacy than perforation repair alone. Previous studies have pointed out that although surgical repair is the standard of treatment for most PU patients, its combination with proton pump inhibitors may be considered because the combination therapy may not only help reduce surgery-related risk but also limit the abuse of proton pump inhibitors, so the two have a certain synergistic role in treatment[21,22]. Tan *et al*[23] pointed out that although perforation repair has the same therapeutic effect as open surgery, the former has the advantages of a lower surgical site infection rate, less postoperative pain, and a shorter nasogastric tube use time. On the other hand, SS has a positive effect on the healing of PU, which may be related to its inhibition of gastrin secretion[24].

Both MDA and LPO can reflect oxidative stress injury associated with PU; the abnormal upregulation of the former is related to the aggravation of cell membrane damage, and the abnormal secretion of the latter is closely related to the deterioration of gastric mucosal tissue damage[25,26]. Therefore, stress response indices such as SS, MDA and LPO were measured to evaluate the ulcer healing and stress response performance of our PU patients. We found that after treatment, RG had a posttreatment SS level that was significantly higher than the pretreatment level and significantly higher than the CG posttreatment level, while MDA and LPO were significantly lower, suggesting that PPZ plus perforation repair can significantly promote ulcer healing and reduce the stress response. The RG had markedly lower inflammatory indices than the pretreatment levels and the CG levels, indicating that PPZ plus perforation repair can effectively inhibit inflammation in PU patients. Recurrence was rarer in the RG *vs* CG (18.97% *vs* 36.00%), suggesting that PPZ plus perforation repair reduces the recurrence risk of PU. In the study by Ng *et al*[27], PPZ was superior to high-dose famotidine in preventing the recurrence of aspirin-related PU, suggesting that PPZ can help to reduce the recurrence risk of PU patients, similar to our findings. Our RG had a markedly lower overall incidence of complications such as perforation, bleeding and pyloric obstruction than the CG (0.00% *vs* 12.00%), demonstrating that PPZ plus perforation repair can help prevent the risk of complications to some extent. Tulinsky *et al*[28] observed that perforation repair for patients with PU perforation was superior to traditional open surgery in terms of safety, and the former helped reduce the incidence of postoperative complications and mortality to some extent, which is consistent with our results.

There are several limitations of this study that need to be addressed. First, since the sample size of this study is only 108, it is necessary to increase the sample size to improve the accuracy of the results. Second, follow-up data were not included to analyze the long-term efficacy and prognosis of PPZ plus perforation repair in PU patients. Supplementing this study with relevant analyses in this regard will help to further demonstrate the potential clinical advantages of PPZ plus perforation repair. Third, this study is a single-center study, and if it can be expanded into a multicenter study, information collection bias can be avoided to a certain extent. In the future, supplementary analyses of the above three areas for improvement will be carried out gradually.

CONCLUSION

In summary, PPZ plus perforation repair is effective in treating PU, as it can suppress the stress response by downregulating MDA and LPO and upregulating SS and can inhibit the inflammatory response by downregulating TNF- α , CRP and IL-1 β while reducing the risks of recurrence and complications. Our findings provide a new theoretical basis for the prevention and treatment of PU patients, as well as provides a novel treatment choice for PU management.

ARTICLE HIGHLIGHTS

Research background

Peptic ulcer (PU) is an abnormal phenomenon of rupture of the mucosa of the digestive tract, which not only affects patients' normal life but also causes an economic burden due to its high medical costs.

Research motivation

There is an urgent need to improve the management of PU from the treatment model and to provide effective treatment options and new clinical references for patients with the disease.

Research objectives

This study investigated the efficacy of pantoprazole (PPZ) plus perforation repair in patients with PU and its effect on the stress response.

Research methods

The study subjects were 108 PU patients admitted between July 2018 and July 2022, including 58 patients receiving PPZ plus perforation repair [research group (RG)] and 50 patients given simple perforation repair [control group (CG)]. The efficacy, somatostatin (SS) concentration, stress reaction [malondialdehyde (MDA), lipid peroxide (LPO)], inflammatory indices [tumor necrosis factor (TNF)- α , C-reactive protein (CRP), interleukin (IL)-1 β], recurrence, and complications (perforation, hemorrhage, and pyloric obstruction) were compared.

Research results

The overall response rate was higher in RG than in CG. RG had markedly elevated SS after treatment, which was higher than that of CG, while MDA, LPO, TNF- α , CRP, and IL-1 β were significantly reduced to lower than those in CG. Lower recurrence and complication rates were identified in RG.

Research conclusions

Therefore, PPZ plus perforation repair is conducive to enhancing treatment outcomes in PU patients, reducing oxidative stress injury and excessive inflammatory reactions, and contributing to low recurrence and complication rates.

Research perspectives

PPZ plus perforation repair is effective in the treatment of PU patients, which can inhibit stress response by down-regulating MDA and LPO and up-regulating SS, alleviate inflammation by down-regulating TNF- α , CRP and IL-1 β levels, and help reduce the risk of recurrence and complications. Our paper develops a theoretical foundation for the prevention and treatment of PU patients and provides a new treatment option and direction for the management of the disease.

FOOTNOTES

Author contributions: Leng ZY and Hua HB designed the research and wrote the first manuscript; Leng ZY, Wang JH, Gao L, Shi K and Hua HB contributed to conceiving the research and analyzing data; Leng ZY and Hua HB conducted the analysis and provided guidance for the research; all authors reviewed and approved the final manuscript.

Institutional review board statement: This study was approved by the Ethic Committee of Jiangyin Hospital Affiliated to Nanjing University of Chinese Medicine.

Informed consent statement: Patients were not required to give informed consent to the study because the analysis used anonymous clinical data that were obtained after each patient agreed to treatment by written consent.

Conflict-of-interest statement: Dr. Hua has nothing to disclose.

Data sharing statement: All data and materials are available from the corresponding author.

Open-Access: This article is an open-access article that was selected by an in-house editor and fully peer-reviewed by external reviewers. It is distributed in accordance with the Creative Commons Attribution NonCommercial (CC BY-NC 4.0) license, which permits others to distribute, remix, adapt, build upon this work non-commercially, and license their derivative works on different terms, provided the original work is properly cited and the use is non-commercial. See: <https://creativecommons.org/licenses/by-nc/4.0/>

Country/Territory of origin: China

ORCID number: Hai-Bing Hua [0009-0006-1774-7292](https://orcid.org/0009-0006-1774-7292).

S-Editor: Lin C

L-Editor: A

P-Editor: Lin C

REFERENCES

- Greenwood-Van Meerveld B, Johnson AC, Grundy D. Gastrointestinal Physiology and Function. *Handb Exp Pharmacol* 2017; **239**: 1-16 [PMID: [28176047](#) DOI: [10.1007/164_2016_118](#)]
- Ardalani H, Hadipanah A, Sahebkar A. Medicinal Plants in the Treatment of Peptic Ulcer Disease: A Review. *Mini Rev Med Chem* 2020; **20**: 662-702 [PMID: [31880244](#) DOI: [10.2174/13895557520666191227151939](#)]
- Lanas A, Chan FKL. Peptic ulcer disease. *Lancet* 2017; **390**: 613-624 [PMID: [28242110](#) DOI: [10.1016/S0140-6736\(16\)32404-7](#)]
- Shim YK, Kim N. Nonsteroidal Anti-inflammatory Drug and Aspirin-induced Peptic Ulcer Disease. *Korean J Gastroenterol* 2016; **67**: 300-312 [PMID: [27312830](#) DOI: [10.4166/kjg.2016.67.6.300](#)]
- Melcarne L, García-Iglesias P, Calvet X. Management of NSAID-associated peptic ulcer disease. *Expert Rev Gastroenterol Hepatol* 2016; **10**: 723-733 [PMID: [26775657](#) DOI: [10.1586/17474124.2016.1142872](#)]
- Kavitt RT, Lipowska AM, Anyane-Yeboah A, Gralnek IM. Diagnosis and Treatment of Peptic Ulcer Disease. *Am J Med* 2019; **132**: 447-456 [PMID: [30611829](#) DOI: [10.1016/j.amjmed.2018.12.009](#)]
- Chan KS, Wang YL, Chan XW, Shelat VG. Outcomes of omental patch repair in large or giant perforated peptic ulcer are comparable to gastrectomy. *Eur J Trauma Emerg Surg* 2021; **47**: 1745-1752 [PMID: [31612272](#) DOI: [10.1007/s00068-019-01237-8](#)]
- Chung KT, Shelat VG. Perforated peptic ulcer - an update. *World J Gastrointest Surg* 2017; **9**: 1-12 [PMID: [28138363](#) DOI: [10.4240/wjgs.v9.i1.1](#)]
- Antoniou SA, Antoniou GA, Koch OO, Pointner R, Granderath FA. Meta-analysis of laparoscopic versus open repair of perforated peptic ulcer. *JSLs* 2013; **17**: 15-22 [PMID: [23743368](#) DOI: [10.4293/108680812X13517013317752](#)]
- Siow SL, Mahendran HA, Wong CM, Hardin M, Luk TL. Laparoscopic versus open repair of perforated peptic ulcer: Improving outcomes utilizing a standardized technique. *Asian J Surg* 2018; **41**: 136-142 [PMID: [27955872](#) DOI: [10.1016/j.asjsur.2016.11.004](#)]
- Varcus F, Paun I, Duta C, Dobrescu A, Frandes M, Tarta C. Laparoscopic repair of perforated peptic ulcer. *Minerva Chir* 2018; **73**: 188-193 [PMID: [29366313](#) DOI: [10.23736/S0026-4733.18.07603-4](#)]
- Kim CW, Kim JW, Yoon SN, Oh BY, Kang BM. Laparoscopic repair of perforated peptic ulcer: a multicenter, propensity score matching analysis. *BMC Surg* 2022; **22**: 230 [PMID: [35710415](#) DOI: [10.1186/s12893-022-01681-1](#)]
- Assalin HB, De Almeida KCG, Guadagnini D, Santos A, Teixeira CJ, Bordin S, Rocha GZ, Saad MJA. Proton Pump Inhibitor Pantoprazole Modulates Intestinal Microbiota and Induces TLR4 Signaling and Fibrosis in Mouse Liver. *Int J Mol Sci* 2022; **23** [PMID: [36430244](#) DOI: [10.3390/ijms232213766](#)]
- Asdaq SMB, Swathi E, Dhamanigi SS, Asad M, Ali Mohzari Y, Alrashed AA, Alotaibi AS, Mohammed Alhassan B, Nagaraja S. Role of

- Daucus carota in Enhancing Antiulcer Profile of Pantoprazole in Experimental Animals. *Molecules* 2020; **25** [PMID: 33202703 DOI: 10.3390/molecules25225287]
- 15 **Moayyedi P**, Eikelboom JW, Bosch J, Connolly SJ, Dyal L, Shestakovska O, Leong D, Anand SS, Störk S, Branch KRH, Bhatt DL, Verhamme PB, O'Donnell M, Maggioni AP, Lonn EM, Piegas LS, Ertl G, Keltai M, Cook Bruns N, Muehlhofer E, Dagenais GR, Kim JH, Hori M, Steg PG, Hart RG, Diaz R, Alings M, Widimsky P, Avezum A, Probstfield J, Zhu J, Liang Y, Lopez-Jaramillo P, Kakkar A, Parkhomenko AN, Ryden L, Pogosova N, Dans A, Lanas F, Commerford PJ, Torp-Pedersen C, Guzik T, Vinereanu D, Tonkin AM, Lewis BS, Felix C, Yusuf K, Metsarinne K, Fox KAA, Yusuf S; COMPASS Investigators. Pantoprazole to Prevent Gastroduodenal Events in Patients Receiving Rivaroxaban and/or Aspirin in a Randomized, Double-Blind, Placebo-Controlled Trial. *Gastroenterology* 2019; **157**: 403-412.e5 [PMID: 31054846 DOI: 10.1053/j.gastro.2019.04.041]
 - 16 **Karabulut K**, Dinçer M, Liman RK, Usta S. Non-operative management of perforated peptic ulcer: A single-center experience. *Ulus Travma Acil Cerrahi Derg* 2019; **25**: 585-588 [PMID: 31701498 DOI: 10.14744/tjtes.2019.31967]
 - 17 **Kamada T**, Satoh K, Itoh T, Ito M, Iwamoto J, Okimoto T, Kanno T, Sugimoto M, Chiba T, Nomura S, Mieda M, Hiraishi H, Yoshino J, Takagi A, Watanabe S, Koike K. Evidence-based clinical practice guidelines for peptic ulcer disease 2020. *J Gastroenterol* 2021; **56**: 303-322 [PMID: 33620586 DOI: 10.1007/s00535-021-01769-0]
 - 18 **Mihály E**, Micsik T, Juhász M, Herszényi L, Tulassay Z. Gastritis and gastropathy. *Orv Hetil* 2014; **155**: 43-61 [PMID: 24389321 DOI: 10.1556/OH.2014.29807]
 - 19 **Coco D**, Leanza S. A Review on Treatment of Perforated Peptic Ulcer by Minimally Invasive Techniques. *Maedica (Bucur)* 2022; **17**: 692-698 [PMID: 36540584 DOI: 10.26574/maedica.2022.17.3.692]
 - 20 **Tarasconi A**, Cocolini F, Biffi WL, Tomasoni M, Ansaloni L, Picetti E, Molfino S, Shelat V, Cimbanassi S, Weber DG, Abu-Zidan FM, Campanile FC, Di Saverio S, Baiocchi GL, Casella C, Kelly MD, Kirkpatrick AW, Leppaniemi A, Moore EE, Peitzman A, Fraga GP, Ceresoli M, Maier RV, Wani I, Pattonieri V, Perrone G, Velmahos G, Sugrue M, Sartelli M, Kluger Y, Catena F. Perforated and bleeding peptic ulcer: WSES guidelines. *World J Emerg Surg* 2020; **15**: 3 [PMID: 31921329 DOI: 10.1186/s13017-019-0283-9]
 - 21 **Krag M**, Marker S, Perner A, Wetterslev J, Wise MP, Schefold JC, Keus F, Guttormsen AB, Bendel S, Borthwick M, Lange T, Rasmussen BS, Siegemund M, Bundgaard H, Elkmann T, Jensen JV, Nielsen RD, Liboriussen L, Bestle MH, Elkjær JM, Palmqvist DF, Bäcklund M, Laake JH, Bådstøløkken PM, Grönlund J, Breum O, Walli A, Winding R, Iversen S, Jarnvig IL, White JO, Brand B, Madsen MB, Quist L, Thornberg KJ, Möller A, Wiis J, Granholm A, Anthon CT, Meyhoff TS, Hjortrup PB, Aagaard SR, Andreasen JB, Sørensen CA, Haure P, Hauge J, Hollinger A, Scheuzger J, Tuchscherer D, Vuillienet T, Takala J, Jakob SM, Vang ML, Pælestik KB, Andersen KLD, van der Horst ICC, Dieperink W, Fjølner J, Kjer CKW, Sølling C, Sølling CG, Karttunen J, Morgan MPG, Sjøbø B, Engstrøm J, Agerholm-Larsen B, Möller MH; SUP-ICU trial group. Pantoprazole in Patients at Risk for Gastrointestinal Bleeding in the ICU. *N Engl J Med* 2018; **379**: 2199-2208 [PMID: 30354950 DOI: 10.1056/NEJMoa1714919]
 - 22 **Clarke K**, Adler N, Agrawal D, Bhakta D, Sata SS, Singh S, Gupta A, Pahwa A, Pherson E, Sun A, Volpicelli F, Cho HJ. Indications for the Use of Proton Pump Inhibitors for Stress Ulcer Prophylaxis and Peptic Ulcer Bleeding in Hospitalized Patients. *Am J Med* 2022; **135**: 313-317 [PMID: 34655535 DOI: 10.1016/j.amjmed.2021.09.010]
 - 23 **Tan S**, Wu G, Zhuang Q, Xi Q, Meng Q, Jiang Y, Han Y, Yu C, Yu Z, Li N. Laparoscopic vs open repair for perforated peptic ulcer: A meta analysis of randomized controlled trials. *Int J Surg* 2016; **33** Pt A: 124-132 [PMID: 27504848 DOI: 10.1016/j.ijsu.2016.07.077]
 - 24 **Batista LM**, Lima GR, De Almeida AB, Magri Lde P, Calvo TR, Ferreira AL, Pellizzon CH, Hiruma-Lima CA, Vilegas W, Sano PT, Brito AR. Ulcer healing and mechanism(s) of action involved in the gastroprotective activity of fractions obtained from *Syngonanthus arthrotrichus* and *Syngonanthus bisulcatus*. *BMC Complement Altern Med* 2015; **15**: 391 [PMID: 26511617 DOI: 10.1186/s12906-015-0923-x]
 - 25 **Pan Z**, He Q, Zeng J, Li S, Li M, Chen B, Yang J, Xiao J, Zeng C, Luo H, Wang H. Naringenin protects against iron overload-induced osteoarthritis by suppressing oxidative stress. *Phytomedicine* 2022; **105**: 154330 [PMID: 35905566 DOI: 10.1016/j.phymed.2022.154330]
 - 26 **Rovani BT**, de Freitas RB, Augusti PR, Araldi IC, Somacal S, Quatrin A, Emanuelli T, da Rocha MP, Bauermann Lde F. Prooxidant activity of norbixin in model of acute gastric ulcer induced by ethanol in rats. *Hum Exp Toxicol* 2016; **35**: 737-746 [PMID: 26353805 DOI: 10.1177/0960327115604199]
 - 27 **Ng FH**, Wong SY, Lam KF, Chu WM, Chan P, Ling YH, Kng C, Yuen WC, Lau YK, Kwan A, Wong BC. Famotidine is inferior to pantoprazole in preventing recurrence of aspirin-related peptic ulcers or erosions. *Gastroenterology* 2010; **138**: 82-88 [PMID: 19837071 DOI: 10.1053/j.gastro.2009.09.063]
 - 28 **Tulinský L**, Sengul D, Sengul I, Hrubovčák J, Martínek L, Kepičová M, Pelikán A, Ihnát P. Laparoscopic Repair Modality of Perforated Peptic Ulcer: Less Is More? *Cureus* 2022; **14**: e30926 [PMID: 36337818 DOI: 10.7759/cureus.30926]



Published by **Baishideng Publishing Group Inc**
7041 Koll Center Parkway, Suite 160, Pleasanton, CA 94566, USA

Telephone: +1-925-3991568

E-mail: bpgoffice@wjgnet.com

Help Desk: <https://www.f6publishing.com/helpdesk>

<https://www.wjgnet.com>

