

World Journal of *Gastrointestinal Surgery*

World J Gastrointest Surg 2023 March 27; 15(3): 307-494



Contents

Monthly Volume 15 Number 3 March 27, 2023

MINIREVIEWS

- 307 Surgical management of acute pancreatitis: Historical perspectives, challenges, and current management approaches
Alzerwi N
- 323 Current trends in perioperative treatment of resectable gastric cancer
Yıldız İ, Özer L, Şenocak Taşçı E, Bayoglu İV, Aytac E
- 338 Vascular injury during laparoscopic cholecystectomy: An often-overlooked complication
Pesce A, Fabbri N, Feo CV

ORIGINAL ARTICLE

Basic Study

- 346 Differential expression and significance of 5-hydroxymethylcytosine modification in hepatitis B virus carriers and patients with liver cirrhosis and liver cancer
Li YC, Hu WY, Li CH, Zhang LL, Xu XW, Li J, Luo HX

Retrospective Cohort Study

- 362 Compliance with enhanced recovery after surgery predicts long-term outcome after hepatectomy for cholangiocarcinoma
Jongkatkorn C, Luvira V, Suwanprinya C, Piampatipan K, Leeratanakachorn N, Tipwaratorn T, Titapun A, Srisuk T, Theeragul S, Jarearnrat A, Thanasukarn V, Pughkem A, Khuntikeo N, Pairojkul C, Kamsa-Ard S, Bhudhisawasdi V
- 374 Pain management in patients with hepatocellular carcinoma after transcatheter arterial chemoembolisation: A retrospective study
Guan Y, Tian Y, Fan YW

Retrospective Study

- 387 Risk factors and prediction model for inpatient surgical site infection after elective abdominal surgery
Zhang J, Xue F, Liu SD, Liu D, Wu YH, Zhao D, Liu ZM, Ma WX, Han RL, Shan L, Duan XL
- 398 Percutaneous management in hepatic alveolar echinococcosis: A sum of single center experiences and a brief overview of the literature
Eren S, Aydın S, Kantarci M, Kızılgöz V, Levent A, Şenbil DC, Akhan O
- 408 Clinical features of acute esophageal mucosal lesions and reflux esophagitis Los Angeles classification grade D: A retrospective study
Ichita C, Sasaki A, Shimizu S
- 420 Positive correlation between latent Epstein-Barr virus infection and severity of illness in inflammatory bowel disease patients
Wei HT, Xue XW, Ling Q, Wang PY, Zhou WX

Clinical Trials Study

- 430** Efficacy and outcome of extensive intraoperative peritoneal lavage plus surgery *vs* surgery alone with advanced gastric cancer patients

Song ED, Xia HB, Zhang LX, Ma J, Luo PQ, Yang LZ, Xiang BH, Zhou BC, Chen L, Sheng H, Fang Y, Han WX, Wei ZJ, Xu AM

Randomized Controlled Trial

- 440** Endoscopic mucosal resection with double band ligation versus endoscopic submucosal dissection for small rectal neuroendocrine tumors

Huang JL, Gan RY, Chen ZH, Gao RY, Li DF, Wang LS, Yao J

SYSTEMATIC REVIEWS

- 450** Preoperative risk modelling for oesophagectomy: A systematic review

Grantham JP, Hii A, Shenfine J

META-ANALYSIS

- 471** Effect of music therapy on chemotherapy-induced nausea and vomiting in gastrointestinal cancer: A systematic review and meta-analysis

Zhong FP, Zhong J, Zhong MY

CASE REPORT

- 480** Immunotherapy in combination with chemotherapy for Peutz-Jeghers syndrome with advanced cervical cancer: A case report

Hu XC, Gan CX, Zheng HM, Wu XP, Pan WS

- 488** Xanthogranulomatous inflammation requiring small bowel anastomosis revision: A case report

Wang W, Korah M, Bessoff KE, Shen J, Forrester JD

ABOUT COVER

Editorial Board Member of *World Journal of Gastrointestinal Surgery*, Valeriu Marin Şrlin, MD, Professor, Surgical Oncologist, Department of Surgery, University of Medicine and Pharmacy of Craiova, Craiova 200391, Dolj, Romania. vsurlin@gmail.com

AIMS AND SCOPE

The primary aim of *World Journal of Gastrointestinal Surgery* (WJGS, *World J Gastrointest Surg*) is to provide scholars and readers from various fields of gastrointestinal surgery with a platform to publish high-quality basic and clinical research articles and communicate their research findings online.

WJGS mainly publishes articles reporting research results and findings obtained in the field of gastrointestinal surgery and covering a wide range of topics including biliary tract surgical procedures, biliopancreatic diversion, colectomy, esophagectomy, esophagostomy, pancreas transplantation, and pancreatectomy, etc.

INDEXING/ABSTRACTING

The WJGS is now abstracted and indexed in Science Citation Index Expanded (SCIE, also known as SciSearch®), Current Contents/Clinical Medicine, Journal Citation Reports/Science Edition, PubMed, PubMed Central, Reference Citation Analysis, China National Knowledge Infrastructure, China Science and Technology Journal Database, and Superstar Journals Database. The 2022 Edition of Journal Citation Reports® cites the 2021 impact factor (IF) for WJGS as 2.505; IF without journal self cites: 2.473; 5-year IF: 3.099; Journal Citation Indicator: 0.49; Ranking: 104 among 211 journals in surgery; Quartile category: Q2; Ranking: 81 among 93 journals in gastroenterology and hepatology; and Quartile category: Q4.

RESPONSIBLE EDITORS FOR THIS ISSUE

Production Editor: Rui-Rui Wu; Production Department Director: Xiang Li; Editorial Office Director: Jia-Ru Fan.

NAME OF JOURNAL

World Journal of Gastrointestinal Surgery

ISSN

ISSN 1948-9366 (online)

LAUNCH DATE

November 30, 2009

FREQUENCY

Monthly

EDITORS-IN-CHIEF

Peter Schemmer

EDITORIAL BOARD MEMBERS

<https://www.wjgnet.com/1948-9366/editorialboard.htm>

PUBLICATION DATE

March 27, 2023

COPYRIGHT

© 2023 Baishideng Publishing Group Inc

INSTRUCTIONS TO AUTHORS

<https://www.wjgnet.com/bpg/gerinfo/204>

GUIDELINES FOR ETHICS DOCUMENTS

<https://www.wjgnet.com/bpg/GerInfo/287>

GUIDELINES FOR NON-NATIVE SPEAKERS OF ENGLISH

<https://www.wjgnet.com/bpg/gerinfo/240>

PUBLICATION ETHICS

<https://www.wjgnet.com/bpg/GerInfo/288>

PUBLICATION MISCONDUCT

<https://www.wjgnet.com/bpg/gerinfo/208>

ARTICLE PROCESSING CHARGE

<https://www.wjgnet.com/bpg/gerinfo/242>

STEPS FOR SUBMITTING MANUSCRIPTS

<https://www.wjgnet.com/bpg/GerInfo/239>

ONLINE SUBMISSION

<https://www.f6publishing.com>



Surgical management of acute pancreatitis: Historical perspectives, challenges, and current management approaches

Nasser Alzerwi

Specialty type: Gastroenterology and hepatology

Provenance and peer review: Invited article; Externally peer reviewed.

Peer-review model: Single blind

Peer-review report's scientific quality classification

Grade A (Excellent): 0
Grade B (Very good): B
Grade C (Good): C, C, C
Grade D (Fair): 0
Grade E (Poor): 0

P-Reviewer: Basson MD, United States; Chen H, China; Kitamura K, Japan

Received: September 21, 2022

Peer-review started: September 21, 2022

First decision: October 21, 2022

Revised: November 19, 2022

Accepted: February 14, 2023

Article in press: February 14, 2023

Published online: March 27, 2023



Nasser Alzerwi, Department of Surgery, Majmaah University, Riyadh 11952, Saudi Arabia

Corresponding author: Nasser Alzerwi, MBBS, SBGS, ABGS, FSMC(HPB), Associate Professor, Department of Surgery, Majmaah University, P. O. Box 66, Al-Majmaah City, Riyadh Region, Riyadh 11952, Saudi Arabia. n.alzerwi@mu.edu.sa

Abstract

Acute pancreatitis (AP) is a serious condition presenting catastrophic consequences. In severe AP, the mortality rate is high, and some patients initially diagnosed with mild-to-moderate AP can progress to a life-threatening severe state. Treatment of AP has evolved over the years. Drainage was the first surgical procedure performed for AP; however, later, surgical approaches were replaced by more conservative approaches due to the availability of advanced medical care and improved understanding of the course of AP. Currently, surgery is used to manage several complications of AP, such as pseudocysts, pancreatic fistulas, and biliary tract obstruction. Patients who are unresponsive to conservative treatment or have complications are typically considered for surgical intervention. This review focuses on the surgical approaches (endoscopic, percutaneous, and open) that have been established in recent studies to treat this acute condition and summarizes the common management guidelines for AP, discussing the relevant indications, significance, and complications. It is evident that despite their reduced involvement, surgeons lead the multidisciplinary care of patients with AP; however, given the gaps in existing knowledge, more research is required to standardize surgical protocols for AP.

Key Words: Acute pancreatitis; Surgery; Endoscopic management; Open surgery; Necrosectomy

©The Author(s) 2023. Published by Baishideng Publishing Group Inc. All rights reserved.

Core Tip: The surgical management of acute pancreatitis has evolved substantially during the last several decades. Conservative therapy is frequently more effective than surgery; nonetheless, surgical treatments are required in cases of non-responsive or complication-prone patients. Such cases may be treated using endoscopic, percutaneous, or open procedures, each with its own set of benefits and risks. Before settling on an acceptable surgical procedure, the AP severity, phase, and anatomical restrictions must be thoroughly reviewed for optimal clinical outcomes.

Citation: Alzerwi N. Surgical management of acute pancreatitis: Historical perspectives, challenges, and current management approaches. *World J Gastrointest Surg* 2023; 15(3): 307-322

URL: <https://www.wjgnet.com/1948-9366/full/v15/i3/307.htm>

DOI: <https://dx.doi.org/10.4240/wjgs.v15.i3.307>

INTRODUCTION

Acute pancreatitis (AP) is a prevalent gastrointestinal disorder resulting in localized damage, systemic inflammatory response syndrome, and organ failure (OF)[1,2]. With a worldwide incidence of 340 per million people overall and case fatality rates of up to 35% in severe instances, AP causes a great deal of distress, morbidity, and financial strain on the healthcare system[3-5].

In Western countries, the prevalence of AP has been steadily rising over the last half-century[6]. Gallstones and alcohol continue to be common causes of AP, contributing to 80% of AP cases, while the remaining occurrences are related to less common causes, such as drug interactions and solid and cystic pancreatic cancers. In particular, the global transition rate from the index AP to a recurring episode is in double digits. Given these concerns and the variety of long-term repercussions, it is prudent not to regard AP as a self-limiting condition[5].

The need for surgical intervention in AP has been under scrutiny for more than a century, with arguments ranging from conservative therapeutic strategies on the one hand to surgical approaches. However, in the last three decades, the discourse has changed significantly, with conservative management gaining favor due to the availability of advanced diagnostic modalities, improved noninvasive care, improved understanding of the underlying mechanisms, and improvements in interventional procedures. However, surgery still serves a critical function in managing AP, and there are specific situations in which minimally invasive or open surgical interventions are necessary.

This review offers a concise overview of the evolution of surgical management of AP, with an emphasis on contemporary surgical techniques. Recent ground-breaking studies have allowed the development of several sets of recommendations and guidelines for the management of AP. This review also summarizes some of these recommendations, focusing on surgical interventions for AP, including indications, staging, and techniques.

AP: ETIOLOGY, CLASSIFICATION, AND DIAGNOSIS

During the mid-twentieth century, researchers realized that AP could have various root causes, each of which required a unique diagnostic and therapeutic strategy. Approximately 40% of AP cases are now attributed to gallstones, and approximately 30% are considered to have alcohol as an etiological component[7] (Figure 1A). Researchers have also identified various other etiologies for AP, including metabolic, immunological, parasitic, genetic, anatomical, and endoscopic retrograde cholangiopancreatography (ERCP). Notably, the prevalence of hypertriglyceridemic AP has increased in recent years [8]. Idiopathic AP is AP with no identified explanation after primary laboratory and imaging studies[9, 10].

Early efforts to categorize pancreatitis focused mainly on describing its clinical and pathological aspects. Fitz distinguished between acute, hemorrhagic, and suppurative forms of pancreatitis[11]. Ranson *et al*[12] demarcated AP's key clinical and biochemical features, now known as the Ranson criteria. Another significant development was the Atlanta classification proposed in 1992[13], wherein objective criteria for severe, interstitial, and necrotizing AP, infected pancreatic necrosis (IPN), and pseudocysts were framed, with a stronger focus on the systemic effect of AP. Two new AP classification systems were released in 2012: Revised Atlanta classification and determinant-based classification[14, 15]. The revised Atlanta classification system is popular at the moment. The severity of AP may be classified as mild, moderately severe (MSAP), or severe (SAP), and there are also two distinct stages (early and late). In addition, it explains how AP is diagnosed, stresses the importance of pain as a benchmark, and singles out local complications, interstitial pancreatitis, and necrotizing pancreatitis (Table 1, Figure 2).

Table 1 Acute pancreatitis diagnosis, classification, and indications for surgery

	Criteria
Diagnosis of AP (any two)	Abdominal pain Serum lipase or amylase anomalies Characteristic radiological features
Mild AP ¹	No OF Absence of local or systemic complications
Moderately severe AP ¹	Transient OF (resolves in < 48 h) Local or systemic complications without persistent OF
Severe AP ¹	Persistent OF
Key indications for surgery	Infected necrosis Complications of pancreatitis Fistulas Pseudocyst Recurrent AP Abdominal compartment syndrome Systemic inflammatory response syndrome Acute necrotizing cholecystitis or intestinal ischemia Acute bleeding due to a failed endovascular approach

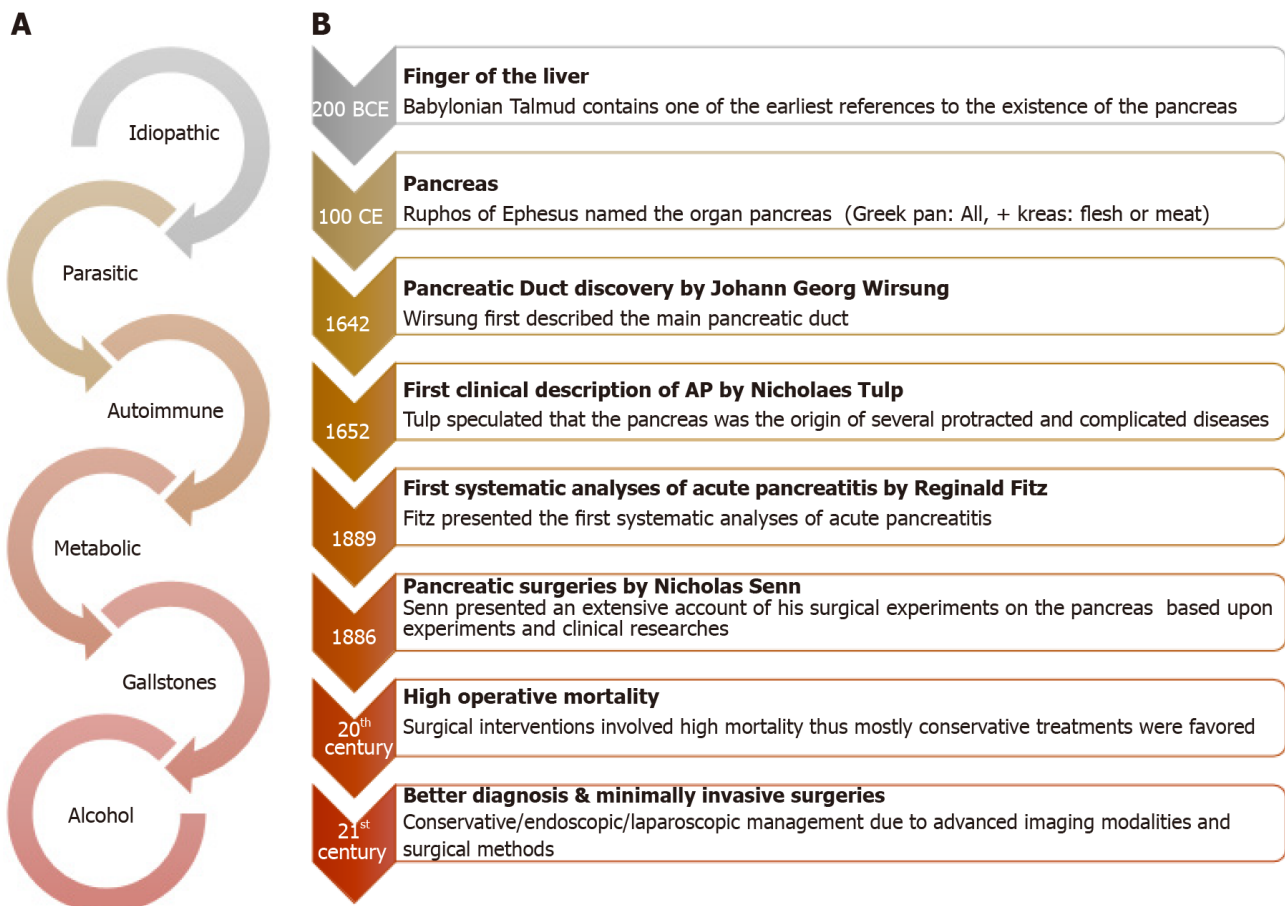
¹Revised Atlanta Classification.

AP: Acute pancreatitis; OF: Organ failure.

The diagnosis of AP is based on the presence of characteristic abdominal pain, biochemical confirmation of pancreatitis, and radiographic proof (at least two out of the Diagnostic Triad and in that order)[2,16]. The early and late phases of AP last about two weeks and several weeks, respectively. Temporary local or systemic problems define MSAP or a transient OF, whereas SAP is defined by a lingering OF. Organized fluid collections within four weeks were denoted as acute peri/pancreatic fluid collections and pseudocysts after four weeks. The term “acute necrotic collections” (ANC) is used to describe necrosis-complicated collections that occur within four weeks, whereas “wall necrosis” (WON) is used to describe collections that occur later than four weeks (Figure 2)[14].

PATHOBIOLOGY OF PANCREATITIS

Various physical and genetic variables predispose individuals to AP[17]. Many studies have been conducted on acute pancreatic inflammation in the last century, but our understanding of its numerous pathophysiological implications remains limited[18]. Based on current research, collapse of the pancreatic acinar cell membrane and intracellular digesting enzymes that cause pancreatic damage are suspected to be significant contributors to AP[19]. In particular, in the early course of pancreatitis, enteropeptidase leads to premature activation of trypsinogen to trypsin in acinar cells (Figure 3). This activation sets off a chain reaction of digestive protease activation, which ultimately digests the acinar cells and causes pancreatitis. Although trypsinogen activation inside the acinar cells has a role in the first stages of acinar damage, the development of local and systemic inflammation in pancreatitis can occur independently. Indeed, in the early stages of pancreatitis, trypsin-mediated cell death causes pancreatic injury; however, multiple parallel mechanisms, including activation of inflammatory cascades, excess calcium (Ca²⁺)-induced endoplasmic reticulum stress, autophagy, and mitochondrial dysfunction in acinar cells, are now recognized as important in driving the profound systemic inflammatory response and extensive pancreatic injury in AP[18]. Notably, nuclear factor-kappaB activation occurs early, independent of trypsinogen activation, and leads to the release of inflammatory mediators and recruitment of inflammatory cells, causing acinar cell death at later stages of pancreatitis and driving the systemic inflammatory response observed in pancreatitis[20].



DOI: 10.4240/wjgs.v15.i3.307 Copyright ©The Author(s) 2023.

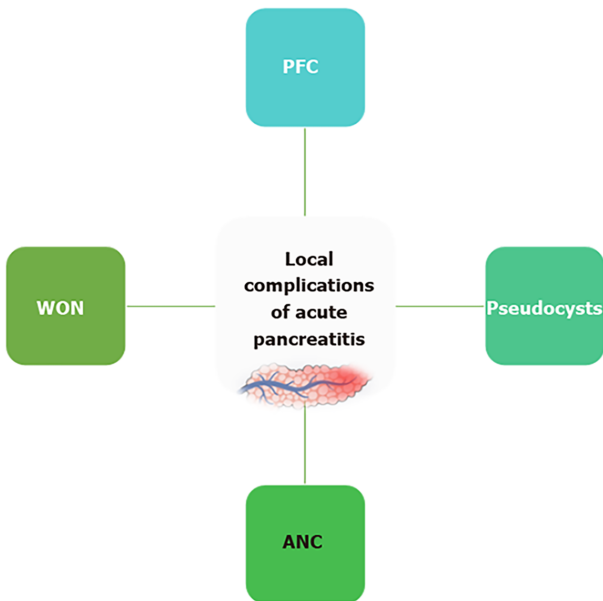
Figure 1 Etiologies and evolution of surgical management of acute pancreatitis. A: Key acute pancreatitis etiologies; B: Evolution of surgical management.

HISTORICAL PERSPECTIVES ON THE PANCREAS AND EVOLUTION OF PANCREATIC SURGERY

One of the first allusions to the presence of the pancreas can be found in Babylonian Talmud and ancient Greek anatomists[21-23] (Figure 1B). Ruphos of Ephesus named the organ the “pancreas” after seeing that it lacked cartilage and bone in human cadavers (pan: All, kreas: Flesh). Galenus recognized the pancreas as a gland and named it kalikreas, a ‘beautiful flesh’. It was not until the 17th century that scientists Johann Georg Wirsung and Giovanni Domenico Santorini discovered primary and secondary pancreatic ducts, respectively[24]. Abraham Vater (1684-1751) described the tubercle or diverticulum, later called the ‘ampulla of Vater’[25]. Pannala *et al*[21] suggested that the pancreas plays a vital role in digestion. Subsequent researchers such as Willy Kuhne (trypsin identification), Alexander Marcet (lipase identification), Willy Kuhne (trypsin identification), Alexander Marcet (lipase discovery), and Ivan Pavlov (nerves of the pancreas) contributed greatly to the understanding of pancreatic physiology.

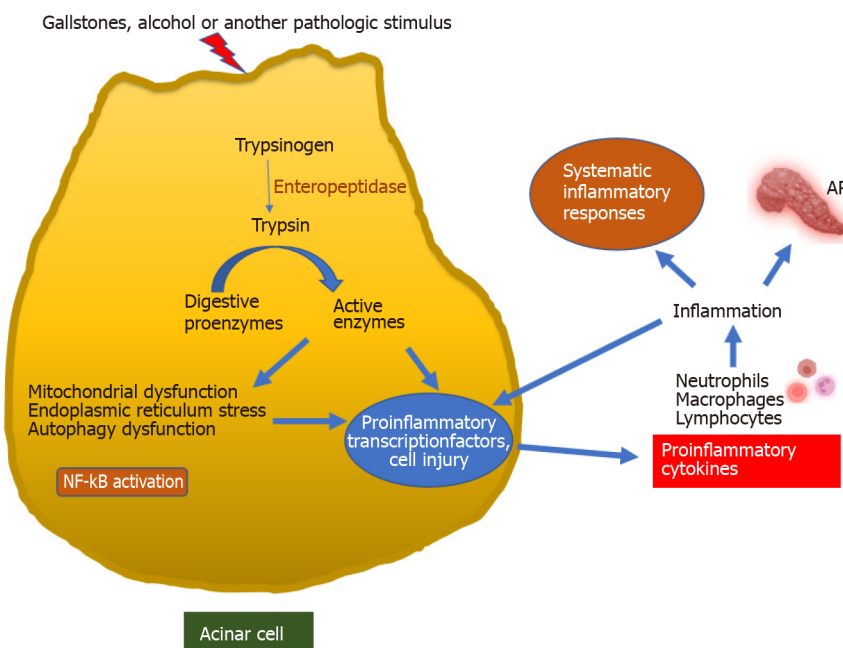
The Dutch anatomist Nicholaes Tulp is accredited with the first publication on the clinical description of AP in 1652. In 1889, Reginald Fitz of Boston offered the first comprehensive analysis of AP in a landmark study. In 1886, Nicholas Senn provided a detailed report of his surgical trials on pancreatic disorders, describing the excision and drainage of retention cysts[26]. In the late nineteenth century, exploratory laparotomy became popular for diagnosing AP and drainage of pancreatic abscesses, and necrotic tissue debridement was performed in some cases. However, despite growing knowledge of pancreatitis, the distinction between chronic pancreatitis and AP was recognized only in the mid-20th century. Surgeons such as Mickulicz, Mayo Robson, and Moynihan were encouraged to employ laparotomy to treat the complications of severe AP as anesthetics developed in the early twentieth century. In the first few decades of the twentieth century, various procedures were performed, such as drainage, resection, and cholecystostomy, but the operative mortality rate remained close to 60%[21].

Later, as the understanding of pancreatic physiology improved and diagnostic modalities advanced, conservative management of patients gained preference. If there is no secondary infection, surgical treatment is not required. With the identification of WON or organized pancreatic necrosis and the advent of advanced antibiotics to curb systemic toxicity and OF, the treatment of pancreatic necrosis has



DOI: 10.4240/wjgs.v15.i3.307 Copyright ©The Author(s) 2023.

Figure 2 Local complications in acute pancreatitis. ANC: Acute necrotic collections; PFC: Peripancreatic fluid collections; WON: Walled-off necrosis.



DOI: 10.4240/wjgs.v15.i3.307 Copyright ©The Author(s) 2023.

Figure 3 Pathogenesis of acute pancreatitis. Early activation of trypsinogen to trypsin in acinar cells triggers a cascade of pathogenic events, resulting in acute pancreatitis. AP: Acute pancreatitis; NF-kB: Nuclear factor kB.

evolved further, and delayed necrosectomy is commonly performed for sterile pancreatic necrosis[27, 28]. Minimally invasive laparoscopic, endoscopic, and percutaneous techniques have been established in recent decades to treat pancreatic necrosis; however, surgery remains an essential treatment for people with severe pathology. Endoscopic ultrasound (US)-guided therapy for pancreatic necrosis and other AP sequelae is also increasingly gaining popularity[10,27,29,30].

SURGICAL MANAGEMENT

Summary of major guidelines

For the treatment of AP, the guidelines of the International Association of Pancreatology (IAP)/ American Pancreatic Association (2013)[31], the World Society of Emergency Surgery (2019)[4], and the American Gastroenterological Association (AGA) published in 2018[32] and 2020[33] are particularly notable. The recommendations of these guidelines for diagnosing and treating AP coincide significantly. The next section briefly summarizes the rationale for surgical interventions and the methods laid forth in the pivotal guidelines.

IAP guidelines: Due to the self-limiting nature and minimal mortality risk, the IAP guidelines explicitly indicate that mild AP is not a justification for surgery. Surgery and drainage are primarily necessary for the clinical indications of sepsis, and early surgery (14 d from the start) should be avoided, especially if patients respond well to conservative therapy. Timing is particularly critical, as cardiac and respiratory failures are common in the early phases of the disease. Furthermore, delaying surgery to a time that provides an improved delineation of the necrotic zone will allow optimal surgical circumstances.

The best surgical approach is removing necrotic tissues while minimizing the risk of subsequent infections, bleeding, necrosis, and inflammation. Most retroperitoneal (RP) debris and exudates are removed postoperatively. Because the pancreas is the main organ responsible for numerous endocrine and exocrine activities, pancreatectomy, whether entire or partial, may cause endocrine inefficiency. Organ preservation techniques such as debridement or necrosectomy are also favored. Although there is no consensus on the ideal strategy for necrosectomy, postoperative mortality has been reported to be less than 15% in various combinations of open necrosectomy with planned relaparotomy. In addition to the open approach, less invasive procedures for necrosectomy are being developed. However, the IAP advises that such treatments should be used in a subset of patients with confined or well-defined necrosis.

Gallstone-associated AP (GSAP) has its own set of management problems, as well as additional co-occurring comorbidities. GSAP requires early management, irrespective of the appearance of obstructive jaundice or severe cholangitis. Because there is no explicit agreement on this topic, the IAP did not recommend the use of endoscopic sphincterotomy (ES) and ERCP for severe GSAP. However, these are needed in the presence of obstructive jaundice or severe cholangitis. In patients with severe GSAP, open cholecystectomy with supraduodenal bile duct exploration and T-tube insertion is often considered an unsatisfactory emergency surgery. If a patient has undergone ES for acute gallstone-associated pancreatitis, the gallbladder should be removed because of the possible risk of gallbladder complications.

Cholecystectomy and clearance of the major bile ducts (when clinical, biochemical, and radiological indicators of persistent biliary obstruction are present) can be performed to prevent the recurrence of biliary pancreatitis. In cases of mild AP associated with gallstones, it should be performed immediately after the patient recovers from the attack. However, in acute GSAP, cholecystectomy should be performed after the inflammatory process has stopped and the patient has recovered clinically to make treatment easier and safer. ES can be used in patients who cannot undergo cholecystectomy; however, the possibility of intervention-induced infections should not be ignored.

Japanese guidelines: The Japanese guidelines[34] for the management of AP were first published in 2006 and have since been amended in 2012 and 2015, respectively. To avoid GSAP recurrence, cholecystectomy is indicated when such an operation is feasible. Because abdominal compartment syndrome (ACS) increases the mortality risk in such situations, sequential IAP monitoring is suggested in patients with abnormal fluid infusion and respiratory or kidney problems.

When an IAP of 12 mmHg persists or recurs, conservative therapy is recommended to maintain it at 15 mmHg. Surgical decompression can be explored when the IAP is greater than 20 mmHg, conservative therapy is ineffective, and OF is a significant concern. Conservative treatment for necrotizing pancreatitis should be attempted first. Suspected or confirmed infections and worsening state are the best justifications for intervention.

IPN is considered when clinical symptoms worsen, along with blood test results that support infection. Four weeks after onset, therapeutic intervention should be initiated when the necrosis is adequately walled off or during the WON phase. Drainage (percutaneous or endoscopic) should be explored, and if no improvement is observed, necrosectomy is a viable approach to treat IPN.

AGA (2018), American College of Gastroenterology (2013), and AGA (2020) guidelines: The 2018 AGA [32] guidelines focused on the initial management of AP. The AGA recommends that AP management during the first 48-72 h after admission should focus on outcome-specific fluid resuscitation. Hydroxyethyl starch fluids are discouraged, and prophylactic antibiotics are not recommended for SAP and necrotizing pancreatitis. AGA advocates early oral feeding and enteral nutrition rather than parenteral nutrition.

Immediate ERCP may be conducted in patients with cholangitis; however, this is not indicated in the context of acute biliary pancreatitis. Cholecystectomy is recommended for patients with acute biliary

pancreatitis, ideally before discharge from the hospital. AGA also recommends same-admission cholecystectomy and short alcohol intercession for biliary and alcohol-induced pancreatitis. AGA does not recommend the regular use of preventive antibiotics in SAP or routine ERCP in patients with AP in the absence of cholangitis.

The 2013 ACG guidelines also indicate that cholecystectomy should be performed before discharge in patients with mild AP with gallstones to avoid recurrent AP[35]. However, cholecystectomy must be postponed in necrotizing biliary AP until active inflammation and fluid collection are managed or stabilized. Asymptomatic pseudocysts and necrosis did not require intervention. In cases of infected necrosis, if the patient's condition is stable, drainage interventions should be postponed for at least four weeks. This period allows the contents to liquefy and forms a fibrous wall surrounding the necrosis. Minimally invasive necrosectomy is preferable to open necrosectomy in symptomatic individuals with infected necrosis. ERCP must be performed within 24 h after admission in patients with AP complicated by acute cholangitis, and pancreatic duct stents and non-steroidal anti-inflammatory drug suppositories should be used in high-risk patients to limit the risk of post-ERCP pancreatitis. Asymptomatic pancreatic and/or extrapancreatic necrosis and/or pseudocysts, regardless of their size, location, or extension, do not require intervention. In infected necrosis, if the condition of the patient is stable, surgical drainage must be postponed for at least four weeks.

The 2020 AGA guidelines focus on pancreatic necrosis[33] and align with the IAP and World Society of Emergency Surgery (WSES) guidelines on most accounts. AGA recognized the importance of surgery and recommended that in cases where clinical experience may be inadequate, patients with substantial pancreatic necrosis should be transferred to a suitable tertiary care hospital. According to the AGA 2020, direct endoscopic necrosectomy (DEN) is an option in cases of extensive necrosis and can also be used in cases of limited necrosis if the patient does not respond well to endoscopic transmural drainage. For debridement of acute necrotizing pancreatitis, minimally invasive surgical approaches should be used instead of open necrosectomy due to the lower risk of morbidity. Multiple debridement techniques should be explored, including videoscopic RP, laparoscopic transgastric, and open transgastric techniques. Distal pancreatectomy can be performed in patients with the detachment of the left pancreatic remnant after acute necrotizing necrosis of the middle body. A step-up approach involving percutaneous drainage or endoscopic transmural drainage followed by DEN and surgical debridement is practical. However, the optimal intervention may differ depending on the accessible clinical expertise.

WSES guidelines: The WSES[4] guidelines aim to provide evidence-based worldwide consensus statements on the treatment of SAP. These guidelines resulted from a special meeting of specialists at the World Congress of Emergency Surgery. According to the IAP guidelines, the WSES does not recommend regular ERCP for GSAP, although it has been suggested for cases of GSAP + cholangitis and GSAP + bile duct obstruction. Infected necrotizing pancreatitis should be treated by percutaneous endoscopic drainage (ED). Surgical approaches may be performed when conservative treatments such as percutaneous or endoscopic approaches do not improve the patient's condition. Surgical intervention is indicated for ACS, hemorrhage, and intestinal ischemia. Regarding surgery, the WSES recommends deferring the operation until four weeks after the initial stage due to better differentiation of necrosis from other vital tissues.

In terms of surgical technique, drainage is the first-line therapy; however, currently, there is not enough information to indicate the best surgical procedure (open or laparoscopic). In the presence of WON and a severed pancreatic duct, a single-stage surgical transgastric necrosectomy may be considered. Laparoscopic cholecystectomy (LCC) is recommended during index hospitalization in patients with moderate GSAP. The risk of recurrent pancreatitis is reduced when sphincterotomy and ERCP are performed during the index hospitalization, although same-admission cholecystectomy is still recommended due to the increased risk of additional biliary problems. Cholecystectomy should be avoided in acute GSAP until fluid collection is clear or stable and acute inflammation subsides.

Surgical decompression and an open abdomen (OA) can be considered for intra-abdominal hypertension/ACS if conservative and noninvasive treatments fail. Negative pressure peritoneal treatment is indicated for the OA because of its shorter duration, fewer dressing changes, and lower reexploration rates.

SUMMARY OF GUIDELINES: MEDICAL TREATMENT OPTIONS

Based on available guidelines, it is evident that the treatment of AP depends significantly on its etiology (Figure 4). The cornerstone of therapy for MSAP patients is supportive care, including resuscitation, pain management, and mobilization. Active rehydration, post-pyloric feeding, and pancreatin inhibitors are first-line therapies for AP. In the event of MSAP, a regular diet should be initiated as soon as possible after admission, and in the case of SAP, enteral nutrition should be initiated as soon as possible after admission. The most common reason for intervention is an infection, and surgery is often necessary to remove necrotic tissue once ACS and/or intestinal ischemia develop[36]. Antibiotics are not required to treat sterile necrosis, and non-operative treatment is preferred. However, antibiotics and image-guided drainage should be used as step-up treatments for patients with infections. As first-line

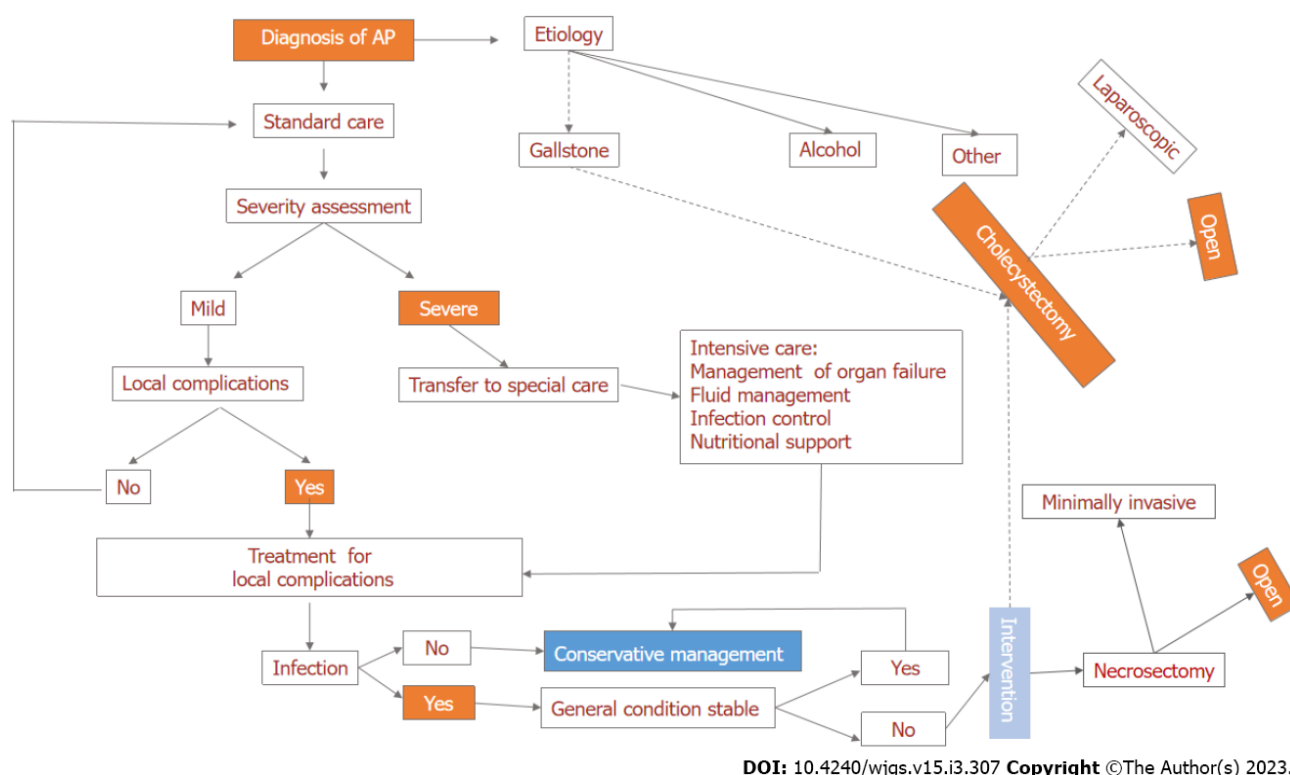


Figure 4 Flow chart of surgical management of acute pancreatitis. AP: Acute pancreatitis.

treatment, minimally invasive image-guided or ED is advised; repeated drains could be required.

Surgery should be considered when less invasive treatments fail but should be postponed until the delineation of necrotic pancreatic tissue (Table 2). Asymptomatic pseudocysts in the pancreas must be treated nonoperatively; in contrast, symptomatic, infectious, or expanding pseudocysts require surgical intervention. Unless there is a strong clinical suspicion of sepsis, fine-needle aspiration (FNA) should be avoided because of the risk of contamination of an otherwise sterile sample; however, in the case of suspected infected necrosis, an image-guided FNA with culture should be performed to distinguish it from sterile necrosis. Pancreatic necrosis may cause OF, and its treatment includes debridement or necrosectomy, peritoneal lavage, drainage, or a “step-up” technique. This step-up strategy is used primarily to treat WON. It consists of prior draining (either endoscopic or percutaneous), followed by a waiting period to allow the wall to mature and debridement using endoscopic or minimally invasive surgical approaches[37]. Due to high mortality, infectious complications, and prolonged hospitalization [38], open surgery is recommended only when the step-up approach fails. Furthermore, in the event of IPN, surgical interventions should be performed after a few weeks (preferably four) of onset to allow the collection to be ‘walled off’. Percutaneous drainage can provide adequate source control of necrosis in most individuals (23%-47 %). Open debridement with external drainage is still used in cases where less invasive treatments have failed or are not an option.

ERCP should be performed within 48 h in patients with persistent or progressive bile duct obstruction (as suspected clinically, biochemically, and/or radiologically) or cholangitis. Percutaneous transhepatic gallbladder drainage should be considered if ERCP is impractical. Cholecystectomy should be performed in patients with mild AP during their first hospital stay (same-admission cholecystectomy approach) but not in patients with severe AP until their clinical state has improved. If cholecystectomy is contraindicated due to medical comorbidities, patients with GSAP should undergo ERCP and sphincterotomy before discharge to prevent recurrence until the interval for which cholecystectomy is deemed feasible and safe. Cholecystectomy is considered safe and feasible in most cases of biliary pancreatitis; however, the risks of biliary damage and postoperative leakage of bile must be considered. It is essential to realize that each intervention for the management of AP has specific indications with benefits and downsides that must be considered in a case-specific manner[10,29,30,39].

SURGICAL DECISION TARGETS (DECISION-MAKING MAP)

The first step after confirming the diagnosis of AP (by at least two out of the diagnostic triad) should be the differential diagnosis of AP by ruling out other major conditions that have overlapping clinical (epigastric abdominal pain radiating to the back) and biochemical (hyperamylasemia) diagnostic criteria

Table 2 Summary of key surgical recommendations in different guidelines for acute pancreatitis management

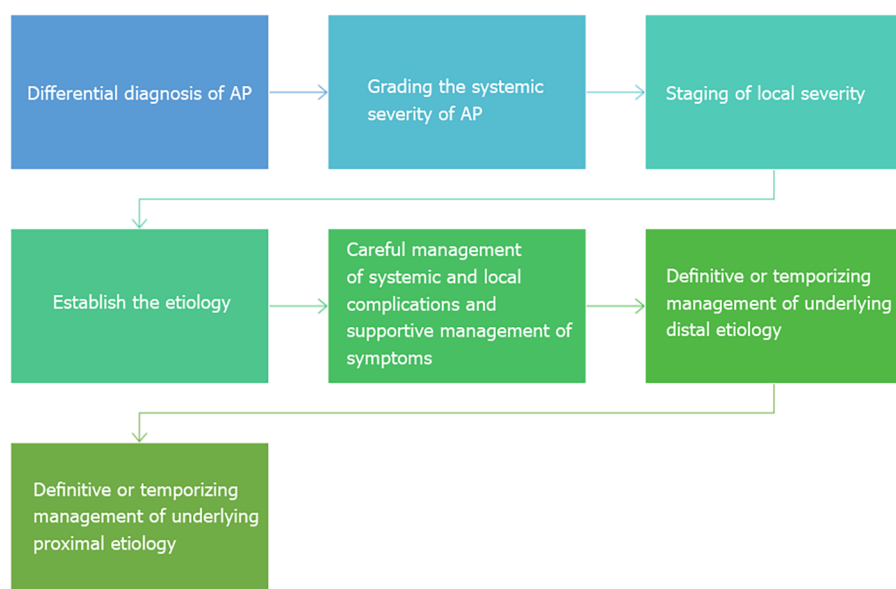
IAP ¹ (grade A and B)[31]	WSES ² (grade 1A, 1B, or 1C)[4]	AGA (pancreatic necrosis)[33]
Mild AP is not an indication for pancreatic surgery (grade B recommendation)	Routine ERCP is not indicated (1A)	Drainage and/or debridement of pancreatic necrosis is indicated in patients with IPN
IPN in patients with clinical signs and symptoms of sepsis is an indication for intervention (recommendation grade B)	ERCP is indicated in patients with GSAP and cholangitis (1B)	Pancreatic debridement should be avoided in the early, acute period (first two weeks)
Early surgery is not recommended within 14 d after the onset of the disease in patients with necrotic pancreatitis (recommendation grade B)	Clinical deterioration with signs of INP is an indication of intervention (1C)	Percutaneous and transmural ED are both appropriate first-line nonsurgical approaches to the management of patients with WON
Interventional management should favor an organ-preserving approach (grade B recommendation)	As a continuum in a step-up approach after percutaneous/endoscopic procedure (1C)	Percutaneous drainage of pancreatic necrosis should be considered in patients with infected or symptomatic necrotic collections in the early acute period (< 2 wk)
ES is an alternative to cholecystectomy in those who are not fit to undergo surgery (grade B recommendation)	In IPN, percutaneous drainage as the first-line of treatment (1A)	SEMS in the form of LAMS appears superior to plastic stents for endoscopic transmural drainage of necrosis
	Minimally invasive surgical strategies result in fewer postoperative new-onset OF (1B)	The use of DEN should be reserved for those patients with limited necrosis and not responding to endoscopic transmural drainage
	Laparoscopic cholecystectomy is recommended during index admission in mild GSAP (1A)	Minimally invasive operative approaches to the debridement of IPN are preferred to open approaches
	The risk of recurrent pancreatitis is reduced when ERCP and sphincterotomy are performed during index admission (1B)	
	Over-resuscitation of patients with early SAP should be avoided; intra-abdominal pressure monitoring is necessary (1C)	A step-up approach consisting of percutaneous drainage or endoscopic transmural drainage, followed by DEN, and then surgical debridement is reasonable
	OA should be avoided if other strategies can be used to manage IAH (1C)	
	Not to use OA after necrosectomy (1C)	
	Not to debride or perform an early necrosectomy if forced to perform an early OA due to ACS (1A)	
		For patients with disconnected left pancreatic remnants after acute necrotizing mid-body necrosis, definitive surgical management with distal pancreatectomy can be performed

¹Grade A: Strong evidence that requires a meta-analysis of randomized controlled trials or at least one randomized controlled trial (evidence categories Ia and Ib); Grade B: Intermediate evidence, requires nonrandomized clinical studies (evidence categories IIa, IIb, and III).

²Grading of recommendations assessment 1A: Strong recommendation, high-quality evidence; 1B: Strong recommendation, moderate-quality evidence; 1C: Strong recommendation, low-quality or very low-quality evidence.

ACS: Abdominal compartment syndrome; AP: Acute pancreatitis; DEN: Direct endoscopic necrosectomy; ES: Endoscopic sphincterotomy; LAMS: Lumen-apposing metal stents; OA: Open abdomen; SAP: Severe acute pancreatitis; SEMS: Self-expanding metal stents; VARD: Video-assisted retroperitoneal debridement; WON: Walled-off necrosis; ERCP: Endoscopic retrograde cholangiopancreatography; IPN: Infected pancreatic necrosis; IAP: International Association of Pancreatology; WSES: World Society of Emergency Surgery; AGA: American Gastroenterological Association; GSAP: Gallstone-associated acute pancreatitis; INP: Infected necrotizing pancreatitis; ED: Endoscopic drainage.

of AP, such as mesenteric ischemia, perforated viscus, inferior wall myocardial infarction, and lower lobar pneumonia, confirming that the diagnosis of AP is not enough. It is still necessary and essential to rule out these serious differentials, as AP itself can be a contributing trigger factor of these differentials (AP can cause aspiration leading to lower lobar pneumonia and affect the portal vein/superior mesenteric vein junction in its inflammatory process, which causes portal vein thrombosis and venous mesenteric ischemia, or unstable angina can lead to a full-blown inferior wall myocardial infarction due to sheer physiological stress and increased demand for cardiac output and oxygen delivery) (Figure 5). Grading the systemic severity of AP, with careful monitoring of hemodynamic stability and OF, and staging of local severity by differentiating between edematous/interstitial and necrotizing types of AP are also crucial at this stage. Once these problems are resolved, the focus should shift to the etiology of AP, the cautious management of systemic and local consequences, and the prioritization of symptomatic support. When the etiology is established, definitive or temporizing management of the underlying distal etiology, for example, by performing preoperative common bile duct exploration and clearance for persistent choledocholithiasis (clinical, biochemical, and/or radiological indicators of persistent



DOI: 10.4240/wjgs.v15.i3.307 Copyright ©The Author(s) 2023.

Figure 5 Decision-making targets in the surgical management of acute pancreatitis (decision-making map). AP: Acute pancreatitis.

biliary/ampullary obstruction) by ERCP, should be attempted, followed by definitive or temporizing management of the underlying proximal etiology, such as cholecystectomy to prevent recurrence of biliary/ampullary obstruction. Finally, malignant obstruction (biliary, ampullary, or pancreatodochal) can be the most proximal etiology and should always be ruled out.

COMMENTARY ON KEY SURGICAL PROCEDURES FOR AP

MSAP and SAP are related to local or systemic sequelae such as peripancreatic fluid accumulation, which presents a risk of compressive or pressure symptoms, organ damage, and mortality[29]. The publication of clinical trials and case reports has increased consistently over the last few decades (Figure 6). The subsequent section reviews some of the most contemporary results of lavage and drainage, necrosectomy, ERCP, and biliary surgery, focusing on open, endoscopic, and percutaneous techniques.

Lavage and drainage

Endoscopic, percutaneous, and open surgical drainage are among the different methods of drainage, each with its own set of benefits and drawbacks[40]. For the first time, Freeny *et al*[41] presented a unique method known as the step-up technique aimed at gradually controlling infections rather than rapidly removing necrosis. It is based on percutaneous catheter drainage (PCD), which is considered the least invasive procedure for managing necrosis of infected AP, with reduced length of stay [intensive care unit (ICU) and hospital], hemorrhage, mortality, fistulas, and OF, compared to open surgery[42,43].

PCD is not optimal as an early invasive intervention or treatment and is recommended at least four weeks later when necrosis is expected to form a wrap. A retrospective cohort study addressed this issue and described a novel insert catheter approach known as abdominal paracentesis drainage (APD)[44]. APD can lower intestinal barrier damage and SAP severity[45]. Early treatment by APD reduces the release of inflammatory factors and improves the prognosis. Furthermore, in MSAP or SAP, APD does not increase infection or mortality complications compared to a strategy without APD[46].

A recent meta-analysis found that APD significantly reduced all-cause mortality, length of hospital stay, and procedure cost compared to conventional follow-up treatment, with no discernible differences in the risk of infection or OF[29]. Another study examined the function of APD before PCD as a variation of the step-up strategy. The use of APD before PCD is also effective in managing AP with abdominal fluid accumulation; however, the conditions under which APD should be used have not been thoroughly explained[47].

According to most international guidelines, catheter drainage should be delayed until the “WON stage” is achieved, which usually takes four weeks after the onset of AP. Interestingly, the practicality of surgical necrosectomy is the primary basis for this advice. van Grinsven *et al*[48] argued that deferring drainage may not be necessary and that early drainage of infected necrosis may improve the results. However, a multicenter randomized superiority trial did not indicate that early drainage was preferable to delayed drainage in terms of complications in cases of IPN[49]. Another recent study compared

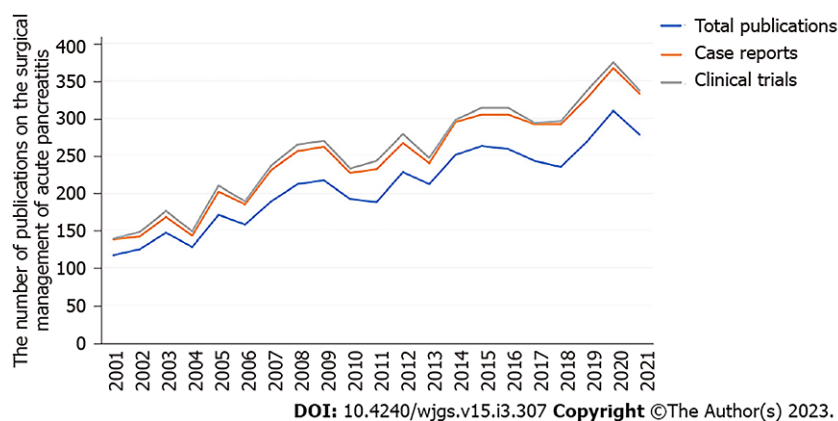


Figure 6 Year-wise growth in the number of publications on the surgical management of acute pancreatitis.

combined endoscopic and percutaneous drainage for necrotic fluid collection (NFC) in the “early” and “late” drainage groups. The study found that early draining of NFC is feasible and safe when performed in a tertiary care facility with therapeutic endoscopic US proficiency[50]. These findings underscore the importance of clinical competence in treating complicated AP.

PCD is usually performed under US or computed tomography (CT) guidance. A study examined the effectiveness of the US/CT image fusion guide, reporting that the US/CT-PCD group showed significantly fewer puncture-related problems, shorter hospital stays and intubation time, and lower treatment costs than the US-PCD group. The authors concluded that for PCD, the US/CT image fusion guide is a reliable approach for SAP with infected WON[51].

EUS-TD has progressed from the involvement of multiple plastic stents to fully covered self-expanding metal stents and lumen-apposing metal stents (LAMS), resulting in a number of procedural and therapeutic advantages without increasing total treatment costs[52]. In early AP, transluminal ED is associated with a shorter resolution period and lower requirement for salvage surgery than PCD[53]. Furthermore, regardless of infection, EUS-guided drainage (EUS-D) has been shown to offer advantages over PCD in terms of clinical success and faster resolution of WON[54]. Prolonged OF is more frequently an indication of PCD in ANC than in WON, although suspected infection is more commonly an indication in WON than in ANC[55]. A study comparing RP and transperitoneal (TP) found that both are safe and effective, although TP has a higher clinical success rate[56].

Another study examined the efficacy of minimally invasive endoscopic procedures in treating IPN. The mortality rate did not differ significantly; however, the incidence of enteral or pancreaticoduodenal fistulas was much lower in the endoscopic group. Furthermore, in the endoscopic approach group, physical health scores for quality of life (QoL) were higher, and the mean total cost of treatment was lower[57]. A systematic review compared the effects of ED with various surgical drainage procedures in necrotizing pancreatitis, indicating that ED had a lower incidence of fistula development than other surgical drainage methods[58]. Another study found that the use of a minimally invasive draining technique in patients with IPN was associated with shorter stays in the ICU and hospital[59].

A systematic review compared endoscopic and surgical treatments in patients with infected walled necrosis. There were no differences in mortality; however, the endoscopic group had fewer new-onset OF and perforations or fistulas[60]. Another study revealed that the endoscopic method could provide superior QoL to surgical necrosectomy[61].

Necrosectomy

The standard therapy for infected pancreatitis necrosis is open necrosectomy, which helps remove necrotic tissue and drain contaminated compartments. The upfront approach has recently gained popularity because of its low mortality and morbidity risks. A prospective multicenter randomized trial found that open necrosectomy was associated with a higher incidence of new-onset multiple OF and mortality equivalent to the step-up approach[37]. In response to further improvements, a one-step laparoscopic pancreatic necrosectomy was developed, with a shorter hospital stay than the surgical step-up group but no equivalent mortality or morbidity burden[62]. Infracolonic necrosectomy and selective Roux-en-Y cystjejunostomy have also been reported as safe operational alternatives for difficult SAP that are not susceptible to drainage/debridement using standard procedures[63].

Endoscopic, minimally invasive, and video-assisted retroperitoneal techniques for debridement have gained increasing attention in recent decades, with an emphasis on reducing mortality and morbidity. A meta-analysis found that endoscopic therapy, as opposed to minimally invasive surgery, substantially reduced complications in patients with infected necrotizing pancreatitis[64]. Recently, Xiao *et al*[65] examined the efficacy of open necrosectomy, minimally invasive surgery, and the endoscopic step-up technique, indicating that the endoscopic step-up group had fewer complications and shorter hospital

stay.

Step-up procedures have become the standard therapy for WON based on extensive evidence from randomized controlled trials[66-69]; however, it is crucial to be wary of pancreatic fistulas and stent-related problems during the endoscopic step-up approach[70]. It should also be noted that there is currently no harmonized strategy for the endoscopic treatment of pancreatic necrosis that considers local knowledge, anatomical characteristics of necrosis, and concomitant disorders[30].

According to Minami *et al*[71], in cases of infected ANC/WON, the open necrosectomy may be performed if clinically necessary. Recently, Jagielski *et al*[72] showed that percutaneous endoscopic necrosectomy (PEN) using self-expanding esophageal metal stents (SEMS) is potentially efficacious and has an acceptable incidence of complications. Ke *et al*[73] verified that the use of SEMS during PEN techniques reduced hospital stay, new-onset sepsis, and duration of the procedure. It should be noted that ED and direct endoscopic necrosectomy (DEN) have been the preferred treatment techniques since the discovery of LAMS, especially when there is considerable solid debris or infection[74]. However, because long-term problems after DEN are comparable to those observed after pancreatectomy, Kim *et al*[75] cautioned that DEN should be performed methodically while avoiding injury to viable pancreatic tissues with appropriate antibiotic escalation. Although the postoperative QoL of patients after minimally invasive pancreatic interventions has not yet been identified, it is widely accepted that customized interventional surgical therapy should be attempted in SAP management to obtain the best clinical and QoL outcomes[76-78].

ERCP and biliary surgery

If gallstones are confirmed to be the source of the problem, cholecystectomy is recommended to avoid repeated episodes and, perhaps, biliary sepsis. It is important to note that GSAP improves when the stone is removed. Novikov *et al*[79] examined all patients admitted to a nationwide inpatient sample for GSAP between 2004 and 2014. These findings support early ERCP in patients with GSAP but without cholangitis. A systematic review evaluated the clinical utility of early ERCP *vs* early conservative therapy in conjunction with ERCP in selected cases, reporting the absence of significant advantages of early routine ERCP in terms of mortality or local or systemic pancreatitis[80]. A randomized controlled study compared the composite outcomes of immediate ERCP with sphincterotomy and conservative treatment in patients with severe GSAP. Compared to conservative therapy, immediate ERCP with sphincterotomy did not reduce the composite outcome[81]. Other studies have also not demonstrated the benefits of early ERCP with biliary sphincterotomy in improving the prognosis of patients with GSAP who do not have associated cholangitis[39,82].

A study examined whether LCC can prevent recurring acute IAP. During surgery, biliary stones or sludge was found in 23/39 (59%) patients, and the authors concluded that when all other plausible causes of pancreatitis were ruled out, LCC could successfully prevent the recurrence of IAP[83]. Faur *et al*[84] investigated the effects of early biliary decompression using a minimally invasive method in patients with acute biliary pancreatitis.

CONCLUSION

Most patients with AP have a moderate, self-limiting, and straightforward clinical course. Mild and life-threatening sequelae, local and systemic, include pancreatic and/or peripancreatic fluid collections, walled necrosis, and IPN. Surgical complication management has undergone a dramatic transformation in recent decades. Patients with sterile necrosis who experience symptoms need intervention less often than those with infected necrosis. Pancreatic necrosis has traditionally been treated by open necrosectomy; however, in recent decades, less invasive methods, including endoscopic treatments, have become the norm. Technological advancements have improved the safety and effectiveness of endoscopic operations. However, certain problems still require further correction. Unfortunately, there is no standardized endoscopic approach or protocol for the treatment of various types and complications of SAP, considering parameters such as clinical competence, infection management, anatomical characteristics of necrosis, and comorbidity profiles. The lack of knowledge of the biology of the disease has also resulted in a scarcity of pharmacological and surgical treatment options for AP. Furthermore, controlled studies are required to determine the efficacy of etiology-specific intervention therapy on outcomes such as recurrent AP, treatment costs, progression to chronic pancreatitis and cancer, QoL, and mortality.

FOOTNOTES

Author contributions: Alzerwi N conducted literature review, analysis, and manuscript writing.

Conflict-of-interest statement: All the authors report no relevant conflicts of interest for this article.

Open-Access: This article is an open-access article that was selected by an in-house editor and fully peer-reviewed by external reviewers. It is distributed in accordance with the Creative Commons Attribution NonCommercial (CC BY-NC 4.0) license, which permits others to distribute, remix, adapt, build upon this work non-commercially, and license their derivative works on different terms, provided the original work is properly cited and the use is non-commercial. See: <https://creativecommons.org/licenses/by-nc/4.0/>

Country/Territory of origin: Saudi Arabia

ORCID number: Nasser Alzerwi 0000-0002-4877-2152.

S-Editor: Wang JJ

L-Editor: Wang TQ

P-Editor: Wang JJ

REFERENCES

- 1 Heckler M, Hackert T, Hu K, Halloran CM, Büchler MW, Neoptolemos JP. Severe acute pancreatitis: surgical indications and treatment. *Langenbecks Arch Surg* 2021; **406**: 521-535 [PMID: 32910276 DOI: 10.1007/s00423-020-01944-6]
- 2 Forsmark CE, Vege SS, Wilcox CM. Acute Pancreatitis. *N Engl J Med* 2016; **375**: 1972-1981 [PMID: 27959604 DOI: 10.1056/NEJMr1505202]
- 3 Bugiantella W, Rondelli F, Boni M, Stella P, Polistena A, Sanguinetti A, Avenia N. Necrotizing pancreatitis: A review of the interventions. *Int J Surg* 2016; **28** Suppl 1: S163-S171 [PMID: 26708848 DOI: 10.1016/j.ijssu.2015.12.038]
- 4 Leppäniemi A, Tolonen M, Tarasconi A, Segovia-Lohse H, Gamberini E, Kirkpatrick AW, Ball CG, Parry N, Sartelli M, Wolbrink D, van Goor H, Baiocchi G, Ansaloni L, Biffi W, Coccolini F, Di Saverio S, Kluger Y, Moore E, Catena F. 2019 WSES guidelines for the management of severe acute pancreatitis. *World J Emerg Surg* 2019; **14**: 27 [PMID: 31210778 DOI: 10.1186/s13017-019-0247-0]
- 5 Petrov MS, Yadav D. Global epidemiology and holistic prevention of pancreatitis. *Nat Rev Gastroenterol Hepatol* 2019; **16**: 175-184 [PMID: 30482911 DOI: 10.1038/s41575-018-0087-5]
- 6 Iannuzzi JP, King JA, Leong JH, Quan J, Windsor JW, Tanyingoh D, Coward S, Forbes N, Heitman SJ, Shaheen AA, Swain M, Buie M, Underwood FE, Kaplan GG. Global Incidence of Acute Pancreatitis Is Increasing Over Time: A Systematic Review and Meta-Analysis. *Gastroenterology* 2022; **162**: 122-134 [PMID: 34571026 DOI: 10.1053/j.gastro.2021.09.043]
- 7 Cappell MS. Acute pancreatitis: etiology, clinical presentation, diagnosis, and therapy. *Med Clin North Am* 2008; **92**: 889-923, ix [PMID: 18570947 DOI: 10.1016/j.mcna.2008.04.013]
- 8 Wu H, Ma K, Liao B, Ji T, Zhang S, Cao T. Comparative Analysis of Early Clinical Features and Complications of Different Types of Acute Pancreatitis. *Oxid Med Cell Longev* 2022; **2022**: 3771610 [PMID: 35795856 DOI: 10.1155/2022/3771610]
- 9 Lee JK, Enns R. Review of idiopathic pancreatitis. *World J Gastroenterol* 2007; **13**: 6296-6313 [PMID: 18081217 DOI: 10.3748/wjg.v13.i47.6296]
- 10 Walkowska J, Zielinska N, Tubbs RS, Podgórski M, Dłubek-Ruxer J, Olewnik Ł. Diagnosis and Treatment of Acute Pancreatitis. *Diagnostics (Basel)* 2022; **12** [PMID: 36010324 DOI: 10.3390/diagnostics12081974]
- 11 Fitz RH. Acute Pancreatitis - A Consideration of Pancreatic Hemorrhage, Hemorrhagic, Suppurative, and Gangrenous Pancreatitis, and of Disseminated Fat-Necrosis. *Boston Med Surg* 1889; **181** [DOI: 10.1056/NEJM188902211200801]
- 12 Ranson JH, Rifkind KM, Roses DF, Fink SD, Eng K, Localio SA. Objective early identification of severe acute pancreatitis. *Am J Gastroenterol* 1974; **61**: 443-451 [PMID: 4835417]
- 13 Bradley EL 3rd. A clinically based classification system for acute pancreatitis. Summary of the International Symposium on Acute Pancreatitis, Atlanta, Ga, September 11 through 13, 1992. *Arch Surg* 1993; **128**: 586-590 [PMID: 8489394 DOI: 10.1001/archsurg.1993.01420170122019]
- 14 Banks PA, Bollen TL, Dervenis C, Gooszen HG, Johnson CD, Sarr MG, Tsiotis GG, Vege SS; Acute Pancreatitis Classification Working Group. Classification of acute pancreatitis--2012: revision of the Atlanta classification and definitions by international consensus. *Gut* 2013; **62**: 102-111 [PMID: 23100216 DOI: 10.1136/gutjnl-2012-302779]
- 15 Dellinger EP, Forsmark CE, Laver P, Lévy P, Maravi-Poma E, Petrov MS, Shimosegawa T, Siriwardena AK, Uomo G, Whitcomb DC, Windsor JA; Pancreatitis Across Nations Clinical Research and Education Alliance (PANCREA). Determinant-based classification of acute pancreatitis severity: an international multidisciplinary consultation. *Ann Surg* 2012; **256**: 875-880 [PMID: 22735715 DOI: 10.1097/SLA.0b013e318256f778]
- 16 Szatmary P, Grammatikopoulos T, Cai W, Huang W, Mukherjee R, Halloran C, Beyer G, Sutton R. Acute Pancreatitis: Diagnosis and Treatment. *Drugs* 2022; **82**: 1251-1276 [PMID: 36074322 DOI: 10.1007/s40265-022-01766-4]
- 17 Ravi Kanth V, Nageshwar Reddy D. Genetics of acute and chronic pancreatitis: An update. *World J Gastrointest Pathophysiol* 2014; **5**: 427-437 [PMID: 25400986 DOI: 10.4291/wjgp.v5.i4.427]
- 18 Zheng Z, Ding YX, Qu YX, Cao F, Li F. A narrative review of acute pancreatitis and its diagnosis, pathogenetic mechanism, and management. *Ann Transl Med* 2021; **9**: 69 [PMID: 33553362 DOI: 10.21037/atm-20-4802]
- 19 Sah RP, Dawra RK, Saluja AK. New insights into the pathogenesis of pancreatitis. *Curr Opin Gastroenterol* 2013; **29**: 523-530 [PMID: 23892538 DOI: 10.1097/MOG.0b013e328363e399]
- 20 Sah RP, Garg P, Saluja AK. Pathogenic mechanisms of acute pancreatitis. *Curr Opin Gastroenterol* 2012; **28**: 507-515 [PMID: 22885948 DOI: 10.1097/MOG.0b013e3283567f52]

- 21 **Pannala R**, Kidd M, Modlin IM. Acute pancreatitis: a historical perspective. *Pancreas* 2009; **38**: 355-366 [PMID: 19390402 DOI: 10.1097/MPA.0b013e318199161c]
- 22 **Navarro S**. Historical review of our knowledge of acute pancreatitis. *Gastroenterol Hepatol* 2018; **41**: 143.e1-143.e10 [PMID: 29249269 DOI: 10.1016/j.gastrohep.2017.11.004]
- 23 **Rocha FG**, Balakrishnan A, Ashley SW, Clancy TE. A historic perspective on the contributions of surgeons to the understanding of acute pancreatitis. *Am J Surg* 2008; **196**: 442-449 [PMID: 18718223 DOI: 10.1016/j.amjsurg.2008.01.028]
- 24 **Stern CD**. A historical perspective on the discovery of the accessory duct of the pancreas, the ampulla 'of Vater' and pancreas divisum. *Gut* 1986; **27**: 203-212 [PMID: 3512385 DOI: 10.1136/gut.27.2.203]
- 25 **Howard JM**, Hess W, Traverso W. Johann Georg Wirsüng (1589-1643) and the pancreatic duct: the prosector of Padua, Italy. *J Am Coll Surg* 1998; **187**: 201-211 [PMID: 9704970 DOI: 10.1016/s1072-7515(98)00136-7]
- 26 **Senn N**. Surgery of the pancreas as based upon experiments and clinical researches. *Trans An Surg Assoc* 1886; **4**: 99-123
- 27 **Rashid MU**, Hussain I, Jehanzeb S, Ullah W, Ali S, Jain AG, Khetpal N, Ahmad S. Pancreatic necrosis: Complications and changing trend of treatment. *World J Gastrointest Surg* 2019; **11**: 198-217 [PMID: 31123558 DOI: 10.4240/wjgs.v11.i4.198]
- 28 **Bradley EL 3rd**, Dexter ND. Management of severe acute pancreatitis: a surgical odyssey. *Ann Surg* 2010; **251**: 6-17 [PMID: 20009748 DOI: 10.1097/SLA.0b013e3181c72b79]
- 29 **Lu Z**, Zhu X, Hua T, Zhang J, Xiao W, Jia D, Yang M. Efficacy and safety of abdominal paracentesis drainage on patients with acute pancreatitis: a systematic review and meta-analysis. *BMJ Open* 2021; **11**: e045031 [PMID: 34373293 DOI: 10.1136/bmjopen-2020-045031]
- 30 **Feng L**, Guo J, Wang S, Liu X, Ge N, Wang G, Sun S. Endoscopic Transmural Drainage and Necrosectomy in Acute Necrotizing Pancreatitis: A Review. *J Transl Int Med* 2021; **9**: 168-176 [PMID: 34900627 DOI: 10.2478/jtim-2021-0031]
- 31 **Working Group IAP/APA Acute Pancreatitis Guidelines**. IAP/APA evidence-based guidelines for the management of acute pancreatitis. *Pancreatology* 2013; **13**: e1-15 [PMID: 24054878 DOI: 10.1016/j.pan.2013.07.063]
- 32 **Crockett SD**, Wani S, Gardner TB, Falck-Ytter Y, Barkun AN; American Gastroenterological Association Institute Clinical Guidelines Committee. American Gastroenterological Association Institute Guideline on Initial Management of Acute Pancreatitis. *Gastroenterology* 2018; **154**: 1096-1101 [PMID: 29409760 DOI: 10.1053/j.gastro.2018.01.032]
- 33 **Baron TH**, DiMaio CJ, Wang AY, Morgan KA. American Gastroenterological Association Clinical Practice Update: Management of Pancreatic Necrosis. *Gastroenterology* 2020; **158**: 67-75.e1 [PMID: 31479658 DOI: 10.1053/j.gastro.2019.07.064]
- 34 **Yokoe M**, Takada T, Mayumi T, Yoshida M, Isaji S, Wada K, Itoi T, Sata N, Gabata T, Igarashi H, Kataoka K, Hirota M, Kadoya M, Kitamura N, Kimura Y, Kiriya S, Shirai K, Hattori T, Takeda K, Takeyama Y, Sekimoto M, Shikata S, Arata S, Hirata K. Japanese guidelines for the management of acute pancreatitis: Japanese Guidelines 2015. *J Hepatobiliary Pancreat Sci* 2015; **22**: 405-432 [PMID: 25973947 DOI: 10.1002/jhbp.259]
- 35 **Tenner S**, Baillie J, DeWitt J, Vege SS; American College of Gastroenterology. American College of Gastroenterology guideline: management of acute pancreatitis. *Am J Gastroenterol* 2013; **108**: 1400-15; 1416 [PMID: 23896955 DOI: 10.1038/ajg.2013.218]
- 36 **Dai JY**, Yin L, Xu J, Walline JH, Lv CZ, Zhao XD, Yu XZ. Expert consensus on emergency diagnosis and treatment procedures for acute upper gastrointestinal bleeding. *J Acute Dis* 2020; **9**: 231-243 [DOI: 10.4103/2221-6189.299177]
- 37 **van Santvoort HC**, Besselink MG, Bakker OJ, Hofker HS, Boermeester MA, Dejong CH, van Goor H, Schaapherder AF, van Eijck CH, Bollen TL, van Ramshorst B, Nieuwenhuijs VB, Timmer R, Laméris JS, Kruyt PM, Manusama ER, van der Harst E, van der Schelling GP, Karsten T, Hesselink EJ, van Laarhoven CJ, Rosman C, Bosscha K, de Wit RJ, Houdijk AP, van Leeuwen MS, Buskens E, Gooszen HG; Dutch Pancreatitis Study Group. A step-up approach or open necrosectomy for necrotizing pancreatitis. *N Engl J Med* 2010; **362**: 1491-1502 [PMID: 20410514 DOI: 10.1056/NEJMoa0908821]
- 38 **Uhl W**, Warshaw A, Imrie C, Bassi C, McKay CJ, Lankisch PG, Carter R, Di Magno E, Banks PA, Whitcomb DC, Dervenis C, Ulrich CD, Satake K, Ghaneh P, Hartwig W, Werner J, McEntee G, Neoptolemos JP, Büchler MW; International Association of Pancreatology. IAP Guidelines for the Surgical Management of Acute Pancreatitis. *Pancreatology* 2002; **2**: 565-573 [PMID: 12435871 DOI: 10.1159/000071269]
- 39 **Shrestha DB**, Budhathoki P, Sedhai YR, Adhikari A, Poudel A, Aryal BB, Gurung TM, Karki B, Karki BR, Patel D. Urgent Endoscopic Retrograde Cholangiopancreatography (ERCP) vs. Conventional Approach in Acute Biliary Pancreatitis Without Cholangitis: An Updated Systematic Review and Meta-Analysis. *Cureus* 2022; **14**: e21342 [PMID: 35198265 DOI: 10.7759/cureus.21342]
- 40 **Bansal A**, Gupta P, Singh AK, Shah J, Samanta J, Mandavdhare HS, Sharma V, Sinha SK, Dutta U, Sandhu MS, Kochhar R. Drainage of pancreatic fluid collections in acute pancreatitis: A comprehensive overview. *World J Clin Cases* 2022; **10**: 6769-6783 [PMID: 36051118 DOI: 10.12998/wjcc.v10.i20.6769]
- 41 **Freney PC**, Hauptmann E, Althaus SJ, Traverso LW, Sinanan M. Percutaneous CT-guided catheter drainage of infected acute necrotizing pancreatitis: techniques and results. *AJR Am J Roentgenol* 1998; **170**: 969-975 [PMID: 9530046 DOI: 10.2214/ajr.170.4.9530046]
- 42 **Zhang ZH**, Ding YX, Wu YD, Gao CC, Li F. A meta-analysis and systematic review of percutaneous catheter drainage in treating infected pancreatitis necrosis. *Medicine (Baltimore)* 2018; **97**: e12999 [PMID: 30461605 DOI: 10.1097/MD.00000000000012999]
- 43 A meta-analysis and systematic review of percutaneous catheter drainage in treating infected pancreatitis necrosis: Erratum. *Medicine (Baltimore)* 2019; **98**: e14457 [PMID: 30732211 DOI: 10.1097/MD.00000000000014457]
- 44 **Liu WH**, Ren LN, Chen T, Liu LY, Jiang JH, Wang T, Xu C, Yan HT, Zheng XB, Song FQ, Tang LJ. Abdominal paracentesis drainage ahead of percutaneous catheter drainage benefits patients attacked by acute pancreatitis with fluid collections: a retrospective clinical cohort study. *Crit Care Med* 2015; **43**: 109-119 [PMID: 25251762 DOI: 10.1097/CCM.0000000000000606]
- 45 **Yuan X**, Luo C, Wu J, Li W, Guo X, Li S, Wang B, Sun H, Tang L. Abdominal paracentesis drainage attenuates intestinal mucosal barrier damage through macrophage polarization in severe acute pancreatitis. *Exp Biol Med (Maywood)* 2021; **246**:

- 2029-2038 [PMID: 34053233 DOI: 10.1177/15353702211015144]
- 46 **Liu L**, Yan H, Liu W, Cui J, Wang T, Dai R, Liang H, Luo H, Tang L. Abdominal Paracentesis Drainage Does Not Increase Infection in Severe Acute Pancreatitis: A Prospective Study. *J Clin Gastroenterol* 2015; **49**: 757-763 [PMID: 26053169 DOI: 10.1097/MCG.0000000000000358]
 - 47 **Zerem E**, Kunosić S, Zerem D, Boloban A, Zerem O, Zlomuzica E. Benefits of abdominal paracentesis drainage performed ahead of percutaneous catheter drainage as a modification of the step-up approach in acute pancreatitis with fluid collections. *Acta Gastroenterol Belg* 2020; **83**: 285-293 [PMID: 32603048]
 - 48 **van Grinsven J**, van Santvoort HC, Boermeester MA, Dejong CH, van Eijck CH, Fockens P, Besselink MG; Dutch Pancreatitis Study Group. Timing of catheter drainage in infected necrotizing pancreatitis. *Nat Rev Gastroenterol Hepatol* 2016; **13**: 306-312 [PMID: 26956064 DOI: 10.1038/nrgastro.2016.23]
 - 49 **Boxhoorn L**, van Dijk SM, van Grinsven J, Verdonk RC, Boermeester MA, Bollen TL, Bouwense SAW, Bruno MJ, Cappendijk VC, Dejong CHC, van Duijvendijk P, van Eijck CHJ, Fockens P, Francken MFG, van Goor H, Hadithi M, Hallensleben NDL, Haveman JW, Jacobs MAJM, Jansen JM, Kop MPM, van Lienden KP, Manusama ER, Mieog JSD, Molenaar IQ, Nieuwenhuijs VB, Poen AC, Poley JW, van de Poll M, Quispel R, Römkens TEH, Schwartz MP, Seerden TC, Stommel MWJ, Straathof JWA, Timmerhuis HC, Venneman NG, Voermans RP, van de Vrie W, Witteman BJ, Dijkgraaf MGW, van Santvoort HC, Besselink MG; Dutch Pancreatitis Study Group. Immediate versus Postponed Intervention for Infected Necrotizing Pancreatitis. *N Engl J Med* 2021; **385**: 1372-1381 [PMID: 34614330 DOI: 10.1056/NEJMoa2100826]
 - 50 **Bomman S**, Sanders D, Coy D, La Selva D, Pham Q, Zehr T, Law J, Larsen M, Irani S, Kozarek RA, Ross A, Krishnamoorthi R. Safety and clinical outcomes of early dual modality drainage (< 28 days) compared to later drainage of pancreatic necrotic fluid collections: a propensity score-matched study. *Surg Endosc* 2022 [PMID: 36038648 DOI: 10.1007/s00464-022-09561-8]
 - 51 **Zhang H**, Chen GY, Xiao L, Ma X, Shi L, Wang T, Yan HT, Zou H, Chen Q, Tang LJ, Liu WH. Ultrasonic/CT image fusion guidance facilitating percutaneous catheter drainage in treatment of acute pancreatitis complicated with infected walled-off necrosis. *Pancreatol* 2018; **18**: 635-641 [PMID: 29954676 DOI: 10.1016/j.pan.2018.06.004]
 - 52 **Falk V**, Kenshil S, Sandha S, Teshima C, D'Souza P, Sandha G. The Evolution of EUS-Guided Transluminal Drainage for the Treatment of Pancreatic Fluid Collections: A Comparison of Clinical and Cost Outcomes with Double-Pigtail Plastic Stents, Conventional Metal Stents and Lumen-Apposing Metal Stents. *J Can Assoc Gastroenterol* 2020; **3**: 26-35 [PMID: 34169224 DOI: 10.1093/jcag/gwy049]
 - 53 **Rana SS**, Verma S, Kang M, Gorski U, Sharma R, Gupta R. Comparison of endoscopic versus percutaneous drainage of symptomatic pancreatic necrosis in the early (< 4 weeks) phase of illness. *Endosc Ultrasound* 2020; **9**: 402-409 [PMID: 33318376 DOI: 10.4103/eus.eus_65_20]
 - 54 **Samanta J**, Dhar J, Muktesh G, Gupta P, Kumar-M P, Das A, Agarwala R, Bellam BL, Chauhan R, Kumar KH, Yadav TD, Gupta V, Sinha SK, Kochhar R, Facciorusso A. Endoscopic drainage versus percutaneous drainage for the management of infected walled-off necrosis: a comparative analysis. *Expert Rev Gastroenterol Hepatol* 2022; **16**: 297-305 [PMID: 35227141 DOI: 10.1080/17474124.2022.2047649]
 - 55 **Mallick B**, Dhaka N, Gupta P, Gulati A, Malik S, Sinha SK, Yadav TD, Gupta V, Kochhar R. An audit of percutaneous drainage for acute necrotic collections and walled off necrosis in patients with acute pancreatitis. *Pancreatol* 2018; **18**: 727-733 [PMID: 30146334 DOI: 10.1016/j.pan.2018.08.010]
 - 56 **Verma N**, Maurya M, Gupta P, Samanta J, Mandavdhare H, Sharma V, Dutta U, Kochhar R. Retroperitoneal versus transperitoneal percutaneous catheter drainage of necrotic pancreatic collections: a comparative analysis. *Abdom Radiol (NY)* 2022; **47**: 1899-1906 [PMID: 35286420 DOI: 10.1007/s00261-022-03476-7]
 - 57 **Bang JY**, Arnoletti JP, Holt BA, Sutton B, Hasan MK, Navaneethan U, Feranec N, Wilcox CM, Tharian B, Hawes RH, Varadarajulu S. An Endoscopic Transluminal Approach, Compared With Minimally Invasive Surgery, Reduces Complications and Costs for Patients With Necrotizing Pancreatitis. *Gastroenterology* 2019; **156**: 1027-1040.e3 [PMID: 30452918 DOI: 10.1053/j.gastro.2018.11.031]
 - 58 **Mohamadnejad M**, Anushiravani A, Kasaieian A, Sorouri M, Djalalinia S, Kazemzadeh Houjaghan A, Gaidhane M, Kahaleh M. Endoscopic or surgical treatment for necrotizing pancreatitis: Comprehensive systematic review and meta-analysis. *Endosc Int Open* 2022; **10**: E420-E428 [PMID: 35433210 DOI: 10.1055/a-1783-9229]
 - 59 **Darrivere L**, Lapidus N, Colignon N, Chafai N, Chaput U, Verdonk F, Paye F, Lescot T. Minimally invasive drainage in critically ill patients with severe necrotizing pancreatitis is associated with better outcomes: an observational study. *Crit Care* 2018; **22**: 321 [PMID: 30466472 DOI: 10.1186/s13054-018-2256-x]
 - 60 **Haney CM**, Kowalewski KF, Schmidt MW, Koschny R, Felinska EA, Kalkum E, Probst P, Diener MK, Müller-Stich BP, Hackert T, Nickel F. Endoscopic versus surgical treatment for infected necrotizing pancreatitis: a systematic review and meta-analysis of randomized controlled trials. *Surg Endosc* 2020; **34**: 2429-2444 [PMID: 32112252 DOI: 10.1007/s00464-020-07469-9]
 - 61 **Psaltis E**, Varghese C, Pandanaboyana S, Nayar M. Quality of life after surgical and endoscopic management of severe acute pancreatitis: A systematic review. *World J Gastrointest Endosc* 2022; **14**: 443-454 [PMID: 36051991 DOI: 10.4253/wjge.v14.i7.443]
 - 62 **Han SB**, Chen D, Chen QY, Hu P, Zheng H, Chen JH, Xu P, Wang CY, Zhao G. One-step laparoscopic pancreatic necrosectomy verse surgical step-up approach for infected pancreatic necrosis: a case-control study. *World J Emerg Med* 2022; **13**: 274-282 [PMID: 35837558 DOI: 10.5847/wjem.j.1920-8642.2022.058]
 - 63 **Latif J**, Creedon L, Mistry P, Thurley P, Bhatti I, Awan A. Complicated Severe Acute Pancreatitis: Open and Laparoscopic Infracolc Approach. *J Gastrointest Surg* 2022; **26**: 1686-1696 [PMID: 35581460 DOI: 10.1007/s11605-022-05350-9]
 - 64 **Bang JY**, Wilcox CM, Arnoletti JP, Varadarajulu S. Superiority of endoscopic interventions over minimally invasive surgery for infected necrotizing pancreatitis: meta-analysis of randomized trials. *Dig Endosc* 2020; **32**: 298-308 [PMID: 31220368 DOI: 10.1111/den.13470]
 - 65 **Xiao J**, Quan X, Liu F, Li W. Comparison of Different Surgical Methods for Necrotizing Pancreatitis: A Meta-Analysis. *Front Surg* 2021; **8**: 723605 [PMID: 34631782 DOI: 10.3389/fsurg.2021.723605]

- 66 **van Brunschot S**, van Grinsven J, van Santvoort HC, Bakker OJ, Besselink MG, Boermeester MA, Bollen TL, Bosscha K, Bouwense SA, Bruno MJ, Cappendijk VC, Consten EC, Dejong CH, van Eijck CH, Erkelens WG, van Goor H, van Grevenstein WMU, Haveman JW, Hofker SH, Jansen JM, Laméris JS, van Lienden KP, Meijssen MA, Mulder CJ, Nieuwenhuijs VB, Poley JW, Quispel R, de Ridder RJ, Römkens TE, Scheepers JJ, Schepers NJ, Schwartz MP, Seerden T, Spanier BWM, Straathof JWA, Strijker M, Timmer R, Venneman NG, Vleggaar FP, Voermans RP, Witteman BJ, Gooszen HG, Dijkgraaf MG, Fockens P; Dutch Pancreatitis Study Group. Endoscopic or surgical step-up approach for infected necrotising pancreatitis: a multicentre randomised trial. *Lancet* 2018; **391**: 51-58 [PMID: [29108721](#) DOI: [10.1016/S0140-6736\(17\)32404-2](#)]
- 67 **Gurusamy KS**, Belgaumkar AP, Haswell A, Pereira SP, Davidson BR. Interventions for necrotising pancreatitis. *Cochrane Database Syst Rev* 2016; **4**: CD011383 [PMID: [27083933](#) DOI: [10.1002/14651858.CD011383.pub2](#)]
- 68 **Wroński M**, Cebulski W, Witkowski B, Jankowski M, Kluciński A, Krasnodębski IW, Słodkowski M. Comparison between minimally invasive and open surgical treatment in necrotizing pancreatitis. *J Surg Res* 2017; **210**: 22-31 [PMID: [28457332](#) DOI: [10.1016/j.jss.2016.10.022](#)]
- 69 **Cao F**, Li A, Wang X, Gao C, Li J, Li F. Laparoscopic transgastric necrosectomy in treatment of walled-off pancreatic necrosis with sinistral portal hypertension. *BMC Surg* 2021; **21**: 362 [PMID: [34629061](#) DOI: [10.1186/s12893-021-01361-6](#)]
- 70 **Xiao NJ**, Cui TT, Liu F, Li W. Current status of treatments of pancreatic and peripancreatic collections of acute pancreatitis. *World J Gastrointest Surg* 2021; **13**: 633-644 [PMID: [34354797](#) DOI: [10.4240/wjgs.v13.i7.633](#)]
- 71 **Minami K**, Horibe M, Sanui M, Sasaki M, Iwasaki E, Sawano H, Goto T, Ikeura T, Takeda T, Oda T, Yasuda H, Ogura Y, Miyazaki D, Kitamura K, Chiba N, Ozaki T, Yamashita T, Koinuma T, Oshima T, Yamamoto T, Hirota M, Tokuhira N, Azumi Y, Nagata K, Takeda K, Furuya T, Lefor AK, Mayumi T, Kanai T. The Effect of an Invasive Strategy for Treating Pancreatic Necrosis on Mortality: a Retrospective Multicenter Cohort Study. *J Gastrointest Surg* 2020; **24**: 2037-2045 [PMID: [31428962](#) DOI: [10.1007/s11605-019-04333-7](#)]
- 72 **Jagielski M**, Chwarscianek A, Piątkowski J, Jackowski M. Percutaneous Endoscopic Necrosectomy-A Review of the Literature. *J Clin Med* 2022; **11** [PMID: [35887696](#) DOI: [10.3390/jcm11143932](#)]
- 73 **Ke L**, Li G, Wang P, Mao W, Lin J, Gao L, Ye B, Zhou J, Tong Z, Li W, Windsor J. The efficacy and efficiency of stent-assisted percutaneous endoscopic necrosectomy for infected pancreatic necrosis: a pilot clinical study using historical controls. *Eur J Gastroenterol Hepatol* 2021; **33**: e435-e441 [PMID: [33731580](#) DOI: [10.1097/MEG.0000000000002127](#)]
- 74 **Pinto S**, Bellizzi S, Badas R, Canfora ML, Loddo E, Spada S, Khalaf K, Fugazza A, Bergamini S. Direct Endoscopic Necrosectomy: Timing and Technique. *Medicina (Kaunas)* 2021; **57** [PMID: [34946249](#) DOI: [10.3390/medicina57121305](#)]
- 75 **Kim YS**, Cho JH, Cho DH, Park SW, Moon SH, Park JS, Lee YN, Lee SS. Long-term Outcomes of Direct Endoscopic Necrosectomy for Complicated or Symptomatic Walled-Off Necrosis: A Korean Multicenter Study. *Gut Liver* 2021; **15**: 930-939 [PMID: [33767033](#) DOI: [10.5009/gnl20304](#)]
- 76 **Del Chiaro M**, Rangelova E, Segersvärd R, Arnelo U. Are there still indications for total pancreatectomy? *Updates Surg* 2016; **68**: 257-263 [PMID: [27605208](#) DOI: [10.1007/s13304-016-0388-6](#)]
- 77 **Di Candio G**, Guadagni S, Furbetta N, Gianardi D, Palmeri M, Di Franco G, Bianchini M, Gambaccini D, Marciano E, Cervelli R, Marchi S, Morelli L. A "tailored" interventional and surgical management for moderate to critical acute pancreatitis in late phase: a cohort study. *Langenbecks Arch Surg* 2022; **407**: 2833-2841 [PMID: [35639137](#) DOI: [10.1007/s00423-022-02557-x](#)]
- 78 **Zelga P**, Rees J, Iaculli E, Johnson C, Jah A. Patient-reported outcomes after minimally invasive retroperitoneal pancreatic necrosectomy to treat acute pancreatitis: An exploratory study. *J Dig Dis* 2021; **22**: 604-614 [PMID: [34331420](#) DOI: [10.1111/1751-2980.13036](#)]
- 79 **Novikov AA**, Fieber JH, Saumoy M, Rosenblatt R, Mekelburg SAC, Shah SL, Crawford CV Jr. ERCP improves mortality in acute biliary pancreatitis without cholangitis. *Endosc Int Open* 2021; **9**: E927-E933 [PMID: [34079880](#) DOI: [10.1055/a-1320-0041](#)]
- 80 **Tse F**, Yuan Y. Early routine endoscopic retrograde cholangiopancreatography strategy versus early conservative management strategy in acute gallstone pancreatitis. *Cochrane Database Syst Rev* 2012; CD009779 [PMID: [22592743](#) DOI: [10.1002/14651858.CD009779.pub2](#)]
- 81 **Schepers NJ**, Hallensleben ND, Besselink MG, Anten MGF, Bollen TL, da Costa DW, van Delft F, van Dijk SM, van Dullemen HM, Dijkgraaf MGW, van Eijck CHJ, Erkelens GW, Erler NS, Fockens P, van Geenen EJM, van Grinsven J, Hollemans RA, van Hooft JE, van der Hulst RWM, Jansen JM, Kubben FJGM, Kuiken SD, Laheij RJF, Quispel R, de Ridder RJ, Rijk MCM, Römkens TEH, Ruigrok CHM, Schoon EJ, Schwartz MP, Smeets XJNM, Spanier BWM, Tan ACITL, Thijs WJ, Timmer R, Venneman NG, Verdonk RC, Vleggaar FP, van de Vrie W, Witteman BJ, van Santvoort HC, Bakker OJ, Bruno MJ; Dutch Pancreatitis Study Group. Urgent endoscopic retrograde cholangiopancreatography with sphincterotomy versus conservative treatment in predicted severe acute gallstone pancreatitis (APEC): a multicentre randomised controlled trial. *Lancet* 2020; **396**: 167-176 [PMID: [32682482](#) DOI: [10.1016/S0140-6736\(20\)30539-0](#)]
- 82 **Birda CL**, Agarwal A. Role of ERCP in acute biliary pancreatitis: yet unanswered. *Endosc Int Open* 2021; **9**: E1917 [PMID: [34917462](#) DOI: [10.1055/a-1591-0833](#)]
- 83 **Räty S**, Pulkkinen J, Nordback I, Sand J, Victorzon M, Grönroos J, Helminen H, Kuusanmäki P, Nordström P, Paajanen H. Can Laparoscopic Cholecystectomy Prevent Recurrent Idiopathic Acute Pancreatitis? *Ann Surg* 2015; **262**: 736-741 [PMID: [26583660](#) DOI: [10.1097/SLA.0000000000001469](#)]
- 84 **Faur M**, Fleaca SR, Gherman CD, Bacila CI, Tanasescu D, Serban D, Tribus LC, Tudor C, Smarandache GC, Costea DO, Tudose MS, Sabau D, Gangura GA, Tanasescu C. Optimal Timing and Outcomes of Minimally Invasive Approach in Acute Biliary Pancreatitis. *Med Sci Monit* 2022; **28**: e937016 [PMID: [35794808](#) DOI: [10.12659/MSM.937016](#)]



Published by **Baishideng Publishing Group Inc**
7041 Koll Center Parkway, Suite 160, Pleasanton, CA 94566, USA

Telephone: +1-925-3991568

E-mail: bpgoffice@wjgnet.com

Help Desk: <https://www.f6publishing.com/helpdesk>

<https://www.wjgnet.com>

