

World Journal of *Gastrointestinal Surgery*

World J Gastrointest Surg 2023 March 27; 15(3): 307-494



Contents

Monthly Volume 15 Number 3 March 27, 2023

MINIREVIEWS

- 307 Surgical management of acute pancreatitis: Historical perspectives, challenges, and current management approaches
Alzerwi N
- 323 Current trends in perioperative treatment of resectable gastric cancer
Yıldız İ, Özer L, Şenocak Taşçı E, Bayoglu İV, Aytac E
- 338 Vascular injury during laparoscopic cholecystectomy: An often-overlooked complication
Pesce A, Fabbri N, Feo CV

ORIGINAL ARTICLE

Basic Study

- 346 Differential expression and significance of 5-hydroxymethylcytosine modification in hepatitis B virus carriers and patients with liver cirrhosis and liver cancer
Li YC, Hu WY, Li CH, Zhang LL, Xu XW, Li J, Luo HX

Retrospective Cohort Study

- 362 Compliance with enhanced recovery after surgery predicts long-term outcome after hepatectomy for cholangiocarcinoma
Jongkatkorn C, Luvira V, Suwanprinya C, Piampatipan K, Leeratanakachorn N, Tipwaratorn T, Titapun A, Srisuk T, Theeragul S, Jarearnrat A, Thanasukarn V, Pughkem A, Khuntikeo N, Pairojkul C, Kamsa-Ard S, Bhudhisawasdi V
- 374 Pain management in patients with hepatocellular carcinoma after transcatheter arterial chemoembolisation: A retrospective study
Guan Y, Tian Y, Fan YW

Retrospective Study

- 387 Risk factors and prediction model for inpatient surgical site infection after elective abdominal surgery
Zhang J, Xue F, Liu SD, Liu D, Wu YH, Zhao D, Liu ZM, Ma WX, Han RL, Shan L, Duan XL
- 398 Percutaneous management in hepatic alveolar echinococcosis: A sum of single center experiences and a brief overview of the literature
Eren S, Aydın S, Kantarci M, Kızılgöz V, Levent A, Şenbil DC, Akhan O
- 408 Clinical features of acute esophageal mucosal lesions and reflux esophagitis Los Angeles classification grade D: A retrospective study
Ichita C, Sasaki A, Shimizu S
- 420 Positive correlation between latent Epstein-Barr virus infection and severity of illness in inflammatory bowel disease patients
Wei HT, Xue XW, Ling Q, Wang PY, Zhou WX

Clinical Trials Study

- 430** Efficacy and outcome of extensive intraoperative peritoneal lavage plus surgery *vs* surgery alone with advanced gastric cancer patients

Song ED, Xia HB, Zhang LX, Ma J, Luo PQ, Yang LZ, Xiang BH, Zhou BC, Chen L, Sheng H, Fang Y, Han WX, Wei ZJ, Xu AM

Randomized Controlled Trial

- 440** Endoscopic mucosal resection with double band ligation versus endoscopic submucosal dissection for small rectal neuroendocrine tumors

Huang JL, Gan RY, Chen ZH, Gao RY, Li DF, Wang LS, Yao J

SYSTEMATIC REVIEWS

- 450** Preoperative risk modelling for oesophagectomy: A systematic review

Grantham JP, Hii A, Shenfine J

META-ANALYSIS

- 471** Effect of music therapy on chemotherapy-induced nausea and vomiting in gastrointestinal cancer: A systematic review and meta-analysis

Zhong FP, Zhong J, Zhong MY

CASE REPORT

- 480** Immunotherapy in combination with chemotherapy for Peutz-Jeghers syndrome with advanced cervical cancer: A case report

Hu XC, Gan CX, Zheng HM, Wu XP, Pan WS

- 488** Xanthogranulomatous inflammation requiring small bowel anastomosis revision: A case report

Wang W, Korah M, Bessoff KE, Shen J, Forrester JD

ABOUT COVER

Editorial Board Member of *World Journal of Gastrointestinal Surgery*, Valeriu Marin vsurlin, MD, Professor, Surgical Oncologist, Department of Surgery, University of Medicine and Pharmacy of Craiova, Craiova 200391, Dolj, Romania. vsurlin@gmail.com

AIMS AND SCOPE

The primary aim of *World Journal of Gastrointestinal Surgery* (WJGS, *World J Gastrointest Surg*) is to provide scholars and readers from various fields of gastrointestinal surgery with a platform to publish high-quality basic and clinical research articles and communicate their research findings online.

WJGS mainly publishes articles reporting research results and findings obtained in the field of gastrointestinal surgery and covering a wide range of topics including biliary tract surgical procedures, biliopancreatic diversion, colectomy, esophagectomy, esophagostomy, pancreas transplantation, and pancreatectomy, etc.

INDEXING/ABSTRACTING

The WJGS is now abstracted and indexed in Science Citation Index Expanded (SCIE, also known as SciSearch®), Current Contents/Clinical Medicine, Journal Citation Reports/Science Edition, PubMed, PubMed Central, Reference Citation Analysis, China National Knowledge Infrastructure, China Science and Technology Journal Database, and Superstar Journals Database. The 2022 Edition of Journal Citation Reports® cites the 2021 impact factor (IF) for WJGS as 2.505; IF without journal self cites: 2.473; 5-year IF: 3.099; Journal Citation Indicator: 0.49; Ranking: 104 among 211 journals in surgery; Quartile category: Q2; Ranking: 81 among 93 journals in gastroenterology and hepatology; and Quartile category: Q4.

RESPONSIBLE EDITORS FOR THIS ISSUE

Production Editor: Rui-Rui Wu; Production Department Director: Xiang Li; Editorial Office Director: Jia-Ru Fan.

NAME OF JOURNAL

World Journal of Gastrointestinal Surgery

ISSN

ISSN 1948-9366 (online)

LAUNCH DATE

November 30, 2009

FREQUENCY

Monthly

EDITORS-IN-CHIEF

Peter Schemmer

EDITORIAL BOARD MEMBERS

<https://www.wjgnet.com/1948-9366/editorialboard.htm>

PUBLICATION DATE

March 27, 2023

COPYRIGHT

© 2023 Baishideng Publishing Group Inc

INSTRUCTIONS TO AUTHORS

<https://www.wjgnet.com/bpg/gerinfo/204>

GUIDELINES FOR ETHICS DOCUMENTS

<https://www.wjgnet.com/bpg/GerInfo/287>

GUIDELINES FOR NON-NATIVE SPEAKERS OF ENGLISH

<https://www.wjgnet.com/bpg/gerinfo/240>

PUBLICATION ETHICS

<https://www.wjgnet.com/bpg/GerInfo/288>

PUBLICATION MISCONDUCT

<https://www.wjgnet.com/bpg/gerinfo/208>

ARTICLE PROCESSING CHARGE

<https://www.wjgnet.com/bpg/gerinfo/242>

STEPS FOR SUBMITTING MANUSCRIPTS

<https://www.wjgnet.com/bpg/GerInfo/239>

ONLINE SUBMISSION

<https://www.f6publishing.com>



Vascular injury during laparoscopic cholecystectomy: An often-overlooked complication

Antonio Pesce, Nicolò Fabbri, Carlo Vittorio Feo

Specialty type: Surgery

Provenance and peer review:

Invited article; Externally peer reviewed.

Peer-review model: Single blind

Peer-review report's scientific quality classification

Grade A (Excellent): 0
Grade B (Very good): 0
Grade C (Good): C, C
Grade D (Fair): 0
Grade E (Poor): 0

P-Reviewer: Chuang SH, Taiwan;
Cochior D, Romania

Received: November 27, 2022

Peer-review started: November 27, 2022

First decision: December 26, 2022

Revised: January 5, 2023

Accepted: February 22, 2023

Article in press: February 22, 2023

Published online: March 27, 2023



Antonio Pesce, Nicolò Fabbri, Carlo Vittorio Feo, Department of Surgery, University of Ferrara, Azienda USL of Ferrara, Azienda USL of Ferrara, Lagosanto 44023, Ferrara, Italy

Corresponding author: Antonio Pesce, FACS, MD, PhD, Research Fellow, Surgeon, Department of Surgery, University of Ferrara, Azienda USL of Ferrara, Azienda USL of Ferrara, 2 Via Valle Oppio, Lagosanto 44023, Ferrara, Italy. antonio.pesce@ausl.fe.it

Abstract

Laparoscopic cholecystectomy is one of the most frequently performed procedures in gastrointestinal surgery worldwide. Bleeding complications due to vascular injuries represent an important cause of morbidity and mortality, especially when facing major bleeding during laparoscopy, where bleeding control can be technically challenging in inexperienced hands. Interestingly, the reported incidence rate of conversion to open surgery due to vascular lesions is approximately 0%-1.9%, with a mortality rate of approximately 0.02%. The primary aim of this article was to perform an up-to-date overview regarding the incidence and surgical management of vascular injuries during laparoscopic cholecystectomy according to the available scientific evidence.

Key Words: Laparoscopic cholecystectomy; Vascular injury; Vascular anomalies; Surgical management; Specialized hepatobiliary centers

©The Author(s) 2023. Published by Baishideng Publishing Group Inc. All rights reserved.

Core Tip: The theme of biliary injuries in laparoscopic cholecystectomy and the prevention and management of bile duct lesions have been extensively examined. However, little attention has been given to vascular injuries. Bleeding complications due to vascular injuries represent an important cause of morbidity and mortality, as well as the negative outcomes of biliary reconstruction when associated with biliary injuries. The vascular lesions should be correctly identified, and surgeons must choose the best therapeutic option to quickly repair the vascular lesion, depending on their own surgical experience and medical center resources. Currently, the management of referrals to specialized hepatobiliary centers for multidisciplinary approaches is mandatory.

Citation: Pesce A, Fabbri N, Feo CV. Vascular injury during laparoscopic cholecystectomy: An often-overlooked complication. *World J Gastrointest Surg* 2023; 15(3): 338-345

URL: <https://www.wjgnet.com/1948-9366/full/v15/i3/338.htm>

DOI: <https://dx.doi.org/10.4240/wjgs.v15.i3.338>

INTRODUCTION

Laparoscopic cholecystectomy (LC) is one of the most frequently performed procedures in general surgery worldwide[1]. Iatrogenic vascular and bile duct injuries still represent a major public health problem related to both medico-legal implications and health care costs[1,2]. The theme of biliary injuries in laparoscopic cholecystectomy and the prevention and management of bile duct lesions have been extensively examined. However, little attention has been given to vascular lesions[3]. Bleeding complications due to vascular injuries are an important cause of morbidity and mortality, especially during laparoscopy, where bleeding control can be technically challenging in inexperienced hands. Vascular injuries during laparoscopic cholecystectomy may mainly occur during trocar or Veress needle insertion or during dissection of the hepato-cystic triangle. Interestingly, the reported incidence rate of conversion to open surgery due to intra-operative vascular lesions is approximately 0%-1.9%, with a mortality rate of approximately 0.02% [3-5]. The aim of this article was to analyze and explore the incidence, diagnosis and surgical management of vascular injuries in laparoscopic cholecystectomy according to the available scientific evidence. MEDLINE and PubMed searches were performed using the MeSH terms “vascular injury”, “vascular lesion”, “vasculo-biliary injury”, and “laparoscopic cholecystectomy” to identify relevant articles (cohort studies, systematic reviews, case reports, multicenter studies) published in English, French, Spanish, and Italian over the last twenty years.

INCIDENCE AND RISK FACTORS

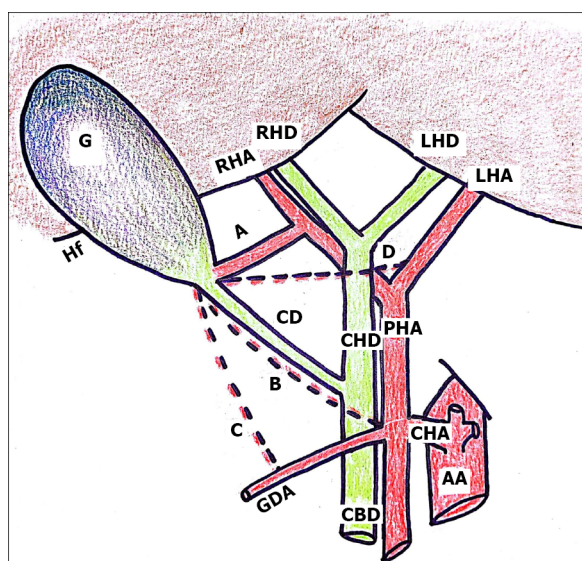
Several risk factors may contribute to vascular injuries during laparoscopic cholecystectomy: Anatomical factors, including vascular anomalies, patient-related factors, the gallbladder pathology and surgeon's experience, as summarized in Table 1. Concerning the anatomical factors, the different variants of vascular anatomy may represent a possible cause of bile duct injuries, particularly anomalies of the cystic artery and right hepatic artery (RHA). If surgeons are not aware of possible variations of the RHA, such as in the case of acute and chronic cholecystitis with unclear anatomy of Calot's triangle, the RHA may be accidentally injured or mistaken for the cystic artery and actively cut off. In a study assessing the frequency of anatomical variations of biliary and vascular systems from Singh *et al*[6], the operative findings revealed 197 (26.62%) vascular anomalies, mostly related to cystic artery and RHA anatomy. Arterial anomalies are more common, occurring in at least 50% of individuals, and can be recognized only by careful dissection[7]. Based on the classification proposed by Smadja and Blumgart [8], the cystic artery is considered normally positioned when located in the center of the hepato-cystic triangle. In a recent Spanish study performed on a sample of 2000 Laparoscopic cholecystectomy procedures, Noguera *et al*[9] found an origin of the cystic artery from the RHA in 91.5% of cases. These data are similar to those of Bergamaschi *et al*[10], where, in a study of 90 consecutive human cadavers, a single artery was found in 59 of 70 specimens (84.3% of all cases). The incidence of third structures within the hepato-cystic triangle was found to be arteries in 36.2% of cases, with a reported incidence of caterpillar hump of the RHA in 12.9% of all cases and double cystic arteries in 5.7%. The most common variations of cystic artery are shown in Figure 1, according to the literature data[7-10]. Among the patient-related factors, overweight and pathological obesity, a history of biliary surgery or endoscopic procedures, and hepatic cirrhosis or chronic liver disease appear to be factors correlated with the development of perioperative complications, both for biliary and vascular structures. However, emergent cholecystectomy for acute cholecystitis increases the risk of iatrogenic lesions, as gallbladder inflammation causes a series of anatomical changes that are associated with an increased risk of iatrogenic injury. Ultimately, the surgeon's experience plays an important role, and for this reason the importance of a correct “learning curve” for young surgeons should be stressed.

HEPATIC ARTERY INJURIES

Intra-operative bleeding is certainly the most common and feared complication of arterial injury during laparoscopic procedures, followed by ligation. Among hepatic artery injuries, lesions of the RHA are the most described complication that may occur during laparoscopic cholecystectomy. Hepatic artery closure is usually well tolerated without any particular consequences due to the portal flow and a dense series of collateral arterial branches coming from the hepatic hilum. However, in such cases, hepatic

Table 1 Summary of risk factors associated to vascular injuries

Anatomical factors	Description
Common vascular variants of cystic artery and right hepatic artery	Single cystic artery[6]
	Two arteries (superficial and deep)[6]
	Single short cystic artery originated from caterpillar right hepatic artery[4,5,10]
	Long single cystic artery not from right hepatic artery crossing anterior to the common hepatic duct[7,8]
	Double cystic artery/accessory cystic artery[9]
	Cystic artery seen more anteriorly than posteriorly in relation to Mascagni's lymph node[7,9]
	A constant vessel found on the postero-lateral margin of gallbladder bed[6,9]
Cystic artery coming from gastroduodenal artery, passing outside Calot's triangle[6,9]	
Patient-related factors	Overweight and pathological obesity[1]
	History of biliary surgery or endoscopic procedures[1]
	Underlying liver disease[1]
Gallbladder pathology	Acute or chronic cholecystitis[1-3]
	Gallbladder anomalies (gallbladder duplication, gallbladder agenesis, left-side gallbladder) [1-3]
Surgical experience	Learning curve[1,2]
	Inadequate exposure[1,2,6]
	Failure to recognize anatomical landmarks[2,6]



DOI: 10.4240/wjgs.v15.i3.338 **Copyright** ©The Author(s) 2023.

Figure 1 Anatomic illustration of the most common variants of cystic artery. Common variants of cystic artery. A: Cystic artery originating from the right hepatic artery in the classical position[6-8]; B: Long cystic artery seen anteriorly to the cystic duct[6,7]; C: Cystic artery coming from the gastroduodenal artery, passing outside Calot's triangle[6,9]; D: Long single cystic artery not from the right hepatic artery crossing anterior to the common hepatic duct[6,9]. RHA: Right hepatic artery; LHA: Left hepatic artery; PHA: Proper hepatic artery; CHA: Common hepatic artery; GDA: Gastroduodenal artery; G: Gallbladder; CHD: Common hepatic duct; CD: Cystic duct; CBD: Common bile duct; RHD: Right hepatic duct; LHD: Left hepatic duct; AA: Abdominal aorta.

artery ligation can sometimes cause ischemic hepatic necrosis or liver atrophy. RHA injury is frequently encountered in association with bile duct injury, even if the true incidence of RHA injury without concomitant bile duct injury is not clear[11]. In a cadaveric study, Halasz[12] reported that the incidence of injury to the RHA or its branches was only 7%. All patients survived at least one year after cholecystectomy, and they had normal livers. For this reason, the decision to immediately repair the lesion remains controversial. RHA injuries always occur in two ways: the first is when the fundus-first approach for laparoscopic cholecystectomy is performed in the presence of severe inflammation[13]; the

second is in the presence of vascular anomalies, as in the case of caterpillar hump of the RHA, where the hepatic artery may be wrongly mistaken for the cystic artery[4,5]. The most important complication of RHA injury is massive bleeding during dissection, which always leads to conversion to open surgery in inexperienced hands. In some cases, laparoscopic repair is feasible and safe[11] by suturing in cases of intra-operative bleeding or direct end-to-end anastomosis when possible in cases of ligation or clipping of the RHA.

Hepatic artery pseudoaneurysm represents another important complication after RHA injury, and it may occur in the early or late postoperative course after LC. Approximately 10% of all the reported cases of hemobilia are secondary to iatrogenic cystic artery or hepatic artery pseudoaneurysms as a consequence of an opening of cystic or RHA pseudoaneurysm within the biliary tree[14]. The exact mechanism of hepatic pseudoaneurysm formation is yet unclear: The most accredited hypotheses concern the mechanical or thermal damage during surgical dissection. Transarterial embolization represents the best therapeutic solution for hepatic artery aneurysm with a high success rate, and surgical repair should be performed in cases where the embolization attempt has failed. In many patients, an open approach in an emergency setting is performed[14], even if a laparoscopic approach is used in some cases[15].

HEPATIC VEINS, PORTAL VEIN AND MAJOR RETROPERITONEAL VESSEL INJURIES

Venous bleeding is less common than arterial bleeding. Bleeding from hepatic vein injury commonly comes from the liver bed during detachment of the gallbladder. Between 10% and 15% of patients may present a large branch of the middle hepatic vein adherent to the liver bed, leading to an increased risk of venous injury during cholecystectomy. In 1999, Misawa *et al*[16] first proposed an ultrasonographic assessment of the risk of injury to branches of the middle hepatic vein during laparoscopic cholecystectomy by analyzing the middle hepatic vein distance from the gallbladder bed before laparoscopy. Currently, there is controversy about the risk of injury to the branch of the middle hepatic vein during LC[17]. In a previous study, Zhang *et al*[18] analyzed the anatomical relationship between the gallbladder bed and the branches of the middle hepatic vein in 143 healthy volunteers by color Doppler ultrasound and found that, in most subjects, the branch of the middle hepatic vein and the gallbladder bed were well separated. Only patients with large branches of the middle hepatic vein running very close to the gallbladder bed are at risk of bleeding during laparoscopic cholecystectomy. The diameter of the distal branch of the middle hepatic vein close to the gallbladder bed is reported to vary from 0.9 mm to 3.2 mm and in some cases over 5 mm[17,19,20]. Moreover, according to Ball *et al* [19], the presence of chronic cholecystitis and fibrous tissue may increase the risk of significant bleeding from the liver bed. Concerning the treatment of venous injuries, bleeding from the middle hepatic vein branch during the operation can only be stopped by direct hemostatic stitches; it can be performed by laparoscopy in experienced hands or can often require conversion to open surgery[21]. In general, we strongly recommend careful dissection during the final steps of laparoscopic cholecystectomy, especially for training surgeons, when dissection becomes easier, and the surgeon may relax.

Portal vein injuries are frequently associated with biliary and RHA injuries. Compared with arterial injury after cholecystectomy, there are very few reports of isolated portal vein injury without associated biliary lesions[22]. Furthermore, as a result of its rarity, the pathogenesis of this type of injury remains unclear. The surgical repair of portal vein lesions is very difficult, often complicated by massive hemorrhage, and seldom successfully managed. When the portal vein is injured during surgery, it should be reconstructed immediately by an experienced hepato-biliary surgeon if the patient is hemodynamically stable. However, the most important complication after surgical repair of a portal vein injury is represented by acute portal thrombosis, often leading to liver infarction. For this reason, anticoagulation therapy should be started as soon as possible to avoid the progression of acute portal vein thrombosis. Liver transplantation is a salvage therapy that should only be considered in end-stage liver disease[22].

Injuries of major retroperitoneal vascular structures are uncommon but potentially life-threatening complications of laparoscopy[23-25]. Inferior vena cava and aorta injuries are frequently associated with trocar or Veress needle insertion during laparoscopic surgery. Early diagnosis and immediate conversion are mandatory for the proper management of these important injuries to minimize morbidity and mortality. Some authors have also described occasional injuries to the right renal artery with the formation of a pseudoaneurysm and consequent renal-vena cava fistula[26,27]. This often represents a late complication following laparoscopic cholecystectomy.

Another important medical complication associated with vena cava injury is venous air embolism [28]; the cardiovascular, pulmonary, and central nervous systems may all be affected, with severity ranging from no symptoms to immediate cardiovascular collapse.

CLASSIFICATION OF VASCULAR INJURIES

Several attempts have been made to uniformly classify vascular lesions, so they are always underreported, as summarized in Table 2. In early 2000, Schäfer *et al*[29] proposed a working classification from the Swiss Association of Laparoscopic and Thoracoscopic Surgery (SALTS) by defining vascular injuries during laparoscopy into intraoperative and postoperative bleeding complications. In 2007, Bektas *et al* [30] proposed the Hannover classification by underlining the importance of including additional vascular injury and the location of the biliary lesion at or above the bifurcation of the hepatic duct, as they were found to have a major impact on the extent of surgical intervention for iatrogenic bile duct injury. The Neuhaus and Strasberg-Bismuth classifications for biliary injuries do not consider vascular involvement.

In 2010, Kaushik[31] suggested a new classification system, wherein vascular injuries were divided into major and minor injuries based on the need for conversion, additional surgical procedures, or blood transfusions.

The European Association for Endoscopic Surgery (EAES) recently proposed a new classification named ATOM, including the anatomy of damage and vascular injury (A), timing of detection (To), and mechanism of damage (M)[32].

VASCULO-BILIARY INJURY

Vascular injury, in particular to the RHA, is found in approximately 12% to 61% of iatrogenic bile duct lesions, leading to high morbidity and mortality associated with altered quality of life[33-35]. It is very important to know preoperatively if a vascular lesion occurs along with a biliary lesion because the poor vascularization of the common bile duct may result in anastomotic strictures after surgical biliary tract repair, recurrent cholangitis and secondary biliary cirrhosis[33]. For these reasons, appropriate knowledge of the vascular lesion represents an important condition when the patient is referred to a specialized hepato-biliary center. In most cases, the surgical repair of biliary and vascular injuries is performed simultaneously. There are no guidelines for the timing of repair, whereas few studies have compared early *vs* late repair of bile duct injury[34,36,37]. In a multicenter study of the European-African Hepato Pancrea to Biliary Association (E-AHPBA), the timing of biliary reconstruction after bile duct injury with hepaticojejunostomy was not correlated with the occurrence of severe postoperative complications, re-intervention or liver-related mortality[34]. In another multicenter study, the most favorable outcomes were more frequently observed in the immediate (within the first 72 h) and (after 6 wk) reconstruction of biliary injury, and type E4 injury was found to be an independent factor of worse outcome[36]. In general, if a major bile duct transection occurs (types E1-E2 according to the Strasberg classification), the integrity of the hepatic artery, especially the RHA, should always be examined meticulously to plan early vascular reconstruction if technically possible. If revascularization is not technically feasible, biliary reconstruction close to the hilar plate is mandatory in order to minimize the possibility of anastomotic complications[38]. If the vascular lesion is discovered late, in a minority of cases, hepatectomy is needed as a salvage strategy[39,40].

DIAGNOSIS AND SURGICAL MANAGEMENT

The diagnosis of intra-operative bleeding during dissection may be obvious, but it should be correctly identified, and surgeons must choose the best therapeutic option to quickly repair the vascular lesion, depending on their own experience and medical center resources. At present, there is no clear consensus on the most suitable type or time to perform the repair, especially when vascular injury occurs in centers not specialized in complex hepato-biliary surgery; thus, the management of these complications is still a much debated topic[33]. In a recent multicenter retrospective study, the authors analyzed the management of vascular injuries during laparoscopic cholecystectomy, focusing on referral to specialized centers, time to perform the repair, and different treatment option outcomes[33]. In a cohort of 104 patients with vascular injuries, 29 patients underwent vascular repair (27.9%), 13 (12.5%) liver resection, and 1 liver transplant as a first treatment. The majority of vascular and biliary injuries occurred in non-specialized centers, and more than half were immediately transferred. The authors concluded that the management of complex vascular and biliary lesions should be mandatory in specialized centers and that late vascular repair is not necessarily associated with worse outcomes[33]. Another interesting study by Li *et al*[38] analyzed the effects of vascular reconstruction and hepatic re-arterialization when technically possible. In this study, successful early arterial reconstruction with or without a vascular graft (within 4 d) allowed recovery from hepatic ischemia, without any evidence of hepatic atrophy or necrosis during follow-up.

Table 2 Classifications of vascular injuries during laparoscopic cholecystectomy

Ref.	Definition of vascular injury
Schäfer <i>et al</i> [29], 2000	Major injury: Injury to any of the following vessels: Aorta, vena cava, portal vein, hepatic artery and splenic artery, iliac vessels, mesenteric, omental and renal vessels; the vascular injury is classified in: Intra-operative; local haemorrhage within the abdominal cavity, retroperitoneum or abdominal wall; post-operative: Bleeding occurring within 24 h after surgery
Bektas <i>et al</i> [30], 2007	Vascular involvement in different biliary injuries grades (types C and D): Type C tangential injury of the common bile duct: with or without vascular lesion; Type D complete transection of the common bile duct: with or without vascular lesion
Kaushik [31], 2010	Major injury: Any bleeding involving cystic artery, right hepatic artery, portal vein, superior mesenteric vein, suprahepatic veins, inferior vena cava, aorta that requires conversion to open surgery to control/repair; additional surgical procedures; need for blood transfusions
Fingerhut <i>et al</i> [32], 2013	Vasculo-biliary involvement by reporting the type of injured vessel
Our study	Major vascular injury: Any bleeding involving right hepatic artery, portal vein, suprahepatic veins, inferior vena cava that always requires conversion to open surgery for control/repair; need for blood transfusions; associated biliary injury; need for transfer to tertiary center

CONCLUSION

Vascular injuries represent a life-threatening complication, and they should be carefully evaluated along with biliary lesions during laparoscopic cholecystectomy. The recognition of these lesions must occur as early as possible, and the surgeon must choose the best therapeutic option for the patient according to available medical resources. Currently, the management of referrals to specialized hepato-biliary centers for multidisciplinary approaches is mandatory.

FOOTNOTES

Author contributions: Pesce A designed the research; Pesce A and Fabbri N researched and wrote the manuscript; Feo C supervised the paper; all authors have read and approved the final manuscript.

Conflict-of-interest statement: There are no conflicts of interest to report.

Open-Access: This article is an open-access article that was selected by an in-house editor and fully peer-reviewed by external reviewers. It is distributed in accordance with the Creative Commons Attribution NonCommercial (CC BY-NC 4.0) license, which permits others to distribute, remix, adapt, build upon this work non-commercially, and license their derivative works on different terms, provided the original work is properly cited and the use is non-commercial. See: <https://creativecommons.org/licenses/by-nc/4.0/>

Country/Territory of origin: Italy

ORCID number: Antonio Pesce 0000-0002-7560-551X; Nicolò Fabbri 0000-0001-7039-3717; Carlo Vittorio Feo 0000-0003-0699-5689.

S-Editor: Chen YL

L-Editor: A

P-Editor: Chen YL

REFERENCES

- 1 Pesce A, Palmucci S, La Greca G, Puleo S. Iatrogenic bile duct injury: impact and management challenges. *Clin Exp Gastroenterol* 2019; **12**: 121-128 [PMID: 30881079 DOI: 10.2147/CEG.S169492]
- 2 Pesce A, Diana M. Critical View of Safety During Laparoscopic Cholecystectomy: From the Surgeon's Eye to Fluorescent Vision. *Surg Innov* 2018; **25**: 197-198 [PMID: 29557253 DOI: 10.1177/1553350618763200]
- 3 Tzovaras G, Dervenis C. Vascular injuries in laparoscopic cholecystectomy: an underestimated problem. *Dig Surg* 2006; **23**: 370-374 [PMID: 17164583 DOI: 10.1159/000097951]
- 4 Marano L, Bartoli A, Polom K, Bellocchi R, Spaziani A, Castagnoli G. The unwanted third wheel in the Calot's triangle: Incidence and surgical significance of caterpillar hump of right hepatic artery with a systematic review of the literature. *J Minim Access Surg* 2019; **15**: 185-191 [PMID: 29737324 DOI: 10.4103/jmas.JMAS_75_18]
- 5 Pesce A, Fabbri N, Labriola R, Barbara SJ, Feo C. Moynihan's hump of the right hepatic artery: the surgeon's eye cannot recognize what mind doesn't know. *ANZ J Surg* 2022 [PMID: 36239703 DOI: 10.1111/ans.18120]
- 6 Singh K, Singh R, Kaur M. Clinical reappraisal of vasculobiliary anatomy relevant to laparoscopic cholecystectomy. *J Minim Access Surg* 2017; **13**: 273-279 [PMID: 28872096 DOI: 10.4103/jmas.JMAS_268_16]

- 7 **Scott-Conner CE**, Hall TJ. Variant arterial anatomy in laparoscopic cholecystectomy. *Am J Surg* 1992; **163**: 590-592 [PMID: [1534463](#) DOI: [10.1016/0002-9610\(92\)90563-7](#)]
- 8 **Smadja C**, Blumgart LH. The biliary tract and the anatomy of biliary exposure. In: Blumgart LH. *Surgery of the liver and biliary tract*. Edinburgh: Churchill Livingstone, 1988 [DOI: [10.1016/b978-1-4160-3256-4.50009-0](#)]
- 9 **Noguera MA**, Romero CA, Martinez AG, Diaz SRH, Rotger M, Espeche F. Findings and proposal for systematization of surgically important variations of the cystic artery based on an in vivo study of 2000 outpatient laparoscopic cholecystectomies. *Int J Morphol* 2020; **38**: 30-34 [DOI: [10.4067/s0717-95022020000100030](#)]
- 10 **Bergamaschi R**, Ignjatovic D. More than two structures in Calot's triangle. A postmortem study. *Surg Endosc* 2000; **14**: 354-357 [PMID: [10790554](#) DOI: [10.1007/s004640000154](#)]
- 11 **Fujioka S**, Fuke A, Funamizu N, Nakayoshi T, Okamoto T, Yanaga K. Laparoscopic repair for intraoperative injury of the right hepatic artery during cholecystectomy. *Asian J Endosc Surg* 2015; **8**: 75-77 [PMID: [25598060](#) DOI: [10.1111/ases.12151](#)]
- 12 **Halasz NA**. Cholecystectomy and hepatic artery injuries. *Arch Surg* 1991; **126**: 137-138 [PMID: [1992990](#) DOI: [10.1001/archsurg.1991.01410260021002](#)]
- 13 **Strasberg SM**, Gouma DJ. 'Extreme' vasculobiliary injuries: association with fundus-down cholecystectomy in severely inflamed gallbladders. *HPB (Oxford)* 2012; **14**: 1-8 [PMID: [22151444](#) DOI: [10.1111/j.1477-2574.2011.00393.x](#)]
- 14 **Alrajaji M**, Nawawi A, Jamjoom R, Qari Y, Aljiffry M. Delayed hemobilia due to hepatic artery pseudo-aneurysm: a pitfall of laparoscopic cholecystectomy. *BMC Surg* 2016; **16**: 59 [PMID: [27549188](#) DOI: [10.1186/s12893-016-0175-9](#)]
- 15 **Panda N**, Narasimhan M, Gunaraj A, Ardhani R. Laparoscopic management of post-cholecystectomy sectoral artery pseudoaneurysm. *J Minim Access Surg* 2014; **10**: 37-39 [PMID: [24501508](#) DOI: [10.4103/0972-9941.124471](#)]
- 16 **Misawa T**, Koike M, Suzuki K, Unemura Y, Murai R, Yoshida K, Kobayashi S, Yamazaki Y. Ultrasonographic assessment of the risk of injury to branches of the middle hepatic vein during laparoscopic cholecystectomy. *Am J Surg* 1999; **178**: 418-421 [PMID: [10612541](#) DOI: [10.1016/s0002-9610\(99\)00202-0](#)]
- 17 **Shen BY**, Li HW, Chen M, Zheng MH, Zang L, Jiang SM, Li JW, Jiang Y. Color Doppler ultrasonographic assessment of the risk of injury to major branch of the middle hepatic vein during laparoscopic cholecystectomy. *Hepatobiliary Pancreat Dis Int* 2003; **2**: 126-130 [PMID: [14607664](#)]
- 18 **Zhang WZ**, Shen J, Xie JX, Zhu H. Color Doppler ultrasonographic examination on the relationship between the gallbladder bed and major branch of the middle hepatic vein. *Hepatobiliary Pancreat Dis Int* 2005; **4**: 299-301 [PMID: [15908334](#)]
- 19 **Ball CG**, MacLean AR, Kirkpatrick AW, Bathe OF, Sutherland F, Debru E, Dixon E. Hepatic vein injury during laparoscopic cholecystectomy: the unappreciated proximity of the middle hepatic vein to the gallbladder bed. *J Gastrointest Surg* 2006; **10**: 1151-1155 [PMID: [16966035](#) DOI: [10.1016/j.gassur.2006.04.012](#)]
- 20 **Levi Sandri GB**, Eugeni E, Bufo A, Dominici E. Unexpected bleeding during laparoscopic cholecystectomy: a hepatic vein injury. *Surg Radiol Anat* 2017; **39**: 1061-1062 [PMID: [28314938](#) DOI: [10.1007/s00276-017-1845-8](#)]
- 21 **Santivañez JJ**, Velásquez ME, Cadena M, Vergara A. Management of Middle Hepatic Vein Injury during Laparoscopic Cholecystectomy: A Case Report. *Surg J (N Y)* 2020; **6**: e47-e48 [PMID: [32158952](#) DOI: [10.1055/s-0040-1701695](#)]
- 22 **Wang Z**, Yu L, Wang W, Xia J, Li D, Lu Y, Wang B. Therapeutic strategies of iatrogenic portal vein injury after cholecystectomy. *J Surg Res* 2013; **185**: 934-939 [PMID: [23859133](#) DOI: [10.1016/j.jss.2013.06.032](#)]
- 23 **Guloglu R**, Dilege S, Aksoy M, Alimoglu O, Yavuz N, Mihmanli M, Gulmen M. Major retroperitoneal vascular injuries during laparoscopic cholecystectomy and appendectomy. *J Laparoendosc Adv Surg Tech A* 2004; **14**: 73-76 [PMID: [15107214](#) DOI: [10.1089/109264204322973826](#)]
- 24 **Thompson JE Jr**, Bock R, Lowe DK, Moody WE 3rd. Vena cava injuries during laparoscopic cholecystectomy. *Surg Laparosc Endosc* 1996; **6**: 221-223 [PMID: [8743368](#)]
- 25 **Alcázar MT**, Ornaque I, Delgado MA, Martí C, Gil A, Montero A. [Abdominal aortic injury as a complication of laparoscopic cholecystectomy]. *Rev Esp Anesthesiol Reanim* 2004; **51**: 452-455 [PMID: [15586539](#)]
- 26 **Lemmo G**, Marrocco-Trischitta MM, Manni R, Snider F. Renal artery pseudoaneurysm and arteriovenous fistula to the inferior vena cava: a late complication following laparoscopic cholecystectomy. *Am Surg* 2002; **68**: 143-145 [PMID: [11842959](#)]
- 27 **Di Stasi C**, Pedicelli A, Manfredi R, Sallustio G. Renocaval arteriovenous fistula as a complication of laparoscopic cholecystectomy. *AJR Am J Roentgenol* 2001; **176**: 261-262 [PMID: [11133586](#) DOI: [10.2214/ajr.176.1.1760261](#)]
- 28 **Abut YC**, Eryilmaz R, Okan I, Erkalp K. Venous air embolism during laparoscopic cholecystectomy. *Minim Invasive Ther Allied Technol* 2009; **18**: 366-368 [PMID: [19929300](#) DOI: [10.3109/13645700903384443](#)]
- 29 **Schäfer M**, Lauper M, Krähenbühl L. A nation's experience of bleeding complications during laparoscopy. *Am J Surg* 2000; **180**: 73-77 [PMID: [11036146](#) DOI: [10.1016/s0002-9610\(00\)00416-5](#)]
- 30 **Bektas H**, Schrem H, Winny M, Klempnauer J. Surgical treatment and outcome of iatrogenic bile duct lesions after cholecystectomy and the impact of different clinical classification systems. *Br J Surg* 2007; **94**: 1119-1127 [PMID: [17497652](#) DOI: [10.1002/bjs.5752](#)]
- 31 **Kaushik R**. Bleeding complications in laparoscopic cholecystectomy: Incidence, mechanisms, prevention and management. *J Minim Access Surg* 2010; **6**: 59-65 [PMID: [20877476](#) DOI: [10.4103/0972-9941.68579](#)]
- 32 **Fingerhut A**, Dziri C, Garden OJ, Gouma D, Millat B, Neugebauer E, Paganini A, Targarona E. ATOM, the all-inclusive, nominal EAES classification of bile duct injuries during cholecystectomy. *Surg Endosc* 2013; **27**: 4608-4619 [PMID: [23892759](#) DOI: [10.1007/s00464-013-3081-6](#)]
- 33 **Lopez-Lopez V**, Kuemmerli C, Cutillas J, Maupoey J, López-Andujar R, Ramos E, Mils K, Valdivieso A, Valero AP, Martinez PA, Paterna S, Serrablo A, Reese T, Oldhafer K, Brusadin R, Conesa AL, Valladares LD, Loinaz C, Garcés-Albir M, Sabater L, Mocchegiani F, Vivarelli M, Pérez SA, Flores B, Lucena JL, Sánchez-Cabús S, Calero A, Mingüillon A, Ramia JM, Alcazar C, Aguilo J, Ruiperez-Valiente JA, Grochola LF, Clavien PA, Petrowsky H, Robles-Campos R. Vascular injury during cholecystectomy: A multicenter critical analysis behind the drama. *Surgery* 2022; **172**: 1067-1075 [PMID: [35965144](#) DOI: [10.1016/j.surg.2022.06.020](#)]

- 34 **A European-African HepatoPancreatoBiliary Association (E-AHPBA) Research Collaborative Study management group**; Other members of the European-African HepatoPancreatoBiliary Association Research Collaborative. Post cholecystectomy bile duct injury: early, intermediate or late repair with hepaticojejunostomy - an E-AHPBA multi-center study. *HPB (Oxford)* 2019; **21**: 1641-1647 [PMID: [31151812](#) DOI: [10.1016/j.hpb.2019.04.003](#)]
- 35 **Strasberg SM**, Helton WS. An analytical review of vasculobiliary injury in laparoscopic and open cholecystectomy. *HPB (Oxford)* 2011; **13**: 1-14 [PMID: [21159098](#) DOI: [10.1111/j.1477-2574.2010.00225.x](#)]
- 36 **El Nakeeb A**, Sultan A, Ezzat H, Attia M, Abd ElWahab M, Kayed T, Hassanen A, AlMalki A, Alqarni A, Mohammed MM. Impact of referral pattern and timing of repair on surgical outcome after reconstruction of post-cholecystectomy bile duct injury: A multicenter study. *Hepatobiliary Pancreat Dis Int* 2021; **20**: 53-60 [PMID: [33268245](#) DOI: [10.1016/j.hbpd.2020.10.001](#)]
- 37 **Conde Monroy D**, Torres Gómez P, Rey Chaves CE, Recamán A, Pardo M, Sabogal JC. Early versus delayed reconstruction for bile duct injury a multicenter retrospective analysis of a hepatopancreaticobiliary group. *Sci Rep* 2022; **12**: 11609 [PMID: [35804006](#) DOI: [10.1038/s41598-022-15978-x](#)]
- 38 **Li J**, Frilling A, Nadalin S, Paul A, Malagò M, Broelsch CE. Management of concomitant hepatic artery injury in patients with iatrogenic major bile duct injury after laparoscopic cholecystectomy. *Br J Surg* 2008; **95**: 460-465 [PMID: [18161898](#) DOI: [10.1002/bjs.6022](#)]
- 39 **Furtado R**, Yoshino O, Muralidharan V, Perini MV, Wigmore SJ. Hepatectomy after bile duct injury: a systematic review. *HPB (Oxford)* 2022; **24**: 161-168 [PMID: [34702627](#) DOI: [10.1016/j.hpb.2021.09.012](#)]
- 40 **Moldovan C**, Cochior D, Gorecki G, Rusu E, Ungureanu FD. Clinical and surgical algorithm for managing iatrogenic bile duct injuries during laparoscopic cholecystectomy: A multicenter study. *Exp Ther Med* 2021; **22**: 1385 [PMID: [34650633](#) DOI: [10.3892/etm.2021.10821](#)]



Published by **Baishideng Publishing Group Inc**
7041 Koll Center Parkway, Suite 160, Pleasanton, CA 94566, USA

Telephone: +1-925-3991568

E-mail: bpgoffice@wjgnet.com

Help Desk: <https://www.f6publishing.com/helpdesk>

<https://www.wjgnet.com>

