

World Journal of *Gastrointestinal Surgery*

World J Gastrointest Surg 2023 March 27; 15(3): 307-494



Contents

Monthly Volume 15 Number 3 March 27, 2023

MINIREVIEWS

- 307 Surgical management of acute pancreatitis: Historical perspectives, challenges, and current management approaches
Alzerwi N
- 323 Current trends in perioperative treatment of resectable gastric cancer
Yıldız İ, Özer L, Şenocak Taşçı E, Bayoglu İV, Aytac E
- 338 Vascular injury during laparoscopic cholecystectomy: An often-overlooked complication
Pesce A, Fabbri N, Feo CV

ORIGINAL ARTICLE

Basic Study

- 346 Differential expression and significance of 5-hydroxymethylcytosine modification in hepatitis B virus carriers and patients with liver cirrhosis and liver cancer
Li YC, Hu WY, Li CH, Zhang LL, Xu XW, Li J, Luo HX

Retrospective Cohort Study

- 362 Compliance with enhanced recovery after surgery predicts long-term outcome after hepatectomy for cholangiocarcinoma
Jongkatkorn C, Luvira V, Suwanprinya C, Piampatipan K, Leeratanakachorn N, Tipwaratorn T, Titapun A, Srisuk T, Theeragul S, Jarearnrat A, Thanasukarn V, Pughkem A, Khuntikeo N, Pairojkul C, Kamsa-Ard S, Bhudhisawasdi V
- 374 Pain management in patients with hepatocellular carcinoma after transcatheter arterial chemoembolisation: A retrospective study
Guan Y, Tian Y, Fan YW

Retrospective Study

- 387 Risk factors and prediction model for inpatient surgical site infection after elective abdominal surgery
Zhang J, Xue F, Liu SD, Liu D, Wu YH, Zhao D, Liu ZM, Ma WX, Han RL, Shan L, Duan XL
- 398 Percutaneous management in hepatic alveolar echinococcosis: A sum of single center experiences and a brief overview of the literature
Eren S, Aydın S, Kantarci M, Kızılgöz V, Levent A, Şenbil DC, Akhan O
- 408 Clinical features of acute esophageal mucosal lesions and reflux esophagitis Los Angeles classification grade D: A retrospective study
Ichita C, Sasaki A, Shimizu S
- 420 Positive correlation between latent Epstein-Barr virus infection and severity of illness in inflammatory bowel disease patients
Wei HT, Xue XW, Ling Q, Wang PY, Zhou WX

Clinical Trials Study

- 430** Efficacy and outcome of extensive intraoperative peritoneal lavage plus surgery *vs* surgery alone with advanced gastric cancer patients

Song ED, Xia HB, Zhang LX, Ma J, Luo PQ, Yang LZ, Xiang BH, Zhou BC, Chen L, Sheng H, Fang Y, Han WX, Wei ZJ, Xu AM

Randomized Controlled Trial

- 440** Endoscopic mucosal resection with double band ligation versus endoscopic submucosal dissection for small rectal neuroendocrine tumors

Huang JL, Gan RY, Chen ZH, Gao RY, Li DF, Wang LS, Yao J

SYSTEMATIC REVIEWS

- 450** Preoperative risk modelling for oesophagectomy: A systematic review

Grantham JP, Hii A, Shenfine J

META-ANALYSIS

- 471** Effect of music therapy on chemotherapy-induced nausea and vomiting in gastrointestinal cancer: A systematic review and meta-analysis

Zhong FP, Zhong J, Zhong MY

CASE REPORT

- 480** Immunotherapy in combination with chemotherapy for Peutz-Jeghers syndrome with advanced cervical cancer: A case report

Hu XC, Gan CX, Zheng HM, Wu XP, Pan WS

- 488** Xanthogranulomatous inflammation requiring small bowel anastomosis revision: A case report

Wang W, Korah M, Bessoff KE, Shen J, Forrester JD

ABOUT COVER

Editorial Board Member of *World Journal of Gastrointestinal Surgery*, Valeriu Marin Şrlin, MD, Professor, Surgical Oncologist, Department of Surgery, University of Medicine and Pharmacy of Craiova, Craiova 200391, Dolj, Romania. vsurlin@gmail.com

AIMS AND SCOPE

The primary aim of *World Journal of Gastrointestinal Surgery* (WJGS, *World J Gastrointest Surg*) is to provide scholars and readers from various fields of gastrointestinal surgery with a platform to publish high-quality basic and clinical research articles and communicate their research findings online.

WJGS mainly publishes articles reporting research results and findings obtained in the field of gastrointestinal surgery and covering a wide range of topics including biliary tract surgical procedures, biliopancreatic diversion, colectomy, esophagectomy, esophagostomy, pancreas transplantation, and pancreatectomy, etc.

INDEXING/ABSTRACTING

The WJGS is now abstracted and indexed in Science Citation Index Expanded (SCIE, also known as SciSearch®), Current Contents/Clinical Medicine, Journal Citation Reports/Science Edition, PubMed, PubMed Central, Reference Citation Analysis, China National Knowledge Infrastructure, China Science and Technology Journal Database, and Superstar Journals Database. The 2022 Edition of Journal Citation Reports® cites the 2021 impact factor (IF) for WJGS as 2.505; IF without journal self cites: 2.473; 5-year IF: 3.099; Journal Citation Indicator: 0.49; Ranking: 104 among 211 journals in surgery; Quartile category: Q2; Ranking: 81 among 93 journals in gastroenterology and hepatology; and Quartile category: Q4.

RESPONSIBLE EDITORS FOR THIS ISSUE

Production Editor: Rui-Rui Wu; Production Department Director: Xiang Li; Editorial Office Director: Jia-Ru Fan.

NAME OF JOURNAL

World Journal of Gastrointestinal Surgery

ISSN

ISSN 1948-9366 (online)

LAUNCH DATE

November 30, 2009

FREQUENCY

Monthly

EDITORS-IN-CHIEF

Peter Schemmer

EDITORIAL BOARD MEMBERS

<https://www.wjgnet.com/1948-9366/editorialboard.htm>

PUBLICATION DATE

March 27, 2023

COPYRIGHT

© 2023 Baishideng Publishing Group Inc

INSTRUCTIONS TO AUTHORS

<https://www.wjgnet.com/bpg/gerinfo/204>

GUIDELINES FOR ETHICS DOCUMENTS

<https://www.wjgnet.com/bpg/GerInfo/287>

GUIDELINES FOR NON-NATIVE SPEAKERS OF ENGLISH

<https://www.wjgnet.com/bpg/gerinfo/240>

PUBLICATION ETHICS

<https://www.wjgnet.com/bpg/GerInfo/288>

PUBLICATION MISCONDUCT

<https://www.wjgnet.com/bpg/gerinfo/208>

ARTICLE PROCESSING CHARGE

<https://www.wjgnet.com/bpg/gerinfo/242>

STEPS FOR SUBMITTING MANUSCRIPTS

<https://www.wjgnet.com/bpg/GerInfo/239>

ONLINE SUBMISSION

<https://www.f6publishing.com>



Immunotherapy in combination with chemotherapy for Peutz-Jeghers syndrome with advanced cervical cancer: A case report

Xiang-Cheng Hu, Chen-Xiao Gan, Hui-Min Zheng, Xue-Ping Wu, Wen-Sheng Pan

Specialty type: Gastroenterology and hepatology

Provenance and peer review: Unsolicited article; Externally peer reviewed.

Peer-review model: Single blind

Peer-review report's scientific quality classification

Grade A (Excellent): 0
Grade B (Very good): B
Grade C (Good): C
Grade D (Fair): 0
Grade E (Poor): 0

P-Reviewer: Oon C, Malaysia; Song Q, China

Received: November 22, 2022

Peer-review started: November 22, 2022

First decision: January 11, 2023

Revised: January 31, 2023

Accepted: March 3, 2023

Article in press: March 3, 2023

Published online: March 27, 2023



Xiang-Cheng Hu, Hui-Min Zheng, Department of Gastroenterology, Bengbu Medical College, Bengbu 233000, Anhui Province, China

Chen-Xiao Gan, Xue-Ping Wu, Wen-Sheng Pan, Department of Gastroenterology, Zhejiang Provincial People's hospital, Hangzhou 310014, Zhejiang Province, China

Corresponding author: Wen-Sheng Pan, MD, Doctor, Department of Gastroenterology, Zhejiang Provincial People's Hospital, No. 158 Shangtang Road, Gongshu District, Hangzhou 310014, Zhejiang Province, China. wspan223@163.com

Abstract

BACKGROUND

Peutz-Jeghers syndrome (PJS) is a rare autosomal dominant disorder, and female patients may develop gynecologic tumours. The prognosis for such patients is poor and the specific pathogenesis remains uncertain. Therefore, there are currently no uniform treatment options.

CASE SUMMARY

Herein, we introduce the case of a 45-year-old female who was diagnosed with PJS for 45 years and cervical cancer for 3 years. Postoperative pathological examination showed metastases in the right external iliac lymph nodes. The patient was initially treated with a combination of doxorubicin and carboplatin chemotherapy and pelvic magnetic resonance showed that the metastases had grown. Subsequently, we performed whole exome sequencing in this patient and identified the relevant causative gene. In addition to the chemotherapy regimen, sintilizumab was administered and the patient was followed up. After 4 cycles of treatment, the metastases were substantially reduced and were not enlarged after six months of follow-up. This case report suggests that patients with PJS combined with cervical cancer may have a sustained response to immune-combination chemotherapy regimens.

CONCLUSION

Clinicians should be aware of the importance of immunotherapy in patients with PJS combined with advanced cervical cancer.

Key Words: Peutz-Jeghers syndrome; Cervical cancer; Programmed cell death protein 1; Chemotherapy; Case report

Core Tip: Peutz-Jeghers syndrome (PJS) is a rare genetic disease with cancerous potential. In this case, the patient was diagnosed with PJS combined with progressive cervical cancer and she initially received doxorubicin and carboplatin; however, the right parietal iliac vessel metastases did not shrink. This case suggests that the use of programmed cell death protein 1 (PD-1) inhibitors was helpful in this patient and that PD-1 inhibitors combined with chemotherapy may be a good choice for treating this disease.

Citation: Hu XC, Gan CX, Zheng HM, Wu XP, Pan WS. Immunotherapy in combination with chemotherapy for Peutz-Jeghers syndrome with advanced cervical cancer: A case report. *World J Gastrointest Surg* 2023; 15(3): 480-487

URL: <https://www.wjgnet.com/1948-9366/full/v15/i3/480.htm>

DOI: <https://dx.doi.org/10.4240/wjgs.v15.i3.480>

INTRODUCTION

Peutz-Jeghers syndrome (PJS) is a rare autosomal dominant-inherited disorder. The incidence of this syndrome ranges from 1 in 25000 to 1 in 28000 people per year[1]. Current research indicates that this disease is caused by a mutation of the *STK11* gene on chromosome 19p13.3(1). Patients with PJS are characterized by dark spots on the skin mucosa and hamartomatous polyps in the digestive tract[2]. At the same time, studies have indicated a higher incidence of malignancy in patients with PJS than in the general population. The cumulative incidence of gastrointestinal cancers is 55%, with colorectal cancer at 39%, pancreatic cancer at 36%-40%, and small bowel cancer at 13%[3,4]. The risk of cancers of the nongastrointestinal tract is also increased, with a cumulative incidence of 32%-54% for breast cancer, 21% for ovarian cancer, and 7% for lung cancer at age 60[5-8]. Cisplatin has been the standard chemotherapy for cervical cancer with distant metastases, and recent evidence supports the use of platinum-based dual therapy rather than cisplatin alone[9-11]. However, in patients with PJS combined with uterine malignancy, the pathogenesis may be more complex and unclear, and there is no standard treatment protocol. We report a patient with PJS combined with progressive cervical cancer. A regimen using a programmed cell death protein 1 (PD-1) inhibitor in combination with chemotherapy may be a good option for treating this disease.

CASE PRESENTATION

Chief complaints

A 45-year-old Chinese female was admitted to the hospital with mucous membrane black spots on the lips, intermittent abdominal pain for more than forty years and recurrent cervical cancer for three years.

History of present illness

Forty years prior, the patient visited several hospitals for lip pigmentation and abdominal pain and was finally diagnosed with PJS by gastroscopy (Figure 1A and B). The patient later underwent three "partial small bowel resections" and two "intestinal polypectomies" for intestinal obstruction. Three years ago, the patient was diagnosed with cervical cancer and underwent "extensive hysterectomy and bilateral adnexal resection". Postoperative pathology suggested an endogenous cervical (size 5.4 cm × 3.5 cm) highly differentiated adenoma with metastasis to the right external iliac vessels (Figure 1C). The patient was treated with six cycles of chemotherapy with a carboplatin-doxorubicin (CD) (doxorubicin 30 mg/m² and carboplatin area under the curve = 5) regimen before admission.

History of past illness

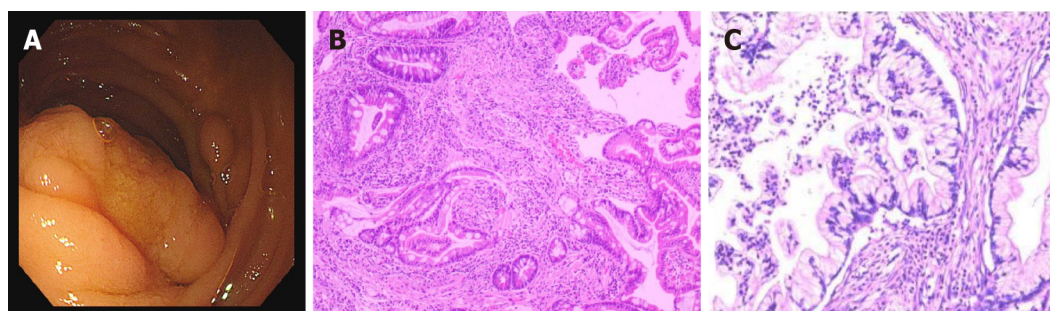
The patient reported no remarkable history of past illness.

Personal and family history

The patient's mother, brother, sister and daughter all had PJS. Her mother died of colon cancer at the age of forty. Genetic mapping was recorded (Figure 2).

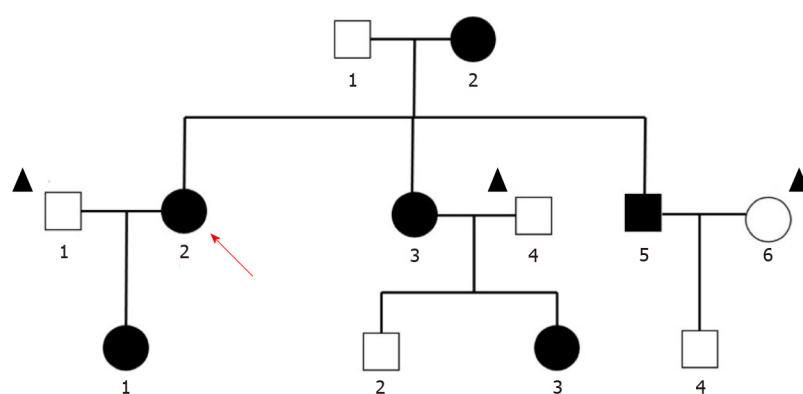
Physical examination

A surgical scar of approximately 5 cm was visible below the umbilicus. Other physical examinations showed no important abnormalities.



DOI: 10.4240/wjgs.v15.i3.480 Copyright ©The Author(s) 2023.

Figure 1 Transoral single-balloon enteroscopy results and cervical cancer histopathological results. A: The images show a polypoid tissue measuring 2 cm × 3 cm was identified 1.5 m below the flexural ligament and was biopsied; B: The pathology of the polyp showed a dendritic extension of the mucosal muscle layer into the central part of the polyp, with the glands forming a villi-like structure. The surface of the polyp was covered with normal epithelium and the interstitium showed no obvious inflammatory lesions; C: Pathological findings of cervical cancer revealed a highly differentiated adenocarcinoma of the cervix, partly with microscopic adenocarcinomatous changes, infiltrating into the deep mesenchymal layer near the outer membrane, with visible vascular tumour plugs and metastases or infiltrations in the right external iliac lymph nodes.



DOI: 10.4240/wjgs.v15.i3.480 Copyright ©The Author(s) 2023.

Figure 2 Pedigree of the family with Peutz-Jeghers syndrome. Black symbols denote individuals with mucocutaneous pigmentations. Circles and squares indicate females and males, respectively, while the arrow indicates the reported patient and one with the triangle is nonfamily members.

Laboratory examinations

The leukocytes, bilirubin, alanine aminotransferase, aspartate aminotransferase, lactate dehydrogenase, infectious disease screening and serum tumour markers were within normal limits, but the carbohydrate antigen-199 (CA199) level was elevated (71.2).

Imaging examinations

After admission, 18F-fluorodeoxyglucose positron emission tomography (PET)/computed tomography (CT) indicated multiple small metastases next to the right iliac vessels [the largest was approximately 0.5 cm × 0.5 cm; the regular scan maximum standardized uptake value (SUVmax) = 1.4; delayed scan SUVmax = 3.2].

FINAL DIAGNOSIS

Based on the patient's transoral single-balloon enteroscopy findings and the patient's surgical report, we diagnosed her with PJS combined with advanced cervical cancer.

TREATMENT

The patient was hospitalized to complete PET-CT and transoral single-balloon enteroscopy and did not continue chemotherapy due to financial reasons. In September 2021, pelvic magnetic resonance (MR) suggested a substantially larger right iliac metastasis than before, with CA199 = 146.8 U/mL. The patient then underwent a four-cycle CD chemotherapy protocol. In January 2022, pelvic MR suggested

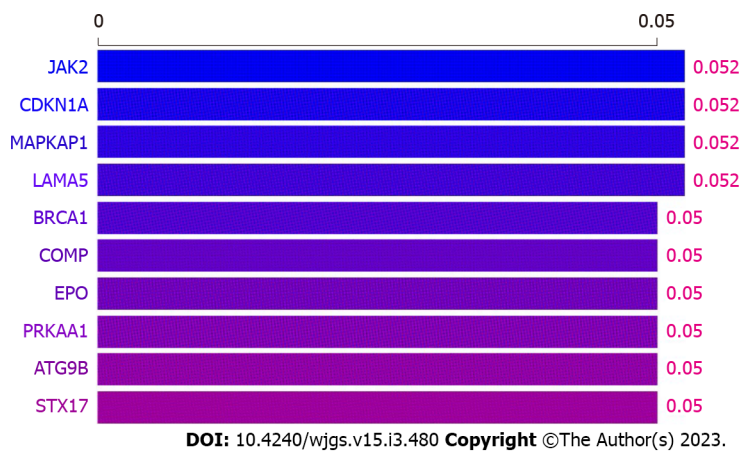


Figure 3 Whole exome-sequencing findings of blood. *JAK2*, *CDKN1A*, *MAPKAP1*, and *LAMA5* genes are slightly associated with Peutz–Jeghers syndrome and cervical cancer.

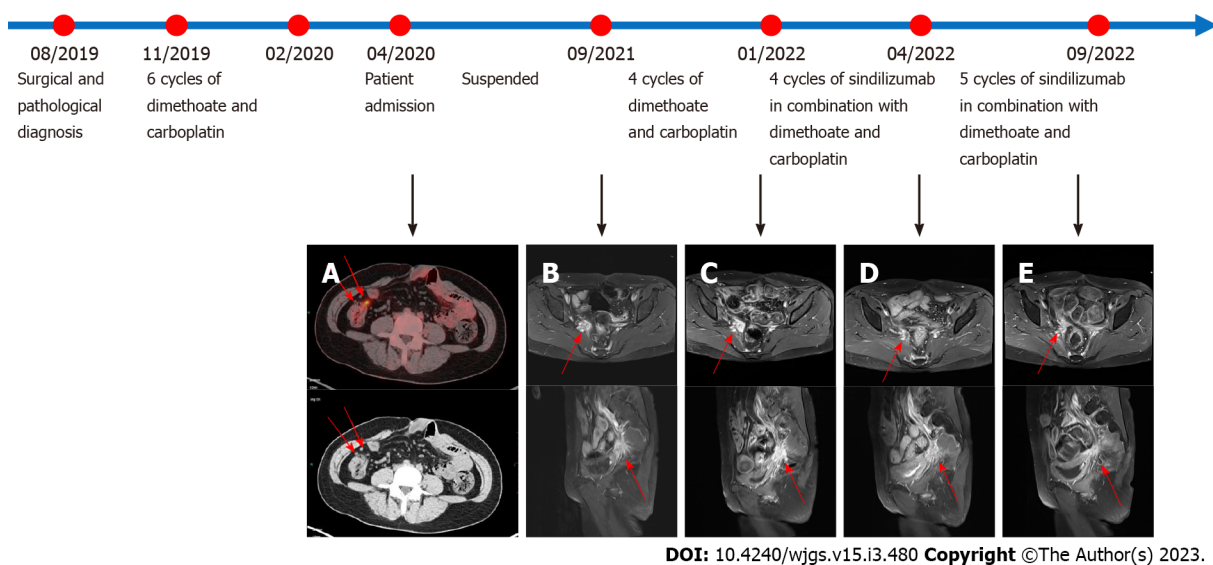


Figure 4 Pelvic magnetic resonance imaging scans before and after the use of sindilizumab and timeline of treatment. Before the use of sindilizumab. A: The red arrows in the positron emission tomography-computed tomography images revealed multiple small nodular foci in the right pelvic wall and anterior sacral space with mildly increased fluorodeoxyglucose metabolism, which was considered to be due to tumor metastasis; B: The red arrow revealed an abnormal signal of about 22 mm × 24 mm mass is shown next to the right iliac vessels; C: After using 4 cycles of doxorubicin and carboplatin, the red arrow revealed the abnormal signal foci beside the right iliac vessels were slightly larger than before, with a size of 25 mm × 38 mm, which was considered to be caused by tumor recurrence. After the use of sindilizumab in combination with doxorubicin and cisplatin; D: The red arrow revealed the abnormal signal foci next to the right iliac vessels were significantly smaller than before, with a size of 17 mm × 12 mm; E: The red arrow revealed a small mass of abnormal signal foci, 17 mm × 12 mm in size, was observed next to the right iliac vessels, similar to the previous one. The timeline showed the whole process of diagnosis and treatment of this patient.

that the metastases continued to increase in size and CA199 was 160.8 U/mL. The patient's platelet count was $42 \times 10^9/L$, suggesting a risk of bleeding, so the patient was not directly punctured to test the expression of PD-L1 on the surface of the tumour cells. In addition, considering that the patient had both PJS and cervical cancer, whole exome sequencing (WES) was performed on the patient's blood and showed a mild correlation between Janus kinase-2 (*JAK2*) and the development of the disease (Figure 3). The patient was then treated for the first time with a PD-1 inhibitor (sindilizumab 200 mg, 21 d per cycle) in combination with the CD chemotherapy regimen[12]. In April 2022, pelvic MR suggested that the lesion had decreased greatly and CA199 was 29.8 U/mL, so the treatment was continued with the above regimen. In September 2022, pelvic MR showed no progression of metastases and CA199 was 27.1 U/mL. The whole treatment process was documented (Figure 4), and the overall health parameters during treatments were recorded (Table 1).

Table 1 Overall health parameters during treatments records

Time	April, 2020		September, 2021	January, 2021	November, 2021	December, 2021	January, 2022	February, 2022	March, 2022	April, 2022	May, 2022	June, 2022	July, 2022	August, 2022	September, 2022
Treatment	Admission	Suspend	4 cycles of doxorubicin and carboplatin				9 cycles of sindilizumb in combination with doxorubicin and carboplatin								
Temp/°C	37.1	NA	36.2	37	36.5	36.8	36.5	36.3	37.1	36.8	NA	36.8	36.9	37.2	36.9
HR/min	86	NA	76	84	75	79	82	78	82	81	NA	79	75	79	77
RR/min	19	NA	19	18	19	19	19	18	19	17	NA	18	19	18	19
BP/kPa	16.1/7.5	NA	15.4/8.5	18.7/9.7	18.4/11.1	16.9/11.9	16.5/9.3	16.5/9.7	16.0/9.5	14.0/8.4	NA	12.0/8.0	12.5/8.7	13.2/9.6	13.1/8.0
Weight/kg	56	NA	49	51	51.5	52	53.8	52	51.3	50.9	NA	50.5	51	52.3	53
WBC/10 ⁹ /L	5.11	NA	5.4	5.91	5.03	3.6	3.34	2.91	3.23	4.02	NA	4.42	4.51	4.43	4.52
Hb/g/L	133	NA	124	114	105	96	102	102	106	109	NA	111	112	112	113
Alb/g/L	39.9	NA	38.5	42	40.3	36.9	45.6	NA	44.2	43.4	NA	43.1	40.7	37.6	35.3
ALT/U/L	34	NA	20	17	17	16	20	21	22	23	NA	24	36	47	54
AST/U/L	29	NA	25	24	17	8.3	26	NA	27	28	NA	28	37	43	47
CEA/μg/L	1	NA	0.8	1.2	1.1	0.9	1	0.8	0.9	0.8	NA	0.8	0.9	0.8	0.8
CA125/U/mL	11.1	NA	14.4	19.3	14.6	8.9	10.2	10.3	9.7	9.1	NA	9	9.3	9.7	10.7
CA199/U/mL	71.2	NA	146.8	151.5	153.6	154.3	160.8	37.8	32.6	29.8	NA	22.3	24.3	25.6	27.1
CA153/U/mL	4.9	NA	5.6	11.1	9.4	7.3	8.4	9	6.1	5.2	NA	4.6	4.6	4.5	4.5
CA724/U/mL	2.3	NA	2.7	5.7	8.5	14.3	1.5	5.6	3.4	3.8	NA	2.4	2.3	2.2	2.1

HR: Heart rate; RR: Respiratory rate; BP: Blood pressure; WBC: White blood cell; Hb: Haemoglobin; Alb: Albumin; ALT: Alanine aminotransferase; AST: Aspartate aminotransferase; CEA: Carcinoma embryonic; CA: Carbohydrate antigen; NA: Not available.

OUTCOME AND FOLLOW-UP

Studies have found that sindilizumab-treated patients often suffer from adverse effects such as fever (38%), anaemia (74.1%) and elevated aspartate aminotransferase (41%) and alanine aminotransferase (40.6%)[13,14]. At the same time, carcinoma embryonic antigen (CEA), CA199 and cancer antigen-125 (CA125) are useful markers for detecting cervical cancer and monitoring the clinical course. In particular, CA199 and CA125 have been shown to be particularly useful in patients with adenocarcinoma[15]. In our case, after two months of follow-up, the patient's temperature, heart rate, respiratory rate, blood pressure, white blood cell, haemoglobin concentration, liver function and tumour markers (including CA199, CA125 and CEA) were within the normal ranges (Table 2).

Table 2 Laboratory examinations of the patient after two months of follow-up

Time	Temp/°C	HR/min	RR/min	BP/kPa	Weight/kg	WBC/109/L	Hb/g/L	Alb/g/L	ALT/U/L	AST/U/L	CEA/μg/L	CA125/U/mL	CA199/U/mL	CA153/U/mL	CA724/U/mL
January, 2022	36.5	92	17	14.2/9.6	44.7	5.99	118	43.1	19	17	2.8	32	23	13.6	18.3
November, 2022	37	87	19	14.7/10.4	45.2	6.45	115	35.8	18	23	2.3	31.7	24.6	15.6	19.3

HR: Heart rate; RR: Respiratory rate; BP: Blood pressure; WBC: White blood cell; Hb: Haemoglobin; Alb: Albumin; ALT: Alanine aminotransferase; AST: Aspartate aminotransferase; CEA: Carcinoma embryonic; CA: Carbohydrate antigen.

DISCUSSION

We introduced a case of PJS combined with advanced cervical cancer. After the use of a PD-1 inhibitor combined with a CD chemotherapy regimen, the patient's right iliac metastases were markedly reduced in volume to a stable state, and a more satisfactory result was achieved.

PJS is a rare autosomal dominant disorder characterized by gastrointestinal malformations and skin pigmentation. Mutations in the *STK11* gene can be detected in 50% to 80% of patients. Other related causative genes include the possible gene in the 19q13.4 region, the *Brg1* gene and the *IFTM1* gene[16]. Patients with PJS are more prone to various malignancies, among which gastrointestinal and reproductive tract and endocrine tumours are the most common. Cervical adenocarcinoma is a common malignancy among patients with PJS (46.8%)[17]. Patients with PJS combined with cervical cancer often present with symptoms such as menstrual irregularities, endocrine disorders and abnormal vaginal bleeding, but there is no uniform treatment protocol. In 2008, Li *et al*[18] first reported a case of PJS complicated by cervical adenocarcinoma and small bowel malignancy in which the patient underwent total hysterectomy after neoadjuvant chemotherapy (paclitaxel 120 mg/dL and carboplatin 350 mg/dL 1 d per week for 6 wk, and the tumour markers returned to normal after three months. However, the patient was not followed up. In 2008, Kilic-Okman *et al*[19] reported a case of PJS combined with stage IIIB cervical cancer in which the patient received six cycles of combination chemotherapy (5-fluorouracil, adriamycin, and cyclophosphamide) and radiotherapy. That patient died of cervical adenocarcinoma progression within one month after the completion of radiotherapy. In 2019, Kim *et al* [20] reported a case of PJS combined with gastric-type mucinous cervical adenocarcinoma. As the mass was confined to the cervix and no peripheral lymph node metastasis was present in this patient, the patient achieved recovery after radical cervical surgery followed by adjuvant radiotherapy. In 2021, Vu Dinh *et al*[21] reported a case of PJS combined with stage IIIC gastric cervical mucinous adenocarcinoma. After adjuvant radiotherapy, the disease was stable with no recurrence at one year of follow-up.

PD-1 (also known as CD279) is a coreceptor expressed on the surface of antigen-stimulated T cells. PD-1 and its ligand (PD-L1) belong to the immune checkpoint pathway. Cervical cancer patients can exhibit PD-L1 expression. In 2018, Feng *et al*[22] reported that 59.1% of cervical cancer patients exhibited PD-L1 expression. Additionally, increased incidents of abortion and childbearing can also enhance PD-L1 expression in tumour cells. The study confirmed that PD-1 in tumour-invasive lymphocytes (TILs) and PD-L1 and TILs in cancer cells together constitute the PD-1/PD-L1 pathway, and the imbalance of this pathway is one of the mechanisms of tumour development and cellular immune escape. In

addition, Meng *et al*[23] revealed that 60.82% of patients had PD-L1 expression, and PD-L1 overexpression was associated with vascular invasion and lymph node metastasis in cervical cancer.

JAK2 is a nonreceptor tyrosine kinase that plays key roles as the intracellular signalling effector of the cytokine receptor[24]. JAK2 was also found to regulate the expression of PD-L1. In 2016, Ikeda *et al*[25] found that the PD-L1 protein is upregulated by the simultaneous amplification of the PD-L1 and JAK2 genes through JAK-STAT signalling in non-small cell lung cancer. In 2017, Garcia-Diaz *et al*[12] discovered that interferon- γ could induce PD-L1 expression *via* the interferon- γ -JAK1/JAK2-STAT1/STAT2/STAT3-IRF1 axis in tumour cells, leading to immune escape and cancer induction.

Based on the above studies and the WES in this case, JAK2 was mildly associated with the development of the disease, and we used sindilizumab in combination with carboplatin and doxorubicin for the treatment of PJS combined with advanced cervical carcinoma[12,22-25]. A more satisfactory result was achieved based on the comparison of the right parietal iliac metastases on pelvic MR before and after drug administration, which showed a substantial reduction.

The unique feature of this case is that PJS is a rare disease about which there are only a few international reports, and there is no uniform treatment protocol. We performed WES, identified the relevant causative genes, and treated the patient with sindilizumab in combination with chemotherapy for the first time. The metastases were substantially reduced and the CA199 was greatly decreased after the treatment, which may suggest that immune-combination chemotherapy may be one of the future treatment directions for PJS combined with progressive cervical cancer.

CONCLUSION

We reported a case of PJS combined with advanced cervical cancer. Protein 1 inhibitor combined with a CD chemotherapy regimen substantially decreased the size of the patient's metastases showing that the aforementioned protocol could be a good choice for such patients.

FOOTNOTES

Author contributions: Hu XC and Gan CX assembled, analysed, and interpreted the patient's data and case presentation; Zheng HM and Wu XP prepared the original manuscript; Pan WS edited and critically revised the manuscript; All authors contributed to writing the manuscript; All authors read and approved the final manuscript.

Informed consent statement: All study participants or their legal guardian provided informed written consent about personal and medical data collection prior to study enrolment.

Conflict-of-interest statement: All the authors report no relevant conflicts of interest for this article.

CARE Checklist (2016) statement: The authors have read the CARE Checklist (2016), and the manuscript was prepared and revised according to the CARE Checklist (2016).

Open-Access: This article is an open-access article that was selected by an in-house editor and fully peer-reviewed by external reviewers. It is distributed in accordance with the Creative Commons Attribution NonCommercial (CC BY-NC 4.0) license, which permits others to distribute, remix, adapt, build upon this work non-commercially, and license their derivative works on different terms, provided the original work is properly cited and the use is non-commercial. See: <https://creativecommons.org/licenses/by-nc/4.0/>

Country/Territory of origin: China

ORCID number: Xue-Ping Wu 0000-0002-9614-1638; Wen-Sheng Pan 0000-0002-2347-1695.

S-Editor: Zhang H

L-Editor: A

P-Editor: Zhang H

REFERENCES

- 1 Sandru F, Petca A, Dumitrascu MC, Petca RC, Carsote M. Peutz-Jeghers syndrome: Skin manifestations and endocrine anomalies (Review). *Exp Ther Med* 2021; **22**: 1387 [PMID: 34650635 DOI: 10.3892/etm.2021.10823]
- 2 Tacheci I, Kopacova M, Bures J. Peutz-Jeghers syndrome. *Curr Opin Gastroenterol* 2021; **37**: 245-254 [PMID: 33591027 DOI: 10.1097/MOG.0000000000000718]
- 3 Hearle N, Schumacher V, Menko FH, Olschwang S, Boardman LA, Gille JJ, Keller JJ, Westerman AM, Scott RJ, Lim W, Trimbath JD, Giardiello FM, Gruber SB, Offerhaus GJ, de Rooij FW, Wilson JH, Hansmann A, Möslin G, Royer-Pokora

- B, Vogel T, Phillips RK, Spigelman AD, Houlston RS. Frequency and spectrum of cancers in the Peutz-Jeghers syndrome. *Clin Cancer Res* 2006; **12**: 3209-3215 [PMID: [16707622](#) DOI: [10.1158/1078-0432.Ccr-06-0083](#)]
- 4 **Signoretti M**, Bruno MJ, Zerboni G, Poley JW, Delle Fave G, Capurso G. Results of surveillance in individuals at high-risk of pancreatic cancer: A systematic review and meta-analysis. *United European Gastroenterol J* 2018; **6**: 489-499 [PMID: [29881603](#) DOI: [10.1177/2050640617752182](#)]
 - 5 **Turpin A**, Cattani S, Leclerc J, Wacrenier A, Manouvrier-Hanu S, Buisine MP, Lejeune-Dumoulin S. [Hereditary predisposition to cancers of the digestive tract, breast, gynecological and gonadal: focus on the Peutz-Jeghers]. *Bull Cancer* 2014; **101**: 813-822 [PMID: [25036236](#) DOI: [10.1684/bdc.2014.1942](#)]
 - 6 **Klimkowski S**, Ibrahim M, Ibarra Rovira JJ, Elshikh M, Javadi S, Klekers AR, Abusaif AA, Moawad AW, Ali K, Elsayes KM. Peutz-Jeghers Syndrome and the Role of Imaging: Pathophysiology, Diagnosis, and Associated Cancers. *Cancers (Basel)* 2021; **13** [PMID: [34680270](#) DOI: [10.3390/cancers13205121](#)]
 - 7 **Giardiello FM**, Brensinger JD, Tersmette AC, Goodman SN, Petersen GM, Booker SV, Cruz-Correa M, Offerhaus JA. Very high risk of cancer in familial Peutz-Jeghers syndrome. *Gastroenterology* 2000; **119**: 1447-1453 [PMID: [11113065](#) DOI: [10.1053/gast.2000.20228](#)]
 - 8 **Lim W**, Olschwang S, Keller JJ, Westerman AM, Menko FH, Boardman LA, Scott RJ, Trimboth J, Giardiello FM, Gruber SB, Gille JJ, Offerhaus GJ, de Rooij FW, Wilson JH, Spigelman AD, Phillips RK, Houlston RS. Relative frequency and morphology of cancers in *STK11* mutation carriers. *Gastroenterology* 2004; **126**: 1788-1794 [PMID: [15188174](#) DOI: [10.1053](#)]
 - 9 **Moore DH**, Blessing JA, McQuellon RP, Thaler HT, Cella D, Benda J, Miller DS, Olt G, King S, Boggess JF, Rocereto TF. Phase III study of cisplatin with or without paclitaxel in stage IVB, recurrent, or persistent squamous cell carcinoma of the cervix: a gynecologic oncology group study. *J Clin Oncol* 2004; **22**: 3113-3119 [PMID: [15284262](#) DOI: [10.1200/jco.2004.04.170](#)]
 - 10 **Monk BJ**, Sill MW, McMeekin DS, Cohn DE, Ramondetta LM, Boardman CH, Benda J, Cella D. Phase III trial of four cisplatin-containing doublet combinations in stage IVB, recurrent, or persistent cervical carcinoma: a Gynecologic Oncology Group study. *J Clin Oncol* 2009; **27**: 4649-4655 [PMID: [19720909](#) DOI: [10.1200/JCO.2009.21.8909](#)]
 - 11 **Bhatla N**, Aoki D, Sharma DN, Sankaranarayanan R. Cancer of the cervix uteri: 2021 update. *Int J Gynaecol Obstet* 2021; **155** Suppl 1: 28-44 [PMID: [34669203](#) DOI: [10.1002/ijgo.13865](#)]
 - 12 **Garcia-Diaz A**, Shin DS, Moreno BH, Saco J, Escuin-Ordinas H, Rodriguez GA, Zaretsky JM, Sun L, Hugo W, Wang X, Parisi G, Saus CP, Torrejon DY, Graeber TG, Comin-Anduix B, Hu-Lieskovan S, Damoiseaux R, Lo RS, Ribas A. Interferon Receptor Signaling Pathways Regulating PD-L1 and PD-L2 Expression. *Cell Rep* 2017; **19**: 1189-1201 [PMID: [28494868](#) DOI: [10.1016/j.celrep.2017.04.031](#)]
 - 13 **Shi Y**, Su H, Song Y, Jiang W, Sun X, Qian W, Zhang W, Gao Y, Jin Z, Zhou J, Jin C, Zou L, Qiu L, Li W, Yang J, Hou M, Zeng S, Zhang Q, Hu J, Zhou H, Xiong Y, Liu P. Safety and activity of sintilimab in patients with relapsed or refractory classical Hodgkin lymphoma (ORIENT-1): a multicentre, single-arm, phase 2 trial. *Lancet Haematol* 2019; **6**: e12-e19 [PMID: [30612710](#) DOI: [10.1016/S2352-3026\(18\)30192-3](#)]
 - 14 **Yang Y**, Wang Z, Fang J, Yu Q, Han B, Cang S, Chen G, Mei X, Yang Z, Ma R, Bi M, Ren X, Zhou J, Li B, Song Y, Feng J, Li J, He Z, Zhou R, Li W, Lu Y, Wang Y, Wang L, Yang N, Zhang Y, Yu Z, Zhao Y, Xie C, Cheng Y, Zhou H, Wang S, Zhu D, Zhang W, Zhang L. Efficacy and Safety of Sintilimab Plus Pemetrexed and Platinum as First-Line Treatment for Locally Advanced or Metastatic Nonsquamous NSCLC: a Randomized, Double-Blind, Phase 3 Study (Oncology pProgram by InnovENT anti-PD-1-11). *J Thorac Oncol* 2020; **15**: 1636-1646 [PMID: [32781263](#) DOI: [10.1016/j.jtho.2020.07.014](#)]
 - 15 **Borras G**, Molina R, Xercavins J, Ballesta A, Iglesias J. Tumor antigens CA 19.9, CA 125, and CEA in carcinoma of the uterine cervix. *Gynecol Oncol* 1995; **57**: 205-211 [PMID: [7729735](#) DOI: [10.1006/gyno.1995.1126](#)]
 - 16 **Kopacova M**, Tacheci I, Rejchrt S, Bures J. Peutz-Jeghers syndrome: diagnostic and therapeutic approach. *World J Gastroenterol* 2009; **15**: 5397-5408 [PMID: [19916169](#) DOI: [10.3748/wjg.15.5397](#)]
 - 17 **Ishida H**, Tajima Y, Gonda T, Kumamoto K, Ishibashi K, Iwama T. Update on our investigation of malignant tumors associated with Peutz-Jeghers syndrome in Japan. *Surg Today* 2016; **46**: 1231-1242 [PMID: [26746637](#) DOI: [10.1007/s00595-015-1296-y](#)]
 - 18 **Li LJ**, Wang ZQ, Wu BP. Peutz-Jeghers syndrome with small intestinal malignancy and cervical carcinoma. *World J Gastroenterol* 2008; **14**: 7397-7399 [PMID: [19109876](#) DOI: [10.3748/wjg.14.7397](#)]
 - 19 **Kilic-Okman T**, Yardim T, Gücer F, Altaner S, Yuce MA. Breast cancer, ovarian gonadoblastoma and cervical cancer in a patient with Peutz-Jeghers Syndrome. *Arch Gynecol Obstet* 2008; **278**: 75-77 [PMID: [18193442](#) DOI: [10.1007/s00404-007-0535-x](#)]
 - 20 **Kim Y**, Kim EY, Kim TJ, Lim KT, Lee KH, Chun Y, So KA. A rare case of gastric-type mucinous adenocarcinoma in a woman with Peutz-Jeghers syndrome. *Obstet Gynecol Sci* 2019; **62**: 474-477 [PMID: [31777745](#) DOI: [10.5468/ogs.2019.62.6.474](#)]
 - 21 **Vu Dinh G**, Doan Thi Hong N, Vo Ngoc T, Nguyen Thanh L, Hoang Thi H, Phung Thi H. Peutz - Jeghers syndrome with gastric type mucinous endocervical adenocarcinoma in a young woman: A case report. *Ann Med Surg (Lond)* 2021; **69**: 102700 [PMID: [34429956](#) DOI: [10.1016/j.amsu.2021.102700](#)]
 - 22 **Feng YC**, Ji WL, Yue N, Huang YC, Ma XM. The relationship between the PD-1/PD-L1 pathway and DNA mismatch repair in cervical cancer and its clinical significance. *Cancer Manag Res* 2018; **10**: 105-113 [PMID: [29403308](#) DOI: [10.2147/CMAR.S152232](#)]
 - 23 **Meng Y**, Liang H, Hu J, Liu S, Hao X, Wong MSK, Li X, Hu L. PD-L1 Expression Correlates With Tumor Infiltrating Lymphocytes And Response To Neoadjuvant Chemotherapy In Cervical Cancer. *J Cancer* 2018; **9**: 2938-2945 [PMID: [30123362](#) DOI: [10.7150/jca.22532](#)]
 - 24 **Sopjani M**, Morina R, Uka V, Xuan NT, Dërmaku-Sopjani M. JAK2-mediated Intracellular Signaling. *Curr Mol Med* 2021; **21**: 417-425 [PMID: [33059575](#) DOI: [10.2174/1566524020666201015144702](#)]
 - 25 **Ikeda S**, Okamoto T, Okano S, Umemoto Y, Tagawa T, Morodomi Y, Kohno M, Shimamatsu S, Kitahara H, Suzuki Y, Fujishita T, Maehara Y. PD-L1 Is Upregulated by Simultaneous Amplification of the PD-L1 and JAK2 Genes in Non-Small Cell Lung Cancer. *J Thorac Oncol* 2016; **11**: 62-71 [PMID: [26762740](#) DOI: [10.1016/j.jtho.2015.09.010](#)]



Published by **Baishideng Publishing Group Inc**
7041 Koll Center Parkway, Suite 160, Pleasanton, CA 94566, USA

Telephone: +1-925-3991568

E-mail: bpgoffice@wjgnet.com

Help Desk: <https://www.f6publishing.com/helpdesk>

<https://www.wjgnet.com>

