

World Journal of *Gastrointestinal Surgery*

World J Gastrointest Surg 2023 April 27; 15(4): 495-744



Contents

Monthly Volume 15 Number 4 April 27, 2023

REVIEW

- 495 Current and emerging therapeutic approaches for colorectal cancer: A comprehensive review
Kumar A, Gautam V, Sandhu A, Rawat K, Sharma A, Saha L
- 520 Harnessing interventions during the immediate perioperative period to improve the long-term survival of patients following radical gastrectomy
Liu LB, Li J, Lai JX, Shi S

MINIREVIEWS

- 534 Nutrition in acute pancreatitis
Gopi S, Saraya A, Gunjan D
- 544 Surgical treatment for recurrent hepatocellular carcinoma: Current status and challenges
Wang D, Xiao M, Wan ZM, Lin X, Li QY, Zheng SS
- 553 The spectrum of pneumatosis intestinalis in the adult. A surgical dilemma
Tropeano G, Di Grezia M, Puccioni C, Bianchi V, Pepe G, Fico V, Altieri G, Brisinda G
- 566 Surgical aspects of small intestinal neuroendocrine tumors
Kupietzky A, Dover R, Mazeh H
- 578 Tumor budding in gastric cancer
Xiao SM, Li J
- 592 Initial management of suspected biliary injury after laparoscopic cholecystectomy
Siiiki A, Ahola R, Vaalavuo Y, Antila A, Laukkanen J

ORIGINAL ARTICLE

Basic Study

- 600 Acinous cell AR42J-derived exosome miR125b-5p promotes acute pancreatitis exacerbation by inhibiting M2 macrophage polarization via PI3K/AKT signaling pathway
Zheng Z, Cao F, Ding YX, Lu JD, Fu YQ, Liu L, Guo YL, Liu S, Sun HC, Cui YQ, Li F

Case Control Study

- 621 Skeletal muscle mass and quality before preoperative chemotherapy influence postoperative long-term outcomes in esophageal squamous cell carcinoma patients
Ichinohe D, Muroya T, Akasaka H, Hakamada K

Retrospective Study

- 634 *In situ* subtotal spleen resection combined with selective pericardial devascularization for the treatment of portal hypertension

Li HL, Ning SL, Gao YJ, Zhou T, Chen YX

- 643 Risk factors for blood transfusion and its prognostic implications in curative gastrectomy for gastric cancer

Kawakami LE, Bonomi PB, Pereira MA, Carvalho FO, Ribeiro Jr U, Zilberstein B, Sampaio LR, Carneiro-D'Albuquerque LA, Ramos MFKP

Clinical Trials Study

- 655 Endoscopic ultrasound-guided intraportal injection of autologous bone marrow in patients with decompensated liver cirrhosis: A case series

Zheng SP, Deng AJ, Zhou JJ, Yuan LZ, Shi X, Wang F

- 664 Computed tomography perfusion in differentiating portal hypertension: A correlation study with hepatic venous pressure gradient

Dong J, Zhang Y, Wu YF, Yue ZD, Fan ZH, Zhang CY, Liu FQ, Wang L

Observational Study

- 674 Ligamentum teres hepatis as a graft for portal and/or superior mesenteric vein reconstruction: From bench to bedside

Zhu WT, Wang HT, Guan QH, Zhang F, Zhang CX, Hu FA, Zhao BL, Zhou L, Wei Q, Ji HB, Fu TL, Zhang XY, Wang RT, Chen QP

- 687 Efficacy and safety analysis of transarterial chemoembolization and transarterial radioembolization in advanced hepatocellular carcinoma descending hepatectomy

Feng R, Cheng DX, Song T, Chen L, Lu KP

Prospective Study

- 698 Effectiveness of a new approach to minimally invasive surgery in palliative treatment of patients with distal malignant biliary obstruction

Susak YM, Markulan LL, Lobanov SM, Palitsya RY, Rudyk MP, Skivka LM

Randomized Controlled Trial

- 712 External use of mirabilite to prevent post-endoscopic retrograde cholangiopancreatography pancreatitis in children: A multicenter randomized controlled trial

Zeng JQ, Zhang TA, Yang KH, Wang WY, Zhang JY, Hu YB, Xiao J, Gu ZJ, Gong B, Deng ZH

SYSTEMATIC REVIEWS

- 723 The global epidemiology of upper and lower gastrointestinal bleeding in general population: A systematic review

Saydam SS, Molnar M, Vora P

CASE REPORT

- 740 Idiopathic colopleural fistula presenting with lung abscess and refractory empyema: A case report

Wang CL, Cheng KC

ABOUT COVER

Editorial Board Member of *World Journal of Gastrointestinal Surgery*, Sami Akbulut, MD, PhD, Full Professor, Department of Surgery and Liver Transplant Institute, Inonu University Faculty of Medicine, Malatya 44280, Turkey. akbulutsami@gmail.com

AIMS AND SCOPE

The primary aim of *World Journal of Gastrointestinal Surgery* (WJGS, *World J Gastrointest Surg*) is to provide scholars and readers from various fields of gastrointestinal surgery with a platform to publish high-quality basic and clinical research articles and communicate their research findings online.

WJGS mainly publishes articles reporting research results and findings obtained in the field of gastrointestinal surgery and covering a wide range of topics including biliary tract surgical procedures, biliopancreatic diversion, colectomy, esophagectomy, esophagostomy, pancreas transplantation, and pancreatectomy, etc.

INDEXING/ABSTRACTING

The WJGS is now abstracted and indexed in Science Citation Index Expanded (SCIE, also known as SciSearch®), Current Contents/Clinical Medicine, Journal Citation Reports/Science Edition, PubMed, PubMed Central, Reference Citation Analysis, China National Knowledge Infrastructure, China Science and Technology Journal Database, and Superstar Journals Database. The 2022 Edition of Journal Citation Reports® cites the 2021 impact factor (IF) for WJGS as 2.505; IF without journal self cites: 2.473; 5-year IF: 3.099; Journal Citation Indicator: 0.49; Ranking: 104 among 211 journals in surgery; Quartile category: Q2; Ranking: 81 among 93 journals in gastroenterology and hepatology; and Quartile category: Q4.

RESPONSIBLE EDITORS FOR THIS ISSUE

Production Editor: Rui-Rui Wu; Production Department Director: Xiang Li; Editorial Office Director: Jia-Ru Fan.

NAME OF JOURNAL

World Journal of Gastrointestinal Surgery

ISSN

ISSN 1948-9366 (online)

LAUNCH DATE

November 30, 2009

FREQUENCY

Monthly

EDITORS-IN-CHIEF

Peter Schemmer

EDITORIAL BOARD MEMBERS

<https://www.wjgnet.com/1948-9366/editorialboard.htm>

PUBLICATION DATE

April 27, 2023

COPYRIGHT

© 2023 Baishideng Publishing Group Inc

INSTRUCTIONS TO AUTHORS

<https://www.wjgnet.com/bpg/gerinfo/204>

GUIDELINES FOR ETHICS DOCUMENTS

<https://www.wjgnet.com/bpg/GerInfo/287>

GUIDELINES FOR NON-NATIVE SPEAKERS OF ENGLISH

<https://www.wjgnet.com/bpg/gerinfo/240>

PUBLICATION ETHICS

<https://www.wjgnet.com/bpg/GerInfo/288>

PUBLICATION MISCONDUCT

<https://www.wjgnet.com/bpg/gerinfo/208>

ARTICLE PROCESSING CHARGE

<https://www.wjgnet.com/bpg/gerinfo/242>

STEPS FOR SUBMITTING MANUSCRIPTS

<https://www.wjgnet.com/bpg/GerInfo/239>

ONLINE SUBMISSION

<https://www.f6publishing.com>



Initial management of suspected biliary injury after laparoscopic cholecystectomy

Antti Siiki, Reea Ahola, Yrjö Vaalavuo, Anne Antila, Johanna Laukkarinen

Specialty type: Surgery

Provenance and peer review:

Invited article; Externally peer reviewed.

Peer-review model: Single blind

Peer-review report's scientific quality classification

Grade A (Excellent): 0

Grade B (Very good): B

Grade C (Good): C

Grade D (Fair): 0

Grade E (Poor): 0

P-Reviewer: Moshref L, Saudi Arabia; Thapar P, India

Received: December 28, 2022

Peer-review started: December 28, 2022

First decision: January 12, 2023

Revised: January 26, 2023

Accepted: March 15, 2023

Article in press: March 15, 2023

Published online: April 27, 2023



Antti Siiki, Reea Ahola, Yrjö Vaalavuo, Anne Antila, Johanna Laukkarinen, Department of Gastroenterology and Alimentary Tract Surgery, Tampere University Hospital, Tampere 33521, Finland

Johanna Laukkarinen, Faculty of Medicine and Health Technology, University of Tampere, Tampere 33521, Finland

Corresponding author: Antti Siiki, MD, PhD, Surgeon, Department of Gastroenterology and Alimentary Tract Surgery, Tampere University Hospital, Teiskontie 35, Tampere 33521, Finland. antti.siiki@finnet.fi

Abstract

Although rare, iatrogenic bile duct injury (BDI) after laparoscopic cholecystectomy may be devastating to the patient. The cornerstones for the initial management of BDI are early recognition, followed by modern imaging and evaluation of injury severity. Tertiary hepato-biliary centre care with a multi-disciplinary approach is crucial. The diagnostics of BDI commences with a multi-phase abdominal computed tomography scan, and when the biloma is drained or a surgical drain is put in place, the diagnosis is set with the help of bile drain output. To visualize the leak site and biliary anatomy, the diagnostics is supplemented with contrast enhanced magnetic resonance imaging. The location and severity of the bile duct lesion and concomitant injuries to the hepatic vascular system are evaluated. Most often, a combination of percutaneous and endoscopic methods is used for control of contamination and bile leak. Generally, the next step is endoscopic retrograde cholangiography (ERC) for downstream control of the bile leak. ERC with insertion of a stent is the treatment of choice in most mild bile leaks. The surgical option of re-operation and its timing should be discussed in cases where an endoscopic and percutaneous approach is not sufficient. The patient's failure to recover properly in the first days after laparoscopic cholecystectomy should immediately raise suspicion of BDI and this merits immediate investigation. Early consultation and referral to a dedicated hepato-biliary unit are essential for the best outcome.

Key Words: Cholecystectomy; Laparoscopy; Bile duct injury; Iatrogenic; Adverse event; Complication

©The Author(s) 2023. Published by Baishideng Publishing Group Inc. All rights reserved.

Core Tip: A rare, but potentially disastrous bile duct injury (BDI) after laparoscopic cholecystectomy may easily go unnoticed at first. Thus, any unwell patient or anyone not recovering properly in the first post-operative days after surgery should be considered as having a surgical complication unless proven otherwise. The right initial management in suspected BDI is essential for prognosis. Early referral to a hepato-biliary unit, combination of modern imaging modalities and consequent evaluation of the severity grade of the injury are the foundations of management. The initial treatment options range from percutaneous and endoscopic methods to surgery, the timing and details of which need a multi-disciplinary hepato-biliary approach.

Citation: Siiki A, Ahola R, Vaalavuo Y, Antila A, Laukkanen J. Initial management of suspected biliary injury after laparoscopic cholecystectomy. *World J Gastrointest Surg* 2023; 15(4): 592-599

URL: <https://www.wjgnet.com/1948-9366/full/v15/i4/592.htm>

DOI: <https://dx.doi.org/10.4240/wjgs.v15.i4.592>

INTRODUCTION

Rare bile duct injury (BDI) after cholecystectomy should be recognized early to allow prompt diagnosis and treatment[1-3]. As most cholecystectomies are operated on laparoscopically, BDI occurs in 0.2%-0.9% of patients; the variation depends on whether all bile leaks or only surgically reconstructed injuries are included[4-6]. Commonly graded by Strasberg's classification[7], bile duct injuries are graded from A to E, where A represents a simple cystic duct leak and C-E complex injuries to the hepatic ducts or common bile duct (CBD)[7-9] (Figure 1). Most post-cholecystectomy bile leaks are mild type A-B lesions, where endoscopic treatment combined with external drainage is usually successful[10-12]. More severe grades often require re-operation or even a combination of endoscopy, interventional radiology and surgery[4,13,14]. Surgical repair of BDI should be avoided between two and six weeks after the cholecystectomy due to the elevated risk of postoperative morbidity and hepaticojejunostomy stricture compared to re-operation at some earlier or later time point[15]. At worst, BDI may lead to morbidity and mortality[11], series of re-interventions, long hospitalization and substantial costs[1,16,17]. BDI has a considerable impact on long-term quality-of-life; *e.g.* surgically repaired BDI may require re-interventions for strictured hepatico-jejunostomy anastomosis in 10%-20%[3,14,18].

REFERRAL AND DIAGNOSIS IN SUSPECTED BDI

Most mild bile duct injuries are recognized a few days after the operation[6,10,19,20]. Prompt referral and evaluation with modern imaging is crucial whenever a patient is not recovering properly after any type of cholecystectomy[2,11,19]. The clinical symptoms of BDI are vague: symptoms such as abdominal pain, fever, sepsis and jaundice are not specific. Liver function tests and inflammatory markers may be normal in the early phase. Noteworthy, elevated liver function test results are associated with biliary obstruction or vascular damage, but in cases with bile leak these are usually normal. The only symptom of the most common iatrogenic injury, a leak from the cystic duct (Strasberg A), is often the patient's unspecific deterioration early in the postoperative course. The key to correct diagnosis is high level of suspicion with consequent swift consultation or referral to a tertiary centre when the patient is unwell in the early days after cholecystectomy[2,10,19,21]. It is known that severe BDIs, especially with concomitant vascular injury, are best treated by early referral to the unit with the most experience and extensive resources for interventional radiology, advanced endoscopy and complex reconstructive surgery[8,22-24].

In the emergency department, abdominal imaging should be performed urgently to rule out any post-operative complications (Figure 2). While transabdominal ultrasound may visualize a fluid collection or dilation of the intrahepatic biliary ducts, a multi-phase abdominal computed tomography (CT) scan is required for BDI diagnosis. The common findings are perihepatic fluid accumulation around the right perihepatic space, gallbladder fossa and inferiorly into the right paracolic gutter[25]. Contrast enhanced CT with arterial phase is necessary to exclude the possibility of arterial injury with associated hypoperfusion of the liver due to damage typically to the right branch of the hepatic artery, occurring in up to 20% of BDIs[23]. CT scan may be followed by hepato-biliary specific contrast media enhanced magnetic resonance imaging (MRI) to identify the leak site and accurately identify the biliary anatomy. When contrast enhanced MRI is not available, standard magnetic resonance cholangio-pancreatography (MRCP) without contrast allows evaluation of the fluid-filled bile ducts and provides indirect evidence of a leak[25]. MRI may also reveal CBD stones predisposing to leak from the stump of the cystic duct.

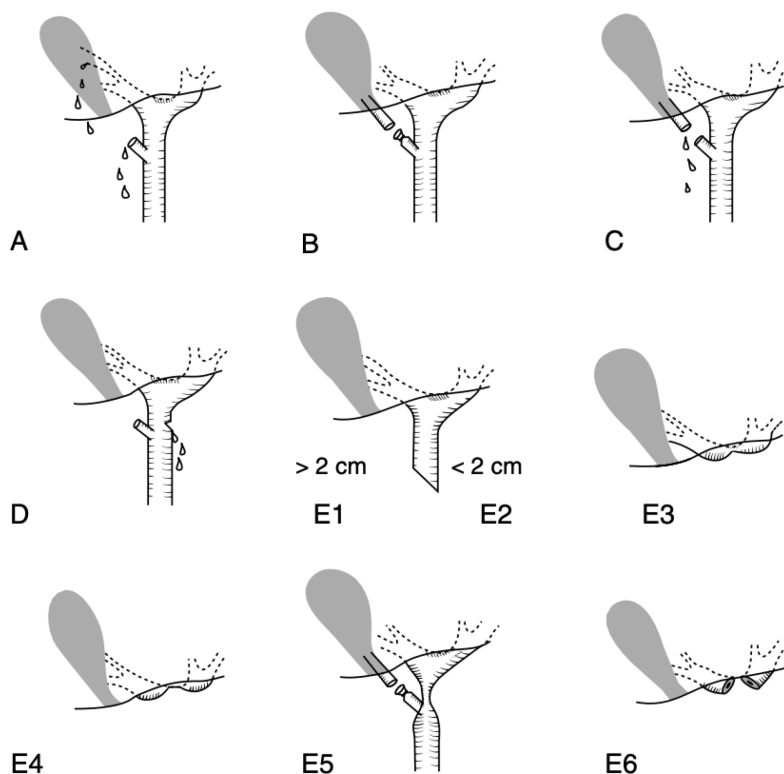


Figure 1 Classification of the bile duct injuries after cholecystectomy. A: Schematic classification of bile duct injuries in laparoscopic cholecystectomy. Originally developed by Strasberg *et al* in 1995[7]. A: Bile leak from the cystic duct stump or minor biliary radical in the gallbladder fossa; B: Occluded right posterior sectoral duct; C: Bile leak from the divided right posterior sectoral duct; D: Bile leak from the main bile duct without major tissue loss; E1: Transected main bile duct with a stricture more than 2 cm from the hilus; E2: Transected main bile duct with a stricture less than 2 cm from the hilus; E3: Stricture of the hilus with right and left ducts in communication; E4: Stricture of the hilus with separation of right and left ducts; E5: Stricture of the main bile duct and the right posterior sectoral duct; E6: complete excision of the extrahepatic ducts involving the confluence (this injury is not described in Strasberg's original classification). Citation: Connor S, Garden OJ. Bile duct injury in the era of laparoscopic cholecystectomy. *Br J Surg* 2006; 93(2): 158-168. Copyright ©John Wiley & Son's Ltd 2006. Published by John Wiley & Son's Ltd[8].

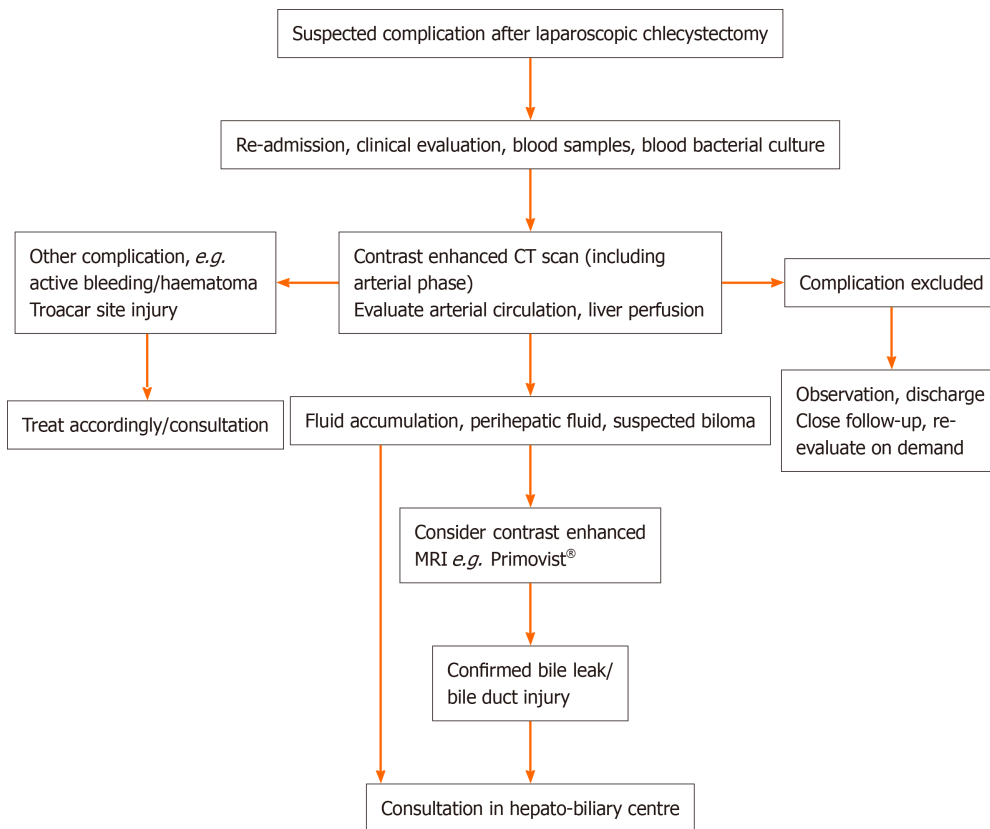
In evaluating the extent of the BDI, it is often useful to consult the original notes from the time of the primary operation. Sometimes crucial information can be obtained on how the anatomy appeared during the cholecystectomy and ascertaining if the critical view of safety was obtained[26,27], how the intra-operative cholangiography (*e.g.*, anatomy, stones, sludge) appeared[28] and what the pre-operative MRI or CT looked like[29,30], or whether the gallbladder was acutely or chronically inflamed, thereby increasing the risks for BDI[4,20,31].

CONTAINING THE CONTAMINATION

The first step in the initial management of BDI is to contain the contamination (Figures 2 and 3). The placement of a percutaneous drain in the biloma is often enough to control the infection combined with wide-spectrum antibiotic treatment. When a drain is placed in the accumulation or a surgical bile-producing drain is left in place in cholecystectomy, samples for bacterial culture and drain bilirubin should be obtained. In cases where interventional radiology is unavailable, especially in a septic patient, emergency laparoscopic lavation may be considered to contain the contamination followed by surgical drains[13]. In these cases, drainage or laparoscopic lavation may be performed in the referring hospital to avoid delays. However, reconstructive surgery for BDI should not be attempted before the severity grade of BDI and possible associated vascular injury are properly evaluated. At the latest, the referral to or consultation with a tertiary hepato-biliary unit should be made at this point, even before any interventions[1,2,19,21,24].

TREATMENT: CONTROLLING THE LEAK

After proper imaging and external drainage, endoscopic retrograde cholangiography (ERC) is the preferred next step in most cases (Figures 2 and 3). When bile drain output continues for more than ca



DOI: 10.4240/wjgs.v15.i4.592 Copyright ©The Author(s) 2023.

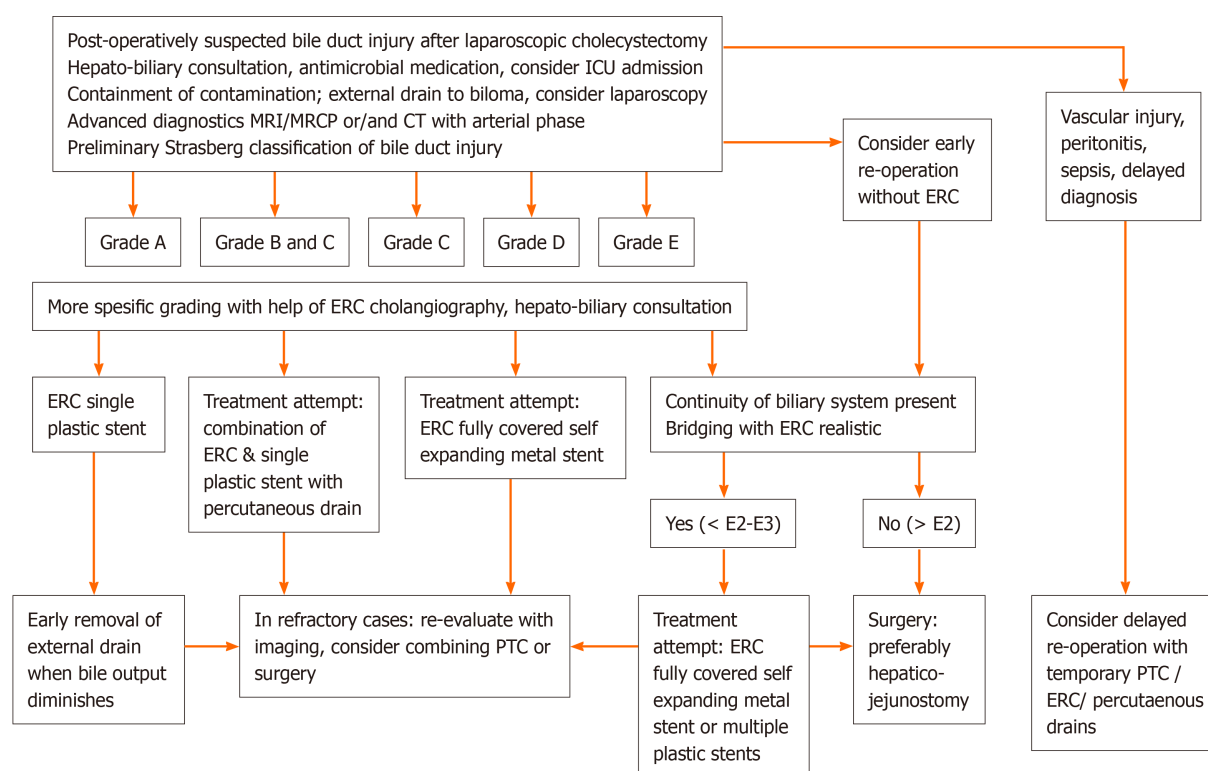
Figure 2 Initial diagnostic flowchart in suspected complication after laparoscopic cholecystectomy. Any patient not recovering correctly in the immediate post-operative phase should be referred and evaluated for the possibility of a complication. Early consultation with the hepato-biliary unit is recommended when bile duct injury or other severe complication of laparoscopic cholecystectomy is suspected. CT: Computed tomography; MRI: Magnetic resonance imaging; MRCP: Magnetic resonance cholangio-pancreatography. (Primovist: Bayer AG, Leverkusen, Germany).

24 h, ERC is often indicated. Endoscopy is used to locate the leak and determine its severity grade and also to treat the bile leak with sphincterotomy and stents. In ERC a leak is carefully visualized with fluoroscopy by injecting pressurized contrast medium over an occlusion balloon[32]. Generally, the most common forms of mild BDI, type A leak from the cystic duct or aberrant duct from the gallbladder fossa, can be easily diagnosed and treated with standard ERC[12,33]. It is often wise to have a hepato-biliary surgeon present in the endoscopy room to see live fluoroscopy findings when a complex BDI is suspected.

When a complete transection of CBD is not present, trans-papillary downstream control of the leak by ERC allows healing in more than 90% of biliary leaks[9,10,34]. In ERC occult CBD stones obstructing the bile flow and predisposing to leak can also be easily removed. In the European guideline, it is recommended to insert a temporary plastic biliary stent rather than to decompress the CBD with sphincterotomy only: stenting provides faster leak resolution than sphincterotomy alone[34]. Stents seem to be equally effective whether biliary sphincterotomy is performed or not. However, while biliary sphincterotomy may be associated with some complications, it is usually necessary for the removal of retained stones. In simple grade A leaks, without bile duct stones, a single plastic stent inserted for four to eight weeks is often enough without sphincterotomy[34]. However, when a stent has been inserted, biliary sludge, stones, or occasionally even a persistent leak may be found at the time of stent removal. Thus, a stent may be preferable to sphincterotomy alone, which can be considered a mere secondary alternative when stone clearance is confirmed and second endoscopy for stent removal would be too risky[9,34]. However, a recent randomised controlled trial proved that after appropriate patient selection in a simple Strasberg type A leak, endoscopic sphincterotomy may be a safe and cost-effective single procedure without stent insertion[12].

When biodegradable biliary stents are available, stent removal in second endoscopy may be avoided [35]. However, in that case, an adequate sphincterotomy followed by careful cleansing of the CBD of stones and sludge should be performed at the index ERC.

In case of more complex BDI, ERC also gives more detailed information for locating the bile leak. It helps to assess the relation of the lesion to the hilum and the main biliary ducts even if the lesion itself may not eventually be treatable by endoscopy only[33]. When only the right hepatic duct is injured or anomalous right segmental biliary branches draining to the cystic duct have been damaged, ERC may be misinterpreted as having no leak despite drain bile output[8]. In this scenario, comparing ERC



DOI: 10.4240/wjgs.v15.i4.592 Copyright ©The Author(s) 2023.

Figure 3 Flow chart of containment and initial treatment in bile leak or bile duct injury. Reconstructive surgery should be planned and performed by hepato-biliary specialists only. ICU: Intensive care unit; CT: Computed tomography; MRI: Magnetic resonance imaging; MRCP: Magnetic resonance cholangio-pancreatography; ERC: Endoscopic retrograde cholangiography; PTC: Percutaneous transhepatic cholangiogram catheter drainage; FCSEMS: Fully covered self-expandable metal stent.

cholangiography to pre-operative MRI may be the way to diagnose this type of lesion correctly[29]. A fistulography performed *via* the catheter drain may also help in determining the extent of the lesion[9]. When the bile duct is disconnected or the main branches entirely transected, early surgery or a combination of external drainage of biloma and percutaneous transhepatic cholangiogram catheter (PTC) for proximal control may be necessary in the early phase in order to gain time for definitive treatment[8].

Instead of plastic stents, self-expanding large bore covered metal stents may be used in ERC in iatrogenic BDI[32,36,37]. Correctly positioned, they may successfully bridge and seal even grade D injuries to the CBD and common hepatic duct[38]. The benefits of self-expanding metal stents are their greater diameter and the sealing effect of the plastic or silicone covering of the stents[36]. Large diameter stents with 8-10 mm bore may be associated with faster leak resolution than plastic stents with 3 mm (10F) calibre[35]. However, care should be taken not to insert a stent with too large a diameter into a narrow normal CBD to prevent circumferential ischaemia and consequent biliary stricture due to stent expansion. Most importantly, before embarking on percutaneous or endoscopic treatment of complex lesions, all diagnostic methods should be undertaken with multi-disciplinary evaluation of the surgical or endoscopic options in a hepato-biliary centre[19,21,24].

SURGICAL OPTIONS

Surgery is the mainstay treatment in cases not manageable by ERC[8]. When BDI is identified during the cholecystectomy, immediate surgical repair should be attempted[16,31]. In these cases, it is important to call a senior surgeon into the operation, carefully evaluate the anatomy and the extent of the lesion with cholangiography[21,28] if this has not been done at an earlier phase of the operation. In the prevention of BDI, a bail-out strategy by stopping further dissection and performing *e.g.*, partial cholecystectomy may be indicated[18,27,39]. Open conversion with Kocher mobilisation or laparoscopic suture, placement of a T-tube with external drainage or even reconstruction with roux-Y hepaticojejunostomy may be considered, depending on the lesion (Figures 1-3), the condition of the patient and the expertise of the surgical team. In complex cases, the best solution may be to do nothing further but call a hepato-biliary specialist during the surgery or place drains and consequently transfer the patient to a centre providing definitive care[8]. When CBD stones are present, it is important to remove them in the

same procedure with repair by choledochoscopy *via e.g.*, choledochotomy. Early or immediate repair may give a good prognosis when performed by experienced specialists only[8,19,40]. In practice, the prerequisites for immediate or early reconstruction with roux-Y hepatico-jejunostomy are: an experienced hepato-biliary team present, the entire biliary tree well visualised in cholangiography, no sepsis or severe biliary peritonitis, no significant co-morbidities and no vascular injury.

According to the literature, the optimal timing of definite reconstructive re-operation varies[9,15]. However, when a complex BDI unamenable to treatment by ERC is diagnosed after the operation, early surgical repair is generally not recommended, especially when diagnosis is delayed or sepsis, biliary peritonitis or arterial injury are concomitant[8,9]. In these cases, the definitive reconstruction should preferably be delayed for up to a few months and preceded by *e.g.*, PTC, multiple drains and also adequate nutritional support[8]. Due to the high risk of morbidity and late stricture formation, surgical reconstruction should be avoided for at least from weeks two to six post-operatively[15]. While the options for re-operation range from reconstruction with roux-Y hepaticojejunostomy[11] to liver resections and even up to liver transplantation[22], any reconstructive late-phase surgery should be performed in an expert hepato-biliary centre[8,19,24].

CONCLUSION

Laparoscopic cholecystectomy is a safe procedure with low morbidity and mortality[4,5]. Any unwell patient with abdominal problems in the immediate post-operative period after cholecystectomy should be managed and referred to specialist care by reason of suspected complication until this possibility can be excluded[1,2,6,19]. Early recognition of BDI improves survival[28]. In addition to BDI related morbidity and mortality[11,14], substantial cost stresses the importance of proper initial management [16,17].

In the surgical emergency department, evaluation starts with blood samples and multi-phase abdominal CT scan[25]. The first step in the treatment of BDI is to contain contamination by percutaneous radiologic catheter drainage, which usually allows time for further decision-making as well as bacterial culture and bile analysis of the drain output[13]. The second step is the evaluation of leak severity, which in practice means contrast-enhanced MRI or MRCP[25] followed by ERC, cholangiography and placement of a temporary stent for down-stream control[33]. The diagnostics of the severity of BDI thus requires a combination of modern imaging modalities. When endoscopic treatment is not sufficient, urgent multi-disciplinary evaluation for further interventional radiologic procedures or re-operation and their optimal timing are called for[8]. While in complex lesions, surgery is the preferred treatment, immediate or early repair by non-specialists is not recommended[8,40]. The long-term consequences of rare severe BDI may be devastating to the patient and the health care system[14, 16,17]. Any reconstructive surgery should be performed in an expert hepato-biliary centre[22,24,40].

Although BDI or bile leak may be inevitable when large numbers of patients are operated on[26], for the most common simple leaks prognosis after ERC is excellent[20,32,36]. Additionally, the vast majority of complex BDIs can be successfully managed surgically in experienced hepato-biliary centres[4,19,24, 40]. However, for the prevention of BDIs, all guidelines stress the importance of proper surgical training, paying due attention to the critical view of safety, use of intraoperative cholangiography to ascertain the anatomy and understanding the role of bail-out strategy[18,21,27,30,39]. In BDI, early recognition, diagnosis and referral are essential[2,19,24], thus a structured algorithm-based approach for the evaluation and referral pattern of complications of laparoscopic cholecystectomy could be useful, possibly similar to that developed for pancreatic surgery[41].

FOOTNOTES

Author contributions: Siiki A, Ahola R, Vaalavuo Y, Antila A and Laukkarinen J contributed to the manuscript drafting and revision.

Conflict-of-interest statement: The authors declare no relevant conflict of interest. Authors Siiki and Laukkarinen have received lecture fees from Boston Scientific, Cook Medical and Olympus Europe.

Open-Access: This article is an open-access article that was selected by an in-house editor and fully peer-reviewed by external reviewers. It is distributed in accordance with the Creative Commons Attribution NonCommercial (CC BY-NC 4.0) license, which permits others to distribute, remix, adapt, build upon this work non-commercially, and license their derivative works on different terms, provided the original work is properly cited and the use is non-commercial. See: <https://creativecommons.org/licenses/by-nc/4.0/>

Country/Territory of origin: Finland

ORCID number: Antti Siiki 0000-0002-1098-0108; Reea Ahola 0000-0002-9702-2729; Yrjö Vaalavuo 0000-0002-1494-2184;

Anne Antila 000-0001-9623-8264; Johanna Laukkarinen 0000-0002-8239-4861.

Corresponding Author's Membership in Professional Societies: Finnish Society of Gastrointestinal Surgery.**S-Editor:** Zhang H**L-Editor:** A**P-Editor:** Zhang H

REFERENCES

- Gouma DJ**, Obertop H. Management of bile duct injuries: treatment and long-term results. *Dig Surg* 2002; **19**: 117-122 [PMID: 11978998 DOI: 10.1159/000052024]
- Wu YV**, Linehan DC. Bile duct injuries in the era of laparoscopic cholecystectomies. *Surg Clin North Am* 2010; **90**: 787-802 [PMID: 20637948 DOI: 10.1016/j.suc.2010.04.019]
- Pucher PH**, Brunt LM, Davies N, Linsk A, Munshi A, Rodriguez HA, Fingerhut A, Fanelli RD, Asbun H, Aggarwal R; SAGES Safe Cholecystectomy Task Force. Outcome trends and safety measures after 30 years of laparoscopic cholecystectomy: a systematic review and pooled data analysis. *Surg Endosc* 2018; **32**: 2175-2183 [PMID: 29556977 DOI: 10.1007/s00464-017-5974-2]
- Harboe KM**, Bardram L. The quality of cholecystectomy in Denmark: outcome and risk factors for 20,307 patients from the national database. *Surg Endosc* 2011; **25**: 1630-1641 [PMID: 21136118 DOI: 10.1007/s00464-010-1453-8]
- Enochsson L**, Thulin A, Osterberg J, Sandblom G, Persson G. The Swedish Registry of Gallstone Surgery and Endoscopic Retrograde Cholangiopancreatography (GallRiks): A nationwide registry for quality assurance of gallstone surgery. *JAMA Surg* 2013; **148**: 471-478 [PMID: 23325144 DOI: 10.1001/jamasurg.2013.1221]
- Barrett M**, Asbun HJ, Chien HL, Brunt LM, Telem DA. Bile duct injury and morbidity following cholecystectomy: a need for improvement. *Surg Endosc* 2018; **32**: 1683-1688 [PMID: 28916877 DOI: 10.1007/s00464-017-5847-8]
- Strasberg SM**, Hertl M, Soper NJ. An analysis of the problem of biliary injury during laparoscopic cholecystectomy. *J Am Coll Surg* 1995; **180**: 101-125 [PMID: 8000648]
- Connor S**, Garden OJ. Bile duct injury in the era of laparoscopic cholecystectomy. *Br J Surg* 2006; **93**: 158-168 [PMID: 16432812 DOI: 10.1002/bjs.5266]
- Soper NJ**, Santos BF. Laparoscopic Cholecystectomy: Complications and Management. In: Tichansky DS, Morton J, Jones DB. The SAGES Manual of Quality, Outcomes and Patient Safety. 1st ed. Boston: Springer, 2012
- Karvonen J**, Salminen P, Grönroos JM. Bile duct injuries during open and laparoscopic cholecystectomy in the laparoscopic era: alarming trends. *Surg Endosc* 2011; **25**: 2906-2910 [PMID: 21432006 DOI: 10.1007/s00464-011-1641-1]
- Viste A**, Horn A, Øvrebo K, Christensen B, Angelsen JH, Hoem D. Bile duct injuries following laparoscopic cholecystectomy. *Scand J Surg* 2015; **104**: 233-237 [PMID: 25700851 DOI: 10.1177/1457496915570088]
- Rainio M**, Lindström O, Udd M, Haapamäki C, Nordin A, Kylänpää L. Endoscopic Therapy of Biliary Injury After Cholecystectomy. *Dig Dis Sci* 2018; **63**: 474-480 [PMID: 28948425 DOI: 10.1007/s10620-017-4768-7]
- Eum YO**, Park JK, Chun J, Lee SH, Ryu JK, Kim YT, Yoon YB, Yoon CJ, Han HS, Hwang JH. Non-surgical treatment of post-surgical bile duct injury: clinical implications and outcomes. *World J Gastroenterol* 2014; **20**: 6924-6931 [PMID: 24944484 DOI: 10.3748/wjg.v20.i22.6924]
- Schreuder AM**, Busch OR, Besselink MG, Ignatavicius P, Gulbinas A, Barauskas G, Gouma DJ, van Gulik TM. Long-Term Impact of Iatrogenic Bile Duct Injury. *Dig Surg* 2020; **37**: 10-21 [PMID: 30654363 DOI: 10.1159/000496432]
- Schreuder AM**, Nunez Vas BC, Booi KAC, van Dieren S, Besselink MG, Busch OR, van Gulik TM. Optimal timing for surgical reconstruction of bile duct injury: meta-analysis. *BJS Open* 2020; **4**: 776-786 [PMID: 32852893 DOI: 10.1002/bjs.5.50321]
- Savader SJ**, Lillemoe KD, Prescott CA, Winick AB, Venbrux AC, Lund GB, Mitchell SE, Cameron JL, Osterman FA Jr. Laparoscopic cholecystectomy-related bile duct injuries: a health and financial disaster. *Ann Surg* 1997; **225**: 268-273 [PMID: 9060582 DOI: 10.1097/00000658-199703000-00005]
- Andersson R**, Eriksson K, Blind PJ, Tingstedt B. Iatrogenic bile duct injury--a cost analysis. *HPB (Oxford)* 2008; **10**: 416-419 [PMID: 19088927 DOI: 10.1080/13651820802140745]
- Gupta V**, Jain G. Safe laparoscopic cholecystectomy: Adoption of universal culture of safety in cholecystectomy. *World J Gastrointest Surg* 2019; **11**: 62-84 [PMID: 30842813 DOI: 10.4240/wjgs.v11.i2.62]
- Nordin A**, Grönroos JM, Mäkisalo H. Treatment of biliary complications after laparoscopic cholecystectomy. *Scand J Surg* 2011; **100**: 42-48 [PMID: 21482504 DOI: 10.1177/145749691110000108]
- Mangieri CW**, Hendren BP, Strode MA, Bandera BC, Faler BJ. Bile duct injuries (BDI) in the advanced laparoscopic cholecystectomy era. *Surg Endosc* 2019; **33**: 724-730 [PMID: 30006843 DOI: 10.1007/s00464-018-6333-7]
- Brunt LM**, Deziel DJ, Telem DA, Strasberg SM, Aggarwal R, Asbun H, Bonjer J, McDonald M, Alseidi A, Ujiki M, Riall TS, Hammill C, Moulton CA, Pucher PH, Parks RW, Ansari MT, Connor S, Dirks RC, Anderson B, Altieri MS, Tsamalaidze L, Stefanidis D; and the Prevention of Bile Duct Injury Consensus Work Group. Safe Cholecystectomy Multi-society Practice Guideline and State of the Art Consensus Conference on Prevention of Bile Duct Injury During Cholecystectomy. *Ann Surg* 2020; **272**: 3-23 [PMID: 32404658 DOI: 10.1097/SLA.0000000000003791]
- Vilatóbá M**, Chávez-Villa M, Figueroa-Méndez R, Domínguez-Rosado I, Cruz-Martínez R, Leal-Villalpando RP, García-Juárez I, Mercado MA. Liver Transplantation as Definitive Treatment of Post-cholecystectomy Bile Duct Injury: Experience in a High-volume Repair Center. *Ann Surg* 2022; **275**: e729-e732 [PMID: 35084146 DOI: 10.1097/SLA.0000000000005245]

- 23 Schmidt SC, Settmacher U, Langrehr JM, Neuhaus P. Management and outcome of patients with combined bile duct and hepatic arterial injuries after laparoscopic cholecystectomy. *Surgery* 2004; **135**: 613-618 [PMID: [15179367](#) DOI: [10.1016/j.surg.2003.11.018](#)]
- 24 de Reuver PR, Grossmann I, Busch OR, Obertop H, van Gulik TM, Gouma DJ. Referral pattern and timing of repair are risk factors for complications after reconstructive surgery for bile duct injury. *Ann Surg* 2007; **245**: 763-770 [PMID: [17457169](#) DOI: [10.1097/01.sla.0000252442.91839.44](#)]
- 25 Patel N, Jensen KK, Shaaban AM, Korngold E, Foster BR. Multimodality Imaging of Cholecystectomy Complications. *Radiographics* 2022; **42**: 1303-1319 [PMID: [35904983](#) DOI: [10.1148/rg.210106](#)]
- 26 Terho P, Sallinen V, Lampela H, Harju J, Koskenvuo L, Mentula P. The Critical View of Safety in Laparoscopic Cholecystectomy: User Trends Among Residents and Consultants. *Surg Laparosc Endosc Percutan Tech* 2022; **32**: 453-461 [PMID: [35881992](#) DOI: [10.1097/SLE.0000000000001077](#)]
- 27 Iwashita Y, Hibi T, Ohyama T, Umezawa A, Takada T, Strasberg SM, Asbun HJ, Pitt HA, Han HS, Hwang TL, Suzuki K, Yoon YS, Choi IS, Yoon DS, Huang WS, Yoshida M, Wakabayashi G, Miura F, Okamoto K, Endo I, de Santibañes E, Giménez ME, Windsor JA, Garden OJ, Gouma DJ, Cherqui D, Belli G, Dervenis C, Deziel DJ, Jonas E, Jagannath P, Supre AN, Singh H, Liao KH, Chen XP, Chan ACW, Lau WY, Fan ST, Chen MF, Kim MH, Honda G, Sugioka A, Asai K, Wada K, Mori Y, Higuchi R, Misawa T, Watanabe M, Matsumura N, Rikiyama T, Sata N, Kano N, Tokumura H, Kimura T, Kitano S, Inomata M, Hirata K, Sumiyama Y, Inui K, Yamamoto M. Delphi consensus on bile duct injuries during laparoscopic cholecystectomy: an evolutionary cul-de-sac or the birth pangs of a new technical framework? *J Hepatobiliary Pancreat Sci* 2017; **24**: 591-602 [PMID: [28884962](#) DOI: [10.1002/jhbp.503](#)]
- 28 Törnqvist B, Strömberg C, Persson G, Nilsson M. Effect of intended intraoperative cholangiography and early detection of bile tract injury on survival after cholecystectomy: population based cohort study. *BMJ* 2012; **345**: e6457 [PMID: [23060654](#) DOI: [10.1136/bmj.e6457](#)]
- 29 Omiya K, Hiramatsu K, Kato T, Shibata Y, Yoshihara M, Aoba T, Arimoto A, Ito A. Preoperative MRI for predicting pathological changes associated with surgical difficulty during laparoscopic cholecystectomy for acute cholecystitis. *BJS Open* 2020; **4**: 1137-1145 [PMID: [32894010](#) DOI: [10.1002/bjs.5.50344](#)]
- 30 Conrad C, Wakabayashi G, Asbun HJ, Dallemagne B, Demartines N, Diana M, Fuks D, Giménez ME, Gouma DJ, Kaneko H, Memeo R, Resende A, Scatton O, Schneck AS, Soubrane O, Tanabe M, van den Bos J, Weiss H, Yamamoto M, Marescaux J, Pessaux P. IRCAD recommendation on safe laparoscopic cholecystectomy. *J Hepatobiliary Pancreat Sci* 2017; **24**: 603-615 [PMID: [29076265](#) DOI: [10.1002/jhbp.491](#)]
- 31 Krähenbühl L, Sclabas G, Wente MN, Schäfer M, Schlumpf R, Büchler MW. Incidence, risk factors, and prevention of biliary tract injuries during laparoscopic cholecystectomy in Switzerland. *World J Surg* 2001; **25**: 1325-1330 [PMID: [11596898](#) DOI: [10.1007/s00268-001-0118-0](#)]
- 32 Rustagi T, Aslanian HR. Endoscopic management of biliary leaks after laparoscopic cholecystectomy. *J Clin Gastroenterol* 2014; **48**: 674-678 [PMID: [24296422](#) DOI: [10.1097/MCG.0000000000000044](#)]
- 33 Kaffes AJ, Hourigan L, De Luca N, Byth K, Williams SJ, Bourke MJ. Impact of endoscopic intervention in 100 patients with suspected postcholecystectomy bile leak. *Gastrointest Endosc* 2005; **61**: 269-275 [PMID: [15729238](#) DOI: [10.1016/s0016-5107\(04\)02468-x](#)]
- 34 Dumonceau JM, Tringali A, Papanikolaou IS, Blero D, Mangiavillano B, Schmidt A, Vanbiervliet G, Costamagna G, Devière J, García-Cano J, Gyökeres T, Hassan C, Prat F, Siersema PD, van Hooft JE. Endoscopic biliary stenting: indications, choice of stents, and results: European Society of Gastrointestinal Endoscopy (ESGE) Clinical Guideline - Updated October 2017. *Endoscopy* 2018; **50**: 910-930 [PMID: [30086596](#) DOI: [10.1055/a-0659-9864](#)]
- 35 Siiki A, Vaalavuo Y, Anttila A, Ukkonen M, Rinta-Kiikka I, Sand J, Laukkanen J. Biodegradable biliary stents preferable to plastic stent therapy in post-cholecystectomy bile leak and avoid second endoscopy. *Scand J Gastroenterol* 2018; **53**: 1376-1380 [PMID: [30394150](#) DOI: [10.1080/00365521.2018.1518480](#)]
- 36 Lam R, Muniraj T. Fully covered metal biliary stents: A review of the literature. *World J Gastroenterol* 2021; **27**: 6357-6373 [PMID: [34720527](#) DOI: [10.3748/wjg.v27.i38.6357](#)]
- 37 Luigiano C, Bassi M, Ferrara F, Fabbri C, Ghersi S, Morace C, Consolo P, Maimone A, Galluccio G, D'Imperio N, Cennamo V. Placement of a new fully covered self-expanding metal stent for postoperative biliary strictures and leaks not responding to plastic stenting. *Surg Laparosc Endosc Percutan Tech* 2013; **23**: 159-162 [PMID: [23579510](#) DOI: [10.1097/SLE.0b013e318278c201](#)]
- 38 Fukuda K, Nakai Y, Mizuno S, Sato T, Noguchi K, Kanai S, Suzuki T, Hakuta R, Ishigaki K, Saito K, Saito T, Takahara N, Hamada T, Kogure H, Fujishiro M. Endoscopic Bridge-and-Seal of Bile Leaks Using a Fully Covered Self-Expandable Metallic Stent above the Papilla. *J Clin Med* 2022; **11** [PMID: [36294340](#) DOI: [10.3390/jcm11206019](#)]
- 39 Strasberg SM. A three-step conceptual roadmap for avoiding bile duct injury in laparoscopic cholecystectomy: an invited perspective review. *J Hepatobiliary Pancreat Sci* 2019; **26**: 123-127 [PMID: [30828991](#) DOI: [10.1002/jhbp.616](#)]
- 40 Perera MT, Silva MA, Hegab B, Muralidharan V, Bramhall SR, Mayer AD, Buckels JA, Mirza DF. Specialist early and immediate repair of post-laparoscopic cholecystectomy bile duct injuries is associated with an improved long-term outcome. *Ann Surg* 2011; **253**: 553-560 [PMID: [21217507](#) DOI: [10.1097/SLA.0b013e318208fad3](#)]
- 41 Smits FJ, Henry AC, Besselink MG, Busch OR, van Eijck CH, Arntz M, Bollen TL, van Delden OM, van den Heuvel D, van der Leij C, van Lienden KP, Moelker A, Bonsing BA, Borel Rinkes IH, Bosscha K, van Dam RM, Derksen WJM, den Dulk M, Festen S, Groot Koerkamp B, de Haas RJ, Hagendoorn J, van der Harst E, de Hingh IH, Kazemier G, van der Kolk M, Liem M, Lips DJ, Luyer MD, de Meijer VE, Mieog JS, Nieuwenhuijs VB, Patijn GA, Te Riele WW, Roos D, Schreinemakers JM, Stommel MWJ, Wit F, Zonderhuis BA, Daamen LA, van Werkhoven CH, Molenaar IQ, van Santvoort HC; Dutch Pancreatic Cancer Group. Algorithm-based care vs usual care for the early recognition and management of complications after pancreatic resection in the Netherlands: an open-label, nationwide, stepped-wedge cluster-randomised trial. *Lancet* 2022; **399**: 1867-1875 [PMID: [35490691](#) DOI: [10.1016/S0140-6736\(22\)00182-9](#)]



Published by **Baishideng Publishing Group Inc**
7041 Koll Center Parkway, Suite 160, Pleasanton, CA 94566, USA

Telephone: +1-925-3991568

E-mail: bpgoffice@wjgnet.com

Help Desk: <https://www.f6publishing.com/helpdesk>

<https://www.wjgnet.com>

