

# World Journal of *Gastrointestinal Surgery*

*World J Gastrointest Surg* 2023 June 27; 15(6): 1007-1261



## Contents

Monthly Volume 15 Number 6 June 27, 2023

## OPINION REVIEW

- 1007 Diverticulitis is a population health problem: Lessons and gaps in strategies to implement and improve contemporary care  
*Stovall SL, Kaplan JA, Law JK, Flum DR, Simianu VV*

## REVIEW

- 1020 Distal pancreatectomy with or without radical approach, vascular resections and splenectomy: Easier does not always mean easy  
*Bencini L, Minuzzo A*

## MINIREVIEWS

- 1033 Endoscopic ultrasound-guided portal pressure gradient measurement in managing portal hypertension  
*Lesmana CRA*
- 1040 Robotic surgery in elderly patients with colorectal cancer: Review of the current literature  
*Teo NZ, Ngu JCY*
- 1048 Median arcuate ligament syndrome often poses a diagnostic challenge: A literature review with a scope of our own experience  
*Giakoustidis A, Moschonas S, Christodoulidis G, Chourmouzi D, Diamantidou A, Masoura S, Louri E, Papadopoulos VN, Giakoustidis D*
- 1056 Surgical complications of oncological treatments: A narrative review  
*Fico V, Altieri G, Di Grezia M, Bianchi V, Chiarello MM, Pepe G, Tropeano G, Brisinda G*

## ORIGINAL ARTICLE

## Basic Study

- 1068 Impact of interstitial cells of Cajal on slow wave and gallbladder contractility in a guinea pig model of acute cholecystitis  
*Ding F, Guo R, Chen F, Liu LP, Cui ZY, Wang YX, Zhao G, Hu H*

## Retrospective Cohort Study

- 1080 Fascia- vs vessel-oriented lateral lymph node dissection for rectal cancer: Short-term outcomes and prognosis in a single-center experience  
*Zhao W, Wang ZJ, Mei SW, Chen JN, Zhou SC, Zhao FQ, Xiao TX, Huang F, Liu Q*
- 1093 Prognostic value of 11-factor modified frailty index in postoperative adverse outcomes of elderly gastric cancer patients in China  
*Xu ZY, Hao XY, Wu D, Song QY, Wang XX*

**Retrospective Study**

- 1104** Long-term outcomes and failure patterns after laparoscopic intersphincteric resection in ultralow rectal cancers  
*Qiu WL, Wang XL, Liu JG, Hu G, Mei SW, Tang JQ*
- 1116** Predictors for success of non-operative management of adhesive small bowel obstruction  
*Ng ZQ, Hsu V, Tee WWH, Tan JH, Wijesuriya R*
- 1125** Preoperative albumin-bilirubin score is a prognostic factor for gastric cancer patients after curative gastrectomy  
*Szor DJ, Pereira MA, Ramos MFKP, Tustumi F, Dias AR, Zilberstein B, Ribeiro Jr U*
- 1138** Ability of lactulose breath test results to accurately identify colorectal polyps through the measurement of small intestine bacterial overgrowth  
*Li L, Zhang XY, Yu JS, Zhou HM, Qin Y, Xie WR, Ding WJ, He XX*
- 1149** Treatment outcome analysis of bevacizumab combined with cyclophosphamide and oxaliplatin in advanced pseudomyxoma peritonei  
*Zhang Y, Zhao X, Gao C, Lin LY, Li Y*
- 1159** Surgical management of duodenal Crohn's disease  
*Yang LC, Wu GT, Wu Q, Peng LX, Zhang YW, Yao BJ, Liu GL, Yuan LW*
- 1169** Influences of dexmedetomidine on stress responses and postoperative cognitive and coagulation functions in patients undergoing radical gastrectomy under general anesthesia  
*Ma XF, Lv SJ, Wei SQ, Mao BR, Zhao XX, Jiang XQ, Zeng F, Du XK*
- 1178** Dissimilar survival and clinicopathological characteristics of mucinous adenocarcinoma located in pancreatic head and body/tail  
*Li Z, Zhang XJ, Sun CY, Li ZF, Fei H, Zhao DB*

**SYSTEMATIC REVIEWS**

- 1191** Gallbladder perforation with fistulous communication  
*Quiroga-Garza A, Alvarez-Villalobos NA, Muñoz-Leija MA, Garcia-Campa M, Angeles-Mar HJ, Jacobo-Baca G, Elizondo-Omana RE, Guzman-Lopez S*

**META-ANALYSIS**

- 1202** Efficacy of transanal drainage tube in preventing anastomotic leakage after surgery for rectal cancer: A meta-analysis  
*Fujino S, Yasui M, Ohue M, Miyoshi N*

**CASE REPORT**

- 1211** Percutaneous transhepatic cholangial drainage-guided methylene blue for fistulotomy using dual-knife for bile duct intubation: A case report  
*Tang BX, Li XL, Wei N, Tao T*

- 1216** Optimal resection of gastric bronchogenic cysts based on anatomical continuity with adherent gastric muscular layer: A case report  
*Terayama M, Kumagai K, Kawachi H, Makuuchi R, Hayami M, Ida S, Ohashi M, Sano T, Nunobe S*
- 1224** Intrahepatic cholangiocarcinoma in patients with primary sclerosing cholangitis and ulcerative colitis: Two case reports  
*Miyazu T, Ishida N, Asai Y, Tamura S, Tani S, Yamade M, Iwaizumi M, Hamaya Y, Osawa S, Baba S, Sugimoto K*
- 1232** Massive bleeding from a gastric artery pseudoaneurysm in hepatocellular carcinoma treated with atezolizumab plus bevacizumab: A case report  
*Pang FW, Chen B, Peng DT, He J, Zhao WC, Chen TT, Xie ZG, Deng HH*
- 1240** Bedside ultrasound-guided water injection assists endoscopically treatment in esophageal perforation caused by foreign bodies: A case report  
*Wei HX, Lv SY, Xia B, Zhang K, Pan CK*
- 1247** Modified stomach-partitioning gastrojejunostomy for initially unresectable advanced gastric cancer with outlet obstruction: A case report  
*Shao XX, Xu Q, Wang BZ, Tian YT*
- 1256** Small bowel diverticulum with enterolith causing intestinal obstruction: A case report  
*Wang LW, Chen P, Liu J, Jiang ZW, Liu XX*

**ABOUT COVER**

Editorial Board Member of *World Journal of Gastrointestinal Surgery*, Danko Mikulic, FEBS, MD, PhD, Assistant Professor, Surgeon, Department of Surgery, University Hospital Merkur, Zagreb 10000, Croatia.  
danko.mikulic@zg.t-com.hr

**AIMS AND SCOPE**

The primary aim of *World Journal of Gastrointestinal Surgery* (WJGS, *World J Gastrointest Surg*) is to provide scholars and readers from various fields of gastrointestinal surgery with a platform to publish high-quality basic and clinical research articles and communicate their research findings online.

WJGS mainly publishes articles reporting research results and findings obtained in the field of gastrointestinal surgery and covering a wide range of topics including biliary tract surgical procedures, biliopancreatic diversion, colectomy, esophagectomy, esophagostomy, pancreas transplantation, and pancreatectomy, etc.

**INDEXING/ABSTRACTING**

The WJGS is now abstracted and indexed in Science Citation Index Expanded (SCIE, also known as SciSearch®), Current Contents/Clinical Medicine, Journal Citation Reports/Science Edition, PubMed, PubMed Central, Reference Citation Analysis, China National Knowledge Infrastructure, China Science and Technology Journal Database, and Superstar Journals Database. The 2022 Edition of Journal Citation Reports® cites the 2021 impact factor (IF) for WJGS as 2.505; IF without journal self cites: 2.473; 5-year IF: 3.099; Journal Citation Indicator: 0.49; Ranking: 104 among 211 journals in surgery; Quartile category: Q2; Ranking: 81 among 93 journals in gastroenterology and hepatology; and Quartile category: Q4.

**RESPONSIBLE EDITORS FOR THIS ISSUE**

Production Editor: Rui-Rui Wu, Production Department Director: Xiang Li, Editorial Office Director: Jia-Ru Fan.

**NAME OF JOURNAL**

*World Journal of Gastrointestinal Surgery*

**ISSN**

ISSN 1948-9366 (online)

**LAUNCH DATE**

November 30, 2009

**FREQUENCY**

Monthly

**EDITORS-IN-CHIEF**

Peter Schemmer

**EDITORIAL BOARD MEMBERS**

<https://www.wjgnet.com/1948-9366/editorialboard.htm>

**PUBLICATION DATE**

June 27, 2023

**COPYRIGHT**

© 2023 Baishideng Publishing Group Inc

**INSTRUCTIONS TO AUTHORS**

<https://www.wjgnet.com/bpg/gerinfo/204>

**GUIDELINES FOR ETHICS DOCUMENTS**

<https://www.wjgnet.com/bpg/GerInfo/287>

**GUIDELINES FOR NON-NATIVE SPEAKERS OF ENGLISH**

<https://www.wjgnet.com/bpg/gerinfo/240>

**PUBLICATION ETHICS**

<https://www.wjgnet.com/bpg/GerInfo/288>

**PUBLICATION MISCONDUCT**

<https://www.wjgnet.com/bpg/gerinfo/208>

**ARTICLE PROCESSING CHARGE**

<https://www.wjgnet.com/bpg/gerinfo/242>

**STEPS FOR SUBMITTING MANUSCRIPTS**

<https://www.wjgnet.com/bpg/GerInfo/239>

**ONLINE SUBMISSION**

<https://www.f6publishing.com>





## Surgical complications of oncological treatments: A narrative review

Valeria Fico, Gaia Altieri, Marta Di Grezia, Valentina Bianchi, Maria Michela Chiarello, Gilda Pepe, Giuseppe Tropeano, Giuseppe Brisinda

**Specialty type:** Surgery

**Provenance and peer review:**

Invited article; Externally peer reviewed.

**Peer-review model:** Single blind

**Peer-review report's scientific quality classification**

Grade A (Excellent): 0

Grade B (Very good): B

Grade C (Good): 0

Grade D (Fair): D

Grade E (Poor): 0

**P-Reviewer:** Amagai T, Japan; Oley MH, Indonesia

**Received:** January 16, 2023

**Peer-review started:** January 16, 2023

**First decision:** January 31, 2023

**Revised:** February 3, 2023

**Accepted:** April 17, 2023

**Article in press:** April 17, 2023

**Published online:** June 27, 2023



**Valeria Fico, Gaia Altieri, Marta Di Grezia, Valentina Bianchi, Gilda Pepe, Giuseppe Tropeano, Giuseppe Brisinda,** Emergency Surgery and Trauma Center, Fondazione Policlinico Universitario A Gemelli IRCCS, Rome 00168, Italy

**Maria Michela Chiarello,** Department of Surgery, Azienda Sanitaria Provinciale di Cosenza, Cosenza 87100, Italy

**Giuseppe Brisinda,** Department of Medicine and Surgery, Catholic School of Medicine, Rome 00168, Italy

**Corresponding author:** Giuseppe Brisinda, MD, Professor, Surgeon, Emergency Surgery and Trauma Center, Fondazione Policlinico Universitario A Gemelli IRCCS, 8 Largo Agostino Gemelli, Rome 00168, Italy. [gbrisin@tin.it](mailto:gbrisin@tin.it)

### Abstract

Gastrointestinal complications are common in patients undergoing various forms of cancer treatments, including chemotherapy, radiation therapy, and molecular-targeted therapies. Surgical complications of oncologic therapies can occur in the upper gastrointestinal tract, small bowel, colon, and rectum. The mechanisms of action of these therapies are different. Chemotherapy includes cytotoxic drugs, which block the activity of cancer cells by targeting intracellular DNA, RNA, or proteins. Gastrointestinal symptoms are very common during chemotherapy, due to a direct effect on the intestinal mucosa resulting in edema, inflammation, ulceration, and stricture. Serious adverse events have been described as complications of molecular targeted therapies, including bowel perforation, bleeding, and pneumatosis intestinalis, which may require surgical evaluation. Radiotherapy is a local anti-cancer therapy, which uses ionizing radiation to cause inhibition of cell division and ultimately lead to cell death. Complications related to radiotherapy can be both acute and chronic. Ablative therapies, including radiofrequency, laser, microwave, cryoablation, and chemical ablation with acetic acid or ethanol, can cause thermal or chemical injuries to the nearby structures. Treatment of the different gastrointestinal complications should be tailored to the individual patient and based on the underlying pathophysiology of the complication. Furthermore, it is important to know the stage and prognosis of the disease, and a multidisciplinary approach is necessary to personalize the surgical treatment. The purpose of this narrative review is to describe complications related to different oncologic therapies that may require surgical interventions.

**Key Words:** Cancer; Chemotherapy; Radiotherapy; Complications; Bowel perforation;

## Gastrointestinal bleeding

©The Author(s) 2023. Published by Baishideng Publishing Group Inc. All rights reserved.

**Core Tip:** Gastrointestinal complications are common in patients undergoing various forms of cancer treatments, including chemotherapy, radiation therapy, and molecular-targeted therapies. Surgical complications of oncologic therapies can occur in the upper gastrointestinal tract, small bowel, colon, and rectum. Treatment of the different gastrointestinal complications should be tailored to the individual patient and based on the underlying pathophysiology of the complication.

**Citation:** Fico V, Altieri G, Di Grezia M, Bianchi V, Chiarello MM, Pepe G, Tropeano G, Brisinda G. Surgical complications of oncological treatments: A narrative review. *World J Gastrointest Surg* 2023; 15(6): 1056-1067

**URL:** <https://www.wjgnet.com/1948-9366/full/v15/i6/1056.htm>

**DOI:** <https://dx.doi.org/10.4240/wjgs.v15.i6.1056>

## INTRODUCTION

Oncological treatments have greatly improved in the past few decades, thanks to the introduction of new therapies, such as immunologic agents or molecular targeted therapies, used alone or in combination with traditional chemotherapy and radiotherapy. The mechanisms of action of the various cancer therapies are different. Chemotherapy includes cytotoxic drugs, which block the activity of cancer cells by targeting intracellular DNA, RNA, or proteins[1,2].

Gastrointestinal symptoms are very common during chemotherapy, due to a direct effect on the intestinal mucosa resulting in edema, inflammation, ulceration, and stricture[3].

The development of molecular targeted therapies was due to the advances in oncological molecular biology. They include monoclonal antibody to vascular endothelial growth factor (VEGF) and epidermal growth factor receptor (EGFR), and tyrosine kinase inhibitors[1]. These drugs modify biological characteristics of tumor cells and have a key role to selectively block some mechanisms related to cell growth, proliferation, and invasion[2]. Serious adverse events have been described as complications of molecular targeted therapies, including bowel perforation, bleeding, and pneumatosis intestinalis (PI), which may require surgical evaluation[2,4-10].

To date, immunotherapy represents the standard of care for different types of cancer. Several agents, such as cytotoxic T-lymphocyte-associated protein-4 (CTLA-4) and inhibitors of programmed cell death protein-1 (PD-1) and its ligand (PD-L1), inhibit tumor growth through the stimulation of the body's immune system against cancer. Immune-related adverse events mostly affect the gastrointestinal system, with heterogeneous symptoms that evolve into bowel ischemia or perforation, rarely[11,12].

Radiotherapy is a local anti-cancer therapy, which uses ionizing radiation to cause inhibition of cell division and ultimately lead to cell death[1]. Complications related to radiotherapy can be both acute and chronic. Acute symptoms occur within 2 mo and usually resolve in 3 mo[13,14]. Chronic symptoms, instead, occur months to years after radiotherapy. A high radiation dose, wide radiation area, long-term radiotherapy, and concurrent chemotherapy, are the factors related to an increased risk of toxicity[15]. The incidence of severe intestinal injury after abdominopelvic radiotherapy is about 4%-8%, and the main potentially surgical complications are perforation, strictures, abscesses, fistulas, and bleeding[16].

Ablative therapies, such as radiofrequency, laser, microwave, cryoablation, and chemical ablation with acetic acid or ethanol, can cause thermal or chemical injuries to the nearby structures[2].

As cancer treatments improve and new drugs are introduced, complications associated with oncologic therapies also increase. Many of these complications are life-threatening and have a high morbidity. As such, they require a prompt diagnosis. Therefore, it is crucial for surgeons to know the different complications and the therapies that can cause them, in order to ensure an immediate surgical treatment, if needed. In addition, knowing the stage and the prognosis of the disease is fundamental, and a multidisciplinary approach is necessary in order to personalize the surgical treatment. The purpose of this narrative review is to describe the complications related to different oncologic therapies that may require surgical interventions.

## ENTEROCOLITIS

Neutropenic enterocolitis or typhlitis is typically diagnosed in patients with severe neutropenia related to oncologic treatment. This is a clinical syndrome characterized by abdominal pain, especially in the

right lower quadrant, and fever. A systematic review by Gorschlüter *et al*[17] showed an incidence of 5.3% of neutropenic enterocolitis in patients treated for hematologic cancers or treated with high dose chemotherapy for solid tumors. Moreover, 7.0% of individuals undergoing myelosuppressive chemotherapy courses for hematologic malignancies will develop *Clostridium difficile*-associated diarrhea, of whom 8.2% will develop severe enterocolitis, compared with the 2.8% incidence in general inpatient cohorts[18,19].

On computed tomography (CT), the cecum is most frequently affected by circumferential wall thickening with involvement of pericolic fat. The most severe form of neutropenic enterocolitis can be characterized by bowel necrosis and perforation. Therefore, a right colectomy should be performed to prevent complications, if there is no improvement in clinical condition within 2-3 d of conservative treatment[20,21].

Radiotherapy can also cause enterocolitis, and the sigmoid colon and rectum are the most affected segments in patients treated for pelvic cancers. Acute enterocolitis, due to edema, inflammation, and atrophy related to mucosal stem cell damage, manifests with abdominal pain, nausea, and diarrhea, and it is usually self-limiting in 2-6 wk with symptomatic treatments[1,15,22].

The pathophysiological mechanism that determines the development of chronic enterocolitis is based on the gradual increase in fibrosis of the intestinal wall, due to collagen deposition[22]. Radiotherapy-related vascular injury causing ischemia is another significant factor.

Chronic radiation enteritis affects 5% of patients treated with a dose of 45 Gy, reaching 50% in those treated with 65 Gy[23,24], and the terminal ileum is more commonly affected (Figure 1). Chronic radiation colitis occurs in 1%-5% of patients[25] and symptoms usually develop 6-12 mo after treatment. Bleeding, fistulas, abscesses, and stricture causing intestinal obstruction are the clinical manifestations of radiotherapy-related enterocolitis that may involve the surgeon.

Patients undergoing chemotherapy may develop *Clostridium difficile* colitis (Figure 2), especially when treated with cyclophosphamide, methotrexate, fluorouracil, and doxorubicin[26]. Indications for surgery are the same as for antibiotic-related pseudomembranous colitis (*i.e.*, perforation, fulminant toxic megacolon, and organ failure).

The most common gastrointestinal complications in case of treatment with checkpoint inhibitors are diarrhea and colitis, mainly in patients treated with anti-CTLA-4 (ipilimumab)[27]. Enterocolitis associated with immunotherapy has an incidence of 2.0%[28], which increases to 40.0% in patients on ipilimumab[29], and usually develops after 6-7 wk of treatment. Bowel perforation and death occur respectively in 1.0% and 0.8% of patients[27-31].

To sum up, surgery is required in all the enterocolitis cases consequent to oncological treatment if there is evidence of persistent bleeding, ischemia, perforation, or clinical worsening despite conservative treatment.

## PNEUMATOSIS

PI is a rare clinical condition characterized by the presence of air in the thickness of the intestinal wall. It is difficult to estimate the incidence of PI, as it is very often asymptomatic. However, its overall incidence, based on autopsy findings, is 0.03%[32].

PI can be idiopathic (about 15% of cases), when a cause cannot be identified, or secondary (about 85% of cases)[33]. In these cases, PI is associated with gastrointestinal or pulmonary diseases, mechanical ventilation, endoscopic procedures, infections, and drugs.

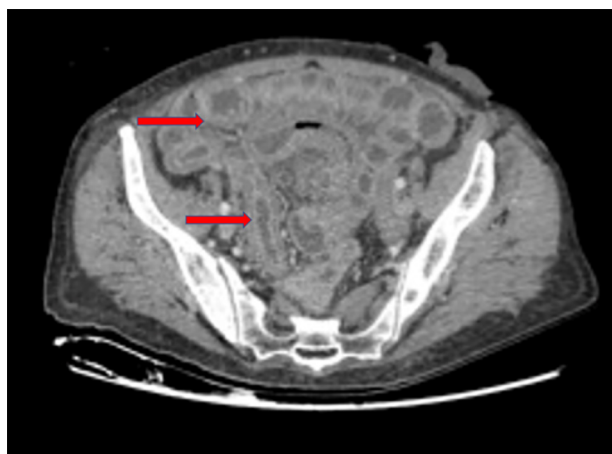
PI (Figure 3) can also occur as a complication of oncological medical therapies, including cytotoxic agents (cyclophosphamide, cytarabine, vincristine, doxorubicin, etoposide, docetaxel, irinotecan, and cisplatin) and molecular targeted agents (tyrosine kinase inhibitors such as imatinib, sunitinib, lenvatinib, and erlotinib; anti-VEGF monoclonal antibodies such as bevacizumab or anti-EGFR monoclonal antibodies such as cetuximab)[34,35].

The pathophysiological mechanisms underlying intestinal pneumatosis are not yet completely understood. As regards chemotherapeutic drugs, the most probable pathogenetic mechanism is the cytotoxic or ischemic damage caused by these drugs to the mucous layer of the intestinal wall. This damage would lead to the entry of gas, which is physiologically contained in the intestinal lumen, into the intestinal wall[36].

Chemotherapy-induced PI is also due to the myelosuppressive effects of drugs, which induce bone marrow aplasia and inhibit the regeneration process of damaged tissue[6]. Targeted therapies, on the other hand, are specific drugs that act as anti-VEGF/VEGFR, anti-EGFR, anti-PDGFR, and c-KIT inhibitors. These can determine a decrease in capillary density causing ischemia (anti-VEGF/VEGFR), a decrease in the efficiency in repairing intestinal damage (anti-EGFR, anti-PDGFR, and c-KIT inhibitors), and a reduction in intestinal motility (c-KIT inhibitors) by acting on Cajal cells[22,37-39].

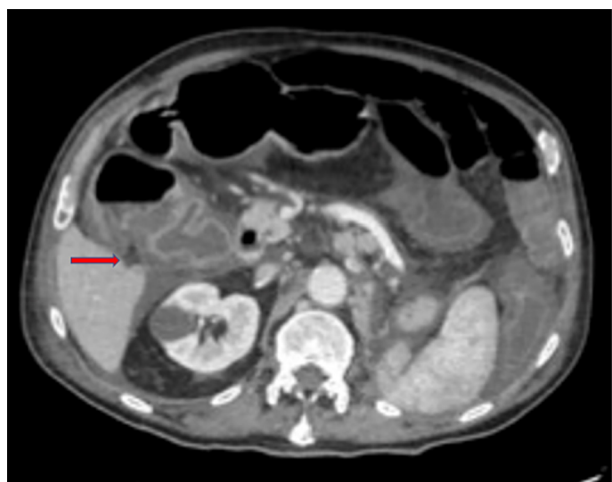
According to a recent paper by Gazzaniga *et al*[6], PI mainly occurs in stage IV cancer patients (69.4% vs 11.1% of patients treated with a neoadjuvant therapy and 2.8% in adjuvant setting), and with the use of targeted therapies. PI is asymptomatic in most cases, and it is very often an occasional finding on CT performed in oncological patients to monitor response to chemotherapy. No therapy is required in





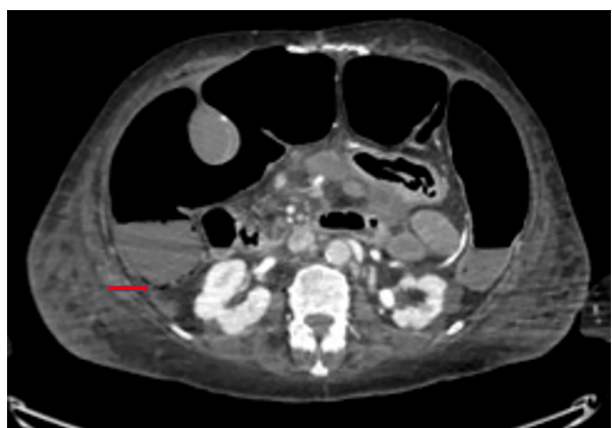DOI: 10.4240/wjgs.v15.i6.1056 Copyright ©The Author(s) 2023.

**Figure 1** Chronic radiation enteritis in a 62-year-old woman with anal cancer. Red arrows indicate regions where radiation enteritis is most evident (personal observation).



DOI: 10.4240/wjgs.v15.i6.1056 Copyright ©The Author(s) 2023.

**Figure 2** *Clostridium difficile* colitis (red arrow) in a 78-year-old man with a malignant tumor of the lung treated with cyclophosphamide. (personal observation).



DOI: 10.4240/wjgs.v15.i6.1056 Copyright ©The Author(s) 2023.

**Figure 3** Bevacizumab-related intestinal pneumatosis with right colon ischemia in a 69-year-old woman being treated for breast cancer. Red arrows indicate regions where pneumatosis is most evident (personal observation).

asymptomatic patients with PI. If present, symptoms can be extremely variable and may be indicative of bowel ischemia. The presence of hepatic and portomesenteric venous gas on a CT scan, associated with abdominal pain and alterations of blood tests and vital parameters, can be indicative of an ischemic pathology[40]. Hence, they require a prompt surgical exploration.

In fact, several studies in the literature demonstrated that the presence of gas in the portal vein is correlated to a transmural bowel ischemia in more than 90% of patients, and it is linked to a poor prognosis[41,42].

Therefore, it is very important to discriminate the cases in which surgery is necessary, to perform an immediate laparoscopy or laparotomy to avoid the progression of necrosis.

## OBSTRUCTION

Intestinal obstructions represent an extremely common clinical condition in cancer patients, and they are caused by the tumor mass in most cases. Nevertheless, they can also be an effect of oncological therapies. Radiotherapy can induce a process of fibro-apoptosis which reduces the elasticity of the wall of the hollow viscera until it determines a stenosis. Small bowel strictures consequent to radiation therapy are a rare complication, caused by wall thickening and edema, which develop in 6-12 mo and occur especially in the terminal ileum, owing to its fixed position[22,43]. Intestinal obstructions caused by chronic radiation enteritis should be initially treated conservatively by fluid infusion, nasogastric tube placement, and possible use of laxatives[4,5].

Surgical treatment is indicated if there is no clinical response to medical therapy. One-third of patients with chronic radiation enteritis require surgery, approximately. Surgery is associated with a high morbidity rate and a high risk of reoperation. It is fundamental to resect the entire bowel involved in the stricture to prevent recurrence of obstruction, and to reduce complication and mortality rates[24]. Radiation therapy can also cause strictures of the esophagus and rectum[44,45]. In these cases, endoscopy is the treatment of choice with endoscopic dilatation and placement of self-expanding stents. Intestinal strictures caused by cytotoxic drugs, such as 5-fluorouracil and monoclonal antibodies (*i.e.*, nivolumab) are extremely rare, but described in the literature[46,47].

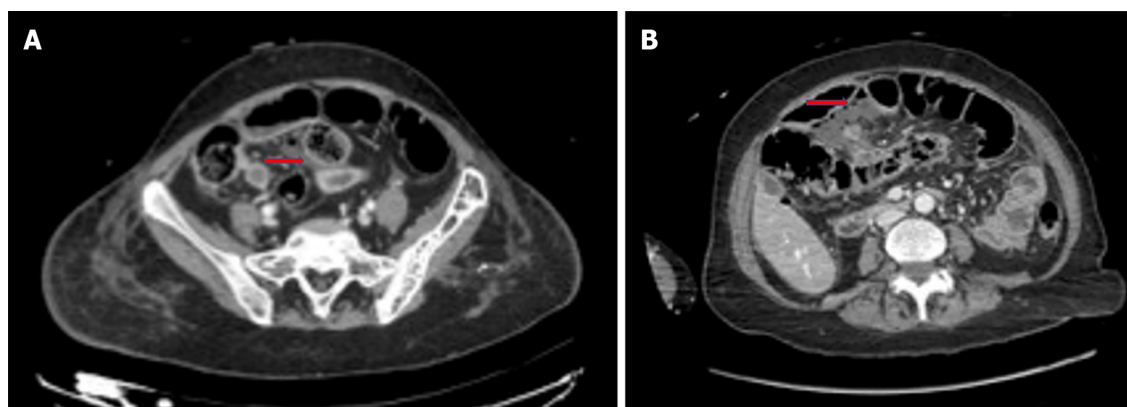
## PERFORATION

Bowel perforation is a rare but serious complication of cancer treatments. It has been reported in association with chemotherapy, molecular targeted therapies, immunotherapy, ablative techniques for solid tumors, and radiation therapy. Several mechanisms may be responsible for gastrointestinal perforation from oncologic treatments. Anticancer drugs induce vascular damage by thrombosis and thromboembolism, and when intestinal vessels are involved, bowel ischemia with perforation may occur[12]. Perforation of the gastrointestinal tract can also occur after prolonged obstruction[48] or due to treatment responses with tumor lysis, as in cases of lymphomas or gastrointestinal stromal tumors [20]. Finally, bowel perforation can be a result of other complications of oncologic therapies, like pneumatosis or enterocolitis. Management of perforation with no generalized peritonitis may be based on placement of image-guided percutaneous drainage in case of fluid collections. If there is a free perforation, instead, urgent laparotomy is needed, primarily to limit septic complications, which are characterized by a very high mortality rate in patients with neutropenia[20]. Gastrointestinal perforation has been reported in the literature with several chemotherapy agents, including fluorouracil, taxols, cisplatin, interleukin-2, and mytomicin[49-52]. Among the molecular targeted therapies, bevacizumab is most commonly associated with gastrointestinal perforation (Figure 4), with an incidence of 0.9%[53], and a correlation with late anastomotic leakage[54]. Risk factors for bevacizumab-related perforation are specific tumors (colorectal, prostate, and gynecological cancers), combination with other treatments, such as oxaliplatin and taxanes, presence of a primary tumor *in situ*, and recent history of endoscopy or abdominal radiotherapy[53,55-57].

Bowel perforation occurs in 80% of patients during the first 6 mo after bevacizumab administration [58], and the most common sites of perforation are the colon, small intestine and stomach[9]. The pathophysiological mechanisms underlying bowel perforation from molecular targeted therapy are different: The antiangiogenic action, which reduces capillary density of the mucosa layer and compromises intestinal wall integrity; the tumor lysis, in response to treatment; the increased risk of thromboembolic events in mesenteric vessels; and the regression of normal blood vessels[8,59].

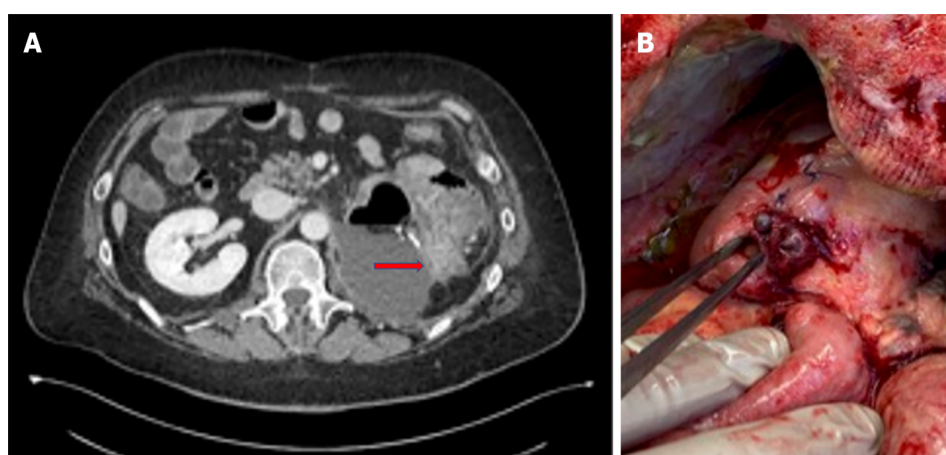
Several studies in the literature also show an association between gastrointestinal perforation and antiangiogenic tyrosine kinase inhibitors, like erlotinib, regorafenib, sunitinib, and sorafenib[10,60-64] (Figure 5).

The incidence of tyrosine kinase inhibitors-related bowel perforation is still unknown, since there are mainly case reports in the literature. Intestinal perforation after immunotherapy is a rare event (Figure 6). A case report by Patel *et al*[31] described a jejunal perforation after treatment with ipilimumab and nivolumab for metastatic melanoma, related to tumor regression. Another paper by



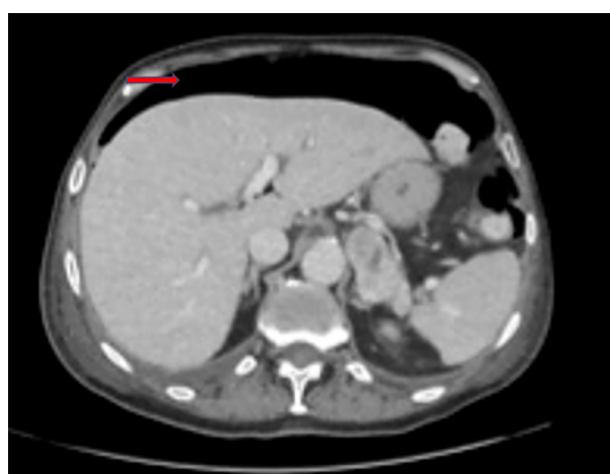
DOI: 10.4240/wjgs.v15.i6.1056 Copyright ©The Author(s) 2023.

**Figure 4 Computed tomography images.** A: Bevacizumab-related small bowel perforation in a 49-year-old female patient with breast cancer (red arrow); B: Bevacizumab-related late anastomotic leakage (red arrow) in a 72-year-old female colon cancer patient (personal observation).



DOI: 10.4240/wjgs.v15.i6.1056 Copyright ©The Author(s) 2023.

**Figure 5 Computed tomography and intraoperative findings.** A: Computed tomography scan of bowel perforation (red arrow) in a 56-year-old male patient undergoing molecular targeted therapy with capozatinib for metastatic renal cell carcinoma; B: Intraoperative findings in the same clinical case (personal observation).



DOI: 10.4240/wjgs.v15.i6.1056 Copyright ©The Author(s) 2023.

**Figure 6 Bowel perforation in a 73-year-old male lung cancer patient undergoing immunotherapy with atezolizumab.** The red arrow indicates subdiaphragmatic free air (personal observation).

Romano *et al*[65] reported a small bowel perforation in a patient treated with nivolumab for metastatic lung cancer. Radiofrequency or micro-wave ablation can cause injuries to nearby organs. Bowel perforation with formation of abscesses and fistulas or free peritonitis, can be due to ablative therapies on liver cancer or, to a greater extent, on solid renal tumors, for direct thermal or chemical injuries[2,3]. In the literature, 4%-8% of patients treated with abdominopelvic radiation therapy can develop serious complications such as fistulas, perforation, or abscesses[16,66].

A recent paper by Zhan *et al*[67] showed that both long course and short course radiotherapy as neoadjuvant treatment for locally advanced rectal cancer increased the risk of anastomotic leakage, without a rise in postoperative mortality.

Risk factors for bowel perforation following radiotherapy are radiation dose, size of irradiation field, and the combination with other cancer treatments[14]. Several studies describe cases of intestinal perforation following the use of radiotherapy together with antiangiogenic agents, like dabrafenib and trametinib for pelvic bone melanoma metastases[68], sorafenib in renal cancer patients[69], and gefitinib in a patient with lung cancer receiving lumbar irradiation[70]. The precise pathophysiology of radiotherapy-related bowel perforation is still unclear, but stem-cell and microvascular damage seems to have a pivotal role in gastrointestinal injuries affecting these patients.

## BLEEDING

Bleeding events in cancer patients can be caused by the disease itself or by medical treatments and require a surgical intervention, rarely. However, the surgeon may be involved in the multidisciplinary management of the patient or in case of failure of conservative treatments. Oncological therapies can affect the risk of hemorrhage both through alteration of the number or function of platelets and effect on the coagulation process. Some chemotherapeutic agents and anti-angiogenic targeted therapies are associated with increased bleeding tendency. For example, gastrointestinal bleeding has been described in patients receiving bevacizumab or in patients with gastrointestinal stromal tumors receiving imatinib or sunitinib[71,72].

Patients may present with different severity symptoms: Visible bleeding such as hematemesis, melaena, and hematuria, or occult bleeding for intraperitoneal or retroperitoneal hemorrhages. Treatment includes initial management by fluid infusion and blood transfusion. Endoscopy is a minimally invasive method to control the bleeding in the gastrointestinal tract, lungs, and bladder[73].

Angiography and interventional radiologic embolization of blood vessels represent additional minimally invasive bleeding control techniques. Nevertheless, these techniques present some technical issues: Accessibility of target blood vessels, subsequent ischemia of important non-target organs, and the availability of appropriate expertise[4,5]. Surgical treatment is reserved for patients with hemodynamic instability or in case of failure of other bleeding control techniques.

Rectal bleeding has been reported to occur in up to 53% of patients who received pelvic radiotherapy, but only 6% of these cases require interventions. The dose of radiotherapy is closely related to the risk of bleeding. The onset of rectal bleeding is described in the literature from 3 mo to 12 mo after radiotherapy.

Medical treatments for rectal bleeding after radiation therapy include sucralfate enemas, long term treatment with metronidazole, vitamin A, and hyperbaric oxygen therapy[74]. Endoscopic thermal therapies are frequently used in rectal bleeding and among these, argon plasma coagulation is the treatment of choice[75]. Radiologic embolization and surgery are required very rarely.

## OTHER COMPLICATIONS

Granulocyte growth factor (G-CSF), also known as colony stimulating factor 3 (CSF 3), is a glycoprotein that stimulates the bone marrow to produce granulocytes and stem cells and release them into the bloodstream. This drug is widely used to treat neutropenia, a frequent side effect of many chemotherapy drugs[76]. It is also used to increase the content of hematopoietic stem cells before a bone marrow donation. Although G-CSF is generally well tolerated, a rare side effect of this drug is splenic rupture[77]. The mechanism underlying splenic damage is likely related to massive extramedullary hematopoiesis resulting in splenomegaly, splenic congestion, and nontraumatic rupture of the viscera. The patients generally present abdominal pain, mostly reported in the left hypochondrium, tenderness, anemia on blood tests and, in the most severe cases, hemodynamic instability. If a splenic rupture is suspected, a CT scan of the abdomen is required. Embolization of the splenic vessels is a valid option for stable patients and in hospital centers with the availability of interventional radiology. On the other hand, splenic rupture represents a surgical emergency for patients with hemodynamic instability. Splenic damage is also reported in the literature in patients treated with imatinib or idarubicin[78,79].

Non-occlusive mesenteric ischemia (NOMI) is another rare but serious complication of oncological treatments. A recent paper by Nagano *et al*[80] describes three cases of NOMI in patients undergoing chemotherapy for head and neck cancers. Prompt diagnosis and emergency surgical treatment are

needed to reduce mortality rate and improve prognosis of patients with NOMI and bowel necrosis. Acute cholecystitis has been described in patients undergoing oncological therapies with antiangiogenic targeted agents, including sunitinib, sorafenib, and bevacizumab[81]. Furthermore, a case of acute cholecystitis in a patient with metastatic renal cell carcinoma during therapy with everolimus, an inhibitor of the mammalian target of rapamycin, is reported in the literature[82]. Alithiasic cholecystitis has been described in patients with hematological diseases treated with vincristine, cyclophosphamide, or cytosine-arabioside[83]. The proposed pathogenetic mechanism for the onset of acute cholecystitis during oncological therapies is related to the presence of microvascular ischemia or to an altered lipid metabolism, with consequent formation of gallstones. Symptoms and ultrasonographic findings, which include gallbladder distension, edema, hyperemia, pericholecystic fluid, and stranding, are analogous to those found in acute cholecystitis due to another etiology. In patients with acute cholecystitis, it is necessary to suspend cancer therapy temporarily or permanently. Some patients were treated exclusively with antibiotic therapy until symptoms resolved, and others underwent urgent cholecystectomy. However, for high risk, immune deficient, or severely ill patients, less invasive image guided percutaneous cholecystostomy must be considered as a bridge to surgery or as a definitive treatment. Finally, acute cholecystitis can also be a complication of locoregional treatments for liver cancer[84]. When hepatic ablation is performed near to the gallbladder, cystic duct stricture can cause acute cholecystitis[85]. Ablative techniques can also cause diaphragmatic injuries, if target lesion is in the high hepatic dome[85].

## SECOND CANCER

The development of specific cancer treatments has improved long-term survival in cancer patients. As a result, the risk of developing a second cancer after a primary oncologic treatment also increases, especially in long-survivor cancer patients.

The risk of a second tumor after radiotherapy is reported to be 0.1% to 1.0%[1] and radiation-induced cancers can be sarcomas, lymphomas, mesotheliomas, and carcinomas. The time to develop a post-radiation sarcoma is estimated to be 4-17 years[86]. Tamoxifen, a selective estrogen receptor modulator, is a chemotherapeutic agent used for the treatment of breast cancer. It is well known that tamoxifen is associated with an increased risk of endometrial cancer (two-to-three times higher than that in normal population)[87] and uterine sarcoma in postmenopausal patients. The onset of both tumors is related to the dose and time of therapy[88], and for this reason it is more frequent in long-survivor breast cancer patients for this reason.

## CONCLUSION

Oncologic therapies have greatly improved over the past few years. As a result, complications related to cancer treatments have also increased. Gastrointestinal complications that most frequently require surgery are bowel perforations and obstructions (if conservative treatment fails). However, even for rarer complications, such as splenic rupture or diaphragmatic injury, emergency surgical treatment is necessary. Hence, it is essential for surgeons to be aware of new cancer therapies and their side effects, in order to act promptly if surgery is needed. It is also essential to keep in mind that the treatment of different gastrointestinal complications should be tailored to the individual patient and based on the underlying pathophysiology of the complication.

## FOOTNOTES

**Author contributions:** Fico V and Altieri GM equally contributed to the drafting of the manuscript; Fico V, Altieri G, Tropeano G, Di Grezia M, Bianchi V, Chiarello MM, and Brisinda G designed the research; Bianchi V, Pepe G, Fico V, and Altieri G performed the research; Fico V, Altieri G, Tropeano G, and Di Grezia M analyzed the data; Fico V, Altieri G, Pepe G, and Brisinda G wrote the paper; all the authors read and approved the final manuscript.

**Conflict-of-interest statement:** The authors declare that they have no conflict of interest to disclose.

**Open-Access:** This article is an open-access article that was selected by an in-house editor and fully peer-reviewed by external reviewers. It is distributed in accordance with the Creative Commons Attribution NonCommercial (CC BY-NC 4.0) license, which permits others to distribute, remix, adapt, build upon this work non-commercially, and license their derivative works on different terms, provided the original work is properly cited and the use is non-commercial. See: <https://creativecommons.org/licenses/by-nc/4.0/>

**Country/Territory of origin:** Italy



**ORCID number:** Valeria Fico 0000-0003-1619-4164; Gaia Altieri 0000-0002-0324-2430; Marta Di Grezia 0000-0002-0191-7545; Valentina Bianchi 0000-0002-8817-3760; Maria Michela Chiarello 0000-0003-3455-0062; Gilda Pepe 0000-0001-9852-6243; Giuseppe Tropeano 0000-0001-9006-5040; Giuseppe Brisinda 0000-0001-8820-9471.

**S-Editor:** Chen YL

**L-Editor:** Wang TQ

**P-Editor:** Yu HG

## REFERENCES

- Ganeshan DM**, Salem U, Viswanathan C, Balachandran A, Garg N, Silverman P, Bhosale P. Complications of oncologic therapy in the abdomen and pelvis: a review. *Abdom Imaging* 2013; **38**: 1-21 [PMID: 22644726 DOI: 10.1007/s00261-012-9899-x]
- Birch JC**, Khatri G, Watumull LM, Arriaga YE, Leyendecker JR. Unintended Consequences of Systemic and Ablative Oncologic Therapy in the Abdomen and Pelvis. *Radiographics* 2018; **38**: 1158-1179 [PMID: 29995613 DOI: 10.1148/rg.2018170137]
- Andreyev HJ**, Davidson SE, Gillespie C, Allum WH, Swarbrick E; British Society of Gastroenterology; Association of Colo-Proctology of Great Britain and Ireland; Association of Upper Gastrointestinal Surgeons; Faculty of Clinical Oncology Section of the Royal College of Radiologists. Practice guidance on the management of acute and chronic gastrointestinal problems arising as a result of treatment for cancer. *Gut* 2012; **61**: 179-192 [PMID: 22057051 DOI: 10.1136/gutjnl-2011-300563]
- Bosscher MR**, van Leeuwen BL, Hoekstra HJ. Surgical emergencies in oncology. *Cancer Treat Rev* 2014; **40**: 1028-1036 [PMID: 24933674 DOI: 10.1016/j.ctrv.2014.05.005]
- Bosscher MR**, van Leeuwen BL, Hoekstra HJ. Mortality in emergency surgical oncology. *Ann Surg Oncol* 2015; **22**: 1577-1584 [PMID: 25344307 DOI: 10.1245/s10434-014-4180-x]
- Gazzaniga G**, Villa F, Tosi F, Pizzutilo EG, Colla S, D'Onghia S, Di Sanza G, Fornasier G, Gringeri M, Lucatelli MV, Mosini G, Pani A, Siena S, Scaglione F, Sartore-Bianchi A. Pneumatosis Intestinalis Induced by Anticancer Treatment: A Systematic Review. *Cancers (Basel)* 2022; **14** [PMID: 35406436 DOI: 10.3390/cancers14071666]
- Shinagare AB**, Howard SA, Krajewski KM, Zukotynski KA, Jagannathan JP, Ramaiya NH. Pneumatosis intestinalis and bowel perforation associated with molecular targeted therapy: an emerging problem and the role of radiologists in its management. *AJR Am J Roentgenol* 2012; **199**: 1259-1265 [PMID: 23169717 DOI: 10.2214/AJR.12.8782]
- Sliesoraitis S**, Tawfik B. Bevacizumab-induced bowel perforation. *J Am Osteopath Assoc* 2011; **111**: 437-441 [PMID: 21803880]
- Yoshimoto T**, Yoshikawa K, Higashijima J, Miyatani T, Tokunaga T, Nishi M, Takasu C, Kashiura H, Takehara Y, Shimada M. Bevacizumab-associated intestinal perforation and perioperative complications in patients receiving bevacizumab. *Ann Gastroenterol Surg* 2020; **4**: 151-155 [PMID: 32258980 DOI: 10.1002/ags3.12312]
- Ouchi R**, Okada K, Usui K, Kurata N, Suzuki S, Nagao M, Watanabe Y, Koyama K. Intestinal Perforation in a Patient with Colon Cancer during Treatment with Regorafenib: A Case Report and Review of the Literature. *Tohoku J Exp Med* 2021; **254**: 207-211 [PMID: 34321384 DOI: 10.1620/tjem.254.207]
- Rajha E**, Chaftari P, Kamal M, Maamari J, Chaftari C, Yeung SJ. Gastrointestinal adverse events associated with immune checkpoint inhibitor therapy. *Gastroenterol Rep (Oxf)* 2020; **8**: 25-30 [PMID: 32104583 DOI: 10.1093/gastro/goz065]
- Reginelli A**, Sangiovanni A, Vacca G, Belfiore MP, Pignatiello M, Viscardi G, Clemente A, Urraro F, Cappabianca S. Chemotherapy-induced bowel ischemia: diagnostic imaging overview. *Abdom Radiol (NY)* 2022; **47**: 1556-1564 [PMID: 33811514 DOI: 10.1007/s00261-021-03024-9]
- Yeoh EK**, Horowitz M. Radiation enteritis. *Surg Gynecol Obstet* 1987; **165**: 373-379 [PMID: 3310287]
- Zheng Y**, Gao W, Spratt DE, Sun Y, Xing L. Management of gastrointestinal perforation related to radiation. *Int J Clin Oncol* 2020; **25**: 1010-1015 [PMID: 32303874 DOI: 10.1007/s10147-020-01662-5]
- O'Reilly M**, Mellotte G, Ryan B, O'Connor A. Gastrointestinal side effects of cancer treatments. *Ther Adv Chronic Dis* 2020; **11**: 2040622320970354 [PMID: 33294145 DOI: 10.1177/2040622320970354]
- Andreyev J**. Gastrointestinal complications of pelvic radiotherapy: are they of any importance? *Gut* 2005; **54**: 1051-1054 [PMID: 16009675 DOI: 10.1136/gut.2004.062596]
- Gorschlüter M**, Mey U, Strehl J, Ziske C, Schepke M, Schmidt-Wolf IG, Sauerbruch T, Glasmacher A. Neutropenic enterocolitis in adults: systematic analysis of evidence quality. *Eur J Haematol* 2005; **75**: 1-13 [PMID: 15946304 DOI: 10.1111/j.1600-0609.2005.00442.x]
- Gorschlüter M**, Glasmacher A, Hahn C, Schakowski F, Ziske C, Molitor E, Marklein G, Sauerbruch T, Schmidt-Wolf IG. Clostridium difficile infection in patients with neutropenia. *Clin Infect Dis* 2001; **33**: 786-791 [PMID: 11512083 DOI: 10.1086/322616]
- Loo VG**, Bourgault AM, Poirier L, Lamothe F, Michaud S, Turgeon N, Toye B, Beaudoin A, Frost EH, Gilca R, Brassard P, Dendukuri N, Béliveau C, Oughton M, Brukner I, Dascal A. Host and pathogen factors for Clostridium difficile infection and colonization. *N Engl J Med* 2011; **365**: 1693-1703 [PMID: 22047560 DOI: 10.1056/NEJMoa1012413]
- Sussman JJ**. Surgical emergencies in the cancer patient. In: Norton JA, editor Surgery: Basic science and clinical evidence. New York: Springer-Verlag, 2007: 2117 [DOI: 10.1007/978-0-387-68113-9]
- Morgan C**, Tillett T, Braybrooke J, Ajithkumar T. Management of uncommon chemotherapy-induced emergencies. *Lancet Oncol* 2011; **12**: 806-814 [PMID: 21276754 DOI: 10.1016/S1470-2045(10)70208-4]
- Viswanathan C**, Bhosale P, Ganeshan DM, Truong MT, Silverman P, Balachandran A. Imaging of complications of oncological therapy in the gastrointestinal system. *Cancer Imaging* 2012; **12**: 163-172 [PMID: 22571819 DOI: 10.1007/s12265-012-9389-9]

- 10.1102/1470-7330.2012.0014]
- 23 **Wobbes T**, Verschueren RC, Lubbers EJ, Jansen W, Paping RH. Surgical aspects of radiation enteritis of the small bowel. *Dis Colon Rectum* 1984; **27**: 89-92 [PMID: 6697836 DOI: 10.1007/BF02553982]
  - 24 **Perrakis N**, Athanassiou E, Vamvakopoulou D, Kyriazi M, Kappos H, Vamvakopoulos NC, Nomikos I. Practical approaches to effective management of intestinal radiation injury: benefit of resectional surgery. *World J Gastroenterol* 2011; **17**: 4013-4016 [PMID: 22046090 DOI: 10.3748/wjg.v17.i35.4013]
  - 25 **Donner CS**. Pathophysiology and therapy of chronic radiation-induced injury to the colon. *Dig Dis* 1998; **16**: 253-261 [PMID: 9732185 DOI: 10.1159/000016873]
  - 26 **Anand A**, Glatt AE. Clostridium difficile infection associated with antineoplastic chemotherapy: a review. *Clin Infect Dis* 1993; **17**: 109-113 [PMID: 8353229 DOI: 10.1093/clinids/17.1.109]
  - 27 **Lomax AJ**, McNeil C. Acute management of autoimmune toxicity in cancer patients on immunotherapy: Common toxicities and the approach for the emergency physician. *Emerg Med Australas* 2017; **29**: 245-251 [PMID: 28093870 DOI: 10.1111/1742-6723.12718]
  - 28 **De Velasco G**, Je Y, Bossé D, Awad MM, Ott PA, Moreira RB, Schutz F, Bellmunt J, Sonpavde GP, Hodi FS, Choueiri TK. Comprehensive Meta-analysis of Key Immune-Related Adverse Events from CTLA-4 and PD-1/PD-L1 Inhibitors in Cancer Patients. *Cancer Immunol Res* 2017; **5**: 312-318 [PMID: 28246107 DOI: 10.1158/2326-6066.CIR-16-0237]
  - 29 **Kumar V**, Chaudhary N, Garg M, Floudas CS, Soni P, Chandra AB. Current Diagnosis and Management of Immune Related Adverse Events (irAEs) Induced by Immune Checkpoint Inhibitor Therapy. *Front Pharmacol* 2017; **8**: 49 [PMID: 28228726 DOI: 10.3389/fphar.2017.00049]
  - 30 **Hodi FS**, O'Day SJ, McDermott DF, Weber RW, Sosman JA, Haanen JB, Gonzalez R, Robert C, Schadendorf D, Hassel JC, Akerley W, van den Eertwegh AJ, Lutzky J, Lorigan P, Vaubel JM, Linette GP, Hogg D, Ottensmeier CH, Lebbé C, Peschel C, Quirt I, Clark JI, Wolchok JD, Weber JS, Tian J, Yellin MJ, Nichol GM, Hoos A, Uria WJ. Improved survival with ipilimumab in patients with metastatic melanoma. *N Engl J Med* 2010; **363**: 711-723 [PMID: 20525992 DOI: 10.1056/NEJMoa1003466]
  - 31 **Patel KR**, Lee LY, Tripathy A, McKean D. Case of small bowel perforation secondary to nivolumab and ipilimumab related tumour regression. *BMJ Case Rep* 2020; **13** [PMID: 32086324 DOI: 10.1136/bcr-2019-232304]
  - 32 **Kang G**. Benign pneumatosis intestinalis: Dilemma for primary care clinicians. *Can Fam Physician* 2017; **63**: 766-768 [PMID: 29025802]
  - 33 **Heng Y**, Schuffler MD, Haggitt RC, Rohrmann CA. Pneumatosis intestinalis: a review. *Am J Gastroenterol* 1995; **90**: 1747-1758 [PMID: 7572888]
  - 34 **Mimatsu K**, Oida T, Kawasaki A, Kano H, Kuboi Y, Aramaki O, Amano S. Pneumatosis cystoides intestinalis after fluorouracil chemotherapy for rectal cancer. *World J Gastroenterol* 2008; **14**: 3273-3275 [PMID: 18506940 DOI: 10.3748/wjg.14.3273]
  - 35 **Chaudhry NS**, Bi WL, Gupta S, Keraliya A, Shimizu N, Chiocca EA. Pneumatosis Intestinalis After Molecular-Targeted Therapy. *World Neurosurg* 2019; **125**: 312-315 [PMID: 30763745 DOI: 10.1016/j.wneu.2019.01.225]
  - 36 **Pieterse AS**, Leong AS, Rowland R. The mucosal changes and pathogenesis of pneumatosis cystoides intestinalis. *Hum Pathol* 1985; **16**: 683-688 [PMID: 4007844 DOI: 10.1016/s0046-8177(85)80152-0]
  - 37 **Vijayakanthan N**, Dhamanaskar K, Stewart L, Connolly J, Leber B, Walker I, Trus M. A review of pneumatosis intestinalis in the setting of systemic cancer treatments, including tyrosine kinase inhibitors. *Can Assoc Radiol J* 2012; **63**: 312-317 [PMID: 22402108 DOI: 10.1016/j.carj.2011.06.004]
  - 38 **Lee YS**, Han JJ, Kim SY, Maeng CH. Pneumatosis cystoides intestinalis associated with sunitinib and a literature review. *BMC Cancer* 2017; **17**: 732 [PMID: 29121860 DOI: 10.1186/s12885-017-3744-0]
  - 39 **Lee JY**, Han HS, Lim SN, Shim YK, Choi YH, Lee OJ, Lee KH, Kim ST. Pneumatosis intestinalis and portal venous gas secondary to Gefitinib therapy for lung adenocarcinoma. *BMC Cancer* 2012; **12**: 87 [PMID: 22405425 DOI: 10.1186/1471-2407-12-87]
  - 40 **Knechtle SJ**, Davidoff AM, Rice RP. Pneumatosis intestinalis. Surgical management and clinical outcome. *Ann Surg* 1990; **212**: 160-165 [PMID: 2375647 DOI: 10.1097/0000658-199008000-00008]
  - 41 **Lassandro F**, Scaglione M, Rossi G, Grassi R, Romano L. Portomesenteric vein gas: diagnostic and prognostic value. *Emerg Radiol* 2002; **9**: 96-99 [PMID: 15290586 DOI: 10.1007/s10140-002-0206-y]
  - 42 **Wiesner W**, Mortelé KJ, Glickman JN, Ji H, Ros PR. Pneumatosis intestinalis and portomesenteric venous gas in intestinal ischemia: correlation of CT findings with severity of ischemia and clinical outcome. *AJR Am J Roentgenol* 2001; **177**: 1319-1323 [PMID: 11717075 DOI: 10.2214/ajr.177.6.1771319]
  - 43 **Theis VS**, Sripadam R, Ramani V, Lal S. Chronic radiation enteritis. *Clin Oncol (R Coll Radiol)* 2010; **22**: 70-83 [PMID: 19897345 DOI: 10.1016/j.clon.2009.10.003]
  - 44 **Murro D**, Jakate S. Radiation esophagitis. *Arch Pathol Lab Med* 2015; **139**: 827-830 [PMID: 26030254 DOI: 10.5858/arpa.2014-0111-RS]
  - 45 **Tagkalidis PP**, Tjandra JJ. Chronic radiation proctitis. *ANZ J Surg* 2001; **71**: 230-237 [PMID: 11355732 DOI: 10.1046/j.1440-1622.2001.02081.x]
  - 46 **Kelvin FM**, Gramm HF, Gluck WL, Lokich JJ. Radiologic manifestations of small-bowel toxicity due to floxuridine therapy. *AJR Am J Roentgenol* 1986; **146**: 39-43 [PMID: 2933934 DOI: 10.2214/ajr.146.1.39]
  - 47 **Tso DK**, Avery LL, Lev MH, Kamalian S. Nivolumab-induced small bowel obstruction and perforation: a rare but life-threatening side effect of immunotherapy. *Emerg Radiol* 2020; **27**: 107-110 [PMID: 31823117 DOI: 10.1007/s10140-019-01731-x]
  - 48 **Katabathina VS**, Restrepo CS, Betancourt Cuellar SL, Riascos RF, Menias CO. Imaging of oncologic emergencies: what every radiologist should know. *Radiographics* 2013; **33**: 1533-1553 [PMID: 24108550 DOI: 10.1148/rg.336135508]
  - 49 **Heimann DM**, Schwartzentruber DJ. Gastrointestinal perforations associated with interleukin-2 administration. *J Immunother* 2004; **27**: 254-258 [PMID: 15076143 DOI: 10.1097/00002371-200405000-00010]
  - 50 **Cronin CG**, O'Connor M, Lohan DG, Keane M, Roche C, Bruzzi JF, Murphy JM. Imaging of the gastrointestinal complications of systemic chemotherapy. *Clin Radiol* 2009; **64**: 724-733 [PMID: 19520217 DOI: 10.1016/j.crad.2009.05.003]

- 10.1016/j.crad.2009.02.016]
- 51 **Liaw CC**, Huang JS, Wang HM, Wang CH. Spontaneous gastroduodenal perforation in patients with cancer receiving chemotherapy and steroids. Report of four cases combining 5-fluorouracil infusion and cisplatin with antiemetics dexamethasone. *Cancer* 1993; **72**: 1382-1385 [PMID: [8339228](#) DOI: [10.1002/1097-0142\(19930815\)72:4<1382::aid-cnecr2820720438>3.0.co;2-y](#)]
- 52 **Rose PG**, Piver MS. Intestinal perforation secondary to paclitaxel. *Gynecol Oncol* 1995; **57**: 270-272 [PMID: [7729749](#) DOI: [10.1006/gyno.1995.1140](#)]
- 53 **Hapani S**, Chu D, Wu S. Risk of gastrointestinal perforation in patients with cancer treated with bevacizumab: a meta-analysis. *Lancet Oncol* 2009; **10**: 559-568 [PMID: [19482548](#) DOI: [10.1016/S1470-2045\(09\)70112-3](#)]
- 54 **Garant A**, Des Groseilliers S, Martin L, Ferland É, Vuong T. Late anastomotic dehiscence during bevacizumab therapy for patients with colorectal cancer. *Clin Oncol (R Coll Radiol)* 2011; **23**: 497-498 [PMID: [21576010](#) DOI: [10.1016/j.clon.2011.03.009](#)]
- 55 **Kabbinavar FF**, Flynn PJ, Kozloff M, Ashby MA, Sing A, Barr CE, Grothey A. Gastrointestinal perforation associated with bevacizumab use in metastatic colorectal cancer: results from a large treatment observational cohort study. *Eur J Cancer* 2012; **48**: 1126-1132 [PMID: [22424880](#) DOI: [10.1016/j.ejca.2012.02.052](#)]
- 56 **Badgwell BD**, Camp ER, Feig B, Wolff RA, Eng C, Ellis LM, Cormier JN. Management of bevacizumab-associated bowel perforation: a case series and review of the literature. *Ann Oncol* 2008; **19**: 577-582 [PMID: [18024857](#) DOI: [10.1093/annonc/mdm508](#)]
- 57 **Bonifazi M**, Rossi M, Moja L, Scigliano VD, Franchi M, La Vecchia C, Zocchetti C, Negri E. Bevacizumab in clinical practice: prescribing appropriateness relative to national indications and safety. *Oncologist* 2012; **17**: 117-124 [PMID: [22210090](#) DOI: [10.1634/theoncologist.2011-0184](#)]
- 58 **Hurwitz H**, Fehrenbacher L, Novotny W, Cartwright T, Hainsworth J, Heim W, Berlin J, Baron A, Griffing S, Holmgren E, Ferrara N, Fyfe G, Rogers B, Ross R, Kabbinavar F. Bevacizumab plus irinotecan, fluorouracil, and leucovorin for metastatic colorectal cancer. *N Engl J Med* 2004; **350**: 2335-2342 [PMID: [15175435](#) DOI: [10.1056/NEJMoa032691](#)]
- 59 **Rutkowski P**, Ruka W. Emergency surgery in the era of molecular treatment of solid tumours. *Lancet Oncol* 2009; **10**: 157-163 [PMID: [19185833](#) DOI: [10.1016/S1470-2045\(09\)70017-8](#)]
- 60 **Cheon YH**, Kim MJ, Kang MG, Kim HJ, Lee SS, Kim CY, Jeon DH, Kim YE, Lee GW. Bowel perforation after erlotinib treatment in a patient with non-small cell lung cancer. *Yonsei Med J* 2011; **52**: 695-698 [PMID: [21623617](#) DOI: [10.3349/ymj.2011.52.4.695](#)]
- 61 **Walraven M**, Witteveen PO, Lolkema MP, van Hillegersberg R, Voest EE, Verheul HM. Antiangiogenic tyrosine kinase inhibition related gastrointestinal perforations: a case report and literature review. *Angiogenesis* 2011; **14**: 135-141 [PMID: [21188500](#) DOI: [10.1007/s10456-010-9197-6](#)]
- 62 **Okamoto I**, Miyazaki M, Morinaga R, Kaneda H, Ueda S, Hasegawa Y, Satoh T, Kawada A, Fukuoka M, Fukino K, Tanigawa T, Nakagawa K. Phase I clinical and pharmacokinetic study of sorafenib in combination with carboplatin and paclitaxel in patients with advanced non-small cell lung cancer. *Invest New Drugs* 2010; **28**: 844-853 [PMID: [19760364](#) DOI: [10.1007/s10637-009-9321-x](#)]
- 63 **Eng FC**, Easson AM, Szentgyorgyi E, Knox JJ. Sorafenib and surgical complications: a case report of adverse reaction to sorafenib during treatment for renal cell carcinoma. *Eur J Surg Oncol* 2009; **35**: 219-221 [PMID: [17976949](#) DOI: [10.1016/j.ejso.2007.09.009](#)]
- 64 **Frieling T**, Heise J, Wassilew SW. Multiple colon ulcerations, perforation and death during treatment of malignant melanoma with sorafenib. *Dtsch Med Wochenschr* 2009; **134**: e1-e2, 1464 [PMID: [19572243](#) DOI: [10.1055/s-0029-1225311](#)]
- 65 **Romano S**, Lassandro F, Scaglione M, Romano L, Rotondo A, Grassi R. Ischemia and infarction of the small bowel and colon: spectrum of imaging findings. *Abdom Imaging* 2006; **31**: 277-292 [PMID: [16283583](#) DOI: [10.1007/s00261-005-0376-7](#)]
- 66 **Andreyev HJ**, Vlavianos P, Blake P, Dearnaley D, Norman AR, Tait D. Gastrointestinal symptoms after pelvic radiotherapy: role for the gastroenterologist? *Int J Radiat Oncol Biol Phys* 2005; **62**: 1464-1471 [PMID: [15927411](#) DOI: [10.1016/j.ijrobp.2004.12.087](#)]
- 67 **Zhan TC**, Zhang DK, Gu J, Li M. Surgical complications after different therapeutic approaches for locally advanced rectal cancer. *World J Gastrointest Oncol* 2019; **11**: 393-403 [PMID: [31139309](#) DOI: [10.4251/wjgo.v11.i5.393](#)]
- 68 **Anker CJ**, Grossmann KF, Atkins MB, Suneja G, Tarhini AA, Kirkwood JM. Avoiding Severe Toxicity From Combined BRAF Inhibitor and Radiation Treatment: Consensus Guidelines from the Eastern Cooperative Oncology Group (ECOG). *Int J Radiat Oncol Biol Phys* 2016; **95**: 632-646 [PMID: [27131079](#) DOI: [10.1016/j.ijrobp.2016.01.038](#)]
- 69 **Inoue T**, Kinoshita H, Komai Y, Kawabata T, Kawa G, Uemura Y, Matsuda T. Two cases of gastrointestinal perforation after radiotherapy in patients receiving tyrosine kinase inhibitor for advanced renal cell carcinoma. *World J Surg Oncol* 2012; **10**: 167 [PMID: [22906119](#) DOI: [10.1186/1477-7819-10-167](#)]
- 70 **Muraoka T**, Tsukuda K, Toyooka S, Kagawa S, Naomoto Y, Takemoto M, Katsui K, Kanazawa S, Maki Y, Masuda H, Harada M, Asano H, Naito M, Miyoshi S. Ileal perforation induced by acute radiation injury under gefitinib treatment. *Int J Clin Oncol* 2011; **16**: 774-777 [PMID: [21706125](#) DOI: [10.1007/s10147-011-0249-8](#)]
- 71 **Demetri GD**, von Mehren M, Blanke CD, Van den Abbeele AD, Eisenberg B, Roberts PJ, Heinrich MC, Tuveson DA, Singer S, Janicek M, Fletcher JA, Silverman SG, Silberman SL, Capdeville R, Kiese B, Peng B, Dimitrijevic S, Druker BJ, Corless C, Fletcher CD, Joensuu H. Efficacy and safety of imatinib mesylate in advanced gastrointestinal stromal tumors. *N Engl J Med* 2002; **347**: 472-480 [PMID: [12181401](#) DOI: [10.1056/NEJMoa020461](#)]
- 72 **Liu Y**, Zhang HL, Zhang Y, Mei JZ, Lin HW, Guo YW, Li RJ, Meng XR, Liu GJ, Li M, Xiao P, Bai H. Digestive tract hemorrhage due to complications with gastrointestinal stromal tumor treated with sunitinib: A case report. *Oncol Lett* 2013; **5**: 699-701 [PMID: [23420084](#) DOI: [10.3892/ol.2012.1050](#)]
- 73 **Pereira J**, Phan T. Management of bleeding in patients with advanced cancer. *Oncologist* 2004; **9**: 561-570 [PMID: [15477642](#) DOI: [10.1634/theoncologist.9-5-561](#)]
- 74 **Cavčić J**, Turčić J, Martinac P, Jelincić Z, Zupancić B, Panijan-Pezerović R, Unusić J. Metronidazole in the treatment of

- chronic radiation proctitis: clinical trial. *Croat Med J* 2000; **41**: 314-318 [PMID: 10962052]
- 75 **Andreyev HJ**. Argon plasma coagulation in chronic radiation proctitis: Postgate et al Endoscopy 2007; 39: 751-2; author reply 752 [PMID: 17661253 DOI: 10.1055/s-2007-966772]
  - 76 **Aapro MS**, Cameron DA, Pettengell R, Bohlius J, Crawford J, Ellis M, Kearney N, Lyman GH, Tjan-Heijnen VC, Walewski J, Weber DC, Zielinski C; European Organisation for Research and Treatment of Cancer (EORTC) Granulocyte Colony-Stimulating Factor (G-CSF) Guidelines Working Party. EORTC guidelines for the use of granulocyte-colony stimulating factor to reduce the incidence of chemotherapy-induced febrile neutropenia in adult patients with lymphomas and solid tumours. *Eur J Cancer* 2006; **42**: 2433-2453 [PMID: 16750358 DOI: 10.1016/j.ejca.2006.05.002]
  - 77 **Masood N**, Shaikh AJ, Memon WA, Idress R. Splenic rupture, secondary to G-CSF use for chemotherapy induced neutropenia: a case report and review of literature. *Cases J* 2008; **1**: 418 [PMID: 19108744 DOI: 10.1186/1757-1626-1-418]
  - 78 **Elliott MA**, Mesa RA, Tefferi A. Adverse events after imatinib mesylate therapy. *N Engl J Med* 2002; **346**: 712-713 [PMID: 11870257 DOI: 10.1056/NEJM200202283460919]
  - 79 **Hernández R**, del Cañizo MC, López C, González MI, Vázquez ML, Caballero MD, San Miguel JF. Pathologic rupture of the spleen during induction with ATRA in a patient with acute promyelocytic leukemia. *Med Oncol* 2000; **17**: 337-339 [PMID: 11114715 DOI: 10.1007/BF02782201]
  - 80 **Nagano H**, Fujiwara Y, Matsuzaki H, Umakoshi M, Ohori J, Kurono Y. Three cases of non-occlusive mesenteric ischemia that developed after head and neck cancer therapy. *Auris Nasus Larynx* 2021; **48**: 1193-1198 [PMID: 32723598 DOI: 10.1016/j.anl.2020.07.003]
  - 81 **Tirumani SH**, Krajewski KM, Shinagare AB, Jagannathan JP, Ramaiya NH. Gallbladder complications associated with molecular targeted therapies: clinical and imaging features. *Clin Imaging* 2014; **38**: 50-55 [PMID: 24135148 DOI: 10.1016/j.clinimag.2013.08.012]
  - 82 **Cetin B**, Coskun U, Yildiz R, Buyukberber S, Baykara M, Benekli M. Acute cholecystitis in a patient with metastatic renal cell carcinoma treated with everolimus. *J Oncol Pharm Pract* 2011; **17**: 274-278 [PMID: 20215482 DOI: 10.1177/1078155210363317]
  - 83 **Büyükaşık Y**, Koşar A, Demiroğlu H, Altinok G, Özcebe OI, Dündar S. Acalculous acute cholecystitis in leukemia. *J Clin Gastroenterol* 1998; **27**: 146-148 [PMID: 9754777 DOI: 10.1097/00004836-199809000-00009]
  - 84 **Kogut MJ**, Bastawrous S, Padia S, Bhargava P. Hepatobiliary oncologic emergencies: imaging appearances and therapeutic options. *Curr Probl Diagn Radiol* 2013; **42**: 113-126 [PMID: 23683852 DOI: 10.1067/j.cpradiol.2012.08.003]
  - 85 **Kim KR**, Thomas S. Complications of image-guided thermal ablation of liver and kidney neoplasms. *Semin Intervent Radiol* 2014; **31**: 138-148 [PMID: 25049443 DOI: 10.1055/s-0034-1373789]
  - 86 **Sheppard DG**, Libshitz HI. Post-radiation sarcomas: a review of the clinical and imaging features in 63 cases. *Clin Radiol* 2001; **56**: 22-29 [PMID: 11162693 DOI: 10.1053/crad.2000.0599]
  - 87 Committee Opinion No. 601: Tamoxifen and uterine cancer. *Obstet Gynecol* 2014; **123**: 1394-1397 [PMID: 24848920 DOI: 10.1097/01.AOG.0000450757.18294.cf]
  - 88 **Fong K**, Causer P, Atri M, Lytwyn A, Kung R. Transvaginal US and hysterosonography in postmenopausal women with breast cancer receiving tamoxifen: correlation with hysteroscopy and pathologic study. *Radiographics* 2003; **23**: 137-50; discussion 151 [PMID: 12533649 DOI: 10.1148/rg.231025048]



Published by **Baishideng Publishing Group Inc**  
7041 Koll Center Parkway, Suite 160, Pleasanton, CA 94566, USA

**Telephone:** +1-925-3991568

**E-mail:** [bpgoffice@wjgnet.com](mailto:bpgoffice@wjgnet.com)

**Help Desk:** <https://www.f6publishing.com/helpdesk>

<https://www.wjgnet.com>

