

# World Journal of *Gastrointestinal Surgery*

*World J Gastrointest Surg* 2023 August 27; 15(8): 1559-1840



## Contents

Monthly Volume 15 Number 8 August 27, 2023

## MINIREVIEWS

- 1559 Impact of tumour rupture risk on the oncological rationale for the surgical treatment choice of gastrointestinal stromal tumours  
*Peparini N*
- 1564 Prevention and treatment of hepatic encephalopathy during the perioperative period of transjugular intrahepatic portosystemic shunt  
*Wang LJ, Yao X, Qi Q, Qin JP*
- 1574 Vascular complications of chronic pancreatitis and its management  
*Walia D, Saraya A, Gunjan D*
- 1591 Historical changes in surgical strategy and complication management for hepatic cystic echinococcosis  
*A JD, Chai JP, Jia SL, A XR*

## ORIGINAL ARTICLE

## Basic Study

- 1600 High spindle and kinetochore-associated complex subunit-3 expression predicts poor prognosis and correlates with adverse immune infiltration in hepatocellular carcinoma  
*Zheng LL, Wang YR, Liu ZR, Wang ZH, Tao CC, Xiao YG, Zhang K, Wu AK, Li HY, Wu JX, Xiao T, Rong WQ*

## Case Control Study

- 1615 Post-transplant biliary complications using liver grafts from deceased donors older than 70 years: Retrospective case-control study  
*Jimenez-Romero C, Justo-Alonso I, del Pozo-Elso P, Marcacuzco-Quinto A, Martín-Arriscado-Arroba C, Manrique-Municio A, Calvo-Pulido J, García-Sesma A, San Román R, Caso-Maestro O*
- 1629 Goldilocks principle of minimally invasive surgery for gastric subepithelial tumors  
*Chang WJ, Tsao LC, Yen HH, Yang CW, Chang HC, Kor CT, Wu SC, Lin KH*

## Retrospective Cohort Study

- 1641 Prognosis after splenectomy plus pericardial devascularization *vs* transjugular intrahepatic portosystemic shunt for esophagogastric variceal bleeding  
*Qi WL, Wen J, Wen TF, Peng W, Zhang XY, Shen JY, Li X, Li C*
- 1652 Initial suction drainage decreases severe postoperative complications after pancreatic trauma: A cohort study  
*Li KW, Wang K, Hu YP, Yang C, Deng YX, Wang XY, Liu YX, Li WQ, Ding WW*

**Retrospective Study**

- 1663** Radiation therapy prior to a pancreaticoduodenectomy for adenocarcinoma is associated with longer operative times and higher blood loss  
*Aploks K, Kim M, Stroever S, Ostapenko A, Sim YB, Sooriyakumar A, Rahimi-Ardabili A, Seshadri R, Dong XD*
- 1673** Prognostic significance of preoperative lymphocyte to monocyte ratio in patients with signet ring gastric cancer  
*Liu HL, Feng X, Tang MM, Zhou HY, Peng H, Ge J, Liu T*
- 1684** Clinical efficacy of total laparoscopic splenectomy for portal hypertension and its influence on hepatic hemodynamics and liver function  
*Qi RZ, Li ZW, Chang ZY, Chang WH, Zhao WL, Pang C, Zhang Y, Hu XL, Liang F*
- 1693** Accurate resection of hilar cholangiocarcinoma using eOrganmap 3D reconstruction and full quantization technique  
*Cui DP, Fan S, Guo YX, Zhao QW, Qiao YX, Fei JD*
- 1703** Regional differences in islet amyloid deposition in the residual pancreas with new-onset diabetes secondary to pancreatic ductal adenocarcinoma  
*Wang R, Liu Y, Liang Y, Zhou L, Chen MJ, Liu XB, Tan CL, Chen YH*
- 1712** Risk factors and their interactive effects on severe acute pancreatitis complicated with acute gastrointestinal injury  
*Chen JH, Zhang MF, Du WC, Zhang YA*
- 1719** Effects of ultrasound monitoring of gastric residual volume on feeding complications, caloric intake and prognosis of patients with severe mechanical ventilation  
*Xu XY, Xue HP, Yuan MJ, Jin YR, Huang CX*
- 1728** Enhanced recovery nursing and mental health education on postoperative recovery and mental health of laparoscopic liver resection  
*Li DX, Ye W, Yang YL, Zhang L, Qian XJ, Jiang PH*
- 1739** Changing trends in gastric and colorectal cancer among surgical patients over 85 years old: A multicenter retrospective study, 2001–2021  
*Chen K, Li M, Xu R, Zheng PP, Chen MD, Zhu L, Wang WB, Wang ZG*

**Observational Study**

- 1751** Knowledge, attitude, and practice of monitoring early gastric cancer after endoscopic submucosal dissection  
*Yang XY, Wang C, Hong YP, Zhu TT, Qian LJ, Hu YB, Teng LH, Ding J*
- 1761** Anti-reflux effects of a novel esophagogastric asymmetric anastomosis technique after laparoscopic proximal gastrectomy  
*Pang LQ, Zhang J, Shi F, Pang C, Zhang CW, Liu YL, Zhao Y, Qian Y, Li XW, Kong D, Wu SN, Zhou JF, Xie CX, Chen S*
- 1774** Prognostic scores in primary biliary cholangitis patients with advanced disease  
*Feng J, Xu JM, Fu HY, Xie N, Bao WM, Tang YM*

### SYSTEMATIC REVIEWS

- 1784** Maternal choledochal cysts in pregnancy: A systematic review of case reports and case series  
*Augustin G, Romic I, Miličić I, Mikuš M, Herman M*
- 1799** Intraoperative pancreas stump perfusion assessment during pancreaticoduodenectomy: A systematic scoping review  
*Robertson FP, Spiers HVM, Lim WB, Loveday B, Roberts K, Pandanaboyana S*
- 1808** Comparison between upfront surgery and neoadjuvant chemotherapy in patients with locally advanced gastric cancer: A systematic review  
*Fiflis S, Papakonstantinou M, Giakoustidis A, Christodoulidis G, Louri E, Papadopoulos VN, Giakoustidis D*

### CASE REPORT

- 1819** Long-term survival of patients with hepatocellular carcinoma with hepatic, pulmonary, peritoneal and rare colon metastasis: A case report  
*Gong YQ, Lu TL, Chen CW*
- 1825** Donor hepatic artery reconstruction based on human embryology: A case report  
*Zhang HZ, Lu JH, Shi ZY, Guo YR, Shao WH, Meng FX, Zhang R, Zhang AH, Xu J*
- 1831** Outpatient hybrid endoscopic submucosal dissection with SOUTEN for early gastric cancer, followed by endoscopic suturing of the mucosal defect: A case report  
*Ito R, Miwa K, Matano Y*

### LETTER TO THE EDITOR

- 1838** Is endoscopic mucosal resection-precutting superior to conventional methods for removing sessile colorectal polyps?  
*Yang QY, Zhao Q, Hu JW*

**ABOUT COVER**

Editorial Board Member of *World Journal of Gastrointestinal Surgery*, Raja Kalayarasana, MS, DNB, MCh, FRCS (Ed), Additional Professor & Head, Department of Surgical Gastroenterology, Jawaharlal Institute of Postgraduate Medical Education and Research (JIPMER), Puducherry 605006, India. kalayarasana@yaho.com

**AIMS AND SCOPE**

The primary aim of *World Journal of Gastrointestinal Surgery* (*WJGS*, *World J Gastrointest Surg*) is to provide scholars and readers from various fields of gastrointestinal surgery with a platform to publish high-quality basic and clinical research articles and communicate their research findings online.

*WJGS* mainly publishes articles reporting research results and findings obtained in the field of gastrointestinal surgery and covering a wide range of topics including biliary tract surgical procedures, biliopancreatic diversion, colectomy, esophagectomy, esophagostomy, pancreas transplantation, and pancreatectomy, etc.

**INDEXING/ABSTRACTING**

The *WJGS* is now abstracted and indexed in Science Citation Index Expanded (SCIE, also known as SciSearch®), Current Contents/Clinical Medicine, Journal Citation Reports/Science Edition, PubMed, PubMed Central, Reference Citation Analysis, China National Knowledge Infrastructure, China Science and Technology Journal Database, and Superstar Journals Database. The 2023 Edition of Journal Citation Reports® cites the 2022 impact factor (IF) for *WJGS* as 2.0; IF without journal self cites: 1.9; 5-year IF: 2.2; Journal Citation Indicator: 0.52; Ranking: 113 among 212 journals in surgery; Quartile category: Q3; Ranking: 81 among 93 journals in gastroenterology and hepatology; and Quartile category: Q4.

**RESPONSIBLE EDITORS FOR THIS ISSUE**

Production Editor: Rui-Rui Wu; Production Department Director: Xiang Li; Editorial Office Director: Jia-Ru Fan.

**NAME OF JOURNAL**

*World Journal of Gastrointestinal Surgery*

**ISSN**

ISSN 1948-9366 (online)

**LAUNCH DATE**

November 30, 2009

**FREQUENCY**

Monthly

**EDITORS-IN-CHIEF**

Peter Schemmer

**EDITORIAL BOARD MEMBERS**

<https://www.wjgnet.com/1948-9366/editorialboard.htm>

**PUBLICATION DATE**

August 27, 2023

**COPYRIGHT**

© 2023 Baishideng Publishing Group Inc

**INSTRUCTIONS TO AUTHORS**

<https://www.wjgnet.com/bpg/gerinfo/204>

**GUIDELINES FOR ETHICS DOCUMENTS**

<https://www.wjgnet.com/bpg/GerInfo/287>

**GUIDELINES FOR NON-NATIVE SPEAKERS OF ENGLISH**

<https://www.wjgnet.com/bpg/gerinfo/240>

**PUBLICATION ETHICS**

<https://www.wjgnet.com/bpg/GerInfo/288>

**PUBLICATION MISCONDUCT**

<https://www.wjgnet.com/bpg/gerinfo/208>

**ARTICLE PROCESSING CHARGE**

<https://www.wjgnet.com/bpg/gerinfo/242>

**STEPS FOR SUBMITTING MANUSCRIPTS**

<https://www.wjgnet.com/bpg/GerInfo/239>

**ONLINE SUBMISSION**

<https://www.f6publishing.com>



## Retrospective Study

# Accurate resection of hilar cholangiocarcinoma using eOrganmap 3D reconstruction and full quantization technique

Da-Peng Cui, Shuang Fan, Ying-Xue Guo, Qian-Wei Zhao, Yue-Xin Qiao, Jian-Dong Fei

**Specialty type:** Gastroenterology and hepatology

**Provenance and peer review:**

Unsolicited article; Externally peer reviewed.

**Peer-review model:** Single blind

**Peer-review report's scientific quality classification**

Grade A (Excellent): 0  
Grade B (Very good): B, B  
Grade C (Good): 0  
Grade D (Fair): 0  
Grade E (Poor): 0

**P-Reviewer:** Bhangu A, United Kingdom; Garcia K, Spain

**Received:** April 11, 2023

**Peer-review started:** April 11, 2023

**First decision:** April 26, 2023

**Revised:** May 5, 2023

**Accepted:** June 13, 2023

**Article in press:** June 13, 2023

**Published online:** August 27, 2023



**Da-Peng Cui, Shuang Fan, Ying-Xue Guo, Qian-Wei Zhao, Yue-Xin Qiao, Jian-Dong Fei,** Department of Hepatobiliary Surgery, The First Affiliated Hospital of Hebei North University, Zhangjiakou 075000, Hebei Province, China

**Corresponding author:** Jian-Dong Fei, MM, Chief Physician, Department of Hepatobiliary Surgery, The First Affiliated Hospital of Hebei North University, No. 12 Changqing Road, Qiaoxi District, Zhangjiakou 075000, Hebei Province, China. [feijiandong52@163.com](mailto:feijiandong52@163.com)

## Abstract

### BACKGROUND

For treatment of hilar cholangiocarcinoma (HCCA), the rate of radical resection is low and prognosis is poor, and preoperative evaluation is not sufficiently accurate. 3D visualization has the advantage of giving a stereoscopic view, which makes accurate resection of HCCA possible.

### AIM

To establish precise resection of HCCA based on eOrganmap 3D reconstruction and full quantification technology.

### METHODS

We retrospectively analyzed the clinical data of 73 patients who underwent HCCA surgery. All patients were assigned to two groups. The traditional group received traditional 2D imaging planning before surgery ( $n = 35$ ). The eOrganmap group underwent 3D reconstruction and full quantitative technical planning before surgery ( $n = 38$ ). The preoperative evaluation, anatomical classification of hilar hepatic vessels, indicators associated with surgery, postoperative complications, liver function, and stress response indexes were compared between the groups.

### RESULTS

Compared with the traditional group, the amount of intraoperative blood loss in the eOrganmap group was lower, the operating time and postoperative intestinal ventilation time were shorter, and R0 resection rate and lymph node dissection number were higher ( $P < 0.05$ ). The total complication rate in the eOrganmap group was 21.05% compared with 25.71% in the traditional group ( $P > 0.05$ ). The levels of total bilirubin, Albumin (ALB), aspartate transaminase, and alanine transaminase in the eOrganmap group were significantly different from those in the traditional group (intergroup effect:  $F = 450.400, 79.120, 95.730, \text{ and } 13.240$ ,



respectively; all  $P < 0.001$ ). Total bilirubin, aspartate transaminase, and alanine transaminase in both groups showed a decreasing trend with time (time effect:  $F = 30.270, 17.340$ , and  $13.380$ , respectively; all  $P < 0.001$ ). There was an interaction between patient group and time (interaction effect:  $F = 3.072, 2.965$ , and  $2.703$ , respectively;  $P = 0.0282, 0.032$ , and  $0.046$ , respectively); ALB levels in both groups tended to increase with time (time effect:  $F = 22.490$ ,  $P < 0.001$ ), and there was an interaction effect between groups and time (interaction effect:  $F = 4.607$ ,  $P = 0.004$ ). In the eOrganmap group, there was a high correlation between the actual volume of intraoperative liver specimen resection and the volume of preoperative virtual liver resection ( $t = 0.916$ ,  $P < 0.001$ ).

## CONCLUSION

The establishment of accurate laparoscopic resection of hilar cholangiocarcinoma based on preoperative eOrganmap 3D reconstruction and full quantization technology can make laparoscopic resection of hilar cholangiocarcinoma more accurate and safe.

**Key Words:** eOrganmap; 3D reconstruction; Full quantification technology; Laparoscopic surgery; Hilar cholangiocarcinoma; Precise resection

©The Author(s) 2023. Published by Baishideng Publishing Group Inc. All rights reserved.

**Core Tip:** The surgical resection rate of hilar cholangiocarcinoma (HCCA) is low, and the overall prognosis is poor. We analyzed 73 patients who underwent HCCA surgery using traditional 2D imaging planning or eOrganmap 3D reconstruction and full quantitative technical planning before surgery. By comparing the preoperative evaluation, anatomical classification of hilar hepatic vessels, indicators associated with surgery, postoperative complications, liver function, and stress response indexes of the two groups of patients, we resolved the problem of poor treatment.

**Citation:** Cui DP, Fan S, Guo YX, Zhao QW, Qiao YX, Fei JD. Accurate resection of hilar cholangiocarcinoma using eOrganmap 3D reconstruction and full quantization technique. *World J Gastrointest Surg* 2023; 15(8): 1693-1702

**URL:** <https://www.wjgnet.com/1948-9366/full/v15/i8/1693.htm>

**DOI:** <https://dx.doi.org/10.4240/wjgs.v15.i8.1693>

## INTRODUCTION

Hilar cholangiocarcinoma (HCCA) is a mucosal carcinoma of the common hepatic duct, the left and right hepatic ducts, or the confluence of the left and right hepatic ducts[1]. Although the global incidence of this disease is low, between 1 and 2 per 100000, it shows a significant increasing trend[2]. Radical surgery has made long-term survival and even cure possible for HCCA[3]. However, a variety of factors such as complex anatomical structures and high probability of variation of hilar bile ducts and blood vessels, invasion of tumor adjacent blood vessels, combined with obstructive jaundice, and impaired liver function limit the scope of resection and may lead to low resection rate and poor overall prognosis[4]. At present, there are modified liver dissection, associating liver partition and portal vein ligation for staged hepatectomy, and selective portal vein embolization, but a unified surgical selection strategy has not been formed. From the perspective of surgical anatomy, it is important to study the structure of hilum hepatis and find a reasonable surgical plan for treatment of HCCA. Accurate preoperative evaluation is an important basis for improving the surgical resection rate of HCCA and reducing the risk of surgical mortality[5]. At present, preoperative evaluation of HCCA mainly relies on traditional computed tomography (CT) and magnetic resonance imaging (MRI). Surgeons need to construct 3D models from 2D images in their minds according to clinical experience and anatomical knowledge, which is subjective and will affect the formulation of surgical plans. At the same time, this imaging evaluation method lacks an overall and 3D sense; therefore, it can lead to differences in image interpretation among surgeons[6]. In recent years, 3D visualization has been gradually applied in clinical practice with the advantages of stereoscopic and intuitive vision, and has shown high clinical value and application in preliminary studies on preoperative evaluation of HCCA[7]. However, its reliability still needs the support of more clinical data. In this study, we retrospectively analyzed the clinical data of 73 patients undergoing HCCA surgery in The First Affiliated Hospital of Hebei North University, to explore the application of laparoscopic precise resection of HCCA based on preoperative eOrganmap 3D reconstruction and full quantification.

## MATERIALS AND METHODS

### General data

We retrospectively analyzed clinical data of 73 patients undergoing HCCA surgery in The First Affiliated Hospital of Hebei North University from February 2019 to January 2022. All patients were assigned to two groups. The traditional group received 2D imaging planning before surgery ( $n = 35$ ). The EOrganmap group underwent 3D reconstruction and

full quantitative technical planning before surgery ( $n = 38$ ). This study was approved by the Medical Ethics Committee of The First Affiliated Hospital of Hebei North University.

The inclusion criteria were as follows: (1) HCCA was diagnosed by preoperative imaging such as CT and MRI, and was diagnosed by postoperative pathology[8]; (2) clear indications for surgery, generally in good condition, with no major heart and lung diseases, and could tolerate anesthesia and surgery after adequate preoperative evaluation; (3) no history of major abdominal trauma or surgery; (4) preoperative liver function assessment was Child-Pugh grade A or B; and (5) pathological data were complete and the treatment compliance was good. The exclusion criteria were: (1) Imaging data showed that the patient had disease other than HCCA; (2) abnormal liver development; (3) extensive tumor metastasis or invasion of important blood vessels; (4) liver function was not significantly improved after the treatment of protecting liver and alleviating jaundice; (5) body mass index  $> 32 \text{ kg/m}^2$ ; (6) switch to laparotomy; and (7) perioperative death or loss of follow-up. The clinicopathological characteristics of the two groups were similar (Table 1). The study protocol is shown in Figure 1.

### Surgical methods

The eOrganmap group established preoperative eOrganmap 3D reconstruction and full quantification technology. In order to ensure the accuracy of the 3D reconstruction image, the procedure was carried out by experienced radiologists. The 320-slice spiral CT was used for scanning, the current and voltage were set to 110 mAs and 120kV, respectively, and the layer thickness was 5 mm. We input the original image data into the eOrganmap 3D reconstruction system. The system automatically sketched the contour of each layer of liver parenchyma according to its anatomical position and density, and it could be modified. 3D reconstruction of the tumor, blood vessels, bile ducts, and liver was conducted by a radiologist and a surgeon. Multislice spiral CT and 3D reconstruction image analysis were performed by a radiologist and a surgeon. The analysis included the tumor location and size, whether it invaded the bile duct at grade II or higher, whether it involved peripheral blood vessels, and whether it had lymph node or distant metastasis. The results were compared with the actual intraoperative situation and postoperative pathological results.

Surgical plan planning: Complete the surgical plan design on the computer. The surgical plan should meet the multi-dimensional R0 margin; the residual liver volume should be at least 30% greater than the standard. Ensure that the pre-preserved liver's blood flow and bile drainage are unobstructed. According to the preoperative evaluation, the surgical plan was formulated, and the patients were treated with hemihepatic resection, expanded hemicombined caudate lobectomy, extrahepatic bile duct resection, endoskeletonization of the hepatoduodenal ligament, and bile duct and jejunum Roux-en-Y anastomosis. A five-hole small incision was made to perform laparoscopic surgery, and abdominal exploration was performed for abdominal and distant lymph node metastasis. The hepatoduodenal ligament was dissected by skeletonization, and the liver on the side to be resected was fully dissociated. The pre-resection area was separated along the hepatic ischemia line and the whole specimen was resected after an appropriate blood flow blocking method was selected. Rapid cryoscopy was performed to determine whether the upper and lower resection margins reached the R0 resection level. After the trans-sectional bile duct was reconstructed, biliary anastomosis was performed with Roux-en-Y. All patients were followed up for 10 mo after surgery.

### Observational indexes

For preoperative evaluation, HCCA tumor progression[9] was evaluated in two aspects: Longitudinal progression (tumor invasion along the bile duct) and vertical progression (tumor invasion through the bile duct into the adjacent portal vein and hepatic artery in the vertical direction). Bismuth-Corlette classification was used for longitudinal progression. For patients in the eOrganmap group, only the tumor and biliary system were displayed after removing other tissues in the 3D model. Longitudinal invasion information was obtained by rotating the field of vision, and the tumor and portal vein or hepatic artery were separately displayed in the 3D model to observe the relationship between the tumor and vasculature from multiple angles. For patients in the traditional group, surgeons judged the degree of longitudinal progression from the CT images, such as middle bile duct stenosis and intraluminal space occupation. The Baek classification[10] was used as the standard to evaluate the degree of hepatic artery and portal vein invasion. Grade 0 tumor invasion indicated no vascular invasion; Grade I indicated that the blood vessels were stained or moved (the tumor was adjacent to the blood vessels); Grade II indicated that the tumor had fused to the blood vessel and completely enclosed it [11]. The Couniaud method was used for bile duct anatomical classification[12], the Cheng method for portal vein classification[13], and the Michels method for hepatic artery variation classification[14].

Indicators associated with surgery: Surgical margin pathology, number of lymph nodes dissected, operating time, amount of intraoperative blood loss, postoperative intestinal ventilation time, and postoperative hospital stay. Postoperative complications included bile leakage, abdominal fluid accumulation, lung infection, postoperative liver insufficiency, and stress ulcers. Evaluation of postoperative bile leakage was based on the diagnostic criteria of the International Liver Surgery Research Group[15]. Total bilirubin (TBIL) level in the abdominal drainage tube was three times higher than in the serum on postoperative day 3. Liver function was detected preoperatively (T1), and on postoperative day 1 (T2), postoperative day 3 (T3), and postoperative day 7 (T4), and the indexes included TBIL, alanine transaminase (ALT), aspartate aminotransferase (AST), and albumin (ALB).

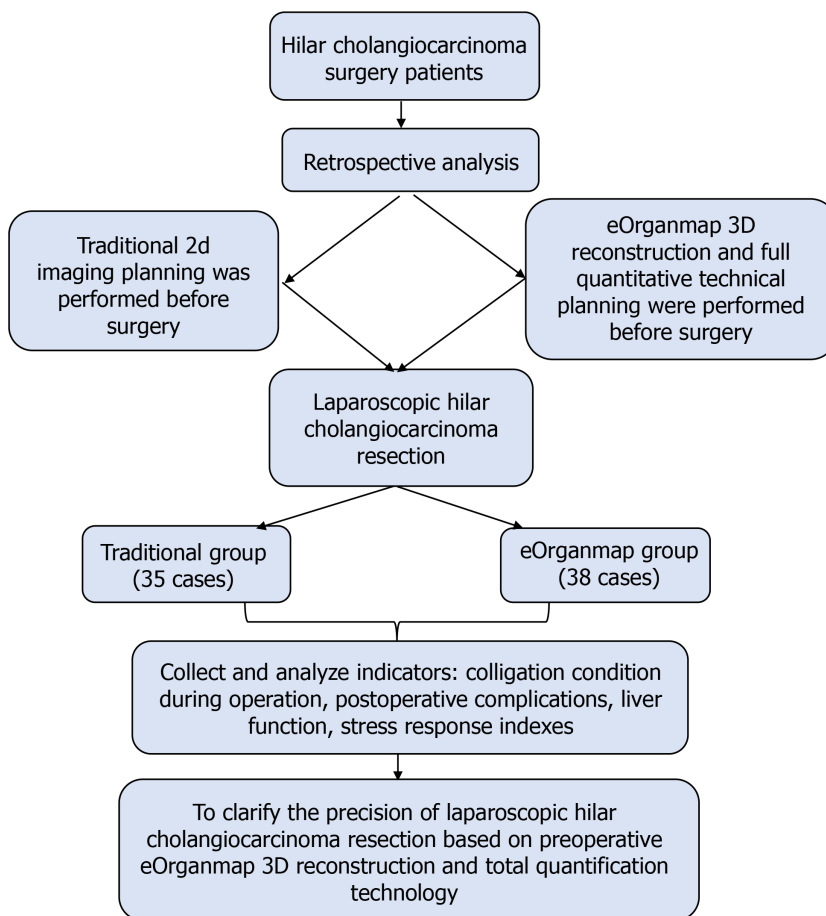
Stress response indexes were: Interleukin (IL)-6, cortisol (Cor), and norepinephrine (NE). For detection, 5 mL venous blood was collected, centrifuged for 10 min at 3000 rpm (Heidolge Medical Equipment, Building 3, 229 Amber Road, Shanghai International Medical Park, Pudong New Area, Shanghai), and the serum was separated and stored at  $-20^{\circ}\text{C}$  for testing. ELISA was used to detect the above indicators.

For patients in the eOrganmap group, the software module was used to automatically calculate the volume of each segment of the liver, and the volume of the excised liver was measured by the drainage method after surgery, and the volume of the virtual excised liver measured by 3D reconstruction before surgery was compared with the actual volume



**Table 1** Clinicopathological characteristics

Group	Sex (male/female)	Age (yr, mean $\pm$ SD)	Child–Pugh grade A/ B	Preoperative biliary drainage (yes/no)	Bismuth classification			
					II	IIIa	IIIb	IV
Traditional group ( <i>n</i> = 35)	15/20	58.55 $\pm$ 5.13	29/6	27/8	3	14	12	6
eOrganmap group ( <i>n</i> = 38)	14/24	57.86 $\pm$ 5.67	34/4	30/8	1	16	13	8
$\chi^2/t$	0.275	0.544	0.675	0.035	1.338			
<i>P</i> value	0.600	0.588	0.411	0.852	0.720			



DOI: 10.4240/wjgs.v15.i8.1693 Copyright ©The Author(s) 2023.

**Figure 1** Study protocol.

of the excised liver specimen during surgery. For the drainage method[16], the excised liver and tumor specimens were wrapped in cling film and placed in a container filled with water. The overflow water was collected and the volume was measured in a measuring cup, which corresponded to the specimen volume.

### Statistical analysis

SPSS 22.0 was used for statistical analysis. The measurement data in line with normal distribution were expressed as mean  $\pm$  SD. The *t* test was used for comparison of measurement data in the two groups, and repeated-measurement analysis of variance was used for comparison of data at different time points between groups. Numerical data were represented by *n* (%) and  $\chi^2$  test. The  $\chi^2$  value was corrected when theoretical frequency was  $\geq 1$  and  $< 5$ , and calculated by exact probability method when theoretical frequency  $< 1$ . Pearson correlation test was used for correlation analysis. *P*  $< 0.05$  was considered statistically significant.

## RESULTS

### Preoperative evaluation

The accuracy of longitudinal progression was 89.47% (34/38) in the eOrganmap group compared with 82.86% (29/35) in the conventional group ( $\chi^2 = 0.231$ ,  $P = 0.631$ ). The accuracy of vertical progression in the eOrganmap group was compared with that in the traditional group: Portal vein invasion: 94.74% (36/38) *vs* 91.43% (32/35) ( $\chi^2 = 0.009$ ,  $P = 0.924$ ); hepatic artery invasion: 89.47% (34/38) *vs* 85.71% (30/35) ( $\chi^2 = 0.017$ ,  $P = 0.895$ ).

### Anatomical classification of hepatic portal

In the eOrganmap group, seven cases of hepatic artery anatomical variation, three of portal vein variation, and four of bile duct anatomical variation were found preoperatively. All the results of preoperative evaluation were identical with the results of intraoperative exploration, and the classification accuracy was 100%. In the traditional group, four cases of hepatic artery anatomical variation, two of portal vein variation, and three of bile duct anatomical variation were found preoperatively. The typing accuracy was 64.29% in three cases of hepatic artery variation, one of portal vein variation and one of bile duct variation. Comparison of typing accuracy between the eOrganmap and traditional groups was  $\chi^2 = 8.027$  and  $P = 0.005$ .

### Indicators associated with surgery

Compared with the traditional group, the amount of intraoperative blood loss in the eOrganmap group was lower, the operating time and postoperative intestinal ventilation time were shorter, and R0 resection rate and lymph node dissection number were higher ( $P < 0.05$ ) (Table 2).

### Postoperative complications

The total complication rate in the eOrganmap group was 21.05%, compared with 25.71% in the traditional group ( $P > 0.05$ ) (Table 3). All patients with postoperative complications were cured after conservative treatment.

### Liver function

The levels of TBIL, ALB, AST, and ALT in the eOrganmap group were significantly different from those in the traditional group (intergroup effect:  $F = 450.40$ , 79.120, 95.730, and 13.240, respectively; all  $P < 0.001$ ). TBIL, AST, and ALT in both groups showed a decreasing trend with time (time effect:  $F = 30.270$ , 17.340, and 13.380, respectively; all  $P < 0.001$ ), and there was an interaction effect between grouping and time ( $F = 3.072$ , 2.965, and 2.703, respectively;  $P = 0.0282$ , 0.032, and 0.046, respectively); ALB levels in both groups tended to increase with time (time effect:  $F = 22.490$ ,  $P < 0.001$ ), and there was an interaction effect between groups and time (interaction effect:  $F = 4.607$ ,  $P = 0.004$ ) (Table 4 and Table 5).

### Stress response indexes

The levels of IL-6, Cor and NE in the eOrganmap group and traditional group were compared before and after surgery ( $P > 0.05$ ) (Table 6 and Figure 2).

### Liver volume

In the eOrganmap group, the preoperative virtual resection volume was  $523.45 \pm 112.03$  mL, and the actual intraoperative resection volume was  $558.43 \pm 125.41$  mL. There was a high correlation between the actual intraoperative resection volume and the preoperative virtual resection volume ( $t = 0.916$ ,  $P < 0.001$ ).

## DISCUSSION

The prevalence of HCCA is increasing annually, and surgical resection is the main treatment. Accurate preoperative evaluation of HCCA and optimal surgical planning are important for good prognosis. In recent years, digital medical technology and the concept of 3D visualization precision diagnosis and treatment have been widely promoted and practiced. The 3D visualization and 3D printed models are more intuitive and accurate than traditional 2D CT and MRI images, making it possible to achieve accurate diagnosis, preoperative evaluation, and accurate surgery.

In this study, laparoscopic precise resection of HCCA was established based on preoperative eOrganmap 3D reconstruction and full quantification technology, which achieved good results. In the evaluation of degree of tumor invasion, we found that there was no difference in the accuracy of preoperative evaluation results and postoperative actual results between the two groups. Bismuth–Corlette classification is the most commonly used clinical classification method, which divides HCCA into types I–IV according to the extent of bile duct invasion by tumor. At present, the formulation of HCCA surgical plan is mainly based on this classification. However, there is no unified standard for surgical procedures established according to this classification method, and Bismuth–Corlette classification does not take into account tumor invasion of the portal vein and hepatic artery, which also affects the choice of surgical procedure. The eOrganmap 3D reconstruction and full quantification can make up for the deficiency of traditional preoperative evaluation methods.

Our results showed that the classification accuracy of patients based on preoperative eOrganmap 3D reconstruction and full quantification technology was significantly increased. The images based on eOrganmap 3D reconstruction and full quantification technology clearly showed the anatomical variation of the hilar liver. As a 3D visualization technology,

**Table 2 Colligation condition during operation**

Group	Traditional group (n = 35)	eOrganmap group (n = 38)	<i>t</i> / $\chi^2$	P value
Surgical procedure, n (%)			1.276	0.865
Left/right half liver + caudate lobectomy	23 (65.71)	27 (71.05)		
Extended hemihepatectomy + caudate lobectomy	6 (17.14)	7 (18.42)		
Liver trilobites + caudate lobectomy	2 (5.71)	2 (5.26)		
Mesohepatectomy + caudate lobectomy	1 (2.86)	1 (2.63)		
Other	3 (8.57)	1 (2.63)		
Amount of intraoperative blood loss (mean $\pm$ SD, mL)	772.52 $\pm$ 112.13	553.62 $\pm$ 98.56	8.875	< 0.001
Operating time (mean $\pm$ SD, min)	645.29 $\pm$ 121.14	523.19 $\pm$ 103.15	4.648	< 0.001
Surgical margin pathology, n (%)			4.425	0.035
R0	29 (82.86)	37 (97.37)		
R1	6 (17.14)	1 (2.63)		
No. of lymph nodes dissected (mean $\pm$ SD)	9.12 $\pm$ 2.34	10.75 $\pm$ 2.58	2.819	0.006
Postoperative intestinal ventilation time (mean $\pm$ SD, d)	3.15 $\pm$ 1.02	2.65 $\pm$ 0.71	2.447	0.017
Postoperative hospital stay (mean $\pm$ SD, d)	22.64 $\pm$ 5.26	21.15 $\pm$ 4.87	1.257	0.213

**Table 3 Postoperative complications, n (%)**

Complication	Traditional group (n = 35)	eOrganmap group (n = 38)	$\chi^2/Z$	P value
Bile leakage	2 (5.71)	2 (5.26)	2.149	0.708
Abdominal fluid accumulation	3 (8.57)	3 (7.89)		
Lung infection	3 (8.57)	2 (5.26)		
Postoperative liver insufficiency	1 (2.86)	0 (0.00)		
Stress ulcers	0 (0.00)	1 (2.63)		
Total complication rate	9 (25.71)	8 (21.05)	0.222	0.638

**Table 4 Total bilirubin and albumin levels (mean SD)**

Time	TBIL ( $\mu$ mol/L)				ALB (g/L)			
	Traditional group (n = 35)	eOrganmap group (n = 38)	<i>t</i>	P value	Traditional group (n = 35)	eOrganmap group (n = 38)	<i>t</i>	P value
T1	211.26 $\pm$ 15.31	209.58 $\pm$ 16.75	0.446	0.657	27.69 $\pm$ 4.13	23.16 $\pm$ 3.83	4.863	< 0.001
T2	165.28 $\pm$ 14.37	151.22 $\pm$ 12.58	4.456	< 0.001	29.39 $\pm$ 4.02	27.24 $\pm$ 4.12	2.253	0.027
T3	148.56 $\pm$ 17.28	140.37 $\pm$ 15.47	2.137	0.036	32.25 $\pm$ 3.23	30.22 $\pm$ 3.54	2.552	0.013
T4	128.62 $\pm$ 14.39	113.28 $\pm$ 15.27	4.408	< 0.001	34.66 $\pm$ 3.15	34.85 $\pm$ 4.41	0.210	0.834

TBIL: Total bilirubin; ALB: Albumin.

eOrganmap 3D reconstruction and full quantification technology uses high-quality 2D-enhanced CT images or MR images to carry out 3D reconstruction, so as to display the lesions' location, size, scope, and their anatomical relationship with the hepatic artery and portal vein in a 3D, comprehensive, and multiangular manner. According to this information, the tumor can be judged whether it has vascular invasion[17]. At the same time, it can evaluate the anatomical variation and spatial conformation of the hepatic artery, portal vein and bile duct, accurately measure the volume of each hepatic segment, and calculate the residual liver volume[18]. Accurate assessment of variation of the hepatic artery, portal vein and hepatic vein is important to surgical planning and avoidance of accidental injury during surgery[19]. In terms of vascular reconstruction, as long as CT image layer is thin enough, 3D software can automatically generate a vascular boundary without manual drawing, which reduces the secondary error caused by manual drawing. The 3D vascular

**Table 5 Aspartate transaminase and alanine transaminase levels (mean SD)**

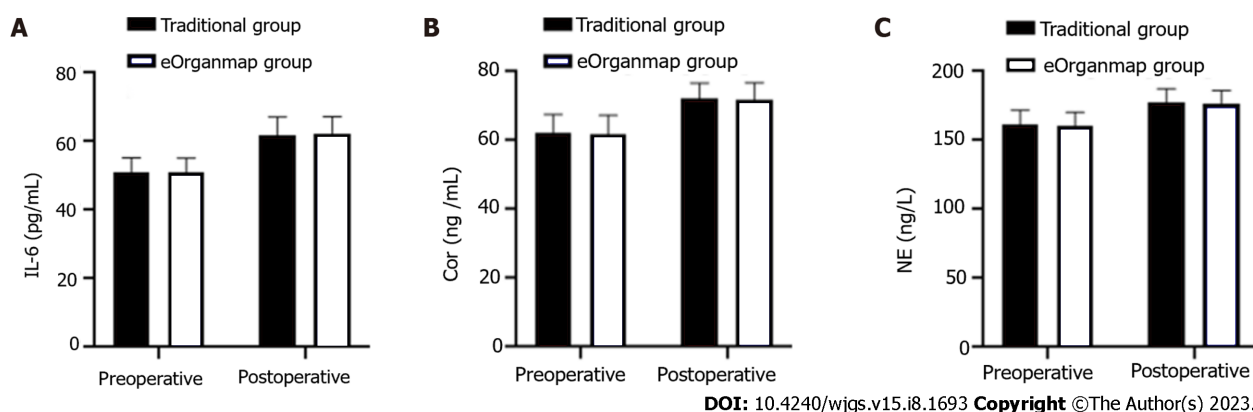
Time	AST (U/L)		<i>t</i>	<i>P</i> value	ALT (U/L)		<i>t</i>	<i>P</i> value
	Traditional group (n = 35)	eOrganmap group (n = 38)			Traditional group (n = 35)	eOrganmap group (n = 38)		
T1	112.17 ± 28.42	108.62 ± 30.23	0.516	0.608	122.15 ± 32.48	123.49 ± 31.58	0.179	0.859
T2	81.82 ± 10.67	75.38 ± 15.43	2.057	0.043	112.41 ± 24.15	101.21 ± 23.24	2.019	0.047
T3	75.25 ± 10.58	70.26 ± 6.38	2.462	0.016	108.36 ± 25.58	95.26 ± 26.31	2.154	0.035
T4	74.85 ± 9.20	56.12 ± 8.39	9.098	< 0.001	107.25 ± 28.56	82.28 ± 30.25	3.619	< 0.001

AST: Aspartate transaminase; ALT: Alanine transaminase.

**Table 6 Stress response indicators (mean SD)**

Indicators	Traditional group (n = 35)	eOrganmap group (n = 38)	$\chi^2/Z$	<i>P</i> value
IL-6 (pg/mL)				
Pre-operation	50.89 ± 4.42	51.02 ± 4.16	0.130	0.897
Post-operation	61.66 ± 5.48	62.07 ± 5.14	1.243	0.742
Cor (ng/mL)				
Pre-operation	62.35 ± 5.16	61.75 ± 5.58	0.476	0.636
Post-operation	72.22 ± 4.48	71.74 ± 5.03	0.429	0.669
NE (ng/L)				
Pre-operation	161.53 ± 10.38	160.85 ± 9.47	0.293	0.771
Post-operation	177.25 ± 10.12	176.95 ± 9.13	0.133	0.894

Cor: Cortisol; IL-6: Interleukin-6; NE: Norepinephrine.

**Figure 2 Interleukin-6, cortisol and norepinephrine levels.** There were 35 cases in the traditional group and 38 in the eOrganmap group. A: Interleukin-6 Levels; B: Cortisol levels; C: Norepinephrine levels. Notes: IL-6: Interleukin-6; Cor: Cortisol; NE: Norepinephrine.

images can intuitively discover the variation in blood vessels and the relationship between tumors and blood vessels, which could improve the accuracy of resectable evaluation[20]. eOrganmap 3D reconstruction and full quantification technology is a new development of CT reconstruction. This technique can register and fuse images of different scanning periods, displaying liver, hepatic artery, portal vein, hepatic vein, and bile duct singly or in combination in the same 3D model, which can be observed by several physicians simultaneously[21,22]. Through the adjustment of transparency, the internal structure can be displayed, so that the spatial deformation of the important tubular structure in the liver can be observed, and an individualized surgical plan formulated. Couinaud's anatomical segmentation can be carried out to achieve virtual surgery. Surgical information can be quantified through the built-in measurement tools of the software. The eOrganmap 3D reconstruction and full quantification technology has transformed the previous qualitative evaluation

into quantitative evaluation, so as to accurately carry out individualized preoperative evaluation and surgical planning, which is consistent with the development of precision surgery.

Preoperative reasonable planning of surgery, prior understanding of the anatomical variation of the perihilar bile duct and blood vessels, and possible intraoperative conditions could reduce the possibility of accidental intraoperative injury of the bile duct and blood vessels, thus avoiding the blindness of intraoperative exploration, and improving the safety of surgery and reducing liver dysfunction[23]. eOrganmap 3D reconstruction and full quantification technology can accurately measure liver volume, which prevents postoperative liver failure and ensures the safety of HCCA surgery. The results of this study showed that laparoscopic HCCA resection based on preoperative eOrganmap 3D reconstruction and full quantification technology reduced intraoperative blood loss, shortened operating time, and promoted postoperative intestinal ventilation, without increasing the incidence of complications and alleviating liver function damage. The results of this study also showed that the R0 resection rate and lymph node dissection number in the eOrganmap group were higher, indicating that 3D reconstruction and full quantification had some advantages in surgical margin treatment and lymph node dissection. Surgical margin and lymph node metastasis are both important factors affecting the prognosis of patients with hilar tumor[24]. Improving R0 resection rate and lymph node dissection are important measures to improve therapeutic efficacy and prognosis. Therefore, we hypothesized that laparoscopic HCCA resection based on preoperative eOrganmap 3D reconstruction and full quantification would promote efficacy and improve prognosis. There was a high correlation between the actual volume of intraoperative liver resection and the volume of preoperative virtual liver resection in the eOrganmap group. Accurate calculation of residual liver volume was important to ensure the safety of hepatectomy. Conventional CT or MRI integral measurement method was difficult to complete the measurement of segmental liver volume; however, preoperative eOrganmap 3D reconstruction and full quantification technology could accurately measure the volume of each segment of liver through a portal vein drainage algorithm, and it was consistent with the actual postoperative situation. In conclusion, accurate measurement of liver volume provides a reliable guarantee for the realization of accurate liver resection.

This study was the first to systematically carry out a new liver segmentation method based on three-dimensional reconstruction visualization and comprehensive quantification technology and the establishment of new indicators for liver reserve function evaluation and used a variety of mathematical models to analyze its feasibility and accuracy, providing a potential evaluation method for preoperative planning and postoperative risk prediction of hilar cholangiocarcinoma. On this basis, laparoscopic precise resection of HCCA was convenient for the application and promotion of this technology. However, this study also had some shortcomings. This study was retrospective and lacked prospective randomized controlled trials, so the reliability of the results could not be guaranteed. In addition, the number of cases included in this study was small, and the results may be biased, which needs to be confirmed by studies with a larger sample size.

## CONCLUSION

Laparoscopic precise resection of HCCA based on preoperative eOrganmap 3D reconstruction and full quantification technology made preoperative assessment, hilar vasculature anatomical classification, and resected liver volume assessment more accurate. It improved the rate of R0 resection and the number of lymph nodes dissected. It also had a low impact on liver function and stress response. Therefore, the method is safe and worthy of wider application.

## ARTICLE HIGHLIGHTS

### Research background

The incidence of hilar cholangiocarcinoma (HCCA) has shown a significant upward trend, and radical surgery is an effective treatment. However, the complexity of the anatomical structure of the hilar bile duct and blood vessels, the invasion of the adjacent blood vessels of the tumor, jaundice, and the scope of hepatectomy have resulted in a low resection rate for HCCA and poor prognosis.

### Research motivation

The preoperative evaluation of HCCA mainly relies on traditional computed tomography and magnetic resonance imaging. Surgeons need to construct 2D images into 3D models in their minds based on clinical experience and anatomical knowledge. Such a method is subjective and will affect the formulation of surgical plans.

### Research objectives

This study aimed to establish a laparoscopic precise resection of HCCA based on preoperative eOrganmap 3D reconstruction and full quantification technology, to provide a new method for precise treatment of HCCA.

### Research methods

We retrospectively analyzed the clinical data of 73 patients with HCCA who underwent surgery. Patients were divided into the traditional group (2D imaging planning before surgery) and eOrganmap group (3D reconstruction and full quantification technology planning before surgery). To compare the relevant indicators of the two groups of patients and



to further explore the difference between eOrganmap 3D reconstruction and full quantification technology and traditional 2D image planning treatment.

### Research results

eOrganmap 3D reconstruction and full quantification technology planning have obvious advantages in classification accuracy, blood loss, operating time, postoperative intestinal ventilation time, R0 resection rate, number of lymph nodes dissected, total complication rate, and liver function. In the eOrganmap group, there was a high correlation between the volume of the actual resected liver specimen and the volume of the virtual resected liver specimen before the operation.

### Research conclusions

Establishing laparoscopic precise resection of hilar cholangiocarcinoma based on preoperative eOrganmap 3D reconstruction and full quantification technology can make laparoscopic HCCA resection more accurate and safe.

### Research perspectives

The results of this study were verified by a retrospective study with a large sample size, which enhanced the reliability of the results and contributed to the clinical promotion of eOrganmap 3D reconstruction and full quantification technology.

## FOOTNOTES

**Author contributions:** Cui DP conceived this study, collected clinical data, interpreted the results, wrote, and revised the manuscript; Fan S, Guo YX participated in collecting data and data statistics; Zhao QW, Qiao YX, Fei JD participated in the study design and revised the manuscript; and All authors read and approved the final manuscript.

**Supported by** Key R&D Program of Hebei Province, No. 223777101D.

**Institutional review board statement:** This study was approved by the Medical Ethics Committee of The First Affiliated Hospital of Hebei North University.

**Informed consent statement:** All patients have signed the previous consent form before the surgery. According to institutional policy, this retrospective study does not require informed consent.

**Conflict-of-interest statement:** The authors declare no conflicts of interest for this article.

**Data sharing statement:** The data set used for this study can be obtained from the corresponding author.

**Open-Access:** This article is an open-access article that was selected by an in-house editor and fully peer-reviewed by external reviewers. It is distributed in accordance with the Creative Commons Attribution NonCommercial (CC BY-NC 4.0) license, which permits others to distribute, remix, adapt, build upon this work non-commercially, and license their derivative works on different terms, provided the original work is properly cited and the use is non-commercial. See: <https://creativecommons.org/licenses/by-nc/4.0/>

**Country/Territory of origin:** China

**ORCID number:** Da-Peng Cui 0009-0001-7942-8207; Shuang Fan 0000-0001-7483-4081; Ying-Xue Guo 0009-0007-4953-2752; Qian-Wei Zhao 0009-0008-7707-6392; Yue-Xin Qiao 0009-0003-3225-382X; Jian-Dong Fei 0009-0008-4024-4831.

**S-Editor:** Wang JL

**L-Editor:** A

**P-Editor:** Ji MX

## REFERENCES

- 1 **Abou-Alfa GK,** Macarulla T, Javle MM, Kelley RK, Lubner SJ, Adeva J, Cleary JM, Catenacci DV, Borad MJ, Bridgewater J, Harris WP, Murphy AG, Oh DY, Whisenant J, Lowery MA, Goyal L, Shroff RT, El-Khoueiry AB, Fan B, Wu B, Chamberlain CX, Jiang L, Gliser C, Pandya SS, Valle JW, Zhu AX. Ivosidenib in IDH1-mutant, chemotherapy-refractory cholangiocarcinoma (ClarIDHy): a multicentre, randomised, double-blind, placebo-controlled, phase 3 study. *Lancet Oncol* 2020; **21**: 796-807 [PMID: 32416072 DOI: 10.1016/S1470-2045(20)30157-1]
- 2 **Li H,** Zhang ZY, Zhou ZQ, Guan J, Tong DN, Zhou GW. Combined gemcitabine and S-1 chemotherapy for treating unresectable hilar cholangiocarcinoma: a randomized open-label clinical trial. *Oncotarget* 2016; **7**: 26888-26897 [PMID: 27058753 DOI: 10.18632/oncotarget.8590]
- 3 **Ma D,** Wang W, Wang J, Zhang T, Jiang Z, Du G, Yang J, Zhang X, Qin G, Jin B. Laparoscopic versus open surgery for hilar cholangiocarcinoma: a retrospective cohort study on short-term and long-term outcomes. *Surg Endosc* 2022; **36**: 3721-3731 [PMID: 34398281 DOI: 10.1007/s00464-021-08686-6]
- 4 **Matsuo K,** Rocha FG, Ito K, D'Angelica MI, Allen PJ, Fong Y, Dematteo RP, Gonen M, Endo I, Jarnagin WR. The Blumgart preoperative staging system for hilar cholangiocarcinoma: analysis of resectability and outcomes in 380 patients. *J Am Coll Surg* 2012; **215**: 343-355

- [PMID: 22749003 DOI: 10.1016/j.jamcollsurg.2012.05.025]
- 5 Peng Y, Zhao Z, Zhao Y, Wang Z, Li J, Zhang H, Liu X, Zhou X. Three-dimensional reconstruction of magnetic resonance images of carp brain for brain control technology. *J Neurosci Methods* 2022; **366**: 109428 [PMID: 34848249 DOI: 10.1016/j.jneumeth.2021.109428]
  - 6 Pang L, Bo X, Wang J, Wang C, Wang Y, Liu G, Yu H, Chen L, Shi H, Liu H. Role of dual-time point (18)F-FDG PET/CT imaging in the primary diagnosis and staging of hilar cholangiocarcinoma. *Abdom Radiol (NY)* 2021; **46**: 4138-4147 [PMID: 33825930 DOI: 10.1007/s00261-021-03071-2]
  - 7 Kelkar A, Kelkar J, Chougule Y, Bolisetty M, Singhvi P. Cognitive workload, complications and visual outcomes of phacoemulsification cataract surgery: Three-dimensional versus conventional microscope. *Eur J Ophthalmol* 2022; **32**: 2935-2941 [PMID: 34825825 DOI: 10.1177/11206721211062034]
  - 8 You Y, Heo JS, Shin SH, Shin SW, Park HS, Park KB, Cho SK, Hyun D, Han IW. Optimal timing of portal vein embolization (PVE) after preoperative biliary drainage for hilar cholangiocarcinoma. *HPB (Oxford)* 2022; **24**: 635-644 [PMID: 34629262 DOI: 10.1016/j.hpb.2021.09.011]
  - 9 Gomez DR, Blumenschein GR Jr, Lee JJ, Hernandez M, Ye R, Camidge DR, Doebele RC, Skoulidis F, Gaspar LE, Gibbons DL, Karam JA, Kavanagh BD, Tang C, Komaki R, Louie AV, Palma DA, Tsao AS, Sepesi B, William WN, Zhang J, Shi Q, Wang XS, Swisher SG, Heymach JV. Local consolidative therapy versus maintenance therapy or observation for patients with oligometastatic non-small-cell lung cancer without progression after first-line systemic therapy: a multicentre, randomised, controlled, phase 2 study. *Lancet Oncol* 2016; **17**: 1672-1682 [PMID: 27789196 DOI: 10.1016/S1470-2045(16)30532-0]
  - 10 Baek SY, Sheafor DH, Keogan MT, DeLong DM, Nelson RC. Two-dimensional multiplanar and three-dimensional volume-rendered vascular CT in pancreatic carcinoma: interobserver agreement and comparison with standard helical techniques. *AJR Am J Roentgenol* 2001; **176**: 1467-1473 [PMID: 11373215 DOI: 10.2214/ajr.176.6.1761467]
  - 11 He M, Li Q, Zou R, Shen J, Fang W, Tan G, Zhou Y, Wu X, Xu L, Wei W, Le Y, Zhou Z, Zhao M, Guo Y, Guo R, Chen M, Shi M. Sorafenib Plus Hepatic Arterial Infusion of Oxaliplatin, Fluorouracil, and Leucovorin vs Sorafenib Alone for Hepatocellular Carcinoma With Portal Vein Invasion: A Randomized Clinical Trial. *JAMA Oncol* 2019; **5**: 953-960 [PMID: 31070690 DOI: 10.1001/jamaoncol.2019.0250]
  - 12 Ludwig K, Santoro L, Ingravalle G, Cazzato G, Giacometti C, Dall'Igna P. Congenital anomalies of the gastrointestinal tract: the liver, extrahepatic biliary tree and pancreas. *Pathologica* 2022; **114**: 55-63 [PMID: 35212316 DOI: 10.32074/1591-951X-709]
  - 13 Cheng YF, Huang TL, Lee TY, Chen TY, Chen CL. Variation of the intrahepatic portal vein; angiographic demonstration and application in living-related hepatic transplantation. *Transplant Proc* 1996; **28**: 1667-1668 [PMID: 8658830]
  - 14 Fang CH, Huang YP, Chen ML, Lu CM, Li XF, Qiu WF. Digital medical technology based on 64-slice computed tomography in hepatic surgery. *Chin Med J (Engl)* 2010; **123**: 1149-1153 [PMID: 20529554]
  - 15 Koch M, Garden OJ, Padbury R, Rahbari NN, Adam R, Capussotti L, Fan ST, Yokoyama Y, Crawford M, Makuuchi M, Christophi C, Banting S, Brooke-Smith M, Usatoff V, Nagino M, Maddern G, Hugh TJ, Vauthey JN, Greig P, Rees M, Nimura Y, Figueras J, DeMatteo RP, Büchler MW, Weitz J. Bile leakage after hepatobiliary and pancreatic surgery: a definition and grading of severity by the International Study Group of Liver Surgery. *Surgery* 2011; **149**: 680-688 [PMID: 21316725 DOI: 10.1016/j.surg.2010.12.002]
  - 16 Hogan MC, Chamberlin JA, Vaughan LE, Waits AL, Banks C, Leistikow K, Oftsie T, Madsen C, Edwards M, Glockner J, Kremers WK, Harris PC, LaRusso NF, Torres VE, Masyuk TV. Pansomatostatin Agonist Pasireotide Long-Acting Release for Patients with Autosomal Dominant Polycystic Kidney or Liver Disease with Severe Liver Involvement: A Randomized Clinical Trial. *Clin J Am Soc Nephrol* 2020; **15**: 1267-1278 [PMID: 32843370 DOI: 10.2215/CJN.13661119]
  - 17 Yamada K, Endo H, Tetsunaga T, Miyake T, Sanki T, Ozaki T. Accuracy of Cup Positioning With the Computed Tomography-Based Two-dimensional to Three-Dimensional Matched Navigation System: A Prospective, Randomized Controlled Study. *J Arthroplasty* 2018; **33**: 136-143 [PMID: 28870743 DOI: 10.1016/j.arth.2017.08.001]
  - 18 Yang SF, Powell A, Srinivasan S, Kim JC, Baker SR, Green GE, Zopf DA. Addressing the Pandemic Training Deficiency: Filling the Void with Simulation in Facial Reconstruction. *Laryngoscope* 2021; **131**: E2444-E2448 [PMID: 33656188 DOI: 10.1002/lary.29490]
  - 19 Dala Riva DF, Nacif LS, Fernandes MR, Silva NA, Pinheiro RS, Rocha-Santos V, De Martino RB, Waisberg DR, Macedo RA, Ducatti L, De Paiva Haddad LB, Galvão FHF, Andraus W, Carneiro-D'Albuquerque L. Relationship of Anatomic Variations and Arterial Reconstruction of the Hepatic Artery: Prevalence and Effect on Orthotopic Liver Transplantation. *Transplant Proc* 2022; **54**: 1313-1315 [PMID: 35717257 DOI: 10.1016/j.transproceed.2022.04.012]
  - 20 Acar G, Cicekcibasi AE, Koplay M, Seher N. Anatomical Variations of the Celiac Trunk and Hepatic Arteries with a New Classification, Based on CT Angiography. *J Coll Physicians Surg Pak* 2022; **32**: 9-14 [PMID: 34983140 DOI: 10.29271/jcpsp.2022.01.9]
  - 21 Smillie RW, Williams MA, Richard M, Cosker T. Producing three-dimensional printed models of the hepatobiliary system from computed tomography imaging data. *Ann R Coll Surg Engl* 2021; **103**: 41-46 [PMID: 32964727 DOI: 10.1308/rcsann.2020.0191]
  - 22 Cannella R, Sartoris R, Grégory J, Garzelli L, Vilgrain V, Ronot M, Dioguardi Burgio M. Quantitative magnetic resonance imaging for focal liver lesions: bridging the gap between research and clinical practice. *Br J Radiol* 2021; **94**: 20210220 [PMID: 33989042 DOI: 10.1259/bjr.20210220]
  - 23 Damle-Vartak A. 3D visualization of the biliary tree by X-ray phase-contrast computed tomography. *Arch Toxicol* 2018; **92**: 3601-3602 [PMID: 30460423 DOI: 10.1007/s00204-018-2346-1]
  - 24 Buettner S, Margonis GA, Kim Y, Gani F, Ethun CG, Poultsides G, Tran T, Idrees K, Isom CA, Fields RC, Krasnick B, Weber SM, Salem A, Martin RC, Scoggins CR, Shen P, Mogal HD, Schmidt C, Beal E, Hatzaras I, Shenoy R, Maithel SK, Pawlik TM. Conditional probability of long-term survival after resection of hilar cholangiocarcinoma. *HPB (Oxford)* 2016; **18**: 510-517 [PMID: 27317955 DOI: 10.1016/j.hpb.2016.04.001]



Published by **Baishideng Publishing Group Inc**  
7041 Koll Center Parkway, Suite 160, Pleasanton, CA 94566, USA

**Telephone:** +1-925-3991568

**E-mail:** [bpgoffice@wjgnet.com](mailto:bpgoffice@wjgnet.com)

**Help Desk:** <https://www.f6publishing.com/helpdesk>

<https://www.wjgnet.com>

