

World Journal of *Gastrointestinal Surgery*

World J Gastrointest Surg 2023 August 27; 15(8): 1559-1840



Contents

Monthly Volume 15 Number 8 August 27, 2023

MINIREVIEWS

- 1559 Impact of tumour rupture risk on the oncological rationale for the surgical treatment choice of gastrointestinal stromal tumours
Peparini N
- 1564 Prevention and treatment of hepatic encephalopathy during the perioperative period of transjugular intrahepatic portosystemic shunt
Wang LJ, Yao X, Qi Q, Qin JP
- 1574 Vascular complications of chronic pancreatitis and its management
Walia D, Saraya A, Gunjan D
- 1591 Historical changes in surgical strategy and complication management for hepatic cystic echinococcosis
A JD, Chai JP, Jia SL, A XR

ORIGINAL ARTICLE

Basic Study

- 1600 High spindle and kinetochore-associated complex subunit-3 expression predicts poor prognosis and correlates with adverse immune infiltration in hepatocellular carcinoma
Zheng LL, Wang YR, Liu ZR, Wang ZH, Tao CC, Xiao YG, Zhang K, Wu AK, Li HY, Wu JX, Xiao T, Rong WQ

Case Control Study

- 1615 Post-transplant biliary complications using liver grafts from deceased donors older than 70 years: Retrospective case-control study
Jimenez-Romero C, Justo-Alonso I, del Pozo-Elso P, Marcacuzco-Quinto A, Martín-Arriscado-Arroba C, Manrique-Municio A, Calvo-Pulido J, García-Sesma A, San Román R, Caso-Maestro O
- 1629 Goldilocks principle of minimally invasive surgery for gastric subepithelial tumors
Chang WJ, Tsao LC, Yen HH, Yang CW, Chang HC, Kor CT, Wu SC, Lin KH

Retrospective Cohort Study

- 1641 Prognosis after splenectomy plus pericardial devascularization *vs* transjugular intrahepatic portosystemic shunt for esophagogastric variceal bleeding
Qi WL, Wen J, Wen TF, Peng W, Zhang XY, Shen JY, Li X, Li C
- 1652 Initial suction drainage decreases severe postoperative complications after pancreatic trauma: A cohort study
Li KW, Wang K, Hu YP, Yang C, Deng YX, Wang XY, Liu YX, Li WQ, Ding WW

Retrospective Study

- 1663** Radiation therapy prior to a pancreaticoduodenectomy for adenocarcinoma is associated with longer operative times and higher blood loss
Aploks K, Kim M, Stroever S, Ostapenko A, Sim YB, Sooriyakumar A, Rahimi-Ardabili A, Seshadri R, Dong XD
- 1673** Prognostic significance of preoperative lymphocyte to monocyte ratio in patients with signet ring gastric cancer
Liu HL, Feng X, Tang MM, Zhou HY, Peng H, Ge J, Liu T
- 1684** Clinical efficacy of total laparoscopic splenectomy for portal hypertension and its influence on hepatic hemodynamics and liver function
Qi RZ, Li ZW, Chang ZY, Chang WH, Zhao WL, Pang C, Zhang Y, Hu XL, Liang F
- 1693** Accurate resection of hilar cholangiocarcinoma using eOrganmap 3D reconstruction and full quantization technique
Cui DP, Fan S, Guo YX, Zhao QW, Qiao YX, Fei JD
- 1703** Regional differences in islet amyloid deposition in the residual pancreas with new-onset diabetes secondary to pancreatic ductal adenocarcinoma
Wang R, Liu Y, Liang Y, Zhou L, Chen MJ, Liu XB, Tan CL, Chen YH
- 1712** Risk factors and their interactive effects on severe acute pancreatitis complicated with acute gastrointestinal injury
Chen JH, Zhang MF, Du WC, Zhang YA
- 1719** Effects of ultrasound monitoring of gastric residual volume on feeding complications, caloric intake and prognosis of patients with severe mechanical ventilation
Xu XY, Xue HP, Yuan MJ, Jin YR, Huang CX
- 1728** Enhanced recovery nursing and mental health education on postoperative recovery and mental health of laparoscopic liver resection
Li DX, Ye W, Yang YL, Zhang L, Qian XJ, Jiang PH
- 1739** Changing trends in gastric and colorectal cancer among surgical patients over 85 years old: A multicenter retrospective study, 2001–2021
Chen K, Li M, Xu R, Zheng PP, Chen MD, Zhu L, Wang WB, Wang ZG

Observational Study

- 1751** Knowledge, attitude, and practice of monitoring early gastric cancer after endoscopic submucosal dissection
Yang XY, Wang C, Hong YP, Zhu TT, Qian LJ, Hu YB, Teng LH, Ding J
- 1761** Anti-reflux effects of a novel esophagogastric asymmetric anastomosis technique after laparoscopic proximal gastrectomy
Pang LQ, Zhang J, Shi F, Pang C, Zhang CW, Liu YL, Zhao Y, Qian Y, Li XW, Kong D, Wu SN, Zhou JF, Xie CX, Chen S
- 1774** Prognostic scores in primary biliary cholangitis patients with advanced disease
Feng J, Xu JM, Fu HY, Xie N, Bao WM, Tang YM

SYSTEMATIC REVIEWS

- 1784** Maternal choledochal cysts in pregnancy: A systematic review of case reports and case series
Augustin G, Romic I, Miličić I, Mikuš M, Herman M
- 1799** Intraoperative pancreas stump perfusion assessment during pancreaticoduodenectomy: A systematic scoping review
Robertson FP, Spiers HVM, Lim WB, Loveday B, Roberts K, Pandanaboyana S
- 1808** Comparison between upfront surgery and neoadjuvant chemotherapy in patients with locally advanced gastric cancer: A systematic review
Fiflis S, Papakonstantinou M, Giakoustidis A, Christodoulidis G, Louri E, Papadopoulos VN, Giakoustidis D

CASE REPORT

- 1819** Long-term survival of patients with hepatocellular carcinoma with hepatic, pulmonary, peritoneal and rare colon metastasis: A case report
Gong YQ, Lu TL, Chen CW
- 1825** Donor hepatic artery reconstruction based on human embryology: A case report
Zhang HZ, Lu JH, Shi ZY, Guo YR, Shao WH, Meng FX, Zhang R, Zhang AH, Xu J
- 1831** Outpatient hybrid endoscopic submucosal dissection with SOUTEN for early gastric cancer, followed by endoscopic suturing of the mucosal defect: A case report
Ito R, Miwa K, Matano Y

LETTER TO THE EDITOR

- 1838** Is endoscopic mucosal resection-precutting superior to conventional methods for removing sessile colorectal polyps?
Yang QY, Zhao Q, Hu JW

ABOUT COVER

Editorial Board Member of *World Journal of Gastrointestinal Surgery*, Raja Kalayarasan, MS, DNB, MCh, FRCS (Ed), Additional Professor & Head, Department of Surgical Gastroenterology, Jawaharlal Institute of Postgraduate Medical Education and Research (JIPMER), Puducherry 605006, India. kalayarasanraja@yahoo.com

AIMS AND SCOPE

The primary aim of *World Journal of Gastrointestinal Surgery* (WJGS, *World J Gastrointest Surg*) is to provide scholars and readers from various fields of gastrointestinal surgery with a platform to publish high-quality basic and clinical research articles and communicate their research findings online.

WJGS mainly publishes articles reporting research results and findings obtained in the field of gastrointestinal surgery and covering a wide range of topics including biliary tract surgical procedures, biliopancreatic diversion, colectomy, esophagectomy, esophagostomy, pancreas transplantation, and pancreatectomy, etc.

INDEXING/ABSTRACTING

The WJGS is now abstracted and indexed in Science Citation Index Expanded (SCIE, also known as SciSearch®), Current Contents/Clinical Medicine, Journal Citation Reports/Science Edition, PubMed, PubMed Central, Reference Citation Analysis, China National Knowledge Infrastructure, China Science and Technology Journal Database, and Superstar Journals Database. The 2023 Edition of Journal Citation Reports® cites the 2022 impact factor (IF) for WJGS as 2.0; IF without journal self cites: 1.9; 5-year IF: 2.2; Journal Citation Indicator: 0.52; Ranking: 113 among 212 journals in surgery; Quartile category: Q3; Ranking: 81 among 93 journals in gastroenterology and hepatology; and Quartile category: Q4.

RESPONSIBLE EDITORS FOR THIS ISSUE

Production Editor: Rui-Rui Wu; Production Department Director: Xiang Li; Editorial Office Director: Jia-Ru Fan.

NAME OF JOURNAL

World Journal of Gastrointestinal Surgery

ISSN

ISSN 1948-9366 (online)

LAUNCH DATE

November 30, 2009

FREQUENCY

Monthly

EDITORS-IN-CHIEF

Peter Schemmer

EDITORIAL BOARD MEMBERS

<https://www.wjgnet.com/1948-9366/editorialboard.htm>

PUBLICATION DATE

August 27, 2023

COPYRIGHT

© 2023 Baishideng Publishing Group Inc

INSTRUCTIONS TO AUTHORS

<https://www.wjgnet.com/bpg/gerinfo/204>

GUIDELINES FOR ETHICS DOCUMENTS

<https://www.wjgnet.com/bpg/GerInfo/287>

GUIDELINES FOR NON-NATIVE SPEAKERS OF ENGLISH

<https://www.wjgnet.com/bpg/gerinfo/240>

PUBLICATION ETHICS

<https://www.wjgnet.com/bpg/GerInfo/288>

PUBLICATION MISCONDUCT

<https://www.wjgnet.com/bpg/gerinfo/208>

ARTICLE PROCESSING CHARGE

<https://www.wjgnet.com/bpg/gerinfo/242>

STEPS FOR SUBMITTING MANUSCRIPTS

<https://www.wjgnet.com/bpg/GerInfo/239>

ONLINE SUBMISSION

<https://www.f6publishing.com>



Outpatient hybrid endoscopic submucosal dissection with SOUTEN for early gastric cancer, followed by endoscopic suturing of the mucosal defect: A case report

Renma Ito, Kazuhiro Miwa, Yutaka Matano

Specialty type: Gastroenterology and hepatology

Provenance and peer review: Unsolicited article; Externally peer reviewed.

Peer-review model: Single blind

Peer-review report's scientific quality classification

Grade A (Excellent): 0
Grade B (Very good): B, B
Grade C (Good): 0
Grade D (Fair): 0
Grade E (Poor): 0

P-Reviewer: Yan B, China; Yu HG, China

Received: May 7, 2023

Peer-review started: May 7, 2023

First decision: June 1, 2023

Revised: June 13, 2023

Accepted: June 27, 2023

Article in press: June 27, 2023

Published online: August 27, 2023



Renma Ito, Kazuhiro Miwa, Yutaka Matano, Internal Medicine, Komatsu Municipal Hospital, Komatsu 923-0961, Japan

Corresponding author: Renma Ito, MD, Chief Doctor, Internal Medicine, Komatsu Municipal Hospital, 60 Mukaimotoorimachi-ho, Komatsu 923-0961, Japan. remma0504@outlook.jp

Abstract

BACKGROUND

Although endoscopic submucosal dissection (ESD) is becoming more common for early gastric cancer, it requires more advanced techniques and a longer treatment duration than endoscopic mucosal resection. Hybrid ESD using a multifunctional snare (SOUTEN) has been reported to be effective for colorectal lesions, as it can reduce treatment duration. Endoscopic suturing of post-ESD mucosal defects has been reported to reduce the incidence of ESD-related complications.

CASE SUMMARY

This study reports outpatient hybrid ESD for early gastric cancer using SOUTEN, followed by endoscopic suturing of post-ESD mucosal defects in an 86-year-old man. On referral for ESD, a 10-mm flat, depressed lesion was found on the posterior wall of the gastric antrum, the depth of which was expected to be mucosal. Given his history of delirium, we performed outpatient endoscopic treatment. The procedure used was hybrid ESD using SOUTEN to reduce the duration of treatment and endoscopic suturing of post-ESD mucosal defects to reduce complications. The procedure time was 62 min and the lesion was completely resected based on histopathological examination, with no reported postoperative complications.

CONCLUSION

This safe and useful procedure may be especially important for outpatient endoscopic treatment.

Key Words: Outpatient treatment; Hybrid endoscopic submucosal dissection; Multifunctional snare; Early gastric cancer; Endoscopic suturing; Case report

©The Author(s) 2023. Published by Baishideng Publishing Group Inc. All rights reserved.

Core Tip: Hybrid endoscopic submucosal dissection (ESD) using a multifunctional snare (SOUTEN) has been reported to be effective in reducing treatment duration, and endoscopic suturing of post-ESD mucosal defects has been reported to reduce complications. Herein, we report an outpatient hybrid ESD for early gastric cancer using SOUTEN, followed by endoscopic suturing of post-ESD mucosal defects in an 86-year-old male. The procedure time was 62 min and the lesion was completely resected based on histopathological examination, with no reported postoperative complications.

Citation: Ito R, Miwa K, Matano Y. Outpatient hybrid endoscopic submucosal dissection with SOUTEN for early gastric cancer, followed by endoscopic suturing of the mucosal defect: A case report. *World J Gastrointest Surg* 2023; 15(8): 1831-1837

URL: <https://www.wjgnet.com/1948-9366/full/v15/i8/1831.htm>

DOI: <https://dx.doi.org/10.4240/wjgs.v15.i8.1831>

INTRODUCTION

Endoscopic submucosal dissection (ESD) is becoming increasingly common for early gastric cancer[1]. ESD requires more advanced techniques and a longer duration of treatment than endoscopic mucosal resection and is potentially associated with more complications. Hybrid ESD performed with multifunctional snare (SOUTEN, Kaneka Medics, Tokyo, Japan) (Figure 1), has been reported to be clinically effective for endoscopic treatment of colorectal lesions and to reduce the duration of treatment[2-4]. Moreover, endoscopic suturing of post-ESD mucosal defects can reduce complications, such as bleeding and perforation[5-7].

Herein, we report a case of early gastric cancer in which outpatient hybrid ESD with SOUTEN was performed in an elderly man with a history of delirium during hospitalization, after which the mucosal defect was sutured endoscopically to reduce complications.

CASE PRESENTATION

Chief complaints

No complaints.

History of present illness

An 86-year-old male diagnosed with early gastric cancer confirmed by esophagogastroduodenoscopy and biopsy was referred to our hospital for ESD. The medical history included Alzheimer's disease, chronic kidney disease, and dyslipidemia.

History of past illness

The patient's past medical history was non-contributory.

Personal and family history

The patient had no family history of gastric cancer and was neither a smoker nor a drinker.

Physical examination

Physical examination did not reveal abnormalities and the Eastern Cooperative Oncology Group performance status score was 1, which was relatively good.

Laboratory examinations


Laboratory examination results were within the normal range.

Imaging examinations

Esophagogastroduodenoscopy revealed a 10-mm flat, depressed lesion on the posterior wall of the gastric antrum that was identified as a demarcation line and had an irregular microvascular pattern detected by magnifying endoscopy with narrow-band imaging (Figure 2). The lesion had already been diagnosed as gastric cancer on the basis of a biopsy performed in a previous hospital.

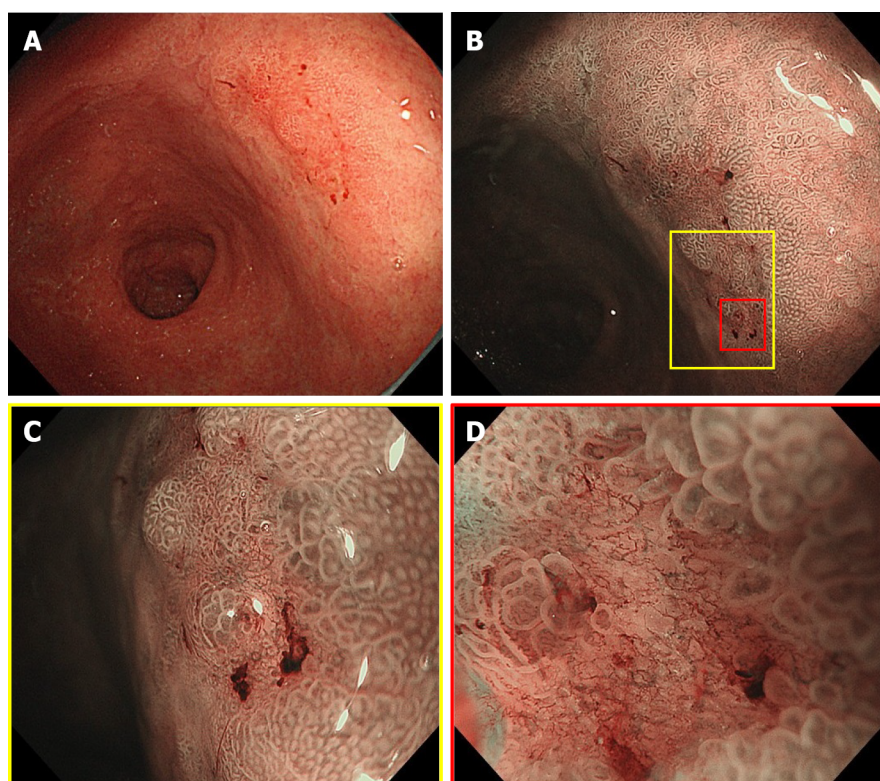
FINAL DIAGNOSIS

The lesion was believed to be mucosal; therefore, the diagnosis of early gastric cancer was further confirmed at our hospital, where ESD was deemed necessary.



DOI: 10.4240/wjgs.v15.i8.1831 Copyright ©The Author(s) 2023.

Figure 1 Details of the SOUTEN device, a multifunctional snare. A: Full view of the SOUTEN device; B: The long diameter of the snare is 40 mm, and the short diameter of the snare is 15 mm; C: A 1.5-mm needle knife with a knob-shaped tip is attached to the top of the snare.

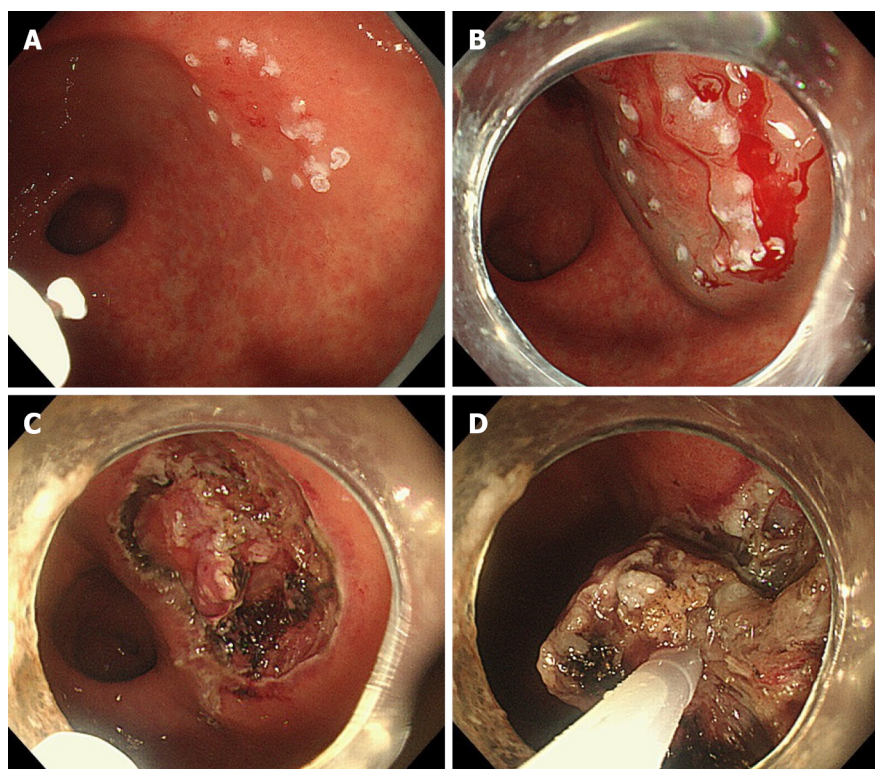


DOI: 10.4240/wjgs.v15.i8.1831 Copyright ©The Author(s) 2023.

Figure 2 Endoscopic view of the 10-mm flat-depressed lesion on the posterior wall of the gastric antrum. A: Distant view of the lesion under white-light imaging; B: Non-expansion view of the lesion using magnifying endoscopy with narrow-band imaging; C: Weak-expansion view of the lesion using magnifying endoscopy with narrow-band imaging; D: Strong-expansion view of the lesion using magnifying endoscopy with narrow-band imaging.

TREATMENT

The patient was unaware of the early gastric cancer diagnosis due to the symptoms of Alzheimer's disease. The patient's family wanted him to undergo ESD; however, they refused hospitalization due to a history of delirium before admission.



DOI: 10.4240/wjgs.v15.i8.1831 Copyright ©The Author(s) 2023.

Figure 3 Hybrid endoscopic submucosal dissection process with SOUTEN. A: A knife attached to the top of the snare is used to mark the lesion; B: A mixture of hyaluronic acid and saline is injected into the submucosa around the lesion; C: A knife attached to the top of the snare is used to dissect the submucosal around the lesion; D: Resection of the lesion with the snare.

Therefore, we planned outpatient hybrid ESD with SOUTEN to reduce the duration of treatment, followed by endoscopic suturing of the post-ESD mucosal defect to reduce complications. Informed consent was obtained from all patients and their families. The patient was administered vonoprazan (20 mg/d) for 8 wk from the day of ESD. We performed an outpatient hybrid ESD for early gastric cancer with SOUTEN (Figure 3) and endoscopically sutured the post-ESD mucosal defect using strings and clips (Figure 4). The procedure time was 62 min. We instructed the patient's family that the patient should only drink fluid on the day of outpatient ESD and eat soft food the next day. Regular meal consumption was resumed 1 wk after outpatient ESD.

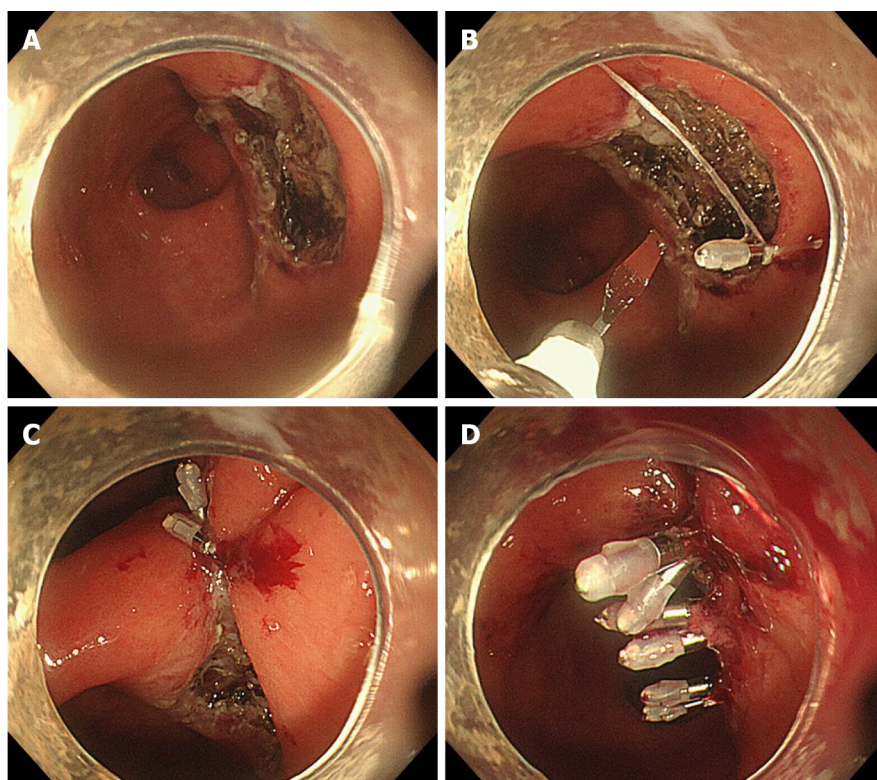
OUTCOME AND FOLLOW-UP

No complications were observed, including delirium, and follow-up after the procedure was uneventful. Histopathological examination of the resected lesion revealed well-differentiated adenocarcinoma with mucosal depth and no lymphatic or vascular invasion. The margins were negative, indicating complete resection of the lesion. One month after outpatient ESD, esophagogastroduodenoscopy revealed that the ulcer had almost healed and only a part of the ulcer floor was visible (Figure 5).

DISCUSSION

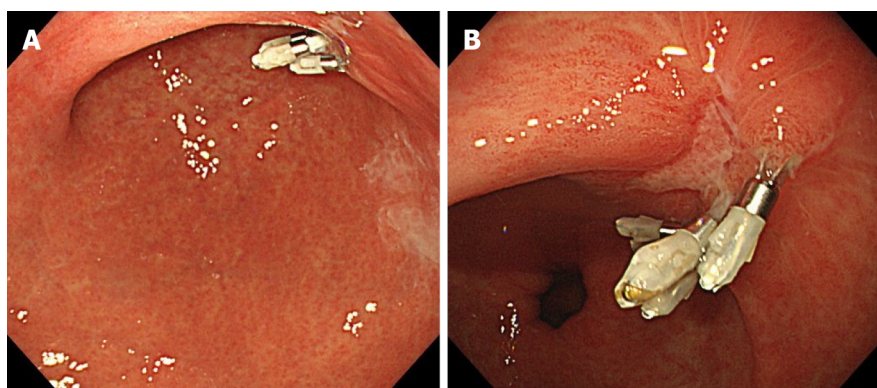
To the best of our knowledge, this is the first report of outpatient hybrid ESD performed for early gastric cancer with SOUTEN and endoscopic suturing of a post-ESD mucosal defect. Treatment was successful and no complications were observed. Hybrid ESD has been reported to achieve a shorter procedure time than ESD with similar *en-bloc* resection rates and adverse events for colorectal lesions[8]. SOUTEN, a device specialized for hybrid ESD, is a multifunctional snare with two features (a high-frequency knife and a snare). Hybrid ESD with SOUTEN is clinically useful for the treatment of colorectal epithelial tumors[2-4]. However, for gastric lesions, it is useful to reduce endoscopic treatment time in basic research, not clinical research[9]. Although we have shown the clinical usefulness of hybrid ESD with SOUTEN for early gastric cancer in this case report, further research is recommended to elucidate its clinical application in gastric lesions.

We believe that hybrid ESD with SOUTEN and endoscopic suturing is advantageous for smaller lesions as in this case, but disadvantageous for large lesions because snaring and suturing large lesions is difficult. Additionally, such treatment might be more difficult for gastric lesions than colorectal lesions because snaring is difficult in some parts such as the



DOI: 10.4240/wjgs.v15.i8.1831 Copyright ©The Author(s) 2023.

Figure 4 Endoscopic suturing process for a mucosal defect after endoscopic submucosal dissection. A: Post-endoscopic submucosal dissection mucosal defect in the posterior wall of the gastric antrum; B: A clip with a string attached to the tip is first attached to the anal aspect of the mucosal defect, and an additional clip is attached to the oral aspect of the mucosal defect while sandwiching the string; C: Bring both ends of the mucosa closer by pulling the string out of the mouth; D: Suturing the mucosal defect completely by attaching additional clips to both sides of the mucosal defect and finally burning off the string with the knife of SOUTEN.



DOI: 10.4240/wjgs.v15.i8.1831 Copyright ©The Author(s) 2023.

Figure 5 Endoscopic view of the ulcer one month after endoscopic submucosal dissection. A: Distant view of the ulcer; B: Close-up view of the ulcer.

angle in the stomach.

The post-ESD mucosal defect was sutured endoscopically to reduce post-ESD bleeding[6] and prevent perforation[7]. In a previous report on gastric ESD, perforation occurred in 2.8% of patients and delayed bleeding that required endoscopic hemostasis occurred in 6.2%[10]. Endoscopic suturing of mucosal defects after ESD may prevent these complications. Therefore, it is desirable to endoscopically suture mucosal defects after ESD to reduce the occurrence of complications, particularly when performing outpatient ESD. Although there are some ways to suture mucosal defects using endoscopy, we believe that endoscopic suturing using a clip with a string[11] is simple and useful; therefore, we sutured the mucosal defects using this method.

Although the usefulness and safety of outpatient ESD for gastric lesions has been reported, some complications centered on delayed bleeding occurred in 1.9%-5.7%[12,13]. We believe that minimizing the occurrence of complications during outpatient ESD is important. Therefore, we used vonoprazan, which has been reported to prevent bleeding from

ED-induced gastric ulcers[14]. Endoscopic suturing of the mucosal defect and the use of vonoprazan for ESD-induced gastric ulcers might be important in reducing complications in outpatient ESD.

We performed endoscopic treatment for early gastric cancer in an 86-year-old patient. The treatment of cancer in elderly patients is challenging because it is unclear whether these patients have a positive prognosis. Furthermore, elderly people are prone to developing delirium during hospitalization. Although the patient experienced psychological problems in the present case, his physical condition was relatively good. Outpatient ESD is useful for treating early gastric cancer and preventing delirium in elderly patients. We believe that endoscopic treatment for early gastric cancer in elderly patients with good physical status is beneficial and that outpatient endoscopic treatment is especially useful for elderly patients.

CONCLUSION

Outpatient hybrid ESD for early gastric cancer using SOUTEN followed by endoscopic suturing of post-ESD mucosal defects was safe and useful. This may be particularly important for outpatient endoscopic treatment.

ACKNOWLEDGEMENTS

The authors thank the staff of the endoscopy room at the Komatsu Municipal Hospital.

FOOTNOTES

Author contributions: Ito R, Miwa K, and Matano Y conceived the idea of the treatment in this case; Ito R drafted the original manuscript; all authors reviewed the manuscript draft and revised it critically.

Informed consent statement: Informed consent for inclusion in the study or equivalent was obtained from the patient's family.

Conflict-of-interest statement: The authors declare that they have no conflict of interest.

CARE Checklist (2016) statement: The authors have read the CARE Checklist (2016), and the manuscript was prepared and revised according to the CARE Checklist (2016).

Open-Access: This article is an open-access article that was selected by an in-house editor and fully peer-reviewed by external reviewers. It is distributed in accordance with the Creative Commons Attribution NonCommercial (CC BY-NC 4.0) license, which permits others to distribute, remix, adapt, build upon this work non-commercially, and license their derivative works on different terms, provided the original work is properly cited and the use is non-commercial. See: <https://creativecommons.org/licenses/by-nc/4.0/>

Country/Territory of origin: Japan

ORCID number: Renma Ito 0000-0001-7706-166X; Kazuhiro Miwa 0000-0002-5486-9137; Yutaka Matano 0000-0003-4933-5381.

S-Editor: Chen YL

L-Editor: A

P-Editor: Chen YL

REFERENCES

- 1 Ono H, Yao K, Fujishiro M, Oda I, Nimura S, Yahagi N, Iishi H, Oka M, Ajioka Y, Ichinose M, Matsui T. Guidelines for endoscopic submucosal dissection and endoscopic mucosal resection for early gastric cancer. *Dig Endosc* 2016; **28**: 3-15 [PMID: 26234303 DOI: 10.1111/den.12518]
- 2 Ohata K, Muramoto T, Minato Y, Chiba H, Sakai E, Matsuhashi N. Usefulness of a multifunctional snare designed for colorectal hybrid endoscopic submucosal dissection (with video). *Endosc Int Open* 2018; **6**: E249-E253 [PMID: 29423435 DOI: 10.1055/s-0043-124364]
- 3 Yoshii S, Kubo M, Matsumoto M, Kikuchi T, Takakuwa Y. Efficacy and Safety of Complete Endoscopic Resection of Colorectal Neoplasia Using a Stepwise Endoscopic Protocol with SOUTEN, a Novel Multifunctional Snare. *Clin Endosc* 2020; **53**: 206-212 [PMID: 32102497 DOI: 10.5946/ce.2019.117]
- 4 Arimoto J, Ohata K, Chiba H, Tachikawa J, Okada N, Kuwabara H, Nakaoka M, Ashikari K, Ishii R, Minato Y, Takita M, Sakai E, Muramoto T, Matsuhashi N, Goto T, Nakajima A. Evaluation of colorectal endoscopic submucosal dissection using a multifunctional snare: a prospective clinical feasibility study (with videos). *Gastrointest Endosc* 2021; **93**: 671-678 [PMID: 32950596 DOI: 10.1016/j.gie.2020.09.019]
- 5 Kantsevov SV, Bitner M, Mitrov AA, Thuluvath PJ. Endoscopic suturing closure of large mucosal defects after endoscopic submucosal dissection is technically feasible, fast, and eliminates the need for hospitalization (with videos). *Gastrointest Endosc* 2014; **79**: 503-507 [PMID: 24332082 DOI: 10.1016/j.gie.2013.10.051]
- 6 Goto O, Oyama T, Ono H, Takahashi A, Fujishiro M, Saito Y, Abe S, Kaise M, Iwakiri K, Yahagi N. Endoscopic hand-suturing is feasible,

- safe, and may reduce bleeding risk after gastric endoscopic submucosal dissection: a multicenter pilot study (with video). *Gastrointest Endosc* 2020; **91**: 1195-1202 [PMID: [31923410](#) DOI: [10.1016/j.gie.2019.12.046](#)]
- 7 **Akimoto T**, Goto O, Sasaki M, Mizutani M, Tsutsumi K, Kiguchi Y, Nakayama A, Kato M, Fujimoto A, Ochiai Y, Machata T, Kaise M, Iwakiri K, Yahagi N. Endoscopic suturing promotes healing of mucosal defects after gastric endoscopic submucosal dissection: endoscopic and histologic analyses in in vivo porcine models (with video). *Gastrointest Endosc* 2020; **91**: 1172-1182 [PMID: [31904381](#) DOI: [10.1016/j.gie.2019.12.032](#)]
 - 8 **Bae JH**, Yang DH, Lee S, Soh JS, Lee HS, Lee HJ, Park SH, Kim KJ, Ye BD, Myung SJ, Yang SK, Byeon JS. Optimized hybrid endoscopic submucosal dissection for colorectal tumors: a randomized controlled trial. *Gastrointest Endosc* 2016; **83**: 584-592 [PMID: [26320696](#) DOI: [10.1016/j.gie.2015.06.057](#)]
 - 9 **Esaki M**, Ihara E, Hashimoto N, Abe S, Aratono C, Shiga N, Sumida Y, Fujii H, Haraguchi K, Takahashi S, Iwasa T, Nakano K, Wada M, Somada S, Nishioka K, Minoda Y, Ogino H, Ogawa Y. Efficacy of hybrid endoscopic submucosal dissection with SOUTEN in gastric lesions: An *ex vivo* porcine model basic study. *World J Gastrointest Surg* 2021; **13**: 563-573 [PMID: [34194614](#) DOI: [10.4240/wjgs.v13.i6.563](#)]
 - 10 **Hasuike N**, Ono H, Boku N, Mizusawa J, Takizawa K, Fukuda H, Oda I, Doyama H, Kaneko K, Hori S, Iishi H, Kurokawa Y, Muto M; Gastrointestinal Endoscopy Group of Japan Clinical Oncology Group (JCOG-GIESG). A non-randomized confirmatory trial of an expanded indication for endoscopic submucosal dissection for intestinal-type gastric cancer (cT1a): the Japan Clinical Oncology Group study (JCOG0607). *Gastric Cancer* 2018; **21**: 114-123 [PMID: [28224238](#) DOI: [10.1007/s10120-017-0704-y](#)]
 - 11 **Yahagi N**, Nishizawa T, Akimoto T, Ochiai Y, Goto O. New endoscopic suturing method: string clip suturing method. *Gastrointest Endosc* 2016; **84**: 1064-1065 [PMID: [27327846](#) DOI: [10.1016/j.gie.2016.05.054](#)]
 - 12 **Baldaque-Silva F**, Marques M, Andrade AP, Sousa N, Lopes J, Carneiro F, Macedo G. Endoscopic submucosal dissection of gastrointestinal lesions on an outpatient basis. *United European Gastroenterol J* 2019; **7**: 326-334 [PMID: [31080617](#) DOI: [10.1177/2050640618823874](#)]
 - 13 **Ahn SY**, Jang SI, Lee DW, Jeon SW. Gastric endoscopic submucosal dissection is safe for day patients. *Clin Endosc* 2014; **47**: 538-543 [PMID: [25505720](#) DOI: [10.5946/ce.2014.47.6.538](#)]
 - 14 **Hamada K**, Uedo N, Tonai Y, Arao M, Suzuki S, Iwatsubo T, Kato M, Shichijo S, Yamasaki Y, Matsuura N, Nakahira H, Kanesaka T, Yamamoto S, Akasaka T, Hanaoka N, Takeuchi Y, Higashino K, Ishihara R, Okada H, Iishi H, Fukui K, Shimokawa T. Efficacy of vonoprazan in prevention of bleeding from endoscopic submucosal dissection-induced gastric ulcers: a prospective randomized phase II study. *J Gastroenterol* 2019; **54**: 122-130 [PMID: [29943163](#) DOI: [10.1007/s00535-018-1487-6](#)]



Published by **Baishideng Publishing Group Inc**
7041 Koll Center Parkway, Suite 160, Pleasanton, CA 94566, USA

Telephone: +1-925-3991568

E-mail: bpgoffice@wjgnet.com

Help Desk: <https://www.f6publishing.com/helpdesk>

<https://www.wjgnet.com>

