

# World Journal of *Gastrointestinal Surgery*

*World J Gastrointest Surg* 2023 September 27; 15(9): 1841-2097



## Contents

Monthly Volume 15 Number 9 September 27, 2023

## REVIEW

- 1841** Indocyanine green dye and its application in gastrointestinal surgery: The future is bright green  
*Lim ZY, Mohan S, Balasubramaniam S, Ahmed S, Siew CCH, Shelat VG*
- 1858** Hepatic ischemia-reperfusion syndrome and its effect on the cardiovascular system: The role of treprostinil, a synthetic prostacyclin analog  
*Mouratidou C, Pavlidis ET, Katsanos G, Kotoulas SC, Mouloudi E, Tsoulfas G, Galanis IN, Pavlidis TE*

## MINIREVIEWS

- 1871** Advances and challenges of gastrostomy insertion in children  
*Bitar R, Azaz A, Rawat D, Hobeldin M, Miqdady M, Abdelsalam S*
- 1879** Surgical decompression for the management of abdominal compartment syndrome with severe acute pancreatitis: A narrative review  
*Nasa P, Chanchalani G, Juneja D, Malbrain ML*

## ORIGINAL ARTICLE

## Retrospective Cohort Study

- 1892** Excision of malignant and pre-malignant rectal lesions by transanal endoscopic microsurgery in patients under 50 years of age  
*Shilo Yaacobi D, Berger Y, Shaltiel T, Bekhor EY, Khalifa M, Issa N*
- 1901** Safety and feasibility of modified duct-to-mucosa pancreaticojejunostomy during pancreatoduodenectomy: A retrospective cohort study  
*Sun Y, Yu XF, Yao H, Xu S, Ma YQ, Chai C*

## Retrospective Study

- 1910** Application of early enteral nutrition nursing based on enhanced recovery after surgery theory in patients with digestive surgery  
*Shao YR, Ke X, Luo LH, Xu JD, Xu LQ*
- 1919** Autologous bone marrow infusion *via* portal vein combined with splenectomy for decompensated liver cirrhosis: A retrospective study  
*Liu BC, Cheng MR, Lang L, Li L, Si YH, Li AJ, Xu Q, Zhang H*
- 1932** Application of multidisciplinary collaborative nursing with family care for enhanced recovery after surgery in children with inguinal hernia  
*Wang XM, Hou Q*
- 1941** Preoperative and postoperative complications as risk factors for delayed gastric emptying following pancreaticoduodenectomy: A single-center retrospective study  
*Xie FL, Ren LJ, Xu WD, Xu TL, Ge XQ, Li W, Ge XM, Zhou WK, Li K, Zhang YH, Wang Z*

- 1950** Efficacy of ileus tube combined with meglumine diatrizoate in treating postoperative inflammatory bowel obstruction after surgery  
*Yang W, Pu J*
- 1959** Effect of internet multiple linkage mode-based extended care combined with in-hospital comfort care on colorectal cancer patients undergoing colostomy  
*Xu L, Zhou MZ*
- 1969** Short- and long-term results of open *vs* laparoscopic multisegmental resection and anastomosis for synchronous colorectal cancer located in separate segments  
*Quan JC, Zhou XJ, Mei SW, Liu JG, Qiu WL, Zhang JZ, Li B, Li YG, Wang XS, Chang H, Tang JQ*
- 1978** Prediction model of stress ulcer after laparoscopic surgery for colorectal cancer established by machine learning algorithm  
*Yu DM, Wu CX, Sun JY, Xue H, Yuwen Z, Feng JX*
- 1986** Effect of two surgical approaches on the lung function and prognosis of patients with combined esophago-gastric cancer  
*Sun CB, Han XQ, Wang H, Zhang YX, Wang MC, Liu YN*
- 1995** Clinical significance of serum oxidative stress and serum uric acid levels before surgery for hepatitis B-related liver cancer  
*Hou JX, Wang YB, Wu J, Ding GS, Wu Y, Wei LH, Wang F, Zhang ZM*
- 2003** Multifactor analysis of the technique in total laparoscopic gastric cancer  
*Shi JK, Wang B, Zhang XS, Lv P, Chen YL, Ren SY*
- 2012** Value of enhanced computed tomography in differentiating small mesenchymal tumours of the gastrointestinal from smooth muscle tumours  
*Nie WJ, Jing Z, Hua M*
- 2021** Risk factors for myocardial injury during living donor liver transplantation in pediatric patients with biliary atresia  
*Wu YL, Li TY, Gong XY, Che L, Sheng MW, Yu WL, Weng YQ*

**Observational Study**

- 2032** Comparative detection of syndecan-2 methylation in preoperative and postoperative stool DNA in patients with colorectal cancer  
*Song JH, Oh TJ, An S, Lee KH, Kim JY, Kim JS*

**Prospective Study**

- 2042** Preoperative prediction of microvascular invasion in hepatocellular carcinoma using ultrasound features including elasticity  
*Jiang D, Qian Y, Tan BB, Zhu XL, Dong H, Qian R*
- 2052** Quantitative evaluation of colorectal tumour vasculature using contrast-enhanced ultrasound: Correlation with angiogenesis and prognostic significance  
*Li MH, Li WW, He L, Li JF, Zhang SY*

**CASE REPORT**

- 2063** Laparoscopy-assisted gastrectomy for advanced gastric cancer patients with situs inversus totalis: Two case reports and review of literature  
*Liu HB, Cai XP, Lu Z, Xiong B, Peng CW*
- 2074** Acute flare of systemic lupus erythematosus with extensive gastrointestinal involvement: A case report and review of literature  
*Huang H, Li P, Zhang D, Zhang MX, Yu K*
- 2083** Surgical management of gallstone ileus after one anastomosis gastric bypass: A case report  
*El Feghali E, Akel R, Chamaa B, Kazan D, Chakhtoura G*
- 2089** Dual transformation therapy for giant hepatocellular carcinoma: Two case reports and review of literature  
*Gao Q, Zhu GZ, Han CY, Ye XP, Huang HS, Mo ST, Peng T*

**ABOUT COVER**

Editorial Board Member of *World Journal of Gastrointestinal Surgery*, Sung Uk Bae, MD, PhD, Associate Professor, Department of Surgery, Keimyung University Dongsan Hospital, Daegu 42601, South Korea.  
sabiston0000@hanmail.net

**AIMS AND SCOPE**

The primary aim of *World Journal of Gastrointestinal Surgery* (WJGS, *World J Gastrointest Surg*) is to provide scholars and readers from various fields of gastrointestinal surgery with a platform to publish high-quality basic and clinical research articles and communicate their research findings online.

WJGS mainly publishes articles reporting research results and findings obtained in the field of gastrointestinal surgery and covering a wide range of topics including biliary tract surgical procedures, biliopancreatic diversion, colectomy, esophagectomy, esophagostomy, pancreas transplantation, and pancreatectomy, etc.

**INDEXING/ABSTRACTING**

The WJGS is now abstracted and indexed in Science Citation Index Expanded (SCIE, also known as SciSearch®), Current Contents/Clinical Medicine, Journal Citation Reports/Science Edition, PubMed, PubMed Central, Reference Citation Analysis, China National Knowledge Infrastructure, China Science and Technology Journal Database, and Superstar Journals Database. The 2023 Edition of Journal Citation Reports® cites the 2022 impact factor (IF) for WJGS as 2.0; IF without journal self cites: 1.9; 5-year IF: 2.2; Journal Citation Indicator: 0.52; Ranking: 113 among 212 journals in surgery; Quartile category: Q3; Ranking: 81 among 93 journals in gastroenterology and hepatology; and Quartile category: Q4.

**RESPONSIBLE EDITORS FOR THIS ISSUE**

Production Editor: Rui-Rui Wu; Production Department Director: Xiang Li; Editorial Office Director: Jia-Ru Fan.

**NAME OF JOURNAL**

*World Journal of Gastrointestinal Surgery*

**ISSN**

ISSN 1948-9366 (online)

**LAUNCH DATE**

November 30, 2009

**FREQUENCY**

Monthly

**EDITORS-IN-CHIEF**

Peter Schemmer

**EDITORIAL BOARD MEMBERS**

<https://www.wjgnet.com/1948-9366/editorialboard.htm>

**PUBLICATION DATE**

September 27, 2023

**COPYRIGHT**

© 2023 Baishideng Publishing Group Inc

**INSTRUCTIONS TO AUTHORS**

<https://www.wjgnet.com/bpg/gerinfo/204>

**GUIDELINES FOR ETHICS DOCUMENTS**

<https://www.wjgnet.com/bpg/GerInfo/287>

**GUIDELINES FOR NON-NATIVE SPEAKERS OF ENGLISH**

<https://www.wjgnet.com/bpg/gerinfo/240>

**PUBLICATION ETHICS**

<https://www.wjgnet.com/bpg/GerInfo/288>

**PUBLICATION MISCONDUCT**

<https://www.wjgnet.com/bpg/gerinfo/208>

**ARTICLE PROCESSING CHARGE**

<https://www.wjgnet.com/bpg/gerinfo/242>

**STEPS FOR SUBMITTING MANUSCRIPTS**

<https://www.wjgnet.com/bpg/GerInfo/239>

**ONLINE SUBMISSION**

<https://www.f6publishing.com>



Retrospective Study

# Value of enhanced computed tomography in differentiating small mesenchymal tumours of the gastrointestinal from smooth muscle tumours

Wen-Jun Nie, Zhao Jing, Mo Hua

**Specialty type:** Gastroenterology and hepatology

**Provenance and peer review:**

Unsolicited article; Externally peer reviewed.

**Peer-review model:** Single blind

**Peer-review report's scientific quality classification**

Grade A (Excellent): 0  
Grade B (Very good): B  
Grade C (Good): C  
Grade D (Fair): 0  
Grade E (Poor): 0

**P-Reviewer:** Alorro MG, Australia; Sherf-Dagan S, Israel

**Received:** June 30, 2023

**Peer-review started:** June 30, 2023

**First decision:** July 18, 2023

**Revised:** July 24, 2023

**Accepted:** August 4, 2023

**Article in press:** August 4, 2023

**Published online:** September 27, 2023



**Wen-Jun Nie, Mo Hua,** Department of Radiology, Changzhou Geriatric Hospital Affiliated to Soochow University, Changzhou No. 7 People's Hospital Radiology Department, Changzhou 213011, Jiangsu Province, China

**Zhao Jing,** Medical Area, Eastern Theater General Hospital, Qinhua District Medical Area, Nanjing 210000, Jiangsu Province, China

**Corresponding author:** Mo Hua, MD, Attending Doctor, Department of Radiology, Changzhou Geriatric Hospital Affiliated to Soochow University, Changzhou No. 7 People's Hospital Radiology Department, No. 288 Yanling East Road, Changzhou 213011, Jiangsu Province, China. [mohuafsk913044@sina.com](mailto:mohuafsk913044@sina.com)

## Abstract

### BACKGROUND

Computed tomography (CT) technology has been gradually used in the differentiation of small mesenchymal tumors of the stomach and intestines from smooth muscle tumours.

### AIM

To explore the value of enhanced CT in the differentiation of small mesenchymal tumors of the stomach and intestines from smooth muscle tumours.

### METHODS

Clinical data of patients with gastric mesenchymal or gastric smooth muscle tumours who were treated in our hospital from May 2018 to April 2023 were retrospectively analysed. Patients were divided into the gastric mesenchymal tumor group and the gastric smooth muscle tumor group respectively ( $n = 50$  cases per group). Clinical data of 50 healthy volunteers who received physical examinations in our hospital during the same period were selected and included in the control group. Serum levels of carcinoembryonic antigen (CEA), alpha-fetoprotein (AFP), carbohydrate antigen 19-9 (CA19-9), CA-125 and cytokeratin 19 fragment antigen 21-1 were compared among the three groups. The value of CEA and CA19-9 in the identification of gastric mesenchymal tumours was analysed using the receiver operating characteristic (ROC) curve. The Kappa statistic was used to analyse the consistency of the combined CEA and CA19-9 test in identifying gastric mesenchymal tumours.

## RESULTS

CEA levels varied among the three groups in the following order: The gastric mesenchymal tumour group > the control group > the gastric smooth muscle tumour group. CA19-9 levels varied among the three groups in the following order: The gastric mesenchymal group > the gastric smooth muscle group > the control group, the difference was statistically significant ( $P < 0.05$ ). ROC analysis showed that the area under the curve of CEA and CA19-9 was 0.879 and 0.782, respectively.

## CONCLUSION

Enhanced CT has shown value in differentiating small mesenchymal tumors of the stomach and intestines from smooth muscle tumors.

**Key Words:** Smooth muscle tumour; Stomach; Intestines; Differentiation

©The Author(s) 2023. Published by Baishideng Publishing Group Inc. All rights reserved.

**Core Tip:** Endoscopic ultrasound can accurately localise the lesion characteristics, and there are significant differences in the echogenic characteristics of intragastric mesenchymal tumours and smooth muscle tumours. In view of the fact that early metastases can occur in gastrointestinal mesenchymal tumours of less than 2 cm in diameter, endoscopic resection is recommended for the definitive diagnosis and simultaneous treatment or closer follow-up of intrinsic mesenchymal tumours with a clear echogenic border and less than 2 cm in diameter.

**Citation:** Nie WJ, Jing Z, Hua M. Value of enhanced computed tomography in differentiating small mesenchymal tumours of the gastrointestinal from smooth muscle tumours. *World J Gastrointest Surg* 2023; 15(9): 2012-2020

**URL:** <https://www.wjgnet.com/1948-9366/full/v15/i9/2012.htm>

**DOI:** <https://dx.doi.org/10.4240/wjgs.v15.i9.2012>

## INTRODUCTION

Gastric cancer is one of the most common malignancies and is among the top three leading causes of cancer-related deaths worldwide[1-11]. According to the Japanese Classification Criteria for Gastric Cancer, early gastric cancer is defined as a lesion in which tumour infiltration is limited to the mucosa or submucosa without consideration of lymph node metastasis (LNM)[12]. In recent years, with the development of endoscopic techniques, endoscopic submucosal dissection (ESD) has been widely used for the treatment of early gastric cancer without LNM, and the indications for ESD in early gastric cancer published by the Japan Gastric Cancer Association classify gastric cancer into differentiated and undifferentiated types[13]. Gastrointestinal mesenchymal tumours (GIMTs), as a mesenchymal-derived tumour with specific histological features, are mainly located in the gastrointestinal tract and abdominal cavity and have a certain chance of malignant transformation and are therefore often diagnosed and treated differently from gastric smooth muscle tumours in clinical practice[14-20].

Although previous clinical reports have shown that GIMTs are rare[21], recent epidemiological studies have shown that 10%-30% of patients with GIMTs have no obvious clinical symptoms, but 15%-50% of patients may have metastases to the liver and abdominal cavity once detected, missing the best time for treatment. Currently, the clinical diagnosis of GIMTs mainly relies on imaging and pathology; however, imaging methods such as ultrasound endoscopy and computed tomography (CT) are influenced by the operator's experience and image quality, and cannot accurately determine the nature of the lesion. Besides, the pathological examination requires endoscopy or surgery to obtain the pathological tissue, which is invasive and painful for patients, and pathological examination is not real-time[22-27]. As a convenient and common clinical test, CT has been widely used in the diagnosis, efficacy and prognosis of clinical tumors, and can be used for the identification of GIMTs[28]. Herein, we retrospectively analysed the clinical data of patients (volunteers) who received treatment or health check-ups in our hospital in recent years and investigated the value of CT in the differential diagnosis of patients with gastric mesenchymal tumours and gastric smooth muscle tumours.

## MATERIALS AND METHODS

### General information

The clinical data of patients with gastric mesenchymal or gastric smooth muscle tumours who were treated in our hospital from May 2018 to April 2023 were retrospectively analyzed. Patients were divided into the gastric mesenchymal tumor group and the gastric smooth muscle tumor group respectively ( $n = 50$  cases per group). Clinical data of 50 healthy volunteers who underwent physical examination in the same hospital during the same period were selected and included in the control group. The gastric mesenchymal tumor group included 24 males and 26 females, aged 38 to 72 years (mean

age:  $56.73 \pm 7.46$  years) and with a body mass index (BMI) of 18–24 kg/m<sup>2</sup> (mean BMI:  $21.76 \pm 2.21$  kg/m<sup>2</sup>). The gastric smooth muscle tumor group included 22 males and 28 females, aged 36 to 71 years (mean age:  $57.11 \pm 7.18$  years) and with a BMI of 18–24 kg/m<sup>2</sup> (mean BMI:  $21.89 \pm 2.14$  kg/m<sup>2</sup>). The control group included 21 males and 29 females, aged 38–70 years (mean age:  $55.82 \pm 7.39$  years) and with a BMI of 18–24 kg/m<sup>2</sup> (mean BMI:  $21.76 \pm 2.21$  kg/m<sup>2</sup>). The differences between the three groups were not statistically significant ( $P > 0.05$ ) and were comparable. Confidentiality of all patient information was maintained in this study.

### Inclusion criteria

Inclusion criteria including: (1) Patients with gastric mesenchymal tumour or gastric smooth muscle tumour, all confirmed by postoperative pathological histology, healthy volunteers with no significant abnormalities by gastric ultrasound; (2) 42–72 years old; and (3) Complete clinical data of patients (or volunteers).

### Exclusion criteria

Exclusion criteria including: (1) Organic heart, liver, or kidney dysfunction; (2) Patients with combined cancer of other tissues or a history of radiotherapy; (3) Unable to participate in this study due to psychiatric illness or other reasons; (4) Combined coagulation disorders or autoimmune diseases; and (5) A history of gastrectomy.

### Methodology

Approximately 5 mL of fasting venous blood was collected from all patients (or volunteers) during the preoperative examination, centrifuged and stored at  $-80^{\circ}\text{C}$ , and the serum levels of carcinoembryonic antigen (CEA), alpha-fetoprotein (AFP), carbohydrate antigen 19-9 (CA19-9), CA-125 and cytokeratin 19 fragment antigen 21-1 (CYFRA21-1) were measured by electrochemiluminescence. The immunoassay was performed using relevant kits on a Beckman Coulter AU5800 fully automated biochemical analyzer (Beckman, United States).

### Observation indicators

Serum levels of CEA, AFP, CA19-9, CA-125 and CYFRA21-1 levels were compared among the three groups. The value of CEA and CA19-9 in identifying gastric mesenchymal tumours was analysed using the receiver operating characteristic (ROC) curve. The ROC curves of CEA and CA19-9 in identifying gastric mesenchymal tumours were plotted separately based on the pathological results of the patients. The area of the lower curve for each measure was calculated, and the area of the lower curve  $> 0.5$  indicated that the measure had diagnostic efficacy, and the closer it was to 1, the higher its diagnostic efficacy.

### Statistical methods

All data were processed using SPSS 22.0 statistical software and were expressed as mean  $\pm$  standard deviation (mean  $\pm$  SD) or percentages (%). The  $\chi^2$  test was used to analyze categorical variables. One-way ANOVA was used to compare multiple groups. The ROC curve was used to analyze the value of CEA and CA19-9 in the diagnosis of gastric mesenchymal tumours. The Kappa test was used for consistency.

## RESULTS

### Gastric mesenchymal and smooth muscle tumours on plain gastroscopy and endoscopic ultrasound

Both intragastric mesenchymal tumours and smooth muscle tumours were found in the fundus and body of the stomach, with no statistically significant difference in the distribution of lesions ( $P = 0.32$ ). The diameter of mesenchymal tumours was larger than that of smooth muscle tumours, and the difference was statistically significant ( $P < 0.05$ ). Both mesenchymal and smooth muscle tumours were smooth, erosive, or ulcerated in surface morphology, with no statistically significant difference ( $P = 0.61$ ). The intrinsic muscular layer and the mucosal muscular layer were the most common sites of origin for both mesenchymal tumours and smooth muscle tumours. The difference was not statistically significant ( $P = 1.0$ ). At endoscopic ultrasound (EUS), mesenchymal tumours appeared as hypoechoic lesions and smooth muscle tumours appeared as hypoechoic and isoechoic lesions. In terms of echogenicity, the echogenic non-uniformity of mesenchymal tumours was more pronounced than that of smooth muscle tumours ( $P < 0.05$ ) see [Table 1](#).

### Comparison of the levels of each tumour marker among the three groups

CEA levels varied among the three groups in the following order: The gastric mesenchymal tumour group  $>$  the control group  $>$  the gastric smooth muscle tumour group. CA19-9 levels varied among the three groups in the following order: The gastric mesenchymal group  $>$  the gastric smooth muscle group  $>$  the control group, the differences were statistically significant ( $P < 0.05$ ) see [Table 2](#).

### ROC curve analysis of CEA and CA19-9 levels for the identification of gastric mesenchymal tumours

The area under the curve (AUC) for the identification of gastric mesenchymal tumours by CEA and CA19-9 was 0.879 and 0.782, respectively ([Table 3](#)). The ROC curves for the identification of gastric mesenchymal tumours by CEA and CA19-9 are shown in [Figure 1](#).

**Table 1 Gastric mesenchymal and smooth muscle tumours on plain gastroscopy and endoscopic ultrasound**

Clinical parameters	Intragastric mesenchymal tumour	Smooth muscle tumour
Male	24 (48.0)	22 (44.0)
Female	26 (52.0)	28 (56.0)
Age, yr	50.5 ± 14.0 <sup>a</sup>	57.9 ± 9.5
Location, %		
Cardia	0	1 (2.0)
Gastric base	26 (52.0)	12 (24.0)
Gastric body	18 (36.0)	11 (22.0)
Gastric sinus	9 (18.0)	2 (4.0)
Diameter, mm	16.2 ± 9.9 <sup>a</sup>	9.7 ± 5.0
Level of origin, %		
Mucosal muscle layer	2 (3.8)	1 (2.0)
Inherent muscle layer	48 (96.0)	25 (50.0)
Indicated ulcers, %		
Yes	6 (12.0)	2 (4.0)
None	47 (94.0)	24 (48.0)
Echo characteristics, %		
Low echo	50 (100)	47 (94.0)
Waiting for an echo	0	1 (2.0)
High echo		0
Echo uniformity, %		
Uniformity	25 (49.1) <sup>a</sup>	50 (100)
Non-homogeneous	27 (50.0) <sup>a</sup>	0

<sup>a</sup>*P* < 0.05 compared with the gastric mesenchymal tumour group.**Table 2 Comparison of tumour marker levels among the three groups (mean ± SD)**

Group	<i>n</i>	CEA (ng/mL)	CA19-9 (ng/mL)	CA-125 (kU/L)	AFP (ng/mL)	CYFRA21-1 (U/mL)
Gastric mesenchymal tumour group	50	1.53 ± 0.24	9.32 ± 2.18	44.34 ± 10.67	5.46 ± 1.18	8.17 ± 1.57
Gastric smooth muscle tumour group	50	0.67 ± 0.15 <sup>a</sup>	8.37 ± 1.81 <sup>a</sup>	41.56 ± 8.74	5.03 ± 0.86	7.44 ± 1.69
Control group	50	1.04 ± 0.18 <sup>a,b</sup>	6.45 ± 1.39 <sup>a,b</sup>	39.67 ± 7.98	5.29 ± 0.74	7.67 ± 1.88
<i>F</i> value		198.507	25.753	2.608	2.100	1.888
<i>P</i> value		0.000	0.000	0.078	0.127	0.156

<sup>a</sup>*P* < 0.05 compared with the gastric mesenchymal tumour group.<sup>b</sup>*P* < 0.05 compared with the gastric smooth muscle group.

CEA: Carcinoembryonic antigen; CA19-9: Carbohydrate antigen 19-9; CA-125: Carbohydrate antigen 125; AFP: Alpha-fetoprotein; CYFRA21-1: Cytokeratin 19 fragment antigen 21-1.

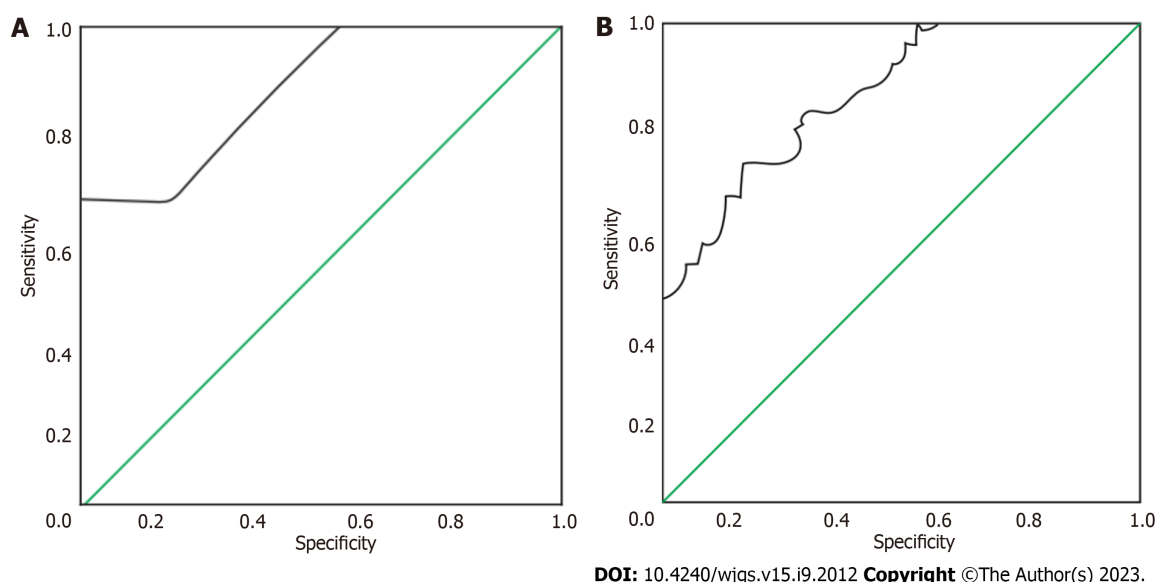
## DISCUSSION

The treatment methods for GIMTs have been rapidly changing with the development of medical treatment technology in recent years, and there are various methods commonly used for differential diagnosis in clinical practice[29-35]. However, the sensitivity of single tumour markers is low, and there is a certain degree of underdiagnosis; thus, combined detection of tumour markers is necessary for the diagnosis of GIMTs[36]. The present study analysed the expression of

**Table 3 Receiver operating characteristic curve analysis of carcinoembryonic antigen and carbohydrate antigen 19-9 levels for the diagnosis of gastric mesenchymal tumour**

Indicators	Area under the curve	Standard error	P value	95%CI	Optimal cut-off value	Sensitivity	Specificity
CEA	0.879	0.036	0.000	0.808-0.950	1.145	0.850	0.675
CA19-9	0.782	0.050	0.000	0.684-0.880	8.880	0.600	0.800

CEA: Carcinoembryonic antigen; CA19-9: Carbohydrate antigen 19-9.



DOI: 10.4240/wjgs.v15.i9.2012 Copyright ©The Author(s) 2023.

**Figure 1 Receiver operating characteristic curve for the diagnosis of gastric mesenchymal tumour.** A: Carcinoembryonic antigen; B: Carbohydrate antigen 19-9.

CEA, AFP, CA19-9, CA-125 and CYFRA21-1 in patients with gastric mesenchymal and smooth muscle tumours to provide a reference for clinical diagnosis. The results showed that CEA levels varied among the three groups in the following order: The gastric mesenchymal tumour group > control group > gastric smooth muscle tumour group, and CA19-9 levels varied in the following order: The gastric mesenchymal tumour group > gastric smooth muscle group > control group, suggesting that CEA and CA19-9 were differentially expressed in patients (or volunteers) with different gastric lesions. Tumour markers are chemical substances that reflect the presence of tumours and are synthesised and released by tumour cells during tumorigenesis and proliferation or are important for the host's responsiveness to cancer [37]. Their formation or change in expression in the blood can indicate the nature of the tumour and thus help the clinician to understand their role in tumour histogenesis, cell differentiation and cell function. Common tumour markers can be classified into embryonic antigens, glycoproteins, kinins, enzymes and oncogene products according to their composition, with CEA being a protein and CA19-9 and CA-125 being glycoantigens[38].

Mesenchymal and smooth muscle tumours are the predominant mesenchymal-derived tumours of the gastrointestinal tract and the most common cause of submucosal lesions. Mesenchymal tumours originate from the interstitial cells of Cajal or mesenchymal stem cells in the gastrointestinal tract. It is currently thought that mutations in the C-kit or platelet-derived growth factor receptor A gene activation are important causes of mesenchymal tumours. Mesenchymal tumours are characterised by dynamic non-directional differentiation and potential malignancy, and even mesenchymal tumours with very low malignant potential may metastasise[39].

Pathological examination and immunohistochemistry are the gold standard for differentiating mesenchymal tumours from smooth muscle tumours. EUS is a non-invasive method that can assist in the diagnosis of the nature of the lesion and the choice of treatment by observing the level of origin, size and echogenicity of the lesion. The identification of the differences by comparing EUS features of intragastric mesenchymal tumours with those of smooth muscle tumours may spare patients with smooth muscle tumours from undergoing resection, while smaller diameter mesenchymal tumours may be diagnosed early, and intervention may be possible.

The data from this study show that mesenchymal tumours are more common than smooth leiomyosarcomas in the augmentation of the stomach, which is consistent with the finding in national studies[40-43]. Both appear as round or oval submucosal masses on plain endoscopy, with some visible surface erosions or ulcers, making differential diagnosis difficult. On EUS, mesenchymal tumours are usually of intramucosal origin, with a few originating in the mucosal layer, and appear as round or oval masses, which may be homogeneously hypoechoic, heterogeneously echogenic or hype-

rechoic with hyperechogenicity. A careful analysis of the endoscopic features of the two tumours revealed no statistically significant differences in the distribution of lesions within the stomach or in the level of origin. In terms of tumour size, the diameter of the mesenchymal tumour was larger than that of the smooth muscle tumour, and the difference was statistically significant. Surface ulceration is an important criterion for differentiating benign and malignant GIMTs, and is often used as a criterion for differentiating mesenchymal tumours from smooth muscle tumours[44]. However, our study found no statistically significant difference between mesenchymal and smooth muscle tumours. The difference in internal echogenicity was statistically significant, particularly in the presence of hyperechoic hyperechogenicity, which was only observed in mesenchymal tumours and not in smooth muscle tumours. The greater the difference in the density between the two sides of the interface and the faster the speed of sound, the higher the acoustic impedance and the echogram signal.

Therefore, the number of cells, their tight arrangement, the presence of liquefied necrosis, calcification and the amount of fibrous cell content are the factors that make up the ultrasound interface and the pathological basis of the ultrasound image in submucosal tumours. As previously discussed, mesenchymal tumours are richer in cells, more variable in their morphology and arrangement and more likely to undergo secondary changes than smooth muscle tumours, leading to differences in their echogenic characteristics.

## CONCLUSION

In summary, EUS can accurately localise lesion characteristics, and there are significant differences in the echogenic characteristics of intragastric mesenchymal and smooth muscle tumours. Since early metastases can occur in GIMTs of less than 2 cm in diameter, endoscopic resection is recommended for the definitive diagnosis and simultaneous treatment or closer follow-up of intrinsic mesenchymal tumours with a clear echogenic border and less than 2 cm in diameter. The diagnosis of smooth muscle tumour is more likely for lesions with homogeneous echogenicity, well-defined borders and an intrinsic muscle layer of less than 2 cm in diameter, and patients can be advised to follow up. Overall, EUS can provide a strong basis for differentiating mesenchymal and smooth muscle tumours of less than 2 cm in diameter in the stomach and for clinical decision-making.

## ARTICLE HIGHLIGHTS

### Research background

With the development of computed tomography technology, the differentiation of small mesenchymal tumors of the stomach and intestines from for smooth muscle tumors has been gradually used in this method.

### Research motivation

To retrospectively analyze the clinical data of patients with gastric mesenchymal tumor and gastric smooth muscle tumor treated in our hospital from May 2018 to April 2023, and include them into the gastric mesenchymal tumor group and the gastric smooth muscle tumor group respectively, both groups consisted of 50 cases, and the clinical data of 50 healthy volunteers who received physical examination in our hospital during the same period were selected and included into the control group; to compare the serum carcinoembryonic antigen (CEA), alpha-fetoprotein, carbohydrate antigen 19-9 (CA19-9).

### Research objectives

The Kappa test was used to analyse the consistency of the combined CEA and CA19-9 test in identifying gastric mesenchymal tumours.

### Research methods

Clinical data of patients with gastric mesenchymal or gastric smooth muscle tumours who were treated in our hospital from May 2018 to April 2023 were retrospectively analysed. The value of CEA and CA19-9 in the identification of gastric mesenchymal tumours was analysed using the receiver operating characteristic curve.

### Research results

When comparing the CEA levels of the three groups, the gastric mesenchymal tumour group > the control group > the gastric smooth muscle tumour group; when comparing the CA19-9 levels of the three groups, the gastric mesenchymal group > the gastric smooth muscle group > the control group, the difference was statistically significant ( $P < 0.05$ ). The area under the curve of CEA and CA19-9 was 0.879 and 0.782, respectively, by receiver operating characteristic analysis.

### Research conclusions

We proposed the theory of nodular and vesicle types domestically through observation, and made breakthroughs in overcoming the issue of inaccurate diagnosis based on a few independent early-stage case reports.

## Research perspectives

According to the different partings under endoscopy, the clinical symptoms, therapeutic efficacy, and prognosis of patients with primary enteric lymphangiectasis were observed.

## FOOTNOTES

**Author contributions:** Nie WJ and Hua M contributed equally to this work; Hua M designed the study; Zhao J contributed to the analysis of the manuscript; Nie WJ and Hua M were involved in the data and writing of this article; and all authors have read and approved the final manuscript.

**Institutional review board statement:** The study was reviewed and approved by the (Changzhou Geriatric Hospital Affiliated to Soochow University, Changzhou No. 7 People's Hospital Radiology Department) Institutional Review Board.

**Informed consent statement:** All study participants and their legal guardians provide informed written consent before the study recruitment.

**Conflict-of-interest statement:** All the authors report no relevant conflicts of interest for this article.

**Data sharing statement:** No additional data are available.

**Open-Access:** This article is an open-access article that was selected by an in-house editor and fully peer-reviewed by external reviewers. It is distributed in accordance with the Creative Commons Attribution NonCommercial (CC BY-NC 4.0) license, which permits others to distribute, remix, adapt, build upon this work non-commercially, and license their derivative works on different terms, provided the original work is properly cited and the use is non-commercial. See: <https://creativecommons.org/licenses/by-nc/4.0/>

**Country/Territory of origin:** China

**ORCID number:** Wen-Jun Nie 0009-0005-7627-2621; Mo Hua 0009-0006-4489-3391.

**S-Editor:** Wang JJ

**L-Editor:** A

**P-Editor:** Wang JJ

## REFERENCES

- Miettinen M, Lasota J. Gastrointestinal stromal tumors: review on morphology, molecular pathology, prognosis, and differential diagnosis. *Arch Pathol Lab Med* 2006; **130**: 1466-1478 [PMID: 17090188 DOI: 10.5858/2006-130-1466-GSTROM]
- Xing JJ, Huang WP, Wang F, Chai YR, Gao JB. Computed tomography features and clinicopathological characteristics of gastric glomus tumor. *BMC Gastroenterol* 2022; **22**: 174 [PMID: 35397495 DOI: 10.1186/s12876-022-02241-w]
- Papanikolaou IS, Triantafyllou K, Kourikou A, Rösch T. Endoscopic ultrasonography for gastric submucosal lesions. *World J Gastrointest Endosc* 2011; **3**: 86-94 [PMID: 21772939 DOI: 10.4253/wjge.v3.i5.86]
- Jo VY, Doyle LA. Refinements in Sarcoma Classification in the Current 2013 World Health Organization Classification of Tumours of Soft Tissue and Bone. *Surg Oncol Clin N Am* 2016; **25**: 621-643 [PMID: 27591490 DOI: 10.1016/j.soc.2016.05.001]
- Tanaka J, Oshima T, Hori K, Tomita T, Kim Y, Watari J, Oh K, Hirota S, Matsumoto T, Miwa H. Small gastrointestinal stromal tumor of the stomach showing rapid growth and early metastasis to the liver. *Dig Endosc* 2010; **22**: 354-356 [PMID: 21175497 DOI: 10.1111/j.1443-1661.2010.01032.x]
- Virani N, Pang J, Lew M. Cytologic and Immunohistochemical Evaluation of Low-Grade Spindle Cell Lesions of the Gastrointestinal Tract. *Arch Pathol Lab Med* 2016; **140**: 1038-1044 [PMID: 27684974 DOI: 10.5858/arpa.2016-0235-RA]
- Kudo M. Immuno-Oncology Therapy for Hepatocellular Carcinoma: Current Status and Ongoing Trials. *Liver Cancer* 2019; **8**: 221-238 [PMID: 31602367 DOI: 10.1159/000501501]
- Vij M, Agrawal V, Kumar A, Pandey R. Gastrointestinal stromal tumors: a clinicopathological and immunohistochemical study of 121 cases. *Indian J Gastroenterol* 2010; **29**: 231-236 [PMID: 21221881 DOI: 10.1007/s12664-010-0079-z]
- Miura H, Tanaka K, Umeda Y, Ikenoyama Y, Yukimoto H, Hamada Y, Yamada R, Tsuboi J, Nakamura M, Katsurahara M, Horiki N, Nakagawa H. Usefulness of magnifying endoscopy with acetic acid and narrow-band imaging for the diagnosis of duodenal neoplasms: proposal of a diagnostic algorithm. *Surg Endosc* 2022; **36**: 8086-8095 [PMID: 35449476 DOI: 10.1007/s00464-022-09239-1]
- Hirano K, Nagata A, Akahane K, Yonekura H, Tomioka I, Kobayashi T, Kawa S, Shimakura K, Oguchi H, Furuta S. [Clinical significance of the fecal chymotrypsin test in chronic pancreatitis--comparative study of its value with the pancreozymin-secretin test, PFD test, and endoscopic retrograde pancreatography]. *Nihon Shokakibyo Gakkai Zasshi* 1985; **82**: 2964-2972 [PMID: 3831448]
- Sakamoto H, Kitano M, Kudo M. Diagnosis of subepithelial tumors in the upper gastrointestinal tract by endoscopic ultrasonography. *World J Radiol* 2010; **2**: 289-297 [PMID: 21160683 DOI: 10.4329/wjr.v2.i8.289]
- Akahoshi K, Oya M, Koga T, Shiratsuchi Y. Current clinical management of gastrointestinal stromal tumor. *World J Gastroenterol* 2018; **24**: 2806-2817 [PMID: 30018476 DOI: 10.3748/wjg.v24.i26.2806]
- Akahoshi K, Sumida Y, Matsui N, Oya M, Akinaga R, Kubokawa M, Motomura Y, Honda K, Watanabe M, Nagaie T. Preoperative diagnosis of gastrointestinal stromal tumor by endoscopic ultrasound-guided fine needle aspiration. *World J Gastroenterol* 2007; **13**: 2077-2082 [PMID: 17090188 DOI: 10.5858/2006-130-1466-GSTROM]

- 17465451 DOI: [10.3748/wjg.v13.i14.2077](https://doi.org/10.3748/wjg.v13.i14.2077)]
- 14 **Levy MJ**, Jondal ML, Clain J, Wiersema MJ. Preliminary experience with an EUS-guided trucut biopsy needle compared with EUS-guided FNA. *Gastrointest Endosc* 2003; **57**: 101-106 [PMID: [12518144](https://pubmed.ncbi.nlm.nih.gov/12518144/) DOI: [10.1067/mge.2003.49](https://doi.org/10.1067/mge.2003.49)]
  - 15 **Xiu H**, Zhao CY, Liu FG, Sun XG, Sun H, Liu XS. Comparing about three types of endoscopic therapy methods for upper gastrointestinal submucosal tumors originating from the muscularis propria layer. *Scand J Gastroenterol* 2019; **54**: 1481-1486 [PMID: [31814460](https://pubmed.ncbi.nlm.nih.gov/31814460/) DOI: [10.1080/00365521.2019.1692064](https://doi.org/10.1080/00365521.2019.1692064)]
  - 16 **Gheorghe G**, Bacalbasa N, Ceobanu G, Ilie M, Enache V, Constantinescu G, Bungau S, Diaconu CC. Gastrointestinal Stromal Tumors-A Mini Review. *J Pers Med* 2021; **11** [PMID: [34442339](https://pubmed.ncbi.nlm.nih.gov/34442339/) DOI: [10.3390/jpm11080694](https://doi.org/10.3390/jpm11080694)]
  - 17 **Fernandes MR**, Ghezzi CLA, Grezzana-Filho TJ, Feier FH, Leipnitz I, Chedid AD, Cerski CTS, Chedid MF, Kruel CRP. Giant hepatic extra-gastrointestinal stromal tumor treated with cytoreductive surgery and adjuvant systemic therapy: A case report and review of literature. *World J Gastrointest Surg* 2021; **13**: 315-322 [PMID: [33796218](https://pubmed.ncbi.nlm.nih.gov/33796218/) DOI: [10.4240/wjgs.v13.i3.315](https://doi.org/10.4240/wjgs.v13.i3.315)]
  - 18 **Kim HJ**, Park JY, Kim BJ, Kim JG, Kim HS, Park JM. Gastric Gastrointestinal Stromal Tumor with Repeated Recurrence at the Anastomosis Site in a Very Elderly Patient. *Korean J Gastroenterol* 2020; **76**: 206-210 [PMID: [33100316](https://pubmed.ncbi.nlm.nih.gov/33100316/) DOI: [10.4166/kjg.2020.76.4.206](https://doi.org/10.4166/kjg.2020.76.4.206)]
  - 19 **Martínez-Cambor P**, Pardo-Fernández JC. Smooth time-dependent receiver operating characteristic curve estimators. *Stat Methods Med Res* 2018; **27**: 651-674 [PMID: [29187044](https://pubmed.ncbi.nlm.nih.gov/29187044/) DOI: [10.1177/0962280217740786](https://doi.org/10.1177/0962280217740786)]
  - 20 **Chiu PWY**, Yip HC, Teoh AYB, Wong VWY, Chan SM, Wong SKH, Ng EKW. Per oral endoscopic tumor (POET) resection for treatment of upper gastrointestinal subepithelial tumors. *Surg Endosc* 2019; **33**: 1326-1333 [PMID: [30604266](https://pubmed.ncbi.nlm.nih.gov/30604266/) DOI: [10.1007/s00464-018-06627-4](https://doi.org/10.1007/s00464-018-06627-4)]
  - 21 **Mekras A**, Krenn V, Perrakis A, Croner RS, Kalles V, Atamer C, Grützmann R, Vassos N. Gastrointestinal schwannomas: a rare but important differential diagnosis of mesenchymal tumors of gastrointestinal tract. *BMC Surg* 2018; **18**: 47 [PMID: [30045739](https://pubmed.ncbi.nlm.nih.gov/30045739/) DOI: [10.1186/s12893-018-0379-2](https://doi.org/10.1186/s12893-018-0379-2)]
  - 22 **Roberto GA**, Rodrigues CMB, Peixoto RD, Younes RN. Gastric neuroendocrine tumor: A practical literature review. *World J Gastrointest Oncol* 2020; **12**: 850-856 [PMID: [32879663](https://pubmed.ncbi.nlm.nih.gov/32879663/) DOI: [10.4251/wjgo.v12.i8.850](https://doi.org/10.4251/wjgo.v12.i8.850)]
  - 23 **Balakrishnan M**, George R, Sharma A, Graham DY. Changing Trends in Stomach Cancer Throughout the World. *Curr Gastroenterol Rep* 2017; **19**: 36 [PMID: [28730504](https://pubmed.ncbi.nlm.nih.gov/28730504/) DOI: [10.1007/s11894-017-0575-8](https://doi.org/10.1007/s11894-017-0575-8)]
  - 24 **Japanese Gastric Cancer Association**. Japanese classification of gastric carcinoma: 3rd English edition. *Gastric Cancer* 2011; **14**: 101-112 [PMID: [21573743](https://pubmed.ncbi.nlm.nih.gov/21573743/) DOI: [10.1007/s10120-011-0041-5](https://doi.org/10.1007/s10120-011-0041-5)]
  - 25 **Rausei S**, Dionigi G, Boni L. Evaluation of the Seventh American Joint Committee on Cancer/International Union Against Cancer Classification of gastric adenocarcinoma in comparison with the sixth classification. *Cancer* 2011; **117**: 2823-4; author reply 2824 [PMID: [21264825](https://pubmed.ncbi.nlm.nih.gov/21264825/) DOI: [10.1002/cncr.25801](https://doi.org/10.1002/cncr.25801)]
  - 26 **Seo HS**, Lee GE, Kang MG, Han KH, Jung ES, Song KY. Mixed Histology Is a Risk Factor for Lymph Node Metastasis in Early Gastric Cancer. *J Surg Res* 2019; **236**: 271-277 [PMID: [30694766](https://pubmed.ncbi.nlm.nih.gov/30694766/) DOI: [10.1016/j.jss.2018.11.055](https://doi.org/10.1016/j.jss.2018.11.055)]
  - 27 **Takizawa K**, Ono H, Kakushima N, Tanaka M, Hasuike N, Matsubayashi H, Yamaguchi Y, Bando E, Terashima M, Kusafuka K, Nakajima T. Risk of lymph node metastases from intramucosal gastric cancer in relation to histological types: how to manage the mixed histological type for endoscopic submucosal dissection. *Gastric Cancer* 2013; **16**: 531-536 [PMID: [23192620](https://pubmed.ncbi.nlm.nih.gov/23192620/) DOI: [10.1007/s10120-012-0220-z](https://doi.org/10.1007/s10120-012-0220-z)]
  - 28 **Russel SM**, Geraghty JR, Renaldi H, Thompson TM, Hirshfield LE. Training for Professional Uncertainty: Socialization of Medical Students Through the Residency Application Process. *Acad Med* 2021; **96**: S144-S150 [PMID: [34348371](https://pubmed.ncbi.nlm.nih.gov/34348371/) DOI: [10.1097/ACM.0000000000004303](https://doi.org/10.1097/ACM.0000000000004303)]
  - 29 **Santiago JM**, Sasako M, Osorio J. [TNM-7th edition 2009 (UICC/AJCC) and Japanese Classification 2010 in Gastric Cancer. Towards simplicity and standardisation in the management of gastric cancer]. *Cir Esp* 2011; **89**: 275-281 [PMID: [21256476](https://pubmed.ncbi.nlm.nih.gov/21256476/) DOI: [10.1016/j.ciresp.2010.10.011](https://doi.org/10.1016/j.ciresp.2010.10.011)]
  - 30 **Japanese Gastric Cancer Association**. Japanese gastric cancer treatment guidelines 2018 (5th edition). *Gastric Cancer* 2021; **24**: 1-21 [PMID: [32060757](https://pubmed.ncbi.nlm.nih.gov/32060757/) DOI: [10.1007/s10120-020-01042-y](https://doi.org/10.1007/s10120-020-01042-y)]
  - 31 **Ikeguchi M**, Murakami D, Kanaji S, Ohro S, Maeta Y, Yamaguchi K, Tatebe S, Kondo A, Tsujitani S, Kaibara N. Lymph node metastasis of gastric cancer: comparison of Union International Contra Cancer and Japanese systems. *ANZ J Surg* 2004; **74**: 852-854 [PMID: [15456431](https://pubmed.ncbi.nlm.nih.gov/15456431/) DOI: [10.1111/j.1445-1433.2004.03188.x](https://doi.org/10.1111/j.1445-1433.2004.03188.x)]
  - 32 **Gotoda T**, Yanagisawa A, Sasako M, Ono H, Nakanishi Y, Shimoda T, Kato Y. Incidence of lymph node metastasis from early gastric cancer: estimation with a large number of cases at two large centers. *Gastric Cancer* 2000; **3**: 219-225 [PMID: [11984739](https://pubmed.ncbi.nlm.nih.gov/11984739/) DOI: [10.1007/pl00011720](https://doi.org/10.1007/pl00011720)]
  - 33 **Park HK**, Lee KY, Yoo MW, Hwang TS, Han HS. Mixed Carcinoma as an Independent Prognostic Factor in Submucosal Invasive Gastric Carcinoma. *J Korean Med Sci* 2016; **31**: 866-872 [PMID: [27247494](https://pubmed.ncbi.nlm.nih.gov/27247494/) DOI: [10.3346/jkms.2016.31.6.866](https://doi.org/10.3346/jkms.2016.31.6.866)]
  - 34 **Yang S**, Gu X, Tao R, Huo J, Hu Z, Sun F, Ni J, Wang X. Relationship between histological mixed-type early gastric cancer and lymph node metastasis: A systematic review and meta-analysis. *PLoS One* 2022; **17**: e0266952 [PMID: [35427370](https://pubmed.ncbi.nlm.nih.gov/35427370/) DOI: [10.1371/journal.pone.0266952](https://doi.org/10.1371/journal.pone.0266952)]
  - 35 **Yang P**, Zheng XD, Wang JM, Geng WB, Wang X. Undifferentiated-predominant mixed-type early gastric cancer is more aggressive than pure undifferentiated type: a systematic review and meta-analysis. *BMJ Open* 2022; **12**: e054473 [PMID: [35393309](https://pubmed.ncbi.nlm.nih.gov/35393309/) DOI: [10.1136/bmjopen-2021-054473](https://doi.org/10.1136/bmjopen-2021-054473)]
  - 36 **Song KY**, Hyung WJ, Kim HH, Han SU, Cho GS, Ryu SW, Lee HJ, Kim MC; Korean Laparoscopic Gastrointestinal Surgery Study (KLASS) Group. Is gastrectomy mandatory for all residual or recurrent gastric cancer following endoscopic resection? A large-scale Korean multi-center study. *J Surg Oncol* 2008; **98**: 6-10 [PMID: [18521830](https://pubmed.ncbi.nlm.nih.gov/18521830/) DOI: [10.1002/jso.21074](https://doi.org/10.1002/jso.21074)]
  - 37 **Ryu KW**, Choi IJ, Doh YW, Kook MC, Kim CG, Park HJ, Lee JH, Lee JS, Lee JY, Kim YW, Bae JM. Surgical indication for non-curative endoscopic resection in early gastric cancer. *Ann Surg Oncol* 2007; **14**: 3428-3434 [PMID: [17899290](https://pubmed.ncbi.nlm.nih.gov/17899290/) DOI: [10.1245/s10434-007-9536-z](https://doi.org/10.1245/s10434-007-9536-z)]
  - 38 **Hatta W**, Gotoda T, Oyama T, Kawata N, Takahashi A, Yoshifuku Y, Hoteya S, Nakagawa M, Hirano M, Esaki M, Matsuda M, Ohnita K, Yamanouchi K, Yoshida M, Dohi O, Takada J, Tanaka K, Yamada S, Tsuji T, Ito H, Hayashi Y, Nakaya N, Nakamura T, Shimosegawa T. A Scoring System to Stratify Curability after Endoscopic Submucosal Dissection for Early Gastric Cancer: "eCura system". *Am J Gastroenterol* 2017; **112**: 874-881 [PMID: [28397873](https://pubmed.ncbi.nlm.nih.gov/28397873/) DOI: [10.1038/ajg.2017.95](https://doi.org/10.1038/ajg.2017.95)]
  - 39 **Takizawa K**, Ono H, Muto M. Current indications of endoscopic submucosal dissection for early gastric cancer in Japan. *Jpn J Clin Oncol* 2019; **49**: 797-802 [PMID: [31322655](https://pubmed.ncbi.nlm.nih.gov/31322655/) DOI: [10.1093/jco/hyz100](https://doi.org/10.1093/jco/hyz100)]
  - 40 **Mikami K**, Hirano Y, Futami K, Maekawa T. Expansion of lymph node metastasis in mixed-type submucosal invasive gastric cancer. *Asian J Surg* 2018; **41**: 462-466 [PMID: [28732676](https://pubmed.ncbi.nlm.nih.gov/28732676/) DOI: [10.1016/j.asjsur.2017.04.004](https://doi.org/10.1016/j.asjsur.2017.04.004)]
  - 41 **Sun F**, Zhang S, Wang X, Yao M, Zhang C, Liu Z, Ai S, Guan W, Wang M. Mixed Histologic Type is a Risk Factor for Lymph Node Metastasis in Submucosal Invasive Early Gastric Cancer. *J Surg Res* 2023; **282**: 160-167 [PMID: [36306586](https://pubmed.ncbi.nlm.nih.gov/36306586/) DOI: [10.1016/j.jss.2022.09.013](https://doi.org/10.1016/j.jss.2022.09.013)]

- 42 **Komatsu S**, Ichikawa D, Miyamae M, Shimizu H, Konishi H, Shiozaki A, Fujiwara H, Okamoto K, Kishimoto M, Otsuji E. Histological mixed-type as an independent prognostic factor in stage I gastric carcinoma. *World J Gastroenterol* 2015; **21**: 549-555 [PMID: [25593472](#) DOI: [10.3748/wjg.v21.i2.549](#)]
- 43 **Nie RC**, Yuan SQ, Li YF, Chen YM, Chen XJ, Zhu BY, Xu LP, Zhou ZW, Chen S, Chen YB. Clinicopathological Characteristics and Prognostic Value of Signet Ring Cells in Gastric Carcinoma: A Meta-Analysis. *J Cancer* 2017; **8**: 3396-3404 [PMID: [29151922](#) DOI: [10.7150/jca.21017](#)]
- 44 **Chen JN**, Wang QW, Zhang QW, Tang ZR, Li XB. Poorly differentiated is more significant than signet ring cell component for lymph node metastasis in mixed-type early gastric cancer: a retrospective study from a large-volume hospital. *Surg Endosc* 2021; **35**: 1558-1565 [PMID: [32277355](#) DOI: [10.1007/s00464-020-07532-5](#)]



Published by **Baishideng Publishing Group Inc**  
7041 Koll Center Parkway, Suite 160, Pleasanton, CA 94566, USA

**Telephone:** +1-925-3991568

**E-mail:** [bpgoffice@wjgnet.com](mailto:bpgoffice@wjgnet.com)

**Help Desk:** <https://www.f6publishing.com/helpdesk>

<https://www.wjgnet.com>

