

# World Journal of *Gastrointestinal Surgery*

*World J Gastrointest Surg* 2023 September 27; 15(9): 1841-2097



## Contents

Monthly Volume 15 Number 9 September 27, 2023

## REVIEW

- 1841 Indocyanine green dye and its application in gastrointestinal surgery: The future is bright green  
*Lim ZY, Mohan S, Balasubramaniam S, Ahmed S, Siew CCH, Shelat VG*
- 1858 Hepatic ischemia-reperfusion syndrome and its effect on the cardiovascular system: The role of treprostinil, a synthetic prostacyclin analog  
*Mouratidou C, Pavlidis ET, Katsanos G, Kotoulas SC, Mouloudi E, Tsoulfas G, Galanis IN, Pavlidis TE*

## MINIREVIEWS

- 1871 Advances and challenges of gastrostomy insertion in children  
*Bitar R, Azaz A, Rawat D, Hobeldin M, Miqdady M, Abdelsalam S*
- 1879 Surgical decompression for the management of abdominal compartment syndrome with severe acute pancreatitis: A narrative review  
*Nasa P, Chanchalani G, Juneja D, Malbrain ML*

## ORIGINAL ARTICLE

## Retrospective Cohort Study

- 1892 Excision of malignant and pre-malignant rectal lesions by transanal endoscopic microsurgery in patients under 50 years of age  
*Shilo Yaacobi D, Berger Y, Shaltiel T, Bekhor EY, Khalifa M, Issa N*
- 1901 Safety and feasibility of modified duct-to-mucosa pancreaticojejunostomy during pancreatoduodenectomy: A retrospective cohort study  
*Sun Y, Yu XF, Yao H, Xu S, Ma YQ, Chai C*

## Retrospective Study

- 1910 Application of early enteral nutrition nursing based on enhanced recovery after surgery theory in patients with digestive surgery  
*Shao YR, Ke X, Luo LH, Xu JD, Xu LQ*
- 1919 Autologous bone marrow infusion *via* portal vein combined with splenectomy for decompensated liver cirrhosis: A retrospective study  
*Liu BC, Cheng MR, Lang L, Li L, Si YH, Li AJ, Xu Q, Zhang H*
- 1932 Application of multidisciplinary collaborative nursing with family care for enhanced recovery after surgery in children with inguinal hernia  
*Wang XM, Hou Q*
- 1941 Preoperative and postoperative complications as risk factors for delayed gastric emptying following pancreaticoduodenectomy: A single-center retrospective study  
*Xie FL, Ren LJ, Xu WD, Xu TL, Ge XQ, Li W, Ge XM, Zhou WK, Li K, Zhang YH, Wang Z*

- 1950** Efficacy of ileus tube combined with meglumine diatrizoate in treating postoperative inflammatory bowel obstruction after surgery  
*Yang W, Pu J*
- 1959** Effect of internet multiple linkage mode-based extended care combined with in-hospital comfort care on colorectal cancer patients undergoing colostomy  
*Xu L, Zhou MZ*
- 1969** Short- and long-term results of open *vs* laparoscopic multisegmental resection and anastomosis for synchronous colorectal cancer located in separate segments  
*Quan JC, Zhou XJ, Mei SW, Liu JG, Qiu WL, Zhang JZ, Li B, Li YG, Wang XS, Chang H, Tang JQ*
- 1978** Prediction model of stress ulcer after laparoscopic surgery for colorectal cancer established by machine learning algorithm  
*Yu DM, Wu CX, Sun JY, Xue H, Yuwen Z, Feng JX*
- 1986** Effect of two surgical approaches on the lung function and prognosis of patients with combined esophago-gastric cancer  
*Sun CB, Han XQ, Wang H, Zhang YX, Wang MC, Liu YN*
- 1995** Clinical significance of serum oxidative stress and serum uric acid levels before surgery for hepatitis B-related liver cancer  
*Hou JX, Wang YB, Wu J, Ding GS, Wu Y, Wei LH, Wang F, Zhang ZM*
- 2003** Multifactor analysis of the technique in total laparoscopic gastric cancer  
*Shi JK, Wang B, Zhang XS, Lv P, Chen YL, Ren SY*
- 2012** Value of enhanced computed tomography in differentiating small mesenchymal tumours of the gastrointestinal from smooth muscle tumours  
*Nie WJ, Jing Z, Hua M*
- 2021** Risk factors for myocardial injury during living donor liver transplantation in pediatric patients with biliary atresia  
*Wu YL, Li TY, Gong XY, Che L, Sheng MW, Yu WL, Weng YQ*

**Observational Study**

- 2032** Comparative detection of syndecan-2 methylation in preoperative and postoperative stool DNA in patients with colorectal cancer  
*Song JH, Oh TJ, An S, Lee KH, Kim JY, Kim JS*

**Prospective Study**

- 2042** Preoperative prediction of microvascular invasion in hepatocellular carcinoma using ultrasound features including elasticity  
*Jiang D, Qian Y, Tan BB, Zhu XL, Dong H, Qian R*
- 2052** Quantitative evaluation of colorectal tumour vasculature using contrast-enhanced ultrasound: Correlation with angiogenesis and prognostic significance  
*Li MH, Li WW, He L, Li JF, Zhang SY*

## CASE REPORT

- 2063** Laparoscopy-assisted gastrectomy for advanced gastric cancer patients with situs inversus totalis: Two case reports and review of literature  
*Liu HB, Cai XP, Lu Z, Xiong B, Peng CW*
- 2074** Acute flare of systemic lupus erythematosus with extensive gastrointestinal involvement: A case report and review of literature  
*Huang H, Li P, Zhang D, Zhang MX, Yu K*
- 2083** Surgical management of gallstone ileus after one anastomosis gastric bypass: A case report  
*El Feghali E, Akel R, Chamaa B, Kazan D, Chakhtoura G*
- 2089** Dual transformation therapy for giant hepatocellular carcinoma: Two case reports and review of literature  
*Gao Q, Zhu GZ, Han CY, Ye XP, Huang HS, Mo ST, Peng T*

**ABOUT COVER**

Editorial Board Member of *World Journal of Gastrointestinal Surgery*, Sung Uk Bae, MD, PhD, Associate Professor, Department of Surgery, Keimyung University Dongsan Hospital, Daegu 42601, South Korea.  
sabiston0000@hanmail.net

**AIMS AND SCOPE**

The primary aim of *World Journal of Gastrointestinal Surgery* (WJGS, *World J Gastrointest Surg*) is to provide scholars and readers from various fields of gastrointestinal surgery with a platform to publish high-quality basic and clinical research articles and communicate their research findings online.

WJGS mainly publishes articles reporting research results and findings obtained in the field of gastrointestinal surgery and covering a wide range of topics including biliary tract surgical procedures, biliopancreatic diversion, colectomy, esophagectomy, esophagostomy, pancreas transplantation, and pancreatectomy, etc.

**INDEXING/ABSTRACTING**

The WJGS is now abstracted and indexed in Science Citation Index Expanded (SCIE, also known as SciSearch®), Current Contents/Clinical Medicine, Journal Citation Reports/Science Edition, PubMed, PubMed Central, Reference Citation Analysis, China National Knowledge Infrastructure, China Science and Technology Journal Database, and Superstar Journals Database. The 2023 Edition of Journal Citation Reports® cites the 2022 impact factor (IF) for WJGS as 2.0; IF without journal self cites: 1.9; 5-year IF: 2.2; Journal Citation Indicator: 0.52; Ranking: 113 among 212 journals in surgery; Quartile category: Q3; Ranking: 81 among 93 journals in gastroenterology and hepatology; and Quartile category: Q4.

**RESPONSIBLE EDITORS FOR THIS ISSUE**

Production Editor: Rui-Rui Wu; Production Department Director: Xiang Li; Editorial Office Director: Jia-Ru Fan.

**NAME OF JOURNAL**

*World Journal of Gastrointestinal Surgery*

**ISSN**

ISSN 1948-9366 (online)

**LAUNCH DATE**

November 30, 2009

**FREQUENCY**

Monthly

**EDITORS-IN-CHIEF**

Peter Schemmer

**EDITORIAL BOARD MEMBERS**

<https://www.wjgnet.com/1948-9366/editorialboard.htm>

**PUBLICATION DATE**

September 27, 2023

**COPYRIGHT**

© 2023 Baishideng Publishing Group Inc

**INSTRUCTIONS TO AUTHORS**

<https://www.wjgnet.com/bpg/gerinfo/204>

**GUIDELINES FOR ETHICS DOCUMENTS**

<https://www.wjgnet.com/bpg/GerInfo/287>

**GUIDELINES FOR NON-NATIVE SPEAKERS OF ENGLISH**

<https://www.wjgnet.com/bpg/gerinfo/240>

**PUBLICATION ETHICS**

<https://www.wjgnet.com/bpg/GerInfo/288>

**PUBLICATION MISCONDUCT**

<https://www.wjgnet.com/bpg/gerinfo/208>

**ARTICLE PROCESSING CHARGE**

<https://www.wjgnet.com/bpg/gerinfo/242>

**STEPS FOR SUBMITTING MANUSCRIPTS**

<https://www.wjgnet.com/bpg/GerInfo/239>

**ONLINE SUBMISSION**

<https://www.f6publishing.com>



## Surgical management of gallstone ileus after one anastomosis gastric bypass: A case report

Elie El Feghali, Rhea Akel, Bilal Chamaa, Daniel Kazan, Ghassan Chakhtoura

**Specialty type:** Surgery

**Provenance and peer review:**

Unsolicited article; Externally peer reviewed.

**Peer-review model:** Single blind

**Peer-review report's scientific quality classification**

Grade A (Excellent): 0  
Grade B (Very good): B, B  
Grade C (Good): 0  
Grade D (Fair): 0  
Grade E (Poor): 0

**P-Reviewer:** Dilek ON, Turkey;  
Wang ZF, China

**Received:** May 25, 2023

**Peer-review started:** May 25, 2023

**First decision:** June 19, 2023

**Revised:** June 27, 2023

**Accepted:** July 25, 2023

**Article in press:** July 25, 2023

**Published online:** September 27, 2023



**Elie El Feghali, Bilal Chamaa, Daniel Kazan, Ghassan Chakhtoura**, Department of General Surgery, Saint Joseph University, Beirut 1107, Lebanon

**Rhea Akel**, Department of Radiology, Saint Joseph University, Beirut 1107, Lebanon

**Corresponding author:** Elie El Feghali, MD, Postdoc, Department of General Surgery, Saint Joseph University, Rue Damas, Ashrafieh, Beirut 1107, Lebanon. [egf995@gmail.com](mailto:egf995@gmail.com)

### Abstract

#### BACKGROUND

Gallstone ileus following one anastomosis gastric bypass (OAGB) is an exceptionally rare complication. The presented case report aims to highlight the unique occurrence of this condition and its surgical management. Understanding the clinical presentation, diagnostic challenges and successful surgical intervention in such cases is crucial for healthcare professionals involved in bariatric surgery.

#### CASE SUMMARY

We present a case report of gallstone ileus following OAGB and discuss its diagnosis and surgical management. A 66-year-old female with a history of OAGB presented to the emergency room with symptoms of small bowel obstruction. Computed tomography scan revealed a gallstone impacted in the distal ileum, causing obstruction. The patient underwent a laparoscopically assisted enterolithotomy, during which the gallstone was extracted and the enterotomy was closed. The patient had an uneventful recovery and was discharged on postoperative day four.

#### CONCLUSION

Gallstone ileus should be considered as a possible complication after OAGB, and prompt surgical intervention is usually required for its management. This case report contributes to the limited existing literature, providing insights into the management of this uncommon complication.

**Key Words:** Gallstone ileus; One anastomosis gastric bypass; Bariatric surgery; Intestinal occlusion; Bilio-digestive fistula; Enterolithotomy; Case report

©The Author(s) 2023. Published by Baishideng Publishing Group Inc. All rights reserved.



**Core Tip:** Gallstone ileus is a rare but serious complication that can occur after bariatric surgery, including one anastomosis gastric bypass (OAGB). Prompt diagnosis and appropriate surgical management are crucial for successful outcomes. In this case report, we present a rare instance of gallstone ileus after OAGB, highlighting the importance of considering this condition in patients presenting with small bowel obstruction symptoms post-bariatric surgery. A laparoscopically assisted enterolithotomy was performed, leading to the successful extraction of the gallstone and subsequent resolution of symptoms. Surgeons should be aware of the increased risk of cholelithiasis after bariatric surgery and consider preventive measures or early intervention to minimize the occurrence of gallstone-related complications.

**Citation:** El Feghali E, Akel R, Chamaa B, Kazan D, Chakhtoura G. Surgical management of gallstone ileus after one anastomosis gastric bypass: A case report. *World J Gastrointest Surg* 2023; 15(9): 2083-2088

**URL:** <https://www.wjgnet.com/1948-9366/full/v15/i9/2083.htm>

**DOI:** <https://dx.doi.org/10.4240/wjgs.v15.i9.2083>

## INTRODUCTION

One anastomosis gastric bypass (OAGB) or mini bypass was first performed by Dr. Robert Rutledge in 1997[1]. It is both a restrictive and malabsorptive bariatric surgical procedure for the treatment of morbid obesity. It was developed as a faster and simpler alternative to the Roux en Y gastric bypass and is the fourth most performed bariatric technique in Europe and in Asia[2]. It is an effective surgical technique in terms of both weight loss and the resolution of comorbidities [3]. Nevertheless, like any other surgical procedure, OAGB can be associated with potential complications such as anastomotic leaks in 0.5 to 5.0 percent of cases, bleeding 0.2 to 2.0 per cent, nutritional deficiencies 5 to 50 per cent[4]. In addition, intestinal obstruction or occlusion is a possible complication after the OAGB with an incidence of 1 to 10 per cent[5] causing symptoms such as abdominal pain, nausea and vomiting and constipation. The most common etiologies of intestinal occlusion post-OAGB include internal hernias, adhesions, strictures and bowel kinking and/or twisting. In our case report, we are going to present a rare cause of intestinal occlusion post-OAGB, the gallstone ileus (GI).

## CASE PRESENTATION

### Chief complaints

A 66-year-old female presented to the ER for abdominal pain and vomiting.

### History of present illness

She had a 4-d history of food intolerance with post-prandial vomiting and diffuse colic type abdominal pain, her bowel movements were maintained. She denied having previously experienced similar symptoms or symptoms suggesting of cholecystitis during her post-operative interval.

### History of past illness

She is known to have bipolar disease treated with Perphenazine 8 mg and known to be a 5 pack/year smoker. She was operated of OAGB 6 years ago for morbid obesity [body mass index (BMI): 66.7 kg/m<sup>2</sup>]. Previous comorbidities that included hypertension and diabetes mellitus were rectified after her weight loss of 90 Kg (BMI: 26.66 kg/m<sup>2</sup>). Previous surgical interventions include 2 C-section deliveries.

### Personal and family history

She has no significant family history.

### Physical examination

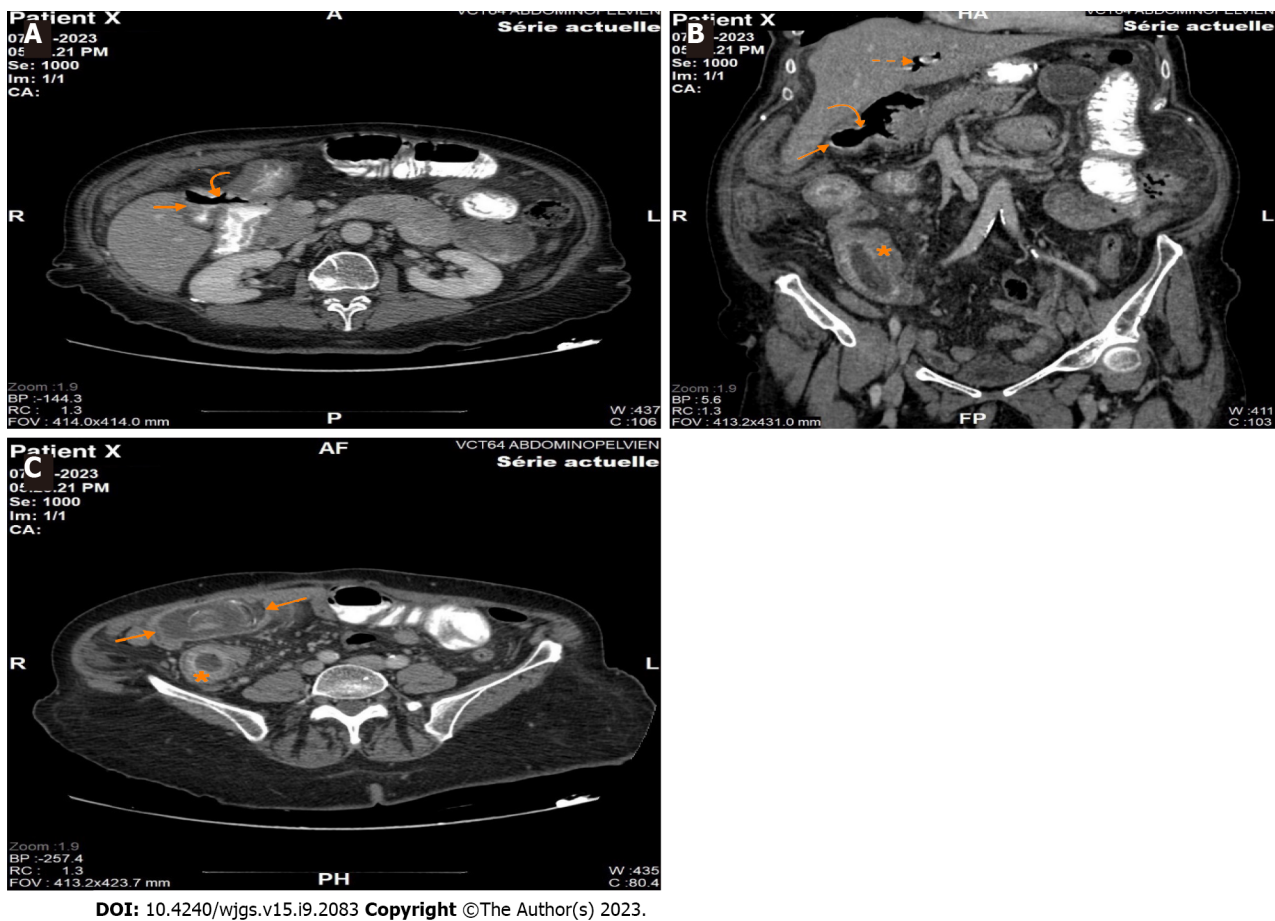
On physical examination, her abdomen was soft with mild tenderness in the lower right quadrant. She had a supra-umbilical hernia from her previous intervention.

### Laboratory examinations

Her labs showed a mild hyper-leukocytosis white blood cell 12000 and C-reactive protein level was 80.8, her liver enzymes were in the normal range.

### Imaging examinations

An abdomino-pelvic computed tomography scan with injection and ingestion of contrast was ordered (Figure 1). It showed a fistulous tract between the gallbladder and the duodenal bulb, extending over 15 mm. The fistula was confirmed with the leakage of the ingested contrast in the lumen of the gallbladder, which was not distended and contained an air-fluid level. It was associated with pneumobilia and small bowel dilation of 42 mm in diameter, with an



**Figure 1 Computed tomography scan.** A: Axial section of contrast-enhanced computed tomography (CT) shows a gallbladder containing a hydro-aeric level with passage of ingested contrast medium (straight arrow) associated to a visible communication of 15 mm between the gallbladder and the duodenal bulb (curved arrow); B: Coronal reconstructed image (using multiplanar reconstruction) of contrast-enhanced CT shows the defect between the gallbladder and the duodenal bulb (curved arrow), the gallbladder filled with air (straight arrow) as well as pneumobilia within the intrahepatic biliary ducts (dotted straight arrow). Note that the distal ileum is mildly dilated, markedly thickened with increased mucosal enhancement (asterisks); C: Axial section of contrast-enhanced CT shows a gallstone measuring almost 45 mm (two arrows) impacted in the distal ileum, with marked thickening and increased mucosal enhancement within the upstream ileum (asterisks).

intestinal segment in the right lower quadrant showing parietal thickening and submucosal edema upstream of a transition zone located at the level of the right iliac fossa, downstream of a probable oval intraluminal calculus of 45 mm. The previous findings evoking a GI with a probable gallstone located at the level of the efferent alimentary loop. It is associated with a trabeculation of the fat at the level of the two flanks, especially on the right, with perihepatic and pelvic ascites of low abundance. Sequelae of gastric surgery with gastro-jejunal anastomosis (Roux en Omega) was identified.

## FINAL DIAGNOSIS

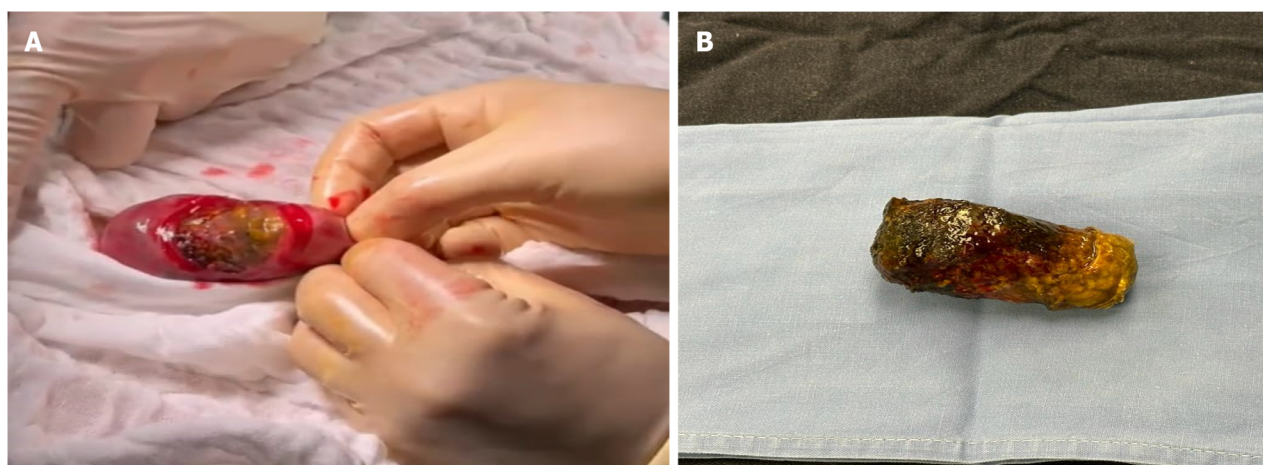
She was thus admitted for adequate treatment of her GI.

## TREATMENT

After establishing the diagnosis of GI and acquiring the written consent of the patient, she was transferred to the operating room for a diagnostic laparoscopy and subsequent enterolithotomy. A nasogastric tube was inserted and she was adequately hydrated.

Open coelioscopy was performed and a 10 mm port was introduced. Pneumoperitoneum was created with a PCO<sub>2</sub> of 12 mmHg. Two para-umbilical 5 mm ports were introduced under vision. There were multiple adhesions over the previous gastro-jejunal anastomosis and over the gallbladder. The entero-biliary fistulae were not visualized, even after adhesiolysis. The afferent biliopancreatic loop was normal in diameter whereas the efferent alimentary loop was distended. The small bowel was run downwards until the obstructed ileal loop was identified. A 5 cm para-umbilical midline incision was made and the bowel segment was exteriorized. A horizontal enterotomy was performed to allow the extraction of an ovoid shaped yellow-brown stone measuring 5 cm × 3 cm × 1 cm approximately (Figure 2). The enterotomy was closed transversely with a double layer of absorbable sutures, and the small bowel was returned to the





DOI: 10.4240/wjgs.v15.i9.2083 Copyright ©The Author(s) 2023.

**Figure 2 Gallstone.** A: Intraoperative photo of gallstone after enterolithotomy; B: Gallstone.

abdomen. The incision was approximated with non-absorbable monofilament sutures.

## OUTCOME AND FOLLOW-UP

The patient's recovery was uneventful with return of bowel function on postoperative day two and diet advanced as tolerated. The patient was discharged home in improved condition on postoperative day four.

## DISCUSSION

Rapid weight loss after bariatric surgery is associated with an increase in cholelithiasis, especially when the weight loss is greater than 25 per cent of the preoperative weight[6] with 38 per cent of patients developing gallstones within 6 mo, of which, 41 per cent will ultimately develop symptomatic cholelithiasis[7].

Gallstone ileus or Bouveret's Syndrome is a rare but serious complication of cholelithiasis as it occurs in 0.3 per cent of patients[8,9]. It results when a supracentimetric gallstone, which was formed during a medically treated or neglected cholecystitis, migrates from the gallbladder to the bowel through a biliary enteric fistula, the most common being a cholecystoduodenal fistula, and causes an obstruction, in more than 70% of cases at the level of the terminal ileum[10].

GI is considered to be implicated in 1 to 4 per cent of mechanical bowel obstruction, and accounts for a quarter of non-strangulated small bowel obstruction in patients above the age of 65 years, with a mortality rate between 15 to 18 per cent [9] with a female to male ratio of 3.5-6.1[11].

The diagnosis of GI is both clinical and radiological. GI has nonspecific symptoms such as nausea and/or vomiting associated with abdominal pain, bloating and constipation. The abdominal computed-tomography scan is the gold standard to establish the diagnosis. Rigler's triad of pneumobilia with small bowel obstruction caused by an ectopic gallstone within the bowel is observed in 40 to 50 per cent of cases[12].

Conservative measures such as nil per os status, nasogastric tube decompression with adequate intravenous hydration may be sufficient in select clinically stable patients with partial bowel obstruction and stones < 2 cm in size[8]. However, GI often requires urgent surgical management, laparoscopically in 10% of cases[13], which allows delineation of the anatomy with decreased bowel manipulation and subsequent safe stone extraction and reduced risk of intestinal content spillage.

The choice of surgical intervention is a subject of controversy[14]. A one or two stage procedure may be proposed: either enterolithotomy alone or enterolithotomy with cholecystectomy and eventual repair of the biliary fistula[15]. Nevertheless, the one stage approach is discouraged in view of the significant mortality (16.9%) compared with the two staged procedure (11.7%)[9]. In addition, laparoscopically assisted enterolithotomy has been credited with a favorable impact as it can be recommended for both diagnosis and treatment[16]. Prevention of symptomatic cholelithiasis after gastric bypass could be achieved by either prophylactic cholecystectomy or administration of ursodiol. In the one hand, prophylactic cholecystectomy during gastric bypass is a debatable subject. Its supporters argue that it is safe and would prevent both the morbidity associated with symptomatic cholelithiasis and a subsequent operation. Those who oppose to it cite that the safety of secondary cholecystectomy with an increase in operative time and length of stay do not justify the prophylactic cholecystectomy[17]. In the other hand, administration of a daily dose of 600 mg of ursodiol after gastric bypass was associated with a significant reduction in the incidence of cholelithiasis compared with placebo at 6 mo (2% *vs* 32%)[18].

To our knowledge, this is the first documented report of GI in a patient after OAGB. The GI diagnosis was established after correlation of the clinical and radiological findings of the patient. The fact that the patient presented to the emergency department with small bowel obstruction symptoms and the CT-scan confirmed the GI diagnosis with the presence of Rigler's triad previously discussed. The decision was to perform a two-staged procedure. Laparoscopically assisted enterolithotomy was preformed because it is in our opinion the safest and fastest therapeutic modality. At our institution, our current practice is to perform the OAGB without prophylactic cholecystectomy given that, if needed, a laparoscopic cholecystectomy is feasible in the case of a symptomatic cholelithiasis.

## CONCLUSION

In conclusion, the incidence of cholelithiasis significantly increases after bariatric surgery and may lead to serious complications such as gallstone ileus, which require further operations.

## FOOTNOTES

**Author contributions:** El Feghali E wrote the manuscript; Akel R provided the radiology images and their respective annotations; Chamaa B and Kazan D performed the research; Chakhtoura G designed the research study; and all authors have read and approve the final manuscript.

**Informed consent statement:** Informed written consent was obtained from the patients for the publication of this report and any accompanying images.

**Conflict-of-interest statement:** There are no conflict-of-interest to disclose.

**CARE Checklist (2016) statement:** The authors have read the CARE Checklist (2016), and the manuscript was prepared and revised according to the CARE Checklist (2016).

**Open-Access:** This article is an open-access article that was selected by an in-house editor and fully peer-reviewed by external reviewers. It is distributed in accordance with the Creative Commons Attribution NonCommercial (CC BY-NC 4.0) license, which permits others to distribute, remix, adapt, build upon this work non-commercially, and license their derivative works on different terms, provided the original work is properly cited and the use is non-commercial. See: <https://creativecommons.org/licenses/by-nc/4.0/>

**Country/Territory of origin:** Lebanon

**ORCID number:** Elie El Feghali [0009-0004-0075-1792](https://orcid.org/0009-0004-0075-1792).

**S-Editor:** Chen YL

**L-Editor:** A

**P-Editor:** Chen YL

## REFERENCES

- 1 Rutledge R. The mini-gastric bypass: experience with the first 1,274 cases. *Obes Surg* 2001; **11**: 276-280 [PMID: [11433900](https://pubmed.ncbi.nlm.nih.gov/11433900/) DOI: [10.1381/096089201321336584](https://doi.org/10.1381/096089201321336584)]
- 2 Angrisani L, Santonicola A, Iovino P, Formisano G, Buchwald H, Scopinaro N. Bariatric Surgery Worldwide 2013. *Obes Surg* 2015; **25**: 1822-1832 [PMID: [25835983](https://pubmed.ncbi.nlm.nih.gov/25835983/) DOI: [10.1007/s11695-015-1657-z](https://doi.org/10.1007/s11695-015-1657-z)]
- 3 Abou Ghazaleh R, Bruzzi M, Bertrand K, M'harzi L, Zinzindohoue F, Douard R, Berger A, Czernichow S, Carette C, Chevallier JM. Is Mini-Gastric Bypass a Rational Approach for Type-2 Diabetes? *Curr Atheroscler Rep* 2017; **19**: 51 [PMID: [29063974](https://pubmed.ncbi.nlm.nih.gov/29063974/) DOI: [10.1007/s11883-017-0689-3](https://doi.org/10.1007/s11883-017-0689-3)]
- 4 Musella M, Susa A, Manno E, De Luca M, Greco F, Raffaelli M, Cristiano S, Milone M, Bianco P, Vilardi A, Damiano I, Segato G, Pedretti L, Giustacchini P, Fico D, Veroux G, Piazza L. Complications Following the Mini/One Anastomosis Gastric Bypass (MGB/OAGB): a Multi-institutional Survey on 2678 Patients with a Mid-term (5 Years) Follow-up. *Obes Surg* 2017; **27**: 2956-2967 [PMID: [28569357](https://pubmed.ncbi.nlm.nih.gov/28569357/) DOI: [10.1007/s11695-017-2726-2](https://doi.org/10.1007/s11695-017-2726-2)]
- 5 Scavone G, Caltabiano DC, Gulino F, Raciti MV, Giarrizzo A, Biondi A, Piazza L, Scavone A. Laparoscopic mini/one anastomosis gastric bypass: anatomic features, imaging, efficacy and postoperative complications. *Updates Surg* 2020; **72**: 493-502 [PMID: [32189194](https://pubmed.ncbi.nlm.nih.gov/32189194/) DOI: [10.1007/s13304-020-00743-4](https://doi.org/10.1007/s13304-020-00743-4)]
- 6 Li VK, Pulido N, Fajnwaks P, Szomstein S, Rosenthal R, Martinez-Duarte P. Predictors of gallstone formation after bariatric surgery: a multivariate analysis of risk factors comparing gastric bypass, gastric banding, and sleeve gastrectomy. *Surg Endosc* 2009; **23**: 1640-1644 [PMID: [19057954](https://pubmed.ncbi.nlm.nih.gov/19057954/) DOI: [10.1007/s00464-008-0204-6](https://doi.org/10.1007/s00464-008-0204-6)]
- 7 Karadeniz M, Görgün M, Kara C. The evaluation of gallstone formation in patients undergoing Roux-en-Y gastric bypass due to morbid obesity. *Ulus Cerrahi Derg* 2014; **30**: 76-79 [PMID: [25931899](https://pubmed.ncbi.nlm.nih.gov/25931899/) DOI: [10.5152/UCD.2014.2538](https://doi.org/10.5152/UCD.2014.2538)]
- 8 Duzgun AP, Ozmen MM, Ozer MV, Coskun F. Internal biliary fistula due to cholelithiasis: a single-centre experience. *World J Gastroenterol* 2007; **13**: 4606-4609 [PMID: [17729415](https://pubmed.ncbi.nlm.nih.gov/17729415/) DOI: [10.3748/wjg.v13.i34.4606](https://doi.org/10.3748/wjg.v13.i34.4606)]

- 9 **BUETOW GW**, CRAMPTON RS. Gallstone ileus. A report of 23 cases. *Arch Surg* 1963; **86**: 504-511 [PMID: [14016662](#) DOI: [10.1001/archsurg.1963.01310090154029](#)]
- 10 **Trump D**. Commentary on: "Randomized, controlled, double-blind, cross-over trial assessing treatment preference for pazopanib versus sunitinib in patients with metastatic renal cell carcinoma: PISCES study." Escudier B, Porta C, Bono P, Powles T, Eisen T, Sternberg CN, Gschwend JE, De Giorgi U, Parikh O, Hawkins R, Sevin E, Négrier S, Khan S, Diaz J, Redhu S, Mehmud F, Cella D. Bernard Escudier, Institut Gustave Roussy, Villejuif; Emmanuel Sevin, Centre François Baclesse, Caen; Sylvie Négrier, Leon Berard Cancer Center, Lyon, France; Camillo Porta, Fondazione Istituto di Ricovero e Cura a Carattere Scientifico (IRCCS) Policlinico S. Matteo, Pavia; Cora N Sternberg, San Camillo Forlanini Hospital, Rome; Ugo De Giorgi, IRCCS Istituto Scientifico Romagnolo per lo Studio e la Cura dei Tumori, Meldola, Italy; Petri Bono, Helsinki University Central Hospital, Helsinki, Finland; Thomas Powles, Barts Experimental Cancer Medicine Centre, Barts Cancer Institute, Queen Mary University of London, London; Tim Eisen, Cambridge University Health Partners, Cambridge; Omi Parikh, Royal Preston Hospital, Lancashire; Robert Hawkins, Christie Cancer Research UK, Manchester; Sadya Khan, Jose Diaz, and Faisal Mehmud, GlaxoSmithKline, Uxbridge, United Kingdom; Jürgen E Gschwend, Klinikum Rechts der Isar der Technischen Universität München, Munich, Germany; Suman Redhu, GlaxoSmithKline, Collegeville, PA; David Cella, Northwestern University Feinberg School of Medicine, Chicago, IL.: *J Clin Oncol*. 2014 May 10;32(14):1412-1418; doi: 10.1200/JCO.2013.50.8267. [Epub 2014 Mar 31]. *Urol Oncol* 2016; **34**: 251 [PMID: [25937427](#) DOI: [10.1016/j.urolonc.2015.03.015](#)]
- 11 **Micheletto G**, Danelli P, Morandi A, Panizzo V, Montorsi M. Gallstone ileus after biliointestinal bypass: report of two cases. *J Gastrointest Surg* 2013; **17**: 2162-2165 [PMID: [23897084](#) DOI: [10.1007/s11605-013-2290-6](#)]
- 12 **Yu CY**, Lin CC, Shyu RY, Hsieh CB, Wu HS, Tyan YS, Hwang JI, Liou CH, Chang WC, Chen CY. Value of CT in the diagnosis and management of gallstone ileus. *World J Gastroenterol* 2005; **11**: 2142-2147 [PMID: [15810081](#) DOI: [10.3748/wjg.v11.i14.2142](#)]
- 13 **Nuño-Guzmán CM**, Marín-Contreras ME, Figueroa-Sánchez M, Corona JL. Gallstone ileus, clinical presentation, diagnostic and treatment approach. *World J Gastrointest Surg* 2016; **8**: 65-76 [PMID: [26843914](#) DOI: [10.4240/wjgs.v8.i1.65](#)]
- 14 **Lê P**, Chambon H, Madeuf E. [Gallstone ileus]. *J Chir (Paris)* 2003; **140**: 169-170 [PMID: [12910216](#)]
- 15 **Doko M**, Zovak M, Kopljär M, Glavan E, Ljubcic N, Hochstädter H. Comparison of surgical treatments of gallstone ileus: preliminary report. *World J Surg* 2003; **27**: 400-404 [PMID: [12658481](#) DOI: [10.1007/s00268-002-6569-0](#)]
- 16 **Moberg AC**, Montgomery A. Laparoscopically assisted or open enterolithotomy for gallstone ileus. *Br J Surg* 2007; **94**: 53-57 [PMID: [17058318](#) DOI: [10.1002/bjs.5537](#)]
- 17 **Hamad GG**, Ikramuddin S, Gourash WF, Schauer PR. Elective cholecystectomy during laparoscopic Roux-en-Y gastric bypass: is it worth the wait? *Obes Surg* 2003; **13**: 76-81 [PMID: [12630618](#) DOI: [10.1381/096089203321136638](#)]
- 18 **Sugerman HJ**, Brewer WH, Shiffman ML, Brolin RE, Fobi MA, Linner JH, MacDonald KG, MacGregor AM, Martin LF, Oram-Smith JC. A multicenter, placebo-controlled, randomized, double-blind, prospective trial of prophylactic ursodiol for the prevention of gallstone formation following gastric-bypass-induced rapid weight loss. *Am J Surg* 1995; **169**: 91-6; discussion 96 [PMID: [7818005](#) DOI: [10.1016/s0002-9610\(99\)80115-9](#)]



Published by **Baishideng Publishing Group Inc**  
7041 Koll Center Parkway, Suite 160, Pleasanton, CA 94566, USA

**Telephone:** +1-925-3991568

**E-mail:** [bpgoffice@wjgnet.com](mailto:bpgoffice@wjgnet.com)

**Help Desk:** <https://www.f6publishing.com/helpdesk>

<https://www.wjgnet.com>

