

World Journal of *Gastrointestinal Surgery*

World J Gastrointest Surg 2024 February 27; 16(2): 260-634



EDITORIAL

- 260 Actuality and underlying mechanisms of systemic immune-inflammation index and geriatric nutritional risk index prognostic value in hepatocellular carcinoma
Tchilikidi KY
- 266 Prognostic impact of preoperative nutritional and immune inflammatory parameters on liver cancer
Bae SU
- 270 Don't forget emergency surgery! Lessons to learn from elective indocyanine green-guided gastrointestinal interventions
Perini D, Martellucci J
- 276 Mutational landscape of TP53 and CDH1 in gastric cancer
Cai HQ, Zhang LY, Fu LM, Xu B, Jiao Y
- 284 Overview of ectopic pancreas
Li CF, Li QR, Bai M, Lv YS, Jiao Y

ORIGINAL ARTICLE

Clinical and Translational Research

- 289 Phospholipase A2 enzymes PLA2G2A and PLA2G12B as potential diagnostic and prognostic biomarkers in cholangiocarcinoma
Qiu C, Xiang YK, Da XB, Zhang HL, Kong XY, Hou NZ, Zhang C, Tian FZ, Yang YL

Case Control Study

- 307 Classification of anatomical morphology of cystic duct and its association with gallstone
Zhu JH, Zhao SL, Kang Q, Zhu Y, Liu LX, Zou H

Retrospective Cohort Study

- 318 Will partial splenic embolization followed by splenectomy increase intraoperative bleeding?
Huang L, Li QL, Yu QS, Peng H, Zhen Z, Shen Y, Zhang Q
- 331 Influence of donor age on liver transplantation outcomes: A multivariate analysis and comparative study
Bezjak M, Stresec I, Kocman B, Jadrijević S, Filipec Kanizaj T, Antonijević M, Dalbelo Bašić B, Mikulić D
- 345 Machine learning-based radiomics score improves prognostic prediction accuracy of stage II/III gastric cancer: A multi-cohort study
Xiang YH, Mou H, Qu B, Sun HR

- 357 Risk stratification in gastric cancer lung metastasis: Utilizing an overall survival nomogram and comparing it with previous staging
Chen ZR, Yang MF, Xie ZY, Wang PA, Zhang L, Huang ZH, Luo Y
- 382 Systemic inflammatory response index is a predictor of prognosis in gastric cancer patients: Retrospective cohort and meta-analysis
Ren JY, Xu M, Niu XD, Ma SX, Jiao YJ, Wang D, Yu M, Cai H
- Retrospective Study**
- 396 Development of a clinical nomogram for prediction of response to neoadjuvant chemotherapy in patients with advanced gastric cancer
Liu B, Xu YJ, Chu FR, Sun G, Zhao GD, Wang SZ
- 409 Laparoscopic left hemihepatectomy guided by indocyanine green fluorescence: A cranial-dorsal approach
Wang XR, Li XJ, Wan DD, Zhang Q, Liu TX, Shen ZW, Tong HX, Li Y, Li JW
- 419 Hemoglobin loss method calculates blood loss during pancreaticoduodenectomy and predicts bleeding-related risk factors
Yu C, Lin YM, Xian GZ
- 429 Short- and long-term outcomes of surgical treatment in patients with intestinal Behcet's disease
Park MY, Yoon YS, Park JH, Lee JL, Yu CS
- 438 Preoperative neutrophil-to-lymphocyte ratio predicts symptomatic anastomotic leakage in elderly colon cancer patients: Multicenter propensity score-matched analysis
Wang CY, Li XL, Ma XL, Yang XF, Liu YY, Yu YJ
- 451 Preoperative blood markers and intra-abdominal infection after colorectal cancer resection
Liu CQ, Yu ZB, Gan JX, Mei TM
- 463 Immune function status of postoperative patients with colon cancer for predicting liver metastasis
Xiong L, Liu FC
- 471 Efficacy of transjugular intrahepatic portosystemic shunts in treating cirrhotic esophageal-gastric variceal bleeding
Hu XG, Dai JJ, Lu J, Li G, Wang JM, Deng Y, Feng R, Lu KP
- 481 Correlation between serum markers and transjugular intrahepatic portosystemic shunt prognosis in patients with cirrhotic ascites
Hu XG, Yang XX, Lu J, Li G, Dai JJ, Wang JM, Deng Y, Feng R
- 491 Development of a new Cox model for predicting long-term survival in hepatitis cirrhosis patients underwent transjugular intrahepatic portosystemic shunts
Lv YF, Zhu B, Meng MM, Wu YF, Dong CB, Zhang Y, Liu BW, You SL, Lv S, Yang YP, Liu FQ
- 503 "Five steps four quadrants" modularized *en bloc* dissection technique for accessing hepatic hilum lymph nodes in laparoscopic pancreaticoduodenectomy
Hu XS, Wang Y, Pan HT, Zhu C, Chen SL, Liu HC, Pang Q, Jin H

- 511** Efficacy and safety of endoscopic submucosal dissection for early gastric cancer and precancerous lesions in elderly patients

Xu WS, Zhang HY, Jin S, Zhang Q, Liu HD, Wang MT, Zhang B

- 518** Nomogram model including *LATS2* expression was constructed to predict the prognosis of advanced gastric cancer after surgery

Sun N, Tan BB, Li Y

Observational Study

- 529** To explore the pathogenesis of anterior resection syndrome by magnetic resonance imaging rectal defecography

Meng LH, Mo XW, Yang BY, Qin HQ, Song QZ, He XX, Li Q, Wang Z, Mo CL, Yang GH

- 539** Biopsy forceps are useful for measuring esophageal varices *in vitro*

Duan ZH, Zhou SY

SYSTEMATIC REVIEWS

- 546** First experience in laparoscopic surgery in low and middle income countries: A systematic review

Troller R, Bawa J, Baker O, Ashcroft J

- 554** Comparative effectiveness of several adjuvant therapies after hepatectomy for hepatocellular carcinoma patients with microvascular invasion

Pei YX, Su CG, Liao Z, Li WW, Wang ZX, Liu JL

META-ANALYSIS

- 571** Is tumor necrosis factor- α monoclonal therapy with proactive therapeutic drug monitoring optimized for inflammatory bowel disease? Network meta-analysis

Zheng FY, Yang KS, Min WC, Li XZ, Xing Y, Wang S, Zhang YS, Zhao QC

- 585** Poor oral health was associated with higher risk of gastric cancer: Evidence from 1431677 participants

Liu F, Tang SJ, Li ZW, Liu XR, Lv Q, Zhang W, Peng D

CASE REPORT

- 596** Treatment of hemolymphangioma by robotic surgery: A case report

Li TN, Liu YH, Zhao J, Mu H, Cao L

- 601** Postoperative encapsulated hemoperitoneum in a patient with gastric stromal tumor treated by exposed endoscopic full-thickness resection: A case report

Lu HF, Li JJ, Zhu DB, Mao LQ, Xu LF, Yu J, Yao LH

- 609** Early endoscopic management of an infected acute necrotic collection misdiagnosed as a pancreatic pseudocyst: A case report

Zhang HY, He CC

- 616** Percutaneous ultrasound-guided coaxial core needle biopsy for the diagnosis of multiple splenic lesions: A case report
Pu SH, Bao WYG, Jiang ZP, Yang R, Lu Q
- 622** Spilled gallstone mimicking intra-abdominal seeding of gallbladder adenocarcinoma: A case report
Huang CK, Lu RH, Chen CC, Chen PC, Hsu WC, Tsai MJ, Ting CT
- 628** Ileal collision tumor associated with gastrointestinal bleeding: A case report and review of literature
Wu YQ, Wang HY, Shao MM, Xu L, Jiang XY, Guo SJ

ABOUT COVER

Editorial Board Member of *World Journal of Gastrointestinal Surgery*, Nikolaos Chatzizacharias, FACS, FRCS, MD, PhD, Consultant Surgeon, Department of HPB and liver transplantation, Queen Elizabeth Hospital, University Hospitals Birmingham, Birmingham B15 2TH, United Kingdom. nikolaos.chatzizacharias@uhb.nhs.uk

AIMS AND SCOPE

The primary aim of *World Journal of Gastrointestinal Surgery* (WJGS, *World J Gastrointest Surg*) is to provide scholars and readers from various fields of gastrointestinal surgery with a platform to publish high-quality basic and clinical research articles and communicate their research findings online.

WJGS mainly publishes articles reporting research results and findings obtained in the field of gastrointestinal surgery and covering a wide range of topics including biliary tract surgical procedures, biliopancreatic diversion, colectomy, esophagectomy, esophagostomy, pancreas transplantation, and pancreatectomy, *etc.*

INDEXING/ABSTRACTING

The WJGS is now abstracted and indexed in Science Citation Index Expanded (SCIE, also known as SciSearch®), Current Contents/Clinical Medicine, Journal Citation Reports/Science Edition, PubMed, PubMed Central, Reference Citation Analysis, China Science and Technology Journal Database, and Superstar Journals Database. The 2023 Edition of Journal Citation Reports® cites the 2022 impact factor (IF) for WJGS as 2.0; IF without journal self cites: 1.9; 5-year IF: 2.2; Journal Citation Indicator: 0.52; Ranking: 113 among 212 journals in surgery; Quartile category: Q3; Ranking: 81 among 93 journals in gastroenterology and hepatology; and Quartile category: Q4.

RESPONSIBLE EDITORS FOR THIS ISSUE

Production Editor: Zi-Hang Xu, Production Department Director: Xiang Li, Editorial Office Director: Jia-Ru Fan.

NAME OF JOURNAL

World Journal of Gastrointestinal Surgery

ISSN

ISSN 1948-9366 (online)

LAUNCH DATE

November 30, 2009

FREQUENCY

Monthly

EDITORS-IN-CHIEF

Peter Schemmer

EDITORIAL BOARD MEMBERS

<https://www.wjgnet.com/1948-9366/editorialboard.htm>

PUBLICATION DATE

February 27, 2024

COPYRIGHT

© 2024 Baishideng Publishing Group Inc

INSTRUCTIONS TO AUTHORS

<https://www.wjgnet.com/bpg/gerinfo/204>

GUIDELINES FOR ETHICS DOCUMENTS

<https://www.wjgnet.com/bpg/GerInfo/287>

GUIDELINES FOR NON-NATIVE SPEAKERS OF ENGLISH

<https://www.wjgnet.com/bpg/gerinfo/240>

PUBLICATION ETHICS

<https://www.wjgnet.com/bpg/GerInfo/288>

PUBLICATION MISCONDUCT

<https://www.wjgnet.com/bpg/gerinfo/208>

ARTICLE PROCESSING CHARGE

<https://www.wjgnet.com/bpg/gerinfo/242>

STEPS FOR SUBMITTING MANUSCRIPTS

<https://www.wjgnet.com/bpg/GerInfo/239>

ONLINE SUBMISSION

<https://www.f6publishing.com>



Observational Study

To explore the pathogenesis of anterior resection syndrome by magnetic resonance imaging rectal defecography

Ling-Hou Meng, Xian-Wei Mo, Bing-Yu Yang, Hai-Quan Qin, Qing-Zhou Song, Xin-Xin He, Qiang Li, Zheng Wang, Chang-Lin Mo, Guo-Hai Yang

Specialty type: Gastroenterology and hepatology

Provenance and peer review:

Invited article; Externally peer reviewed.

Peer-review model: Single blind

Peer-review report's scientific quality classification

Grade A (Excellent): A
Grade B (Very good): 0
Grade C (Good): C
Grade D (Fair): 0
Grade E (Poor): 0

P-Reviewer: Ekine-Afolabi B, United Kingdom; Rather AA, India

Received: October 7, 2023

Peer-review started: October 7, 2023

First decision: November 12, 2023

Revised: November 26, 2023

Accepted: January 29, 2024

Article in press: January 29, 2024

Published online: February 27, 2024



Ling-Hou Meng, Bing-Yu Yang, Hai-Quan Qin, Qing-Zhou Song, Xin-Xin He, Chang-Lin Mo, Department of Gastrointestinal Surgery, Guangxi Clinical Research Center for Colorectal Cancer, Guangxi Medical University Cancer Hospital, Nanning 530021, Guangxi Zhuang Autonomous Region, China

Xian-Wei Mo, Department of Colorectal and Anal Surgery, Guangxi Medical University Cancer Hospital, Nanning 530021, Guangxi Zhuang Autonomous Region, China

Qiang Li, Zheng Wang, Department of Radiology, Guangxi Medical University Cancer Hospital, Nanning 530021, Guangxi Zhuang Autonomous Region, China

Guo-Hai Yang, First Department of Chemotherapy, Guangxi Medical University Cancer Hospital, Nanning 530021, Guangxi Zhuang Autonomous Region, China

Corresponding author: Xian-Wei Mo, MD, PhD, Chief Physician, Doctor, Professor, Department of Colorectal and Anal Surgery, Guangxi Medical University Cancer Hospital, No. 71 Hedi Road, Nanning 530021, Guangxi Zhuang Autonomous Region, China.
moxianwei888@163.com

Abstract

BACKGROUND

Over 90% of rectal cancer patients develop low anterior resection syndrome (LARS) after sphincter-preserving resection. The current globally recognized evaluation method has many drawbacks and its subjectivity is too strong, which hinders the research and treatment of LARS.

AIM

To evaluate the anorectal function after colorectal cancer surgery by quantifying the index of magnetic resonance imaging (MRI) defecography, and pathogenesis of LARS.

METHODS

We evaluated 34 patients using the standard LARS score, and a new LARS evaluation index was established using the dynamic images of MRI defecography to verify the LARS score.

RESULTS

In the LARS score model, there were 10 (29.41%) mild and 24 (70.58%) severe cases of LARS. The comparison of defecation rate between the two groups was $29.36 \pm 14.17\%$ versus $46.83 \pm 18.62\%$ ($P = 0.004$); and MRI-rectal compliance (MRI-RC) score was 3.63 ± 1.96 versus 7.0 ± 3.21 ($P = 0.001$). Severe and mild LARS had significant differences using the two evaluation methods. There was a significant negative correlation between LARS and MRI-RC score ($P < 0.001$), and they had a negative correlation with defecation rate ($P = 0.028$).

CONCLUSION

MRI defecography and standard LARS score can both be used as an evaluation index to study the pathogenesis of LARS.

Key Words: Anterior resection syndrome; Colorectal cancer; Diagnostic evaluation system; Magnetic resonance imaging defecography; Pathogenesis

©The Author(s) 2024. Published by Baishideng Publishing Group Inc. All rights reserved.

Core Tip: Currently, the evaluation of low anterior resection syndrome (LARS) symptoms in patients is solely reliant on subjective measures, such as questionnaires. There is a lack of a standardized and objective medical assessment index. We innovatively used magnetic resonance imaging (MRI) defecography to judge and quantify the compliance of neorectum after rectal cancer surgery. We established the objective diagnosis and severity evaluation criteria for LARS MRI defecography, quantify the severity of LARS by objective clinical evaluation index, which promotes the exploration of the pathogenesis of LARS.

Citation: Meng LH, Mo XW, Yang BY, Qin HQ, Song QZ, He XX, Li Q, Wang Z, Mo CL, Yang GH. To explore the pathogenesis of anterior resection syndrome by magnetic resonance imaging rectal defecography. *World J Gastrointest Surg* 2024; 16(2): 529-538

URL: <https://www.wjgnet.com/1948-9366/full/v16/i2/529.htm>

DOI: <https://dx.doi.org/10.4240/wjgs.v16.i2.529>

INTRODUCTION

Patients diagnosed with lower rectal cancer who require sphincter-preserving resection (SPR) have a high risk of postoperative decline in anorectal function. After long-term follow-up after SPR[1,2], > 90% of rectal cancer patients experienced suboptimal recovery of anorectal function, characterized by increased defecation frequency, higher incidence of encopresis, and incontinence of liquid or solid stools, collectively referred to as low anterior resection syndrome (LARS)[3]. Postoperative intestinal dysfunction is a prevalent occurrence in patients with rectal cancer, with an incidence rate ranging from 70% to 90%. Such dysfunction may manifest as periodic alterations in stool consistency, transitioning from dry and rigid to pasty, thereby significantly compromising quality of life[4]. This symptom has been a persistent source of distress for numerous patients, and its resolution without efficacious treatment measures has led to a cascade of physical and psychological ailments[5]. Efficient enhancement of postoperative anorectal function is of utmost importance. Numerous studies on anal function have failed to provide a comprehensive explanation and precise evaluation of postoperative anorectal function impairment. Currently, the evaluation of LARS symptoms in patients is solely reliant on subjective measures, such as questionnaires. There is a lack of a standardized and objective medical assessment index, as well as an absence of an objective index for the systematic classification and grading of symptoms[6]. Consequently, the evaluation and analysis of diagnostic and therapeutic measures for patients with LARS are limited, leading to a dearth of investigations on the prevention and treatment of LARS following anal preservation for rectal cancer. This has resulted in the absence of effective objective evaluation criteria, thereby impeding the progress of research on LARS prevention and treatment over an extended period. Exploration of defecography to assess and quantify compliance of the neorectum after lower rectal cancer surgery is a valuable approach to establish objective diagnostic criteria for LARS rectal magnetic resonance imaging (MRI) defecography, and the pathogenesis of LARS by imaging index.

MATERIALS AND METHODS

Study population

The research cohort comprised 34 patients, aged 18-76 years, who had been diagnosed with lower rectal cancer and had undergone total mesorectal excision (TME) and one-stage intestinal anastomosis within 12 months prior to enrollment. Patients were diagnosed with rectal cancer that was amenable to surgical resection, and whose tumors were situated below the S2 level with a lower margin within 5 cm of the dentate line. The preoperative rectal MRI measurement of the mean distance between the lower border of the tumor and the anal margin was 4.12 ± 1.04 cm. The pathological classification of the observed condition was adenocarcinoma. The diagnosis of T1-3, negative mesorectal fascia or extramural

vascular invasion was determined through rectal MRI. Patients were excluded if they had distant organ metastases, severe cardiac or pulmonary medical disease, gastrointestinal dysfunction or motility disorders, or metabolic, neurogenic or endocrine disease known to cause colonic motility disorders. Patients with anastomotic leakage or requiring multiple dilations of the anastomotic stricture were also excluded. The present study recruited a control group consisting of 26 healthy volunteers, aged 18–60 years, who underwent MRI defecography at the hospital where the research was conducted. The control group exhibited regular bowel patterns, characterized by a frequency of three bowel movements per day to one every 3 d, and was devoid of any gastrointestinal symptoms. The medical records, follow-up data, and postoperative pathology of the patients were comprehensive. The patients were duly informed and provided their consent by signing the informed consent form, subsequently returning to the hospital for the LARS questionnaire and MRI defecography imaging assessment after surgery. The treatment process was consistently overseen by the same surgical team, ensuring uniformity in all procedures and follow-up.

Evaluation of neorectal defecation frequency and MRI-rectal compliance through MRI defecography

Prior to the examination, a standard bowel cleansing protocol was implemented and the bladder was voided 30 min prior to the procedure. The patient assumed a supine position with the head advanced, both arms elevated, and the knees elevated to induce flexion in the lower limbs, followed by administration of static and dynamic MRI scans of the rectum. The United Imaging 1.5 T superconducting MRI served as the examination tool. The pelvic examination site was equipped with an abdominal phased-array coil, and the initial scan conducted was the resting sagittal T2-weighted imaging (T2WI). Subsequently, transverse-axis T2WI, which was perpendicular to the long axis of the anal canal, and oblique coronal T2WI, which was parallel to the long axis of the anal canal, were scanned in the median sagittal position. Prior to the injection of the ultrasonic coupling agent, a predetermined amount of 150–250 mL was weighed and administered through the anal canal. The sagittal localization image was rescanned, and fast imaging employing steady acquisition sequence dynamic defecography scan was performed in the median sagittal position. Patients were instructed to forcefully evacuate the bowel until it was emptied and perform an anal lift. Single-excitation, fast spin-echo sequence T2WI, and resting and maximum force evacuation images were taken in the median sagittal position for dynamic real-time MRI, which lasted 68 s. Finally, the transverse axis of T2WI was scanned; and the coronal dynamic Valsalva maneuver images were also scanned if necessary. The scan layer thickness was 15 mm, interval 0 mm, matrix 272×85 , and field-of-view 250×250 . The coupling agent that was discharged from the patient was gathered and reweighed, and the ratio between the mass of the discharged and injected coupling agents was determined as the defecation rate.

Rectal compliance was assessed using the five-line partition scoring method, and the dynamic images were captured. Six diameters perpendicular to the midline of the intestinal canal were made along the sacral intervertebral space, and the midline and vertical line of the intestinal canal were divided into five regions. Each region was represented by the letters A–E, and each region was defined as two points. The intestinal wall motion of each region was observed during force exclusion. The score of the area can be defined when there is a significant swing of the intestinal wall during defecation (Figures 1 and 2).

Method of follow-up

There was an average follow-up time of 18 months for anal defecation, during which the subjective index of the severity of LARS after the operation was obtained using the LARS Score developed by Danish scholar Emmertsen in 2012[7]. A lower score was indicative of milder symptoms, while a higher score was associated with more severe symptoms. For instance, a score of 0–20 was indicative of mild LARS, 21–29 suggested moderate LARS, and 30–42 indicated severe LARS (Figure 3).

Statistical analysis

SPSS version 26 was used for statistical analysis. The measurement data for the experimental and control groups were presented as mean \pm SD. Comparison between groups was conducted using the independent sample *t* test, while the correlation analysis in the experimental group was performed using Pearson correlation analysis. $P \leq 0.05$ indicated statistical significance.

Biostatistics statement

The statistical methods of this study were reviewed by a member of the Department of Epidemiology and Biostatistics, School of Public Health from Guangxi Medical University.

RESULTS

The LARS scores of each patient in the experimental cohort were consistently monitored at 6 and 12 months post-surgery: 37.02 ± 3.43 vs 32.58 ± 4.91 ($P < 0.001$). The MRI defecation rate and MRI-rectal compliance (MRI-RC) score were utilized to analyze the 34 patients in the experimental group. The MRI defecation rate was $39.47 \pm 0.15\%$ vs $35.53 \pm 0.17\%$ ($P = 0.411$), and the MRI-RC score was 4.41 ± 2.40 vs 4.82 ± 2.92 ($P = 0.165$) 6 and 12 months after surgery, respectively (Table 1). Despite a decrease in the LARS score, the actual anorectal function was not accurately assessed.

The average MRI-RC score and defecation rate in the control group were 8.88 ± 0.90 and $61.19 \pm 0.86\%$, respectively. The MRI-RC score and MRI defecation rate were compared between the experimental and control groups. The experimental group had significantly lower scores for MRI-RC (4.82 ± 2.92 vs 8.88 ± 0.90 ; $P < 0.001$) and defecation rate ($35.53 \pm 0.17\%$ vs $61.19 \pm 0.86\%$; $P = 0.007$) (Table 2). These findings suggest that there was a notable difference in neorectal

Table 1 Evaluation of three different methods in the experimental group 6 months after operation and 12 months after operation

| | Six months after operation | Twelve months after operation | P value |
|-----------------------------------|----------------------------|-------------------------------|---------|
| LARS score (<i>n</i> = 34) | 37.02 ± 4.91 | 32.58 ± 3.43 | < 0.001 |
| Defecation rate% (<i>n</i> = 34) | 39.47 ± 0.15 | 35.53 ± 0.17 | 0.411 |
| MRI-RC score (<i>n</i> = 34) | 4.41 ± 2.40 | 4.82 ± 2.92 | 0.165 |

LARS: Low Anterior Resection Syndrome Score; MRI-RC: Magnetic resonance imaging-rectal compliance.

Table 2 Analysis of the relationship between defecation rate and magnetic resonance imaging-rectal compliance score between experimental group and control group

| | Experimental group (<i>n</i> = 34) | Control group (<i>n</i> = 26) | P value |
|---------------------|-------------------------------------|--------------------------------|---------|
| Defecation rate (%) | 35.53 ± 0.17 | 61.19 ± 0.86 | 0.007 |
| MRI-RC score | 4.82 ± 2.92 | 8.88 ± 0.90 | < 0.001 |

MRI-RC: Magnetic resonance imaging-rectal compliance.

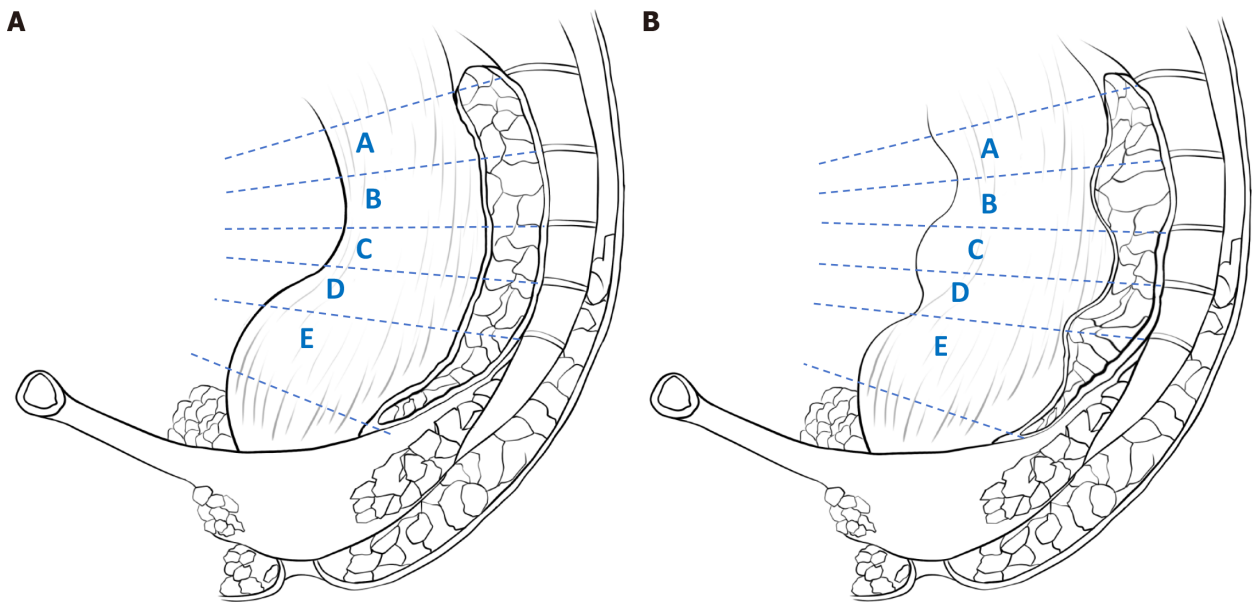


Figure 1 Rectal compliance was assessed by five-line partition scoring. A: The shape of the wall of the intestine in the area where the bowel was at rest; B: Continuous contraction and relaxation of the intestinal wall in the area where the contrast agent passes through the intestine.

function between postoperative patients and normal subjects. Based on the LARS scores, the cohort of 34 patients was stratified into the severe LARS group (*n* = 24) and mild LARS group (*n* = 10). There was a significant difference in defecation rates between the two groups: 29.36 ± 14.17% vs 46.83 ± 18.62% for the severe and mild group, respectively (*P* = 0.004). Additionally, the MRI-RC score was significantly lower in the severe group (3.63 ± 1.96) compared with the mild group (7.0 ± 3.21) (*P* = 0.001) (Table 3). There was a significant relationship between severe and mild LARS as assessed by the two methods. Specifically, the LARS score and MRI-RC score showed a significant negative correlation (*P* < 0.001) and were negatively correlated with defecation rate (*P* = 0.028). Both the LARS score and MRI defecography had the same evaluation effectiveness, as demonstrated in Figures 4 and 5.

DISCUSSION

In experimental model, we used LARS scoring scale which is globally accepted for modeling. Long-term follow-up indicates that patients' perception of LARS-related symptoms evolves over time, with some patients experiencing gradual relief of their symptoms, while others continue to experience LARS symptoms for an extended period. By evaluating the

Table 3 Analysis of the relationship between defecation rate and magnetic resonance imaging-rectal compliance score in severe group and mild group

| | Severe group (<i>n</i> = 24) | Mild group (<i>n</i> = 10) | <i>P</i> value |
|---------------------|-------------------------------|-----------------------------|----------------|
| Defecation rate (%) | 29.36 ± 14.17 | 46.83 ± 18.62 | 0.004 |
| MRI-RC score | 3.63 ± 1.96 | 7.0 ± 3.21 | 0.001 |

MRI-RC: Magnetic resonance imaging-rectal compliance.

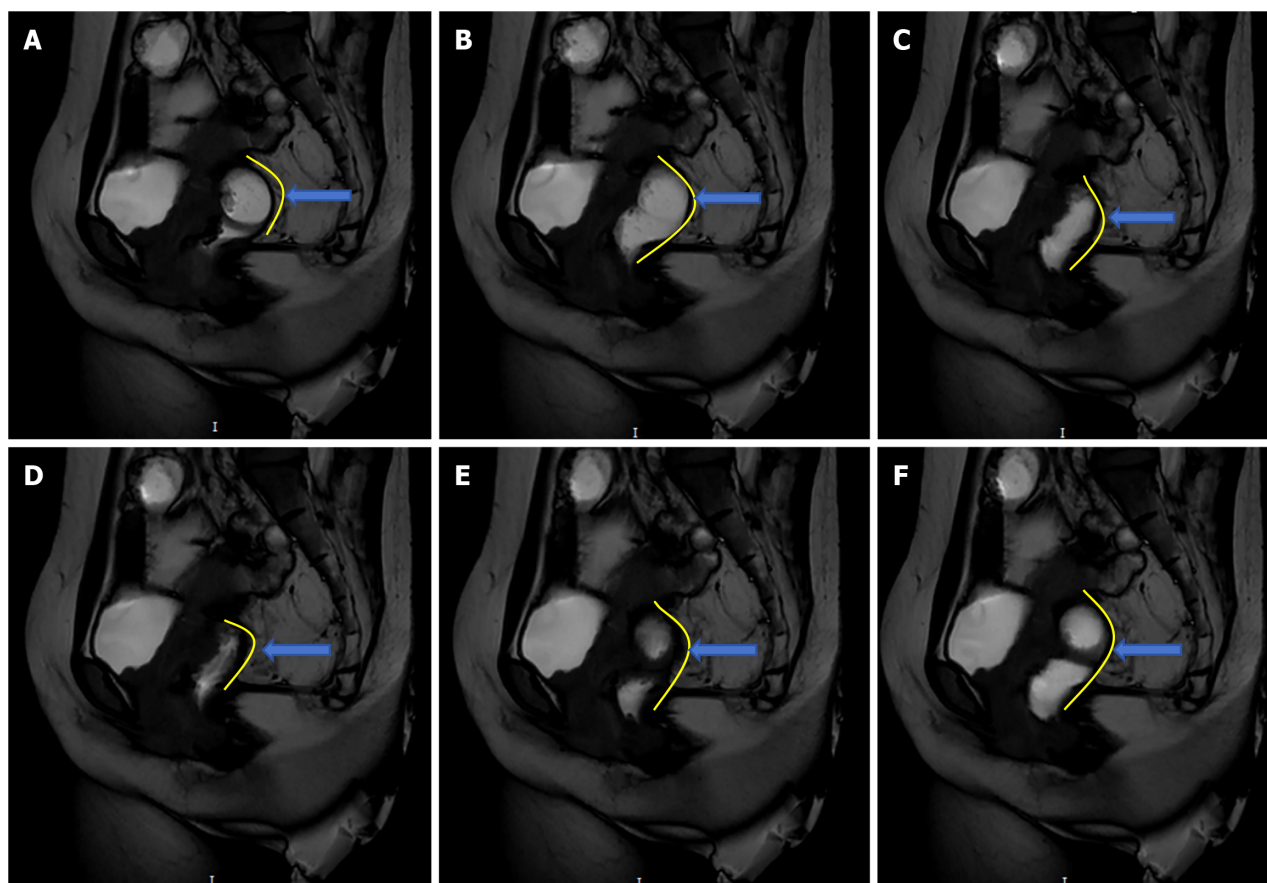


Figure 2 Utilization of magnetic resonance imaging scanning for the acquisition of dynamic and static rectal images. A: Rectum condition in preparation for defecation; B: Rectum deformation at the beginning of defecation; C: Rectum deformation during defecation; D: Rectum deformation after defecation; E: Rectum deformation at the end of defecation; F: Rectum returns to initial state after defecation (contrast agent downward filling in upper segment).

anal function of 34 patients at different time points after surgery, we found that LARS was not a short-term intestinal adaptation process but rather a potentially permanent pathogenic mechanism[8]. However, the LARS score showed subjective variance and immediacy among patients, rendering an accurate and objective evaluation of symptom severity unattainable. Consequently, we developed an imaging-based observation data model that facilitated detection of LARS score in a more intuitive manner. To ascertain the efficacy of the model, we enlisted 26 individuals who were in good health, and subsequently compared them with patients diagnosed with LARS. The data outcomes showed variance in defecation rate and MRI-RC between LARS patients and healthy volunteers. The imaging model successfully identified mild and severe LARS patients, revealing significant differences in defecation rate and MRI-RC score between the two groups. These findings suggest that the newly proposed evaluation model is comparable in effectiveness to the LARS score. Therefore, MRI defecography can be used to study LARS more intuitively compared with LARS score.

Defecation is a complex physiological process that includes synergistic movement of anal inner and outer sphincters, colorectal movement, and neurohormones. Abnormalities in one of the links are highly likely to cause defecation dysfunction[9]. However, the pathophysiological mechanism of LARS remains unclear. Recent research indicates that the pathogenesis may have a strong correlation with the perirectal nerve, muscle injury, neorectal volume, and intestinal compliance, with the latter being potentially the most important factor[10-13]. A considerable quantity of striplike scar images were detected in the postoperative computed tomography images of the pre-rectal sacral soft tissues in most patients. These scar tissues were observed to be firmly attached to the bowel during the surgical procedure, leading to a marked decrease in bowel compliance[14,15]. Currently, the LARS score, multiple quality of life score, fecal incontinence

The Low Anterior Resection Syndrome Score (LARS score)

LARS-score-Scoring Instructions

| | |
|--|----|
| Q1. Do you ever have occasions when you cannot control your flatus (wind)? | |
| <input type="checkbox"/> No, never | 0 |
| <input type="checkbox"/> Yes, less than once per week | 4 |
| <input type="checkbox"/> Yes, at least once per week | 7 |
| Q2. Do you ever have any accidental leakage of liquid stool? | |
| <input type="checkbox"/> No, never | 0 |
| <input type="checkbox"/> Yes, less than once per week | 3 |
| <input type="checkbox"/> Yes, at least once per week | 3 |
| Q3. How often do you open your bowels? | |
| <input type="checkbox"/> More than 7 times per day (24 h) | 4 |
| <input type="checkbox"/> 4-7 times per day (24 h) | 2 |
| <input type="checkbox"/> 1-3 times per day (24 h) | 0 |
| <input type="checkbox"/> Less than once per day (24 h) | 5 |
| Q4. Do you ever have to open your bowels again within one hour of the last bowel opening? | |
| <input type="checkbox"/> No, never | 0 |
| <input type="checkbox"/> Yes, less than once per week | 9 |
| <input type="checkbox"/> Yes, at least once per week | 11 |
| Q5. Do you ever have such a strong urge to open your bowels that you have to rush to the toilet? | |
| <input type="checkbox"/> No, never | 0 |
| <input type="checkbox"/> Yes, less than once per week | 11 |
| <input type="checkbox"/> Yes, at least once per week | 16 |

Add the scores from each 5 answers to one final score

Total Score:

Interpretation:

0-20: No LARS

21-29: Minor LARS

30-42: Major LARS

Figure 3 Low Anterior Resection Syndrome Score. LARS: Low Anterior Resection Syndrome Score.

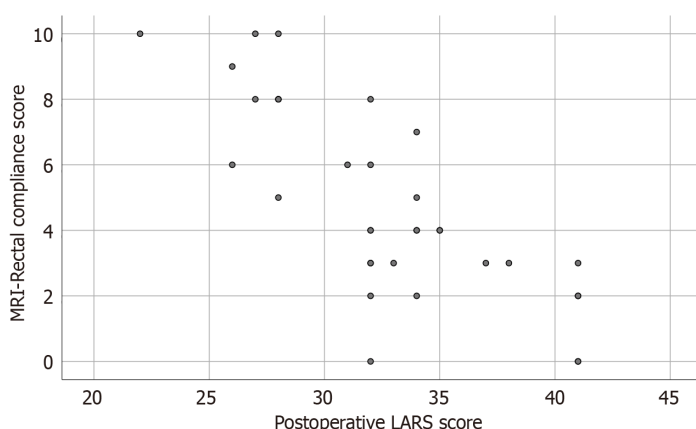


Figure 4 Relationship between postoperative Low Anterior Resection Syndrome Score and magnetic resonance imaging-rectal compliance score. LARS: Low Anterior Resection Syndrome Score; MRI: Magnetic resonance imaging.

score, anorectal manometry, and other techniques are predominantly used; however, these methods exhibit numerous drawbacks in their clinical application[16,17]. There are cultural differences in the evaluation of the symptoms through the LARS score[18]. Despite the widespread use of language and text processing in our country[19], the subjective nature of this approach may result in clinical evaluations that do not align with the actual symptoms in some cases. In clinical settings, the variability of successive measurements for a single patient and the inability of examination results to accurately reflect the long-term function of the intestinal tube pose significant challenges to the research and treatment of LARS[12,20]. This study used rectal MRI defecography to quantify relevant indices and analyze the pathophysiological characteristics of LARS, with the aim of proposing a novel method for assessing intestinal dysfunction following TME. By comparison with normal subjects, rectal MRI defecography showed that neorectal movement characteristics after TME were different from those of normal subjects, in which there were more variations in the defecation process in patients with severe LARS symptoms. In static images, the presacral structure of normal mesenteric tissue was funnel-shaped, and the neorectum formed adhesions due to the unclear presacral structure after TME. In dynamic images, the neorectum had a low degree of activity because of adhesion, and the loss of intestinal pressure gradient conversion led to insufficient defecation. To confirm the variation in defecation after TME, imaging observation of intestinal activity and comparative study of defecation rate showed that the new method directly evaluated the functional status of the neorectum during defecation and complemented LARS score.

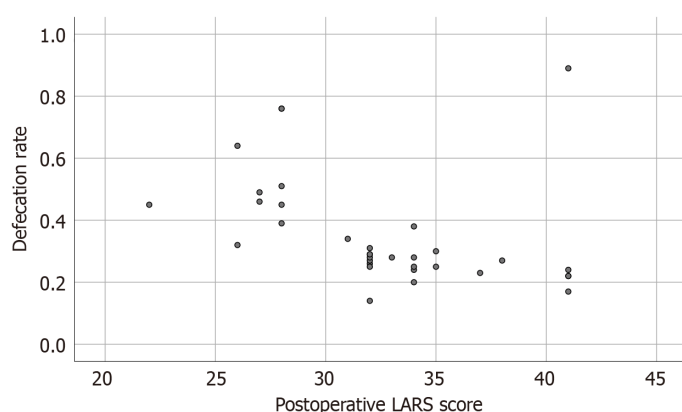


Figure 5 Relationship between postoperative Low Anterior Resection Syndrome Score and defecation rate. LARS: Low Anterior Resection Syndrome Score.

Prior research has solely relied on the LARS score, which is primarily influenced by patients' subjective perceptions, to assess defecation dysfunction[21]. The LARS score gradually tends towards a stable value 6 months after surgery, and tends to change from severe to moderate[22-24]. However, we found that the two groups of data did not reflect significant physiological changes in anorectal function in the new experimental model. The lower MRI-RC score reflects that decreased intestinal compliance is the main factor leading to defecation disorders and high LARS scores. The intestinal motility and compliance were quantitatively analyzed by analyzing the range of motion of the intestinal wall in the dynamic images of MRI defecography combined with weighing the contrast medium. Defecation disorder mainly arises from three features: (1) The formation of a novel perirectal adhesion scar results in rectal stiffness, which impairs the normal physiological processes of contraction and dilatation. The severity of the symptoms associated with LARS is directly proportional to the length of the scar; (2) anastomotic stricture; and (3) the capacity to defecate voluntarily is solely dependent on the abdominal pressure generated by contraction of the abdominal muscles, resulting in disorganized defecation owing to the absence of bowel motility. This is because the rectum of normal people is generally empty and collapsed in a quiescent state. The movement of feces in the colon is usually caused by the reverse pressure gradient transformation of peristaltic waves and the movement mode dominated by the cyclic motor pattern (CMP) of the distal colon[25]. In order to prevent the defecation reflex caused by the rapid filling of the rectum in a short period of time, the above two control modes help to control normal defecation and abstinence[26,27]. The primary point of origin for CMP is located at the junction of the rectum and sigmoid[26]. Observation of patients with intestinal dysfunction after TME shows that, with consideration of the safety of the surgical margin, the upper incisional margin is usually 10 cm away from the tumor, so that the origin of CMP is inevitably removed. The lower digestive tract of patients in our study was reconstructed solely using the partial sigmoid colon and distal residual rectal anastomosis. Defecography images showed that the movement pattern was not observed during defecation, and the transformation process of the pressure gradient of the neorectum was out of balance. When the neorectum loses mesenteric tissue and adheres to the anterior sacrum, the capacity for transport of intestinal contents is reduced, and the next intestinal canal cannot be dilated effectively in the process of propulsion. As a result, a large amount of dynamic energy produced by abdominal pressure cannot be transferred continuously, resulting in the phenomenon of "squeezing toothpaste". The decrease of the degree of dilatation and the range of movement can lead to a significant decrease in the maximum tolerance capacity of the intestine compared with the original rectum (the neorectal volume is fixed in a short time and the later stage increases the intestinal dilatation due to compensation). This is reflects in a decrease of intestinal compliance. For most patients with lower rectal cancer, neorectal compliance is decreased after surgery[14]. However, some scholars believe that the colonic transport capacity of patients with severe LARS is enhanced[28]. This is due to a significant increase in systolic pressure in the neorectum of severe LARS patients caused by increased adhesion tension[29]. In the late recovery of the neorectum, the intestinal canal forms a new pressure gradient, but the intestinal compliance is still not recovered; each defecation can only discharge a small amount of feces, and the intestinal pressure is temporarily reduced. The defecation reflex disappears, and when the intestines push forward a small amount of feces, a new defecation reflex leads to an increase in the number of defecations. Therefore, this phenomenon does not mean that the patient's transport capacity is enhanced, but a sign of reduced intestinal compliance. However, it is worth noting that the loss of anterograde and retrograde CMP may also lead to different symptoms of LARS, such as stool retention and incontinence.

Changes in the anatomical structure of the rectum and presacral fascia after surgery and the establishment of the neorectum cause LARS, which exists for a long time and cannot be cured by any intervention[30]. Research on LARS is mainly based on the subjective feelings of the patients. In the process of long-term tolerance and adaptation, the intestinal canal compensates to increase fecal storage capacity. That is, some patients report that their symptoms have improved, but in these patients, the size of the anastomosis must match the transport capacity of the neorectum in order to have such an effect. One year after TME, the LARS score of patients often returns to a moderate state, and the patients also return to normal work and life. However, defecography images showed that most of the patients still had difficult defecation process, so the evaluation of LARS symptoms could not accurately and objectively reflect the real state. The long-term observation of LARS symptoms does not necessarily indicate gradual recovery, but the adaptation of patients to form new defecation habits.

One limitation of this study was the small sample size. There is heterogeneity in the defecation process of patients with severe LARS, indicating that a large sample size is needed for in-depth comparison in the future. All studies are conducted after intestinal preparation in advance, which is standard practice for defecography, but this may cause spontaneous contraction of the colon, and high-amplitude transmitted contractions may be associated with symptoms such as defecation urgency and incontinence[25]. In the future, it will be valuable to conduct a comprehensive assessment of anorectal function in conjunction with rectal defecography to determine other physiological features that may lead to LARS symptoms, such as neorectal mobility and anal sphincter dysfunction.

The emergence of TME has improved the survival rate of patients with rectal cancer, but the separation of presacral tissue destroys the nervous tissue and aseptic inflammation of the wound leads to intestinal adhesion, which may be an important factor leading to LARS. Although the disease is curable, it can have long-term adverse consequences. The current LARS score method has many drawbacks and its subjectivity is too strong, which hinders research and treatment of LARS. To observe the intestinal compliance more intuitively and quantify it, we developed a five-line zoning scoring method that was more accurate than rectal manometry, and more in line with the true movement status of the intestine. However, the gold standard is still the subjective feelings of patients. We developed an innovative method of MRI defecography to evaluate and quantify neorectal compliance after low rectal cancer surgery. This enabled us to determine the severity of LARS after rectal cancer surgery using an objective clinical evaluation index, and will allow evaluation of future methods of prevention and treatment of LARS.

CONCLUSION

The novel evaluation method of MRI defecography has good potential for diagnosis and evaluation of LARS. It can compensate for the drawback of subjective assessment using the LARS score, and promote exploration of the pathogenesis of LARS.

ARTICLE HIGHLIGHTS

Research background

Over 90% of rectal cancer patients develop low anterior resection syndrome (LARS) after sphincter-preserving resection. Currently, the LARS score, multiple quality of life scores, fecal incontinence score, anorectal manometry, and other techniques are predominantly used to assess LARS.

Research motivation

The LARS score has many drawbacks and its subjectivity is too strong, which hinders research and treatment of LARS.

Research objectives

We aimed to establish a model comparable in effectiveness to the LARS score using magnetic resonance imaging (MRI) defecography, to quantify the severity of LARS, which would be more helpful for evaluation of prevention and treatment of LARS.

Research methods

We assessed 34 patients using the LARS score, and a new LARS evaluation index was established using the dynamic images of MRI defecography to verify the results of the LARS score.

Research results

Severe and mild LARS both differed significantly with the two evaluation methods. There was a significant negative correlation between LARS score and MRI-rectal compliance score, and a negative correlation with the defecation rate.

Research conclusions

MRI defecography and standard LARS scoring method may have similar evaluation effectiveness and can be used to study the pathogenesis of LARS.

Research perspectives

The pathological mechanism leading to LARS symptoms needs a comprehensive physiological study.

ACKNOWLEDGEMENTS

We thank the Department of Radiology, Guangxi Medical University Cancer Hospital for their support of this study.

FOOTNOTES

Co-first authors: Ling-Hou Meng and Bing-Yu Yang.

Author contributions: Qin HQ, He XX and Li Q collected the data; Wang Z, Mo CL, Song QZ and Yang GH analyzed the data; Mo CL and Mo XW discussed the results and revised the final manuscript. All authors critically revised the manuscript and approved of the final version. All authors had full access to all the data in the study and accept responsibility to submit for publication. Together, Meng LH and Yang BY paid the time and energy needed to complete the research and the final paper, assumed the related responsibilities and burdens, and completed the design, preparation, submission and other steps of this research. This also ensures that the quality and reliability of the paper is ultimately improved. And, Meng LH and Yang BY contributed efforts of equal substance throughout the research process, made the most significant intellectual contribution and contributed equally to this work. The choice of these researchers as co-authors acknowledges and respects this equal contribution, while recognizing the spirit of teamwork and collaboration of this study.

Institutional review board statement: The study was reviewed and approved by the Guangxi Medical University Cancer Hospital (Guangxi).

Informed consent statement: All study participants, or their legal guardian, provided informed written consent prior to study enrollment.

Conflict-of-interest statement: There are no conflicts of interest to report.

Data sharing statement: No additional data are available.

STROBE statement: The authors have read the STROBE Statement-checklist of items, and the manuscript was prepared and revised according to the STROBE Statement-checklist of items.

Open-Access: This article is an open-access article that was selected by an in-house editor and fully peer-reviewed by external reviewers. It is distributed in accordance with the Creative Commons Attribution NonCommercial (CC BY-NC 4.0) license, which permits others to distribute, remix, adapt, build upon this work non-commercially, and license their derivative works on different terms, provided the original work is properly cited and the use is non-commercial. See: <https://creativecommons.org/licenses/by-nc/4.0/>

Country/Territory of origin: China

ORCID number: Xian-Wei Mo [0000-0002-7910-9556](https://orcid.org/0000-0002-7910-9556).

S-Editor: Qu XL

L-Editor: A

P-Editor: Zhao S

REFERENCES

- 1 **Nguyen TH**, Chokshi RV. Low Anterior Resection Syndrome. *Curr Gastroenterol Rep* 2020; **22**: 48 [PMID: [32749603](https://pubmed.ncbi.nlm.nih.gov/32749603/) DOI: [10.1007/s11894-020-00785-z](https://doi.org/10.1007/s11894-020-00785-z)]
- 2 **Keane C**, Fearnhead NS, Bordeianou LG, Christensen P, Basany EE, Laurberg S, Mellgren A, Messick C, Orangio GR, Verjee A, Wing K, Bissett I; LARS International Collaborative Group. International Consensus Definition of Low Anterior Resection Syndrome. *Dis Colon Rectum* 2020; **63**: 274-284 [PMID: [32032141](https://pubmed.ncbi.nlm.nih.gov/32032141/) DOI: [10.1097/DCR.0000000000001583](https://doi.org/10.1097/DCR.0000000000001583)]
- 3 **Bryant CL**, Lunniss PJ, Knowles CH, Thaha MA, Chan CL. Anterior resection syndrome. *Lancet Oncol* 2012; **13**: e403-e408 [PMID: [22935240](https://pubmed.ncbi.nlm.nih.gov/22935240/) DOI: [10.1016/S1470-2045\(12\)70236-X](https://doi.org/10.1016/S1470-2045(12)70236-X)]
- 4 **Westerduin E**, Elfeki H, Frontali A, Lakkis Z, Laurberg S, Tanis PJ, Wolthuis AM, Panis Y, D'Hoore A, Bemelman WA, Juul T. Functional Outcomes and Quality of Life after Redo Anastomosis in Patients With Rectal Cancer: An International Multicenter Comparative Cohort Study. *Dis Colon Rectum* 2021; **64**: 822-832 [PMID: [33902088](https://pubmed.ncbi.nlm.nih.gov/33902088/) DOI: [10.1097/DCR.0000000000002025](https://doi.org/10.1097/DCR.0000000000002025)]
- 5 **Pieniowski EHA**, Palmer GJ, Juul T, Lagergren P, Johar A, Emmertsen KJ, Nordenvall C, Abraham-Nordling M. Low Anterior Resection Syndrome and Quality of Life After Sphincter-Sparing Rectal Cancer Surgery: A Long-term Longitudinal Follow-up. *Dis Colon Rectum* 2019; **62**: 14-20 [PMID: [30394987](https://pubmed.ncbi.nlm.nih.gov/30394987/) DOI: [10.1097/DCR.0000000000001228](https://doi.org/10.1097/DCR.0000000000001228)]
- 6 **Bazzell A**, Madsen LT, Dains J. Clinical Management of Bowel Dysfunction After Low Anterior Resection for Rectal Cancer. *J Adv Pract Oncol* 2016; **7**: 618-629 [PMID: [29588867](https://pubmed.ncbi.nlm.nih.gov/29588867/)]
- 7 **Emmertsen KJ**, Laurberg S. Low anterior resection syndrome score: development and validation of a symptom-based scoring system for bowel dysfunction after low anterior resection for rectal cancer. *Ann Surg* 2012; **255**: 922-928 [PMID: [22504191](https://pubmed.ncbi.nlm.nih.gov/22504191/) DOI: [10.1097/SLA.0b013e31824f1c21](https://doi.org/10.1097/SLA.0b013e31824f1c21)]
- 8 **Chen TY**, Wiltink LM, Nout RA, Meershoek-Klein Kranenbarg E, Laurberg S, Marijnen CA, van de Velde CJ. Bowel function 14 years after preoperative short-course radiotherapy and total mesorectal excision for rectal cancer: report of a multicenter randomized trial. *Clin Colorectal Cancer* 2015; **14**: 106-114 [PMID: [25677122](https://pubmed.ncbi.nlm.nih.gov/25677122/) DOI: [10.1016/j.clcc.2014.12.007](https://doi.org/10.1016/j.clcc.2014.12.007)]
- 9 **Bharucha AE**, Wald A, Enck P, Rao S. Functional anorectal disorders. *Gastroenterology* 2006; **130**: 1510-1518 [PMID: [16678564](https://pubmed.ncbi.nlm.nih.gov/16678564/) DOI: [10.1053/j.gastro.2005.11.064](https://doi.org/10.1053/j.gastro.2005.11.064)]
- 10 **Murray RD**, Qualman SJ, Powers P, Caniano DA, McClung HJ, Ulysses B, Li K, Heitlinger LA. Rectal myopathy in chronically constipated children. *Pediatr Pathol* 1992; **12**: 787-798 [PMID: [1448388](https://pubmed.ncbi.nlm.nih.gov/1448388/) DOI: [10.3109/15513819209024235](https://doi.org/10.3109/15513819209024235)]

- 11 **Sarcher T**, Dupont B, Alves A, Menahem B. Anterior resection syndrome: What should we tell practitioners and patients in 2018? *J Visc Surg* 2018; **155**: 383-391 [PMID: [30126800](#) DOI: [10.1016/j.jviscsurg.2018.03.006](#)]
- 12 **Ihnát P**, Vávra P, Prokop J, Pelikán A, Ihnát Rudinská L, Penka I. Functional outcome of low rectal resection evaluated by anorectal manometry. *ANZ J Surg* 2018; **88**: E512-E516 [PMID: [28922706](#) DOI: [10.1111/ans.14207](#)]
- 13 **Martellucci J**. Low Anterior Resection Syndrome: A Treatment Algorithm. *Dis Colon Rectum* 2016; **59**: 79-82 [PMID: [26651116](#) DOI: [10.1097/DCR.0000000000000495](#)]
- 14 **Meng L**, Qin H, Huang Z, Liao J, Cai J, Feng Y, Luo S, Lai H, Tang W, Mo X. Analysis of presacral tissue structure in LARS and the prevention of LARS by reconstruction of presacral mesorectum with pedicled greater omentum flap graft. *Tech Coloproctol* 2021; **25**: 1291-1300 [PMID: [34581900](#) DOI: [10.1007/s10151-021-02521-9](#)]
- 15 **Qin H**, Meng L, Huang Z, Liao J, Feng Y, Luo S, Lai H, Tang W, Mo X. A study on the clinical application of greater omental pedicle flap transplantation to correct anterior resection syndrome in patients with low rectal cancer. *Regen Ther* 2021; **18**: 146-151 [PMID: [34222567](#) DOI: [10.1016/j.reth.2021.05.003](#)]
- 16 **Liao C**, Gao F, Cao Y, Tan A, Li X, Wu D. Meta-analysis of the colon J-pouch vs transverse colectomy pouch after anterior resection for rectal cancer. *Colorectal Dis* 2010; **12**: 624-631 [PMID: [19555386](#) DOI: [10.1111/j.1463-1318.2009.01964.x](#)]
- 17 **Jorge JM**, Wexner SD. Etiology and management of fecal incontinence. *Dis Colon Rectum* 1993; **36**: 77-97 [PMID: [8416784](#) DOI: [10.1007/BF02050307](#)]
- 18 **Juul T**, Ahlberg M, Biondo S, Emmertsen KJ, Espin E, Jimenez LM, Matzel KE, Palmer G, Sauermann A, Trenti L, Zhang W, Laurberg S, Christensen P. International validation of the low anterior resection syndrome score. *Ann Surg* 2014; **259**: 728-734 [PMID: [23598379](#) DOI: [10.1097/SLA.0b013e31828fac0b](#)]
- 19 **Yan JJ**, Mou SY, Tan RF, Wang XH. Empirical Research of the Chinese Version of Low Anterior Resection Syndrome Score (LARS). *Jiefangjun Huli Zazhi* 2015; **32**: 12-15 [DOI: [10.3969/j.issn.1008-9993.2015.04.003](#)]
- 20 **Guerriero O**, Tufano G, Pennetti L, D'Amore E, Sarnella G, Sodano B. Sphincter-saving surgery in low rectal cancer. *Chir Ital* 2006; **58**: 83-92 [PMID: [16729614](#)]
- 21 **Carrillo A**, Enriquez-Navascués JM, Rodríguez A, Placer C, Múgica JA, Saralegui Y, Timoteo A, Borda N. Incidence and characterization of the anterior resection syndrome through the use of the LARS scale (low anterior resection score). *Cir Esp* 2016; **94**: 137-143 [PMID: [26796026](#) DOI: [10.1016/j.ciresp.2015.11.005](#)]
- 22 **Ekkarat P**, Boonpipattanapong T, Tantiphlachiva K, Sangkhathat S. Factors determining low anterior resection syndrome after rectal cancer resection: A study in Thai patients. *Asian J Surg* 2016; **39**: 225-231 [PMID: [26340884](#) DOI: [10.1016/j.asjsur.2015.07.003](#)]
- 23 **Luca F**, Valvo M, Guerra-Cogorno M, Simo D, Blesa-Sierra E, Biffi R, Garberoglio C. Functional results of robotic total intersphincteric resection with hand-sewn coloanal anastomosis. *Eur J Surg Oncol* 2016; **42**: 841-847 [PMID: [27050311](#) DOI: [10.1016/j.ejso.2016.03.007](#)]
- 24 **Beppu N**, Kimura H, Matsubara N, Tomita N, Yanagi H, Yamanaka N. Long-Term Functional Outcomes of Total Mesorectal Excision Following Chemoradiotherapy for Lower Rectal Cancer: Stapled Anastomosis versus Intersphincteric Resection. *Dig Surg* 2016; **33**: 33-42 [PMID: [26569467](#) DOI: [10.1159/000441571](#)]
- 25 **Keane C**, Paskaranandavivel N, Vather R, Rowbotham D, Arkwright J, Dinning P, Bissett I, O'Grady G. Altered colonic motility is associated with low anterior resection syndrome. *Colorectal Dis* 2021; **23**: 415-423 [PMID: [33253472](#) DOI: [10.1111/codi.15465](#)]
- 26 **Lin AY**, Du P, Dinning PG, Arkwright JW, Kamp JP, Cheng LK, Bissett IP, O'Grady G. High-resolution anatomic correlation of cyclic motor patterns in the human colon: Evidence of a rectosigmoid brake. *Am J Physiol Gastrointest Liver Physiol* 2017; **312**: G508-G515 [PMID: [28336544](#) DOI: [10.1152/ajpgi.00021.2017](#)]
- 27 **Rao SS**, Welcher K. Periodic rectal motor activity: the intrinsic colonic gatekeeper? *Am J Gastroenterol* 1996; **91**: 890-897 [PMID: [8633577](#)]
- 28 **Ng KS**, Russo R, Gladman MA. Colonic transit in patients after anterior resection: prospective, comparative study using single-photon emission CT/CT scintigraphy. *Br J Surg* 2020; **107**: 567-579 [PMID: [32154585](#) DOI: [10.1002/bjs.11471](#)]
- 29 **Chan CL**, Lunniss PJ, Wang D, Williams NS, Scott SM. Rectal sensorimotor dysfunction in patients with urge faecal incontinence: evidence from prolonged manometric studies. *Gut* 2005; **54**: 1263-1272 [PMID: [15914573](#) DOI: [10.1136/gut.2005.071613](#)]
- 30 **Keane C**, Wells C, O'Grady G, Bissett IP. Defining low anterior resection syndrome: a systematic review of the literature. *Colorectal Dis* 2017; **19**: 713-722 [PMID: [28612460](#) DOI: [10.1111/codi.13767](#)]



Published by **Baishideng Publishing Group Inc**
7041 Koll Center Parkway, Suite 160, Pleasanton, CA 94566, USA

Telephone: +1-925-3991568

E-mail: office@baishideng.com

Help Desk: <https://www.f6publishing.com/helpdesk>

<https://www.wjgnet.com>

