

World Journal of *Gastrointestinal Surgery*

World J Gastrointest Surg 2024 March 27; 16(3): 635-973



Contents

Monthly Volume 16 Number 3 March 27, 2024

EDITORIAL

- 635 *Ex vivo* liver resection and auto-transplantation and special systemic therapy in perihilar cholangiocarcinoma treatment
Tchilikidi KY
- 641 Indocyanine green: The guide to safer and more effective surgery
Fransvea P, Chiarello MM, Fico V, Cariati M, Brisinda G

MINIREVIEWS

- 650 Alcohol associated liver disease and bariatric surgery: Current perspectives and future directions
Cooper KM, Colletta A, Hebda N, Devuni D
- 658 Applications of gastric peroral endoscopic myotomy in the treatment of upper gastrointestinal tract disease
Chang SY, Jin GH, Sun HB, Yang D, Tang TY

ORIGINAL ARTICLE

Retrospective Cohort Study

- 670 Evaluation of bacterial contamination and medium-term oncological outcomes of intracorporeal anastomosis for colon cancer: A propensity score matching analysis
Kayano H, Mamuro N, Kamei Y, Ogimi T, Miyakita H, Nakagohri T, Koyanagi K, Mori M, Yamamoto S
- 681 Rescue from complications after pancreaticoduodenectomies at a low-volume Caribbean center: Value of tailored peri-pancreatectomy protocols
Cawich SO, Dixon E, Shukla PJ, Shrikhande SV, Deshpande RR, Mohammed F, Pearce NW, Francis W, Johnson S, Bujhawan J
- 689 Comparison of prognosis and postoperative morbidities between standard pancreaticoduodenectomy and the TRIANGLE technique for resectable pancreatic ductal adenocarcinoma
Hang HX, Cai ZH, Yang YF, Fu X, Qiu YD, Cheng H
- 700 Analysis of the impact of immunotherapy efficacy and safety in patients with gastric cancer and liver metastasis
Liu K, Wu CX, Liang H, Wang T, Zhang JY, Wang XT

Retrospective Study

- 710 Clinical observation of extraction-site incisional hernia after laparoscopic colorectal surgery
Fan BH, Zhong KL, Zhu LJ, Chen Z, Li F, Wu WF
- 717 Predicting short-term major postoperative complications in intestinal resection for Crohn's disease: A machine learning-based study
Wang FT, Lin Y, Yuan XQ, Gao RY, Wu XC, Xu WW, Wu TQ, Xia K, Jiao YR, Yin L, Chen CQ

- 731 Analysis of factors impacting postoperative pain and quality of life in patients with mixed hemorrhoids: A retrospective study

Sun XW, Xu JY, Zhu CZ, Li SJ, Jin LJ, Zhu ZD

- 740 Pre-operative visceral adipose tissue radiodensity is a potentially novel prognostic biomarker for early endoscopic post-operative recurrence in Crohn's disease

Gu P, Dube S, Gellada N, Choi SY, Win S, Lee YJ, Yang S, Haritunians T, Melmed GY, Vasiliauskas EA, Bonthala N, Syal G, Yarur AJ, Ziring D, Rabizadeh S, Fleshner P, Kallman C, Devkota S, Targan SR, Li D, McGovern DP

- 751 Clinical study on the relationship between liver cirrhosis, ascites, and hyponatremia

Li XJ, Meng HH

- 759 Comparison of the clinical effects of dual-modality endoscopy and traditional laparotomy for the treatment of intra- and extrahepatic bile duct stones

Wang W, Xia H, Dai B

- 768 Role of ablation therapy in conjunction with surgical resection for neuroendocrine tumors involving the liver

Ostapenko A, Stroeve S, Eyasu L, Kim M, Aploks K, Dong XD, Seshadri R

- 777 Feasibility and safety of minimally invasive multivisceral resection for T4b rectal cancer: A 9-year review

Chan KS, Liu B, Tan MNA, How KY, Wong KY

- 790 MH-STRALP: A scoring system for prognostication in patients with upper gastrointestinal bleeding

Hu JN, Xu F, Hao YR, Sun CY, Wu KM, Lin Y, Zhong L, Zeng X

Clinical Trials Study

- 807 Early postoperative complications after transverse colostomy closure, a retrospective study

Liu F, Luo XJ, Li ZW, Liu XY, Liu XR, Lv Q, Shu XP, Zhang W, Peng D

- 816 Clinical study of enhanced recovery after surgery in laparoscopic appendectomy for acute appendicitis

Li ZL, Ma HC, Yang Y, Chen JJ, Wang ZJ

Observational Study

- 823 Reinforced tissue matrix to strengthen the abdominal wall following reversal of temporary ostomies or to treat incisional hernias

Lake SP, Deeken CR, Agarwal AK

Randomized Controlled Trial

- 833 Whole-process case management effects on mental state and self-care ability in patients with liver cancer

Ju MD, Qin Q, Li M

Clinical and Translational Research

- 842 Construction and validation of somatic mutation-derived long non-coding RNAs signatures of genomic instability to predict prognosis of hepatocellular carcinoma

Duan BT, Zhao XK, Cui YY, Liu DZ, Wang L, Zhou L, Zhang XY

Basic Study

- 860 Influence of different magnetic forces on the effect of colonic anastomosis in rats
Tian BY, Zhang MM, Ma J, Lyu Y, Yan XP
- 871 Inflammatory responses in esophageal mucosa before and after laparoscopic antireflux surgery
Ergun P, Kipcak S, Selvi Gunel N, Yildirim Sozmen E, Bor S
- 882 Etanercept-synthesizing adipose-derived stem cell secretome: A promising therapeutic option for inflammatory bowel disease
Kim SJ, Kim OH, Hong HE, Ju JH, Lee DS

SYSTEMATIC REVIEWS

- 893 Impact of frailty on short-term postoperative outcomes in patients undergoing colorectal cancer surgery: A systematic review and meta-analysis
Zhou Y, Zhang XL, Ni HX, Shao TJ, Wang P

META-ANALYSIS

- 907 Endoscopic-ultrasound-guided biliary drainage with placement of electrocautery-enhanced lumen-apposing metal stent for palliation of malignant biliary obstruction: Updated meta-analysis
Peng ZX, Chen FF, Tang W, Zeng X, Du HJ, Pi RX, Liu HM, Lu XX
- 921 Clinical efficacy and safety of erlotinib combined with chemotherapy in the treatment of advanced pancreatic cancer: A meta-analysis
Liu XY, Pan HN, Yu Y

CASE REPORT

- 932 Link between mutations in *ACVRL1* and *PLA2G4A* genes and chronic intestinal ulcers: A case report and review of literature
Tang YJ, Zhang J, Wang J, Tian RD, Zhong WW, Yao BS, Hou BY, Chen YH, He W, He YH
- 944 Mucinous neoplasm of the appendix: A case report and review of literature
Chang HC, Kang JC, Pu TW, Su RY, Chen CY, Hu JM
- 955 Abdominal cocoon syndrome-a rare culprit behind small bowel ischemia and obstruction: Three case reports
Vipudhamorn W, Juthasilaparut T, Sutharat P, Sanmee S, Supatrakul E
- 966 Endoscopic ultrasound-guided lauromacrogol injection for treatment of colorectal cavernous hemangioma: Two case reports
Zhu HT, Chen WG, Wang JJ, Guo JN, Zhang FM, Xu GQ, Chen HT

ABOUT COVER

Editorial Board Member of *World Journal of Gastrointestinal Surgery*, Jia-Gang Han, MD, Professor, Department of General Surgery, Beijing Chaoyang Hospital, Capital Medical University, Beijing 100020, China. hjg211@163.com

AIMS AND SCOPE

The primary aim of *World Journal of Gastrointestinal Surgery* (WJGS, *World J Gastrointest Surg*) is to provide scholars and readers from various fields of gastrointestinal surgery with a platform to publish high-quality basic and clinical research articles and communicate their research findings online.

WJGS mainly publishes articles reporting research results and findings obtained in the field of gastrointestinal surgery and covering a wide range of topics including biliary tract surgical procedures, biliopancreatic diversion, colectomy, esophagectomy, esophagostomy, pancreas transplantation, and pancreatectomy, *etc.*

INDEXING/ABSTRACTING

The WJGS is now abstracted and indexed in Science Citation Index Expanded (SCIE, also known as SciSearch®), Current Contents/Clinical Medicine, Journal Citation Reports/Science Edition, PubMed, PubMed Central, Reference Citation Analysis, China Science and Technology Journal Database, and Superstar Journals Database. The 2023 Edition of Journal Citation Reports® cites the 2022 impact factor (IF) for WJGS as 2.0; IF without journal self cites: 1.9; 5-year IF: 2.2; Journal Citation Indicator: 0.52; Ranking: 113 among 212 journals in surgery; Quartile category: Q3; Ranking: 81 among 93 journals in gastroenterology and hepatology; and Quartile category: Q4.

RESPONSIBLE EDITORS FOR THIS ISSUE

Production Editor: Zi-Hang Xu, Production Department Director: Xiang Li, Cover Editor: Jia-Ru Fan.

NAME OF JOURNAL

World Journal of Gastrointestinal Surgery

ISSN

ISSN 1948-9366 (online)

LAUNCH DATE

November 30, 2009

FREQUENCY

Monthly

EDITORS-IN-CHIEF

Peter Schemmer

EDITORIAL BOARD MEMBERS

<https://www.wjgnet.com/1948-9366/editorialboard.htm>

PUBLICATION DATE

March 27, 2024

COPYRIGHT

© 2024 Baishideng Publishing Group Inc

INSTRUCTIONS TO AUTHORS

<https://www.wjgnet.com/bpg/gerinfo/204>

GUIDELINES FOR ETHICS DOCUMENTS

<https://www.wjgnet.com/bpg/GerInfo/287>

GUIDELINES FOR NON-NATIVE SPEAKERS OF ENGLISH

<https://www.wjgnet.com/bpg/gerinfo/240>

PUBLICATION ETHICS

<https://www.wjgnet.com/bpg/GerInfo/288>

PUBLICATION MISCONDUCT

<https://www.wjgnet.com/bpg/gerinfo/208>

ARTICLE PROCESSING CHARGE

<https://www.wjgnet.com/bpg/gerinfo/242>

STEPS FOR SUBMITTING MANUSCRIPTS

<https://www.wjgnet.com/bpg/GerInfo/239>

ONLINE SUBMISSION

<https://www.f6publishing.com>



Mucinous neoplasm of the appendix: A case report and review of literature

Hao-Cheng Chang, Jung-Cheng Kang, Ta-Wei Pu, Ruei-Yu Su, Chao-Yang Chen, Je-Ming Hu

Specialty type: Gastroenterology and hepatology

Provenance and peer review:

Unsolicited article; Externally peer reviewed.

Peer-review model: Single blind

Peer-review report's scientific quality classification

Grade A (Excellent): 0
Grade B (Very good): 0
Grade C (Good): C, C
Grade D (Fair): 0
Grade E (Poor): 0

P-Reviewer: Morozov S, Russia; Xu HT, China

Received: November 29, 2023

Peer-review started: November 29, 2023

First decision: December 6, 2023

Revised: December 17, 2023

Accepted: February 22, 2024

Article in press: February 22, 2024

Published online: March 27, 2024



Hao-Cheng Chang, Department of Surgery, Tri-Service General Hospital, Taipei 114, Taiwan

Jung-Cheng Kang, Division of Colon and Rectal Surgery, Department of Surgery, Taiwan Adventist Hospital, Taipei 105, Taiwan

Ta-Wei Pu, Division of Colon and Rectal Surgery, Department of Surgery, Tri-Service General Hospital Songshan Branch, National Defense Medical Center, Taipei 105, Taiwan

Ta-Wei Pu, Chao-Yang Chen, Je-Ming Hu, Division of Colon and Rectal Surgery, Department of Surgery, Tri-Service General Hospital, National Defense Medical Center, Taipei 114, Taiwan

Ruei-Yu Su, Department of Pathology, Tri-Service General Hospital, National Defense Medical Center, Taipei 105, Taiwan

Ruei-Yu Su, Department of Pathology and Laboratory Medicine, Taoyuan Armed Forces General Hospital, Taoyuan 325, Taiwan

Corresponding author: Ta-Wei Pu, MD, Lecturer, Division of Colon and Rectal Surgery, Department of Surgery, Songshan Branch, Tri-Service General Hospital, National Defense Medical Center, No. 131 Jiankang Road, Taipei 105, Taiwan. tawei0131@gmail.com

Abstract

BACKGROUND

Appendiceal mucinous neoplasms (AMNs), although not classified as rare, are relatively uncommon tumors most often discovered incidentally during colorectal surgery. Accurate identification of AMNs is difficult due to non-specific symptoms, overlapping tumor markers with other conditions, and the potential for misdiagnosis. This underscores the urgent need for precision in diagnosis to prevent severe complications.

CASE SUMMARY

This case report describes the unexpected discovery and treatment of a low-grade AMN (LAMN) in a 74-year-old man undergoing laparoscopic hemicolectomy for transverse colon adenocarcinoma (AC). Preoperatively, non-specific gastrointestinal symptoms and elevated tumor markers masked the presence of AMN. The tumor, presumed to be an AMN peritoneal cyst intraoperatively, was confirmed as LAMN through histopathological examination. The neoplasm exhibited mucin accumulation and a distinct immunohistochemical profile: Positive for Homeobox protein CDX-2, Cytokeratin 20, special AT-rich sequence-binding protein

2, and Mucin 2 but negative for cytokeratin 7 and Paired box gene 8. This profile aids in distinguishing appendiceal and ovarian mucinous tumors. Postoperative recovery was uncomplicated, and the patient initiated adjuvant chemotherapy for the colon AC.

CONCLUSION

This case highlights the diagnostic complexity of AMNs, emphasizing the need for vigilant identification to avert potential complications, such as pseudomyxoma peritonei.

Key Words: Adenocarcinoma; Appendiceal neoplasms; Low-grade appendiceal mucinous neoplasm; Peritoneal neoplasms; Pseudomyxoma peritonei; Case report

©The Author(s) 2024. Published by Baishideng Publishing Group Inc. All rights reserved.

Core Tip: Here we present a case of an appendiceal mucinous neoplasm (AMN) incidentally identified during a laparoscopic hemicolectomy performed to treat adenocarcinoma in the transverse colon of a 74-year-old male. This presentation underscores the diagnostic complexity posed by AMNs, which often manifest nonspecifically and may be mistaken for other malignancies. This case highlights the critical role of immunohistochemical analysis in establishing a definitive diagnosis and informing surgical strategy, with a particular focus on averting misdiagnosis and potential complications, such as pseudomyxoma peritonei.

Citation: Chang HC, Kang JC, Pu TW, Su RY, Chen CY, Hu JM. Mucinous neoplasm of the appendix: A case report and review of literature. *World J Gastrointest Surg* 2024; 16(3): 944-954

URL: <https://www.wjgnet.com/1948-9366/full/v16/i3/944.htm>

DOI: <https://dx.doi.org/10.4240/wjgs.v16.i3.944>

INTRODUCTION

Appendiceal mucinous neoplasm (AMN) is an uncommon malignancy originating from the epithelium of the appendix, often incidentally discovered during surgical procedures. Symptoms may be absent or nonspecific, making preoperative identification difficult. In females, elevated tumor markers [carbohydrate antigen 19-9 (CA19-9), CA 125, or carcinoembryonic antigen (CEA)] can lead to misdiagnosis, particularly as ovarian cancer[1-3]. As such, AMN should be considered in the differential diagnosis of asymptomatic right adnexal cystic masses, particularly in postmenopausal women with increased tumor marker levels. Surgical removal, prioritizing the prevention of appendiceal rupture to avoid mucin spread and potential pseudomyxoma peritonei (PMP), is the preferred treatment.

Herein, we report the case of a 74-year-old male in whom a low-grade AMN (LAMN), initially misdiagnosed as a peritoneal cyst, was incidentally discovered during laparoscopic extended right hemicolectomy for transverse colon adenocarcinoma (AC). The patient's preoperative CEA level was elevated at 7.81 ng/mL, and imaging revealed a large cyst in the right lower quadrant of the abdomen. These findings contributed to the initial misdiagnosis of peritoneal cyst, as the possibility of synchronous malignancies was not adequately considered. This case highlights the importance of considering concurrent lesions of different cancers in the differential diagnosis of patients with elevated CEA levels and abdominal cysts, even in the presence of a known malignancy.

CASE PRESENTATION

Chief complaints

A 74-year-old Chinese man presented the gastrointestinal outpatient clinic with gastrointestinal discomfort and occult blood in the stool.

History of present illness

The patient's condition was characterized by an unexplained weight loss and hematochezia for 6 months. Colonoscopy revealed obstructive AC in the transverse colon, causing further investigative challenges (Figures 1 and 2).

History of past illness

The patient underwent extended right hemicolectomy during surgery. A 6 cm transverse colon tumor with regional lymph nodes was excised, along with a 9 cm encapsulated appendiceal mass. Histopathological analysis revealed a 4 cm × 4 cm ulcerative colon tumor infiltrating the muscularis layer and a diffusely enlarged 6 cm × 9 cm appendix with a significantly thinned mucin-filled wall with no solid components (Figure 3A-E). Postoperatively, the patient was extubated and transferred to the intensive care unit (ICU), where he showed an unremarkable postoperative course. Flatus

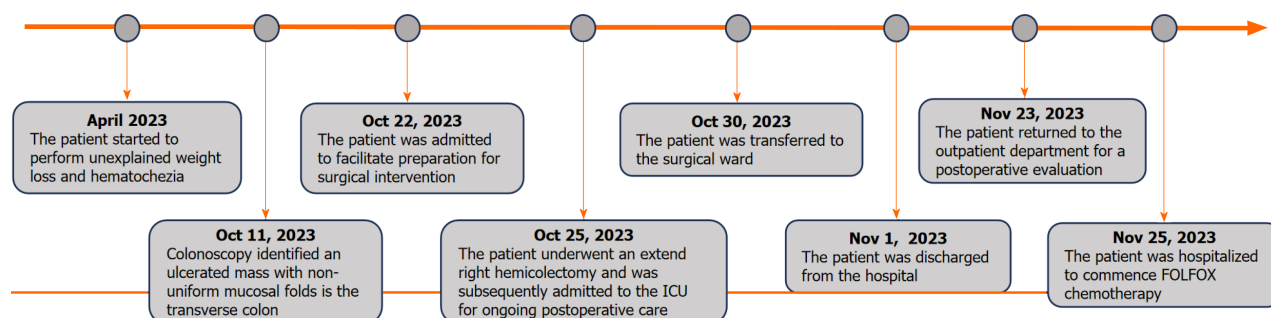


Figure 1 Timeline of the initial diagnosis, surgical intervention, subsequent follow-up period, and adjuvant therapy.

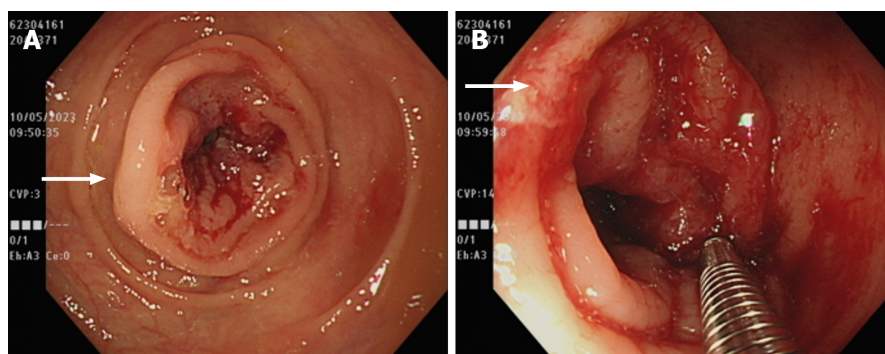


Figure 2 Diagnostic imaging and interventions with the colonoscope. A: Colonoscopic examination revealed a 3-cm ulcerative lesion within the transverse colon, characterized by irregular luminal stenosis (white arrow); B: An attempt was made to obtain a biopsy through the colonoscope for pathological examination (white arrow).

occurred on the second postoperative day, and oral intake was initiated on the third day. After stable progress in the ICU, the patient was moved to the surgical ward on postoperative day 5 and discharged on postoperative day 7, with satisfactory nutritional recovery.

Personal and family history

The patient denied any family history of malignant tumors.

Physical examination

During physical assessment, the patient's vital signs were recorded as follows: Body temperature of 36.0 °C, blood pressure of 100/62 mmHg, heart rate of 55 beats per minute, and respiratory rate of 18 breaths per minute. A subsequent routine health examination revealed an ulcerative mass exhibiting irregular mucosal folds and lumen constriction within the transverse colon, which was histopathologically confirmed as AC.

Laboratory examinations

Preoperative laboratory evaluations revealed a normal complete blood count, including a white blood cell count of 7830/ μ L, red blood cell count of 4250/ μ L, mean corpuscular volume of 87.8 fL, mean corpuscular hemoglobin of 27.5 pg, and mean corpuscular hemoglobin concentration of 31.4 g/dL. The coagulation panel revealed an international normalized ratio of 1.0 and an activated partial thromboplastin time of 34.4 s. Overall, the patient's blood work demonstrated no significant abnormalities. Tumor marker analysis revealed normal alpha-fetoprotein levels (2.80 ng/mL), elevated CEA levels (9.05 ng/mL), and normal CA19-9 levels (12.2 U/mL). Squamous cell carcinoma antigen (0.5 ng/mL) and prostate-specific antigen (0.702 ng/mL) remained within the normal ranges. Postoperative immunohistochemical (IHC) analysis revealed positive expression of epidermal growth factor receptor and intact mismatch repair (MMR) proteins.

Imaging examinations

Computed tomography (CT) and magnetic resonance imaging (MRI) confirmed transverse colon wall thickening and regional lymphadenopathy and identified a 9 cm mesenteric cystic mass, supporting the clinical diagnosis of transverse colon AC (Figures 4 and 5).

Further diagnostic work-up

Pathological examination of the transverse colon revealed a 35.0 cm segment harboring three ulcerative tumors invading the muscularis propria. Two of these tumors were well-differentiated, while the third showed only moderate differentiation. Metastasis was identified in only one of the 26 examined lymph nodes (pT3N1aMx, mpStage IIIB). IHC analysis

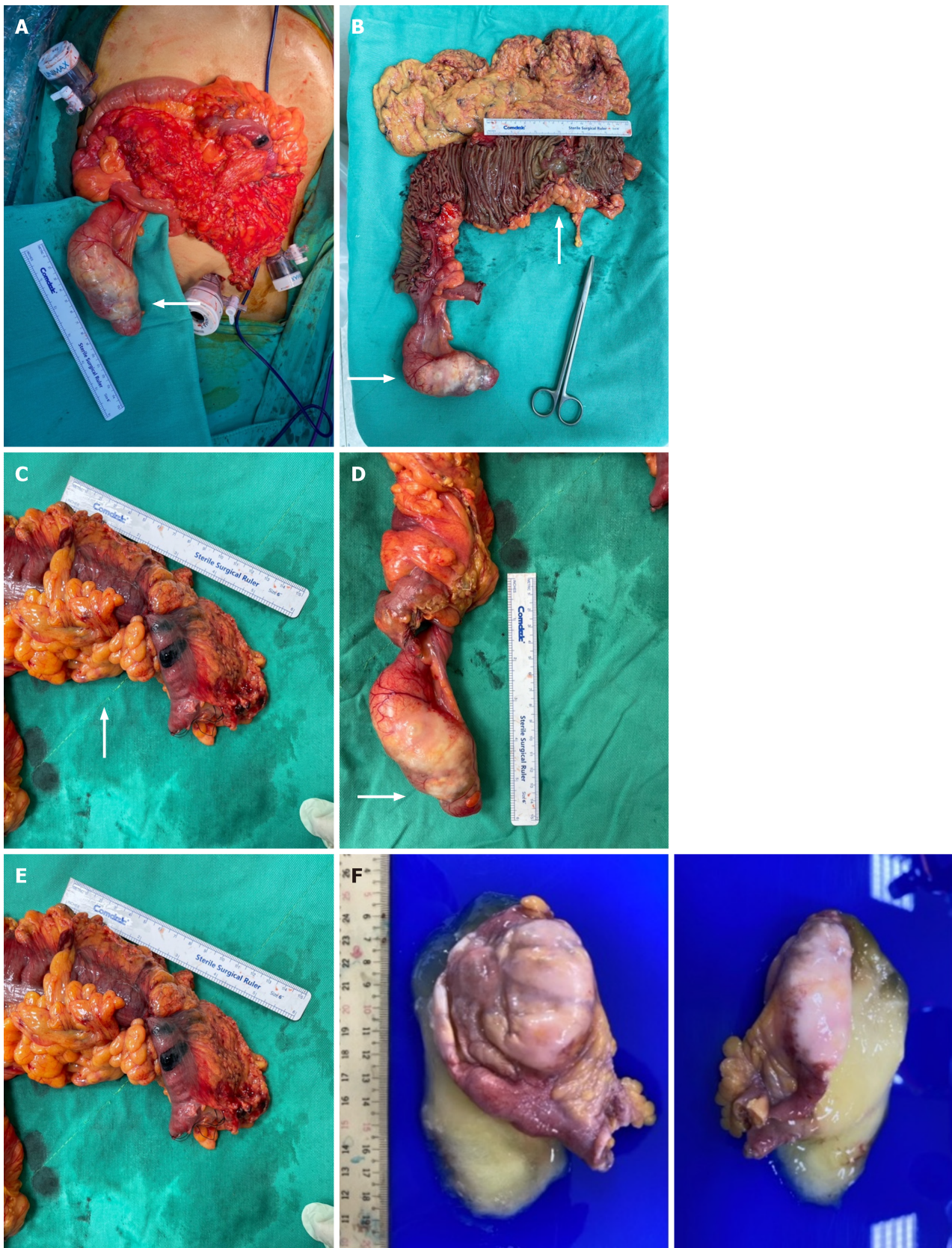


Figure 3 Multistage intraoperative and specimen images of colonic adenocarcinoma and appendiceal mucinous neoplasm. A: Intraoperative photograph depicting the surgical field (white arrow); B: Comprehensive visualization of the adenocarcinoma and appendiceal mucinous neoplasm following an extended right hemicolectomy (white arrows); C: Image of the 6-cm neoplastic lesion located in the transverse colon (white arrow); D: Image of the 9-cm appendiceal mucinous neoplasm, featuring an intact capsular structure; E: Depiction of a large mucinous cavity within the appendix, which simulates a pseudo-diverticulum formation; F: The specimen submitted consists of one tissue fragment, measuring 10.6 cm × 4.0 cm × 3.3 cm in size, fixed in formalin. Grossly, it is opened and filled with mucoid materials.

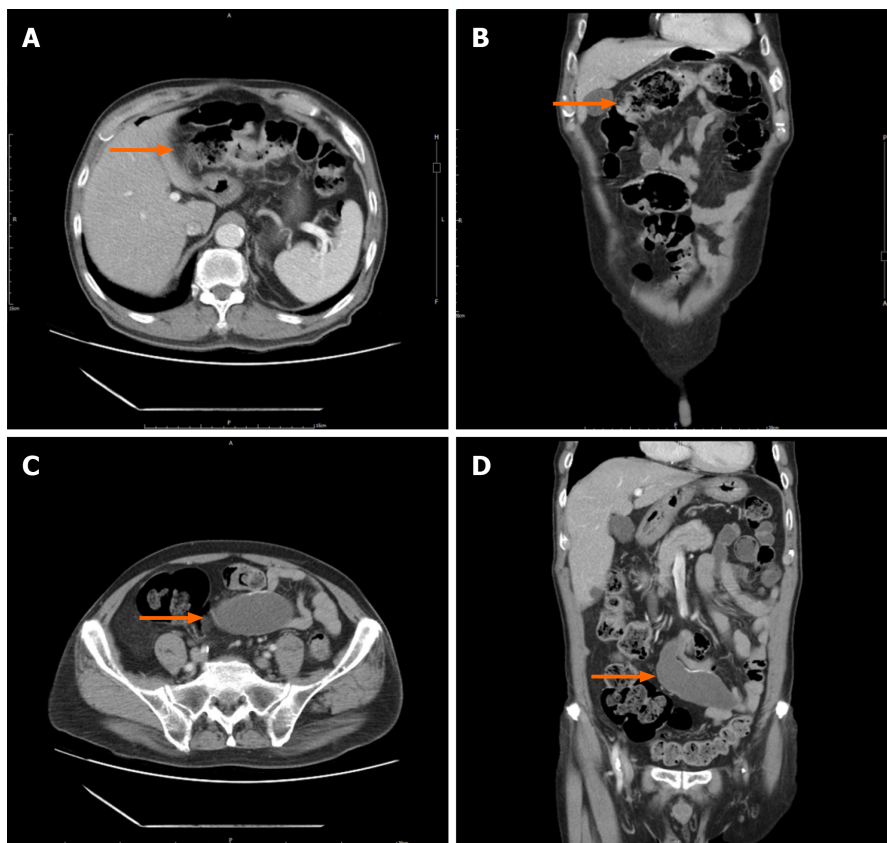


Figure 4 Preoperative abdominal computed tomography image. A and B: The transverse colon wall and regional lymphadenopathy, correlating to a T3N1Mx stage, according to the 8th edition of the American Joint Committee on Cancer cancer staging guidelines (orange arrow); C and D: A cystic formation approximately 9 cm in size was initially detected and interpreted as a mesenteric cyst; subsequent scrutiny ascertained it as an appendiceal mucinous neoplasm (orange arrow).

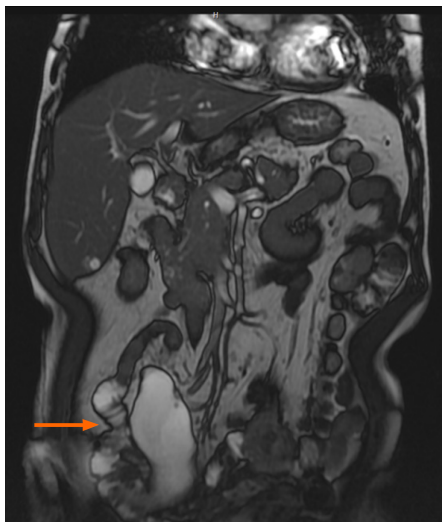


Figure 5 Preoperative coronal 2D Fast Imaging Employing Steady-state Acquisition magnetic resonance imaging of the abdomen revealed a cystic structure measuring approximately 9 cm in the right mesentery. The imaging was conducted with a 1.5 Tesla superconducting magnet and a phased-array body coil. The patient was positioned supine, with the imaging parameters set to a field of view of 40 cm, a slice thickness of 6 mm, and an interslice gap of 1.5 mm. This lesion was subsequently identified as an appendiceal mucinous neoplasm.

confirmed epidermal growth factor receptor positivity (1+) and intact expression of MMR proteins, suggesting a low probability of microsatellite instability-high status.

Examination of the appendiceal lesion revealed a 10.6 cm × 4.0 cm × 3.3 cm LAMN filled with mucinous material (Figure 3F). The neoplasm was lined by tall columnar epithelial cells exhibiting low-grade dysplastic alterations, embedded within a fibrous stromal matrix. IHC markers profiling confirmed the LAMN diagnosis, showing positivity for

homeobox protein CDX-2 (CDX2), cytokeratin 20 (CK20), special AT-rich sequence-binding protein 2 (SATB2), and mucin 2 (MUC2), and negativity for cytokeratin 7 (CK7) and paired box gene 8 (PAX8), as detailed in [Figure 6](#). LAMNs confined by the muscularis propria, such as in the present case, are classified as stage TisN0M0 according to the American Joint Committee on Cancer (AJCC) ninth edition.

FINAL DIAGNOSIS

The patient was finally diagnosed with transverse colon AC, classical subtype, with lymphovascular invasion (mpStage IIIB), and concurrent LAMN, stage TisN0M0.

TREATMENT

In the postoperative phase, the patient exhibited a favorable recovery, culminating in discharge on the seventh day following the surgical procedure. Four weeks after surgery, the patient commenced a chemotherapeutic regimen comprising folinic acid, fluorouracil, and oxaliplatin.

OUTCOME AND FOLLOW-UP

One month following surgery, the patient's CEA levels presented a slight increase (7.81 ng/mL), albeit with a significant decrease compared to the initial reference point. Concurrent chest and abdominal radiographic evaluations showed no abnormalities, and the surgical wound exhibited satisfactory healing.

DISCUSSION

AMN is a relatively rare pathological condition characterized by the cystic dilation of the appendiceal lumen filled with mucinous content. Clinically, AMNs can present with various syndromes, or may be detected incidentally. Epidemiological data suggest that AMNs occur in approximately 0.2%-0.4% of appendectomy specimens and constitute 0.4%-1% of all gastrointestinal malignancies in the United States, with an estimated 1500 new cases each year[1-5].

Individuals with appendiceal tumors may present with non-specific clinical symptoms, leading to potential delays in diagnosis[6,7]. In the early stages of the disease, symptoms may resemble acute appendicitis, often manifesting as right lower quadrant pain, which can be attributed to mucin-induced distension of the appendix[8]. Complications such as appendicitis or perforation of the appendix can occur if the neoplasm obstructs the appendiceal lumen. A previous study reported that 32% of patients with appendiceal neoplasms are preliminarily diagnosed with acute appendicitis before surgery, and in 23% of cases, the diagnosis is incidental[9].

In the advanced stages of the disease, patients may exhibit increased abdominal girth, often due to the accumulation of mucinous ascitic fluid within the peritoneal cavity. Other clinical features at this stage may include chronic abdominal pain, significant weight loss, anemia, infertility, and the development of umbilical or inguinal hernias[6,10]. Although mucinous implants are frequently found on peritoneal, serosal, and omental layers, the initial presentation involving intestinal obstruction is uncommon[11,12].

Preoperative diagnosis of appendiceal mucocoeles poses significant challenges owing to its typically asymptomatic nature and non-specific clinical manifestations. Diagnostic imaging techniques, such as ultrasound and CT, are commonly used to detect these lesions. CT scans are particularly useful, often revealing well-circumscribed, round, cystic lesions with thin walls; in addition, calcifications are observed in approximately 55% of instances[13,14]. Enhanced nodules within the mucocoele wall suggest cystadenocarcinoma[15]. Mucocoeles < 2 cm rarely exhibit malignant features[16-18], whereas those < 6 cm are frequently associated with cystadenoma or cystadenocarcinoma, carrying a perforation risk of approximately 20%[19-21]. CT may also show scalloping effects, indicative of malignancy, resulting from mucin-secreting cells adhering to static areas within the gut lumen that are later dislodged by peristalsis. Ultrasound can provide additional insights, sometimes showing a cystic structure adherent to the cecum with an "onion skin" pattern. Colonoscopy offers supplementary diagnostic insights, occasionally identifying a submucosal mass with a yellowish hue over the cecum[20]. Rarely, the "volcano sign"-describing an appendiceal orifice centered within the mass-can be observed[16,21]. Despite these diagnostic tools, a precise preoperative diagnosis is confirmed in only approximately 30% of the patients. Comprehensive evaluation is imperative for individuals diagnosed with appendiceal mucocoele to rule out synchronous neoplastic conditions[16].

Historically, the taxonomy of appendiceal ACs has been debated, yielding disparate conclusions. The Peritoneal Surface Oncology Group International consensus provides a classification system for appendiceal and peritoneal lesions[22-24]. Appendiceal mucinous lesions are histologically categorized as non-neoplastic or neoplastic epithelial lesions. The neoplastic forms can be further subdivided into serrated polyps, hyperplastic polyps, LAMNs, high-grade AMNs, and mucinous ACs. An accurate histopathological analysis of the entire appendiceal specimen is critical to ensure an accurate diagnosis. Specifically, the identification of epithelial invasion within the appendiceal wall is pivotal for distinguishing

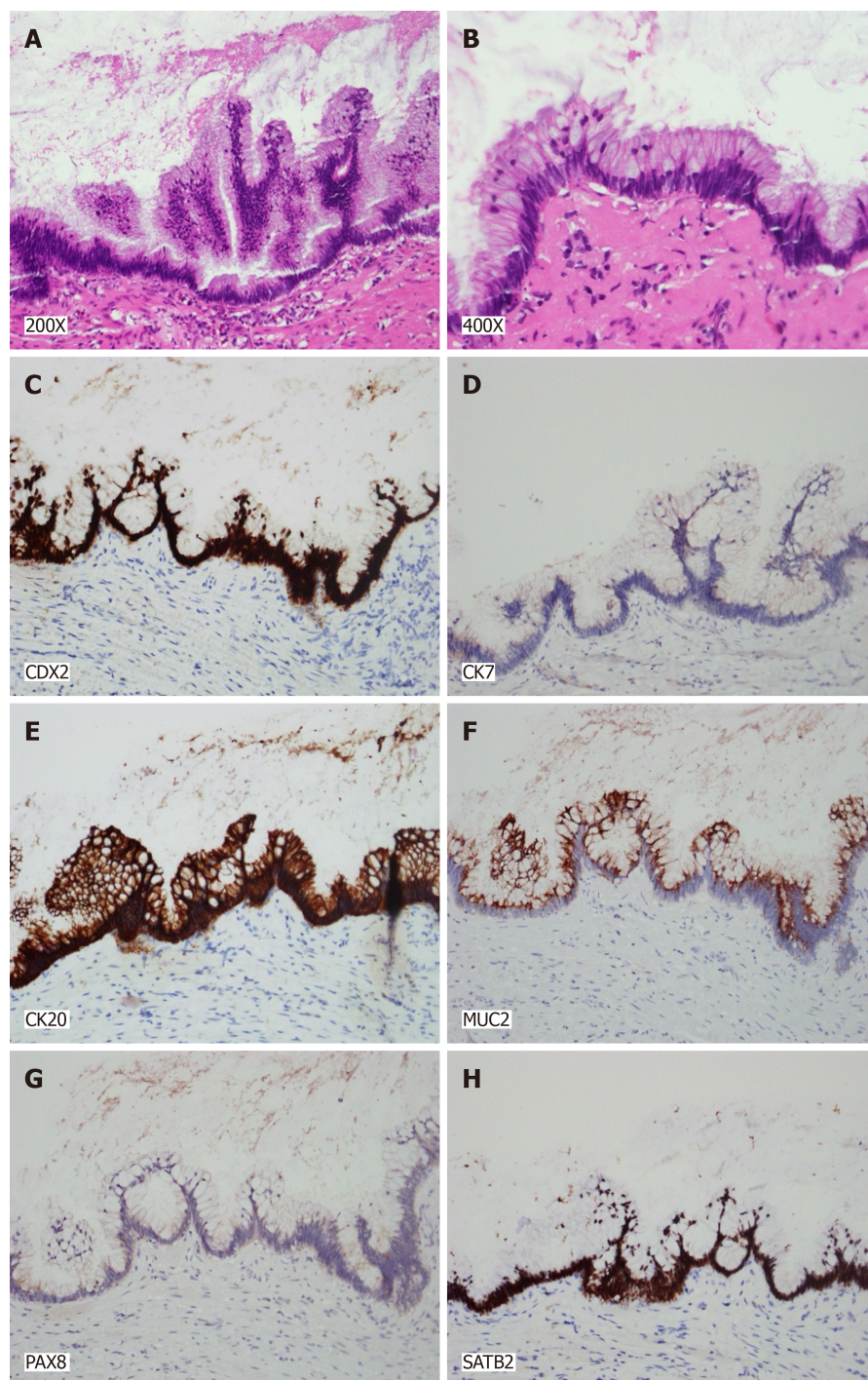


Figure 6 Histological examination of the lesion revealing characteristic patterns. A: A 200 × magnification image showing slender villi lined by tall mucinous epithelial cells with low-grade dysplasia; B: A 400 × magnification image demonstrating tall mucinous epithelial cells with low-grade dysplasia, set within a fibrous stromal framework; C: Immunohistochemical staining displaying positive CDX2 expression in the villous cells; D: Immunohistochemical staining displaying positive CDX20 expression in the villous cells; E: Immunohistochemical staining displaying positive SATB2 expression in the villous cells; F: Immunohistochemical staining displaying positive MUC2 expression in the villous cells; G: Immunohistochemical staining showing the villous cells negative for CK7; H: Immunohistochemical staining showing the villous cells negative for PAX8. Collective histopathological and immunohistochemical findings indicate the lesion to be a low-grade appendiceal mucinous neoplasm. The evaluation of surgical margins shows no neoplastic presence, indicating a clear disease-free status.

ACs from other mucinous lesions. The presence of this key histological indicator can be challenging to ascertain as overt invasion may not be evident and may instead present as fibrotic attenuation of the mural layers, with or without mucin penetration. Current classification systems for these neoplastic lesions take into account the histological appearance of the epithelial layer and the pattern of involvement of the appendiceal wall[9,22].

In the realm of AMNs, the TNM classification system delineated by the AJCC serves as a preliminary framework for staging. This system involves methodical evaluation of the dimensions and invasion depth of the primary tumor, the extent of lymph node involvement, presence of distant metastasis, and histological grade[25]. Distinctions in survival rates are apparent when comparing non-mucinous tumors with mucinous histology.

In a previous study, in the cohort with non-mucinous histologic types, 5-year survival rates were 90.34%, 87.97%, 75.47%, and 59.84% for stages I, IIA, IIB, and IIC, respectively. Notably, patients with stages IIIA and IIIB disease exhibited more favorable prognoses, with 5-year survival rates of 82.02% and 64.07%, respectively. Conversely, the prognosis declined precipitously for patients with stage IVA, IVB, and IVC disease, with survival rates of only 34.84%, 23.50%, and 14.18%, respectively[26].

Despite the in-situ nature of the AMN, the possibility of metastasis must still be considered. In our case, the patient had coexisting transverse colon cancer, specifically the classical AC subtype, which virtually eliminated the possibility of a metastatic origin for the AMN. However, it is important to remember that colon tumors can exhibit a range of subtypes. Currently, four main subtypes are recognized: Classical AC, mucinous AC (MAC), signet-ring cell carcinoma, and mixed subtypes[27-29]. Of note, MAC may also develop in the colon, meaning that metastatic concerns should not be excluded. To date, no studies have yet reported a double tumor of MACs due to its rarity.

In contrast to patients with non-mucinous tumors, patients with mucinous and signet ring cell appendiceal cancers demonstrated a more systematic hierarchical order in 5-year overall survival rates when grouped by pathological stage. Specifically, individuals with mucinous histology at stage I had a 5-year survival rate of 92.80%, with a sequential decrease noted across advancing stages: 84.32% for stage IIA, 79.71% for stage IIB, 72.07% for stage IIC, 58.01% for stage IIIA to IIIC, 63.25% for stage IVA to IVB, and 46.81% for stage IVC[26]. Moreover, the survival metrics for patients presenting with signet ring cell histology were as follows: 86.67% for stage I, which decreased to 60.82% for stages IIA through IIIC, and markedly lower for stages IVA through IVB at 10.26%, with stage IVC disease showing a survival rate of 12.81%[26].

The management strategy for AMN is contingent upon the initial diagnostic findings, particularly the presence of perforation. A treatment algorithm for AMNs, as proposed by Govaerts *et al*[30] and Shaib *et al*[31], is depicted in Figure 7. Appendectomy is generally prescribed for straightforward mucoceles. To rule out mucinous AC, histopathological evaluation of frozen sections of the appendiceal base is recommended[18,30]. In cases of mucinous AC without perforation and mesenteric lymph node involvement or encroachment on surrounding tissues, a simple appendectomy coupled with mesenteric excision is often deemed adequate[30,31]. In contrast, in instances where diagnostic ambiguity prevails, a more aggressive surgical approach, such as cecal resection, right hemicolectomy, or cytoreductive surgery, may be recommended[31]. A thorough abdominal assessment is considered crucial for all patients undergoing surgical treatment for AMN[18,30-32].

Surgical excision of benign mucocoele, mucosal hyperplasia, and mucinous AC typically results in excellent outcomes, with 5-year survival rates reported ranging between 90% and 100%[18,26]. The development of recurrent disease following resection, such as PMP or metachronous colonic carcinoma, is a relatively rare event[18]. Likewise, mucinous AC that remain localized in the appendix and have not invaded the base or adjacent organs are associated with highly favorable prognoses. Nevertheless, in cases with peritoneal spread or PMP, the 5-year survival rates are significantly reduced, dropping to approximately 25%[13].

Postoperative histopathological assessment of AMN relies heavily on mucin detection. AMNs characteristically exhibit consistent positivity for CK20 in all cases (100%), with CK7 negativity in 71% of cases. Additionally, these neoplasms frequently express Mucin-5AC (86%) and deleted in Pancreatic Cancer-4/Mothers against decapentaplegic homolog 4 (100%). It is worth noting that both colorectal carcinoma and appendiceal tumors typically present with a patchy CK7 and a diffuse CK20 staining pattern[33,34]. However, distinguishing primary ovarian mucinous tumors from AMNs that have metastasized to the ovary presents diagnostic difficulties owing to similarities in the morphological characteristics and IHC profiles of conventional markers. Strickland *et al*[35] suggested the utility of additional markers, including SATB2, CK20, MUC2, and PAX8, in the differential diagnosis. SATB2 is positive in 93.8% of appendiceal tumors and is rarely positive in ovarian tumors, demonstrating 97.5% specificity for the appendiceal origin. CK20, CDX2, and MUC2 are typically strongly and diffusely positive in appendiceal tumors, whereas ovarian tumors may exhibit positivity, but with a patchy distribution and less intensity. CK7 expression was observed in 97.5% of ovarian tumors compared to 31.2% of appendiceal tumors. PAX8 is positive in 70% of ovarian tumors but is consistently negative in appendiceal tumors. These markers are recommended as markers for the evaluation of ovarian mucinous tumors, particularly when clinical or pathological indications suggest a secondary origin.

Our case serves as a pertinent example of the diagnostic intricacies associated with AMNs and underscores the importance of their consideration in differential diagnoses, especially when a right adnexal or mesenteric mass is detected *via* imaging. Initially, the rarity of AMNs led to the misinterpretation of the cystic fluid observed on CT and MRI as a simple cyst, inadvertently posing the risk of PMP. Furthermore, the patient's elevated tumor marker levels and gastrointestinal symptoms could have been erroneously ascribed to primary AC. Overall, this case highlights the critical clinical, diagnostic, and therapeutic conundrums posed by AMNs, emphasizing the need for increased clinical vigilance to prevent misdiagnosis and ensure optimal treatment strategies, particularly in individuals undergoing colorectal cancer surgery.

The histopathological evaluation of the tumor in the present case demonstrated IHC positivity for CDX2, CK20, SATB2, and MUC2 and negativity for CK7 and PAX8, confirming the diagnosis of a LAMN. This immunoprofile is emblematic of neoplasms emanating from the appendiceal epithelium, providing a critical distinction between gastrointestinal and ovarian mucinous tumors that exhibit variant marker expression. As such, this case report details the innovative application of IHC analysis for the characterization of AMNs. While AMNs are relatively uncommon, accurate diagnosis and classification is critical for optimal patient management. Further, despite their clinical significance, the IHC properties of AMNs remain largely underreported in the literature. This lack of data poses a significant challenge for pathologists seeking definitive diagnoses and classifications for these neoplasms. Our report presents valuable confirmatory evidence for the IHC profile of AMN. Through a comprehensive analysis of IHC markers, we were able to definitively diagnose and classify AMN in our patient. This information played a pivotal role in guiding appropriate treatment decisions.

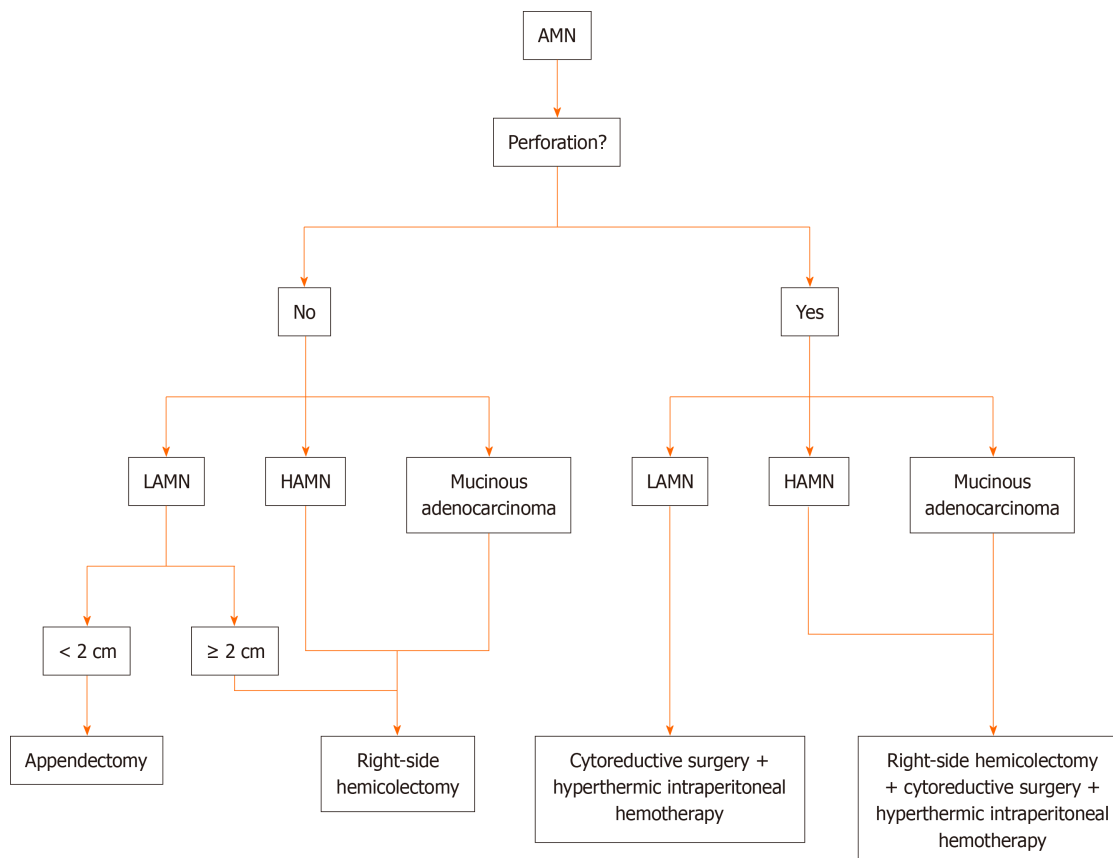


Figure 7 Treatment recommendations for appendiceal mucinous neoplasms (adapted from Govaerts *et al*[30] and Shaib *et al*[31]). LAMN: Low-grade appendiceal mucinous neoplasm; AMN: Appendiceal mucinous neoplasm; HAMN: High-grade Appendiceal Mucinous Neoplasm.

The strategic application of IHC analysis, as demonstrated in this case report, significantly enhances our ability to accurately identify the origin of and to classify neoplasms. This improved accuracy is crucial for optimal patient management, enabling more tailored and effective therapeutic decision-making. For example, given the shared features between AMNs and ovarian mucinous tumors, female patients with AMNs require a more thorough examination due to the high potential for association. For example, in such cases, SATB2 staining can be particularly helpful for diagnosing ovarian metastases of a LAMN[36]. Furthermore, this report contributes significantly to the development of a comprehensive database for future research endeavors. By providing confirmatory evidence of the IHC profile of AMNs, this report lays the basis for a deeper understanding of these neoplasms and the refinement of diagnostic and therapeutic approaches. In conclusion, IHC analysis offers a valuable tool for the characterization of AMNs. This case report highlights the innovative use of these techniques and underscores their potential to improve diagnostic accuracy and inform therapeutic decision-making. As we continue to accumulate data and build a comprehensive database, we will further refine our understanding of AMNs and develop more effective management strategies for patients with this rare but important disease.

CONCLUSION

AMNs, a heterogeneous group of tumors, are rarely diagnosed before elective surgery, while treatment is guided by both stage and histopathology. Early-stage, low-grade tumors typically require surgical excision, while the optimal management of high-grade tumors remains unclear and necessitates further clinical research. Current treatment options for advanced disease include cytoreductive surgery followed by hyperthermic intraperitoneal chemotherapy, with preoperative chemotherapy potentially playing an adjunctive role. Although IHC examination is widely accepted as important for the pathological diagnosis of LAMN, and several novel markers have been proposed, it is crucial to remember that immunohistochemistry is not entirely specific and should not be solely relied upon for diagnosis. Clinical and imaging findings remain paramount in diagnosis and treatment decisions. Overall, the diverse treatment landscape for AMNs highlights the critical need for a more comprehensive understanding of this disease.

FOOTNOTES

Author contributions: Chang HC, Kang JC, Pu TW, Chen CY and Hu JM designed and performed the research; Chang HC, Kang JC, and Pu TW performed surgery; Chang HC wrote the manuscript; Su RY analyzed the histopathology specimens.

Informed consent statement: Informed written consent was obtained from the patient for publication of this report and any accompanying images.

Conflict-of-interest statement: The authors declare that they have no conflicts of interest to disclose.

CARE Checklist (2016) statement: The authors have read the CARE Checklist (2016), and the manuscript was prepared and revised according to the CARE Checklist (2016).

Open-Access: This article is an open-access article that was selected by an in-house editor and fully peer-reviewed by external reviewers. It is distributed in accordance with the Creative Commons Attribution NonCommercial (CC BY-NC 4.0) license, which permits others to distribute, remix, adapt, build upon this work non-commercially, and license their derivative works on different terms, provided the original work is properly cited and the use is non-commercial. See: <https://creativecommons.org/licenses/by-nc/4.0/>

Country/Territory of origin: Taiwan

ORCID number: Hao-Cheng Chang 0009-0008-7983-3203; Jung-Cheng Kang 0000-0001-7511-5337; Ta-Wei Pu 0000-0002-0538-407X; Ruei-Yu Su 0000-0001-6728-8705; Chao-Yang Chen 0000-0002-2246-7635; Je-Ming Hu 0000-0002-7377-0984.

S-Editor: Qu XL

L-Editor: A

P-Editor: Xu ZH

REFERENCES

- 1 Yakan S, Caliskan C, Uguz A, Korkut M, Çoker A. A Retrospective Study on Mucocoele of the Appendix Presented with Acute Abdomen or Acute Appendicitis. *Hong Kong J Emerg Med* 2011; **18**: 144-149 [DOI: [10.1177/102490791101800303](https://doi.org/10.1177/102490791101800303)]
- 2 Minni F, Petrella M, Morganti A, Santini D, Marrano D. Giant mucocoele of the appendix: report of a case. *Dis Colon Rectum* 2001; **44**: 1034-1036 [PMID: [11496084](https://pubmed.ncbi.nlm.nih.gov/11496084/) DOI: [10.1007/bf02235492](https://doi.org/10.1007/bf02235492)]
- 3 Fujiwara T, Hizuta A, Iwagaki H, Matsuno T, Hamada M, Tanaka N, Orita K. Appendiceal mucocoele with concomitant colonic cancer. Report of two cases. *Dis Colon Rectum* 1996; **39**: 232-236 [PMID: [8620794](https://pubmed.ncbi.nlm.nih.gov/8620794/) DOI: [10.1007/bf02068082](https://doi.org/10.1007/bf02068082)]
- 4 McCusker ME, Coté TR, Clegg LX, Sobin LH. Primary malignant neoplasms of the appendix: a population-based study from the surveillance, epidemiology and end-results program, 1973-1998. *Cancer* 2002; **94**: 3307-3312 [PMID: [12115365](https://pubmed.ncbi.nlm.nih.gov/12115365/) DOI: [10.1002/cncr.10589](https://doi.org/10.1002/cncr.10589)]
- 5 COLLINS DC. 71,000 HUMAN APPENDIX SPECIMENS. A FINAL REPORT, SUMMARIZING FORTY YEARS' STUDY. *Am J Proctol* 1963; **14**: 265-281 [PMID: [14098730](https://pubmed.ncbi.nlm.nih.gov/14098730/)]
- 6 Ito H, Osteen RT, Bleday R, Zinner MJ, Ashley SW, Whang EE. Appendiceal adenocarcinoma: long-term outcomes after surgical therapy. *Dis Colon Rectum* 2004; **47**: 474-480 [PMID: [14978617](https://pubmed.ncbi.nlm.nih.gov/14978617/) DOI: [10.1007/s10350-003-0077-7](https://doi.org/10.1007/s10350-003-0077-7)]
- 7 Sugarbaker PH. New standard of care for appendiceal epithelial neoplasms and pseudomyxoma peritonei syndrome? *Lancet Oncol* 2006; **7**: 69-76 [PMID: [16389186](https://pubmed.ncbi.nlm.nih.gov/16389186/) DOI: [10.1016/s1470-2045\(05\)70539-8](https://doi.org/10.1016/s1470-2045(05)70539-8)]
- 8 Bradley RF, Stewart JH 4th, Russell GB, Levine EA, Geisinger KR. Pseudomyxoma peritonei of appendiceal origin: a clinicopathologic analysis of 101 patients uniformly treated at a single institution, with literature review. *Am J Surg Pathol* 2006; **30**: 551-559 [PMID: [16699309](https://pubmed.ncbi.nlm.nih.gov/16699309/) DOI: [10.1097/01.pas.0000202039.74837.7d](https://doi.org/10.1097/01.pas.0000202039.74837.7d)]
- 9 Carr NJ, McCarthy WF, Sobin LH. Epithelial noncarcinoid tumors and tumor-like lesions of the appendix. A clinicopathologic study of 184 patients with a multivariate analysis of prognostic factors. *Cancer* 1995; **75**: 757-768 [PMID: [7828125](https://pubmed.ncbi.nlm.nih.gov/7828125/) DOI: [10.1002/1097-0142\(19950201\)75:3<757::aid-cncr2820750303>3.0.co;2-f](https://doi.org/10.1002/1097-0142(19950201)75:3<757::aid-cncr2820750303>3.0.co;2-f)]
- 10 Garg PK, Prasad D, Aggarwal S, Mohanty D, Jain BK. Acute intestinal obstruction: an unusual complication of mucocoele of appendix. *Eur Rev Med Pharmacol Sci* 2011; **15**: 99-102 [PMID: [21381505](https://pubmed.ncbi.nlm.nih.gov/21381505/)]
- 11 Rutledge RH, Alexander JW. Primary appendiceal malignancies: rare but important. *Surgery* 1992; **111**: 244-250 [PMID: [1542852](https://pubmed.ncbi.nlm.nih.gov/1542852/)]
- 12 Young RH. Pseudomyxoma peritonei and selected other aspects of the spread of appendiceal neoplasms. *Semin Diagn Pathol* 2004; **21**: 134-150 [PMID: [15807473](https://pubmed.ncbi.nlm.nih.gov/15807473/) DOI: [10.1053/j.semdp.2004.12.002](https://doi.org/10.1053/j.semdp.2004.12.002)]
- 13 Isaacs KL, Warshauer DM. Mucocoele of the appendix: computed tomographic, endoscopic, and pathologic correlation. *Am J Gastroenterol* 1992; **87**: 787-789 [PMID: [1590322](https://pubmed.ncbi.nlm.nih.gov/1590322/)]
- 14 Pickhardt PJ, Levy AD, Rohrmann CA Jr, Kende AI. Primary neoplasms of the appendix: radiologic spectrum of disease with pathologic correlation. *Radiographics* 2003; **23**: 645-662 [PMID: [12740466](https://pubmed.ncbi.nlm.nih.gov/12740466/) DOI: [10.1148/rg.233025134](https://doi.org/10.1148/rg.233025134)]
- 15 Chiou YY, Pitman MB, Hahn PF, Kim YH, Rhea JT, Mueller PR. Rare benign and malignant appendiceal lesions: spectrum of computed tomography findings with pathologic correlation. *J Comput Assist Tomogr* 2003; **27**: 297-306 [PMID: [12794590](https://pubmed.ncbi.nlm.nih.gov/12794590/) DOI: [10.1097/00004728-200305000-00001](https://doi.org/10.1097/00004728-200305000-00001)]
- 16 Ruiz-Tovar J, Teruel DG, Castiñeiras VM, Dehesa AS, Quindós PL, Molina EM. Mucocoele of the appendix. *World J Surg* 2007; **31**: 542-548 [PMID: [17318706](https://pubmed.ncbi.nlm.nih.gov/17318706/) DOI: [10.1007/s00268-006-0454-1](https://doi.org/10.1007/s00268-006-0454-1)]
- 17 Pai RK, Longacre TA. Appendiceal mucinous tumors and pseudomyxoma peritonei: histologic features, diagnostic problems, and proposed classification. *Adv Anat Pathol* 2005; **12**: 291-311 [PMID: [16330927](https://pubmed.ncbi.nlm.nih.gov/16330927/) DOI: [10.1097/01.pap.0000194625.05137.51](https://doi.org/10.1097/01.pap.0000194625.05137.51)]
- 18 Aho AJ, Heinonen R, Laurén P. Benign and malignant mucocoele of the appendix. Histological types and prognosis. *Acta Chir Scand* 1973;

- 139: 392-400 [PMID: 4718184]
- 19 **Noritake N**, Ito Y, Yamakita N, Azuma S, Shimokawa K, Miura K. A case of primary mucinous cystadenocarcinoma of the appendix with elevated serum carcinoembryonic antigen (CEA). *Jpn J Med* 1990; **29**: 642-646 [PMID: 2101417 DOI: 10.2169/internalmedicine1962.29.642]
- 20 **Ponsky JL**. An endoscopic view of mucocoele of the appendix. *Gastrointest Endosc* 1976; **23**: 42-43 [PMID: 964590 DOI: 10.1016/s0016-5107(76)73580-6]
- 21 **Hamilton DL**, Stormont JM. The volcano sign of appendiceal mucocoele. *Gastrointest Endosc* 1989; **35**: 453-456 [PMID: 2792684 DOI: 10.1016/s0016-5107(89)72860-1]
- 22 **Carr NJ**, Cecil TD, Mohamed F, Sobin LH, Sugarbaker PH, González-Moreno S, Taflampas P, Chapman S, Moran BJ; Peritoneal Surface Oncology Group International. A Consensus for Classification and Pathologic Reporting of Pseudomyxoma Peritonei and Associated Appendiceal Neoplasia: The Results of the Peritoneal Surface Oncology Group International (PSOGI) Modified Delphi Process. *Am J Surg Pathol* 2016; **40**: 14-26 [PMID: 26492181 DOI: 10.1097/PAS.0000000000000535]
- 23 **Carr NJ**, Bibeau F, Bradley RF, Dartigues P, Feakins RM, Geisinger KR, Gui X, Isaac S, Milione M, Misdradi J, Pai RK, Rodriguez-Justo M, Sobin LH, van Velthuysen MF, Yantiss RK. The histopathological classification, diagnosis and differential diagnosis of mucinous appendiceal neoplasms, appendiceal adenocarcinomas and pseudomyxoma peritonei. *Histopathology* 2017; **71**: 847-858 [PMID: 28746986 DOI: 10.1111/his.13324]
- 24 **Leonards LM**, Pahwa A, Patel MK, Petersen J, Nguyen MJ, Jude CM. Neoplasms of the Appendix: Pictorial Review with Clinical and Pathologic Correlation. *Radiographics* 2017; **37**: 1059-1083 [PMID: 28598731 DOI: 10.1148/rg.2017160150]
- 25 **Overman MJ**, Kakar S, Carr NJ, Hanna N, Holowatyj AN, Gress D, Williams A, Goldberg RM, Kitterman AC, Washington MK. AJCC Cancer Staging System: Appendix: Version 9 of AJCC Cancer Staging System (Version 9 of the AJCC Cancer Staging System). Am Joint Committee Cancer 2022. Available from: <https://www.facs.org/quality-programs/cancer-programs/american-joint-committee-on-cancer/>
- 26 **Janczewski LM**, Browner AE, Cotler JH, Nelson H, Kakar S, Carr NJ, Hanna NN, Holowatyj AN, Goldberg RM, Washington MK, Asare EA, Overman MJ; American Joint Committee on Cancer Expert Panel on Cancers for the Lower Gastrointestinal Appendix Disease Site. Survival outcomes used to validate version 9 of the American Joint Committee on Cancer staging system for appendiceal cancer. *CA Cancer J Clin* 2023; **73**: 590-596 [PMID: 37358310 DOI: 10.3322/caac.21806]
- 27 **Nitsche U**, Zimmermann A, Späth C, Müller T, Maak M, Schuster T, Slotta-Huspenina J, Käser SA, Michalski CW, Janssen KP, Friess H, Rosenberg R, Bader FG. Mucinous and signet-ring cell colorectal cancers differ from classical adenocarcinomas in tumor biology and prognosis. *Ann Surg* 2013; **258**: 775-82; discussion 782 [PMID: 23989057 DOI: 10.1097/SLA.0b013e3182a69f7e]
- 28 **Sheng H**, Wei X, Mao M, He J, Luo T, Lu S, Zhou L, Huang Z, Yang A. Adenocarcinoma with mixed subtypes is a rare but aggressive histologic subtype in colorectal cancer. *BMC Cancer* 2019; **19**: 1071 [PMID: 31703713 DOI: 10.1186/s12885-019-6245-5]
- 29 **Fleming M**, Ravula S, Tatishchev SF, Wang HL. Colorectal carcinoma: Pathologic aspects. *J Gastrointest Oncol* 2012; **3**: 153-173 [PMID: 22943008 DOI: 10.3978/j.issn.2078-6891.2012.030]
- 30 **Govaerts K**, Lurvink RJ, De Hingh IHJT, Van der Speeten K, Villeneuve L, Kusamura S, Kepenekian V, Deraco M, Glehen O, Moran BJ; PSOGI. Appendiceal tumours and pseudomyxoma peritonei: Literature review with PSOGI/EURACAN clinical practice guidelines for diagnosis and treatment. *Eur J Surg Oncol* 2021; **47**: 11-35 [PMID: 32199769 DOI: 10.1016/j.ejso.2020.02.012]
- 31 **Shaib WL**, Assi R, Shamseddine A, Alese OB, Staley C 3rd, Memis B, Adsay V, Bekaii-Saab T, El-Rayes BF. Appendiceal Mucinous Neoplasms: Diagnosis and Management. *Oncologist* 2017; **22**: 1107-1116 [PMID: 28663356 DOI: 10.1634/theoncologist.2017-0081]
- 32 **Higa E**, Rosai J, Pizzimbono CA, Wise L. Mucosal hyperplasia, mucinous cystadenoma, and mucinous cystadenocarcinoma of the appendix. A re-evaluation of appendiceal "mucocoele". *Cancer* 1973; **32**: 1525-1541 [PMID: 4757938 DOI: 10.1002/1097-0142(197312)32:6<1525::aid-cnrc2820320632>3.0.co;2-c]
- 33 **Ji H**, Isacson C, Seidman JD, Kurman RJ, Ronnett BM. Cytokeratins 7 and 20, Dpc4, and MUC5AC in the distinction of metastatic mucinous carcinomas in the ovary from primary ovarian mucinous tumors: Dpc4 assists in identifying metastatic pancreatic carcinomas. *Int J Gynecol Pathol* 2002; **21**: 391-400 [PMID: 12352188 DOI: 10.1097/00004347-200210000-00009]
- 34 **Kinzler KW**, Vogelstein B. Lessons from hereditary colorectal cancer. *Cell* 1996; **87**: 159-170 [PMID: 8861899 DOI: 10.1016/s0092-8674(00)81333-1]
- 35 **Strickland S**, Parra-Herran C. Immunohistochemical characterization of appendiceal mucinous neoplasms and the value of special AT-rich sequence-binding protein 2 in their distinction from primary ovarian mucinous tumors. *Histopathology* 2016; **68**: 977-987 [PMID: 26542609 DOI: 10.1111/his.12899]
- 36 **Schmoeckel E**, Kirchner T, Mayr D. SATB2 is a supportive marker for the differentiation of a primary mucinous tumor of the ovary and an ovarian metastasis of a low-grade appendiceal mucinous neoplasm (LAMN): A series of seven cases. *Pathol Res Pract* 2018; **214**: 426-430 [PMID: 29487003 DOI: 10.1016/j.prp.2017.12.008]



Published by **Baishideng Publishing Group Inc**
7041 Koll Center Parkway, Suite 160, Pleasanton, CA 94566, USA

Telephone: +1-925-3991568

E-mail: office@baishideng.com

Help Desk: <https://www.f6publishing.com/helpdesk>

<https://www.wjgnet.com>

