

World Journal of *Gastrointestinal Surgery*

World J Gastrointest Surg 2024 March 27; 16(3): 635-973



Contents

Monthly Volume 16 Number 3 March 27, 2024

EDITORIAL

- 635 *Ex vivo* liver resection and auto-transplantation and special systemic therapy in perihilar cholangiocarcinoma treatment
Tchilikidi KY
- 641 Indocyanine green: The guide to safer and more effective surgery
Fransvea P, Chiarello MM, Fico V, Cariati M, Brisinda G

MINIREVIEWS

- 650 Alcohol associated liver disease and bariatric surgery: Current perspectives and future directions
Cooper KM, Colletta A, Hebda N, Devuni D
- 658 Applications of gastric peroral endoscopic myotomy in the treatment of upper gastrointestinal tract disease
Chang SY, Jin GH, Sun HB, Yang D, Tang TY

ORIGINAL ARTICLE

Retrospective Cohort Study

- 670 Evaluation of bacterial contamination and medium-term oncological outcomes of intracorporeal anastomosis for colon cancer: A propensity score matching analysis
Kayano H, Mamuro N, Kamei Y, Ogimi T, Miyakita H, Nakagohri T, Koyanagi K, Mori M, Yamamoto S
- 681 Rescue from complications after pancreaticoduodenectomies at a low-volume Caribbean center: Value of tailored peri-pancreatectomy protocols
Cawich SO, Dixon E, Shukla PJ, Shrikhande SV, Deshpande RR, Mohammed F, Pearce NW, Francis W, Johnson S, Bujhawan J
- 689 Comparison of prognosis and postoperative morbidities between standard pancreaticoduodenectomy and the TRIANGLE technique for resectable pancreatic ductal adenocarcinoma
Hang HX, Cai ZH, Yang YF, Fu X, Qiu YD, Cheng H
- 700 Analysis of the impact of immunotherapy efficacy and safety in patients with gastric cancer and liver metastasis
Liu K, Wu CX, Liang H, Wang T, Zhang JY, Wang XT

Retrospective Study

- 710 Clinical observation of extraction-site incisional hernia after laparoscopic colorectal surgery
Fan BH, Zhong KL, Zhu LJ, Chen Z, Li F, Wu WF
- 717 Predicting short-term major postoperative complications in intestinal resection for Crohn's disease: A machine learning-based study
Wang FT, Lin Y, Yuan XQ, Gao RY, Wu XC, Xu WW, Wu TQ, Xia K, Jiao YR, Yin L, Chen CQ

- 731** Analysis of factors impacting postoperative pain and quality of life in patients with mixed hemorrhoids: A retrospective study
Sun XW, Xu JY, Zhu CZ, Li SJ, Jin LJ, Zhu ZD
- 740** Pre-operative visceral adipose tissue radiodensity is a potentially novel prognostic biomarker for early endoscopic post-operative recurrence in Crohn's disease
Gu P, Dube S, Gellada N, Choi SY, Win S, Lee YJ, Yang S, Haritunians T, Melmed GY, Vasiliauskas EA, Bonthala N, Syal G, Yarur AJ, Ziring D, Rabizadeh S, Fleshner P, Kallman C, Devkota S, Targan SR, Li D, McGovern DP
- 751** Clinical study on the relationship between liver cirrhosis, ascites, and hyponatremia
Li XJ, Meng HH
- 759** Comparison of the clinical effects of dual-modality endoscopy and traditional laparotomy for the treatment of intra- and extrahepatic bile duct stones
Wang W, Xia H, Dai B
- 768** Role of ablation therapy in conjunction with surgical resection for neuroendocrine tumors involving the liver
Ostapenko A, Stroeve S, Eyasu L, Kim M, Aploks K, Dong XD, Seshadri R
- 777** Feasibility and safety of minimally invasive multivisceral resection for T4b rectal cancer: A 9-year review
Chan KS, Liu B, Tan MNA, How KY, Wong KY
- 790** MH-STRALP: A scoring system for prognostication in patients with upper gastrointestinal bleeding
Hu JN, Xu F, Hao YR, Sun CY, Wu KM, Lin Y, Zhong L, Zeng X
- Clinical Trials Study**
- 807** Early postoperative complications after transverse colostomy closure, a retrospective study
Liu F, Luo XJ, Li ZW, Liu XY, Liu XR, Lv Q, Shu XP, Zhang W, Peng D
- 816** Clinical study of enhanced recovery after surgery in laparoscopic appendectomy for acute appendicitis
Li ZL, Ma HC, Yang Y, Chen JJ, Wang ZJ
- Observational Study**
- 823** Reinforced tissue matrix to strengthen the abdominal wall following reversal of temporary ostomies or to treat incisional hernias
Lake SP, Deeken CR, Agarwal AK
- Randomized Controlled Trial**
- 833** Whole-process case management effects on mental state and self-care ability in patients with liver cancer
Ju MD, Qin Q, Li M
- Clinical and Translational Research**
- 842** Construction and validation of somatic mutation-derived long non-coding RNAs signatures of genomic instability to predict prognosis of hepatocellular carcinoma
Duan BT, Zhao XK, Cui YY, Liu DZ, Wang L, Zhou L, Zhang XY

Basic Study

- 860 Influence of different magnetic forces on the effect of colonic anastomosis in rats
Tian BY, Zhang MM, Ma J, Lyu Y, Yan XP
- 871 Inflammatory responses in esophageal mucosa before and after laparoscopic antireflux surgery
Ergun P, Kipcak S, Selvi Gunel N, Yildirim Sozmen E, Bor S
- 882 Etanercept-synthesizing adipose-derived stem cell secretome: A promising therapeutic option for inflammatory bowel disease
Kim SJ, Kim OH, Hong HE, Ju JH, Lee DS

SYSTEMATIC REVIEWS

- 893 Impact of frailty on short-term postoperative outcomes in patients undergoing colorectal cancer surgery: A systematic review and meta-analysis
Zhou Y, Zhang XL, Ni HX, Shao TJ, Wang P

META-ANALYSIS

- 907 Endoscopic-ultrasound-guided biliary drainage with placement of electrocautery-enhanced lumen-apposing metal stent for palliation of malignant biliary obstruction: Updated meta-analysis
Peng ZX, Chen FF, Tang W, Zeng X, Du HJ, Pi RX, Liu HM, Lu XX
- 921 Clinical efficacy and safety of erlotinib combined with chemotherapy in the treatment of advanced pancreatic cancer: A meta-analysis
Liu XY, Pan HN, Yu Y

CASE REPORT

- 932 Link between mutations in *ACVRL1* and *PLA2G4A* genes and chronic intestinal ulcers: A case report and review of literature
Tang YJ, Zhang J, Wang J, Tian RD, Zhong WW, Yao BS, Hou BY, Chen YH, He W, He YH
- 944 Mucinous neoplasm of the appendix: A case report and review of literature
Chang HC, Kang JC, Pu TW, Su RY, Chen CY, Hu JM
- 955 Abdominal cocoon syndrome-a rare culprit behind small bowel ischemia and obstruction: Three case reports
Vipudhamorn W, Juthasilaparut T, Sutharat P, Sanmee S, Supatrakul E
- 966 Endoscopic ultrasound-guided lauromacrogol injection for treatment of colorectal cavernous hemangioma: Two case reports
Zhu HT, Chen WG, Wang JJ, Guo JN, Zhang FM, Xu GQ, Chen HT

ABOUT COVER

Editorial Board Member of *World Journal of Gastrointestinal Surgery*, Jia-Gang Han, MD, Professor, Department of General Surgery, Beijing Chaoyang Hospital, Capital Medical University, Beijing 100020, China. hjg211@163.com

AIMS AND SCOPE

The primary aim of *World Journal of Gastrointestinal Surgery* (WJGS, *World J Gastrointest Surg*) is to provide scholars and readers from various fields of gastrointestinal surgery with a platform to publish high-quality basic and clinical research articles and communicate their research findings online.

WJGS mainly publishes articles reporting research results and findings obtained in the field of gastrointestinal surgery and covering a wide range of topics including biliary tract surgical procedures, biliopancreatic diversion, colectomy, esophagectomy, esophagostomy, pancreas transplantation, and pancreatectomy, *etc.*

INDEXING/ABSTRACTING

The WJGS is now abstracted and indexed in Science Citation Index Expanded (SCIE, also known as SciSearch®), Current Contents/Clinical Medicine, Journal Citation Reports/Science Edition, PubMed, PubMed Central, Reference Citation Analysis, China Science and Technology Journal Database, and Superstar Journals Database. The 2023 Edition of Journal Citation Reports® cites the 2022 impact factor (IF) for WJGS as 2.0; IF without journal self cites: 1.9; 5-year IF: 2.2; Journal Citation Indicator: 0.52; Ranking: 113 among 212 journals in surgery; Quartile category: Q3; Ranking: 81 among 93 journals in gastroenterology and hepatology; and Quartile category: Q4.

RESPONSIBLE EDITORS FOR THIS ISSUE

Production Editor: Zi-Hang Xu, Production Department Director: Xiang Li, Editorial Office Director: Jia-Ru Fan.

NAME OF JOURNAL

World Journal of Gastrointestinal Surgery

ISSN

ISSN 1948-9366 (online)

LAUNCH DATE

November 30, 2009

FREQUENCY

Monthly

EDITORS-IN-CHIEF

Peter Schemmer

EDITORIAL BOARD MEMBERS

<https://www.wjgnet.com/1948-9366/editorialboard.htm>

PUBLICATION DATE

March 27, 2024

COPYRIGHT

© 2024 Baishideng Publishing Group Inc

INSTRUCTIONS TO AUTHORS

<https://www.wjgnet.com/bpg/gerinfo/204>

GUIDELINES FOR ETHICS DOCUMENTS

<https://www.wjgnet.com/bpg/GerInfo/287>

GUIDELINES FOR NON-NATIVE SPEAKERS OF ENGLISH

<https://www.wjgnet.com/bpg/gerinfo/240>

PUBLICATION ETHICS

<https://www.wjgnet.com/bpg/GerInfo/288>

PUBLICATION MISCONDUCT

<https://www.wjgnet.com/bpg/gerinfo/208>

ARTICLE PROCESSING CHARGE

<https://www.wjgnet.com/bpg/gerinfo/242>

STEPS FOR SUBMITTING MANUSCRIPTS

<https://www.wjgnet.com/bpg/GerInfo/239>

ONLINE SUBMISSION

<https://www.f6publishing.com>



Abdominal cocoon syndrome-a rare culprit behind small bowel ischemia and obstruction: Three case reports

Witcha Vipudhamorn, Tawan Juthasilaparut, Pawit Sutharat, Suwan Sanmee, Ekkarin Supatrakul

Specialty type: Gastroenterology and hepatology

Provenance and peer review: Unsolicited article; Externally peer reviewed.

Peer-review model: Single blind

Peer-review report's scientific quality classification

Grade A (Excellent): 0
Grade B (Very good): 0
Grade C (Good): 0
Grade D (Fair): 0
Grade E (Poor): 0

P-Reviewer: Esch M, Germany

Received: November 26, 2023

Peer-review started: November 26, 2023

First decision: December 15, 2023

Revised: December 16, 2023

Accepted: February 6, 2024

Article in press: February 6, 2024

Published online: March 27, 2024



Witcha Vipudhamorn, Pawit Sutharat, Suwan Sanmee, Ekkarin Supatrakul, Department of Colorectal Surgery, Chiang Mai University, Chiang Mai 50200, Thailand

Tawan Juthasilaparut, Department of Surgery, Lampang Hospital, Lampang 52000, Thailand

Corresponding author: Witcha Vipudhamorn, FRCS (Gen Surg), Surgeon, Department of Colorectal Surgery, Chiang Mai University, No. 110 Intavaroros, Sripoom, Maung, Chiang Mai 50200, Thailand. witcha.vip@cmu.ac.th

Abstract

BACKGROUND

Abdominal cocoon syndrome (ACS) represents a category within sclerosing encapsulating peritonitis, characterized by the encapsulation of internal organs with a fibrous, cocoon-like membrane of unknown origin, resulting in bowel obstruction and ischemia. Diagnosing this condition before surgery poses a challenge, often requiring confirmation during laparotomy. In this context, we depict three instances of ACS: One linked to intestinal obstruction, the second exclusively manifesting as intestinal ischemia without any obstruction, and the final case involving a discrepancy between the radiologist and the surgeon.

CASE SUMMARY

Three male patients, aged 53, 58, and 61 originating from Northern Thailand, arrived at our medical facility complaining of abdominal pain without any prior surgeries. Their vital signs remained stable during the assessment. The diagnosis of abdominal cocoon was confirmed through abdominal computed tomography (CT) before surgery. In the first case, the CT scan revealed capsules around the small bowel loops, showing no enhancement, along with mesenteric congestion affecting both small and large bowel loops, without a clear obstruction. The second case showed intestinal obstruction due to an encapsulated capsule on the CT scan. In the final case, a patient presented with recurring abdominal pain. Initially, the radiologist suspected enteritis as the cause after the CT scan. However, a detailed review led the surgeon to suspect encapsulating peritoneal sclerosis (ACS) and subsequently perform surgery. The surgical procedure involved complete removal of the encapsulating structure, resection of a portion of the small bowel, and end-to-end anastomosis. No complications occurred during surgery, and the patients had a smooth recovery after surgery, eventually discharged in good health. The histopathological examination of the fibrous membrane (cocoon) across all cases consistently revealed the presence of fibro-

collagenous tissue, without any indications of malignancy.

CONCLUSION

Individuals diagnosed with abdominal cocoons commonly manifest vague symptoms of abdominal discomfort. An elevated degree of clinical suspicion, combined with the application of appropriate radiological evaluations, markedly improves the probability of identifying the abdominal cocoon before surgical intervention. In cases of complete bowel obstruction or ischemia, the established norm is the comprehensive removal of the peritoneal sac as part of standard care. Resection with intestinal anastomosis is advised solely when ischemia and gangrene have been confirmed.

Key Words: Sclerosing encapsulation peritonitis; Abdominal cocoon; Peritoneal Fibrosis; Peritoneal encapsulation syndrome; Intestinal obstruction; Surgery; Case report

©The Author(s) 2024. Published by Baishideng Publishing Group Inc. All rights reserved.

Core Tip: Diagnosing Abdominal cocoon syndrome (ACS) poses challenges, often necessitating laparotomy for confirmation. This study presents three distinct ACS cases: one featuring bowel obstruction, another with isolated ischemia, and the last highlighting disparities between radiological findings and surgical assessments. Preoperative computed tomography scans played a crucial role in diagnosis, revealing diverse manifestations such as capsules encasing the bowels, mesenteric congestion, or ambiguous obstructions. Surgical excision of encapsulating structures led to successful recovery. Additionally, one case involved a traumatic event, requiring exploratory laparotomy a year later, where no fibrosis was found around the previously removed intestine. Early clinical suspicion, coupled with precise radiological examination, aids in identifying ACS before surgery. Complete removal of the sac during obstruction/ischemia is the established approach, recommending resection solely for confirmed ischemic complications.

Citation: Vipudhamorn W, Juthasilaparut T, Sutharat P, Sanmee S, Supatrakul E. Abdominal cocoon syndrome-a rare culprit behind small bowel ischemia and obstruction: Three case reports. *World J Gastrointest Surg* 2024; 16(3): 955-965

URL: <https://www.wjgnet.com/1948-9366/full/v16/i3/955.htm>

DOI: <https://dx.doi.org/10.4240/wjgs.v16.i3.955>

INTRODUCTION

Intra-abdominal inflammation, recognized as sclerosing encapsulating peritonitis (SEP), stands as an uncommon yet consequential condition precipitating intestinal obstruction and the peril of gangrene. This affliction delineates a scenario where abdominal organs become enveloped or encased within a dense fibrous tissue, evoking the imagery of a protective 'cocoon.' SEP, a complex entity, assumes two primary classifications: primary SEP and secondary encapsulating peritonitis.

Primary SEP, a distinctly rare manifestation, perplexes medical practitioners owing to its elusive etiology, devoid of identifiable causes. Conversely, secondary encapsulating peritonitis emerges consequent to prolonged and recurrent inflammation within the abdominal cavity, notably observed in patients undergoing peritoneal dialysis[1,2]. This dichotomy between primary and secondary forms poses diagnostic and therapeutic challenges, demanding tailored approaches for optimal management.

The diagnosis of abdominal cocoon syndrome (ACS) poses considerable challenges, necessitating a comprehensive approach involving meticulous medical history assessment, thorough physical examination, heightened clinical suspicion, and a range of both laboratory and radiological investigations[3]. Typically, symptomatic ACS presents as acute intestinal obstruction, often leading to emergent visits to healthcare facilities. Rigorous evaluation involving detailed medical and surgical histories, alongside physical examinations and diverse laboratory investigations, is crucial in excluding common causes of intestinal obstruction, predominantly attributed (80%) to postoperative adhesions. A minority of cases (approximately 6%) stem from atypical conditions such as internal hernias, substantial intussusception, and chronic idiopathic intestinal pseudo-obstruction[4].

Internal hernias represent a pertinent differential diagnosis, exhibiting similar computed tomography (CT) findings to ACS but usually lacking a membrane-like sac evident in CT scans[5]. Conversely, chronic idiopathic intestinal pseudo-obstruction manifests as bowel dilation in both small and large intestines, devoid of a membrane-like sac as seen in ACS [6]. Traditionally, ACS is diagnosed intraoperatively by the presence of a thick membrane enveloping the intestines[4]. However, recent advancements in radiological imaging have proven valuable in facilitating preoperative diagnoses.

The management approach to primary SEP remains a subject of intense debate within the medical community. While unanimity eludes consensus regarding the ideal course of action, surgical intervention typically garners favor among most surgeons, particularly when patients confront complications such as bowel obstruction. Contrarily, the therapeutic strategies for secondary SEP exhibit a spectrum of variability. Ongoing research and evolving clinical observations reflect the prevalent utilization of steroids and tamoxifen post-SEP diagnosis. Initial indications hint at the potential efficacy of

steroids, tamoxifen, or Angiotensin II inhibitors, showcasing a promising avenue for further exploration and refinement of treatment modalities[7].

This distinct delineation between primary and secondary SEP necessitates a nuanced understanding, not solely for accurate diagnosis but also for devising tailored therapeutic interventions. Exploring the interplay between etiological factors, pathophysiological mechanisms, and treatment outcomes holds significant promise in enhancing the management strategies for these encapsulating peritonitis entities[8]. We present in this report 3 cases of abdominal cocoons diagnosed preoperatively by abdominal CT and managed with surgical excision of all attached membranes.

CASE PRESENTATION

Chief complaints

Case 1: A 58-year-old male patient presented with left lower quadrant abdominal pain persisting for eight hours.

Case 2: A 61-year-old male presented with recurrent abdominal pain and substantial weight loss for one month.

Case 3: A 53-year-old male presented with colicky periumbilical pain for ten hours.

History of present illness

Case 1: A 58-year-old male patient admitted to Maharaj Chiang Mai Hospital exhibited escalating left lower quadrant abdominal pain persisting for eight hours. Over two years, he intermittently experienced chronic abdominal pain, though the symptoms spontaneously resolved. Abdominal pain was not associated with nausea and vomiting.

Case 2: A 61-year-old male presented with recurrent abdominal pain and substantial weight loss, decreasing from 45 to 40 kg within a month. Upon admission to a rural hospital, he reported early satiety and abdominal distension. Following successful management like partial small bowel obstruction at the rural facility, he was referred to the General Surgery Outpatient Department at Lampang Hospital.

Case 3: A 53-year-old male. Patient endured recurrent abdominal pain persisting for the last eight years, mostly resolving spontaneously. During this period, he sought medical attention at Lampang Hospital's Emergency Room (ER) on five occasions and was admitted once five years ago. However, his symptoms were effectively managed with pain control. On this occasion, the patient experienced colicky periumbilical pain ten hours before presenting at the ER. Initial pain management led to slight symptom improvement, prompting discharge. However, the patient returned to the ER three hours later due to the persistent symptoms, leading to subsequent admission to the general surgical ward.

History of past illness

Case 1: His medical history included non-valvular atrial fibrillation, managed with a daily intake of 2 mg of warfarin.

Case 2: No significant past history or any illness or surgery.

Case 3: No significant past history or any illness or surgery.

Personal and family history

The patient denied any family history of malignant tumours.

Physical examination

Case 1: Upon clinical examination, pronounced tenderness and guarding were observed in the left lower quadrant, alongside the identification of a palpable 5 cm × 8 cm mass characterized by firm consistency.

Case 2: During the outpatient evaluation, a physical examination revealed a 10 cm × 10 cm abdominal mass protruding in the mid-abdominal region (Figure 1). The patient had mild tenderness at mass without rebound tenderness or guarding.

Case 3: Upon examination in the ward, a distended abdomen with moderate tenderness in the lower left abdomen (more pronounced than the right) was noted.

Laboratory examinations

Case 1: Laboratory analysis revealed a slight elevation in leukocyte count [white blood counts (WBC) 11000/μL] and C-reactive protein (CRP) was 175 mg/dL while other parameters remained within normal ranges.

Case 2: Laboratory analysis revealed no leukocytosis [WBC 8100/cumm, polymorphonuclear neutrophil (PMN) 72%] and normal electrolyte levels (initial setting).

Case 3: Laboratory analysis revealed minimal leukocytosis (WBC 11300/cumm, PMN 81%) and normal electrolyte levels.

Imaging examinations

Case 1: Plain abdominal X-rays yielded unremarkable results (Figure 2A and B), whereas abdominal CT scans displayed an encapsulated thickening of the peritoneum with enhanced features, coupled with ascites between bowel loops. No

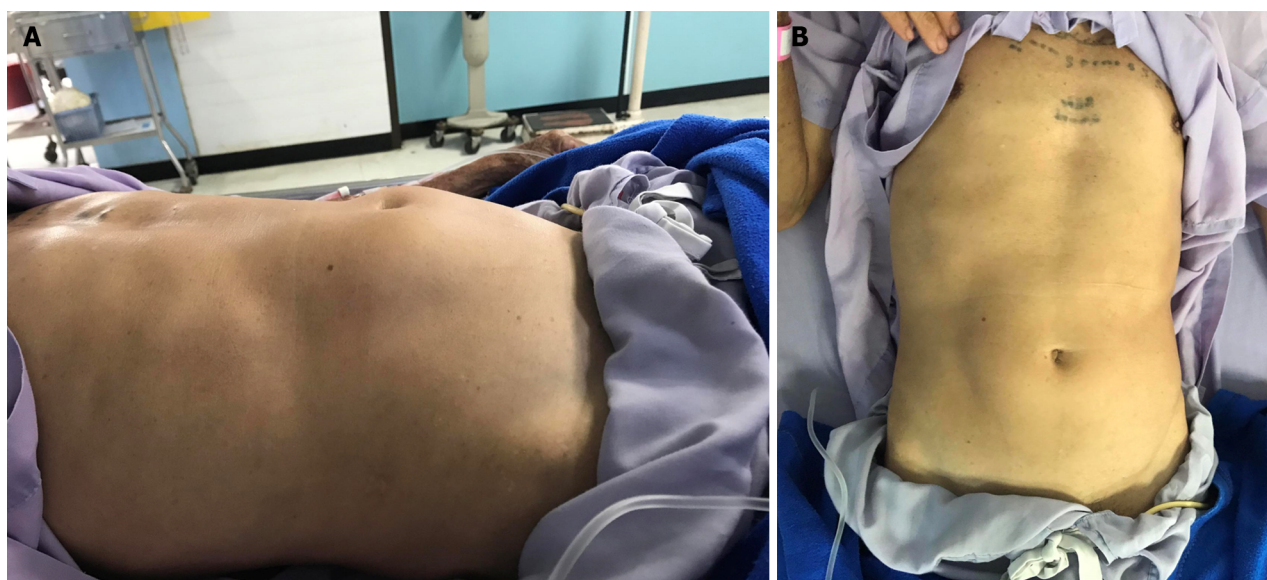

Figure 1 Physical exam of bulging mid-abdomen. A: Lateral view of abdomen; B: Bird eye view of abdomen.

signs of bowel dilation or obstruction were evident (Figure 2C and D).

Case 2: Abdominal X-rays indicated normal gas distribution in the colon and rectum, they revealed a gasless small bowel (Figure 3A). The intern referred the patient for an abdominal ultrasound examination due to the presence of a mid-abdominal mass. The ultrasound revealed multiple bowel loops, raising suspicion of a mass near the cecum, warranting a differential diagnosis that included the possibility of colon cancer. The primary surgeon elected an abdominal CT scan, revealing diffuse thickening of the small bowel wall without any blockage suggestive of encapsulating peritoneal sclerosis (Figure 4A).

Case 3: The abdominal plain film demonstrated a gasless small bowel (Figure 5A) with slight air retention in the colon and rectum. An abdominal CT scan, initially suspected to indicate sigmoid diverticulitis, was reported by the radiologist as suggestive of enteritis. However, a closer review of the CT scan raised suspicion of encapsulating peritoneal sclerosis with complications, as it exhibited stacked small bowel loops within a thick, membrane-like sac (Figure 5B and C).

FINAL DIAGNOSIS

All of the patients received a diagnosis of “acute ACS” with associated complications.

TREATMENT

Case 1

Our initial approach prioritized conservative treatment, considering the absence of peritonitis during the patient's initial presentation at the ER. However, within the subsequent six hours during follow-up, the patient exhibited a fever along with increased abdominal pain. Physical examination revealed significant tenderness around the mass and guarding specifically in the right lower quadrant area. Subsequently, due to the emergence of peritonitis symptoms, an exploratory laparotomy was considered necessary. During the laparotomy, extensive dense fibrotic tissue enveloping the third part of the duodenum up to the upper rectum was observed (Figure 6A), presenting a cocoon-like appearance with multiple loops. Subsequent resection of this fibrotic tissue revealed approximately 20 cm of mid-ileal ischemia attributed to the wrapping of fibrotic tissue around the mesentery (Figure 6B and C). Surgical intervention involved the resection of the affected segment of the small bowel followed by a hand-sewn end-to-end anastomosis by polydioxanone 4-0. Moreover, we decided to perform an appendectomy during the same setting to avoid entering a hostile abdomen in the future, especially with atypical presentation.

Case 2

After CT scan was done, a subsequent referral to a gastroenterologist raised suspicion of encapsulating peritoneal sclerosis. Despite negative results for sputum acid-fast bacilli (AFB) and Gene X-pert for tuberculosis (TB), esophago-gastroduodenoscopy and colonoscopy were performed, uncovering gastritis, erosive esophagitis, and an unremarkable colonoscopy. Histopathological analysis from random biopsies exhibited significant chronic gastritis with moderate activity and persistent inflammation of the terminal ileum. Regrettably, five days after the colonoscopy procedure, the

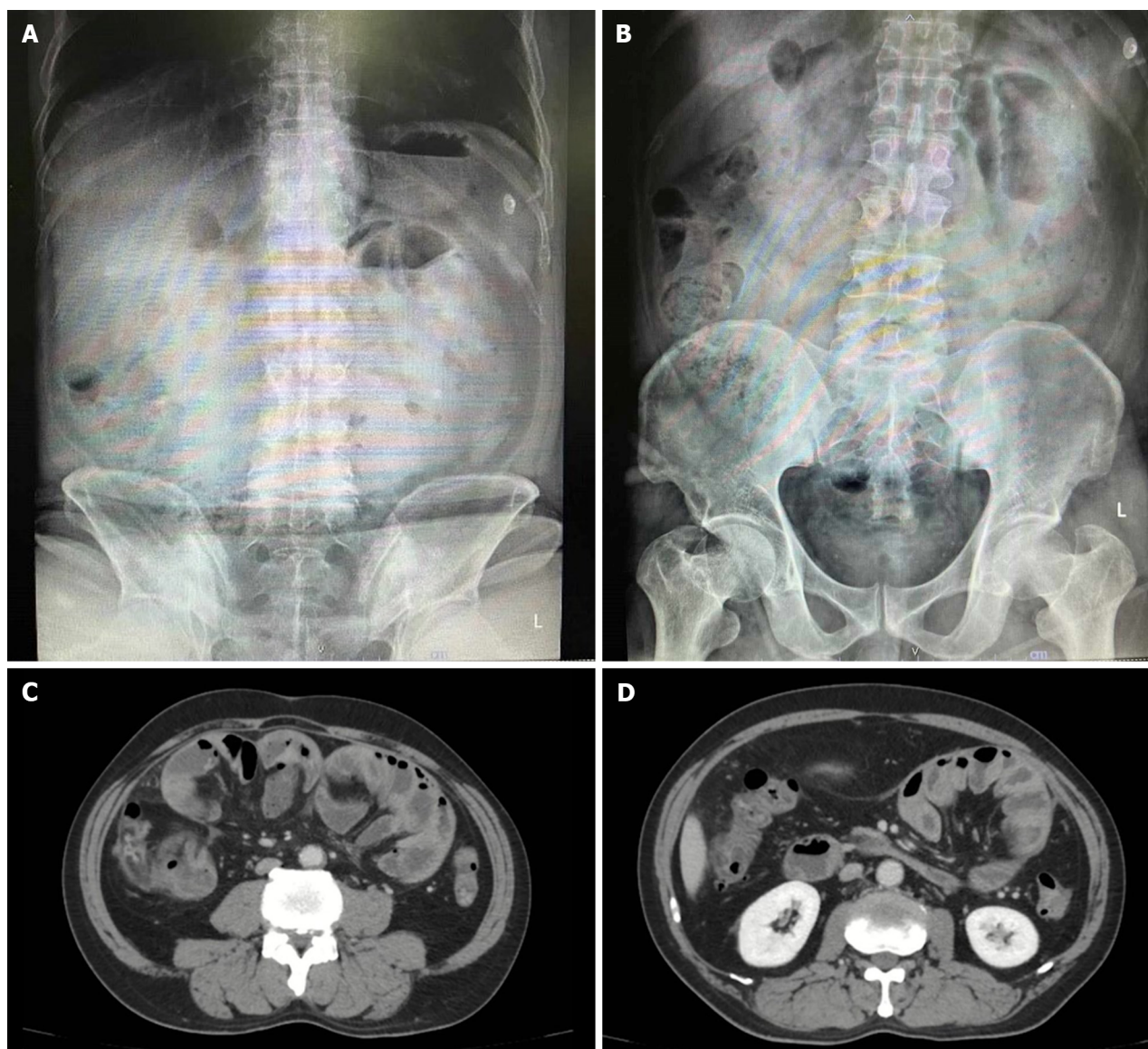


Figure 2 Abdominal X-ray and computed tomography scan whole abdomen with contrast. A: Upright view; B: Supine view; C and D: Computed tomography scan of enhancing peritoneum (cocoon-like) without small bowel dilatation.

patient developed fresh-onset abdominal pain, prompting an ER visit. Physical examination corroborated the previously documented abdominal mass, devoid of fever, alongside moderate tenderness and voluntary guarding. Subsequent abdominal X-rays exhibited decreasing air in the colon (Figure 3B). Laboratory findings indicated minimal leukocytosis (WBC 9800 /cu.mm, PMN 69%) and normal electrolyte levels. The attending surgeon elected to perform a repeat CT scan, revealing small bowel loops arranged within a substantial, membrane-like sac and a newly developed small bowel feces sign (Figure 4B and C), arousing suspicion of encapsulating peritoneal sclerosis accompanied by complications. Upon exploratory laparotomy, an extensive fibrous sheath enveloping the entirety of the small bowel and colon was revealed (Figure 7A). The fibrous sheath encapsulating the small bowel underwent meticulous dissection through sharp dissection with excision of the sheath. Successful adhesiolysis between the small bowel loops was achieved. While observing small bowel congestion, normal peristalsis was preserved (Figure 7B). A minimal quantity of reddish ascites was collected for laboratory analysis.

Case 3

Due to bowel obstruction and peritonitis, surgical management was performed. During the surgery, an extensive fibrous sheath covered the entire small bowel and colon, reminiscent of the previous case, albeit with minimal soft adhesions between the parietal peritoneum and the fibrous sheath (Figure 8). Remarkably, the small bowel remained viable. A meager amount of yellowish ascitic fluid was collected for laboratory examination.

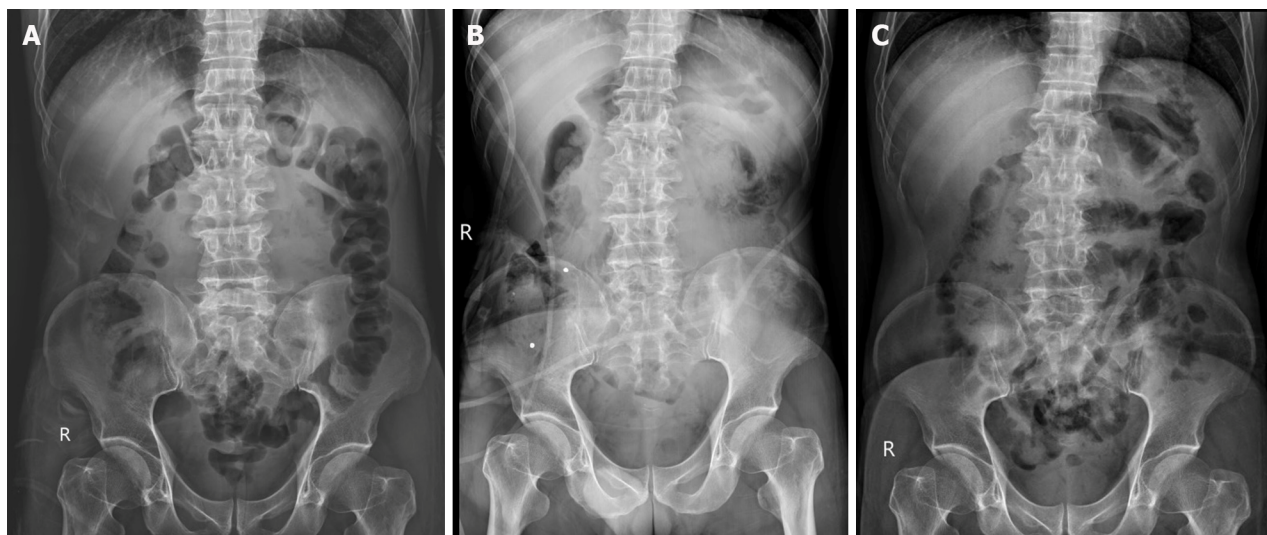


Figure 3 Abdominal X-rays. A: Gasless small bowel from X-ray in 1st visit; B: Small bowel devoid of gas observed on the fifth day after the completion of a colonoscopy procedure; C: Disappearance of gasless small bowel after operation.

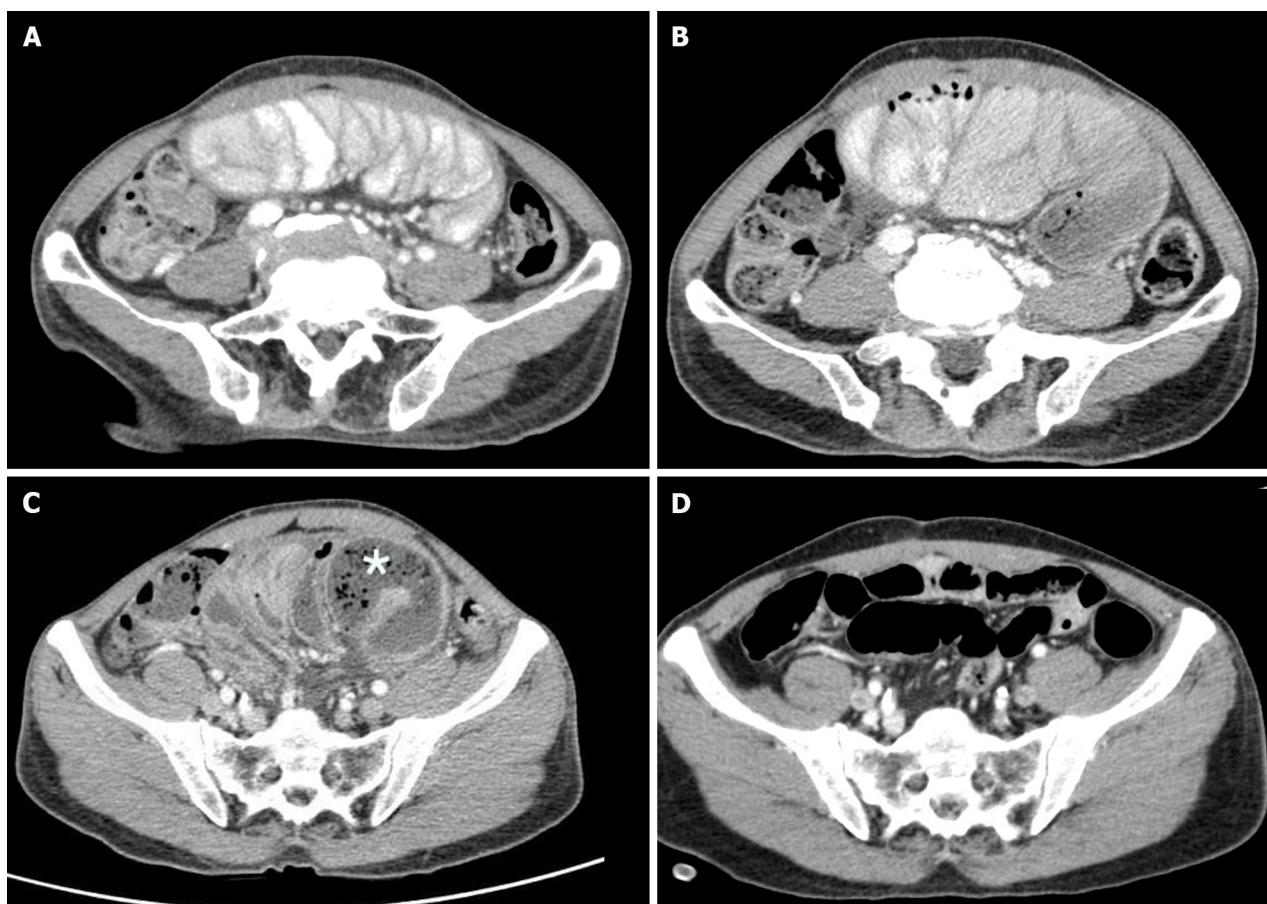


Figure 4 Computed tomography scan whole abdomen with contrast. A and B: Stacking small bowel loops inside a thick membrane-like sac; C: Small bowel feces sign (asterisk); D: Normal alignment of the small bowel after operation.

OUTCOME AND FOLLOW-UP

Case 1

The patient was discharged on the seventh-day post-surgery, exhibiting no postoperative complications. After a two-week follow-up, the blood chemistry was within a normal range (CRP 0.2 mg/dL). The culture results were negative for viruses, bacteria, and mycobacteria. The small bowel pathology disclosed acute transmural hemorrhagic infarction,

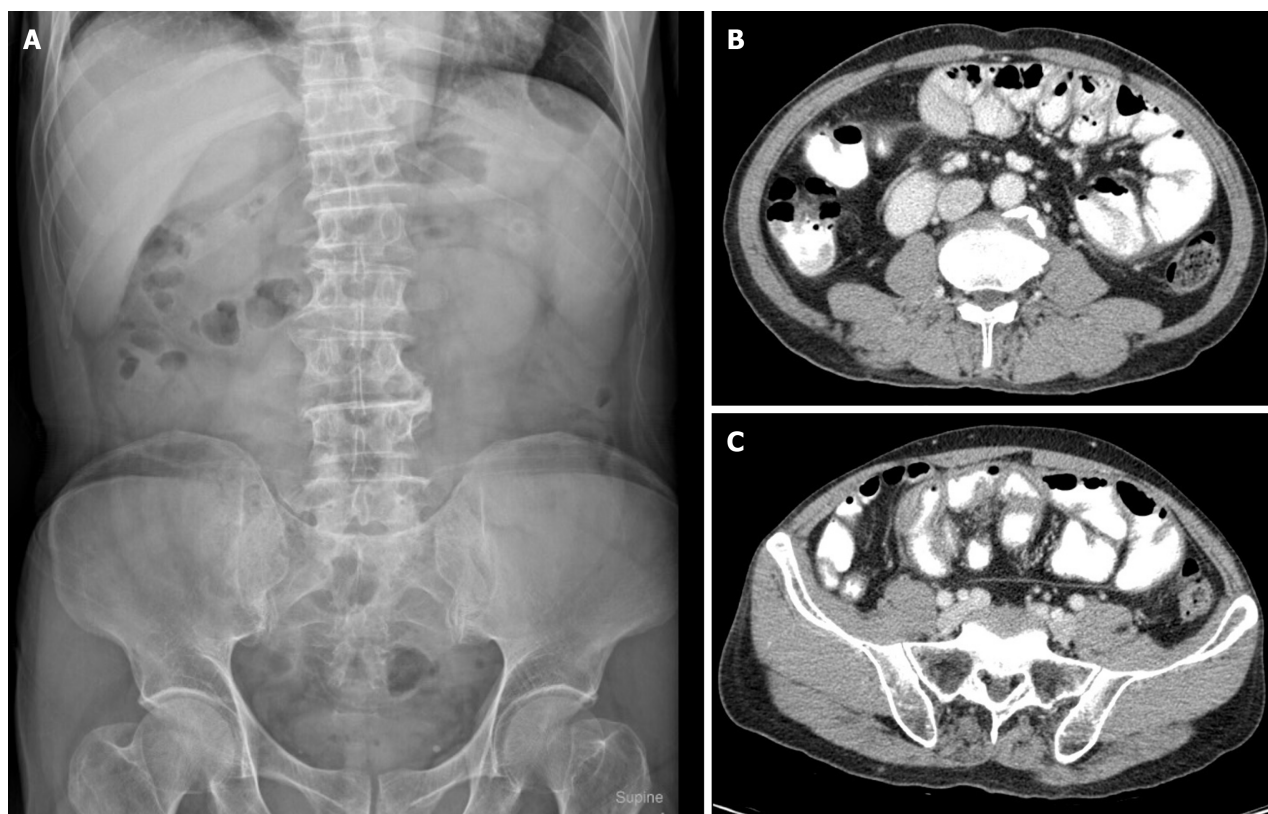


Figure 5 Abdominal X-ray and computed tomography whole abdomen with oral and IV contrast. A: Gasless small bowel; B and C: Stacking small bowel loops inside a thick membrane-like sac.

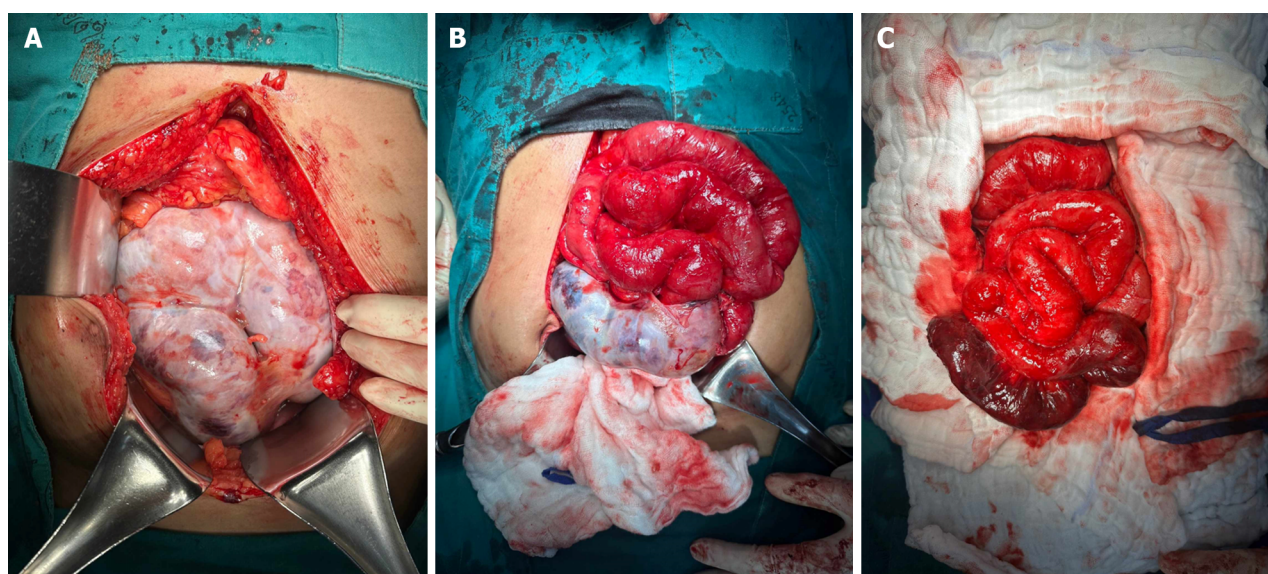


Figure 6 Intraoperative finding of encapsulated of intestine. A: Entire intestine with dense fibrous tissue; B: Partial resection of dense fibrous tissue; C: After complete resection of all fibrous tissue with small bowel necrosis.

devoid of thrombus in the vascular margin. Analysis of the resected dense, cocoon-like tissue solely indicated fibrosis and fibrous formations, with no signs of malignancy. The whole cocoon contained only fibro-collagenous tissue. Further staining of the specimen for IgG4/IgG revealed a plasma cell ratio of 0%.

Case 2

After surgery, the patient abstained from food until the resolution of bowel ileus and was discharged on the seventh postoperative day, progressing toward an uncomplicated recovery. Pathological analysis of the fibrous membrane revealed benign fibrotic tissue with mild, persistent inflammation, lacking granulomas, or malignancy. Assessments of

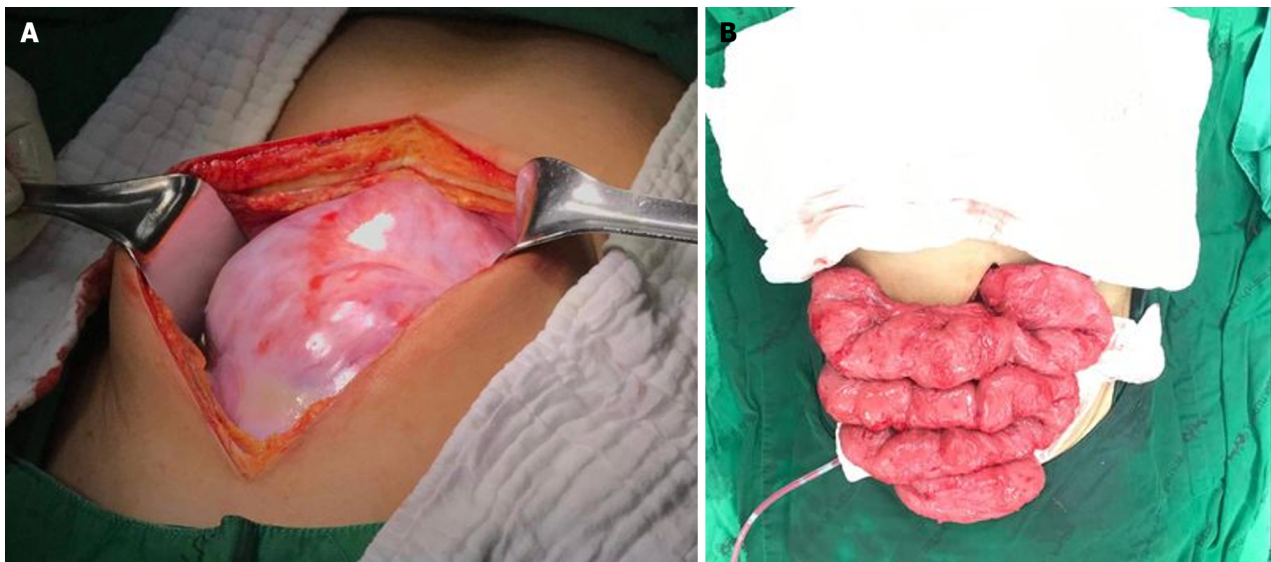


Figure 7 Intraoperative images. A: Fibrous sheath encapsulated small bowel; B: Small bowel after complete adhesiolysis.

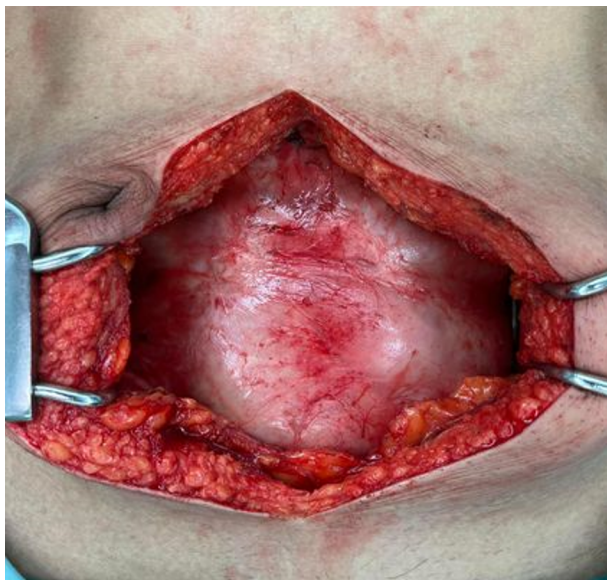


Figure 8 Intraoperative finding.

ascitic fluid exhibited negative findings for both gram and AFB stains. Cultures for bacteria, fungi, and TB demonstrated uniformly negative results. Follow-up evaluations conducted two weeks after surgery indicated the patient's complete resolution of symptoms and regained body weight. Subsequent abdominal X-rays demonstrated normal air distribution in the small bowel and colon (Figure 3C).

Nevertheless, a year later, the patient required readmission to the trauma unit due to multiple injuries sustained in a fall. Despite the injuries, the patient remained asymptomatic, maintaining a stable body weight of 50 kg. During this hospital stay, the patient encountered hematemesis, leading to a comprehensive whole abdomen CT angiogram performed by a trauma surgeon, revealing normal alignment of the small bowel (Figure 4D).

Case 3

Postoperative management mirrored that of the previous case, and the patient was discharged on the fifth postoperative day, experiencing an uncomplicated recovery. Pathological scrutiny of the fibrous membrane indicated benign fibrous tissue without granulomas or malignancy. Ascitic fluid analyses showed negative results for gram stain, Wright's stain, mycobacterial AFB stain, and AFB stain. Bacterial culture yielded negative results. Two weeks postoperatively, the patient remained asymptomatic during the follow-up.

DISCUSSION

Peritoneal encapsulation, an unusual anatomical condition initially termed peritonitis chronica fibrosa incapsulata in 1907 due to an additional peritoneal membrane, gained recognition as an 'abdominal cocoon' by Foo *et al*[2] in 1978[1,2]. Despite extensive research, the precise etiology of SEP remains enigmatic. SEP is classified into primary or secondary types based on etiology and pathogenesis[7].

Primary SEP, also known as idiopathic SEP or ACS, denotes instances where alternative causative factors are excluded or when the phenomenon defies explanation within the patient's medical context. Literature analysis reveals a higher prevalence of ACS in specific regions such as China, India, and Turkey, exhibiting a twofold higher incidence in males compared to females[8]. In contrast, secondary SEP is associated with clearly identified etiological causes like peritoneal dialysis, TB infection, sarcoidosis, abdominal trauma, surgery, autoimmune diseases, or beta-blockers used[9,10].

In delineating the complexities of SEP, an intriguing observation surfaces: a seemingly elevated prevalence in Asia, aligning with the reported distribution in previous scholarly works. This regional correlation hints at a distinctive trend within the epidemiological landscape, suggesting a potentially heightened incidence or recognition of SEP cases in Asian populations. This noteworthy observation corresponds to previously documented reports, underscoring a particular focus on Asia in the prevalence and incidence of SEP cases[4,7,10,11].

The rarity of ACS often leads to underdiagnosis, with most patients presenting recurrently with abdominal discomfort, tenderness, nausea/vomiting, intestinal distention, and abdominal masses[7]. Manifestations vary across acute, subacute, and chronic settings, frequently accompanied by weight loss and malnutrition. Notably, Li *et al*'s study highlighted that 75% of chronic ACS patients exhibited a body mass index of $< 18.5 \text{ kg/m}^2$ [4]. The challenging diagnostic landscape results in severe presentations like intestinal obstruction or bowel ischemia, an uncommon occurrence without concomitant bowel obstruction, typically attributed to fibrotic band entanglement within the small bowel mesentery.

Initial diagnosis utilizing a plain X-ray abdomen aids in identifying characteristic signs such as air-fluid levels and dilated bowel loops associated with bowel obstruction cases[12]. Reports suggest ultrasound's potential in diagnosing ACS by revealing dilated small bowel loops, trilaminar bowel wall appearance, membrane formation, and bowel tethering to the posterior abdominal wall. However, its operator-dependent nature limits sensitivity and specificity as shown in the second case report[13]. CT scans emerge as the most reliable diagnostic tool for ACS, revealing thickened peritoneum ($> 2 \text{ mm}$), peritoneal or mural calcification, and indications of bowel obstruction[14,15]. Due to the rare etiology of this disease, it is imperative that both surgeons and radiologists possess awareness and understanding of this condition.

The absence of standardized ACS treatment guidelines prompts surgical interventions primarily in cases complicated by intestinal obstruction. Surgical objectives encompass the complete release of fibrotic bands along the intestine and mesenteric root. Bowel resection is reserved for nonviable segments, avoiding unnecessary resections to prevent complications like short bowel syndrome. In select cases, appendectomy during the same procedure may preclude future diagnostic ambiguities, given the potential for atypical presentations in ACS patients[16,17]. Mild cases may warrant conservative treatment; ongoing trials have shown promising outcomes with steroids, colchicine, tamoxifen, and azathioprine[11].

Presently, histopathological analysis is infrequently deemed necessary due to the diagnostic confidence achieved through a combination of CT imaging patterns and clinical manifestations in identifying SEP. Histologically, examination of the peritoneum reveals an overgrowth of fibro-connective tissue, accompanied by inflammatory infiltrates and dilated lymphatics. Notably absent are indications of foreign body granulomas, giant cells, or birefringent material. The term 'sclerosing' delineates the progressive development of dense collagenous layers, 'encapsulating' refers to the newly formed fibrous tissue sheath enveloping and constricting the small bowel, thereby restricting its motility. Moreover, 'peritonitis' signifies an ongoing inflammatory state, evidenced by a mononuclear inflammatory infiltrate within the evolving fibrosing tissue[6,18,19].

This comprehensive overview of SEP and ACS highlights the multifaceted nature of these conditions, emphasizing the need for further research to establish standardized diagnostic protocols and effective treatment guidelines to improve patient outcomes.

CONCLUSION

In conclusion, the intricate nature of SEP, particularly in its manifestation as ACS, underscores the challenges in understanding its origins and diagnosing its diverse presentations. While primary and secondary classifications offer insights into potential causative factors, the rarity of ACS often leads to underdiagnosis, accentuating the need for heightened clinical suspicion. Diagnostic modalities like plain X-ray, ultrasound, and CT scans provide crucial tools, yet their limitations necessitate further refinement for accurate and timely identification. Surgical interventions, guided by tailored approaches, remain pivotal in managing complications, advocating for meticulous band release while preserving bowel integrity. Amidst ongoing trials exploring conservative treatments, a standardized approach is paramount, urging continued research to unravel the complexities of SEP and ACS, thereby paving the way for enhanced diagnostic strategies and more efficacious treatment paradigms to benefit patients.

FOOTNOTES

Co-first authors: Witcha Vipudhamorn and Tawan Juthasilaparut.

Author contributions: Vipudhamorn W and Juthasilaparut T contributed to manuscript writing and editing, and data collection; Sutharat P, Sanmee S and Supatrakul E contributed to conceptualization and supervision; all authors have read and approved the final manuscript. Notably, Vipudhamorn W and Juthasilaparut T, as doctors directly involved in the care of the patients featured in this case report, not only spearheaded the drafting of the manuscript but also contributed their clinical insights and expertise. While Vipudhamorn W and Juthasilaparut T took the lead in composing the manuscript, Sutharat P, Sanmee S, and Supatrakul E diligently reviewed articles for discussion and contributed significantly to the revision process. Furthermore, all authors played integral roles in the critical review of the results, collectively ensuring the accuracy and validity of the final manuscript, which has been unanimously approved by the entire team. Vipudhamorn W and Juthasilaparut T are designated as co-first authors for several compelling reasons. Firstly, their involvement extended beyond writing; their direct patient care and clinical insights profoundly influenced the depth and context of this study. Secondly, both Vipudhamorn W and Juthasilaparut T made substantive and equal contributions throughout the research process, reflecting the essence of teamwork and dedication. In essence, designating Vipudhamorn W and Juthasilaparut T as co-first authors aptly reflects the collaborative spirit, equal contributions, and clinical expertise they brought to this manuscript. Their direct involvement with the patients, combined with their writing efforts, significantly enriched the depth and authenticity of this study, thereby enhancing its value to the medical community.

Informed consent statement: Informed written consent was obtained from the patient for publication of this report and any accompanying images.

Conflict-of-interest statement: The authors declare that they have no conflict of interest.

CARE Checklist (2016) statement: The authors have read the CARE Checklist (2016), and the manuscript was prepared and revised according to the CARE Checklist (2016).

Open-Access: This article is an open-access article that was selected by an in-house editor and fully peer-reviewed by external reviewers. It is distributed in accordance with the Creative Commons Attribution NonCommercial (CC BY-NC 4.0) license, which permits others to distribute, remix, adapt, build upon this work non-commercially, and license their derivative works on different terms, provided the original work is properly cited and the use is non-commercial. See: <https://creativecommons.org/licenses/by-nc/4.0/>

Country/Territory of origin: Thailand

ORCID number: Witcha Vipudhamorn 0009-0008-5639-8253; Tawan Juthasilaparut 0009-0006-7744-3493; Ekkarin Supatrakul 0000-0003-3299-7151.

S-Editor: Qu XL

L-Editor: A

P-Editor: Cai YX

REFERENCES

- 1 Singhal M, Krishna S, Lal A, Narayanasamy S, Bal A, Yadav TD, Kochhar R, Sinha SK, Khandelwal N, Sheikh AM. Encapsulating Peritoneal Sclerosis: The Abdominal Cocoon. *Radiographics* 2019; **39**: 62-77 [PMID: 30526331 DOI: 10.1148/rg.2019180108]
- 2 Foo KT, Ng KC, Rauff A, Foong WC, Sinniah R. Unusual small intestinal obstruction in adolescent girls: the abdominal cocoon. *Br J Surg* 1978; **65**: 427-430 [PMID: 656764 DOI: 10.1002/bjs.1800650617]
- 3 Awe JA. Abdominal cocoon syndrome (idiopathic sclerosing encapsulating peritonitis): how easy is its diagnosis preoperatively? A case report. *Case Rep Surg* 2013; **2013**: 604061 [PMID: 23738183 DOI: 10.1155/2013/604061]
- 4 Li N, Zhu W, Li Y, Gong J, Gu L, Li M, Cao L, Li J. Surgical treatment and perioperative management of idiopathic abdominal cocoon: single-center review of 65 cases. *World J Surg* 2014; **38**: 1860-1867 [PMID: 24519587 DOI: 10.1007/s00268-014-2458-6]
- 5 Chorti A, Panidis S, Konstantinidis D, Cheva A, Papavramidis T, Michalopoulos A, Paramythiotis D. Abdominal cocoon syndrome: Rare cause of intestinal obstruction-Case report and systematic review of literature. *Medicine (Baltimore)* 2022; **101**: e29837 [PMID: 35801789 DOI: 10.1097/MD.00000000000029837]
- 6 Honda K, Oda H. Pathology of encapsulating peritoneal sclerosis. *Perit Dial Int* 2005; **25** Suppl 4: S19-S29 [PMID: 16300269]
- 7 Machado NO. Sclerosing Encapsulating Peritonitis: Review. *Sultan Qaboos Univ Med J* 2016; **16**: e142-e151 [PMID: 27226904 DOI: 10.18295/squmj.2016.16.02.003]
- 8 Akbulut S. Accurate definition and management of idiopathic sclerosing encapsulating peritonitis. *World J Gastroenterol* 2015; **21**: 675-687 [PMID: 25593498 DOI: 10.3748/wjg.v21.i2.675]
- 9 Xia J, Xie W, Chen L, Liu D. Abdominal cocoon with early postoperative small bowel obstruction: A case report and review of literature in China. *Medicine (Baltimore)* 2018; **97**: e11102 [PMID: 29924005 DOI: 10.1097/MD.00000000000011102]
- 10 Aziz W, Malik Y, Haseeb S, Mirza RT, Aamer S. Abdominal Cocoon Syndrome: A Laparoscopic Approach. *Cureus* 2021; **13**: e16787 [PMID: 34513394 DOI: 10.7759/cureus.16787]
- 11 Kappauf C, Rahaman J, Popowich D. Abdominal cocoon: an unexpected cause of ascites in a healthy patient. *J Surg Case Rep* 2019; **2019**: rjz310 [PMID: 31832134 DOI: 10.1093/jscr/rjz310]
- 12 Karona P, Blevrakis E, Kastanaki P, Tzouganakis A, Kastanakis M. Abdominal Cocoon Syndrome: An Extremely Rare Cause of Small Bowel Obstruction. *Cureus* 2021; **13**: e14351 [PMID: 33972908 DOI: 10.7759/cureus.14351]

- 13 **Tannoury JN**, Abboud BN. Idiopathic sclerosing encapsulating peritonitis: abdominal cocoon. *World J Gastroenterol* 2012; **18**: 1999-2004 [PMID: [22563185](#) DOI: [10.3748/wjg.v18.i17.1999](#)]
- 14 **Dave A**, McMahon J, Zahid A. Congenital peritoneal encapsulation: A review and novel classification system. *World J Gastroenterol* 2019; **25**: 2294-2307 [PMID: [31148901](#) DOI: [10.3748/wjg.v25.i19.2294](#)]
- 15 **Gupta S**, Shirahatti RG, Anand J. CT findings of an abdominal cocoon. *AJR Am J Roentgenol* 2004; **183**: 1658-1660 [PMID: [15547206](#) DOI: [10.2214/ajr.183.6.01831658](#)]
- 16 **Solak A**, Solak İ. Abdominal cocoon syndrome: preoperative diagnostic criteria, good clinical outcome with medical treatment and review of the literature. *Turk J Gastroenterol* 2012; **23**: 776-779 [PMID: [23864454](#) DOI: [10.4318/tjg.2012.0500](#)]
- 17 **Wei B**, Wei HB, Guo WP, Zheng ZH, Huang Y, Hu BG, Huang JL. Diagnosis and treatment of abdominal cocoon: a report of 24 cases. *Am J Surg* 2009; **198**: 348-353 [PMID: [19217609](#) DOI: [10.1016/j.amjsurg.2008.07.054](#)]
- 18 **Clatworthy MR**, Williams P, Watson CJ, Jamieson NV. The calcified abdominal cocoon. *Lancet* 2008; **371**: 1452 [PMID: [18440427](#) DOI: [10.1016/S0140-6736\(08\)60625-X](#)]
- 19 **Okada K**, Onishi Y, Oinuma T, Nagura Y, Soma M, Saito S, Kanmatsuse K, Takahashi S. Sclerosing encapsulating peritonitis: regional changes of peritoneum. *Nephron* 2002; **92**: 481-483 [PMID: [12218337](#) DOI: [10.1159/000063290](#)]



Published by **Baishideng Publishing Group Inc**
7041 Koll Center Parkway, Suite 160, Pleasanton, CA 94566, USA

Telephone: +1-925-3991568

E-mail: office@baishideng.com

Help Desk: <https://www.f6publishing.com/helpdesk>

<https://www.wjgnet.com>

