

## Concurrent and subsequent radiofrequency ablation combined with hepatectomy for hepatocellular carcinomas

Dongil Choi, Hyo K Lim, Hyunchul Rhim

Dongil Choi, Hyo K Lim, Hyunchul Rhim, Department of Radiology and Center for Imaging Science, Samsung Medical Center, Sungkyunkwan University School of Medicine, 50, Ilwon-Dong, Kangnam-Ku, Seoul 135-710, South Korea

Author contributions: Lim HK designed the study; Choi D drafted the article; Rhim H revised the article.

Correspondence to: Hyo K Lim, MD, Department of Radiology and Center for Imaging Science, Samsung Medical Center, Sungkyunkwan University School of Medicine, 50, Ilwon-Dong, Kangnam-Ku, Seoul 135-710, South Korea. [rfalim@skku.edu](mailto:rfalim@skku.edu)  
Telephone: +82-2-34102505 Fax: +82-2-34102559

Received: November 10, 2009 Revised: December 25, 2009

Accepted: January 2, 2010

Published online: April 27, 2010

**Peer reviewers:** Zenichi Morise, MD, PhD, Department of Surgery, Fujita Health University School of Medicine, 1-98 Dengakugakubo Kutsukakecho, Toyoake AICHI, 470-1192, Japan; Michael E de Vera, MD, Starzl Transplant Institute, UPMC, Montefiore 7, South 3459, 5th Ave, Pittsburgh, PA 15213, United States

Choi D, Lim HK, Rhim H. Concurrent and subsequent radiofrequency ablation combined with hepatectomy for hepatocellular carcinomas. *World J Gastrointest Surg* 2010; 2(4): 137-142 Available from: URL: <http://www.wjgnet.com/1948-9366/full/v2/i4/137.htm> DOI: <http://dx.doi.org/10.4240/wjgs.v2.i4.137>

### Abstract

Partial hepatectomy has long been the standard treatment modality for patients with hepatocellular carcinoma (HCC), although the majority of patients with HCCs are not candidates for curative resection. Radiofrequency ablation (RFA) has been widely used as the preferred locoregional therapy. RFA and hepatectomy can be complementary to each other for the treatment of multifocal HCCs. Combining hepatectomy with RFA permits the removal of larger tumors while simultaneously ablating any smaller residual tumors. By using this combination treatment, more patients might become candidates for curative resection. For treating recurrent tumors involving the liver after hepatectomy, RFA has been performed recently instead of transcatheter arterial chemoembolization or ethanol ablation. Many retrospective studies on the combination of RFA and hepatectomy demonstrate favorable results of effectiveness and safety. However, further investigation of prospective design will be needed to confirm these encouraging results.

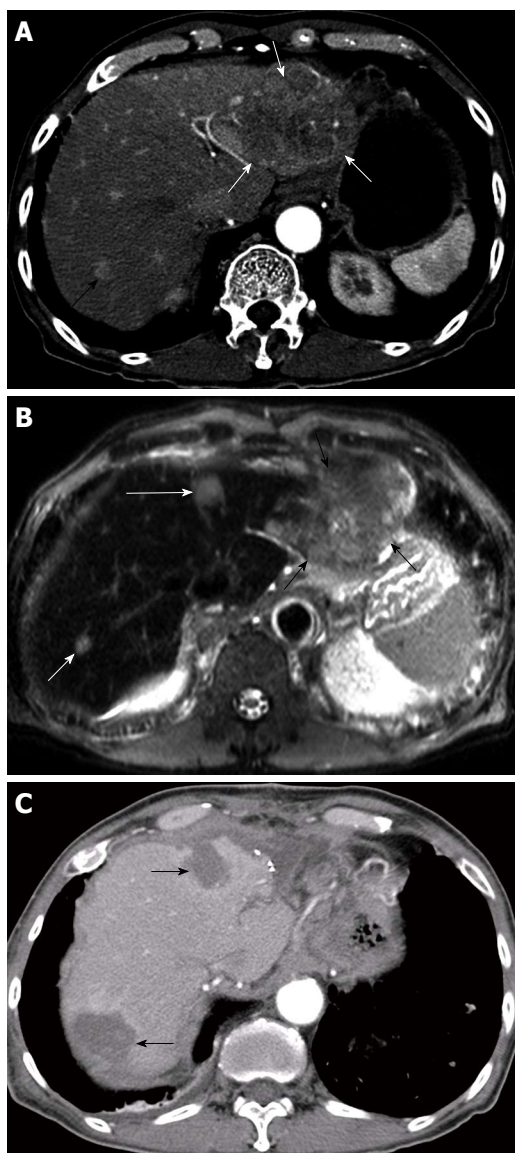
© 2010 Baishideng. All rights reserved.

**Key words:** Radiofrequency ablation; Hepatocellular carcinoma; Hepatectomy; Combination treatment

### INTRODUCTION

Liver transplantation is the most effective treatment modality for patients with hepatocellular carcinoma (HCC), as it not only completely removes HCCs in the liver but also treats the underlying cirrhosis<sup>[1]</sup>. However, transplantation has been performed restrictively owing to a shortage of donors and the long waiting time<sup>[1]</sup>. Thus, partial hepatectomy has long been the standard treatment modality for patients with HCCs. However, the majority of patients with HCCs cannot undergo curative resection owing to inadequate functional hepatic reserve, multifocality, or both<sup>[1-4]</sup>.

Among many locoregional treatment modalities, transcatheter arterial chemoembolization (TACE), ethanol ablation and radiofrequency ablation (RFA) have been widely used. TACE is usually applied to patients with multiple tumors and relatively preserved function of the liver whilst ethanol ablation and RFA is usually performed on patients with a small number of tumors<sup>[1-4]</sup>. RFA is increasingly used as the preferred therapy because it produces more consistent local tumor control and good survival results<sup>[5-9]</sup>. Moreover, several recent studies reported that RFA might achieve long-term survival results similar to those for resection for small HCCs<sup>[10-14]</sup>. A most recent report asserted that RFA can be considered the treatment of choice for patients with single 2 cm or smaller HCC, even when surgical resection is possible<sup>[15]</sup>.



**Figure 1** Successful radiofrequency ablation (RFA) combined with hepatic resection for multifocal hepatocellular carcinomas (HCCs) in a 74-year-old man. A: Contrast-enhanced transverse helical CT scan obtained during the arterial phase before treatment shows two HCCs in the both hepatic lobes. There are 11.0-cm-diameter HCC (white arrows) in left lateral segment and 1.1-cm-diameter HCC (black arrow) in liver segment 7; B: Ferucarbotran-enhanced T2-weighted fast spin echo MR image shows another 1.5-cm-diameter HCC (long white arrow) in liver segment 4. He underwent resection for a large tumor and concurrent RFA for two small tumors; C: Contrast-enhanced transverse helical CT scan obtained 1 mo after combined hepatectomy and RFA shows two round ablation zones (arrows) of low attenuation that suggests technical success of ablation. At 4 mo after treatment, multiple metastatic tumors were found in the both lungs (not shown).

## PRINCIPLE OF CONCURRENT RFA AND HEPATECTOMY

RFA is competitive with hepatectomy in the treatment of small HCCs, although RFA and hepatectomy can be complementary to each other for the treatment of multifocal HCCs<sup>[16]</sup>. In order to permit complete treatment of unresectable multifocal hepatic tumors including metastases from colorectal cancer, RFA or other locoregional

therapies combined with hepatic resection have been introduced<sup>[17-20]</sup>. A prior report proposed that reduction surgery allowed a survival benefit for patients with multiple HCCs when combined with intraoperative adjuvant therapy for remaining satellite tumors<sup>[20]</sup>. This study found that the cumulative survival results of these patients with reductive hepatic resection were better than those of patients treated non surgically with TACE or ethanol ablation. Figure 1 shown a RFA combined with hepatic resection for multifocal HCCs in a 74-year-old man.

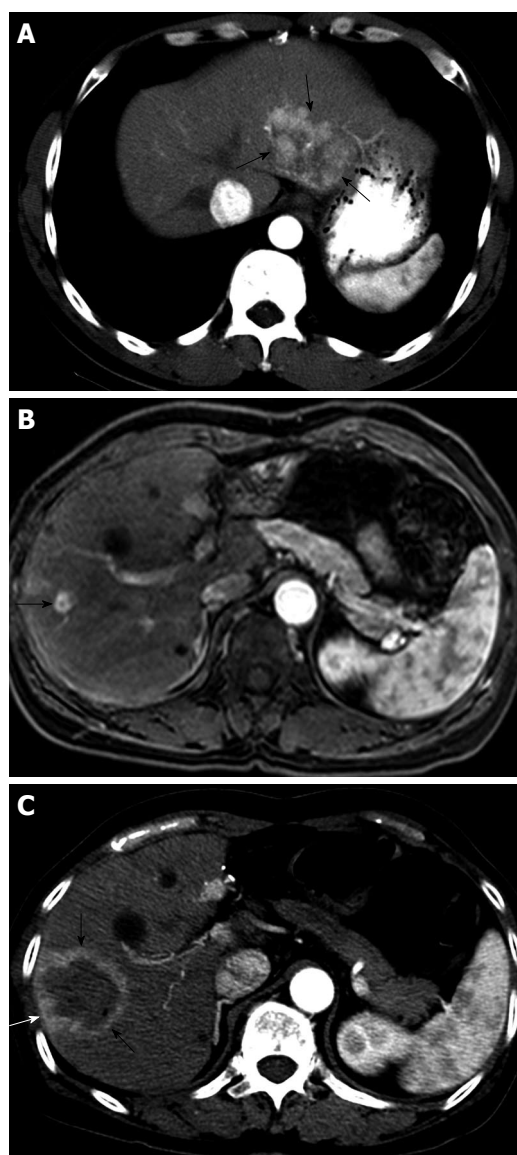
When compared to colorectal liver metastasis, combining hepatectomy with RFA may play a more important role in treating HCC because of the high frequency of multifocal tumors and associated liver cirrhosis<sup>[16]</sup>. In a previous study of patients with bilobar HCCs, combined resection of HCC in one lobe and wedge resection or ethanol ablation of lesions in the contralateral lobe showed better long-term survival than nonsurgical treatments<sup>[21]</sup>. However, wedge resection for contralateral lobe lesions can be performed only for superficial tumors, and ethanol ablation is reported to be inferior to RFA in terms of local tumor control. RFA is a better modality for treatment of contralateral lesions and can be performed for deep tumors<sup>[16]</sup>.

In patients with multifocal HCCs that are untreatable with hepatectomy alone, the dominant tumors are resected first, and the remaining small tumors can be treated simultaneously with RFA. This makes more patients potential candidates for curative resection. All sonographically-detectable small tumors can be completely eradicated with preserving hepatic reserve<sup>[22,23]</sup>. Intraoperative RFA can be performed for some tumors ineligible for percutaneous RFA. Tumors near the hepatic hilum, stomach, colon, or diaphragm can easily be treated with intraoperative RFA.

## CLINICAL RESULTS OF CONCURRENT RFA AND HEPATECTOMY

Recently, Choi *et al.*<sup>[22]</sup> reported good perioperative results and long-term survival in a series of 53 patients who had undergone combined hepatectomy and RFA for multifocal HCCs. During a single operation, as well as hepatectomy the intraoperative RFA procedures were performed for one or more (up to three) of 59 small (4 cm or smaller in maximum diameter) unresectable HCCs<sup>[22]</sup>. This study also found that resected tumor size was a significant prognostic predictor of long-term survival. They confirmed an important role for RFA in enhancing the chance of curative treatments for patients with multifocal tumors that might traditionally be considered unresectable.

In patients with HCC in a cirrhotic liver, preoperative evaluation including Child-Pugh classification, indocyanine green retention test, and volumetric analysis is essential<sup>[2,3,24-29]</sup>. Although survival after resection for properly selected candidates can reach 70% at 5 years<sup>[2]</sup>, large series of resections for HCCs reported moderate or good, 3-year and 5-year survival rates between 51%-73% and 34%-59%, respectively<sup>[29-32]</sup>. Choi *et al.*<sup>[22]</sup> demonstrated that resection plus RFA provided long-term survival comparable to that with hepatectomy alone. This study



**Figure 2 Successful RFA of intrahepatic recurrent HCC in a 49-year-old man.** A: Contrast-enhanced transverse helical CT scan obtained during the arterial phase before hepatectomy shows a 5.7-cm-diameter HCC (arrows) in left lateral segment; B: At 5 years after left lateral segmentectomy, Gd-EOB-DTPA-enhanced T1-weighted MR image obtained during the arterial phase before RFA shows a 1.0-cm-diameter recurrent HCC (arrow) in liver segment 8; C: Contrast-enhanced transverse helical CT scan obtained 1 h after RFA shows a round ablation zone (arrows) of low attenuation with peripheral rim hyperemia. The patient has been alive without recurrence for 14 mo.

reported that the cumulative survival rates at 1, 3 and 5 years were 87% 80% and 55%, respectively. However, in spite there being only one case with incomplete ablation and two others with local tumor progression after ablating 66 tumors, the 5-year cancer-free survival was 0%. Either tumor recurrence at the other parts of the liver or extrahepatic metastasis is very common where multifocal HCCs are treated. Although small recurrent tumors in the liver could possibly be ablated, novel adjuvant therapies such as sorafenib may be needed<sup>[33-35]</sup>.

Despite the theoretical appeal of combining hepatectomy with RFA, safety can be a concern because both resection and intraoperative RFA are procedures that may

potentially cause morbidity<sup>[22,23]</sup>. Choi *et al.*<sup>[22]</sup> reported no operative mortality and an 8% of major complication rate in a study of combined hepatectomy and RFA for multifocal HCCs. Their selection criterion for lobectomy of 10% or less indocyanine green retention at 15 min is conservative. The strategy of hepatectomy and RFA may reduce the surgical risk when compared with an extended resection, although this is still a high-risk procedure in patients with limited hepatic reserve.

## RFA FOR RECURRENT HCCS AFTER HEPATECTOMY

Another combination treatment is subsequent RFA for recurrent HCCs after hepatectomy. In spite of curative hepatectomy, recurrent tumors are found in more than 70% of patients within 5 years after hepatectomy, and repeat hepatectomy is recommended for intrahepatic recurrence<sup>[36-42]</sup>.

However, this is not feasible in the majority of patients because of significant hepatic dysfunction or multiplicity of recurrent HCCs<sup>[41,43-45]</sup>.

In the past, such patients underwent TACE or ethanol ablation<sup>[45-48]</sup>. Recently, RFA has increasingly been performed for treating recurrent tumors in the remnant liver after hepatectomy<sup>[49-54]</sup>. In addition to some initial reports introducing the possibility of RFA to treat recurrent HCCs after hepatectomy<sup>[49-51]</sup>, a study with 45 patients documented that the 3-year survival rate after percutaneous RFA for recurrent HCCs after hepatectomy was 54%<sup>[52]</sup>. Lu *et al.*<sup>[54]</sup> also reported on the long-term survival results of 72 patients who underwent percutaneous microwave ablation ( $n = 33$ ) and RFA ( $n = 39$ ). The overall survival rates at 3 years and 5 years after thermal ablation were 43% and 18%, respectively. In another study, the 3-year survival rate after percutaneous RFA for recurrent HCCs after hepatectomy was 44%<sup>[55]</sup>.

Repeat hepatectomy may promise complete resection of intrahepatic recurrences, and any extrahepatic lesions in the abdominal cavity can also be explored. However, this operation is more difficult to perform than an initial hepatectomy, and it results in increased risks of postoperative morbidity and mortality<sup>[38,41]</sup>. In prior reports on repeat hepatectomy for recurrent HCCs, the 3-year and 5-year survival rates were 56% to 83% and 40% to 52%, respectively<sup>[38,39,41,56,57]</sup>. A recent study of RFA for recurrent HCCs after hepatectomy in 102 patients demonstrated comparable long-term survival results (65.7% and 51.6% at 3 and 5 year, respectively)<sup>[53]</sup>. This study also showed that the primary effectiveness rate was 93.3% (111 of 119) and the cumulative rate of local tumor progression at 5 years was 11.9%. In this study, liver abscess is the only complication, which can be related with bilioenteric anastomoses following surgical procedures<sup>[58]</sup>. When percutaneous RFA is performed for recurrent HCCs abutting the gastrointestinal tract, bowel perforation frequently occurred due to postoperative adhesion<sup>[59,60]</sup>. Figure 2 shown a successful RFA of intrahepatic recurrent HCC in a 49-year-old man.



In three studies with large populations, long-term survival of patients with HCCs treated with percutaneous RFA as a first-line treatment depended upon the Child-Pugh class, serum  $\alpha$ -fetoprotein (AFP) level, age, tumor size, and multiplicity of tumors<sup>[61-63]</sup>. In addition, several prior reports suggested various prognostic factors after surgical resection for HCCs<sup>[24,29,64-66]</sup>. Among them, histopathologic grading of resected HCCs, tumor size, Child-Pugh class, fibrosis staging of the liver, serum AFP level, and microvascular invasion were generally considered to be prognostic predictors. However, in a recent study of RFA for recurrent HCCs after hepatectomy by Choi *et al.*<sup>[53]</sup> serum AFP level before RFA and resected tumor size were independent significant predictive factors of long-term survival. Lu *et al.*<sup>[54]</sup> reported that the pre-ablation serum AFP level was the only prognostic predictor.

## CONCLUSION

For the treatment of multifocal HCCs and recurrent HCC, RFA can be complementary to hepatectomy. In fact, most patients with HCCs received multimodal approaches to treatment that included hepatectomy, TACE, RFA, ethanol ablation, microwave ablation, radiation therapy, or systemic chemotherapy, either in sequence or combination<sup>[35,67]</sup>. Aggressive combination treatment by concurrent RFA and hepatic resection may enhance the chance of curative treatments for patients with multifocal tumors that are traditionally considered unresectable. However, further investigation should compare the outcome of hepatectomy plus RFA with that of hepatectomy alone to see whether the survival results are truly comparable<sup>[16]</sup>. For recurrent HCCs in patients who were not eligible for repeat hepatectomy, RFA should be considered. However, it remains unclear whether percutaneous RFA can replace repeat hepatectomy as the standard treatment for small, resectable, recurrent HCCs. For this issue, randomized controlled trials that compare RFA and repeat hepatectomy would be needed.

## REFERENCES

- Llovet JM, Burroughs A, Bruix J. Hepatocellular carcinoma. *Lancet* 2003; **362**: 1907-1917
- Llovet JM. Updated treatment approach to hepatocellular carcinoma. *J Gastroenterol* 2005; **40**: 225-235
- Schwartz JM, Ham JM. Treatment of Hepatocellular Carcinoma. *Curr Treat Options Gastroenterol* 2003; **6**: 465-472
- Poon RT, Fan ST, Tsang FH, Wong J. Locoregional therapies for hepatocellular carcinoma: a critical review from the surgeon's perspective. *Ann Surg* 2002; **235**: 466-486
- Lencioni RA, Allgaier HP, Cioni D, Olschewski M, Deibert P, Crocetti L, Frings H, Laubenberger J, Zuber I, Blum HE, Bartolozzi C. Small hepatocellular carcinoma in cirrhosis: randomized comparison of radio-frequency thermal ablation versus percutaneous ethanol injection. *Radiology* 2003; **228**: 235-240
- Lin SM, Lin CJ, Lin CC, Hsu CW, Chen YC. Radiofrequency ablation improves prognosis compared with ethanol injection for hepatocellular carcinoma  $\leq$  4 cm. *Gastroenterology* 2004; **127**: 1714-1723
- Lin SM, Lin CJ, Lin CC, Hsu CW, Chen YC. Randomised controlled trial comparing percutaneous radiofrequency thermal ablation, percutaneous ethanol injection, and percutaneous acetic acid injection to treat hepatocellular carcinoma of 3 cm or less. *Gut* 2005; **54**: 1151-1156
- Shibata T, Iimuro Y, Yamamoto Y, Maetani Y, Ametani F, Itoh K, Konishi J. Small hepatocellular carcinoma: comparison of radio-frequency ablation and percutaneous microwave coagulation therapy. *Radiology* 2002; **223**: 331-337
- Shiina S, Teratani T, Obi S, Sato S, Tateishi R, Fujishima T, Ishikawa T, Koike Y, Yoshida H, Kawabe T, Omata M. A randomized controlled trial of radiofrequency ablation with ethanol injection for small hepatocellular carcinoma. *Gastroenterology* 2005; **129**: 122-130
- Vivarelli M, Guglielmi A, Ruzzenente A, Cucchetti A, Bellusci R, Cordiano C, Cavallari A. Surgical resection versus percutaneous radiofrequency ablation in the treatment of hepatocellular carcinoma on cirrhotic liver. *Ann Surg* 2004; **240**: 102-107
- Hong SN, Lee SY, Choi MS, Lee JH, Koh KC, Paik SW, Yoo BC, Rhee JC, Choi D, Lim HK, Lee KW, Joh JW. Comparing the outcomes of radiofrequency ablation and surgery in patients with a single small hepatocellular carcinoma and well-preserved hepatic function. *J Clin Gastroenterol* 2005; **39**: 247-252
- Khan MR, Poon RT, Ng KK, Chan AC, Yuen J, Tung H, Tsang J, Fan ST. Comparison of percutaneous and surgical approaches for radiofrequency ablation of small and medium hepatocellular carcinoma. *Arch Surg* 2007; **142**: 1136-1143; discussion 1143
- Guglielmi A, Ruzzenente A, Valdegamberi A, Pachera S, Campagnaro T, D'Onofrio M, Martone E, Nicoli P, Iacono C. Radiofrequency ablation versus surgical resection for the treatment of hepatocellular carcinoma in cirrhosis. *J Gastrointest Surg* 2008; **12**: 192-198
- Chen MS, Li JQ, Zheng Y, Guo RP, Liang HH, Zhang YQ, Lin XJ, Lau WY. A prospective randomized trial comparing percutaneous local ablative therapy and partial hepatectomy for small hepatocellular carcinoma. *Ann Surg* 2006; **243**: 321-328
- Livraghi T, Meloni F, Di Stasi M, Rolle E, Solbiati L, Tinelli C, Rossi S. Sustained complete response and complications rates after radiofrequency ablation of very early hepatocellular carcinoma in cirrhosis: Is resection still the treatment of choice? *Hepatology* 2008; **47**: 82-89
- Poon RT. Radiofrequency ablation combined with resection enhances chance for curative treatment of hepatocellular carcinoma. *Ann Surg Oncol* 2007; **14**: 3299-3300
- Abdalla EK, Vauthey JN, Ellis LM, Ellis V, Pollock R, Broglio KR, Hess K, Curley SA. Recurrence and outcomes following hepatic resection, radiofrequency ablation, and combined resection/ablation for colorectal liver metastases. *Ann Surg* 2004; **239**: 818-825; discussion 825-827
- Elias D, Goharin A, El Otmány A, Taieb J, Duvillard P, Lasser P, de Baere T. Usefulness of intraoperative radiofrequency thermoablation of liver tumours associated or not with hepatectomy. *Eur J Surg Oncol* 2000; **26**: 763-769
- Pawlik TM, Izzo F, Cohen DS, Morris JS, Curley SA. Combined resection and radiofrequency ablation for advanced hepatic malignancies: results in 172 patients. *Ann Surg Oncol* 2003; **10**: 1059-1069
- Wakabayashi H, Ushiyama T, Ishimura K, Izuishi K, Karasawa Y, Masaki T, Watanabe S, Kuriyama S, Maeta H. Significance of reduction surgery in multidisciplinary treatment of advanced hepatocellular carcinoma with multiple intrahepatic lesions. *J Surg Oncol* 2003; **82**: 98-103
- Liu CL, Fan ST, Lo CM, Ng IO, Poon RT, Wong J. Hepatic resection for bilobar hepatocellular carcinoma: is it justified? *Arch Surg* 2003; **138**: 100-104
- Choi D, Lim HK, Joh JW, Kim SJ, Kim MJ, Rhim H, Kim YS, Yoo BC, Paik SW, Park CK. Combined hepatectomy and radiofrequency ablation for multifocal hepatocellular carcinomas: long-term follow-up results and prognostic factors. *Ann Surg Oncol* 2007; **14**: 3510-3518

- 23 **Kim YS**, Rhim H, Lim HK, Choi D, Lee WJ, Jeon TY, Joh JW, Kim SJ. Intraoperative radiofrequency ablation for hepatocellular carcinoma: long-term results in a large series. *Ann Surg Oncol* 2008; **15**: 1862-1870
- 24 **Hanazaki K**, Kajikawa S, Koide N, Adachi W, Amano J. Prognostic factors after hepatic resection for hepatocellular carcinoma with hepatitis C viral infection: univariate and multivariate analysis. *Am J Gastroenterol* 2001; **96**: 1243-1250
- 25 **Ng KK**, Poon RT. Current treatment strategy for hepatocellular carcinoma. *Saudi Med J* 2007; **28**: 1330-1338
- 26 **Pawlik TM**, Scoggins CR, Thomas MB, Vauthey JN. Advances in the surgical management of liver malignancies. *Cancer J* 2004; **10**: 74-87
- 27 **Poon RT**, Fan ST. Hepatectomy for hepatocellular carcinoma: patient selection and postoperative outcome. *Liver Transpl* 2004; **10**: S39-S45
- 28 **Vauthey JN**, Chaoui A, Do KA, Bilimoria MM, Fenstermacher MJ, Charnsangavej C, Hicks M, Alsfasser G, Lauwers G, Hawkins IF, Caridi J. Standardized measurement of the future liver remnant prior to extended liver resection: methodology and clinical associations. *Surgery* 2000; **127**: 512-519
- 29 **Yanaga K**. Current status of hepatic resection for hepatocellular carcinoma. *J Gastroenterol* 2004; **39**: 919-926
- 30 **Hanazaki K**, Kajikawa S, Shimozaawa N, Mihara M, Shimada K, Hiraguri M, Koide N, Adachi W, Amano J. Survival and recurrence after hepatic resection of 386 consecutive patients with hepatocellular carcinoma. *J Am Coll Surg* 2000; **191**: 381-388
- 31 **Hsia CY**, Lui WY, Chau GY, King KL, Loong CC, Wu CW. Perioperative safety and prognosis in hepatocellular carcinoma patients with impaired liver function. *J Am Coll Surg* 2000; **190**: 574-579
- 32 **Makuuchi M**, Takayama T, Kubota K, Kimura W, Midorikawa Y, Miyagawa S, Kawasaki S. Hepatic resection for hepatocellular carcinoma – Japanese experience. *Hepatogastroenterology* 1998; **45** Suppl 3: 1267-1274
- 33 **Ishii H**, Yamamoto J, Ikari T. Adjuvant treatments for resectable hepatocellular carcinoma. *J Hepatobiliary Pancreat Surg* 2008; **15**: 459-462
- 34 **Boucher E**, Forner A, Reig M, Bruix J. New drugs for the treatment of hepatocellular carcinoma. *Liver Int* 2009; **29** Suppl 1: 148-158
- 35 **Cabibbo G**, Latteri F, Antonucci M, Craxi A. Multimodal approaches to the treatment of hepatocellular carcinoma. *Nat Clin Pract Gastroenterol Hepatol* 2009; **6**: 159-169
- 36 **Balsells J**, Charco R, Lazaro JL, Murio E, Vargas V, Allende E, Margarit C. Resection of hepatocellular carcinoma in patients with cirrhosis. *Br J Surg* 1996; **83**: 758-761
- 37 **Matsuda M**, Fujii H, Kono H, Matsumoto Y. Surgical treatment of recurrent hepatocellular carcinoma based on the mode of recurrence: repeat hepatic resection or ablation are good choices for patients with recurrent multicentric cancer. *J Hepatobiliary Pancreat Surg* 2001; **8**: 353-359
- 38 **Neeleman N**, Andersson R. Repeated liver resection for recurrent liver cancer. *Br J Surg* 1996; **83**: 893-901
- 39 **Shuto T**, Kinoshita H, Hirohashi K, Kubo S, Tanaka H, Tsukamoto T, Okuda T. Indications for, and effectiveness of, a second hepatic resection for recurrent hepatocellular carcinoma. *Hepatogastroenterology* 1996; **43**: 932-937
- 40 **Suenaga M**, Sugiura H, Kokuba Y, Uehara S, Kurumiya T. Repeated hepatic resection for recurrent hepatocellular carcinoma in eighteen cases. *Surgery* 1994; **115**: 452-457
- 41 **Sugimachi K**, Maehara S, Tanaka S, Shimada M, Sugimachi K. Repeat hepatectomy is the most useful treatment for recurrent hepatocellular carcinoma. *J Hepatobiliary Pancreat Surg* 2001; **8**: 410-416
- 42 **Takenaka K**, Kawahara N, Yamamoto K, Kajiyama K, Maeda T, Itasaka H, Shirabe K, Nishizaki T, Yanaga K, Sugimachi K. Results of 280 liver resections for hepatocellular carcinoma. *Arch Surg* 1996; **131**: 71-76
- 43 **Capussotti L**, Borgonovo G, Bouzari H, Smadja C, Grange D, Franco D. Results of major hepatectomy for large primary liver cancer in patients with cirrhosis. *Br J Surg* 1994; **81**: 427-431
- 44 **Hu RH**, Lee PH, Yu SC, Dai HC, Sheu JC, Lai MY, Hsu HC, Chen DS. Surgical resection for recurrent hepatocellular carcinoma: prognosis and analysis of risk factors. *Surgery* 1996; **120**: 23-29
- 45 **Shimada M**, Takenaka K, Gion T, Fujiwara Y, Kajiyama K, Maeda T, Shirabe K, Nishizaki T, Yanaga K, Sugimachi K. Prognosis of recurrent hepatocellular carcinoma: a 10-year surgical experience in Japan. *Gastroenterology* 1996; **111**: 720-726
- 46 **Okazaki M**, Yamasaki S, Ono H, Higashihara H, Koganemaru F, Kimura S, Kuroda Y, Sato S, Ryu K, Ohtsubo T. Chemembolotherapy for recurrent hepatocellular carcinoma in the residual liver after hepatectomy. *Hepatogastroenterology* 1993; **40**: 320-323
- 47 **Poon RT**, Fan ST, Lo CM, Liu CL, Wong J. Intrahepatic recurrence after curative resection of hepatocellular carcinoma: long-term results of treatment and prognostic factors. *Ann Surg* 1999; **229**: 216-222
- 48 **Takayasu K**, Wakao F, Moriyama N, Muramatsu Y, Yamazaki S, Kosuge T, Takayama T, Okada S, Okazaki N, Makuuchi M. Postresection recurrence of hepatocellular carcinoma treated by arterial embolization: analysis of prognostic factors. *Hepatology* 1992; **16**: 906-911
- 49 **Elias D**, De Baere T, Smayra T, Ouellet JF, Roche A, Lasser P. Percutaneous radiofrequency thermoablation as an alternative to surgery for treatment of liver tumour recurrence after hepatectomy. *Br J Surg* 2002; **89**: 752-756
- 50 **Kainuma O**, Asano T, Aoyama H, Shinohara Y. Recurrent hepatocellular carcinoma successfully treated with radiofrequency thermal ablation. *J Hepatobiliary Pancreat Surg* 1999; **6**: 190-194
- 51 **Nicoli N**, Casaril A, Marchiori L, Mangiante G, Hasheminia AR. Treatment of recurrent hepatocellular carcinoma by radiofrequency thermal ablation. *J Hepatobiliary Pancreat Surg* 2001; **8**: 417-421
- 52 **Choi D**, Lim HK, Kim MJ, Lee SH, Kim SH, Lee WJ, Lim JH, Joh JW, Kim YI. Recurrent hepatocellular carcinoma: percutaneous radiofrequency ablation after hepatectomy. *Radiology* 2004; **230**: 135-141
- 53 **Choi D**, Lim HK, Rhim H, Kim YS, Yoo BC, Paik SW, Joh JW, Park CK. Percutaneous radiofrequency ablation for recurrent hepatocellular carcinoma after hepatectomy: long-term results and prognostic factors. *Ann Surg Oncol* 2007; **14**: 2319-2329
- 54 **Lu MD**, Yin XY, Xie XY, Xu HX, Xu ZF, Liu GJ, Kuang M, Zheng YL. Percutaneous thermal ablation for recurrent hepatocellular carcinoma after hepatectomy. *Br J Surg* 2005; **92**: 1393-1398
- 55 **Schindera ST**, Nelson RC, DeLong DM, Clary B. Intrahepatic tumor recurrence after partial hepatectomy: value of percutaneous radiofrequency ablation. *J Vasc Interv Radiol* 2006; **17**: 1631-1637
- 56 **Arii S**, Teramoto K, Kawamura T, Okamoto H, Kaido T, Mori A, Imamura M. Characteristics of recurrent hepatocellular carcinoma in Japan and our surgical experience. *J Hepatobiliary Pancreat Surg* 2001; **8**: 397-403
- 57 **Nagasue N**, Kohno H, Hayashi T, Uchida M, Ono T, Yukaya H, Yamanoi A. Repeat hepatectomy for recurrent hepatocellular carcinoma. *Br J Surg* 1996; **83**: 127-131
- 58 **Choi D**, Lim HK, Kim MJ, Kim SJ, Kim SH, Lee WJ, Lim JH, Paik SW, Yoo BC, Choi MS, Kim S. Liver abscess after percutaneous radiofrequency ablation for hepatocellular carcinomas: frequency and risk factors. *AJR Am J Roentgenol* 2005; **184**: 1860-1867
- 59 **Choi D**, Lim HK, Kim MJ, Kim SH, Lee WJ, Kim SH, Lim JH, Paik SW, Koh KC, Yoo BC. Therapeutic efficacy and safety of percutaneous radiofrequency ablation of hepatocellular carcinoma abutting the gastrointestinal tract. *AJR Am J Roentgenol* 2004; **183**: 1417-1424

- 60 **Meloni MF**, Goldberg SN, Moser V, Piazza G, Livraghi T. Colonic perforation and abscess following radiofrequency ablation treatment of hepatoma. *Eur J Ultrasound* 2002; **15**: 73-76
- 61 **Choi D**, Lim HK, Rhim H, Kim YS, Lee WJ, Paik SW, Koh KC, Lee JH, Choi MS, Yoo BC. Percutaneous radiofrequency ablation for early-stage hepatocellular carcinoma as a first-line treatment: long-term results and prognostic factors in a large single-institution series. *Eur Radiol* 2007; **17**: 684-692
- 62 **Lencioni R**, Cioni D, Crocetti L, Franchini C, Pina CD, Lera J, Bartolozzi C. Early-stage hepatocellular carcinoma in patients with cirrhosis: long-term results of percutaneous image-guided radiofrequency ablation. *Radiology* 2005; **234**: 961-967
- 63 **Tateishi R**, Shiina S, Teratani T, Obi S, Sato S, Koike Y, Fujishima T, Yoshida H, Kawabe T, Omata M. Percutaneous radiofrequency ablation for hepatocellular carcinoma. An analysis of 1000 cases. *Cancer* 2005; **103**: 1201-1209
- 64 **Koike Y**, Shiratori Y, Sato S, Obi S, Teratani T, Imamura M, Hamamura K, Imai Y, Yoshida H, Shiina S, Omata M. Risk factors for recurring hepatocellular carcinoma differ according to infected hepatitis virus-an analysis of 236 consecutive patients with a single lesion. *Hepatology* 2000; **32**: 1216-1223
- 65 **Wayne JD**, Lauwers GY, Ikai I, Doherty DA, Belghiti J, Yamaoka Y, Regimbeau JM, Nagorney DM, Do KA, Ellis LM, Curley SA, Pollock RE, Vauthey JN. Preoperative predictors of survival after resection of small hepatocellular carcinomas. *Ann Surg* 2002; **235**: 722-730; discussion 730-731
- 66 **Zhou XD**, Tang ZY, Yang BH, Lin ZY, Ma ZC, Ye SL, Wu ZQ, Fan J, Qin LX, Zheng BH. Experience of 1000 patients who underwent hepatectomy for small hepatocellular carcinoma. *Cancer* 2001; **91**: 1479-1486
- 67 **Masaki T**, Morishita A, Kurokohchi K, Kuriyama S. Multidisciplinary treatment of patients with hepatocellular carcinoma. *Expert Rev Anticancer Ther* 2006; **6**: 1377-1384

**S- Editor** Li LF **L- Editor** Hughes D **E- Editor** Yang C