

## Retroanastomotic hernia after Moynihan's gastroenterostomy

Kerem Karaman, Omer Yalkin, Metin Ercan, Hakan Demir, Fatih Altintoprak, Ismail Zengin

Kerem Karaman, Metin Ercan, Fatih Altintoprak, Department of General Surgery, Faculty of Medicine, Sakarya University, Serdivan 54130, Sakarya, Turkey

Omer Yalkin, Hakan Demir, Ismail Zengin, Department of General Surgery, Sakarya Teaching and Research Hospital, Serdivan 54130, Sakarya, Turkey

Author contributions: All the authors contributed equally to this work.

Correspondence to: Kerem Karaman, MD, Department of General Surgery, Faculty of Medicine, Sakarya University, No: 76 Atioglu Sitesi B Blok Kapısı Girişi Daire: 4, Serdivan 54130, Sakarya, Turkey. [karaman\\_kerem@yahoo.com.tr](mailto:karaman_kerem@yahoo.com.tr)

Telephone: +90-505-4926238

Received: May 25, 2014 Revised: June 24, 2014

Accepted: July 25, 2014

Published online: September 27, 2014

### Abstract

Retroanastomotic hernias after gastroenterostomies-either antecolic or retrocolic-are extremely rare but are associated with high mortality rates due to delayed identification which precludes immediate surgical reduction. In this report, we present a 77-year-old man with retroanastomotic herniation of the efferent loop segments that occurred 14 years after a Moynihan's gastroenterostomy.

© 2014 Baishideng Publishing Group Inc. All rights reserved.

**Key words:** Retroanastomotic hernia; Moynihan's gastroenterostomy; Intestinal obstruction

**Core tip:** Retroanastomotic hernia is a rare but fatal condition. Preoperative diagnosis by ultrasound and/or computerized tomography is difficult and sometimes confusing. Early surgery is the key to decreasing mortality. The use of a short afferent loop and closure of the retroanastomotic space would decrease the incidence of these hernias.

Karaman K, Yalkin O, Ercan M, Demir H, Altintoprak F, Zengin

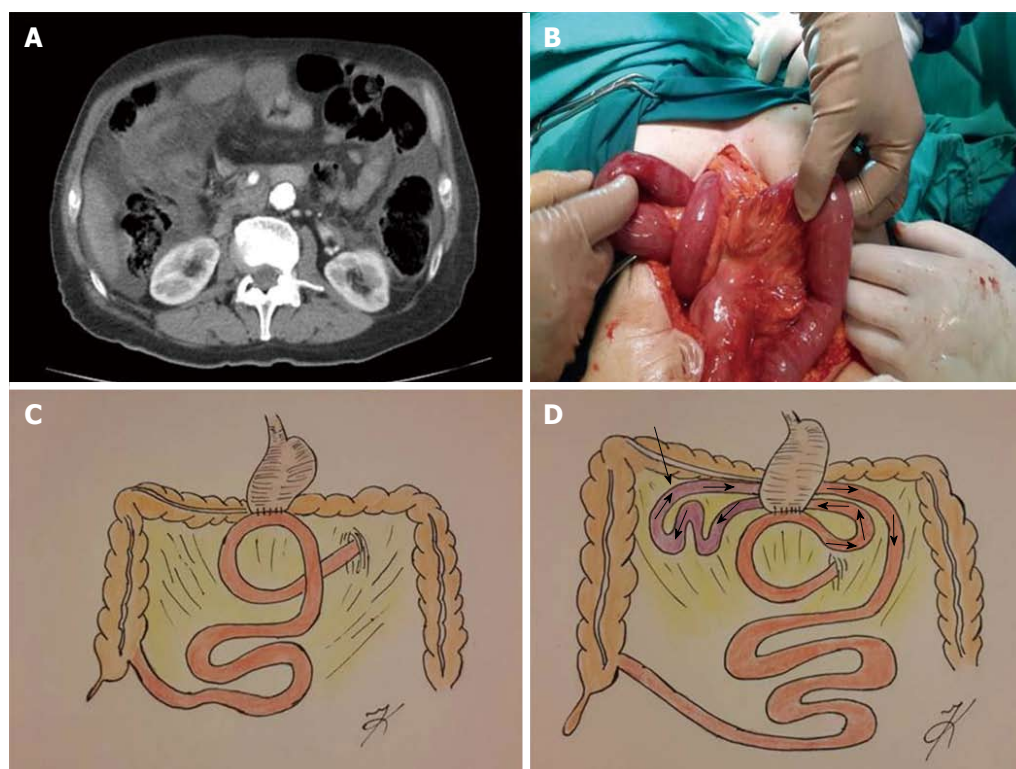
I. Retroanastomotic hernia after Moynihan's gastroenterostomy. *World J Gastrointest Surg* 2014; 6(9): 187-189 Available from: URL: <http://www.wjgnet.com/1948-9366/full/v6/i9/187.htm> DOI: <http://dx.doi.org/10.4240/wjgs.v6.i9.187>

### INTRODUCTION

Retroanastomotic hernias after gastroenterostomies-either antecolic or retrocolic-are extremely rare but are associated with high mortality rates due to a delay in identification which precludes immediate surgical reduction<sup>[1]</sup>. Since Petersen<sup>[2]</sup> provided the first detailed description of a retroanastomotic hernia known as Petersen's hernia in 1900, there have been few case reports or case series in the literature referring to this entity. In this report, we present a 77-year-old man with retroanastomotic herniation of the efferent loop segments that occurred 14 years after a Moynihan's gastroenterostomy.

### CASE REPORT

A 77-year-old man presented with a sudden onset of acute abdominal pain accompanied by nausea and vomiting. The physical examination revealed rebound tenderness with abdominal distention. Abdominal computed tomography showed edematous bowel wall thickening in proximal small bowel segments and dense fluid collection in the right upper quadrant which was considered an indication of visceral organ perforation (Figure 1A). The patient underwent a subtotal gastrectomy for duodenal ulcer 14 years ago. During explorative laparotomy, a retroanastomotic hernia of the efferent loop segments, passing from right to left through the orifice between the transverse colon and the antecolic, antiperistaltic gastrojejunostomy anastomosis (Moynihan type), was found (Figure 1B-D). The herniated bowel segments were reduced and the defect was closed with running sutures. Viability of the ischemic bowel segments improved after application of warm pads and the abdomen was closed without further intervention. The postoperative course was un-



**Figure 1** Illustration of diagnosis and treatment of the present case. A: Abdominal computed tomography image of the retroanastomotic hernia; B: Intraoperative image of the retroanastomotic herniation; C: Illustration of the original operation (Moynihan's gastroenterostomy); D: Illustration of the retroanastomotic herniation of the present case with a black arrow showing the incarcerated bowel segments of the efferent loop.

eventful and the patient was discharged on the fifth post-operative day.

## DISCUSSION

Herniation of intestinal loops through the defect between the small bowel limbs can occur after any type of gastrojejunostomy<sup>[3,4]</sup>. Half of all retroanastomotic hernias occur within the first postoperative month; more than half of the remaining during the first year, and a small percentage even later<sup>[5]</sup>. Efferent loop hernias occur three times more than those involving the afferent loop. For afferent loop hernias, pain is localized to the epigastric region and is constantly sudden in onset. Vomiting is infrequent and bile is almost absent, if not at all. On the other hand, in efferent loop hernias, abdominal pain is more generalized and colicky, and vomiting with bile stained material is common<sup>[1]</sup>. Preoperative diagnosis by ultrasound and/or computed tomography is difficult and sometimes confusing: the most frequently detected signs are mural thickening and dilatation of the herniated bowel loops<sup>[6]</sup>.

Efferent loop hernias usually occur from right to left. In the present case, however, the direction of the herniation was from left to right, which may be related to the type of gastroenterostomy (Moynihan type). Another important characteristic of the present case was the long duration of the disease without any signs.

In conclusion, retroanastomotic hernias, though rare, are a potentially fatal condition. Early surgery is the key

to decreasing mortality. The use of a short afferent loop and closure of the retroanastomotic space would decrease the incidence of these hernias.

## COMMENTS

### Case characteristics

A 77-year-old man presented with retroanastomotic herniation of the efferent loop segments that occurred 14 years after a Moynihan's gastroenterostomy.

### Clinical diagnosis

Retroanastomotic herniation of efferent loop segments after the antecolic gastrojejunostomy anastomosis.

### Differential diagnosis

Acute abdomen due to visceral organ perforation.

### Laboratory diagnosis

White blood cells: 16.400/mm<sup>3</sup>; hemoglobin: 121.0 g/L. Metabolic panel and liver function test were within normal limits.

### Imaging diagnosis

Computed tomography showed edematous bowel wall thickening in proximal small bowel segments and dense fluid collection in the right upper quadrant which was considered an indication of visceral organ perforation.

### Treatment

Reduction of the herniated efferent loop segments and primary closure of the hernia defect.

### Related reports

There have been few case reports or case series in the literature referring to this entity.

### Term explanation

Retroanastomotic hernias after gastroenterostomies-either antecolic or retrocolic-are extremely rare but are associated with high mortality rates due to a delay in identification which precludes immediate surgical reduction.

### Experiences and lessons

Retroanastomotic hernias, though rare, are a potentially fatal condition. Early

surgery is the key to decreasing mortality. The use of a short afferent loop and closure of the retroanastomotic space would decrease the incidence of these hernias.

### Peer review

This article is referring a rare complication of gastroenterostomy anastomosis and discusses the possible causes and preventive approaches.

## REFERENCES

- 1 **Rutledge RH.** Retroanastomotic hernias after gastrojejunal anastomoses. *Ann Surg* 1973; **177**: 547-553 [PMID: 4704039 DOI: 10.1097/00000658-197305000-00006]
- 2 **Petersen W.** Ueber darmverschlingung nach der gastroenterostomie. *Arch Klin Chir* 1900; **62**: 94-97
- 3 **Faria G,** Preto J, Oliveira M, Pimenta T, Baptista M, Costa-Maia J. Petersen's space hernia: A rare but expanding diagnosis. *Int J Surg Case Rep* 2011; **2**: 141-143 [PMID: 22096708 DOI: 10.1016/j.ijscr.2011.03.004]
- 4 **Kojima K,** Inokuchi M, Kato K, Motoyama K, Sugihara K. Petersen's hernia after laparoscopic distal gastrectomy with Roux-en-Y reconstruction for gastric cancer. *Gastric Cancer* 2014; **17**: 146-151 [PMID: 23558458 DOI: 10.1007/s10120-013-0256-8]
- 5 **Bastable JR,** Huddy PE. Retro-anastomotic hernia. Eight cases of internal hernia followSing gastrojejunal anastomosis, with a review of the literature. *Br J Surg* 1960; **48**: 183-189 [PMID: 13687665 DOI: 10.1002/bjs.18004820821]
- 6 **Kwon JH,** Jang HY. Retroanastomotic hernia after gastrojejunostomy: US and CT findings with an emphasis on the whirl sign. *Abdom Imaging* 2005; **30**: 656-664 [PMID: 16252151 DOI: 10.1007/s00261-005-0310-z]

**P- Reviewer:** Kate V, Piccolo G, Shrestha BM **S- Editor:** Song XX  
**L- Editor:** Wang TQ **E- Editor:** Liu SQ





Published by **Baishideng Publishing Group Inc**

8226 Regency Drive, Pleasanton, CA 94588, USA

Telephone: +1-925-223-8242

Fax: +1-925-223-8243

E-mail: [bpgoffice@wjgnet.com](mailto:bpgoffice@wjgnet.com)

Help Desk: <http://www.wjgnet.com/esps/helpdesk.aspx>

<http://www.wjgnet.com>

