

# World Journal of *Gastrointestinal Oncology*

*World J Gastrointest Oncol* 2018 December 15; 10(12): 465-531





### REVIEW

- 465 Current strategies for malignant pedunculated colorectal polyps  
*Ciocalteu A, Gheonea DI, Saftoiu A, Streba L, Dragoescu NA, Tenea-Cojan TS*

### ORIGINAL ARTICLE

#### Basic Study

- 476 Histological analysis of human pancreatic carcinoma following irreversible electroporation in a nude mouse model  
*Su JJ, Xu K, Wang PF, Zhang HY, Chen YL*

#### Retrospective Study

- 487 Clutch Cutter knife efficacy in endoscopic submucosal dissection for early gastric neoplasms  
*Hayashi Y, Esaki M, Suzuki S, Ihara E, Yokoyama A, Sakisaka S, Hosokawa T, Tanaka Y, Mizutani T, Tsuruta S, Iwao A, Yamakawa S, Irie A, Minoda Y, Hata Y, Ogino H, Akiho H, Ogawa Y*

- 496 Stents combined with iodine-125 implantation to treat main portal vein tumor thrombus  
*Wu YF, Wang T, Yue ZD, Zhao HW, Wang L, Fan ZH, He FL, Liu FQ*

#### Clinical Trials Study

- 505 Multicenter phase II trial of modified FOLFIRINOX in gemcitabine-refractory pancreatic cancer  
*Chung MJ, Kang H, Kim HG, Hyun JJ, Lee JK, Lee KH, Noh MH, Kang DH, Lee SH, Bang S, Pancreatobiliary Cancer Study Group of Korean Society of Gastrointestinal Cancer*

### CASE REPORT

- 516 Small intestinal hemangioma: Endoscopic or surgical intervention? A case report and review of literature  
*Hu PF, Chen H, Wang XH, Wang WJ, Su N, Shi B*
- 522 Experience in the diagnosis and treatment of mesenteric lymphangioma in adults: A case report and review of literature  
*Chen J, Du L, Wang DR*

### LETTER TO THE EDITOR

- 528 Considering FOLFOXIRI plus bevacizumab for metastatic colorectal cancer with left-sided tumors  
*Sunakawa Y, Satake H, Ichikawa W*

## Contents

*World Journal of Gastrointestinal Oncology*  
Volume 10 Number 12 December 15, 2018

### ABOUT COVER

Editorial Board Member of *World Journal of Gastrointestinal Oncology*, Mao-Ming Xiong, MD, Professor, Department of General Surgery, First Affiliated Hospital of Anhui Medical University, Hefei 230022, Anhui Province, China

### AIM AND SCOPE

*World Journal of Gastrointestinal Oncology* (*World J Gastrointest Oncol*, *WJGO*, online ISSN 1948-5204, DOI: 10.4251) is a peer-reviewed open access academic journal that aims to guide clinical practice and improve diagnostic and therapeutic skills of clinicians.

*WJGO* covers topics concerning carcinogenesis, tumorigenesis, metastasis, diagnosis, prevention, prognosis, clinical manifestations, nutritional support, molecular mechanisms, and therapy of benign and malignant tumors of the digestive tract. The current columns of *WJGO* include editorial, frontier, diagnostic advances, therapeutics advances, field of vision, mini-reviews, review, topic highlight, medical ethics, original articles, case report, clinical case conference (Clinicopathological conference), and autobiography. Priority publication will be given to articles concerning diagnosis and treatment of gastrointestinal oncology diseases. The following aspects are covered: Clinical diagnosis, laboratory diagnosis, differential diagnosis, imaging tests, pathological diagnosis, molecular biological diagnosis, immunological diagnosis, genetic diagnosis, functional diagnostics, and physical diagnosis; and comprehensive therapy, drug therapy, surgical therapy, interventional treatment, minimally invasive therapy, and robot-assisted therapy.

We encourage authors to submit their manuscripts to *WJGO*. We will give priority to manuscripts that are supported by major national and international foundations and those that are of great clinical significance.

### INDEXING/ABSTRACTING

*World Journal of Gastrointestinal Oncology* (*WJGO*) is now indexed in Science Citation Index Expanded (also known as SciSearch®), PubMed, and PubMed Central. The 2018 edition of Journal Citation Reports® cites the 2017 impact factor for *WJGO* as 3.140 (5-year impact factor: 3.228), ranking *WJGO* as 39 among 80 journals in gastroenterology and hepatology (quartile in category Q2), and 114 among 222 journals in oncology (quartile in category Q3).

### EDITORS FOR THIS ISSUE

Responsible Assistant Editor: *Xiang Li*  
Responsible Electronic Editor: *Han Song*  
Proofing Editor-in-Chief: *Lian-Sheng Ma*

Responsible Science Editor: *Fang-Fang Ji*  
Proofing Editorial Office Director: *Jin-Lei Wang*

#### NAME OF JOURNAL

*World Journal of Gastrointestinal Oncology*

#### ISSN

ISSN 1948-5204 (online)

#### LAUNCH DATE

February 15, 2009

#### FREQUENCY

Monthly

#### EDITORIAL BOARD MEMBERS

All editorial board members resources online at <https://www.wjgnet.com/1948-5204/editorialboard.htm>

#### EDITORIAL OFFICE

Jin-Lei Wang, Director  
*World Journal of Gastrointestinal Oncology*  
Baishideng Publishing Group Inc

7901 Stoneridge Drive, Suite 501, Pleasanton, CA 94588, USA

Telephone: +1-925-2238242

Fax: +1-925-2238243

E-mail: [editorialoffice@wjgnet.com](mailto:editorialoffice@wjgnet.com)

Help Desk: <https://www.f6publishing.com/helpdesk>

<https://www.wjgnet.com>

#### PUBLISHER

Baishideng Publishing Group Inc

7901 Stoneridge Drive,  
Suite 501, Pleasanton, CA 94588, USA

Telephone: +1-925-2238242

Fax: +1-925-2238243

E-mail: [bpgoffice@wjgnet.com](mailto:bpgoffice@wjgnet.com)

Help Desk: <https://www.f6publishing.com/helpdesk>

<https://www.wjgnet.com>

#### PUBLICATION DATE

December 15, 2018

#### COPYRIGHT

© 2018 Baishideng Publishing Group Inc. Articles published by this Open-Access journal are distributed under the terms of the Creative Commons Attribution Non-commercial License, which permits use, distribution, and reproduction in any medium, provided the original work is properly cited, the use is non commercial and is otherwise in compliance with the license.

#### SPECIAL STATEMENT

All articles published in journals owned by the Baishideng Publishing Group (BPG) represent the views and opinions of their authors, and not the views, opinions or policies of the BPG, except where otherwise explicitly indicated.

#### INSTRUCTIONS TO AUTHORS

<https://www.wjgnet.com/bpg/gerinfo/204>

#### ONLINE SUBMISSION

<https://www.f6publishing.com>

## Small intestinal hemangioma: Endoscopic or surgical intervention? A case report and review of literature

Ping-Fang Hu, Han Chen, Xiao-Hang Wang, Wei-Jun Wang, Ning Su, Bin Shi

Ping-Fang Hu, Xiao-Hang Wang, Bin Shi, Department of Gastroenterology, Changzheng Hospital, Second Military Medical University, Shanghai 200003, China

Han Chen, Department of General Surgery, Hongkou Branch of Changhai Hospital, Second Military Medical University, Shanghai 200081, China

Wei-Jun Wang, Ning Su, Department of General Surgery, Changzheng Hospital, Second Military Medical University, Shanghai 200003, China

ORCID number: Ping-Fang Hu (0000-0002-2790-9674); Han Chen (0000-0002-5912-3692); Xiao-Hang Wang (0000-0001-7598-9755); Wei-Jun Wang (0000-0002-8831-0665); Ning Su (0000-0002-8423-0975); Bin Shi (0000-0003-1775-4581).

**Author contributions:** Hu PF and Chen H reviewed the literature, designed the case report presentation and wrote the manuscript; Wang XH participated in manuscript preparation, revision, patient investigation and treatment; Wang WJ and Su N participated in patient investigation and treatment and provided the gross and pathology images; Shi B designed the case report presentation and revised the manuscript.

**Informed consent statement:** The study participant provided informed written consent prior to study enrollment.

**Conflict of interest statement:** The authors have no conflict of interest to declare.

**CARE Checklist (2016) statement:** The authors have read the CARE Checklist (2016), and the manuscript was prepared and revised according to the CARE Checklist (2016).

**Open-Access:** This article is an open-access article that was selected by an in-house editor and fully peer-reviewed by external reviewers. It is distributed in accordance with the Creative Commons Attribution Non Commercial (CC BY-NC 4.0) license, which permits others to distribute, remix, adapt, build upon this work non-commercially, and license their derivative works on different terms, provided the original work is properly cited and the use is non-commercial. See: <http://creativecommons.org/licenses/by-nc/4.0/>

**Manuscript source:** Unsolicited manuscript

Corresponding author to: Bin Shi, MD, Professor, Department of Gastroenterology, Changzheng Hospital, Second Military Medical University, 415 Fengyang Road, Shanghai 200003, China. [shibin7305@smmu.edu.cn](mailto:shibin7305@smmu.edu.cn)  
Telephone: +86-21-81885346  
Fax: +86-21-81886924

Received: September 18, 2018

Peer-review started: September 18, 2018

First decision: October 15, 2018

Revised: October 24, 2018

Accepted: November 7, 2018

Article in press: November 7, 2018

Published online: December 15, 2018

### Abstract

#### BACKGROUND

Hemangioma of the small intestine is a rare vascular malformation. Before the advent of capsule endoscopy (CE) and balloon-assisted enteroscopy (BAE), preoperative diagnosis of this disease was extremely difficult.

#### CASE SUMMARY

In this study, we report a 24-year-old female with a large transmural small bowel cavernous hemangioma, which was diagnosed with CE and BAE preoperatively and removed successfully using minimally invasive surgery. Meanwhile, we perform a literature review of the studies about intestinal hemangiomas published after 2000. Literature review revealed that 91.9% of the lesions were diagnosed preoperatively by CE and/or BAE and 45.9% of them were treated endoscopically, which is a marked improvement compared to before 2000. Therefore, CE and BAE are useful modalities for the preoperative diagnosis of hemangiomas in the small intestine.

#### CONCLUSION

Endoscopic treatment of intestinal hemangioma is



generally prudent and might be suitable for multiple, relatively small lesions.

**Key words:** Hemangioma; Capsule endoscopy; Balloon-assisted enteroscopy; Endoscopic intervention; Surgery; Case report

© **The Author(s) 2018.** Published by Baishideng Publishing Group Inc. All rights reserved.

**Core tip:** Hemangioma of the small intestine is a rare disease and mostly presents as gastrointestinal bleeding. With the advent of capsule endoscopy and balloon-assisted enteroscopy, the preoperative diagnosis of this disease has been considerably improved. Surgical resection is the conventional treatment modality. With the improvement of endoscopic therapeutic interventions, less invasive procedures are becoming possible. However, potential risks of endoscopic treatment include bleeding and intestinal perforation. Since intestinal hemangiomas originate from the submucosal layer and some of them are transmural, endoscopic treatment might sometimes result in uncontrolled bleeding or perforation.

Hu PF, Chen H, Wang XH, Wang WJ, Su N, Shi B. Small intestinal hemangioma: Endoscopic or surgical intervention? A case report and review of literature. *World J Gastrointest Oncol* 2018; 10(12): 516-521  
URL: <https://www.wjgnet.com/1948-5204/full/v10/i12/516.htm>  
DOI: <https://dx.doi.org/10.4251/wjgo.v10.i12.516>

## INTRODUCTION

Hemangioma of the small intestine is a rare disease, accounting for 7%-10% of all benign tumors of the small intestine<sup>[1,2]</sup>. It may be solitary or multiple, with the jejunum being the most common site of involvement<sup>[3]</sup>. The main presenting symptoms include hemorrhage, abdominal pain, obstruction, intussusceptions, or rarely, perforation<sup>[4,5]</sup>. It originates from the submucosal vascular plexuses and may extend into the muscular layer or beyond<sup>[6]</sup>. Histologically, hemangiomas are congenital benign vascular lesions that can be classified as capillary, cavernous, or mixed-type according to the size of the vascular channels<sup>[2]</sup>. With the advent of capsule endoscopy (CE) and balloon-assisted enteroscopy (BAE), complete investigation of the small bowel is possible<sup>[7]</sup>. The preoperative diagnosis of this disease has been considerably improved. Recent advances in endoscopic techniques have led to successful endoscopic intervention, but most large lesions have been treated surgically. Here, we present a case with solitary small bowel hemangioma, which was diagnosed preoperatively by CE and BAE and removed successfully using minimally invasive surgery.

## CASE PRESENTATION

### Chief complaints

A 24-year-old female suffered from recurrent melena and fatigue for 1 year.

### History of present illness

Over the past year, the patient experienced repeated black stool, accompanied by fatigue, without hematemesis, hematochezia, abdominal pain or fever. The lowest level of hemoglobin was 42 g/L.

### History of past illness

Past and family medical history was unremarkable.

### Physical examination

Physical examination showed moderate anemia. Detailed dermatological evaluation did not show any cutaneous lesions.

### Laboratory testing

Laboratory studies revealed moderated microcytic and hypochromic anemia (hemoglobin, 7.5 g/dL). Fecal occult blood test was positive.

### Imaging examination

Gastroscopy and colonoscopy were normal. CE was performed, showing a prominent polypoid lesion in the ileum with no sign of active bleeding (Figure 1). Transanal double-balloon enteroscopy (DBE) revealed a reddish purple lesion in the ileum about 80 cm proximal to the ileocecal valve (Figure 2A). A titanium clip was used to mark the limit reached. Transoral DBE was performed to assess the remainder of small bowel, which revealed no additional lesions (Figure 2B).

## MULTIDISCIPLINARY EXPERT CONSULTATION

### Ping-Fang Hu, MD, Attending Doctor, Department of Gastroenterology

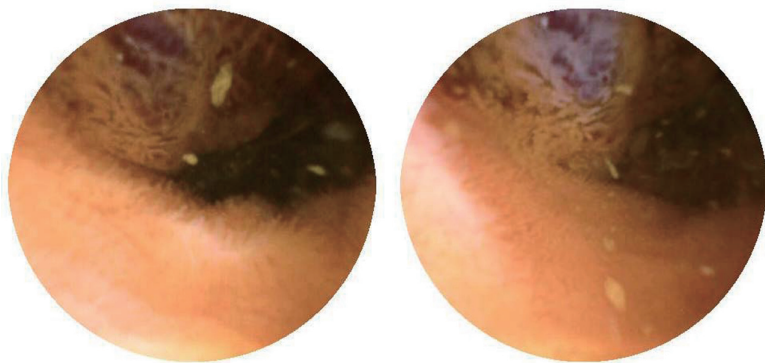
From the endoscopic appearance of the lesion, it was most likely a hemangioma. Considering that the lesion was large and diffuse, endoscopic interventions such as endoscopic mucosal resection (EMR) and endoscopic sclerotherapy might lead to uncontrolled bleeding or perforation. Therefore, laparoscopic surgery was deemed the best choice.

### Bin Shi, MD, Professor, Department of Gastroenterology

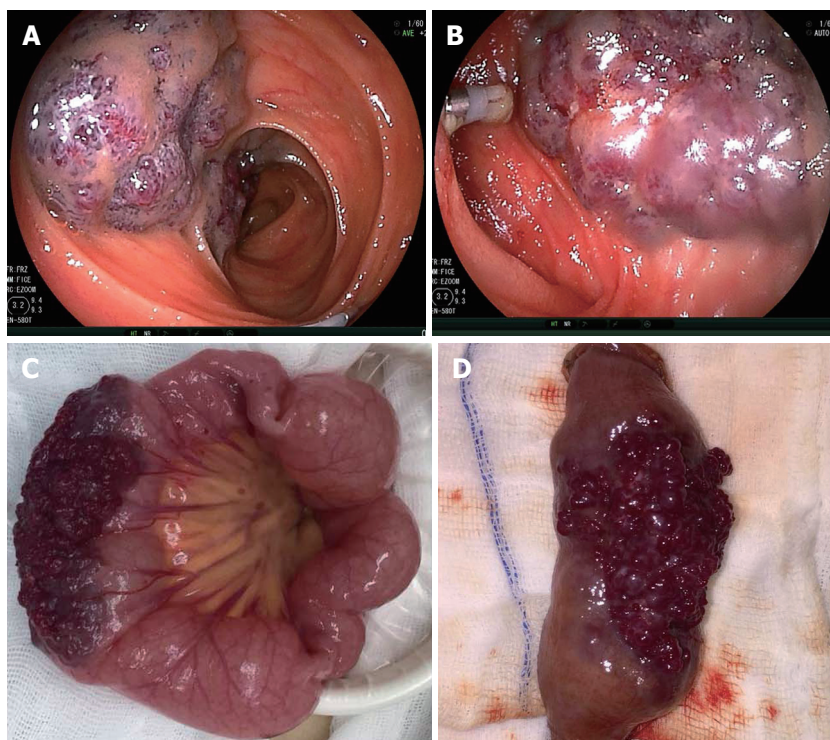
The patient had repeated bleeding and a large amount of bleeding every time. Since the lesion was large and diffuse, surgery would be better for the patient.

### Han Chen, MD, Attending Doctor, Department of Surgery

The patient suffered from recurrent melena in the past year. From the results of the CE and BAE, the cause



**Figure 1** Capsule endoscopic appearance of the lesion. Capsule endoscopy showed a prominent polypoid lesion in the ileum.



**Figure 2** Endoscopic and gross appearance of the lesion. A: Transanal double-balloon enteroscopy revealed a reddish purple lesion in the ileum about 80 cm proximal to the ileocecal valve, and a titanium clip was used to mark the limit reached; B: Transanal double-balloon enteroscopy showed the same lesion and the marked titanium clip; C: Gross intraoperative appearance of the lesion; D: Gross appearance of the lesion after resection.

is likely the small intestinal hemangioma. The surgical indication was explicit.

**Ning Su, MD, Attending Doctor, Department of Surgery**

The diagnosis is relatively clear. Since biopsy might lead to uncontrolled bleeding, we could not verify the diagnosis preoperatively.

**Wei-Jun Wang, Professor, Department of Surgery**

Imaging examination including ultrasound and CT scan did not find any abnormalities. From the endoscopic appearance of the lesion, it was most likely a hemangioma. The patient was a young female with a good health status. We could consider resecting the

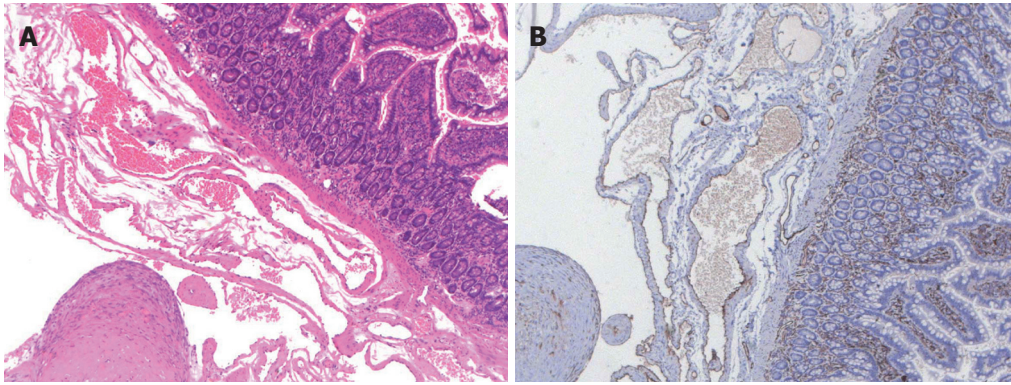
lesion laparoscopically.

## FINAL DIAGNOSIS

Small bowel bleeding and small intestinal hemangioma.

## TREATMENT

The patient was sent to laparoscopy, and a 5 cm × 3 cm × 3 cm purple-colored, raspberry-like lesion was found spreading diffusely along the serosal surface of the ileum (Figure 2C). The lesion was completely resected (Figure 2D). Hematoxylin-eosin staining (Figure 3A) and CD31 immunohistochemistry (Figure 3B) indicated



**Figure 3** Histopathological examination of the lesion. A: Hematoxylin-eosin staining showed a blood-filled sinus-like space in the whole layer of the ileum ( $\times 50$ ); B: Immunohistochemistry indicated the cells lined with the vascular spaces were CD31-positive ( $\times 50$ ).

a transmural cavernous hemangioma.

## OUTCOME AND FOLLOW-UP

The patient recovered quickly and had no further episodes of bleeding since the operation. The hemoglobin value increased to normal (12.4 g/dL) and was stable.

## DISCUSSION

Hemangioma accounts for only 0.05% of all gastrointestinal (GI) neoplasms. They mostly present with occult GI bleeding and iron deficiency anemia. Because of its rarity, it is not considered a common cause of GI bleeding. Previously, the preoperative diagnosis of this disease was difficult, and almost all cases were diagnosed during or after the operation<sup>[1]</sup>. With the introduction of CE and BAE over the past decades, the small intestine has now become an area that can be targeted<sup>[8]</sup>. We searched the PubMed database for studies about intestinal hemangiomas published after 2000 utilizing the following search terms: "hemangioma", "vascular malformation", "small intestine" and "small bowel". A manual search was also performed using the references of eligible articles. The language was limited to English. A total of 37 cases (16 women, 21 men, mean age 39 years) were retrieved and reviewed (Table 1). The most common manifestation included GI bleeding and anemia. A total of 75.7% (28/37) of the cases were single, and the common location of the small intestine was the jejunum (60.9%). Thirty-four of the 37 lesions (91.9%) were diagnosed before operation by CE and/or BAE. Of these cases, 11 were detected with CE alone, and 22 were diagnosed with both CE and BAE. Compared with the cases reported before 2000, a markedly increased proportion of cases were preoperatively diagnosed<sup>[1]</sup>. As in our case, CE was used to initially examine the GI tract, which was based on the algorithms for the diagnosis and treatment of obscure GI bleeding<sup>[7]</sup>. Both transanal DBE and transoral DBE were then performed to complete total enteroscopy, which was useful to localize the lesion and rule out

other lesions.

Surgical resection, which is relatively more invasive, is the conventional treatment modality for intestinal hemangiomas. With the improvement of endoscopic therapeutic interventions, less invasive procedures are becoming more widely employed. Of the 37 cases of intestinal hemangiomas published after 2000 (Table 1), 17 cases (45.9%) were treated endoscopically. Among them, 3 cases were removed by EMR, one case was treated by argon plasma coagulation, and 13 cases were subjected to sclerotherapy. Most of these lesions were multiple (14/17, 82.4%), and the lesions were relatively small. As suggested by the guideline on the management of small bowel bleeding, the patient should be managed with endoscopic therapy if a source of bleeding is found. Surgical treatment is generally regarded as a last resort<sup>[7]</sup>. Compared with surgery, endoscopic treatments including sclerotherapy and EMR are less invasive. However, they increase the potential risks of GI bleeding and intestinal perforation. Since intestinal hemangiomas originate from the submucosal layer, endoscopic treatment such as EMR is dangerous because of the risk of perforation. Endoscopic treatment might lead to perforation because some intestinal hemangiomas were transmural, as in our case. Considering that the hemangioma was large in the current case, uncontrolled bleeding would probably occur after endoscopic intervention. After discussion with a multidisciplinary team, which included gastroenterologists, endoscopists and surgeons, we decided to remove the lesion by laparoscopy. It turned out that a laparoscopic approach was likely the best choice for our case, as the lesion was relatively large and most importantly, transmural. Thus, endoscopic treatment of intestinal hemangioma should be prudent. It is likely suitable for multiple, relatively small lesions.

In conclusion, we present a case of small bowel hemangioma that was preoperatively diagnosed by CE and BAE and treated by laparoscopy. We believe it is important for both the endoscopist and surgeons to recognize this somewhat unusual lesion. It is recommended that careful consideration of the indications for



Table 1 Summary of hemangioma of small intestine reported after 2000

Ref.	Country	Case	Sex/age	Complaint	Diagnosis	Location	Single/multiple	Treatment	Pathology
Easler <i>et al</i> <sup>[9]</sup>	United States	1	M/71	Anemia, melena	BAE	Jejunum	Single	EMR	Cavernous
Ng <i>et al</i> <sup>[10]</sup>	China	1	F/20	Anemia	Small bowel enema	Terminal ileum	Multiple	APC	-
Wardi <i>et al</i> <sup>[11]</sup>	Israel	1	M/77	Anemia, melena	CE	Ileum	Single	Laparoscopy	Capillary
Ersoy <i>et al</i> <sup>[6]</sup>	Turkey	1	F/50	Melena, hematemesis	CE + BAE	Proximal jejunum	Single	Laparoscopy	Cavernous
Fernandes <i>et al</i> <sup>[12]</sup>	Portugal	1	F/56	Hematochezia, syncope	CE	Ileum	Single	Laparoscopy	Cavernous
Law <sup>[13]</sup>	China	1	F/31	Melena	CE + BAE	Jejunum	Single	Laparoscopy	Cavernous
Ning <i>et al</i> <sup>[4]</sup>	China	1	M/10	Melena	BAE	Jejunum/ileum	Multiple	Polidocanol injection	-
Elias <i>et al</i> <sup>[15]</sup>	United States	1	M/30	Anemia	CE + BAE	Jejunum	Multiple	Surgery	Cavernous
Shibuya <i>et al</i> <sup>[16]</sup>	Japan	1	M/74	Melena	CE + BAE	jejunum	Single	EMR	Capillary
Willert <i>et al</i> <sup>[6]</sup>	Australia	1	M/19	Anemia	CE + BAE	Jejunum/ileum	Multiple	EMR	Cavernous
Igawa <i>et al</i> <sup>[17]</sup>	Japan	12	6M/6F	Gastrointestinal bleeding	CE + BAE	Jejunum/ileum	7 single/5 multiple	Polidocanol injection	-
Takase <i>et al</i> <sup>[18]</sup>	Japan	2	F-62/M-52	Melena	CE + BAE	Jejunum/ileum	Single	Laparoscopy	Cavernous/capillary
Akazawa <i>et al</i> <sup>[19]</sup>	Japan	1	F/56	Melena	CE + BAE	Jejunum	Single	Laparoscopy	Cavernous
Chen <i>et al</i> <sup>[20]</sup>	United States	1	M/23	Fatigue	CE	Ileum	Single	Laparoscopy	Cavernous
Dhumane <i>et al</i> <sup>[21]</sup>	France	1	M/60	Anemia	CE + BAE	Jejunum	Single	Laparoscopy	Cavernous
Bae <i>et al</i> <sup>[22]</sup>	South Korea	1	M/13	Dizziness, fatigue	CE	Jejunum	Single	Laparoscopy	Cavernous
Huber <i>et al</i> <sup>[23]</sup>	Germany	1	M/23	Weakness, dizziness	CE + BAE	Jejunum	Single	Laparoscopy	Cavernous
Quentin <i>et al</i> <sup>[5]</sup>	France	1	F/32	Hematochezia	CE	Jejunum	Single	Laparoscopy	Cavernous
Khurana <i>et al</i> <sup>[24]</sup>	United States	1	M/62	Melena	BAE	Jejunum	Single	Surgery	Cavernous
Pera <i>et al</i> <sup>[25]</sup>	Spain	1	M/16	Fatigue	CE	Jejunum	Single	Laparoscopy	-
Pinho <i>et al</i> <sup>[26]</sup>	Portugal	1	F/9	Melena, anemia	CE	Ileum	Single	Surgery	Cavernous
Magnano <i>et al</i> <sup>[27]</sup>	Italy	1	M/13	Fatigue, malaise	CE	Ileum	Single	Laparoscopy	Cavernous
Kuo <i>et al</i> <sup>[28]</sup>	China	1	F/20	Abdominal pain	-	Jejunum	Single	Laparoscopy	Cavernous
Guardiola <i>et al</i> <sup>[29]</sup>	Spain	1	M/19	Anemia	CE	Ileum	Single	Laparoscopy	Cavernous
Purdy-Payne <i>et al</i> <sup>[30]</sup>	United States	1	F/20	Abdominal pain	-	Terminal ileum	Single	Laparoscopy	Cavernous

CE: Capsule endoscopy; BAE: Balloon assisted enteroscopy; EMR: Endoscopic mucosal resection; APC: Argon plasma coagulation.

endoscopic treatment. As in our case, hemangiomas may sometimes involve the entire wall of the intestine. Endoscopic intervention may lead to uncontrolled bleeding or perforation. For the large and diffuse lesions, a laparoscopic excision might be a better approach.

EXPERIENCES AND LESSONS

Hemangioma of the small intestine is a rare disease, which mostly presented as occult GI bleeding and iron deficiency anemia. With the advent of CE and BAE, the diagnosis of lesions in the small intestine has been considerably improved. Endoscopic treatment of intestinal hemangioma should be prudent, and it might be suitable for multiple and relatively small lesions.

REFERENCES

1 Ramanujam PS, Venkatesh KS, Bettinger L, Hayashi JT, Rothman MC, Fietz MJ. Hemangioma of the small intestine: case report and literature review. *Am J Gastroenterol* 1995; 90: 2063-2064 [PMID: 7485031]  
2 Kumar N, Adam SZ, Goodhartz LA, Hoff FL, Lo AA, Miller FH. Beyond hepatic hemangiomas: the diverse appearances of gastrointestinal and genitourinary hemangiomas. *Abdom Imaging* 2015; 40: 3313-3329 [PMID:



- 26239397 DOI: 10.1007/s00261-015-0515-8]
- 3 **Quentin V**, Lermite E, Lebigot J, Marannes MZ, Arnaud JP, Boyer J. Small bowel cavernous hemangioma: wireless capsule endoscopy diagnosis of a surgical case. *Gastrointest Endosc* 2007; **65**: 550-552 [PMID: 17321267 DOI: 10.1016/j.gie.2006.12.024]
  - 4 **Rao AB**, Pence J, Mirkin DL. Diffuse infantile hemangiomatosis of the ileum presenting with multiple perforations: a case report and review of the literature. *J Pediatr Surg* 2010; **45**: 1890-1892 [PMID: 20850639 DOI: 10.1016/j.jpedsurg.2010.05.019]
  - 5 **Ruiz AR Jr**, Ginsberg AL. Giant mesenteric hemangioma with small intestinal involvement: an unusual cause of recurrent gastrointestinal bleed and review of gastrointestinal hemangiomas. *Dig Dis Sci* 1999; **44**: 2545-2551 [PMID: 10630511 DOI: 10.1023/A:1026659710815]
  - 6 **Ersay O**, Akin E, Demirezer A, Koseoglu H, Balci S, Kiyak G. Cavernous haemangioma of small intestine mimicking gastrointestinal stromal tumour. *Arab J Gastroenterol* 2013; **14**: 139-140 [PMID: 24206746 DOI: 10.1016/j.ajg.2013.08.008]
  - 7 **Gerson LB**, Fidler JL, Cave DR, Leighton JA. ACG Clinical Guideline: Diagnosis and Management of Small Bowel Bleeding. *Am J Gastroenterol* 2015; **110**: 1265-1287; quiz 1288 [PMID: 26303132 DOI: 10.1038/ajg.2015.246]
  - 8 **Willert RP**, Chong AK. Multiple cavernous hemangiomas with iron deficiency anemia successfully treated with double-balloon enteroscopy. *Gastrointest Endosc* 2008; **67**: 765-767 [PMID: 18155208 DOI: 10.1016/j.gie.2007.07.044]
  - 9 **Easler JJ**, Papachristou GI. A case of obscure gastrointestinal bleeding. *Gastroenterology* 2012; **142**: 700, 1044 [PMID: 22370215 DOI: 10.1053/j.gastro.2011.09.009]
  - 10 **Ng EK**, Cheung FK, Chiu PW. Blue rubber bleb nevus syndrome: treatment of multiple gastrointestinal hemangiomas with argon plasma coagulator. *Dig Endosc* 2009; **21**: 40-42 [PMID: 19691801 DOI: 10.1111/j.1443-1661.2008.00817.x]
  - 11 **Wardi J**, Shahmurov M, Czerniak A, Avni Y. Clinical challenges and images in GI. Capillary hemangioma of small intestine. *Gastroenterology* 2007; **132**: 1656, 2084 [PMID: 17484862 DOI: 10.1053/j.gastro.2007.03.081]
  - 12 **Fernandes D**, Dionisio I, Neves S, Duarte P. Cavernous hemangioma of small bowel: a rare cause of digestive hemorrhage. *Rev Esp Enferm Dig* 2014; **106**: 214-215 [PMID: 25007019]
  - 13 **Law WL**. Cavernous hemangioma: uncommon cause of obscure gastrointestinal bleeding. *J Am Coll Surg* 2007; **205**: 511 [PMID: 17765169 DOI: 10.1016/j.jamcollsurg.2006.10.035]
  - 14 **Ning S**, Zhang Y, Zu Z, Mao X, Mao G. Enteroscopic sclerotherapy in blue rubber bleb nevus syndrome. *Pak J Med Sci* 2015; **31**: 226-228 [PMID: 25878650 DOI: 10.12669/pjms.311.5858]
  - 15 **Elias G**, Toubia N. Hemangioma of the small intestine presenting with recurrent overt, obscure gastrointestinal bleeding. *Clin Gastroenterol Hepatol* 2010; **8**: A18, A18.e1 [PMID: 19362610 DOI: 10.1016/j.cgh.2009.03.036]
  - 16 **Shibuya T**, Osada T, Mitomi H, Takeda T, Nomura O, Nakayama H, Hidaka Y, Mori H, Beppu K, Sakamoto N, Nagahara A, Otaka M, Ogihara T, Yao T, Watanabe S. Jejunal capillary hemangioma treated by using double-balloon endoscopy (with video). *Gastrointest Endosc* 2010; **72**: 660-661 [PMID: 20546731 DOI: 10.1016/j.gie.2009.12.051]
  - 17 **Igawa A**, Oka S, Tanaka S, Kuniyama S, Nakano M, Chayama K. Polidocanol injection therapy for small-bowel hemangioma by using double-balloon endoscopy. *Gastrointest Endosc* 2016; **84**: 163-167 [PMID: 26907744 DOI: 10.1016/j.gie.2016.02.021]
  - 18 **Takase N**, Fukui K, Tani T, Nishimura T, Tanaka T, Harada N, Ueno K, Takamatsu M, Nishizawa A, Okamura A, Kaneda K. Preoperative detection and localization of small bowel hemangioma: Two case reports. *World J Gastroenterol* 2017; **23**: 3752-3757 [PMID: 28611528 DOI: 10.3748/wjg.v23.i20.3752]
  - 19 **Akazawa Y**, Hiramatsu K, Nosaka T, Saito Y, Ozaki Y, Takahashi K, Naito T, Ofuji K, Matsuda H, Ohtani M, Nemoto T, Suto H, Yamaguchi A, Imamura Y, Nakamoto Y. Preoperative diagnosis of cavernous hemangioma presenting with melena using wireless capsule endoscopy of the small intestine. *Endosc Int Open* 2016; **4**: E249-E251 [PMID: 27004239 DOI: 10.1055/s-0041-111321]
  - 20 **Chen CH**, Jones J, McGowan P. Profound iron deficiency anemia caused by a small-intestinal cavernous hemangioma. *Gastrointest Endosc* 2009; **69**: 1392-1393; discussion 1393 [PMID: 19481664 DOI: 10.1016/j.gie.2009.01.049]
  - 21 **Dhumane P**, Mutter D, D'Agostino J, Mavrogenis G, Leroy J, Marescaux J. Small bowel exploration and resection using single-port surgery: a safe and feasible approach. *Colorectal Dis* 2013; **15**: 109-114 [PMID: 22672499 DOI: 10.1111/j.1463-1318.2012.03118.x]
  - 22 **Bae SJ**, Hwang G, Kang HS, Song HJ, Chang WY, Maeng YH, Kang KS. Single Cavernous Hemangioma of the Small Bowel Diagnosed by Using Capsule Endoscopy in a Child with Chronic Iron-Deficiency Anemia. *Clin Endosc* 2015; **48**: 340-344 [PMID: 26240811 DOI: 10.5946/ce.2015.48.4.340]
  - 23 **Huber A**, Abdel Samie A, Kychenko D, Theilmann L. A rare cause of recurrent iron-deficiency anemia: cavernous hemangioma of the small intestine. *J Gastrointest Liver Dis* 2012; **21**: 343 [PMID: 23256111]
  - 24 **Khurana V**, Dala R, Barkin JS. Small bowel cavernous hemangioma. *Gastrointest Endosc* 2004; **60**: 96 [PMID: 15229433 DOI: 10.1016/S0016-5107(04)01292-1]
  - 25 **Pera M**, Márquez L, Dedeu JM, Sánchez J, García M, Ramón JM, Puigvehí M. Solitary cavernous hemangioma of the small intestine as the cause of long-standing iron deficiency anemia. *J Gastrointest Surg* 2012; **16**: 2288-2290 [PMID: 22875598 DOI: 10.1007/s11605-012-1991-6]
  - 26 **Pinho R**, Rodrigues A, Proença L, Silva AP, Fernandes S, Leite S, Amaral I, de Sousa P, Fraga J. Solitary hemangioma of the small bowel disclosed by wireless capsule endoscopy. *Gastroenterol Clin Biol* 2008; **32**: 15-18 [PMID: 18405648 DOI: 10.1016/j.gcb.2007.11.004]
  - 27 **Magnano A**, Privitera A, Calogero G, Nanfity L, Basile G, Sanfilippo G. Solitary hemangioma of the small intestine: an unusual cause of bleeding diagnosed at capsule endoscopy. *J Pediatr Surg* 2005; **40**: e25-e27 [PMID: 16226971 DOI: 10.1016/j.jpedsurg.2005.06.014]
  - 28 **Kuo LW**, Chuang HW, Chen YC. Small bowel cavernous hemangioma complicated with intussusception: report of an extremely rare case and review of literature. *Indian J Surg* 2015; **77**: 123-124 [PMID: 25972669 DOI: 10.1007/s12262-014-1194-3]
  - 29 **Guardiola A**, Navajas J, Valle J, López-Pardo R, Rodríguez-Merlino R, Lombera Mdel M, Alcántara M. Small bowel giant cavernous hemangioma diagnosed by capsule endoscopy. *Rev Esp Enferm Dig* 2012; **104**: 277-278 [PMID: 22662783 DOI: 10.4321/S1130-01082012000500011]
  - 30 **Purdy-Payne EK**, Miner JF, Foles B, Tran TA. The "Endothelialized Muscularis Mucosae": A Case Report Describing a Large Cavernous Hemangioma at the Terminal Ileum and a New Histologic Clue for Preoperative Diagnosis from Endoscopic Biopsy. *Case Rep Gastrointest Med* 2015; **2015**: 454836 [PMID: 26442160 DOI: 10.1155/2015/454836]

**P-Reviewer:** Cao ZF, Sawaki A, Yarema RR **S-Editor:** Ji FF  
**L-Editor:** Filipodia **E-Editor:** Song H





Published by **Baishideng Publishing Group Inc**  
7901 Stoneridge Drive, Suite 501, Pleasanton, CA 94588, USA  
Telephone: +1-925-223-8242  
Fax: +1-925-223-8243  
E-mail: [bpgoffice@wjgnet.com](mailto:bpgoffice@wjgnet.com)  
Help Desk: <https://www.f6publishing.com/helpdesk>  
<https://www.wjgnet.com>

